

We are IntechOpen, the world's leading publisher of Open Access books Built by scientists, for scientists

6,900

Open access books available

186,000

International authors and editors

200M

Downloads

Our authors are among the

154

Countries delivered to

TOP 1%

most cited scientists

12.2%

Contributors from top 500 universities



WEB OF SCIENCE™

Selection of our books indexed in the Book Citation Index
in Web of Science™ Core Collection (BKCI)

Interested in publishing with us?
Contact book.department@intechopen.com

Numbers displayed above are based on latest data collected.
For more information visit www.intechopen.com



Oral Mucosal Melanosis

Liviu Feller, Razia A.G. Khammissa and
Johan Lemmer

Additional information is available at the end of the chapter

<http://dx.doi.org/10.5772/65567>

Abstract

In the mouth, melanin is produced by melanocytes residing in the basal cell layer of the oral epithelium. Melanin influences the colour of the oral mucosa and provides protection against reactive oxygen species and bacterial-derived enzymes and toxins and acts as a physical barrier to both microorganisms invading the oral epithelium and to other microenvironmental stressors. The functional activity of epithelial melanocytes is regulated by biological agents in the microenvironment, including proopiomelanocortin-derived peptides, and by reciprocal interactions between melanocytes on the one hand and neighbouring keratinocytes and signals from the underlying lamina propria on the other hand. Oral mucosal melanin hyperpigmentation is common and may be physiological or pathological, and in either case the pattern of distribution and the intensity of the melanosis are variable. Physiological melanin hyperpigmentation is the result of increased melanin biosynthesis by melanocytes in the basal cell layer of the oral epithelium, but pathological melanin pigmentation may be the result of increased number of normal melanocytes or atypical melanocytes, of increased melanogenic activity of normal or atypical melanocytes, or of both. Oral mucosal melanin hyperpigmentation may be secondary to disease, medications, or smoking, and physiological oral melanin hyperpigmentation may be clinically and histopathologically similar so that the differentiation between pathological and physiological oral melanosis can at times be difficult.

Keywords: oral mucosa, melanocytes, melanosomes, melanotic macule, melanoma, naevus, physiological oral pigmentation

1. Introduction

There are both melanin-producing and amelanotic melanocytes in the oral stratified squamous epithelium, and the degree of melanin pigmentation of the oral mucosa is genetically determined. Dark-skinned persons more often have physiological oral mucosal melanin

hyperpigmentation than do light-skinned persons. Regardless of race/ethnicity, the number and the distribution of melanocytes are very much the same within each oral anatomical region but vary from region to region. Even when there is no obvious pigmentation, oral mucosal melanocytes are always present and produce some melanin but the amount produced is determined by their melanogenic activity [1–4].

The vascularity, the blood haemoglobin concentration, the degree of keratinization of the epithelium, and the type and amount of melanin pigment present are variable determinants of the colour of the oral mucosa. The degree of melanin pigmentation *per se* is determined by the number and distribution of melanocytes in the basal cell layer of the oral epithelium of each anatomical region, by their melanogenic activity, by the degree of arborisation of the dendritic processes of the melanocytes, and by the number, size, and distribution of melanosomes in the ‘melanocyte-keratinocyte unit’ [4–6].

Most of the information on the physiology of oral mucosal melanocytes is derived from research on epidermal melanocytes. Oral mucosal and epidermal melanocytes are histologically and ultrastructurally similar, but under physiological conditions, it seems that the former are intrinsically less metabolically active. However, in response to chemical or physical environmental triggers, to certain drugs and hormones, to inflammation, and in association with certain systemic diseases or neoplastic processes, the metabolism of oral melanocytes may increase with consequent increase in biosynthesis of melanin [4, 6]. The intracellular and the microenvironmental molecular signalling pathways that drive the development of oral mucosal melanin pigmentation remain largely unknown [7].

Brown/black eumelanin and yellow/red pheomelanin are pigmented polymers synthesized in unique organelles called melanosomes within melanocytes. Melanin has the capacity to scavenge reactive oxygen species and to neutralize microorganisms and their harmful products. Melanocytes also contribute to the homeostasis of skin and oral mucosa by acting as neuroendocrine cells secreting neuropeptides and as antigen presenting cells and phagocytes [4, 6, 8, 9].

Upregulation of melanin biosynthesis or increase in the number either of normal or of atypical oral mucosal melanocytes may bring about oral mucosal melanin hyperpigmentation. Physiological and pathological oral mucosal melanin hyperpigmentations may be similar in appearance, and sometimes may be difficult to differentiate even on the basis of history and microscopical features. Pathological oral mucosal melanin hyperpigmentations include those related to tobacco smoke, to certain systemic diseases or syndromes, to inflammatory processes, to certain drugs, and to developmental, benign, or malignant changes in melanocytes [4, 6, 10–13].

Engaging in any clinical or histopathological study on oral mucosal melanin hyperpigmentation is complex. Many subjects with oral mucosal melanin hyperpigmentation, whether physiological or pathological in origin, are usually unaware of it so cannot give information about its duration or progression. Oral mucosal melanin hyperpigmentation secondary to disease and physiological oral mucosal melanin hyperpigmentation may be clinically and histopathologically similar, and in some cases, it is almost impossible to determine whether oral mucosal melanin hyperpigmentation is physiological or is induced by smoking, by drugs, or by both.

Not all biological, physical, or chemical factors that may promote melanogenesis are known, neither are all the factors that may influence the size, distribution, or intensity of areas of oral pigmentation. Further research is needed to elucidate these issues; and into the roles that melanocytes and melanin play in the maintenance of homeostasis of the oral mucosa, as well as into the roles physiological or benign oral mucosal melanin hyperpigmentations may play as precursors of premalignant and malignant oral melanotic lesions.

In this chapter, we briefly review some aspects of the biology and physiology of oral melanocytes, the function of melanin in the oral epithelium, and the features of several different oral mucosal melanin hyperpigmentations, including physiological hyperpigmentation, tobacco-related melanosis, human immunodeficiency virus (HIV)-associated melanosis, melanotic maculae, naevomelanocytic naevus, and oral mucosal melanoma.

2. The biology of oral melanocytes

Melanocytes originate from neural crest precursor cells, which during embryogenesis migrate from the neural crest to their ultimate destination in the basal cell layer of the epidermis and of the epithelium of mucous membranes where they differentiate into mature melanin-producing melanocytes with complex network of dendritic processes [14]. However, some neural crest cells in their process of migration to the epithelium may become arrested in the lamina propria/dermis, remaining there in an immature state. These arrested immature melanocytes also sometimes termed naevomelanocytes, can become active, forming nests of cells giving rise to dermal/intra lamina propria naevi, and rarely to melanomata at those sites [15].

It is not clear whether the replacement of melanocytes of the basal cell layer of the oral epithelium lost to physiological processes of apoptosis or senescence, or to mechanical, thermal, or chemical injury is the result of cell division of 'mature' melanocytes in the basal cell layer of the oral epithelium which still retain their capacity of replication, or a result of migration from their local niche reservoirs of melanocyte stem/progenitor cells and their subsequent proliferation [6].

The mechanism by which the population of melanocytes of the oral epithelium is maintained in a steady state is unknown [7]. While melanocyte stem/progenitor cells and their reservoir niche have been identified in the skin, in the oral mucosa they have not been found [6, 15]. Tissue-specific melanocyte stem/progenitor cells are, however, relatively undifferentiated, divide infrequently, and have the capacity for self-renewal thus maintaining the genetic information necessary for regeneration of the population of melanin-producing melanocytes [16].

The ratio of melanocytes to keratinocytes in the basal cell layer of the oral epithelium, measured linearly, ranges from 1:10 to 1:15 [17]. However, this ratio varies at different oral mucosal sites of the same persons, but is similar in the same oral sites of different persons, regardless of their race/ethnicity [18, 19]. Melanocytes in the basal cell layer of the epithelium are connected to and communicate with their immediate neighbouring keratinocytes by means of tight junctions and gap junctions. Expression of E-cadherin cell adhesion molecules

suppresses melanocyte proliferation, but on the other hand, expression of N-cadherin triggered by trauma or metabolic changes in the microenvironment promotes proliferation and migration of melanocytes, which can then aggregate in nests [4, 6].

It has been suggested that keratinocytes, through the release of biological mediators, pro-opiomelanocortin (POMC)-derived peptides, basic fibroblast growth factor, and endothelins, regulate proliferation and differentiation of melanocytes and stimulate melanogenesis through receptor-mediated signalling pathways [20].

Melanin is produced in melanosomes within the melanocytes in the basal cell layer of the oral epithelium. Mature melanin-containing melanosomes are transported from a perinuclear position in the cytoplasm of the melanocytes into and along microtubules towards the end of the dendritic processes, borne by the motor proteins kinesin and dynein. At the tip of the arborising dendritic processes, the melanosomes are transferred to neighbouring keratinocytes [4, 6, 21, 22]. It appears that each melanocyte is in contact with about 35 neighbouring keratinocytes in the basal and suprabasal cell layers of the epithelium, each forming a 'melanocyte-keratinocyte unit' [4, 6, 7].

3. Functions of melanocytes

Melanin influences the colour of the skin, oral mucosa, hair, and eyes. Melanin can also inactivate reactive oxygen species and free radicals, can sequester redox-active metals and organic toxic compounds, can neutralize bacteria-derived enzymes and toxins, and can downregulate inflammatory processes [4, 6, 7].

In the process of ascending through the cell layers of the epithelium to the surface desquamating layer, melanosomes lost from keratinocytes that form part of the melanocyte-keratinocyte unit disintegrate, releasing melanin 'dust' into the microenvironment. As melanin has strong binding properties, it can act as a physical barrier to both microorganisms invading the skin or mucous membrane and to other environmental stressors [4, 6, 7].

Although melanin itself provides protection against reactive oxygen species (ROS) and toxic free radicals, paradoxically, the biosynthesis of melanin itself generates ROS that may cause DNA damage; and quinones and semiquinones, which are intermediates of melanin biosynthesis, are mutagenic with the capacity to cause cytogenetic instability. Therefore, loss of the integrity of melanosome membranes with leakage of these intrinsic toxic agents has the potential to cause self-injury to the melanocytes [6].

Apart from the beneficial effects and detrimental side effects of melanin production, melanocytes can also protect against microbial infections by acting as antigen-presenting cells producing cytokines, phagocytosing microorganisms, and degrading both phagocytosed bacteria and bacteria in the microenvironment by means of melanosomal lysosomal enzymes [4, 6, 7].

Melanocytes can also function as neuroendocrine cells by producing acetylcholine, catecholamines, and POMC-derived peptides, which have the capacity to mediate local

immunoinflammatory and antimicrobial responses and to modulate the biological behaviour of oral tissues [4]. Melanocytes function as stress sensors, as immunocytes, and as neuroendocrine cells, thus playing several important roles in maintaining tissue homeostasis [23–25].

The functional activity of epithelial melanocytes is regulated by the reciprocal interaction of melanocytes in the basal cell layer of the epithelium with the underlying lamina-propria connective tissue and by several other biological agents. These include the POMC-derived peptides released by neighbouring keratinocytes and the neuropeptide calcitonin gene-related peptide, substance P, and neuropeptide Y released from intramucosal free nerve endings, which are in close contact with melanocytes in the basal cell layer of the epithelium. Adrenergic and cholinergic agents, growth factors, inflammatory mediators, and other autocrine and endocrine stimuli also contribute to the regulation of the functional activity of melanocytes [6].

4. Melanin biosynthesis

Premelanosomes contain all the proteins and enzymes required for their maturation to the fully functional specialised membrane-bound organelles called melanosomes, which are the sites of biosynthesis of melanin [26, 27]. The fully functional melanosomes contain all the proteins and enzymes required for biosynthesis of melanin, and the structural matrix proteins form an internal scaffold both to support the architecture of the melanosomes and to serve as a nidus for melanin deposition [22].

The melanosomes in melanocytes residing in the basal cell layer of the epithelium can synthesise two chemically distinct types of melanin: brown/black eumelanin and red/yellow pheomelanin, both of which are derivatives of the amino acid tyrosine through the intermediate step of conversion of dopa to dopamine [4]. Both eumelanin and pheomelanin can be produced in the same melanocyte, but by different melanosomes. Eumelanosomes and pheomelanosomes differ in shape and in their patterns of internal melanin deposition. Eumelanosomes are elliptical and characterized by longitudinal deposition of the pigment; and pheomelanosomes are spherical, characterized by granular deposition of the melanin [4]. The ratio of eumelanin to pheomelanin is genetically determined by a number of factors including the degree of base-line functional activity of the enzymes and proteins driving the 'mixed melanogenesis', by the melanocortin 1 receptor (MC1R) genetic polymorphism, and by the amount of the tyrosine in the melanosome [6].

The following agents are important in melanin biosynthesis. Tyrosinase drives the complex conversion of tyrosine to melanin. p protein is involved in stabilizing the melanosomal protein complex, in regulating the melanosomal pH, and in transporting the requisite proteins to the melanosomes. Tyrosinase-related protein 1 stabilizes the enzyme tyrosinase and is involved in melanosome maturation, and tyrosinase-related protein 2 modulates the quantity and quality of the melanin produced. The membrane-associated transport protein (MATP) functions as its name implies [5, 28].

5. Regulation of melanin biosynthesis and distribution

Upregulation of melanin biosynthesis may be triggered by external stimuli, such as radiation, tobacco smoke, certain drugs, and endogenous paracrine and endocrine agents. POMC-derived peptides including adrenocorticotropin (ACTH), alpha melanocyte stimulating hormone (α -MSH), β -MSH and β -endorphins, MC1R, adrenergic and cholinergic agents, and growth factors, cytokines, or nitric oxide (NO) secreted in the local microenvironment are all involved in the regulation of melanogenesis [6].

POMC-derived peptides, particularly α -MSH, stimulate MC1R of melanocytes, releasing the intracellular second messenger cAMP, which in turn induces a cascade of intracellular molecular events, ultimately activating the microphthalmia-associated transcription factor (MITF). This is the master regulator of genes driving the process of melanogenesis. Thus, the α -MSH/MC1R/cAMP/MITF molecular signalling pathway is fundamental to melanin biosynthesis and to a great extent determines the type and amount of the melanin produced [4, 6]. The MC1R gene is highly polymorphic; the most common MC1R variant promotes eumelanin production, but other germline variants are associated with increased pheomelanin and decreased eumelanin biosynthesis [6].

β -endorphin, the POMC-derived opioid peptide, has the capacity to upregulate melanogenesis and melanin distribution by promoting maturation of melanocytes and arborisation of their dendritic processes, thus increasing the efficacy of the transfer and distribution of melanosomes to neighbouring keratinocytes [23, 29].

Non-neural adrenergic and cholinergic signalling pathways are expressed by melanocytes. Activation of adrenalin/ β 2-adrenoreceptor/cAMP/MITF and of noradrenalin/ α 1-adrenoreceptor/cAMP/MITF also induces melanin biosynthesis and arborisation of melanocytic dendrites. Activation of nicotine receptors on oral melanocytes by acetylcholine or by nicotine may bring about melanin hyperpigmentation [4, 6, 30].

Inflammatory mediators can induce production of prostaglandin E_2 (PGE_2) and NO, which in turn have the capacity to promote maturation and increase transport of melanosomes, to upregulate the expression of the tyrosinase gene, and to increase the complexity of the network of melanocytic dendrites. PGE_2 and NO together promote melanogenesis and melanin deposition [4, 6, 31, 32].

To the best of our knowledge, the role that the melanocortin, adrenergic, and cholinergic systems play in relation to melanogenesis in the oral mucosa has not been demonstrated, and current knowledge of these systems is from research on epidermal melanin.

6. Oral mucosal melanin hyperpigmentation

Oral mucosal melanin hyperpigmentation is common and may be physiological (racial) or pathological [4, 6]. In either case, the pattern of distribution and the intensity of the pigmentation are

variable. The pigmentation may be the result of an increase in the number of melanocytes in the basal cell layer of the oral epithelium, or of increased melanin biosynthesis by the melanocytes. Sometimes pathological hyperpigmentation may be brought about by hyperplasia or increased melanogenesis of atypical melanocytes [33]. Melanogenically active melanocytes/nevomelanocytes in the lamina propria also have the capacity to cause oral mucosal melanin hyperpigmentation [34]. Occasionally histopathological examination of a biopsy specimen from a pigmented lesion is needed to rule out a malignancy.

6.1. Physiological oral mucosal melanin hyperpigmentation

Physiological oral mucosal melanin hyperpigmentation manifests clinically as asymptomatic, single or multiple, well-demarcated or ill-defined patchy or uniform macules which range in colour from light to dark brown or black, and are of variable size and configuration. It may affect any part of the oral mucosa, but most frequently the gingiva, where it is usually bilaterally symmetrical, does not transgress the mucogingival junction, and does not involve the marginal gingiv (**Figure 1**) [4, 6]. Physiological gingival melanin hyperpigmentation is often more pronounced in the anterior than in the posterior part of the mouth, and the buccal/labial surfaces are more intensely pigmented than the lingual/palatal [35].

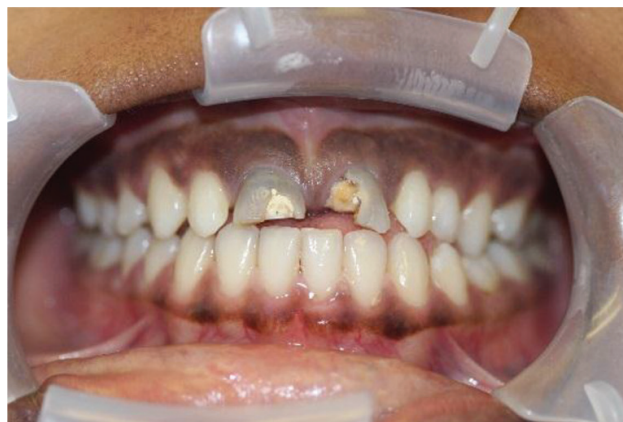

Figure 1. Generalized black-brown physiological melanin hyperpigmentation of the maxillary and mandibular gingiva, not transgressing the mucogingival junction. The patient's main concern was her carious incisors.

Physiological oral mucosal melanin hyperpigmentation is very common in Blacks, in general is more frequent in darker-skinned than in lighter-skinned persons regardless of their race/ethnicity, and is most probably caused by genetically determined metabolic hyperactivity of oral melanocytes. It affects males and females equally and usually develops during the first three decades of life. Many persons with oral mucosal melanin hyperpigmentation are unaware of its presence [7]. According to some publications, the extent and the intensity of physiological oral mucosal melanin hyperpigmentation increase with age probably owing to the cumulative effects of endogenous and extrinsic melanogenic stimuli, such as inflammatory processes, drugs, tobacco smoke, and recurrent minor functional injuries [4, 6, 11, 13].

In physiological oral mucosal melanin hyperpigmentation there is no increase in the number of melanocytes, but there is increased melanin in melanocytes in the basal cell layer of the oral epithelium, in the 'melanocyte-keratinocyte units', and in the lamina propria within melanophages. Occasionally, extracellular particles of pigment may be observed. These microscopical features are very similar to those observed in idiopathic melanotic macules, in melanosis related to smoking tobacco or inflammation, in melanosis induced by certain medications, and in HIV melanosis [11, 36]. Therefore, a thorough medical history may be helpful for differential diagnosis, but the differentiation of physiological oral mucosal melanin hyperpigmentation from single or multiple melanotic macules based on medical history and on clinical and histological grounds may be impossible as they share the same clinical and microscopical features and both may develop at a young age. It is also almost impossible to determine whether the oral mucosal melanin hyperpigmentation in an HIV-seropositive smoker who is on multiple drug therapy is owing to the medication, to the HIV infection, to the use of tobacco, or to the interaction between these factors.

Physiological melanin hyperpigmentation does not require treatment, but if for cosmetic reasons it has to be removed, laser or cryotherapy or surgical excision are often successful. However, recurrence is not uncommon most probably because treatment does not always completely eliminate the genetically programmed hyperactive melanocytes in the epithelial field surrounding the hyperpigmentation [4].

6.2. Inflammation-associated oral mucosal melanin hyperpigmentation

Under circumstances that are not well defined, certain inflammatory cytokines and mediators have the capacity to promote the production of α -MSH by oral melanocytes and keratinocytes and to upregulate the expression of MC1R of melanocytes resulting in increased biosynthesis of melanin. Independently of this α -MSH/MC1R pathway, PGE_2 can promote tyrosinase activity and arborisation of melanocytic dendrites. Thus, melanin hyperpigmentation may develop at chronically inflamed oral mucosal sites, as in association with repetitive local trauma or injury or with immunoinflammatory pathological conditions, such as oral lichen planus and oral lichenoid reactions [37].

Such inflammation-associated oral mucosal melanin hyperpigmentation occurs most commonly in darker skinned persons and usually manifests as single or multiple brown-black patches, which may persist for a long time after the resolution of the inflammatory process [6, 11, 37]. These inflammation-associated hyperpigmented patches are of no clinical significance, their biological significance is unknown, and treatment is not required.

6.3. Tobacco-related oral melanosis

Tobacco smoking may cause diffuse brown-black hyperpigmentation of the oral mucosa in 20–30% of chronic heavy smokers. This usually affects the gingiva, palate, and the buccal mucosa, and the intensity of the pigmentation is related to total tobacco usage. It has been suggested that the melanin produced in response to cigarette smoking is a protective reaction, contributing to the detoxification of polyaromatics, nicotine, and benzopyrene in the tobacco smoke. Smoker's melanosis may gradually diminish if the smoking habit is stopped. Importantly, smoker's melanosis does not undergo malignant transformation [11, 36].

As in differentiating some other cases of oral mucosal melanin hyperpigmentations one from another, on clinical and histological grounds alone it is impossible to make a positive diagnosis of tobacco-related melanosis.

6.4. Human immunodeficiency virus (HIV)-associated and medication-induced oral mucosal melanin hyperpigmentations

Oral melanin hyperpigmentation is common in HIV-seropositive subjects. It may develop secondarily to HIV-induced cytokine dysregulation, to medications used in the treatment of HIV infection or HIV-associated diseases (zidovudine, clofazimine and ketoconazole), or to adrenocortical deficiency, which is not infrequent in HIV-seropositive subjects with a low CD4⁺ T cell counts [6, 10].

It is unknown whether structural proteins of HIV can stimulate melanocyte activity directly to upregulate their melanin biosynthesis. It is possible that HIV-associated mucosal hyperpigmentation may fortuitously represent a local protective immune reaction against subclinical oral infections and concomitant inflammatory processes. Indeed, it has been suggested that certain cytokines that are upregulated during HIV infection have the capacity to induce the production of α -MSH by oral melanocytes and keratinocytes and to mediate the upregulation of expression of MC1R by melanocytes, resulting in increased melanin production. In some HIV-seropositive subjects, this may trigger oral mucosal melanin hyperpigmentation [6, 14].

If it occurs, HIV-associated oral mucosal melanin hyperpigmentation usually develops within 2 years of contracting HIV or within a few months of starting antiretroviral treatment with the drug zidovudine. Typically, it manifests clinically either as solitary or multiple dark melanotic macules (**Figure 2a, b**) or as diffuse brownish or brown-black areas of melanin hyperpigmentation (**Figure 3**). This may involve any part of the oral mucosa but most frequently the buccal mucosa, affecting females and males equally [6, 14].

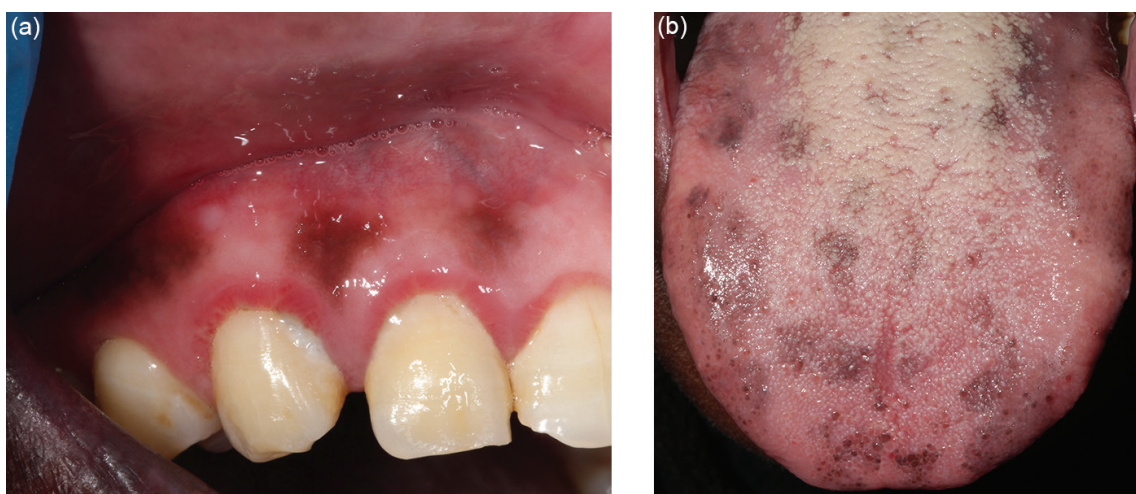


Figure 2. (a) Multiple pigmented maculae of the maxillary labial attached gingiva in a 32-year-old HIV-seropositive female with a CD4⁺ T cell count of 425 cells/mm³. (b) Multiple pigmented maculae of the dorsum of the tongue in a 42-year-old HIV-seropositive female on HAART with a CD4⁺ T cell count of 176 cells/mm³.

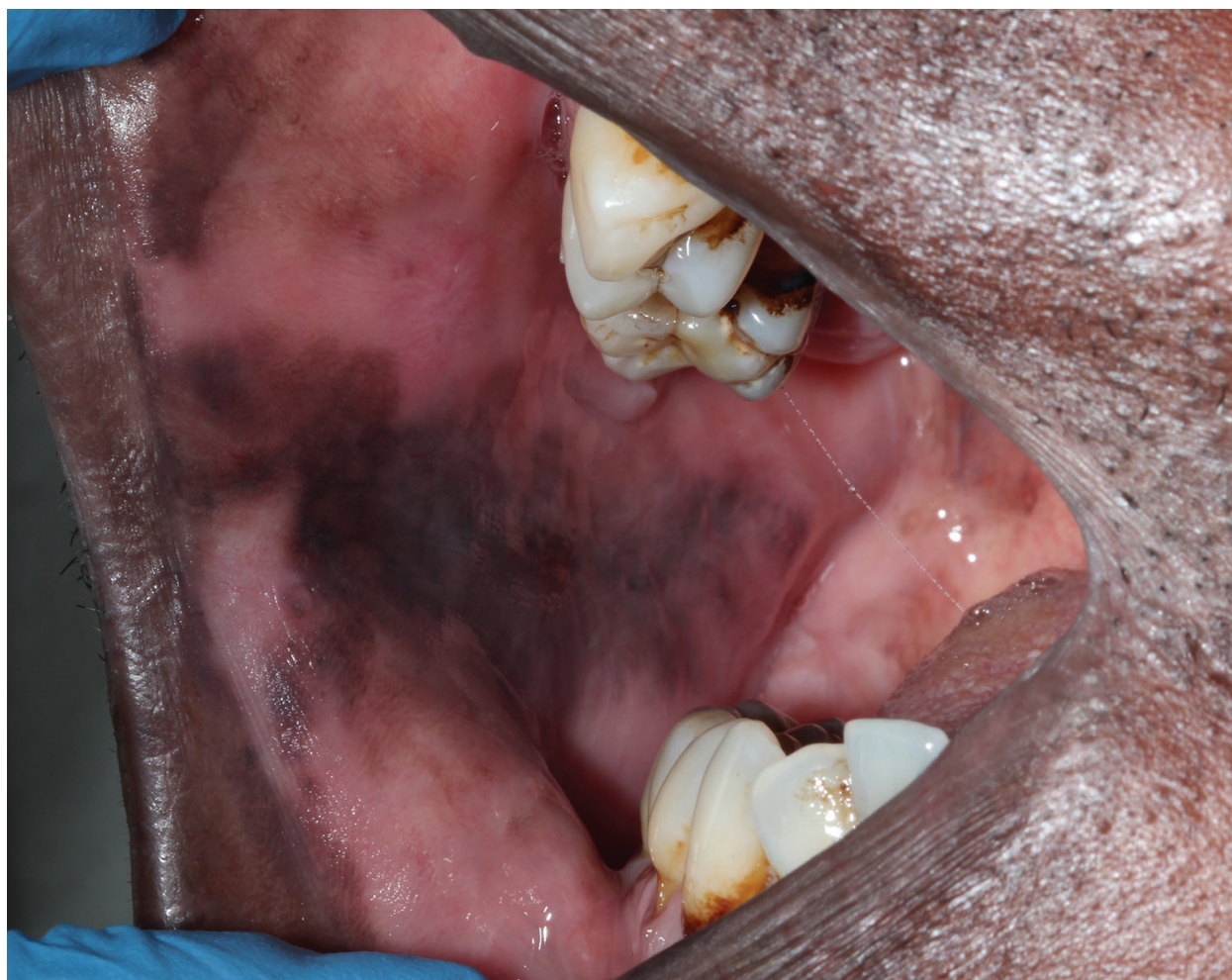

Figure 3. Irregular, diffuse, mottled hyperpigmentation of the buccal mucosa in a 40-year-old HIV-seropositive male with a CD4⁺ T cell count of 240 cells/mm³.

Apart from zidovudine used in the treatment of HIV infection, antimalarials, oestrogen, ketoconazole, clofazimine, and imatinib may mediate the development of oral mucosal melanin hyperpigmentation [12, 38]. There will usually be a gradual diminution of the hyperpigmentation after the medication is discontinued [6].

The mechanisms by which certain medications bring about oral mucosal melanin hyperpigmentation include upregulation of tyrosinase activity, deposition of complexes of the drug with pre-existing melanin in the mucosa, or induction of local inflammatory reactions with the triggering of melanin production [11, 38].

Histopathologically, medication-induced melanin pigmentation is characterised by the presence of melanin within the lamina propria either as free granules or within melanophages, but without melanocytic hyperplasia. Melanosis of basal cells can commonly be observed [11, 38].

6.5. Oral mucosal melanin hyperpigmentation associated with syndromes and systemic diseases

Oral mucosal melanin hyperpigmentation is often observed in the systemic conditions such as Peutz-Jegher syndrome, McCune-Albright syndrome, Laugier-Hunziker syndrome, Addison disease, and neurofibromatosis. The clinical appearance is one of the brown to black spots or macules, with a histopathological increase in melanin in the basal cell layer of the oral epithelium and melanin incontinence in the upper portion of the lamina propria, but without an increase in the number of melanocytes [11, 39, 40].

6.6. Oral melanotic macules

An oral melanotic macule, by conventional definition is a focal, well-defined, uniformly coloured oral mucosal hyperpigmentation, less than 1 cm in diameter, of unknown aetiology. The colour of the macule may range from light to dark brown. Any part of the oral mucosa may be affected, but particularly the buccal mucosa, and although they are usually solitary, there are sometimes several oral melanotic macules. The average age at diagnosis is 43 years, and it is observed more commonly in females than in males [11, 13, 36, 40]. Any recently developed oral melanotic maculae that are irregularly pigmented or have recently increased in size should be viewed with suspicion and microscopically examined to exclude melanoma; and melanotic maculae of the maxillary gingiva or the palatal mucosa which are the most common sites of melanoma should be viewed with even greater suspicion [34, 41].

6.7. Oral melanoacanthoma

Oral melanoacanthoma, mainly seen on the buccal mucosa of young Black women, is an uncommon, asymptomatic, brown to black melanotic lesion, reactive in origin, usually flat or slightly elevated with a smooth surface. It usually increases rapidly in size to several centimetres and is characterised by acanthosis and spongiosis of the affected epithelium with dendritic melanocytes dispersed throughout the thickness of the epithelium, with a mild inflammatory cell infiltrate in the superficial lamina propria [11, 13, 34]. As the appearance of oral melanoacanthoma is not diagnostic, diagnosis must be established histopathologically.

6.8. Oral mucosal melanotic naevus (naevomelanocytic naevus)

Broadly, the term oral naevus refers to a congenital or acquired melanotic pigmentation of the oral mucosa brought about by abnormal excessive accumulation of melanocytes/naevomelanocytes at the junction of the epithelium and the lamina propria or in the lamina propria [34]. The sequence of biological events leading to the development of oral naevomelanocytic naevi is largely unknown. It is suggested that oral naevomelanocytes, like oral melanocytes, are derived from neural crest precursor cells, which during embryogenesis migrate to a final destination in the basal cell layer of the oral epithelium. However, it is not clear which one of several mechanisms are implicated in the development of melanocytic naevi. Naevomelanocytes may originate from melanocyte precursors that have acquired some genetic alterations during development, consequently preventing them from differentiation into mature functioning

melanocytes in the basal cell layer of the oral epithelium; they may originate from mature melanocytes residing in the basal cell layer of the epithelium that have undergone some cytogenetic alterations culminating in their dedifferentiation into naevomelanocytes or they may originate from stem/progenitor melanocytes that have undergone cytogenetic alteration in the process of replacing mature melanocytes in the epithelium lost to mechanical, thermal, or chemical injury or as a result of apoptotic processes. A further possible mechanism is that naevomelanocytes originate from neural crest cells destined to become melanocytes in the oral epithelium, but for reasons unknown remain entrapped in the submucosa. Naevomelanocytic naevi may thus be manifestations of a developmental malformation or of hyperplasia of melanocytes [34, 42].

As many naevomelanocytes in cutaneous naevi show activating mutations in the BRAF or in the NRAS intracellular signalling pathways which mediate cell proliferation and differentiation [11, 34, 42], naevi are considered by many to be benign naevomelanocytic neoplasias. Histopathologically, naevomelanocytic naevi are characterised by several directly contacting naevomelanocytes in clusters confined to the junction of the epithelium and the lamina propria (junctional naevi), to both junctional zone and to the superficial lamina propria (compound naevi), or only to the subepithelial connective tissue (intra-lamina proprii naevi). The naevomelanocytes within all three types of naevi are devoid of melanosome-transferring dendritic processes, so that the colour of these naevomelanocytic naevi derives entirely from the melanosome content of the melanocytes themselves. Most oral mucosal melanocytic naevi are acquired rather than congenital and are of the intra-lamina proprii type [11, 13, 34, 36, 43].

Acquired oral mucosal melanocytic naevi are uncommon, occur more frequently in females than in males, and are observed mainly on the hard palate, gingiva, and buccal mucosa. The mean age at diagnosis is 35 years. They are small, well-defined asymptomatic macules or papules, usually brown to black in colour (**Figure 4**), but sometimes may be bluish-grey [11, 13, 36, 40].

The blue naevus is a less common oral mucosal naevus. The clinical appearance is of small blue macules or papules almost always on the palates of children or young adults (**Figure 5**) [34] and is characterised histopathologically by spindle-shaped melanin-producing naevomelanocytes arranged in fascicles parallel to the overlying epithelium, deep within the lamina propria [11, 13, 34].

6.9. Oral mucosal melanoma

Oral mucosal melanoma is an uncommon malignancy accounting for only about 0.5% of all oral cancers. It is rapidly growing and usually asymptomatic, so it is often diagnosed only when the melanomatous lesions are already advanced and there has been metastatic spread to the regional lymph nodes. Under these circumstances, the prognosis is poor with a mean 5-year survival rate of 15–20% [15, 44]. Large clinical size, microscopical evidence of deeply invasive front, a high mitotic rate of the melanoma cells, lymph node metastasis, and vascular or neural invasion and spread are all indicators of poor prognosis [45, 46].

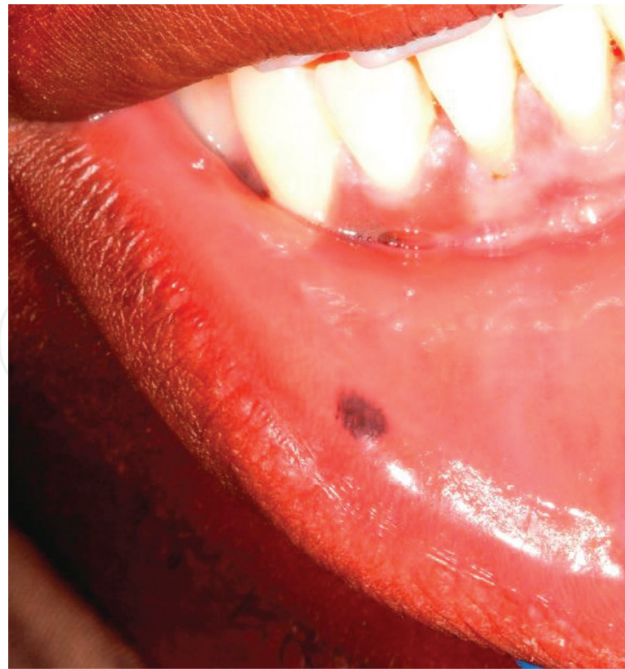

Figure 4. A 20-year-old male had this melanotic lesion of the lower labial mucosa, self-reportedly since birth. It was probably a congenital naevus but the patient refused biopsy. Note also the physiological gingival melanosis.

The palate and the gingiva are the oral mucosal sites most frequently affected. Up to one-third of oral mucosal melanomata arise from pre-existing benign oral mucosal hyperpigmentations [15, 47–49] and the remaining two-thirds arise *de-novo* [15, 44, 50, 51].

Oral mucosal melanoma differs from cutaneous melanoma in its profile of cytogenetic alterations, its more aggressive clinical course and the fact that it is not associated with any known carcinogenic agents or extrinsic risk factors [15]. The oral lesions are usually irregularly shaped melanotic macules, papules, plaques, or a combination of these forms, and their pigmentation is non-uniform, with mottled shades of grey, dark blue, dark brown, or black (Figure 6a–c) [15, 44].

The melanoma precursor most probably originates from a stem/progenitor cell that has undergone cytogenetic alterations and consequently expresses dysregulated developmental signalling pathways and transcription factors, ultimately acquiring a malignant phenotype. However, it is also possible that melanoma precursor cells originate from mature melanocytes in the basal cell layer of the epithelium that have undergone dedifferentiation following cytogenetic alterations or from immature melanocytes/naevomelanocytes arrested in the submucosa during migration from the neural crest which for reasons unknown have acquired a malignant phenotype [15].

The acquired genetic alterations confer upon the initially transformed atypical melanocytes and later upon the melanoma cells that evolved, a selective advantage over their neighbouring normal cells in terms of fitness and proliferation. Melanoma cells then have the capacity

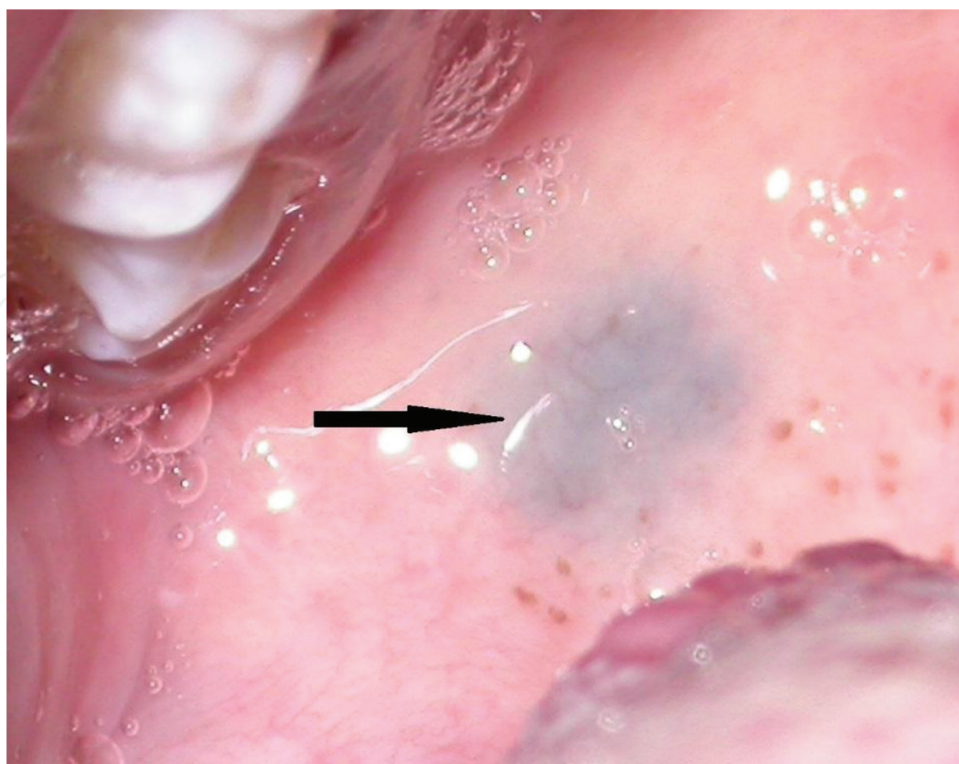


Figure 5. A blue naevus (arrow) on the soft palate in a 35-year-old male. Patient was unaware of its presence, and it was observed on routine oral examination. Histopathological examination confirmed the clinical diagnosis of blue naevus.

to undergo clonal expansion to invade and destroy local tissues, to metastasize to regional lymph nodes, and to spread to the lungs, bone, liver, brain, or skin [15, 52–54].

Melanoma cells arising from the immature melanocytes that have become arrested in the lamina propria of the oral mucosa proliferate, forming nodular aggregates in the lamina propria/submucosa with or without breaching the subepithelial basement membrane. Oral mucosal melanoma arising from melanocytes residing in the basal cell layer of the oral epithelium, on the other hand, give rise to three transient histopathological patterns: an epithelial *in-situ* pattern characterised by radial growth within the oral epithelium; an invasive pattern characterized by nodular aggregates of infiltrating epithelial melanoma cells within the lamina propria; and a combined form in which both junctional and nodular patterns occur [15, 55, 56]. Ultimately if not treated, all three patterns will become deeply invasive and metastatic.

Although the pathogenesis of oral mucosal melanoma is incompletely understood as yet, melanin, intermediates of melanin synthesis, and MC1R genetic polymorphism play roles in the pathogenesis of some cases of oral mucosal melanoma [57, 58]. Certain MC1R variants reduce the capacity for repair to damaged DNA [5], while the process of melanin biosynthesis, particularly of pheomelanin, may itself generate reactive oxygen species and other by-products that may be cytotoxic, genotoxic, or mutagenic causing DNA damage [4, 6].

It has been demonstrated that in some cases of oral mucosal melanoma, there is loss of the integrity of the melanosomal membrane with leakage into the cytoplasm and nucleoplasm of

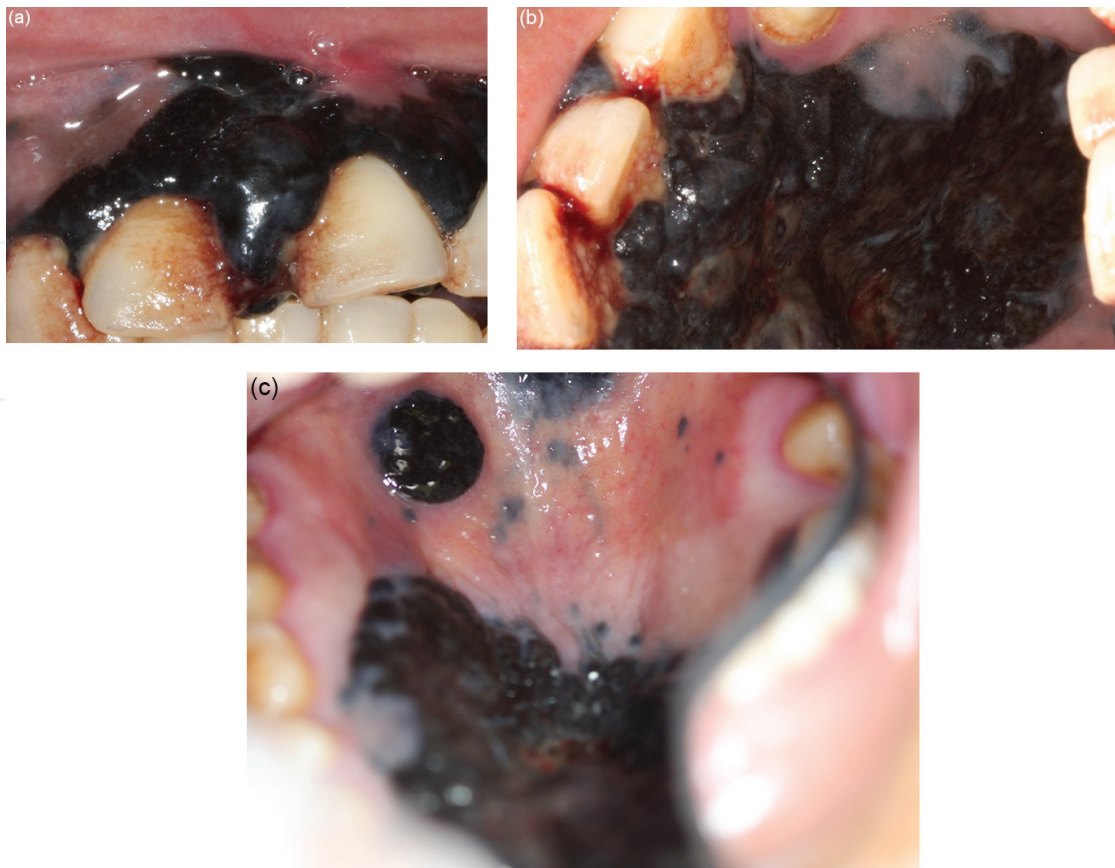

Figure 6. A 56-year-old black female with histologically confirmed melanoma of the hard palate and maxillary gingiva (a–c) of 3-year duration. It developed from a pigmented ‘patch’ of the buccal gingiva (reproduced with permission from Tlholoe et al. [15]).

the melanocytes, of toxic melanin particles, intermediates of melanogenesis and reactive oxygen species, with consequent DNA damage and increase in the risk of genetic mutations [59]. Furthermore, when leaked into the extracellular microenvironment, the intermediate metabolites of melanogenesis, which are also immunosuppressive, may promote evasion of immune responses by the initially transformed melanocyte precursors and their offspring melanoma cells, increasing the risk of melanomagenesis and melanoma growth [60].

Some oral mucosal melanomata are amelanotic, but most are heavily to very heavily melanin-pigmented. It is unknown whether the abnormally increased biosynthesis of melanin is the outcome of an early biopathological process in the development of oral mucosal melanoma, playing a role in the initial transformational events of melanocytes, or whether it is a manifestation of a malignant phenotype arising subsequently to the malignant transformation of normal melanocytes. As stated above, it has been reported that up to one-third of oral mucosal melanoma arise within fields of benign melanin hyperpigmentation [15, 47–49]. If this is true, then it is likely that either the upregulated process of melanin biosynthesis, the increased amount of melanin in the melanocytes, or both, occurring in the fields of benign oral melanin hyperpigmentation, constitute risk factors for transformation into oral mucosal melanomata.

Thus, in a nutshell, it is possible that the initial DNA damage that predisposes melanocytes to malignant transformation and cytogenetic alterations that later promote actual malignant transformation of the initially transformed melanocytes may be driven by dysregulation in melanin biosynthesis and by the increased cellular content of melanin [10].

Author details

Liviu Feller*, Razia A.G. Khammissa and Johan Lemmer

*Address all correspondence to: liviu.feller@smu.ac.za

Department of Periodontology and Oral Medicine, Sefako Makgatho Health Sciences University Pretoria, South Africa

References

- [1] Barrett AW, Scully C. Human oral mucosal melanocytes: a review. *Journal of Oral Pathology & Medicine: Official Publication of the International Association of Oral Pathologists and the American Academy of Oral Pathology*. 1994;**23**:97–103.
- [2] Amir E, Gorsky M, Buchner A, Sarnat H, Gat H. Physiologic pigmentation of the oral mucosa in Israeli children. *Oral Surgery, Oral Medicine, and Oral Pathology*. 1991;**71**:396–398.
- [3] Squier CA, Kremer MJ. Biology of oral mucosa and esophagus. *Journal of the National Cancer Institute Monographs*. 2001;**29**:7–15.
- [4] Feller L, Masilana A, Khammissa RA, Altini M, Jadwat Y, Lemmer J. Melanin: the biophysiology of oral melanocytes and physiological oral pigmentation. *Head & Face Medicine*. 2014;**10**:8.
- [5] Lekalakala PT, Khammissa RA, Kramer B, Ayo-Yusuf OA, Lemmer J, Feller L. Oculocutaneous Albinism and squamous cell carcinoma of the skin of the head and neck in Sub-Saharan Africa. *Journal of Skin Cancer*. 2015;**2015**:167847.
- [6] Feller L, Chandran R, Kramer B, Khammissa RA, Altini M, Lemmer J. Melanocyte biology and function with reference to oral melanin hyperpigmentation in HIV-seropositive subjects. *AIDS Research and Human Retroviruses*. 2014;**30**:837–843.
- [7] Masilana A, Khammissa RAG, Lemmer J, Feller J. Oral medicine case book 66: Physiological/racial oral melanin hyperpigmentation. *SADJ: Journal of the South African Dental Association = tydskrif van die Suid-Afrikaanse Tandheelkundige Vereniging*. 2015;**70**:28–31.
- [8] Mackintosh JA. The antimicrobial properties of melanocytes, melanosomes and melanin and the evolution of black skin. *Journal of Theoretical Biology*. 2001;**211**:101–113.
- [9] Tobin DJ. Biochemistry of human skin--our brain on the outside. *Chemical Society Reviews*. 2006;**35**:52–67.

- [10] Chandran R, Feller L, Lemmer J, Khammissa RA. HIV-associated oral mucosal melanin hyperpigmentation: A Clinical Study in a South African Population Sample. *AIDS Research and Treatment*. 2016;**2016**:8389214.
- [11] Gondak RO, da Silva-Jorge R, Jorge J, Lopes MA, Vargas PA. Oral pigmented lesions: Clinicopathologic features and review of the literature. *Medicina Oral, Patologia Oral y Cirugia Bucal*. 2012;**17**:e919–e924.
- [12] Yuan A, Woo SB. Adverse drug events in the oral cavity. *Oral Surgery, Oral Medicine, Oral Pathology and Oral Radiology*. 2015;**119**:35–47.
- [13] Muller S. Melanin-associated pigmented lesions of the oral mucosa: presentation, differential diagnosis, and treatment. *Dermatologic Therapy*. 2010;**23**:220–229.
- [14] Chandran R, Khammissa RAG, Lemmer J, Feller L. HIV associated oral melanin hyperpigmentation. *SADJ: Journal of the South African Dental Association = tydskrif van die Suid-Afrikaanse Tandheelkundige Vereniging*. 2014;**69**:370–371.
- [15] Tlholoe MM, Khammissa RA, Bouckaert M, Altini M, Lemmer J, Feller L. Oral mucosal melanoma: some pathobiological considerations and an illustrative report of a case. *Head and Neck Pathology*. 2015;**9**:127–134.
- [16] Nishimura EK, Jordan SA, Oshima H, Yoshida H, Osawa M, Moriyama M, et al. Dominant role of the niche in melanocyte stem-cell fate determination. *Nature*. 2002;**416**:854–860.
- [17] Yamaguchi Y, Brenner M, Hearing VJ. The regulation of skin pigmentation. *The Journal of Biological Chemistry*. 2007;**282**:27557–27561.
- [18] Barrett AW, Raja AM. The immunohistochemical identification of human oral mucosal melanocytes. *Archives of Oral Biology*. 1997;**42**:77–81.
- [19] Squier CA, Waterhouse JP. The ultrastructure of the melanocyte in human gingival epithelium. *Archives in Oral Biology*. 1967;**12**:119–129.
- [20] Hirobe T. Role of keratinocyte-derived factors involved in regulating the proliferation and differentiation of mammalian epidermal melanocytes. *Pigment Cell Research/ Sponsored by the European Society for Pigment Cell Research and the International Pigment Cell Society*. 2005;**18**:2–12.
- [21] Hara M, Toyoda M, Yaar M, Bhawan J, Avila EM, Penner IR, et al. Innervation of melanocytes in human skin. *The Journal of Experimental Medicine*. 1996;**184**:1385–1395.
- [22] Schiaffino MV. Signaling pathways in melanosome biogenesis and pathology. *The International Journal of Biochemistry & Cell Biology*. 2010;**42**:1094–1104.
- [23] Slominski A, Tobin DJ, Shibahara S, Wortsman J. Melanin pigmentation in mammalian skin and its hormonal regulation. *Physiological Reviews*. 2004;**84**:1155–1228.
- [24] Slominski A, Wortsman J, Paus R, Elias PM, Tobin DJ, Feingold KR. Skin as an endocrine organ: implications for its function. *Drug Discovery Today Disease Mechanisms*. 2008;**5**:137–144.

- [25] Plonka PM, Passeron T, Brenner M, Tobin DJ, Shibahara S, Thomas A, et al. What are melanocytes really doing all day long...? *Experimental Dermatology*. 2009;**18**:799–819.
- [26] Chi A, Valencia JC, Hu ZZ, Watabe H, Yamaguchi H, Mangini NJ, et al. Proteomic and bioinformatic characterization of the biogenesis and function of melanosomes. *Journal of Proteome Research*. 2006;**5**:3135–3144.
- [27] Marks MS, Seabra MC. The melanosome: membrane dynamics in black and white. *Nature Reviews Molecular Cell Biology*. 2001;**2**:738–748.
- [28] Tsukamoto K, Jackson IJ, Urabe K, Montague PM, Hearing VJ. A second tyrosinase-related protein, TRP-2, is a melanogenic enzyme termed DOPAchrome tautomerase. *The EMBO Journal*. 1992;**11**:519–526.
- [29] Kauser S, Schallreuter KU, Thody AJ, Gummer C, Tobin DJ. Regulation of human epidermal melanocyte biology by beta-endorphin. *The Journal of Investigative Dermatology*. 2003;**120**:1073–1080.
- [30] Grando SA, Pittelkow MR, Schallreuter KU. Adrenergic and cholinergic control in the biology of epidermis: physiological and clinical significance. *The Journal of Investigative Dermatology*. 2006;**126**:1948–1965.
- [31] Sowden HM, Naseem KM, Tobin DJ. Differential expression of nitric oxide synthases in human scalp epidermal and hair follicle pigmentary units: implications for regulation of melanogenesis. *The British Journal of Dermatology*. 2005;**153**:301–309.
- [32] Starner RJ, McClelland L, Abdel-Malek Z, Fricke A, Scott G. PGE(2) is a UVR-inducible autocrine factor for human melanocytes that stimulates tyrosinase activation. *Experimental Dermatology*. 2010;**19**:682–684.
- [33] Buchner A, Merrell PW, Carpenter WM. Relative frequency of solitary melanocytic lesions of the oral mucosa. *Journal of Oral Pathology & Medicine: official publication of the International Association of Oral Pathologists and the American Academy of Oral Pathology*. 2004;**33**:550–557.
- [34] Neville BW, Damm DD, Allen AM, Chi AC. Epithelial pathology. In: Falk K, editor. *Oral and Maxillofacial Pathology*. 1. St Louis, Missouri, USA: Elsevier; 2016. p. 350–355.
- [35] Dummett CO. Physiologic pigmentation of the oral and cutaneous tissues in the Negro. *Journal of Dental Research*. 1946;**25**:421–432.
- [36] Meleti M, Vescovi P, Mooi WJ, van der Waal I. Pigmented lesions of the oral mucosa and perioral tissues: a flow-chart for the diagnosis and some recommendations for the management. *Oral Surgery, Oral Medicine, Oral Pathology, Oral Radiology, and Endodontics*. 2008;**105**:606–616.
- [37] Mergoni G, Ergun S, Vescovi P, Mete O, Tanyeri H, Meleti M. Oral postinflammatory pigmentation: an analysis of 7 cases. *Medicina Oral, Patologia Oral y Cirugia Bucal*. 2011;**16**:e11–e14.

- [38] Li CC, Malik SM, Blaeser BF, Dehni WJ, Kabani SP, Boyle N, et al. Mucosal pigmentation caused by imatinib: report of three cases. *Head and Neck Pathology*. 2012;**6**:290–295.
- [39] Nikitakis NG, Koumaki D. Laugier-Hunziker syndrome: case report and review of the literature. *Oral Surgery, Oral Medicine, Oral Pathology and Oral Radiology*. 2013;**116**:e52–e58.
- [40] Fernandes D, Ferrisse TM, Navarro CM, Massucato EM, Onofre MA, Bufalino A. Pigmented lesions on the mucosa: a wide range of diagnoses. *Oral Surgery, Oral Medicine, Oral Pathology and Oral Radiology*. 2015;**119**:374–378.
- [41] Kauzman A, Pavone M, Blanas N, Bradley G. Pigmented lesions of the oral cavity: review, differential diagnosis, and case presentations. *Journal (Canadian Dental Association)*. 2004;**70**:682–683.
- [42] Grichnik JM, Rhodes AR, Sober AJ. Benign neoplasias and hyperplasias of melanocytes. In: Sydor AM, Pancotti R, editors. *Fitzpatrick's Dermatology in General Medicine*. 2: New York: The McGraw-Hill Companies, Inc; 2016. p. 1377–1416.
- [43] Biesbrock AR, Aguirre A. Multiple focal pigmented lesions in the maxillary tuberosity and hard palate: a unique display of intraoral junctional nevi. *Journal of Periodontology*. 1992;**63**:718–721.
- [44] Feller L, Masipa JN, Wood NH, Khamissa RA, Meyerov R, Lemmer J. Primary oral melanoma associated with HIV infection. *SADJ: Journal of the South African Dental Association = tydskrif van die Suid-Afrikaanse Tandheelkundige Vereniging*. 2008;**63**:016–017.
- [45] Postow MA, Hamid O, Carvajal RD. Mucosal melanoma: pathogenesis, clinical behavior, and management. *Current Oncology Reports*. 2012;**14**:441–448.
- [46] Kerr EH, Hameed O, Lewis JS, Jr., Bartolucci AA, Wang D, Said-Al-Naief N. Head and neck mucosal malignant melanoma: clinicopathologic correlation with contemporary review of prognostic indicators. *International Journal of Surgical Pathology*. 2012;**20**:37–46.
- [47] Garzino-Demo P, Fasolis M, Maggiore GM, Pagano M, Berrone S. Oral mucosal melanoma: a series of case reports. *Journal of Cranio-Maxillo-Facial Surgery: Official Publication of the European Association for Cranio-Maxillo-Facial Surgery*. 2004;**32**:251–257.
- [48] Kahn MA, Weathers DR, Hoffman JG. Transformation of a benign oral pigmentation to primary oral melanoma. *Oral Surgery, Oral Medicine, Oral Pathology, Oral Radiology, and Endodontics*. 2005;**100**:454–459.
- [49] Shen ZY, Liu W, Bao ZX, Zhou ZT, Wang LZ. Oral melanotic macule and primary oral malignant melanoma: epidemiology, location involved, and clinical implications. *Oral Surgery, Oral Medicine, Oral Pathology, Oral Radiology, and Endodontics*. 2011;**112**:e21–e25.
- [50] Benoist LB, van Looij MA. Images in clinical medicine. Melanoma of the oral cavity. *The New England Journal of Medicine*. 2013;**368**:e14.

- [51] Martinelli-Klay CP, Laporte ML, Martinelli CR, Martinelli C, Lombardi T. Oral malignant melanoma initially misdiagnosed as a racial pigmentation: a case report. *Dermatopathology*. 2016;**3**:1–7.
- [52] Carlson JA, Murphy M, Slominski A, Vincent WL. Evidence of skin field cancerization. In: Dakubo GD E, editor. *Filed Cancerization: Basic Science and Clinical Applications*. Ontario, Canada: Nova Science Publishers; 2011. p. 317–370.
- [53] Wang X, Wu HM, Ren GX, Tang J, Guo W. Primary oral mucosal melanoma: advocate a wait-and-see policy in the clinically N0 patient. *Journal of Oral and Maxillofacial Surgery* 2012;**70**:1192–1198.
- [54] Grichnik JM. Melanoma, nevogenesis, and stem cell biology. *The Journal of Investigative Dermatology*. 2008;**128**:2365–2380.
- [55] Mohan M, Sukhadia VY, Pai D, Bhat S. Oral malignant melanoma: systematic review of literature and report of two cases. *Oral Surgery, Oral Medicine, Oral Pathology and Oral Radiology*. 2013;**116**:e247–e254.
- [56] Barker BF, Carpenter WM, Daniels TE, Kahn MA, Leider AS, Lozada-Nur F, et al. Oral mucosal melanomas: the WESTOP Banff workshop proceedings. Western Society of Teachers of Oral Pathology. *Oral Surgery, Oral Medicine, Oral Pathology, Oral Radiology, and Endodontics*. 1997;**83**:672–679.
- [57] Nan H, Kraft P, Hunter DJ, Han J. Genetic variants in pigmentation genes, pigmentary phenotypes, and risk of skin cancer in Caucasians. *International Journal of Cancer* 2009;**125**:909–917.
- [58] Han J, Kraft P, Colditz GA, Wong J, Hunter DJ. Melanocortin 1 receptor variants and skin cancer risk. *International Journal of Cancer* 2006;**119**:1976–1984.
- [59] Gidanian S, Mentelle M, Meyskens FL, Jr., Farmer PJ. Melanosomal damage in normal human melanocytes induced by UVB and metal uptake—a basis for the pro-oxidant state of melanoma. *Photochemistry and Photobiology*. 2008;**84**:556–564.
- [60] Slavin S. Effector cells of experimental and clinical cellular adoptive immunobiology. In: Morstyn G, Sheridan W, editors. *Cell Therapy: Stem Cell Transplantation, Gene Therapy, and Cellular Immunotherapy*. Los Angeles: Cambridge University Press; 1996. p. 18–42.