

We are IntechOpen, the world's leading publisher of Open Access books Built by scientists, for scientists

6,900

Open access books available

186,000

International authors and editors

200M

Downloads

Our authors are among the

154

Countries delivered to

TOP 1%

most cited scientists

12.2%

Contributors from top 500 universities



WEB OF SCIENCE™

Selection of our books indexed in the Book Citation Index
in Web of Science™ Core Collection (BKCI)

Interested in publishing with us?
Contact book.department@intechopen.com

Numbers displayed above are based on latest data collected.
For more information visit www.intechopen.com



Chronic Mitral Valve Insufficiency in Dogs: Recent Advances in Diagnosis and Treatment

Sang-Il Suh, Dong-Hyun Han, Seung-Gon Lee,
Yong-Wei Hung, Ran Choi and Changbaig Hyun

Additional information is available at the end of the chapter

<http://dx.doi.org/10.5772/64611>

Abstract

Chronic mitral valvular insufficiency (CMVI) is the most common acquired heart disease in dogs and is characterized by degenerative valvular changes causing progressive thickening of mitral leaflets and incomplete closure of mitral valve. As the disease progresses, it causes congestive heart failure (CHF) and pulmonary edema if the LA dilation cannot accommodate the volume overload by mitral regurgitation. Therefore, it is the most common cause of cardiac mortality in dogs. This chapter discusses general features of CMVI in dogs focusing on recent advances in diagnosis and treatment.

Keywords: mitral valve , degenerative valve disease , mitral valve insufficiency , heart failure , mitral regurgitation

1. Introduction

Chronic mitral valvular insufficiency (CMVI) is the most common cause of congestive heart failure (CHF) in small breed dogs [1, 2] and is characterized by progressive myxomatous degeneration of the atrioventricular valves [3]. Mitral regurgitation (MR) is the most common sequel to CMVI, which causes volume overload at the left atrial (LA) and left ventricle (LV) and progresses to CHF [4]. Underlying causes of CMVI have yet been identified, although aging and genetic causes were suggested in a certain breed of dogs [5–8] and humans [4]. CMVI is more often seen in old and small breeds of dog. Higher prevalence of CMVI was noticed in Cavalier King Charles Spaniels (CKCS) and Dachshund [9, 10]. CMVI has been noticed in ~50% of 6- to 7-year-old CKCS dogs and ~50% of 10-year-old Dachshund dogs. Those two

studies strongly suggested genetic etiology for this disease, although other study found the aging is the major cause for this disease [11]. In these dog breeds, the CMVI is occurred at younger age and progressed more rapidly. List of dog breeds having high prevalence rate for CMVI are Chihuahuas, Malteses, Yorkshire Terriers, Poodles, Papillons, Pekingeses, Miniature Pinschers, Bologneses, Dachshunds, Shih Tzus, Cairn Terriers, Miniature Schnauzers, Bichon Frises, Carvalier King Charles Spaniels, Pugs, West Highland White Terriers, Fox Terriers, Boston Terriers, Welsh Terriers, Whippets, American Cocker Spaniels, Beagles, German Shepherds, and Great Danes [12], although almost one-quarter of dogs over the age of 10 have degenerative changes on mitral valve in any breeds of dog. Higher prevalence rate in Maltese and Shih Tzu has been found in some Asian countries including Korea, Japan, and Taiwan [13].

CMVI is an animal model of human mitral valve prolapse (MVP), which is suggested of polygenic inheritance [14]. Several canine studies also suggested polygenic inheritance for CMVI [6, 8, 15]. Male dogs have higher rate of prevalence almost 1.5 times than female dogs [3]. One study found that the mitral valve was affected in ~60% case of CMVI, and tricuspid valve only was affected in ~10% of CMVI, while both atrioventricular valves (mitral valve and tricuspid valve) were affected in ~30% of CMVI [16].

2. Pathogenesis and clinical signs

Pathological features of canine CMVI are degenerative changes on mitral valve, mitral valve thickening and opacity, several degrees of leaflet retraction, node of valve's end, and lengthened chordae tendineae (**Figure 1**) [17, 18] and are similar to human MVP [19, 20]. Disruption of collagen and deposition of glycosaminoglycans in mitral valve are also common microscopic feature in this disease [11, 19, 21]. Long-standing mitral valvular insufficiency can

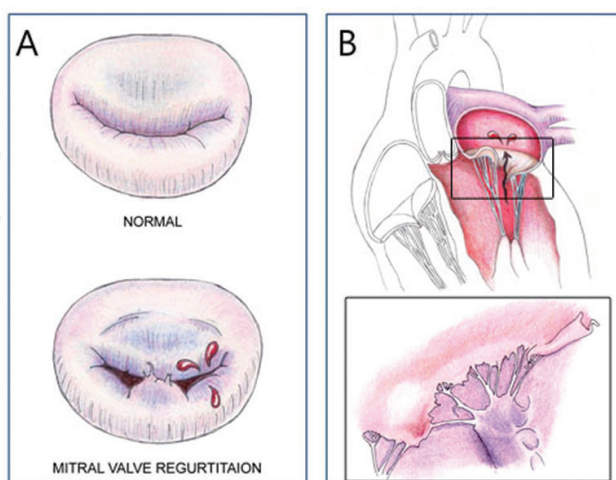


Figure 1. Pathological features of canine chronic mitral valvular insufficiency are degenerative changes on mitral valve, mitral valve thickening and opacity, several degrees of leaflet retraction, node of valve's end and lengthened chordae tendineae. (A) Diagram of normal mitral valve (top) and mitral regurgitation (bottom), (B) diagram of mitral valve insufficiency from chronic degenerative changes on mitral valve leaflets (box).

cause volume overload of both the LA and the LV. Furthermore, the increased end-diastolic volume in LV can cause pressure overload on the LA. Subsequently, the increased pressure in the LA inhibits drainage of blood from the lungs via the pulmonary veins and thus causes pulmonary congestion. If this condition is untreated, it will eventually develop LV dysfunction and CHF [22].

Coughing, especially nocturnal cough, may be the first clinical signs in CMVI. However, in dogs with advanced stage of heart failure (HF), dyspnea such as shortness of breath, difficulty breathing, and orthopnea may be the major signs. Depending on the severity of CMVI, the dog maybe had certain degree of exercise intolerance, lethargy, reduced appetite, and weight loss [23].

3. Diagnosis

3.1. Physical examination

Heart murmur is a major finding in physical examination. Depending on the severity, clinicians can hear various grade of heart murmur before the onset of clinical signs. In early stages of the CMVI, heart murmur can be localized and weak as 1~2/6 scale at left apex. In late stages of the CMVI, heart murmur is gradually radiated and louder and is typically crescendo-decrescendo type systolic regurgitant murmur (**Figure 2A**). Recent study found that the grade of heart murmur was closely related to the severity of CMVI [24].

3.2. Laboratory tests

Common laboratory findings in dogs with CMVI are normal or slightly raise in kidney and/or liver chemistry profiles, probably due to the congestion and poor body perfusion [25]. One recent study evaluated hepatic panel in dogs at different stages of heart failure from CMVI [26].

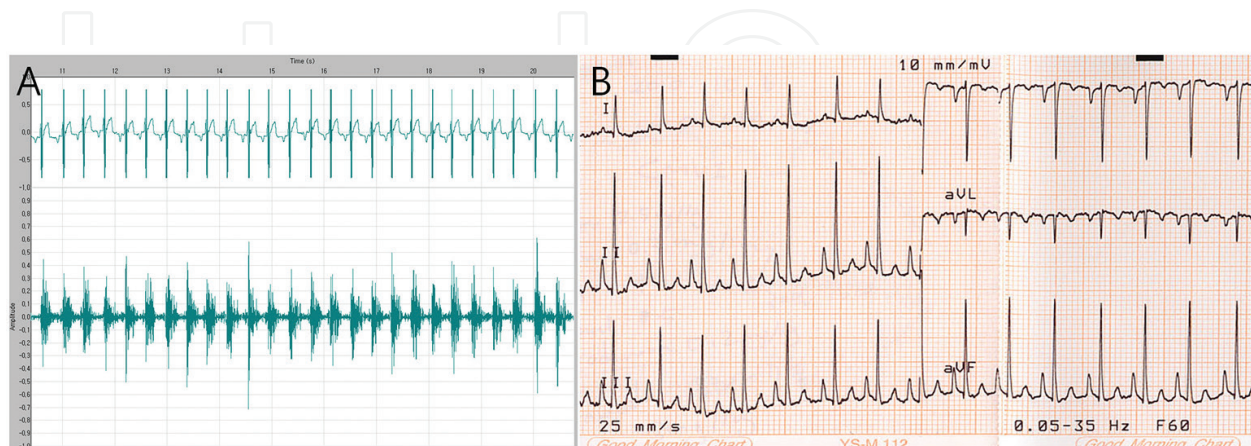


Figure 2. (A) Phonocardiogram in dogs with CMVI. Heart murmur is gradually radiated and louder and is typically crescendo-decrescendo type systolic regurgitant murmur. (B) ECG in dogs with CMVI. P-mitrale (wide P-wave) and wide and tall QRS complexes indicating LA and LV dilation.

Serum levels of ALT and GGT were statistically significantly higher in ISACHC II and III groups ($p < 0.05$), while levels of AST, albumin, cholesterol, and total bilirubin were not significantly differed among groups. Level of NT-proBNP was also significantly higher in ISACHC II and III groups ($p < 0.05$), although the level was not significantly differed in ISACHC I group. There were no correlations between levels of AST, albumin, cholesterol, and total bilirubin to echocardiographic indices. The level of NT-proBNP was correlated with most echocardiographic indices (LA/Ao, LVID/Ao, E-peak, EDVI, $r > 0.7$) and ALT ($r = 0.701$) and GGT ($r = 0.782$). This study revealed the biochemical evidence of hepatic injuries in dogs with advanced stage of CMVI [26].

Poor tissue perfusion from CMVI causes pancreatitis in dogs, as indicated by serum pancreatic lipase concentrations. One recent study has evaluated the prevalence of pancreatitis in 62 client-owned dogs consisting of 40 dogs with different stages of heart failure from CMVI and 22 age-matched healthy dogs [27]. Serum canine pancreatic lipase immunoreactivity (cPLI) concentrations were determined by quantitative cPLI test in healthy and CMVI groups in this study. Serum cPLI concentrations were 54.0 $\mu\text{g/L}$ (IQR: 38.0–78.8 $\mu\text{g/L}$) in control, 55.0 $\mu\text{g/L}$ (IQR: 38.3–88.8 $\mu\text{g/L}$) in ISACHC I, 115.0 $\mu\text{g/L}$ (IQR: 45.0–179.0 $\mu\text{g/L}$) in ISACHC II, and 223.0 $\mu\text{g/L}$ (IQR: 119.5–817.5 $\mu\text{g/L}$) in ISACHC III. Also, close correlation of serum cPLI concentration was found in the left atrial to aorta (LA/Ao) ratio ($r = 0.597$; $P = 0.000$) and the severity of heart failure ($r = 0.530$; $P = 0.000$). This study found that the CMVI is associated with pancreatic injury in congestive heart failure due to the CMVI [27].

Reduction in glomerular filtration rate (GFR) is a common complication in advanced stages of heart failure (HF). The convenient and precise assessment for GFR would be useful for early detection of renal impairment in HF dogs. One recent study has evaluated the reduction in GFR in advanced stages of HF from CMVI, using renal markers including serum cystatin C (Cys-C) and symmetric dimethylarginine (SDMA) concentrations [28]. Forty-three client-owned dogs consisting of 33 dogs with different stages of HF from CMVI and 10 age-matched healthy dogs were enrolled in this study. Serum Cys-C and SDMA concentrations along with other renal (i.e., urea nitrogen and creatinine) and echocardiographic markers were evaluated in healthy and CMVI dogs. Serum Cys-C concentrations were 1.4 ± 0.4 mg/l in control, 2.1 ± 0.9 mg/l in ISACHC I, 2.9 ± 0.8 mg/l in ISACHC II, and 3.6 ± 0.6 mg/l in ISACHC III dogs, whereas serum SDMA concentrations were 8 ± 2 $\mu\text{g/dl}$ in control, 14 ± 3 $\mu\text{g/dl}$ in ISACHC I, 18 ± 6 $\mu\text{g/dl}$ in ISACHC II, and 22 ± 7 $\mu\text{g/dl}$ in ISACHC III dogs. There was close correlation of serum Cys-C and SDMA concentrations with serum creatinine, urea nitrogen, and the severity of HF. This study demonstrated that the GFR was decreased in dogs with CMVI having earlier stages of HF [28].

3.3. Cardiac biomarkers

In recent years, cardiac biomarkers have been developed that are differentiating cardiac and respiratory diseases to evaluate the progress of heart failure in dogs and cats. There are many cardiac biomarkers. The ideal biomarkers should reflect the therapeutic response, the pathophysiology of heart diseases, assist in the early diagnosis of CHF, and be applicable throughout the various phases of the syndrome from before the onset of its clinical manifestations

through its end-stage. Cardiac biomarkers have used as diagnostic tools [29], prognostic indicator [30], and monitoring system [31] for CHF.

Troponins are marker of myocardial necrosis and ischemia and found to be closely associated with the severity of heart failure in dogs [32] and cats [33], although it often elevated in many noncardiac disease [34–36]. Natriuretic peptides (NPs) are markers releasing from hemodynamic stress on the heart [37], responded against volume expansion/pressure overload [37]. The plasma concentration of N-terminal prohormone of brain natriuretic peptide (NT-proBNP) is well correlated with severity of heart failure in dogs [38], although the level of NT-proBNP can be affected by noncardiac factors such as body weight and renal function [39]. Cardiopet® proBNP is a commercially available diagnostic test. According to the manufacturer (Idexx, USA), dogs with <900 pmol/L of serum NT-proBNP may not have heart failure, while dogs with 900–1800 pmol/L may have heart failure, but is required further discriminative tests. Dogs with >1800 pmol/L may have higher possibility of heart failure. C-reactive protein (CRP) is an acute-phase reactant protein [40, 41] that is increased in several diseases in dogs [42–47]. Although the level of CRP is increased in dogs with CMVI, the CRP concentration was not related to the presence of CHF or murmur grade [48].

3.4. Electrocardiogram

Major findings on the electrocardiography (ECG) in dogs with CMVI are P mitrale (wide P-wave) and wide and tall QRS complexes indicating LA and LV dilation (**Figure 2B**) [49]. Tachycardia may be occurred either persistently or intermittently as the CMVI progresses [50, 51]. Although atrial fibrillation is often observed in large breed dogs with CMVI, it is rarely found in the small breed dogs. However, if dogs have early stage of CMVI, there will be no abnormal finding on the ECG [23]. The ECG signs indicating myocardial hypoxic damage (i.e., the ST-slurring) can be seen in dogs with advanced stage of heart failure [52].

3.5. Thoracic radiography

Thoracic radiography is the diagnostic test of choice in dogs with CMVI [23]. Enlargement of the LA/LV and pulmonary venous vasculatures is common findings on thoracic radiography (**Figure 3**) [23, 53, 54]. Other radiographic signs indicating left-sided heart failure including the dorsal displacement of trachea, the compression and/or elevation of left main stem bronchus, and the dividing view of left and right stem bronchus can be noticed as the disease progresses (**Figure 3**) [55]. In advanced stage, radiographic signs related to pulmonary edema (i.e., pulmonary venous engorgement, peribronchial pattern, air bronchograms) can be obvious in most cases [23]. Also, when complications with pulmonary hypertension (PHT) are combined, radiographic signs indicating right-sided heart failure (i.e., hepatomegaly, ascites) can be observed [23].

3.6. Echocardiography

The transthoracic echocardiographic examination is noninvasive diagnostic method and can help to identify mitral valvular lesions and to determine the severity of MR. Echocardiography

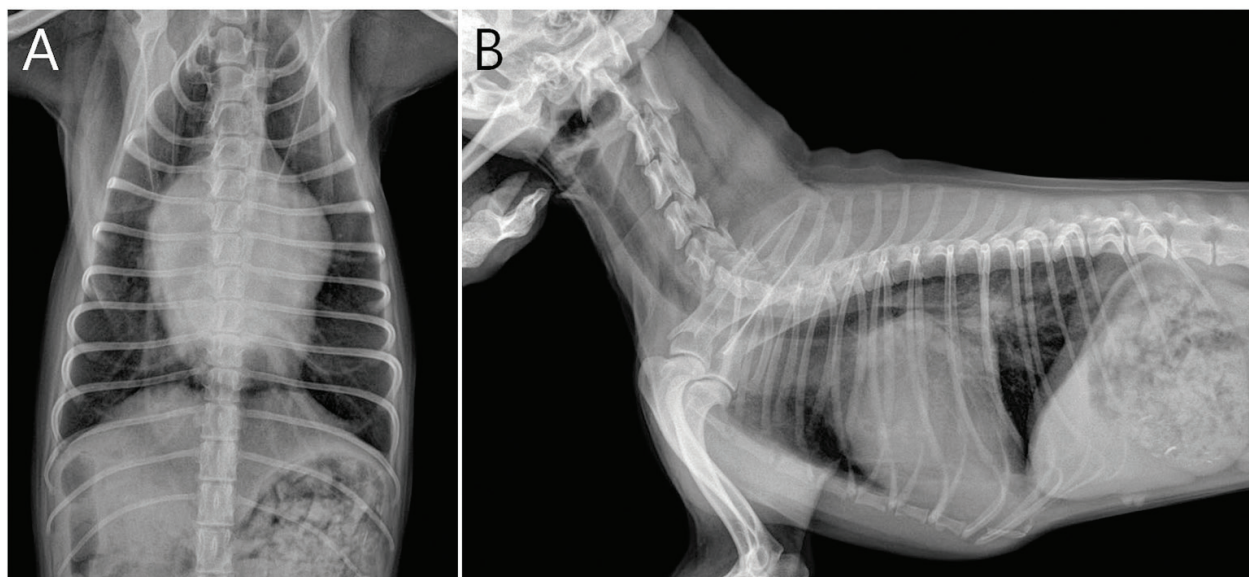


Figure 3. Thoracic radiography in dogs with CMVI. Enlargement of the LA/LV and pulmonary venous vasculatures is common findings on thoracic radiography. Other radiographic signs indicating left-sided heart failure including the dorsal displacement of trachea, the compression and/or elevation of left main stem bronchus, and the dividing view of left and right stem bronchus can be noticed as the disease progresses. (A) Ventrodorsal projection. (B) Right lateral projection.

can also assess its impact on cardiac remodeling, myocardial function, left ventricular filling pressures, and pulmonary arterial pressure [56–61].

Mitral valve lesion can be identified using two-dimensional and M-mode echocardiography. The mitral valve lesions associated with CMVI are small and smooth, creating a club-shaped appearance to the leaflet tips during early stages of the disease, but may become large and irregular during disease progression (**Figure 4B**) [56, 62, 63]. Mitral valve prolapse, which is characterized by one or both leaflets bent back into the left atrial chamber during systole, occurs commonly in dogs with CMVI (**Figure 4A**) [7, 64]. In one recent study, the severity of mitral valve prolapse was significantly correlated with MR severity [64]. Anterior leaflet of mitral valve is more commonly affected than posterior leaflet in dogs [64]. Abnormal excursion [i.e., decreased ejection fraction (EF) slope] and thickening of anterior mitral leaflet can also be detected in M-mode echocardiography (**Figure 5A**).

Ruptured chordae tendineae is also common echocardiographic finding in dogs with CMVI [64]. The mitral valve leaflet is seen pointing back into the left atrium (LA) during systole and bent back on itself within the left ventricular outflow tract during diastole [65–67]. Chordae tendineae of anterior mitral valve leaflet is more commonly ruptured in dogs [68].

It is clinically important to evaluate severity of MR in dogs with CMVI. Color-flow Doppler imaging (CFDI) is widely used for detection and assessment of MR in dogs with CMVI (**Figures 4C, D and 6B**). Maximal area of the regurgitant jet signals to the left atrium area (ARJ/LAA) ratio, which is the maximal ratio of the regurgitant jet area signal to left atrial area, is used in semi-quantification of MR [56, 69, 70]. The ARJ/LAA ratio lesser than 20–30%

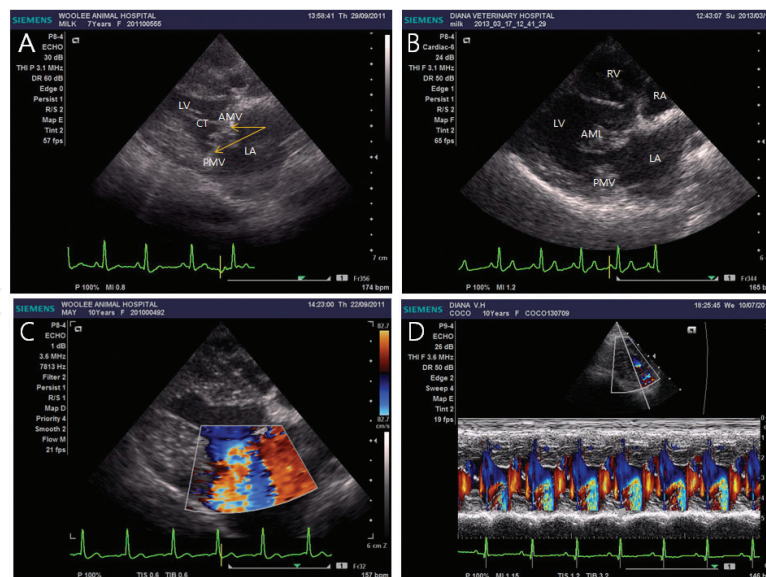


Figure 4. 2D and color Doppler echocardiography in dogs with CMVI. (A) Mitral valve prolapse, which is characterized by one or both leaflets bent back into the left atrial chamber during systole, occurs commonly in dogs with CMVI. The severity of mitral valve prolapse was significantly correlated with MR severity. (B) The mitral valve lesions associated with CMVI are large and irregular in advanced stage of CMVI. Anterior leaflet of mitral valve is more commonly affected than posterior leaflet in dogs. (C) Color-flow Doppler imaging in 2D echocardiography revealed severe regurgitant jets from left ventricle to left atrium during systole and is widely used for detection and assessment of MR in dogs with CMVI. (D) The MR can be also detected in color M-mode echocardiography on the LV short-axis view. LV, left ventricle; CT, chordae tendineae; AMV, anterior mitral valve; PMV, posterior mitral valve; RV, right ventricle; RA, right atrium.

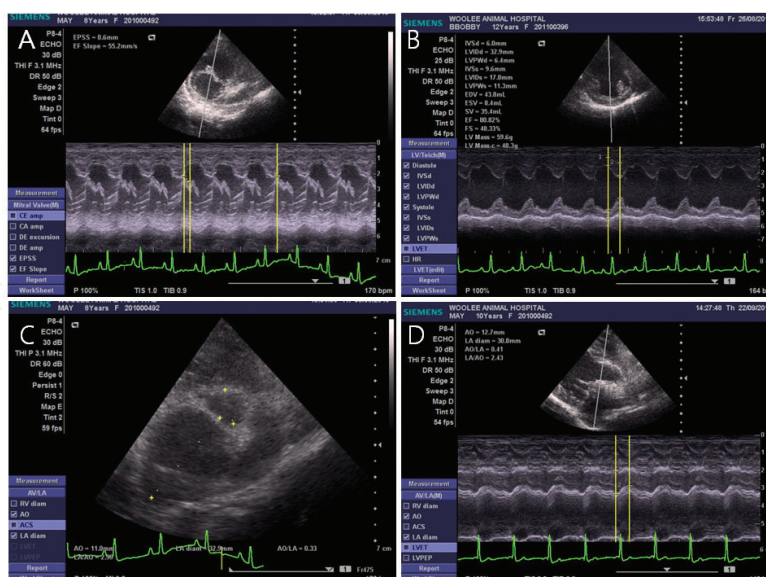


Figure 5. 2D and M-mode echocardiography in dogs with CMVI. (A) Abnormal excursion (decreased EF slope) and thickening of anterior mitral leaflet can be detected in M-mode echocardiography. (B) The eccentric hypertrophy, which is characterized by an increase in end-diastolic left ventricular dimensions (EDV), occurs in dogs with CMVI. (C)–(D) Hemodynamically significant chronic MR can induce volume overload, which subsequently can increase LV and LA volume and can result in LA and LV dilation. The degree of left atrial enlargement that is assessed by the left atrium to aorta (LA/Ao) ratio in 2D and M-mode echocardiography and is closely correlated with the severity of heart failure.

is indicative of mild MR. The ratio involves between 20 and 30, 70% is indicative of moderate MR, and >70% is indicative of severe MR [56, 69–71].

The vena contracta is the measurement of smallest mitral regurgitant jet width through the valve and is correlated with MR severity [71]. Measuring the vena contracta uses parasternal long-axis views that identify the vena contracta perpendicular to the sound plane. Very few data are available regarding vena contracta associated with dogs with CMVI [71]. In human study, a correlation was found between vena contracta and MR severity [72–74]. The proximal isovelocity surface area (PISA) method can be used in echocardiography to estimate the area of flow acceleration and convergence proximal to the mitral valve as the regurgitant jet approaches the orifice [75]. Left apical four-chamber views confirming the mitral regurgitant jet are generally recommended for measurement. Regurgitant orifice area, regurgitant fraction, and volume can be measured by this method. In study performed on dogs with severe MR, mitral regurgitant fraction calculated using PISA method was significantly correlated with MR severity [76].

Hemodynamically significant chronic MR can induce volume overload, which subsequently can increase LV and LA volume and can result in LA and LV dilation [63]. The degree of left atrial enlargement that is assessed by the left atrium to aorta (LA/Ao) ratio is closely correlated with the severity of heart failure (**Figure 5C and D**). Both two-dimensional mode and M-mode echocardiography should be used in order to determine left atrial enlargement. Other indirect signs of high LA pressures in dogs with CMVI are left atrial rupture or acquired atrial

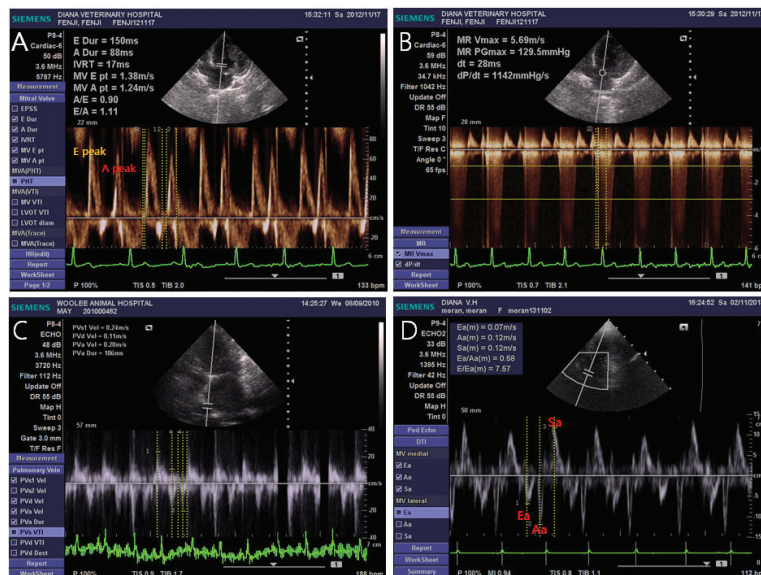


Figure 6. Pulse and continuous Doppler and tissue Doppler echocardiography in dogs with CMVI. (A) The transmitral flow profile consists of E and A and is affected by the pressure gradient between the LA and LV. Elevated E represents increased LA pressure and a worsening of heart failure. (B) Continuous Doppler echocardiography is useful to detect MR in dogs with CMVI. However, the degree of MR is not correlated with the severity of CMVI. (C) Pulse Doppler echocardiography in pulmonary venous flow is also useful to assess the progression of CMVI. The presence of pulmonary venous flow at atrial systole (PvA) indicates high LA pressure noticed in advanced stage of CMVI. (D) The early mitral inflow velocity to early mitral annular tissue velocity (E:Ea) ratio can be used to assess LV diastolic function. The E:E' ratio is significantly correlated with left ventricular filling pressures.

septal defect secondary to atrial septal rupture [77–79]. Due to volume retention, remodeling, and elevations in LA and pulmonary venous pressures, left ventricular volume overload can occur concomitantly with MR worsening [80]. The eccentric hypertrophy, which is characterized by an increase in end-diastolic left ventricular dimensions (EDV), occurs in dogs with CMVI (**Figure 5B**) [81]. The diastolic left ventricular volume and diameters should be assessed by both M-mode and two-dimensional echocardiography.

The common indices of left ventricular systolic myocardial function are ejection fraction (EF) and fractional shortening (FS). The EF is defined by the percent of the end-diastolic volume ejected from left ventricle (LV) with each heart beat. The FS is a measure of the percent change in the dimension from end diastole to end systole [82]. FS is dependent on preload, afterload, and myocardial contractility. Left ventricular systolic myocardial dysfunction is traditionally characterized by reduced EF and FS. However, FS should be increased in dogs with CMVI because of elevated preload and reduced afterload, and hyperdynamic ventricular contraction.

Systolic myocardial dysfunction may be identified by end-systolic left ventricular dimensions, such as end-systolic diameter, end-systolic volume, and end-systolic volume indexed to body surface area (ESVI) [60, 61, 83]. Increased end-systolic left ventricular dimensions are consistently referred to impaired left ventricular systolic function. There are three ultrasound methods, including the Teichholz method, the monoplane Simpson's derived method of discs, and the length-area method, to measure ESVI. Because the Teichholz method tends to overestimate ESVI, other methods except Teichholz method may be recommended in dogs with CMVI [61].

Spectral Doppler methods, including pulsed wave Doppler (PWD) and continuous wave Doppler (CWD), can identify regurgitant jet, transmitral flow in dogs with CMVI (**Figure 6A** and **B**). PWD may be used to record transmitral flow profile. The sample gate should be located in the tip of the leaflet. The transmitral flow profile looks like “M-shaped” and consists of E (peak early transmitral flow velocity) and A (peak late transmitral flow velocity) related to early filling and atrial contraction, respectively [84]. Diastolic function and left ventricular filling pressures can be assessed using PWD method [84]. CWD is generally used for assessing severity of MR and thus provides information on LA pressure, preload, and systemic arterial pressure. CWD can be used to identify elevated LA pressure, left ventricular systolic and diastolic dysfunction in dogs with CMVI [60]. The presence of pulmonary venous flow at atrial systole (PVa) indicates high LA pressure and is commonly noticed in advanced stage of CMVI (**Figure 6C**). Continuous Doppler echocardiography is useful to detect MR in dogs with CMVI (**Figure 6B**). However, the degree of MR is not correlated with the severity of CMVI.

Advanced echocardiographic techniques, including tissue Doppler image (TDI), strain and strain rate imaging, and speckle tracking echocardiography (STE), are recently developed to assess myocardial abnormalities. TDI measures the myocardial velocities to quantify myocardial abnormalities. Systolic and diastolic myocardial abnormalities can be detected by TDI. TDI can be used in PWD and CDI. Myocardial velocity profile is characterized by a S wave, an E wave, and an A wave related to systolic myocardial velocity, early diastolic myocardial relaxation velocity, and late diastolic myocardial relaxation velocity, respectively. Strain and

strain rate imaging are TDI-based measurement and represent regional myocardial deformation and deformation rate, respectively [85, 86]. The two-dimensional STE is recently available and can be used to assess regional myocardial function. The STE is created by irregularities in reflected ultrasound from neighboring structures [87]. Very few data are available regarding advanced echocardiographic techniques data associated with canine heart diseases. TDI provides myocardial and annular velocity. Unlike Doppler patterns of mitral inflow, TDI assessment of diastolic function is relatively load-independent. The early mitral inflow velocity to early mitral annular tissue velocity (E:Ea) can be used to assess LV diastolic function (**Figure 6D**). The E:Ea ratio is significantly correlated with left ventricular filling pressures [88, 89].

Because most dogs affected by CMVI are older, progression of CMVI can lead to diastolic dysfunction, with time. Diastolic dysfunction is characterized by increased resistance to filling and increased left ventricular filling pressure secondary to decreased compliance and impaired relaxation [90, 91]. The assessment of left ventricular diastolic function is difficult to undertake in the dogs with CMVI. Diastolic function can be assessed using several parameters, including isovolumetric relaxation time (IVRT), transmitral flow velocities, and myocardial velocities.

Elevated LA pressure caused by MR and volume overload was found in dogs with moderate-to-severe CMVI [92, 93]. For the noninvasive assessment of LA pressure, the IVRT can be used in volume overload model [93]. IVRT is the time that elapses from aortic valve closure to mitral valve opening. In recent studies, the duration of IVRT and the ratio of E to IVRT were used in the diagnosis of elevated LA pressure [94, 95]. Decrease in IVRT is indicative for increase in LA pressure.

The left ventricular diastolic function can be assessed by Doppler patterns of mitral inflow. The transmitral flow profile consists of E and A and is affected by the pressure gradient between the LA and LV. Elevated E represents increased LA pressure and a worsening of heart failure (**Figure 6A**) [5]. If diastolic function is normal, E is greater than A. In early diastolic dysfunction, a reversal of E and A can be occurred, as left ventricular compliance decreases. Further worsening of diastolic function leads to pseudonormalization associated with increased LA pressure. Because mitral inflow velocities are load-dependent, the use of transmitral flow profile to assess diastolic function remains limited.

One recent study has evaluated the diagnostic value of left atrial volume index (LAVi) and the ratio of early filling to early diastolic mitral annular velocity (E/Ea) on the progression of heart failure in 51 dogs with CMVI and body weight matched 18 healthy control dogs, along with other known echocardiographic markers [96]. The LAVi and E/Ea were well correlated with the severity of heart failure in this study group. Based on the receiver-operating characteristic analysis on echocardiographic variables, the echocardiographic indications for advanced heart failure in this study were left atrium to aorta ratio (LA:Ao) >2.0, left ventricular diastolic dimension to aorta ratio (LVIDd:Ao) >2.4, end-diastolic volume index (EDVI) >100 ml/m², transmitral E-peak >1.2 m/s, E/Ea >9.0 and LAVi 49 ml/m², while indications for healthy or dogs with no signs of cardiac enlargement were LA:Ao <1.3, LVIDd:Ao <1.7, EDVI <45 ml/m², E-peak <0.65 m/s, E/Ea <6.0 and LAVi <15 ml/m² in dogs with CMVI.

4. Treatment

Before initiating treatment for dogs with CMVI, proper staging of heart failure in each affected dogs is required. Two classification systems can be applied in dogs: International Small Animal Cardiac Health Council System (ISACHC) and American College of Veterinary Internal Medicine (ACVIM) classification (**Table 1**).

Basic strategies for treating CMVI are (1) to lessen cardiac workload, (2) to improve clinical conditions from CHF, (3) to retard cardiac remodeling from neurohormonal response from heart failure, and (4) to reduce complications from heart failure. Several therapeutic strategies have been recommended in the veterinary literatures [18, 97–101]. In 2009, the ACVIM released an expert consensus statement and provided therapeutic guideline for dogs with

ISACHC		ACVIM	
		A	Patient at risk of developing heart disease in the future, e.g., patient from breed with high predisposition for cardiac disease
Ia	Asymptomatic: no evidence of compensation for underlying heart disease (no volume overload or pressure overload detected radiographically or echocardiographically)	B1	Asymptomatic patients with evidence of structural heart disease, e.g., presence of murmur: with no evidence of cardiac remodeling (radiographically or echocardiographically)
Ib	Asymptomatic: clinical signs of compensation for underlying heart disease (volume overload or pressure overload detected radiographically or echocardiographically)	B2	Asymptomatic patients with evidence of structural heart disease, e.g., presence of murmur: with evidence of cardiac remodeling
II	Mild-to-moderate heart failure with clinical signs at rest or with mild exercise. Treatment required	C	Patients with clinical signs of congestive heart failure (either past or present) Stage C1 (stabilized CHF) Stage C2 (mild to moderate CHF) Stage C3 (severe and/or life threatening CHF)
IIIa	Advanced heart failure; clinical signs of severe congestive heart failure: home treatment possible		
IIIb	Advanced heart failure; clinical signs of severe congestive heart failure: requires hospitalization		Refractory heart failure. Patients showing clinical signs in spite of standard treatment for congestive heart failure

Table 1. International Small Animal Cardiac Health Council System (ISACHC) and American College of Veterinary Internal Medicine (ACVIM) classification in dogs with heart failure.

CMVI [3]. In practice, the first-line medications for heart failure in dogs with CMVI should include furosemide, pimobendan, and angiotensin-converting enzyme (ACE) inhibitor. The route and dose of furosemide administration should be adjusted based on the degree of respiratory distress and disability. Monitoring renal function is necessary for every dogs, especially before and 3–5 days after initiation and adjustment of furosemide and an ACE inhibitor (ACEI). Either surgical replacement or valvuloplasty of damaged mitral valve has been successfully applied in dogs. Furthermore, experimental prosthetic devices for treating CMVI in dogs are under development and evaluation [102, 103].

4.1. Guidelines for long-term management of CMVI

Stage A (risk for heart failure): Certain breeds of dogs with genetic etiologies, family history of heart disease, a breed predisposition, or concurrent systemic disease with cardiovascular implications (e.g., Cavalier King Charles Spaniels) may have high risk of heart diseases. In these dogs, periodical monitoring for heart diseases is necessary, although no specific therapy is required before the evidence of heart diseases is detectable, according to recent guideline from ACVIM [3]. Dogs used for breeding should be removed from the breeding program if CMVI is present in earlier life. It should be recommended to the dog's owner for periodic cardiac examinations. It is also recommended to manage predisposing condition and to manage systemic hypertension, if present. No dietary sodium modifications are necessary in this stage.

Stage B1 (heart disease is present: no symptoms, no obvious chamber enlargement): It is better to inform the owner clinical signs related to CHF (tachypnea, dyspnea, coughing) as early as possible. Periodic reevaluation for signs of disease progression and complications is necessary. For patients with CMVI, there is no evidence indicating that there is any beneficial effect of using an ACE inhibitor (ACEI) or pimobendan at this stage.

Stage B2 (heart disease is present: no symptoms, cardiomegaly present): It is generally recommended the use of ACEI (enalapril 0.5 mg/kg PO sid to bid; benazepril 0.5 mg/kg PO sid) and highly palatable mildly sodium-restricted diet. Some cardiologists suggested the use of spironolactone 1 mg/kg PO bid for possible aldactone escape. More detailed guideline can be found in the section “Guideline for asymptomatic dogs with CMVI.”

Stage C1 (stabilized CHF): If dogs had historical signs of congestive heart failure (CHF), but had no symptoms currently, it is important to keep clinical signs stabilized. Drugs for routine use are furosemide (mandatory) along with ACEI, and/or pimobendan. Drugs for selected patients are spironolactone, digoxin, thiazide, amlodipine/hydralazine, or other vasodilator. In this stage of dogs, excessive sodium intake, beta-blockers, corticosteroid, and intravenous (IV) fluid should be avoided, if possible (unless required for concurrent disease). If IV fluid is given to this dog, it requires careful monitoring of the respiratory rate trend.

Stage C2 (mild-to-moderate CHF): Therapeutic goals are to eliminate pulmonary edema or effusions, to improve hemodynamics, and to modulate neurohormonal activation. In dogs with CMVI, drugs include furosemide (1–2 mg/kg PO bid), ACEI (enalapril 0.5 mg/kg PO bid), and pimobendan (0.25 mg/kg PO bid). Digoxin may be beneficial, if atrial fibrillation is

present. Beta-blockers should not be introduced firstly, unless the dog is being medicated. In this stage of dogs, excessive sodium intake, beta-blockers, corticosteroid, and intravenous (IV) fluid should be avoided, if possible (unless required for concurrent disease). If IV fluid is given to this dog, it requires careful monitoring of the respiratory rate trend.

Stage C3 (severe and/or life threatening CHF): Therapeutic goals are to treat hypoxemia, to increase cardiac output, and to stabilize the patient in hospital with intravenous drugs. Drugs for routine use in stage C2 are needed with oxygen supplementation (depending on dog's condition) and high dose of furosemide (2–8 mg/kg IV; repeat injections every 1–2 h if there is no improvement in respiratory rate) with nitrate therapy (e.g., nitroglycerin patch/cream, sodium nitroprusside, isosorbide dinitrate). As the respiratory rate decreases, the dosage and frequency of administration are reduced to the lowest dose effective in controlling the pulmonary edema. Renal function should be kept monitoring.

Stage D (refractory, chronic CHF): Drugs for routine use in stage C3 are needed with increased dose/frequency of pimobendan (up to 0.7 mg/kg, PO, tid), supplementation of spironolactone (1–2 mg/kg PO, bid) and hydrochlorothiazide (1–2 mg/kg, PO, bid), subcutaneous furosemide, repeated centesis for effusions, digoxin or other antiarrhythmic drugs if needed, and very low sodium intake. Triple diuretics (furosemide, spironolactone, hydrochlorothiazide) can reduce the dose of furosemide required to control the patient's congestive signs. In CMVI, it can be considered for additional amlodipine (0.05 mg/kg PO, sid, then 0.1 mg/kg PO, with blood pressure monitoring) if blood pressure is normally preserved.

4.2. Guidelines for short-term management (acute pulmonary edema) of CMVI

Stage Ca (acute heart failure requiring hospitalization): The goals of therapy are to relieve the severe pulmonary edema. For dogs with pulmonary edema from acute pulmonary edema, the therapy should be directed (1) to reduce the circulating blood volume by either/both aggressive and immediate diuretic therapy (e.g., furosemide IV or CRI) and/or phlebotomy (10 ml/kg), (2) to reduce the venous return to the cardiac chambers [e.g., topical 2% nitroglycerin cream, intravenous acepromazine, intravenous sodium nitroprusside (SNP) CRI], (3) to increase oxygen saturation (e.g., oxygen tent or nasal oxygen), and (4) to strengthen myocardial systolic function (e.g., intravenous dobutamine 5–15 µg/kg/min CRI).

Stage Da (refractory heart failure requiring hospitalization): Aggressive furosemide therapy [4 mg/kg IV followed by repeat injections every 4 h or 4 mg/kg IV followed by CRI (0.2–1 mg/kg/hr for 8–12 h)] should be initiated as early as possible, till respiratory rate has fallen by 50%. Intravenous sodium nitroprusside (SNP) therapy along with furosemide would be beneficial to stabilize CHF dogs. To achieve this therapeutic goal, intravenous infusion of SNP should be administered at 2 µg/kg/min and then increased by increments of 1 µg/kg/min every 30 min (maximum dose should not be over 6 µg/kg/min) to reach desirable therapeutic effect, if mean and systolic blood pressure of dogs maintain above 75 and 90 mmHg, respectively. Intravenous inotropic support using dobutamine is often also required. Intravenous dobutamine infusion should be started at 5 µg/kg/min and then increased by 2.5 µg/kg/min every 4 h to reach therapeutic effect (a maximal dose of 15 µg/kg/min). The dose rate should be adjusted by mean heart rate (HR) of dogs. The infusion rate should be reduced, if the

heart rate increases by 10% or rises over 180 bpm. It is also recommended to supply oxygen by tent, cage, mask, and neck collar or even mechanical ventilation. Clinicians should relieve dyspnea/discomfort via appropriate humidity, environmental temperature, and body positioning during oxygen supplementation.

4.3. Guideline for asymptomatic dogs with CMVI

Several studies have evaluated what cardiac medications can retard the progression of heart failure and can be more effective in asymptomatic HF dogs [18, 104], although most monotherapy was not able to achieve these goals, to date. One recent study has evaluated the outcome of dogs with preclinical cardiomyopathy with atrial fibrillation after either pimobendan monotherapy or benazepril monotherapy, and has found that pimobendan monotherapy provided significantly better outcome (i.e., prolonged time to onset of HF or reduced incidence of sudden death [105]). Unfortunately, several studies failed to find beneficial effects on survival and onset of HF in asymptomatic dogs with various heart diseases after the long-term administration of ACEI including enalapril [99, 105]. One recent small pilot study in dogs with asymptomatic HF found modest evidence of beneficial effect on retarding the onset of clinical HF after pimobendan and enalapril dual therapy [106]. One other recent study in asymptomatic dogs with CMVI has also found echocardiographic evidences on improvement of cardiac performance (i.e., increased %LVEF and decreased ESVI) for the first few months after pimobendan monotherapy [107], although this effect did not last to the end of test period (6 months). One recent study on preclinical CMVI dogs after long-term treatment of enalapril has found long-term administration of enalapril could significantly delay onset of HF and the endpoint of HF-all-cause death [104], although the other study in asymptomatic Cavalier King Charles Spaniels with CMVI has failed to find this beneficial effect [99].

4.4. New therapeutic agents in dogs with CMVI

Isosorbide dinitrate (ISDN) is a moderate- to long-acting organic nitrate, and its venodilatory effects may help reduce preload and hence pulmonary edema. In humans, ISDN is used for treating or preventing angina, treating esophageal spasm and achalasia [108, 109]. In addition, it is widely used for CHF outpatients as an adjunctive treatment in CHF [110, 111]. In dogs, it occasionally used to adjuvant agent for management of chronic heart failure or in combination with an arteriolar dilator for patients unable to tolerate an ACEI [112]. However, there is limited experience in using this drug in veterinary medicine, and adverse effect is not well known. In humans, the most common adverse effects are headache and postural hypotension. Tachycardia, restlessness, or gastrointestinal effects are not uncommon. There have been rare cases of patients who are hypersensitive to organic nitrates. One recent study has evaluated the efficacy of ISDN for treating advanced stage CHF due to CMVI [113]. Twenty dogs with CMVI were enrolled in this study. All dogs were administered sustained-release ISDN (1 mg/kg, q12hr, PO) along with conventional cardiac medication. Changes in systolic blood pressure (SAP), heart rate (HR), and echocardiographic indices indicating the progression of CHF were evaluated at 7, 15, 30, and 60 days after the administration of ISDN. Significant improvements in echocardiographic indices were found at 7, 15, 30, and 60 days after the administration of ISDN, although the Systolic arterial pressure (SAP) was slightly decreased and the HR

was slightly increased. This study suggested that ISDN could effectively reduce the cardiac preload and thus improve cardiac performance in dogs with advanced heart failure [113].

Angiotensin receptor blockers (ARBs) inhibit type I angiotensin II (AT1) receptor distributed in blood vessels and heart, and thus exert similar pharmacological action of ACEI. Because the ARBs only block type I receptor, they can reduce risk of renal injury from full inhibition of ACE [114]. Therefore, it can use for treating dogs with CHF, when the ACEIs cause renal azotemia [115]. However, the application of these agents on veterinary medicine is limited due to lack of studies related to ARBs in dogs. The common ARBs in veterinary fields are candesartan, losartan, valsartan, and telmisartan.

Pimobendan is a benzimidazole-pyridazinone drug which is used commonly for treating various heart diseases in dogs including CHF. It acts through calcium sensitization and inhibition of phosphodiesterase III [116, 117]. Pimobendan has vasorelaxation effect by inhibition of phosphodiesterase III and positive inotropic effect through calcium sensitization in myocardial sarcomere [118, 119]. Pimobendan can improve myocardial contractility without increasing the risk of arrhythmia unlike digitalis, because this drug does not require oxygen consumption of myocardium [100, 120]. Pimobendan can effectively decrease afterload and peripheral vessel resistance by relaxing vascular smooth muscle through inhibiting a vasoconstriction factor like PDE III [121, 122]. Pimobendan can also delay inflammatory response of myocardium and can improve myocardial contraction by weakening revelation of inflammation precursor and nitric oxide synthesis [123, 124]. Pimobendan can increase sinus rate through rising of blood volume in normal dogs, although it rarely causes arrhythmia unlike digitalis [125, 126]. Therefore, those pharmacological effects are very useful for control clinical signs associated with CHF in dogs and have been well documented in veterinary literatures [127, 128].

5. Complications and prognosis

There are some complications due to heart failure from CMVI such as ruptured chordae tendineae (RCT), pulmonary hypertension (PHT), acute exacerbation of pulmonary congestion, LA rupture, and cardio-renal syndrome (CRS) caused by forward heart failure from CMVI [23, 129].

5.1. Deterioration of cardiac disease

RCT can cause acute exacerbation of pulmonary congestion and edema in dogs with CMVI. In particular, if the first-order chordae attached to the septal leaflet is ruptured, the clinical signs tend to more rapidly aggravate from acute volume overload and fulminant pulmonary edema [68], although the RCT in different mitral leaflet may not cause significant clinical signs. In dogs with significant RCT, marked increase in LA and pulmonary venous pressures can lead to acute pulmonary edema, pulmonary artery hypertension, and right-sided heart failure [22, 130]. Therefore, these dogs usually require intensive care to stabilize the condition along with the standard therapy for CMVI.

Right-sided heart failure is common, especially in dogs with long-standing history of CMVI. Right-sided heart failure can be occurred by either/both concurrent chronic tricuspid insufficiency from myxomatous degeneration and/or the PHT from LA volume and pressure overload. Dogs with marked PHT generally show marked exercise intolerance with signs of weakness or collapse. Signs related to right-sided heart failure (e.g., ascites, pleural effusion, hepatic and splenic congestion, and distention of the jugular veins with abnormal pulsations) can be noticed in physical examination. The presence and degree of PHT can be accurately assessed by Doppler echocardiography. Oxygen supplementation and pulmonary arterial vasodilator (e.g., sildenafil) are helpful to lessen clinical signs in dogs [131, 132].

Tachyarrhythmias are more commonly occurred in dogs having an enlarged LA. Common tachyarrhythmias in dogs with CMVI are supraventricular premature beats, atrial fibrillation, and supraventricular tachycardia. If the tachyarrhythmia has ventricular rate >180 bpm, it can cause hemodynamically significant change in dogs with CMVI and cause an acute onset of pulmonary edema. This condition is more often seen in dogs with long-standing CMVI. Therapeutic goals for these dogs are directed to relieve the pulmonary edema along with the reduction in heart rate to an acceptable rate for improving cardiac output.

Left atrial rupture and cardiac tamponade can be occurred by marked dilation of LA in dogs with CMVI, because the LA becomes thin walled and more vulnerable to increase in pressure. One study found that endocardial splitting is more common in dogs with long-standing CMVI [133]. Long-standing and marked LA volume and pressure overload can progress to rupture of the LA, subsequently with the acute onset of hemopericardium, cardiac tamponade, and sudden death. Acute development of ascites, collapse, or marked exercise intolerance can be signs for sudden development of LA rupture and cardiac tamponade. Echocardiography is necessary for confirming the presence of significant pericardial effusion. Although immediate pericardiocentesis may be helpful to alleviate clinical signs, the prognosis is usually poor.

5.2. Cardio-renal syndrome

Cardio-renal syndrome (CRS) is a clinical syndrome broadly in which dysfunctional hearts and dysfunctional kidneys can “initiate and perpetuate disease in the other organ through common hemodynamic, neurohormonal, and immunological/biochemical feedback pathways” [134]. General definition of CRS is a pathophysiologic disorder of the heart and kidneys, whereby acute or chronic dysfunction in one organ may induce acute or chronic dysfunction in the other organ. According to human medical literature [134], the CRS is largely divided into five types: (1) Type I (acute CRS) is acute kidney injury induced by acute heart failure (e.g., acute cardiogenic shock or acutely decompensated CHF), (2) Type II (chronic CRS) is permanent and progressive chronic kidney disease induced by chronic heart failure (e.g., chronic abnormalities in cardiac function), (3) Type III (acute reno-cardiac syndrome, RCS) is acute heart failure induced by acute kidney diseases (e.g., acute kidney ischemia or glomerulonephritis), (4) Type IV (chronic RCS) is chronic heart failure induced by chronic kidney disease (e.g., chronic glomerular or interstitial disease), and (5) Type V (secondary CRS) is heart and renal failure induced by systemic diseases (e.g., diabetes mellitus, sepsis). Major mechanisms of CRS include renal hypoperfusion directly resulting from a decreased

cardiac output and neurohormone-mediated renal damage as hypertensive nephropathy via activation of the renin-angiotensin-aldosterone system (RAAS) among others.

In veterinary study, the prevalence of azotemia is high in dogs with CMVI and increases with the severity of the heart failure and azotemia is associated with a decrease in GFR [135]. Azotemia and renal impairment increase with the severity of CHF and are frequent findings in dogs with CMVI [129]. One retrospective study of 33 dogs with CMVI demonstrated that the prevalence of azotemia (defined as abnormally elevated serum levels of Cys-C, SDMA, and creatinine) was increased in dogs with CMVI [28]. Azotemia and renal impairment increase with the severity of HF and are frequent findings in dogs with CMVI [129]. Keys for successful management of CRS are: (1) try to decrease the dosage of furosemide if azotemia was worsen during the CHF treatment, (2) increase water intake, (3) consider IV fluid, if patients have clinical sings of azotemia (e.g., 2.5% dex + 0.45% saline, 5% dextrose; 30–40 ml/kg/day), and (4) monitor patient's condition regularly to maintain proper dose of furosemide/ACEI.

5.3. Impaired function of digestive system

Impaired function of digestive system is associated with malassimilation (i.e., maldigestion and malabsorption) induced weight loss [136]. The weight loss is a major clinical finding in certain degenerative diseases including CMVI [23], hepatobiliary disease [137], and pancreatitis [138]. Aging is involved in the pathogenesis of CMVI in dogs [6–8, 139] and can induce several anatomical changes and involve in progressive deterioration of the vital physiological functions. The organ congestion and poor body perfusion can be occurred by heart failure [25], and these can lead to organ damage (i.e., pancreas, liver, intestine) and dysfunction (i.e., maldigestion and malabsorption, hepatomegaly, ascites) [23, 140–144]. Therefore, pancreatic dysfunction associated with heart failure can be occurred in dogs with advanced stage of heart diseases. Ischemia can induce acute/chronic pancreatitis and is one of the important etiologies of acute pancreatitis in human. Several mechanisms are involved in pathogenesis of pancreatitis, such as hemorrhage or hypotension, mesenteric macro-vessel occlusion, post-transplantation pancreatitis, cardiopulmonary bypass. Different causes of ischemia can lead to a hypoperfusion of the pancreas with a consecutive induction of an inflammatory response. Diagnosis of pancreatitis is straightforward with in-house diagnostic test kit (SNAP® cPLI™), which has 95% correlation on sensitivity to the reference laboratory. One recent study found that CMVI is associated with pancreatic injury in congestive heart failure caused by CMVI. Therefore, periodic monitoring on cPLI could be useful in monitoring dogs in heart failure [27].

Oral cavity is one of the blood-rich organs. Hypoxia can induce many dental problems including dental tartar and periodontitis, which is requiring general anesthesia for treatment. We developed anesthetic protocol for dogs with cardiac diseases [145]. Our study was designed to evaluate the effects on cardiovascular system in dogs using anesthetic combination of alfaxalone, butorphanol, and midazolam. Compared to the baseline value (before anesthesia), all cardiac indices were decreased, although only heart rate and aortic blood pressure were statistically significantly decreased ($p < 0.05$). However, the cardiac depression was minimal and transient by this combination of anesthetic agents [145].

Cardiac cachexia is generally seen in dogs with history of long-standing CMVI [23, 99]. Once heart failure develops, an important indicator of a worsening condition is the occurrence of cardiac cachexia, which is unintentional rapid weight loss (a loss of at least 7.5% of normal weight within 6 months).

5.4. Prognosis

Many dogs with CMVI may live for years before developing any symptoms. Prognosis for dogs with CMVI is greatly depending on the severity of heart failure and duration and quality of medical therapy and patient monitoring. Generally, the average survival time of dogs with CMVI is ~3 years in dogs with ISACHC I stage heart failure, while 1–3 years in dogs with ISACHC II stage heart failure and ~6–12 months in dogs with ISACHC III stage of heart failure, respectively [13]. There are several prognostic indicators for dogs with CMVI. The degree of exercise intolerance [146], degree of cardiomegaly [53], degree of LA/LV enlargement [7, 147], and certain ECG indices (e.g., the degree of tachycardia or vagus tone index) [51] were closely related to the prognosis. Furthermore, certain echocardiographic indices (e.g., LA/Ao ratio, E/A wave ratio, EDVI) were found to be a good prognostic indicator in dogs with CMVI [84, 148]. Weight loss (e.g., cachexia) and degree of azotemia by reduced glomerular filtration rate (GFR) are indicators for worsening clinical signs.

Author details

Sang-II Suh¹, Dong-Hyun Han¹, Seung-Gon Lee², Yong-Wei Hung³, Ran Choi⁴ and Changbaig Hyun^{1*}

*Address all correspondence to: hyun5188@kangwon.ac.kr

1 Section of Small Animal Internal Medicine, College of Veterinary Medicine, Kangwon National University, Chuncheon, Korea

2 Seoul Animal Heart Hospital, Seoul, Korea

3 Cardiospecial Veterinary Hospital, Taipei, Taiwan

4 Cardiology Section, Dasom Animal Medical Center, Busan, Korea

References

- [1] Buchanan JW: Prevalence of cardiovascular disorders. In: Fox PR, Sisson D, Moise NS, editors. Textbook of canine and feline cardiology, 2nd ed. Philadelphia: WB Saunders; 1999. p. 457–470.
- [2] Häggström J, Pedersen DH, Kvart C: New insights into degenerative mitral valve disease in dogs. *Vet Clin North Am Small Anim Pract.* 2004; **34**: 1209–1226. doi:10.1016/j.cvsm.2004.05.002

- [3] Atkins C, Bonagura J, Ettinger S, Fox P, Gordon S, Häggström J, Hamlin R, Keene B, Luis-Fuentes V, Stepien R: Guidelines for the diagnosis and treatment of canine chronic valvular heart disease. *J Vet Intern Med.* 2009; **23**: 1142–1150. doi:10.1111/j.1939-1676.2009.0392.x
- [4] Fox PR: Pathology of myxomatous mitral valve disease in the dog. *J Vet Cardiol.* 2012; **14**: 103–126. doi:10.1016/j.jvc.2012.02.001
- [5] Borgarelli M, Savarino P, Crosara S, Santilli RA, Chiavegato D, Poggi M, Bellino C, La Rosa G, Zanatta R, Haggstrom J, Tarducci A: Survival characteristics and prognostic variables of dogs with mitral regurgitation attributable to myxomatous valve disease. *J Vet Intern Med.* 2008; **22**: 120–128. doi:10.1111/j.1939-1676.2007.0008.x
- [6] Olsen LH, Fredholm M, Pedersen HD: Epidemiology and inheritance of mitral valve prolapse in dachshunds. *J Vet Intern Med.* 1999; **13**: 448–456. doi:10.1111/j.1939-1676.1999.tb01462.x
- [7] Pedersen D, Lorentzen K, Kristensen B: Echocardiographic mitral valve prolapse in cavalier king charles spaniels: epidemiology and prognostic significance for regurgitation. *Vet Rec.* 1999; **144**: 315–320. doi:10.1136/vr.144.12.315
- [8] Swenson L, Häggström J, Kvart C, Juneja R: Relationship between parental cardiac status in cavalier king charles spaniels and prevalence and severity of chronic valvular disease in offspring. *J Am Vet Med Assoc.* 1996; **208**: 2009–2012.
- [9] Häggström J, Hansson K, Kvart C, Swenson L: Chronic valvular disease in the cavalier king charles spaniel in Sweden. *Vet Rec.* 1992; **131**: 549–553. doi:10.1136/vr.131.24.549
- [10] Pedersen HD, Nørby B, Lorentzen KA: Echocardiographic study of mitral valve prolapse in dachshunds. *Zentralbl Veterinarmed A.* 1996; **43**: 103–110. doi:10.1111/j.1439-0442.1996.tb00433.x
- [11] Buchanan JW: Chronic valvular disease (endocardiosis) in dogs. *Adv Vet Sci Comp Med.* 1977; **21**: 75–106.
- [12] Parker HG, Kilroy-Glynn P: Myxomatous mitral valve disease in dogs: does size matter? *J Vet Cardiol.* 2012; **14**: 19–29. doi:10.1016/j.jvc.2012.01.006
- [13] Hyun C: Acquired heart valvular diseases. In: Hyun C, editor. *Case studies in small animal cardiology*, 1st ed. Seoul: Panmun Education; 2013. p. 353–398.
- [14] Yosefy C, Ben BA: Floppy mitral valve/mitral valve prolapse and genetics. *J Heart Valve Dis.* 2007; **16**: 590–595.
- [15] Lewis T, Swift S, Woolliams JA, Blott S: Heritability of premature mitral valve disease in cavalier king charles spaniels. *Vet J.* 2011; **188**: 73–76. doi:10.1016/j.tvjl.2010.02.016
- [16] Kienle R, Thomas W. Echocardiography. In: Nyland T, Mattoon J, editors. *Small animal diagnostic ultrasound*, 2nd ed. Philadelphia: WB Saunders; 2002. p. 354–423.
- [17] Das K, Tashjian R: Chronic mitral valve disease in the dog. *Vet Med Small Anim Clin.* 1965; **60**: 1209–1216.

- [18] Kvart C, Häggström J, Pedersen HD, Hansson K, Eriksson A, Järvinen A-K, Tidholm A, Bsenko K, Ahlgren E, Lives M, Åblad B, Falk T, Bjerkås E, Gundler S, Lord P, Wegeland G, Adolfsson E, Corfitzen J: Efficacy of enalapril for prevention of congestive heart failure in dogs with myxomatous valve disease and asymptomatic mitral regurgitation. *J Vet Intern Med.* 2002; **16**: 80–88. doi:10.1111/j.1939-1676.2002.tb01610.x
- [19] Kogure K: Pathology of chronic mitral valvular disease in the dog. *Nihon Juigaku Zasshi.* 1980; **42**: 323–335. doi:10.1292/jvms1939.42.323
- [20] Pomerance A, Whitney JC: Heart valve changes common to man and dog: a comparative study. *Cardiovasc Res.* 1970; **4**: 61–66. doi:10.1111/j.1748-5827.1970.tb05603.x
- [21] Davies M, Moore B, Braimbridge M: The floppy mitral valve. Study of incidence, pathology, and complications in surgical, necropsy, and forensic material. *Br Heart J.* 1978; **40**: 468. doi:10.1136/hrt.40.5.468
- [22] Kihara Y, Sasayama S, Miyazaki S, Onodera T, Susawa T, Nakamura Y, Fujiwara H, Kawai C: Role of the left atrium in adaptation of the heart to chronic mitral regurgitation in conscious dogs. *Circ Res.* 1988; **62**: 543–553. doi:10.1161/01.RES.62.3.543
- [23] Olsen LH, Häggström J, Petersen HD. Acquired valvular heart disease. In: Ettinger SJ, Feldman E, editors. *Textbook of veterinary internal medicine*, 7th ed. Philadelphia: W.B. Saunders; 2010. p. 1299–1319.
- [24] Häggström J, Kvart C, Hansson K: Heart sounds and murmurs: changes related to severity of chronic valvular disease in the cavalier king charles spaniel. *J Vet Intern Med.* 1995; **9**: 75–85. doi:10.1111/j.1939-1676.1995.tb03276.x
- [25] Smith P: Management of chronic degenerative mitral valve disease in dogs. In *Practice.* 2006; 376. doi:10.1136/inpract.28.7.376
- [26] Choi W-J: Evaluation of hepatic function panel in dogs with degenerative valvular disease [thesis]. Chuncheon: Kangwon National University; 2016.
- [27] Han D, Choi R, Hyun C: Canine pancreatic-specific lipase concentrations in dogs with heart failure and chronic mitral valvular insufficiency. *J Vet Intern Med.* 2015; **29**: 180–183. doi:10.1111/jvim.12521
- [28] Choi B-S, Moon H-S, Suh S-I, Hyun C. Evaluation of serum cystatin-C and symmetric dimethylarginine concentrations in dogs with heart failure from chronic mitral valvular insufficiency. *J Vet Med Sci.* 2016, in press.
- [29] Maisel AS, Krishnaswamy P, Nowak RM, McCord J, Hollander JE, Duc P, Omland T, Storrow AB, Abraham WT, Wu AH, Clopton P, Steg PG, Westheim A, Knudsen CW, Perez A, Kazanegra R, Herrmann HC, McCullough PA: Rapid measurement of b-type natriuretic peptide in the emergency diagnosis of heart failure. *N Engl J Med.* 2002; **347**: 161–167. doi:10.1056/NEJMoa020233
- [30] Antman EM, Tanasijevic MJ, Thompson B, Schactman M, McCabe CH, Cannon CP, Fischer GA, Fung AY, Thompson C, Wybenga D, Braunwald E: Cardiac-specific troponin

- i levels to predict the risk of mortality in patients with acute coronary syndromes. *N Engl J Med*. 1996; **335**: 1342–1349. doi:10.1056/NEJM199610313351802
- [31] Jain MK, Ridker PM: Anti-inflammatory effects of statins: clinical evidence and basic mechanisms. *Nat Rev Drug Discov*. 2005; **4**: 977–987. doi:10.1038/nrd1901
- [32] Spratt DP, Mellanby RJ, Drury N, Archer J: Cardiac troponin I: evaluation i of a bio-marker for the diagnosis of heart disease in the dog. *J Small Anim Pract*. 2005; **46**: 139–145. doi:10.1111/j.1748-5827.2005.tb00304.x
- [33] Herndon WE, Kittleson MD, Sanderson K, Drobatz KJ, Clifford CA, Gelzer A, Summerfield NJ, Linde A, Sleeper MM: Cardiac troponin i in feline hypertrophic cardiomyopathy. *J Vet Intern Med*. 2002; **16**: 558–564. doi:10.1111/j.1939-1676.2002.tb02387.x
- [34] Hagman R, Lagerstedt AS, Fransson BA, Bergstrom A, Haggstrom J: Cardiac troponin i levels in canine pyometra. *Acta Vet Scand*. 2007; **49**: 6. doi:10.1186/1751-0147-49-6
- [35] Schober KE, Cornand C, Kirbach B, Aupperle H, Oechtering G: Serum cardiac troponin i and cardiac troponin t concentrations in dogs with gastric dilatation-volvulus. *J Am Vet Med Assoc*. 2002; **221**: 381–388. doi:10.2460/javma.2002.221.381
- [36] Schober KE, Kirbach B, Oechtering G: Noninvasive assessment of myocardial cell injury in dogs with suspected cardiac contusion. *J Vet Cardiol*. 1999; **1**: 17–25. doi:10.1016/S1760-2734(06)70030-3
- [37] Palazzuoli A, Beltrami M, Ruocco G, Pellegrini M, Nuti R: The role of natriuretic peptides for the diagnosis of left ventricular dysfunction. *Sci. World J*. 2013; 2013: 784670. doi:10.1155/2013/784670
- [38] DeFrancesco TC, Rush JE, Rozanski EA, Hansen BD, Keene BW, Moore DT, Atkins CE: Prospective clinical evaluation of an elisa b-type natriuretic peptide assay in the diagnosis of congestive heart failure in dogs presenting with cough or dyspnea. *J Vet Intern Med*. 2007; **21**: 243–250. doi:10.1111/j.1939-1676.2007.tb02956.x
- [39] Boswood A, Dukes-McEwan J, Loureiro J, James RA, Martin M, Stafford-Johnson M, Smith P, Little C, Attree S: The diagnostic accuracy of different natriuretic peptides in the investigation of canine cardiac disease. *J Small Anim Pract*. 2008; **49**: 26–32. doi:10.1111/j.1748-5827.2007.00510.x
- [40] Caspi D, Snel FW, Batt RM, Bennett D, Rutteman GR, Hartman EG, Baltz ML, Gruys E, Pepys MB: C-reactive protein in dogs. *Am J Vet Res*. 1987; **48**: 919–921.
- [41] Kushner I, Feldmann G: Control of the acute phase response. Demonstration of c-reactive protein synthesis and secretion by hepatocytes during acute inflammation in the rabbit. *J Exp Med*. 1978; **148**: 466–477. doi:10.1084/jem.148.2.466
- [42] Dabrowski R, Kostro K, Lisiecka U, Szczubial M, Krakowski L: Usefulness of c-reactive protein, serum amyloid a component, and haptoglobin determinations in bitches with pyometra for monitoring early post-ovariohysterectomy complications. *Theriogenology*. 2009; **72**: 471–476. doi:10.1016/j.theriogenology.2009.03.017

- [43] Kjelgaard-Hansen M, Jensen AL, Houser GA, Jessen LR, Kristensen AT: Use of serum c-reactive protein as an early marker of inflammatory activity in canine type II immune-mediated polyarthritis: case report. *Acta Vet Scand.* 2006; **48**: 9. doi:10.1186/1751-0147-48-9
- [44] Matijatko V, Mrljak V, Kis I, Kucer N, Forsek J, Zivicnjak T, Romic Z, Simec Z, Ceron JJ: Evidence of an acute phase response in dogs naturally infected with *babesia canis*. *Vet Parasitol.* 2007; **144**: 242–250. doi:10.1016/j.vetpar.2006.10.004
- [45] Nakamura M, Takahashi M, Ohno K, Koshino A, Nakashima K, Setoguchi A, Fujino Y, Tsujimoto H: C-reactive protein concentration in dogs with various diseases. *J Vet Med Sci.* 2008; **70**: 127–131. doi:10.1292/jvms.70.127
- [46] Otabe K, Ito T, Sugimoto T, Yamamoto S: C-reactive protein (CRP) measurement in canine serum following experimentally-induced acute gastric mucosal injury. *Lab Anim.* 2000; **34**: 434–438. doi:10.1258/002367700780387679
- [47] Yamamoto S, Shida T, Miyaji S, Santsuka H, Fujise H, Mukawa K, Furukawa E, Nagae T, Naiki M: Changes in serum c-reactive protein levels in dogs with various disorders and surgical traumas. *Vet Res Commun.* 1993; **17**: 85–93. doi:10.1007/BF01839236
- [48] Rush JE, Lee ND, Freeman LM, Brewer B: C-reactive protein concentration in dogs with chronic valvular disease. *J Vet Intern Med.* 2006; **20**: 635–639. doi:10.1111/j.1939-1676.2006.tb02908.x
- [49] Hyun C. Valvular diseases. In: Hyun C, editor. *Small animal cardiology*, 1st ed. Seoul: Panmun Publication; 2005. p. 185–206.
- [50] Häggström J, Hamlin RL, Hansson K, Kvart C: Heart rate variability in relation to severity of mitral regurgitation in cavalier king charles spaniels. *J Small Anim Pract.* 1996; **37**: 69–75. doi:10.1111/j.1748-5827.1996.tb01941.x
- [51] Lopez-Alvarez J, Boswood A, Moonarmart W, Hezzell MJ, Lotter N, Elliott J: Longitudinal electrocardiographic evaluation of dogs with degenerative mitral valve disease. *J Vet Intern Med.* 2014; **28**: 393–400. doi:10.1111/jvim.12311
- [52] Rush JE: Chronic valvular heart disease in dogs. In: *Proceedings of 26th Annual Waltham Diets/OSU Symposium for the Treatment of Small Animal Cardiology*. 2002.
- [53] Buchanan JW, Bucheler J: Vertebral scale system to measure canine heart size in radiographs. *J Am Vet Med Assoc.* 1995; **206**: 194–199.
- [54] Lord PF, Hansson K, Carnabuci C, Kvart C, Haggstrom J: Radiographic heart size and its rate of increase as tests for onset of congestive heart failure in cavalier king charles spaniels with mitral valve regurgitation. *J Vet Intern Med.* 2011; **25**: 1312–1319. doi:10.1111/j.1939-1676.2011.00792.x
- [55] Ettinger S, Kantrowitz B. Disease of the trachea. In: Ettinger S, Feldman E, editors. *Textbook of veterinary internal medicine*. 6th ed. St. Louis, MO: Elsevier Saunders; 2005. p. 1217–1232.

- [56] Boon JA: Acquired heart disease: mitral insufficiency; In: Boon JA, editor. *Manual of veterinary echocardiography*. 1st ed. Baltimore: Williams and Wilkins; 1998. p. 261–286.
- [57] Serres FJ, Chetboul V, Tissier R, Carlos Sampedrano C, Gouni V, Nicolle AP, Pouchelon JL: Doppler echocardiography-derived evidence of pulmonary arterial hypertension in dogs with degenerative mitral valve disease: 86 cases (2001–2005). *J Am Vet Med Assoc*. 2006; **229**: 1772–1778. doi:10.2460/javma.229.11.1772
- [58] Stepien RL: Pulmonary arterial hypertension secondary to chronic left-sided cardiac dysfunction in dogs. *J Small Anim Pract*. 2009; **50**(Suppl 1): 34–43. doi:10.1111/j.1748-5827.2009.00802.x
- [59] Chiavegato D, Borgarelli M, D'Agnolo G, Santilli RA: Pulmonary hypertension in dogs with mitral regurgitation attributable to myxomatous valve disease. *Vet Radiol Ultrasound*. 2009; **50**: 253–258. doi:10.1111/j.1740-8261.2009.01529.x
- [60] Bonagura JD, Schober KE: Can ventricular function be assessed by echocardiography in chronic canine mitral valve disease? *J Small Anim Pract*. 2009; **50**(Suppl 1): 12–24. doi:10.1111/j.1748-5827.2009.00803.x
- [61] Serres F, Chetboul V, Tissier R, Poujol L, Gouni V, Carlos Sampedrano C, Pouchelon JL: Comparison of 3 ultrasound methods for quantifying left ventricular systolic function: correlation with disease severity and prognostic value in dogs with mitral valve disease. *J Vet Intern Med*. 2008; **22**: 566–577. doi:10.1111/j.1939-1676.2008.0097.x
- [62] Kvart C, Häggström J. Acquired valvular heart disease. In: Ettinger S, Feldman E, editors. *Textbook of veterinary internal medicine*, 6th ed. Philadelphia: WB Saunders; 2005. p. 1022–1039.
- [63] Bonagura JD, Herring DS: Echocardiography. Acquired heart disease. *Vet Clin North Am Small Anim Pract*. 1985; **15**: 1209–1224. doi:10.1016/S0195-5616(85)50366-6
- [64] Terzo E, Di Marcello M, McAllister H, Glazier B, Lo Coco D, Locatelli C, Palermo V, Brambilla PG: Echocardiographic assessment of 537 dogs with mitral valve prolapse and leaflet involvement. *Vet Radiol Ultrasound*. 2009; **50**: 416–422. doi:10.1111/j.1740-8261.2009.01559.x
- [65] Olivier N, Kittleson M, Eyster G, Miller J: M-mode echocardiography in the diagnosis of ruptured mitral chordae tendineae in a dog. *J Am Vet Med Assoc*. 1984; **184**: 588–589.
- [66] Jacobs G, Calvert C, Mahaffey M, Hall D: Echocardiographic detection of flail left atrioventricular valve cusp from ruptured chordae tendineae in 4 dogs. *J Vet Intern Med*. 1995; **9**: 341–346. doi:10.1111/j.1939-1676.1995.tb01095.x
- [67] Kittleson M, Kienle R. Myxomatous atrioventricular valvular degeneration. In: Kittleson M, Kienle R, eds. *Small animal cardiovascular medicine*. St. Louis: Mosby; 1998. p. 297–318.
- [68] Serres F, Chetboul V, Tissier R, Sampedrano CC, Gouni V, Nicolle AP, Pouchelon JL: Chordae tendineae rupture in dogs with degenerative mitral valve disease: prevalence,

- survival, and prognostic factors (114 cases, 2001–2006). *J Vet Intern Med.* 2007; **21**: 258–264. doi:10.1111/j.1939-1676.2007.tb02958.x
- [69] Muzzi RA, de Araujo RB, Muzzi LA, Pena JL, Silva EF: Regurgitant jet area by doppler color flow mapping: quantitative assessment of mitral regurgitation severity in dogs. *J Vet Cardiol.* 2003; **5**: 33–38. doi:10.1016/S1760-2734(06)70050-9
- [70] Gouni V, Serres FJ, Pouchelon JL, Tissier R, Lefebvre HP, Nicolle AP, Sampedrano CC, Chetboul V: Quantification of mitral valve regurgitation in dogs with degenerative mitral valve disease by use of the proximal isovelocity surface area method. *J Am Vet Med Assoc.* 2007; **231**: 399–406. doi:10.2460/javma.231.3.399
- [71] Zoghbi WA, Enriquez-Sarano M, Foster E, Grayburn PA, Kraft CD, Levine RA, Nihoyannopoulos P, Otto CM, Quinones MA, Rakowski H, Stewart WJ, Waggoner A, Weissman NJ: Recommendations for evaluation of the severity of native valvular regurgitation with two-dimensional and doppler echocardiography. *J Am Soc Echocardiogr.* 2003; **16**: 777–802. doi:10.1016/S0894-7317(03)00335-3
- [72] Patel AR, Mochizuki Y, Yao J, Pandian NG: Mitral regurgitation: comprehensive assessment by echocardiography. *Echocardiography.* 2000; **17**: 275–283. doi:10.1111/j.1540-8175.2000.tb01138.x
- [73] Tribouilloy C, Shen W, Quere J, Rey J, Choquet D, Dufossé H, Lesbre J: Assessment of severity of mitral regurgitation by measuring regurgitant jet width at its origin with transesophageal Doppler color flow imaging. *Circulation.* 1992; **85**: 1248–1253. doi:10.1161/01.CIR.85.4.1248
- [74] Fehske W, Omran H, Manz M, Köhler J, Hagendorff A, Lüderitz B: Color-coded Doppler: imaging of the vena contracta as a basis of quantification of pure mitral regurgitation. *Am J Cardiol.* 1994; **73**: 268–274. doi:10.1016/0002-9149(94)90232-1
- [75] Little SH, Igo SR, Pirat B, McCulloch M, Hartley CJ, Nosé Y, Zoghbi WA: In vitro validation of real-time three-dimensional color Doppler echocardiography for direct measurement of proximal isovelocity surface area in mitral regurgitation. *Am J Cardiol.* 2007; **99**: 1440–1447. doi:10.1016/j.amjcard.2006.12.079
- [76] Kittleson MD, Brown WA: Regurgitant fraction measured by using the proximal isovelocity surface area method in dogs with chronic myxomatous mitral valve disease. *J Vet Intern Med.* 2003; **17**: 84–88. doi:10.1892/0891-6640(2003)017<0084:RFMBUT>2.3.CO;2
- [77] Peddle GD, Buchanan JW: Acquired atrial septal defects secondary to rupture of the atrial septum in dogs with degenerative mitral valve disease. *J Vet Cardiol.* 2010; **12**: 129–134. doi:10.1016/j.jvc.2010.03.002
- [78] Buchanan JW, Kelly AM: Endocardial splitting of the left atrium in the dog with hemorrhage and hemopericardium. *J AM Vet Rad Soc.* 1964; **5**: 28–39. doi:10.1111/j.1740-8261.1964.tb01302.x

- [79] Sadanaga KK, MacDonald MJ, Buchanan JW: Echocardiography and surgery in a dog with left atrial rupture and hemopericardium. *J Vet Intern Med.* 1990; **4**: 216–221. doi:10.1111/j.1939-1676.1990.tb00900.x
- [80] Katayama K, Tajimi T, Guth BD, Matsuzaki M, Lee JD, Seitelberger R, Peterson KL: Early diastolic filling dynamics during experimental mitral regurgitation in the conscious dog. *Circulation.* 1988; **78**: 390–400. doi:10.1161/01.CIR.78.2.390
- [81] O’Gara P, Sugeng L, Lang R, Sarano M, Hung J, Raman S, Fischer G, Carabello B, Adams D, Vannan M: The role of imaging in chronic degenerative mitral regurgitation. *JACC Cardiovasc Imaging.* 2008; **1**: 221–237. doi:10.1016/j.jcmg.2008.01.011
- [82] Richard D, William P. Thomas. Echocardiography. In: Nyland TG, Mattoon JS, editors. *Small animal diagnostic ultrasound*, 2nd ed. Philadelphia: WB Saunders; 2002. p. 370.
- [83] Kittleson MD, Eyster GE, Knowlen GG, Bari Olivier N, Anderson LK: Myocardial function in small dogs with chronic mitral regurgitation and severe congestive heart failure. *J Am Vet Med Assoc.* 1984; **184**: 455–459.
- [84] Chetboul V, Tissier R: Echocardiographic assessment of canine degenerative mitral valve disease. *J Vet Cardiol.* 2012; **14**: 127–148. doi:10.1016/j.jvc.2011.11.005
- [85] Chetboul V, Carlos Sampedrano C, Gouni V, Nicolle AP, Pouchelon JL, Tissier R: Ultrasonographic assessment of regional radial and longitudinal systolic function in healthy awake dogs. *J Vet Intern Med.* 2006; **20**: 885–893. doi:10.1111/j.1939-1676.2006.tb01802.x
- [86] Chetboul V: Advanced techniques in echocardiography in small animals. *Vet Clin North Am Small Anim Pract.* 2010; **40**: 529–543. doi:10.1016/j.cvsm.2010.03.007
- [87] Artis NJ, Oxborough DL, Williams G, Pepper CB, Tan LB: Two-dimensional strain imaging: a new echocardiographic advance with research and clinic applications. *Int J Cardiol.* 2008; **123**: 240–248. doi:10.1016/j.ijcard.2007.02.046
- [88] Nagueh SF, Middleton KJ, Kopelen HA, Zoghbi WA, Quiñones MA: Doppler tissue imaging: a noninvasive technique for evaluation of left ventricular relaxation and estimation of filling pressures. *J Am Coll Cardiol.* 1997; **30**: 1527–1533. doi:10.1016/S0735-1097(97)00344-6
- [89] Ommen SR, Nishimura RA, Appleton CP, Miller FA, Oh JK, Redfield MM, Tajik AJ: Clinical utility of Doppler echocardiography and tissue Doppler imaging in the estimation of left ventricular filling pressures: a comparative simultaneous Doppler-catheterization study. *Circulation.* 2000; **102**: 1788–1794. doi:10.1161/01.CIR.102.15.1788
- [90] Federman M, Hess O: Differentiation between systolic and diastolic dysfunction. *Eur Heart J.* 1994; **15**(Suppl D): 2–6. doi:10.1093/eurheartj/15.suppl_D.2
- [91] DeMaria A, Wisenbaugh T, Smith M, Harrison M, Berk M: Doppler echocardiographic evaluation of diastolic function. *Circulation.* 1991; **84**(Suppl 1): 288–295.

- [92] Abott JA. Acquired valvular disease. In: Larry P, Tilley FWKSJ, Oyama MA, Meg MS, editors. *Manual of canine and feline cardiology*, 4th ed. Philadelphia: WB Saunders; 2008. p. 110–138.
- [93] Strickland KN. Pathophysiology and therapy of heart failure. In: Larry P, Tilley FWKSJ, Oyama MA, Meg MS, editors. *Manual of canine and feline cardiology*, 4th ed. Philadelphia: WB Saunders; 2008. p. 288–314.
- [94] Schober KE, Bonagura JD, Scansen BA, Stern JA, Ponzio NM: Estimation of left ventricular filling pressure by use of doppler echocardiography in healthy anesthetized dogs subjected to acute volume loading. *Am J Vet Res*. 2008; **69**: 1034–1049. doi:10.2460/javma.233.4.617
- [95] Schober KE, Stern JA, DaCunha DN, Pedraza-Toscano AM, Shemanski D, Hamlin RL: Estimation of left ventricular filling pressure by doppler echocardiography in dogs with pacing-induced heart failure. *J Vet Intern Med*. 2008; **22**: 578–585. doi:10.1111/j.1939-1676.2008.0099.x
- [96] Ho D-M. Evaluation of prognostic echocardiographic markers in Dogs with Chronic Mitral Valve Insufficiency [thesis]. Chuncheon: Kangwon National University; 2016.
- [97] BENCH Study Group: The effect of benazepril on survival times and clinical signs of dogs with congestive heart failure: results of a multicenter, prospective, randomized, double-blinded, placebo-controlled, long-term clinical trial. *J Vet Cardiol*. 1999; **1**: 7–18. doi:10.1016/S1760-2734(06)70025-X
- [98] Ettinger SJ, Benitz AM, Ericsson GF, Cifelli S, Jernigan AD, Longhofer SL, Trimboli W, Hanson PD: Effects of enalapril maleate on survival of dogs with naturally acquired heart failure. The long-term investigation of veterinary enalapril (live) study group. *J Am Vet Med Assoc*. 1998; **213**: 1573–1577.
- [99] Häggström J, Boswood A, O'Grady M, Jöns O, Smith S, Swift S, Borgarelli M, Gavaghan B, Kresken JG, Patteson M, Ablad B, Bussadori CM, Glaus T, Kovacević A, Rapp M, Santilli RA, Tidholm A, Eriksson A, Belanger MC, Deinert M, Little CJ, Kvart C, French A, Rønn-Landbo M, Wess G, Eggertsdottir AV, O'Sullivan ML, Schneider M, Lombard CW, Dukes-McEwan J, Willis R, Louvet A, DiFrancia R: Effect of pimobendan or benazepril hydrochloride on survival times in dogs with congestive heart failure caused by naturally occurring myxomatous mitral valve disease: the QUEST study. *J Vet Intern Med*. 2008; **22**: 1124–1135. doi:10.1111/j.1939-1676.2008.0150.x
- [100] Lombard CW, Jons O, Bussadori CM: Clinical efficacy of pimobendan versus benazepril for the treatment of acquired atrioventricular valvular disease in dogs. *J Am Anim Hosp Assoc*. 2006; **42**: 249–261. doi:10.5326/0420249
- [101] Woodfield JA: Controlled clinical evaluation of enalapril in dogs with heart failure: results of the cooperative veterinary enalapril study group the cove study group. *J Vet Intern Med*. 1995; **9**: 243–252. doi:10.1111/j.1939-1676.1995.tb01075.x
- [102] Avalonmed. Mitralseal canine mitral valve replacement technology. 2011. Available from: <http://www.youtube.com/watch?v=SbEBsejEJ1I> [Accessed: 2016-08-24].

- [103] Scientific Animations: Mitral valve repair surgery—cardiac animation. 2011. Available from: http://www.youtube.com/watch?v=t9FpQ_wSVD4 [Accessed: 2016-08-24].
- [104] Atkins CE, Rausch WP, Gardner SY, Defrancesco TC, Keene BW, Levine JF: The effect of amlodipine and the combination of amlodipine and enalapril on the renin-angiotensin-aldosterone system in the dog. *J Vet Pharmacol Ther.* 2007; **30**: 394–400. doi:10.1111/j.1365-2885.2007.00894.x
- [105] Vollmar AC, Fox PR: Long-term outcome of Irish Wolfhound Dogs with preclinical cardiomyopathy, atrial fibrillation, or both treated with Pimobendan, Benazepril Hydrochloride, or Methyldigoxin Monotherapy. *J Vet Intern Med.* 2016; **30**: 553–559. doi:10.1111/jvim.13914
- [106] Park D-S. Evaluation of vital signs and echocardiographic indices in asymptomatic dogs with chronic mitral valvular insufficiency after efficacy of pimobendan and enalapril treatment [thesis]. Chuncheon: Kangwon National University; 2016.
- [107] Ouellet M, Bélanger MC, Difruscia R, Beauchamp G: Effect of pimobendan on echocardiographic values in dogs with asymptomatic mitral valve disease. *J Vet Intern Med.* 2009; **23**: 258–263. doi:10.1111/j.1939-1676.2008.0239.x
- [108] Thadani U, Fung HL, Darke AC, Parker JO: Oral isosorbide dinitrate in the treatment of angina pectoris. Dose-response relationship and duration of action during acute therapy. *Circulation.* 1980; **62**: 491–502. doi:10.1161/01.CIR.62.3.491
- [109] Schroeder JS: Combination therapy with isosorbide dinitrate: current status and the future. *Am Heart J.* 1985; **110**: 284–291. doi:10.1016/0002-8703(85)90503-4
- [110] Aviado DM, Folle LE, Bellet S: Cardiopulmonary effects of glyceryl trinitrate and isosorbide dinitrate. *Cardiologia.* 1968; **52**: 287–303. doi:10.1159/000166129
- [111] Cohn JN, Johnson G, Ziesche S, Cobb F, Francis G, Tristani F, Smith R, Dunkman WB, Loeb H, Wong M, Bhat G, Goldman S, Fletcher RD, Doherty J, Hughes CV, Carson P, Cintron G, Shabetai R, Haakenson C: A comparison of enalapril with hydralazine-isosorbide dinitrate in the treatment of chronic congestive heart failure. *N Engl J Med.* 1991; **325**: 303–310. doi:10.1056/NEJM199108013250502
- [112] McDonald KM, Francis GS, Matthews J, Hunter D, Cohn JN: Long-term oral nitrate therapy prevents chronic ventricular remodeling in the dog. *J Am Coll Cardiol.* 1993; **21**: 514–522. doi:10.1016/0735-1097(93)90697-Y
- [113] Kim J-B, Suh S-I, Hyun C: Evaluation of efficacy of sustained-release form of isosorbide dinitrate in dogs heart failure from chronic mitral valvular insufficiency. *J Vet Clin.* 2016; in press.
- [114] Tashjian RJ, Das KM, Palich WE, Hamlin RL, Yarns DA: Studies on cardiovascular disease in the cat. *Ann NY Acad Sci.* 1965; **127**: 581–605. doi:10.1111/j.1749-6632.1965.tb49425.x
- [115] Thomason JD, Fallaw TK, Calvert C: Pimobendan treatment in dogs with congestive heart failure. *Vet Med.* 2007; **102**: 736–740.

- [116] Gordon SG, Saunders AB, Roland RM, Winter RL, Drourr L, Achen SE, Hariu CD, Fries RC, Boggess MM, Miller MW: Effect of oral administration of pimobendan in cats with heart failure. *J Am Vet Med Assoc.* 2012; **241**: 89–94. doi:10.2460/javma.241.1.89
- [117] Ishiki R, Ishihara T, Izawa H, Nagata K, Hirai M, Yokota M: Acute effects of a single low oral dose of pimobendan on left ventricular systolic and diastolic function in patients with congestive heart failure. *J Cardiovasc Pharmacol.* 2000; **35**: 897–905. doi:10.1097/00005344-200006000-00011
- [118] Bowles D, Fry D: Pimobendan and its use in treating canine congestive heart failure. *Compend Contin Educ Vet.* 2011; **33**: E1.
- [119] Macgregor JM, Rush JE, Laste NJ, Malakoff RL, Cunningham SM, Aronow N, Hall DJ, Williams J, Price LL: Use of pimobendan in 170 cats (2006–2010). *J Vet Cardiol.* 2011; **13**: 251–260. doi:10.1016/j.jvc.2011.08.001
- [120] Asanoi H, Ishizaka S, Kameyama T, Ishise H, Sasayama S: Disparate inotropic and lusitropic responses to pimobendan in conscious dogs with tachycardia-induced heart failure. *J Cardiovasc Pharmacol.* 1994; **23**: 268–274. doi:10.1097/00005344-199411000-00014
- [121] Fuentes VL, Corcoran B, French A, Schober KE, Kleemann R, Justus C: A double-blind, randomized, placebo-controlled study of pimobendan in dogs with dilated cardiomyopathy. *J Vet Intern Med.* 2002; **16**: 255–261. doi:10.1111/j.1939-1676.2002.tb02366.x
- [122] Hanzlicek AS, Gehring R, Kukanich B, Kukanich KS, Borgarelli M, Smee N, Olson EE, Margiocco M: Pharmacokinetics of oral pimobendan in healthy cats. *J Vet Cardiol.* 2012; **14**: 489–496. doi:10.1016/j.jvc.2012.06.002
- [123] Fusellier M, Desfontis JC, Le Roux A, Madec S, Gautier F, Thuleau A, Gogny M: Effect of short-term treatment with meloxicam and pimobendan on the renal function in healthy beagle dogs. *J Vet Pharmacol Ther.* 2008; **31**: 150–155. doi:10.1111/j.1365-2885.2007.00934.x
- [124] Reina-Doreste Y, Stern JA, Keene BW, Tou SP, Atkins CE, DeFrancesco TC, Ames MK, Hodge TE, Meurs KM: Case-control study of the effects of pimobendan on survival time in cats with hypertrophic cardiomyopathy and congestive heart failure. *J Am Vet Med Assoc.* 2014; **245**: 534–539. doi:10.2460/javma.245.5.534
- [125] Hambrook LE, Bennett PF: Effect of pimobendan on the clinical outcome and survival of cats with non-auricular responsive dilated cardiomyopathy. *J Feline Med Surg.* 2012; **14**: 233–239. doi:10.1177/1098612X11429645
- [126] Kanno N, Kuse H, Kawasaki M, Hara A, Kano R, Sasaki Y: Effects of pimobendan for mitral valve regurgitation in dogs. *J Vet Med Sci.* 2007; **69**: 373–377. doi:10.1292/jvms.69.373
- [127] Reinker LN, Lee JA, Hovda LR, Rishniw M: Clinical signs of cardiovascular effects secondary to suspected pimobendan toxicosis in five dogs. *J Am Anim Hosp Assoc.* 2012; **48**: 250–255. doi:10.5326/JAAHA-MS-5775

- [128] Tissier R, Chetboul V, Moraillon R, Nicolle A, Carlos C, Enriquez B, Pouchelon JL: Increased mitral valve regurgitation and myocardial hypertrophy in two dogs with long-term pimobendan therapy. *Cardiovasc Toxicol.* 2005; **5**: 43–51. doi:10.1385/CT:5:1:043
- [129] Nicolle AP, Chetboul V, Allerheiligen T, Pouchelon JL, Gouni V, Tessier-Vetzel D, Sampedrano CC, Lefebvre HP: Azotemia and glomerular filtration rate in dogs with chronic valvular disease. *J Vet Intern Med.* 2007; **21**: 943–949. doi:10.1111/j.1939-1676.2007.tb03047.x
- [130] Braunwald E: Valvular heart disease. In: Braunwald E, editor. *Heart disease*, 5th ed. Philadelphia: Saunders; 1997. p. 1017.
- [131] Kellum HB, Stepien RL: Sildenafil citrate therapy in 22 dogs with pulmonary hypertension. *J Vet Intern Med.* 2007; **21**: 1258–1264. doi:10.1892/07-006.1
- [132] Moreno HJ: Clinical characteristics and outcome of 13 dogs with pulmonary arterial hypertension (ph) treated with sildenafil. *J Vet Intern Med.* 2007; **21**: 1165. doi:10.1892/0891-6640(2007)21[1165:C]2.0.CO;2
- [133] Sisson D, Kvart C, Darke P. Acquired valvular heart disease in dogs and cats. In: Fox P, Sisson D, Moise N, editors. *Textbook of canine and feline cardiology*, 1st ed. Philadelphia: Saunders; 1999. p. 536.
- [134] Bock JS, Gottlieb SS: Cardiorenal syndrome: new perspectives. *Circulation.* 2010; **121**: 2592–2600. doi:10.1161/CIRCULATIONAHA.109.886473
- [135] Watson P: Chronic pancreatitis in dogs. *Top Companion Anim Med.* 2012; **27**: 133–139. doi:10.1053/j.tcam.2012.04.006
- [136] Scopinaro N, Gianetta E, Civalleri D, Bonalumi U, Bachi V: Bilio-pancreatic bypass for obesity: 1. An experimental study in dogs. *Br J Surg.* 1979; **66**: 613–617. doi:10.1002/bjs.1800660905
- [137] Webster CRL: History, clinical signs, and physical findings in hepatobiliary disease. In Ettinger S, Feldman E (eds): *Textbook of veterinary internal medicine*, 7th ed. Philadelphia: W.B. Saunders; 2010: p. 1612–1625.
- [138] Steiner JM. Canine pancreatic disease. In: Ettinger SJ, Feldman EC, editors. *Textbook of veterinary internal medicine*, 7th ed. Philadelphia: W.B. Saunders; 2010. p. 1695–1703.
- [139] Borgarelli M, Häggström J: Canine degenerative myxomatous mitral valve disease: natural history, clinical presentation and therapy. *Vet Clin North Am Small Anim Pract.* 2010; **40**: 651–663. doi:10.1016/j.cvsm.2010.03.008
- [140] Gullo L, Cavicchi L, Tomassetti P, Spagnolo C, Freyrie A, D'Addato M: Effects of ischemia on the human pancreas. *Gastroenterology.* 1996; **111**: 1033–1038. doi:10.1016/S0016-5085(96)70072-0
- [141] Hackert T, Hartwig W, Schneider L, Strobel O, Büchler M, Werner J: Ischemic acute pancreatitis: clinical features, diagnosis, therapy and outcome. *Pancreas.* 2007; **35**: 406. doi:10.1097/01.mpa.0000297712.13843.c3

- [142] Moneva-Jordan A: Dietary considerations for the cardiac patient. *In Practice*. 2012; **38**: 28–29. doi:10.1136/inp.f6018
- [143] Sakorafas GH, Tsiotos GG, Sarr MG: Ischemia/reperfusion-induced pancreatitis. *Dig Surg*. 2000; **17**: 3–14. doi:10.1159/000018793
- [144] Warshaw AL, O'Hara PJ: Susceptibility of the pancreas to ischemic injury in shock. *Ann Surg*. 1978; **188**: 197–201. doi:10.1097/0000658-197808000-00012
- [145] Seo JI, Han SH, Choi R, Han J, Lee L, Hyun C: Cardiopulmonary and anesthetic effects of the combination of butorphanol, midazolam and alfaxalone in Beagle dogs. *Vet Anaesth Analg*. 2015; **42**: 304–308. doi:10.1111/vaa.12223
- [146] Fox PR, Sisson D, Moise NS. International small animal cardiac health council. Appendix A—recommendations for diagnosis of heart disease and treatment of heart failure in small animals. In: Fox PR, Sisson D, Moise NS, editors. *Textbook of canine and feline cardiology*, 2nd ed. Philadelphia: W.B. Saunders; 1999. p. 883–901.
- [147] Pape LA, Price JM, Alpert JS, Ockene IS, Weiner BH: Relation of left atrial size to pulmonary capillary wedge pressure in severe mitral regurgitation. *Cardiology*. 1991; **78**: 297–303. doi:10.1159/000174808
- [148] Hezzell MJ, Boswood A, Moonarmart W, Elliott J: Selected echocardiographic variables change more rapidly in dogs that die from myxomatous mitral valve disease. *J Vet Cardiol*. 2012; **14**: 269–279. doi:10.1016/j.jvc.2012.01.009