

# We are IntechOpen, the world's leading publisher of Open Access books Built by scientists, for scientists

6,900

Open access books available

185,000

International authors and editors

200M

Downloads

Our authors are among the

154

Countries delivered to

TOP 1%

most cited scientists

12.2%

Contributors from top 500 universities



WEB OF SCIENCE™

Selection of our books indexed in the Book Citation Index  
in Web of Science™ Core Collection (BKCI)

Interested in publishing with us?  
Contact [book.department@intechopen.com](mailto:book.department@intechopen.com)

Numbers displayed above are based on latest data collected.  
For more information visit [www.intechopen.com](http://www.intechopen.com)



---

# Head Posture and Upper Cervical Spine Morphology in Patients with Obstructive Sleep Apnea

---

Liselotte Sonnesen

Additional information is available at the end of the chapter

<http://dx.doi.org/10.5772/65436>

---

## Abstract

The main aim of this chapter is to describe the role of upper cervical spine morphology and head and neck posture in the etiology, diagnosis, and treatment in patients with obstructive sleep apnea (OSA). Previously it has been documented that the posture of the head and neck was related to the morphology of the facial profile, dysfunction of the jaws, and obstruction of the upper airway. It has been shown that head posture in relation to the upper cervical spine was extended in OSA patients. New findings have been added concerning the occurrence and pattern of deviations of the upper cervical spine morphology in OSA. Furthermore, associations between upper cervical spine morphology and the morphology of the facial profile, including the cranial base in OSA patients have been reported. In addition, the occurrence of upper cervical spine morphological deviations in OSA patients seems to affect the outcome of the treatment with a mandibular advancement device (MAD). Accordingly, it is suggested that upper cervical spine morphology and posture of the head and neck are important factors in the etiology, diagnosis, and treatment considerations in OSA patients.

**Keywords:** head posture, cervical spine morphology, sleep apnea

---

## 1. Introduction

Obstructive sleep apnea (OSA) is by far the most common sleep-related breathing disorder, affecting 2–4% of the adult population, particularly males aged 60 years and older where the prevalence is 30–60% [1, 2]. OSA is defined as cessation of airflow with persistent respiratory effort, due to repeated anatomical obstruction or partial collapse of the oropharyngeal region,

involving the soft palate, dorsum of the tongue, and the posterior pharyngeal wall [1, 3]. The majority of the patients have symptoms such as loud snoring and excessive daytime sleepiness [4, 5]. Nightly choking or gasping, morning headache, memory loss, decreased concentration, increased irritability, and nocturia are also reported [4, 6]. Thus, OSA has consequences for the quality of life, working ability, and traffic safety as well as comorbidities as hypertension [4–7]. OSA is multifactorial with age, gender, and body mass index (BMI) as predisposing factors [1, 3]. The authors agree that there are craniofacial morphological and postural characteristics in OSA patients such as reduced posterior airway space, abnormally long soft palate, low position of the hyoid bone, and an extended head posture [8, 9]. The primary treatments of OSA are based on physical effects and consist of continuous positive airway pressure (CPAP), mandibular advancement device (MAD), and upper airway surgery [6, 7].

This chapter focuses on the role of head posture and the morphology of the upper cervical spine in the etiology, diagnosis, and treatment in patients with OSA.

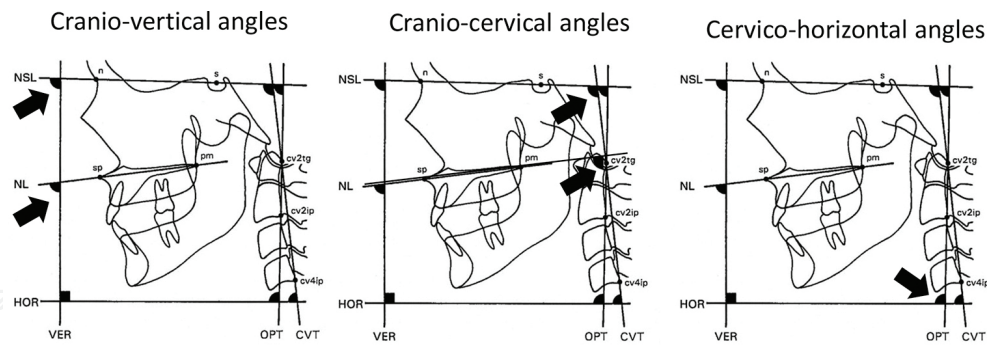
## 2. Head posture in relation to OSA

Associations between head posture and pharyngeal airway dimensions have been documented on lateral cephalograms [9–12]. It was found that an extension of the head in relation to the upper cervical spine resulted in an increase of the anterior-posterior dimension of the pharynx. Furthermore, studies have shown the influence of airway obstruction on head posture [9, 13, 14] where airway obstruction resulted in an extension of the head in relation to the upper cervical spine. Due to the head posture's close associations with the pharyngeal airway, it seems relevant to focus on the relationship between the head posture and OSA.

### 2.1. Definition of head posture

Natural head position is a standardized and reproducible position of the head in an upright position determined by the subjects' own postural control system [14–16]. Accordingly, the posture of the head and neck can be defined in two ways: with or without external reference. The “self-balance position” is without external reference (the subjects' proprioceptive system) and the “mirror position”, with external reference (the subjects' proprioceptive and visual system) [13, 14]. In this chapter, the head posture refers to the OSA patients' “self-balance position” or the “mirror position” evaluated on lateral cephalograms and defined as the following angles [17–19] (**Figure 1**).

1. Posture of the head related to an environmentally determined vertical or horizontal line, that is, the cranio-vertical angles (NSL/VER, NL/VER).
2. Posture of the head related to a line representing the upper spine, that is, the cranio-cervical angles (NSL/OPT, NL/OPT, NSL/CVT, NL/CVT).
3. The upper spine inclination expressed in relation to the environmentally determined true horizontal, that is, the cervico-horizontal angles (OPT/HOR, CVT/HOR).

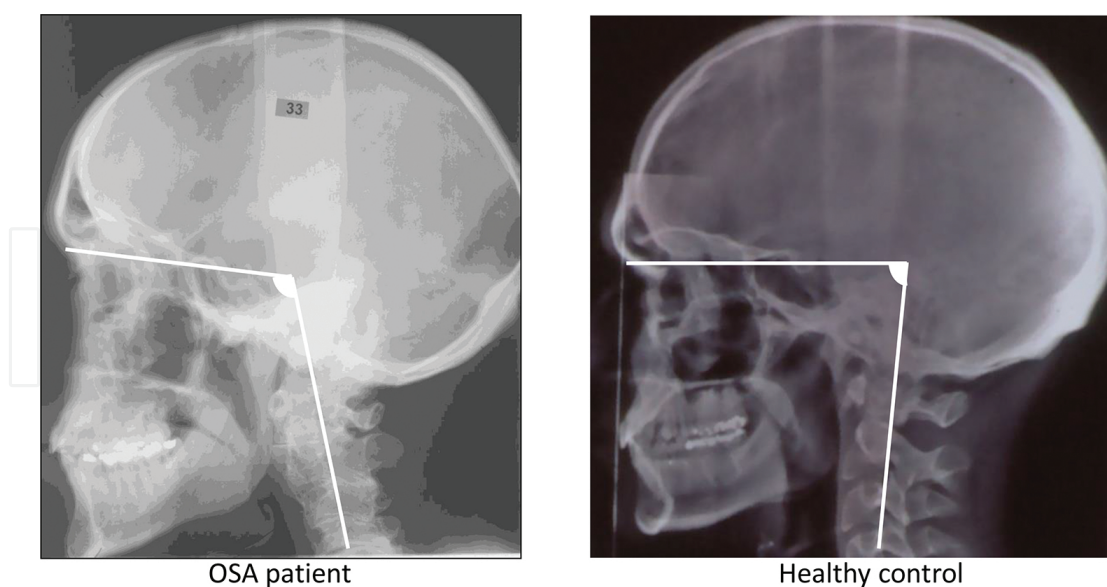


**Figure 1.** Angles describing the head posture.

Extension of the head means a raised position of the head in relation to the upper spine or true vertical, that is, large cranio-cervical angle (NSL/OPT, NL/OPT, NSL/CVT, NL/CVT) and cranio-vertical angle (NSL/VER, NL/VER), respectively. Forward inclination of the upper spine means a small cervico-horizontal angle (OPT/HOR, CVT/HOR).

## 2.2. Head posture in OSA patients

In OSA patients, an extended posture of the head in relation to the upper cervical spine in the upright awake position was found to be associated with larger pharyngeal airway dimensions [9, 20–25]. It was especially the lower part of the pharyngeal airway that was increased in relation to an extended head posture. Furthermore, an extended posture of the head has also been demonstrated in men with OSA compared to healthy controls [9, 24] (**Figure 2**).



**Figure 2.** Extended head posture in an OSA patient compared to a healthy control illustrated on lateral cephalograms.

The severity of OSA was also associated with head posture. The more severe OSA, the more extended and forward head posture was observed [20–23]. The extended head posture in OSA

patients may be a compensatory physiological postural mechanism that serves to maintain airway adequacy in OSA patients [9, 20–25]. It is suggested that airway obstruction via neuromuscular control triggers an increase in the cranio-cervical angle in order to relieve the obstruction by facilitating oral breathing due to enlargement of the naso-and oropharyngeal airway space [9, 13, 24, 26]. The hypothesis is supported by a study in OSA patients showing that the airway resistance significantly influences the head posture [21]. A decreased airway resistance (less obstructive) was seen in OSA patients with an extended head posture. Thus, an extended head posture in the upright awake position was found in OSA patients. The results were considered to reflect a compensatory physiological postural mechanism that serves to maintain airway adequacy in OSA patients in the awake upright posture.

### 3. Upper spine morphology in relation to OSA

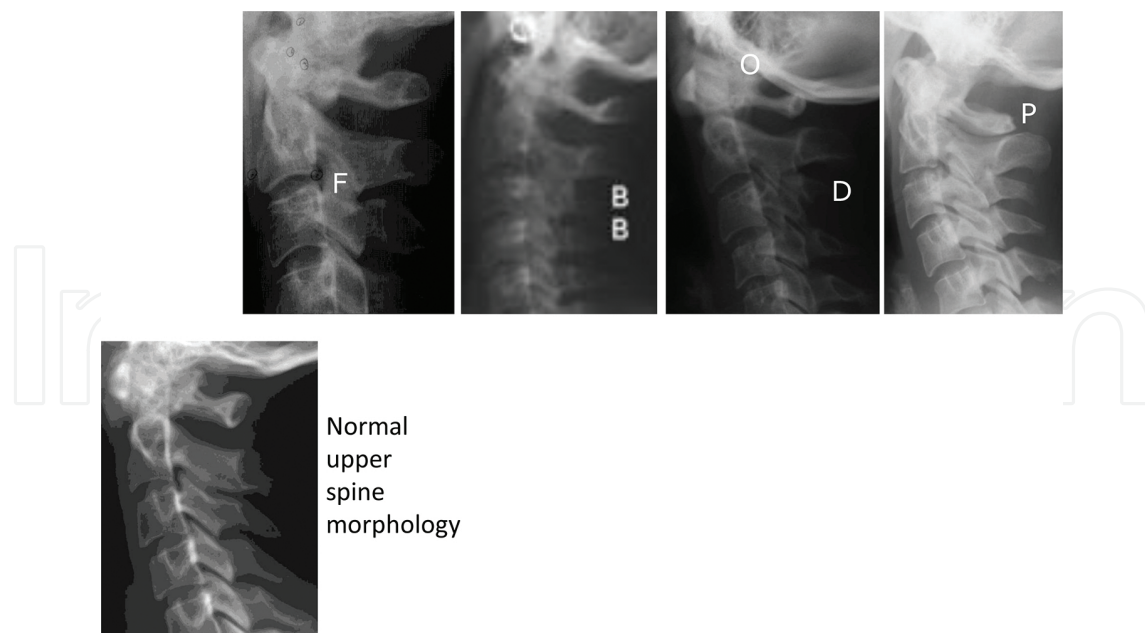
Until recently, deviations of the upper cervical spine have only been described in relation to craniofacial syndromes and cleft lip and palate. Craniosynostosis syndromes, for example, Pfeiffer's, Crouzon's, and Apert's syndromes, showed deviations such as fusion anomalies [27–31]. Furthermore, deviations of the upper cervical spine morphology were seen in Saethre-Chotzen, Klippel-Feil, Turner, Down syndromes, and patients with hypophosphatemic rickets [32–38]. Also, upper spine morphological deviations have been closely investigated in patients with cleft lip and/or palate [39–44]. Recently, upper spine morphological deviations are also found to be associated with severe malocclusion traits and the craniofacial profile [45–49]. In addition, upper spine morphological deviations are associated with head posture [50–52]. As an association between head posture and OSA and between head posture and upper cervical spine morphology is documented, it seems relevant to focus on the relationship between the morphology of the upper cervical spine and OSA.

#### 3.1. Definition of upper spine morphology

The upper cervical spine morphology can be obtained from conventional two-dimensional (2D) lateral cephalograms or from three-dimensional (3D) cone beam computed tomography (CBCT). One method to describe the upper cervical spine morphology on either lateral cephalograms or on CBCT is by visual assessment of the first five cervical vertebral units as referred to in this chapter. The morphological deviations are divided into two categories “Posterior arch deficiency” and “fusion anomalies” [14, 40, 45] (**Figure 3**):

1. Posterior arch deficiency consisted of *partial cleft*: failure of the posterior part of the neural arch to fuse and *dehiscence*: failure of part of a vertebral unit to develop (**Figure 3**).
2. Fusion anomalies consisted of *fusion*: fusion of one unit with another at the articulation facets, neural arch or transverse processes, *block fusion*: fusion of more than two units at the vertebral bodies, articulation facets, neural arch or transverse processes and *occipitalization*: assimilation either partial or complete of the atlas (C1) with the occipital bone (**Figure 3**).

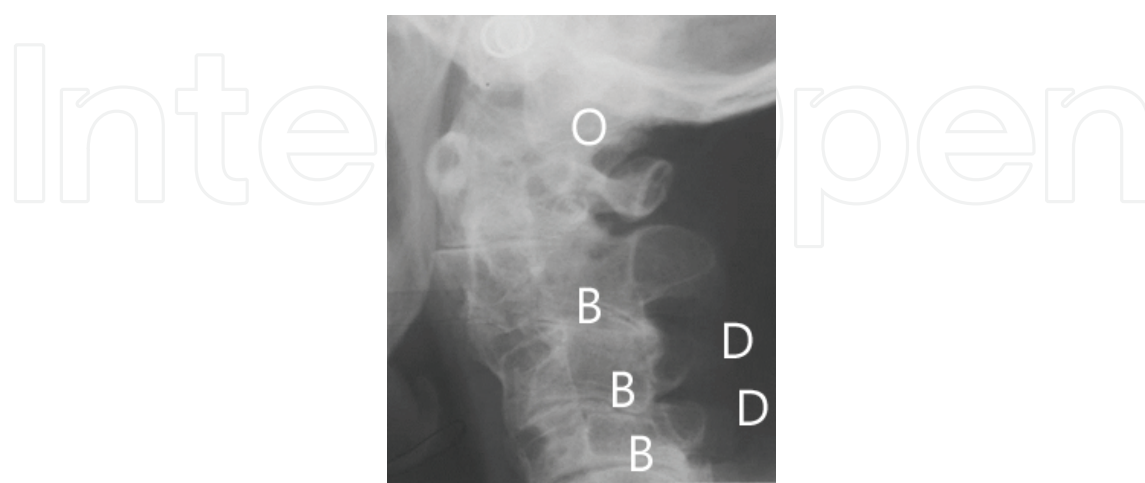




**Figure 3.** Upper spine morphological deviations and normal upper spine morphology illustrated on lateral cephalograms. P: partial cleft, D: dehiscence, F: fusion, B: block fusion, O: occipitalization.

### 3.2. Upper spine morphology in OSA patients

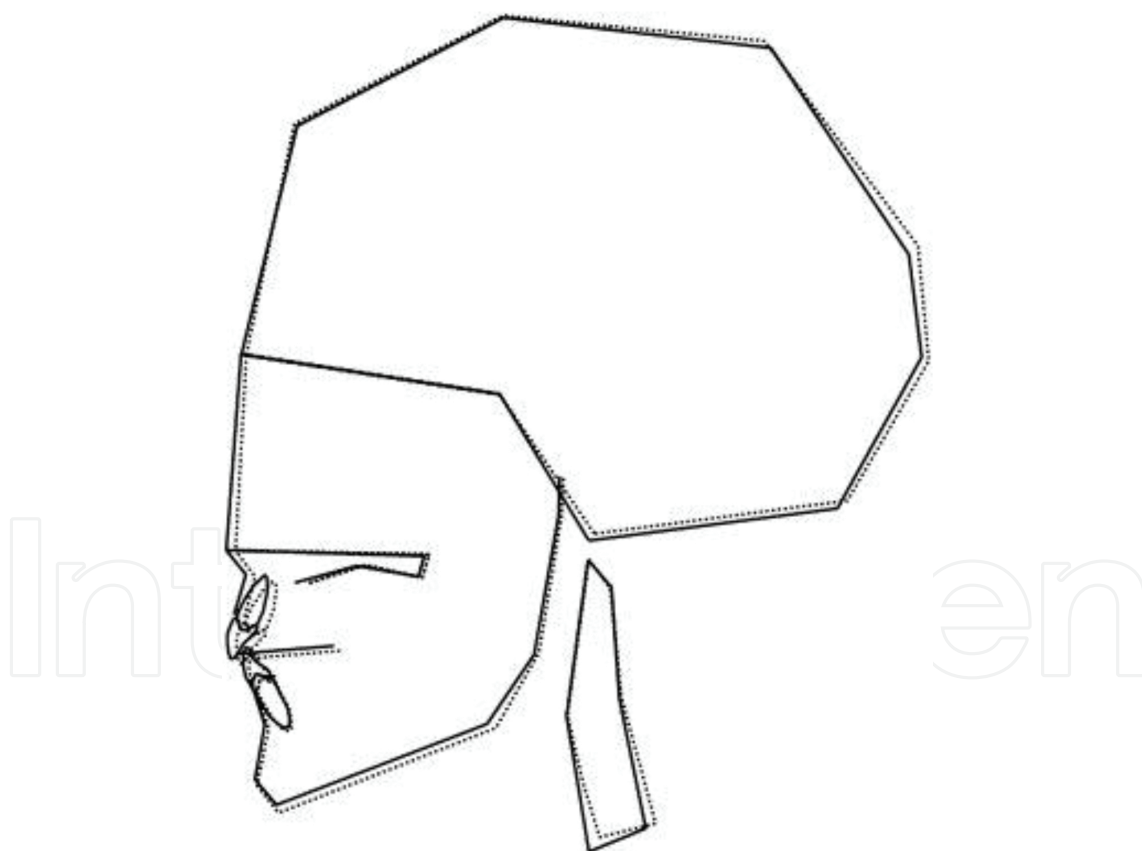
Previous studies have shown that morphological deviations in the upper cervical spine evaluated on 2D lateral cephalograms and 3D CBCT occurred significantly more often in OSA patients compared to healthy controls [53, 54]. The morphological deviations occurred in 32–46% as fusion anomalies: fusions either between the second and third vertebrae, between the third and fourth vertebrae, or between the fourth and fifth cervical vertebrae; block fusions: fusions either between the second, third, or fourth vertebrae, between the second, third, fourth, and fifth vertebrae, or between the third, fourth, and fifth vertebrae; occipitali-



**Figure 4.** Upper spine morphological deviations in patients with OSA illustrated on lateral cephalograms. O: occipitalization, B: block fusion, D: dehiscence.

zation in combination with fusions, block fusions or as a single deviation. Posterior arch deficiency: partial cleft of the first cervical vertebra or dehiscence of the third cervical vertebra and the fourth cervical vertebra [53, 54] (**Figure 4**). The pattern of morphological deviations in the upper spine seen in OSA patients is more severe and occurred more caudally than seen in healthy subjects and in orthodontic patients with severe malocclusion [45–49]. Occipitalization, block fusion, and dehiscence were the phenotypes, which were characteristic of sleep apnea (**Figure 4**).

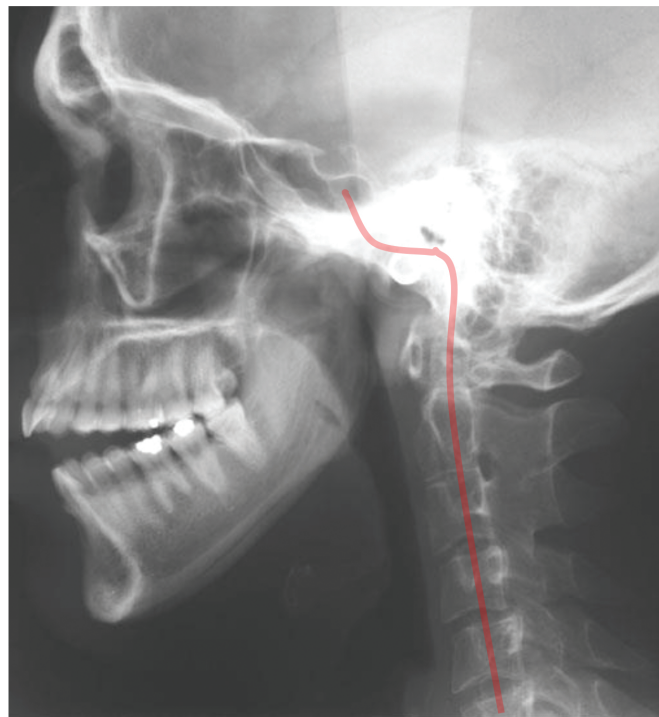It is presumed that the pattern and location of upper cervical spine morphological deviations is connected to different locations of neural crest cell migration along the body axis [55]. Accordingly, it is hypothesized that the level of pharyngeal obstruction in sleep apnea is associated with the caudally/cranially positioned cervical spine deviation. Furthermore, the craniofacial profile of OSA patients with upper spine morphological deviations was significantly different from the craniofacial profile in OSA patients without deviations in the upper spine [56] (**Figure 5**). A long and retrognathic facial profile together with an extended head posture was characteristic of OSA patients with upper spine morphological deviations.



**Figure 5.** Mean diagrams of OSA patient's craniofacial profile with (dotted line) and without (bold line) upper spine morphological deviations.

The background for the interrelationship between the cervical spine and the craniofacial profile can be traced back to early embryological development of these structures [57]. It has been

documented that the development of the body axis is regulated by the notochord [58, 59]. It is also well known that the notochord runs in its full extent from the sacral region to the sella turcica in the posterior part of the cranial base to which the jaws are attached [55]. Different genes act in different segments along the path [60]. A deviation in the development of the notochord may influence the surrounding bone tissue in the spine as well as in the posterior part of the cranial base. On lateral cephalograms and CBCTs, it can be observed that the bone tissues formed around the notochord are the vertebral bodies and the basilar part of the occipital bone (**Figure 6**). The shared origin of the spine and posterior part of the cranial base is the basis for the hypothesis of associations between the spine and the cranial base to which the jaws are attached [60, 61].



**Figure 6.** The red line illustrates the extension of the notochord. Note that the notochord disappears in the early embryogenesis before the ossification of the bone tissue.

The findings indicated that morphological deviations of the upper cervical spine may play a role in the phenotypical subdivision and diagnosis of OSA. In addition, OSA patients with morphological deviations in the upper spine may respond poorer to MAD treatment compared to OSA patients without morphological deviations in the upper spine [62]. This finding further supports the role of upper spine morphological deviations in OSA patients. So far, the complex aetiology of OSA is not fully understood and the explanation for the association between upper spine morphological deviations and OSA is still unknown. Thus, the findings indicated that the aetiology in OSA patients with morphological deviations in the upper spine is characterized by other factors or combinations of different factors than in OSA patients without upper spine morphological deviations and that upper spine morphological deviations therefore may influence the MAD treatment outcome in OSA patient [53, 54, 56, 62].



## 4. Conclusion

When head position and upper cervical spine morphological deviations are evaluated on 2D lateral cephalograms and 3D CBCTs taken in the standardized upright position of the head determined by the subjects' own postural control system, the following is concluded: on average, an extended posture of the head and a significantly larger occurrence of upper spine morphological deviations were seen in patients with OSA. The craniofacial profile of OSA patients with upper cervical spine morphological deviations differed significantly from the craniofacial profile of other OSA patients without morphological deviations in the upper spine. OSA patients with morphological deviations in the upper spine may respond poorer to MAD treatment compared to OSA patients without morphological deviations in the upper spine. The findings indicated that head posture and morphological deviations of the upper cervical spine play a role in the phenotypical subdivision and diagnosis of OSA and thereby for the treatment outcome.

## Author details

Liselotte Sonnesen

Address all correspondence to: [alson@sund.ku.dk](mailto:alson@sund.ku.dk)

Department of Odontology, Faculty of Medical Health and Sciences, Copenhagen University, Copenhagen, Denmark

## References

- [1] Prisant LM, Dillard TA, Blanchard AR. Obstructive sleep apnea syndrome. *J Clin Hypertens (Greenwich)*. 2006;8:746–750.
- [2] Wolkove N, Elkholy O, Baltzan M, Palayew M. Sleep and aging: 1. Sleep disorders commonly found in older people. *CMAJ*. 2007;176:1299–1304.
- [3] Guilleminault C, Tilkian A, Dement WC. The sleep apnea syndromes. *Annu Rev Med*. 1976;27:465–484.
- [4] Balachandran JS, Patel SR. In the clinic. Obstructive sleep apnea. *Ann Intern Med*. 2014;161:ITC1.
- [5] Ngiam J, Balasubramaniam R, Darendeliler MA, Cheng AT, Waters K, Sullivan CE. Clinical guidelines for oral appliance therapy in the treatment of snoring and obstructive sleep apnea. *Aust Dent J*. 2013;58:408–419.

- [6] Epstein LJ, Kristo D, Strollo Jr. PJ, Friedman N. Clinical guideline for the evaluation, management and long-term care of obstructive sleep apnea in adults. *J Clin Sleep Med*. 2009;5:263–276.
- [7] Jordan AS, McSharry DG, Malhotra A. Adult obstructive sleep apnoea. *Lancet*. 2014;383:736–747.
- [8] Neelapu BC, Kharbanda OP, Sardana HK, Balachandran R, Sardana V, Kapoor P, Gupta A, Vasamsetti S. Craniofacial and upper airway morphology in adult obstructive sleep apnea patients: a systematic review and meta-analysis of cephalometric studies. *Sleep Med Rev*. 2016.DOI: 10.1016/j.smrv.2016.01.007.
- [9] Solow B, Skov S, Ovesen J, Norup PW, Wildschjødtz G. Airway dimensions and head posture in obstructive sleep apnoea. *Eur J Orthod*. 1996;18(6):571–579.
- [10] Anegawa E, Tsuyama H, Kusukawa J. Lateral cephalometric analysis of the pharyngeal airway space affected by headposture. *Int J Oral Maxillofac Surg*. 2008;37:805–809.
- [11] Muto T, Takeda S, Kanazawa M, Yamazaki A, Fujiwara Y, Mizoguchi I. The effect of head posture on the pharyngeal airway space (PAS). *Int J Oral Maxillofac Surg*. 2002;31:579–583.
- [12] Hellsing E. Changes in the pharyngeal airway in relation to extension of the head. *Eur J Orthod*. 1989;11(4):359–365.
- [13] Solow B, Sandham A. Cranio-cervical posture: a factor in the development and function of the dentofacial structures. *Eur J Orthod*. 2002;24(5):447–456.
- [14] Sonnesen L. Head posture and upper spine morphology in relation to the craniofacial profile and orofacial function. In: Curran SA, editor. *Posture: Types, Exercises and Health Effects*. Nova Science Publishers, Inc. USA.; 2014. Chapter 3, p. 43–55.
- [15] Moorrees CF. Natural head position-a revival. *Am J Orthod Dentofacial Orthop*. 1994;105(5):512–513.
- [16] Molhave A. A biostatic investigation. The standing posture of man theoretically and statometrically illustrated. *Acta Orthop Scand*. 1960;29:291–300.
- [17] Solow B, Tallgren A. Natural head position in standing subjects. *Acta Odont Scand*. 1971;29:591–607.
- [18] Solow B, Tallgren A. Craniocervical posture in relation to skeletal and dentoalveolar morphology. *Trans Eur Orthodon Soc*. 1975;231–235.
- [19] Solow B, Tallgren A. Head posture and craniofacial morphology. *Am J Phys Anthropol*. 1976;44:417–435.
- [20] Tong M, Sakakibara H, Xia X, Suetsugu S. Compensatory head posture changes in patients with obstructive sleep apnea. *J Tongji Med Univ*. 2000;20(1):66–69.

- [21] Choi JK, Goldman M, Koyal S, Clark G. Effect of jaw and head position on airway resistance in obstructive sleep apnea. *Sleep Breath*. 2000;4(4):163–168.
- [22] Tangugorn V, Krogstad O, Espeland L, Lyberg T. Obstructive sleep apnea (OSA): a cephalometric analysis of severe and non-severe OSA patients. Part I: multiple comparison of cephalometric variables. *Int J Adult Orthodon Orthognath Surg*. 2000;15(2):139–152.
- [23] Ozbek MM, Miyamoto K, Lowe AA, Fleetham JA. Natural head posture, upper airway morphology and obstructive sleep apnoea severity in adults. *Eur J Orthod*. 1998;20(2):133–143.
- [24] Solow B, Ovesen J, Nielsen PW, Wildschjødtz G, Tallgren A. Head posture in obstructive sleep apnoea. *Eur J Orthod*. 1993;15(2):107–114.
- [25] Tangugorn V, Skatvedt O, Krogstad O, Lyberg T. Obstructive sleep apnoea: a cephalometric study. Part I. Cervico-craniofacial skeletal morphology. *Eur J Orthod*. 1995;17(1):45–56.
- [26] Solow B, Kreiborg S. Soft-tissue stretching: a possible control factor in craniofacial morphogenesis. *Scand J Dent Res*. 1977;85:505–507.
- [27] Hemmer KM, McAlister WH, Marsh JL. Cervical spine anomalies in the craniosynostosis syndromes. *Cleft Palate J*. 1987;24(4):328–333.
- [28] Kreiborg S, Barr Jr M, Cohen Jr MM. Cervical spine in the Apert syndrome. *Am J Med Genet*. 1992; 43(4):704–708.
- [29] Anderson PJ, Hall CM, Evans RD, Jones BM, Harkness W, Hayward RD. The cervical spine in Pfeiffer's syndrome. *J Craniofac Surg*. 1996;7(4):275–279.
- [30] Anderson PJ, Hall C, Evans RD, Jones BM, Harkness WJ, Hayward RD. The cervical spine in Crouzon syndrome. *Spine*. 1997;22(4):402–405.
- [31] Thompson DNP, Slaney SF, Hall CM, Shaw D, Jones BM, Hayward RD. Congenital cervical spinal fusion: a study in Apert syndrome. *Pediatr Neurosurg*. 1996;25(1):22–27.
- [32] Anderson PJ, Hall CM, Evans RD, Hayward RD, Harkness WJ, Jones BM. The cervical spine in Saethre-Chotzen syndrome. *Cleft Palate Craniofac J*. 1997;34(1):79–82.
- [33] Frost M, Huffer WE, Sze CI, Badesch D, Cajade-Law AG, Kleinschmidt-Demasters BK. Cervical spine abnormalities in Down syndrome. *Clin Neuropathol*. 1999;18(5):250–259.
- [34] Trusen A, Beissert M, Collmann H, Darge K. The pattern of skeletal anomalies in the cervical spine, hands and feet in patients with Saethre-Chotzen syndrome and Muenke type mutation. *Pediatr Radiol*. 2003;33(3):168–172.
- [35] Samartzis D, Herman J, Lubicky JP, Shen FH. Classification of congenitally fused cervical patterns in Klippel-Feil patients: epidemiology and role in the development of

cervical spine-related symptoms. *Spine*. 2006;31(21):E798–E804. DOI:10.1097/01.brs.0000239222.36505.46

- [36] Shen FH, Samartzis D, Herman, Lubicky JP. Radiographic assessment of segmental motion at the atlantoaxial junction in the Klippel-Feil patient. *Spine*. 2006; 31(2):171–177.
- [37] Gjørup H, Sonnesen L, Beck-Nielsen SS, Haubek D. Upper spine morphology in hypophosphatemic rickets and healthy controls: a radiographic study. *Eur J Orthod*. 2014;36(2):217–225.
- [38] Michelsen T, Brusgaard P, Sonnesen L. Klippel-Feil: a syndrome in the occipital-cervical spine field and its dentofacial manifestations. *World J Stomatol*. 2015;20(2):81–86.
- [39] Ross RB, Lindsay WK. The cervical vertebrae as a factor in etiology of cleft palate. *Cleft Palate J*. 1965;36:273–281.
- [40] Sandham A. Cervical vertebral anomalies in cleft lip and palate. *Cleft Palate J*. 1986;23(3):206–214.
- [41] Horswell BB. The incidence and relationship of cervical spine anomalies in patients with cleft lip and/or palate. *J Oral Maxillofac Surg*. 1991;49(7):693–697.
- [42] Hoenig JF, Schoener WF. Radiological survey of the cervical spine in cleft lip and palate. *Dentomaxillofac Radiol*. 1992;21(1):36–39.
- [43] Ugar DA, Semb G. The prevalence of anomalies of the upper cervical vertebrae in subjects with cleft lip, cleft palate, or both. *Cleft Palate Craniofac J*. 2001;38(5):498–503.
- [44] Rajion ZA, Townsend GC, Netherway DJ, et al. A three-dimensional computed tomographic analysis of the cervical spine in unoperated infants with cleft lip and palate. *Cleft Palate Craniofac J*. 2006;43(5):513–518.
- [45] Sonnesen L. Associations between the cervical vertebral column and craniofacial morphology. *Int J Dent*. 2010;2010:295728. DOI: 10.1155/2010/295728.
- [46] Sonnesen L, Kjaer I. Cervical column morphology in patients with skeletal Class III malocclusion and mandibular overjet. *Am J Orthod Dentofacial Orthop*. 2007;132(4):427.e7–12. DOI:10.1016/j.ajodo.2007.01.019
- [47] Sonnesenn L, Kjaer I. Cervical vertebral body fusions in patients with skeletal deep bite. *Eur J Orthod*. 2007;29(5):464–470.
- [48] Sonnesen L, Kjaer I. Anomalies of the cervical vertebrae in patients with skeletal Class II malocclusion and horizontal maxillary overjet. *Am J Orthod Dentofacial Orthop*. 2008;133(2):188.e15–20. DOI: 10.1016/j.ajodo.2007.07.018.
- [49] Sonnesen L, Kjaer I. Cervical column morphology in patients with skeletal open bite. *Orthod Craniofac Res*. 2008;11(1):17–23.
- [50] Sonnesen L, Pedersen CE, Kjær I. Cervical column morphology related to head posture, cranial base angle, and condylar malformation. *Eur J Orthod*. 2007;29(4):398–403.

- [51] Arntsen T, Sonnesen L. Cervical vertebral column morphology related to craniofacial morphology and head posture in preorthodontic children with Class II malocclusion and horizontal maxillary overjet. *Am J Orthod Dentofacial Orthop.* 2011;140(1):e1–7.
- [52] Kim P, Sarauw MT, Sonnesen L. Cervical vertebral column morphology and head posture in preorthodontic patients with anterior open bite. *Am J Orthod Dentofacial Orthop.* 2014;145(3):359–366.
- [53] Sonnesen L, Petri N, Kjaer I, Svanholt P. Cervical column morphology in adult patients with obstructive sleep apnoea. *Eur J Orthod.* 2008;30:521–526.
- [54] Sonnesen L, Jensen KE, Petersson AR, Petri N, Berg S, Svanholt P. Cervical vertebral column morphology in patients with obstructive sleep apnoea assessed using lateral cephalograms and cone beam CT. A comparative study. *Dentomaxillofac Radiol.* 2013;42:20130060. DOI: 10.1259/dmfr.20130060 DOI:10.1259%2Fdmfr.20130060 #pmc\_ext.
- [55] Kjaer I. Neuroosteology. *Crit Rev Oral Biol Med.* 1999;9:224–244.
- [56] Svanholt P, Petri N, Wildschjødtz G, Sonnesen L, Kjaer I. Associations between craniofacial morphology, head posture, and cervical vertebral body fusions in men with sleep apnoea. *Am J Orthod Dentofac Orthop.* 2009;135:702.e1–9.
- [57] Kjaer I. Human prenatal craniofacial development related to brain development under normal and pathological conditions. *Acta Odontol Scand.* 1995;53:135–143.
- [58] Kjaer I, Kjær TW, Græm N. Ossification sequence of occipital bone and vertebrae in human fetuses. *J Craniofac Genet Dev Biol.* 1993;13:83–88.
- [59] Nolting D, Hansen BF, Keeling J, Kjaer I. Prenatal development of the human vertebral corpora in different segments of the spine. *Spine.* 1998;23:2265–2271.
- [60] Sonnesen L, Nolting D, Kjaer KW, Kjaer I. Association between the development of the body axis and the craniofacial skeleton studied by immunohistochemical analyses using collagen II, Pax9, Pax1, and Noggin antibodies. *Spine (Phila Pa 1976).* 2008;33(15):1622–6.
- [61] Sonnesen L, Nolting D, Engel U, Kjaer I. Cervical vertebrae, cranial base, and mandibular retrognathia in human triploid fetuses. *Am J Med Genet A.* 2009;149A(2):177–187.
- [62] Svanholt P, Petri N, Wildschjødtz G, Sonnesen L. Influence of craniofacial and upper spine morphology on mandibular advancement device treatment outcome in patients with obstructive sleep apnoea: a pilot study. *Eur J Orthod.* 2015;37:391–397.