

We are IntechOpen, the world's leading publisher of Open Access books Built by scientists, for scientists

6,900

Open access books available

186,000

International authors and editors

200M

Downloads

Our authors are among the

154

Countries delivered to

TOP 1%

most cited scientists

12.2%

Contributors from top 500 universities



WEB OF SCIENCE™

Selection of our books indexed in the Book Citation Index
in Web of Science™ Core Collection (BKCI)

Interested in publishing with us?
Contact book.department@intechopen.com

Numbers displayed above are based on latest data collected.
For more information visit www.intechopen.com



Cerebrovascular Anatomy, Neuropathology, Clinics of Stroke: Endovascular Treatment, Decompressive Craniectomy

Erion Musabelliu, Masahiro Oomura and Yoko Kato

Additional information is available at the end of the chapter

<http://dx.doi.org/10.5772/64610>

Abstract

Stroke, a disease of millions, and a financial burden for many more is still challenging health sciences, as we greatly increase our efforts to better understand stroke pathogenesis, early diagnose, prevent and treat high risk and major risk factors we still need to update our clinical and surgical skills in treating stroke event and its aftermath. Use of applied anatomical and physiological knowledge should apply the same everywhere, and based on these standard principles we should be able to predict the early course of stroke neuropathology and its potential consequences. Updated new guidelines of recombinant tissue plasminogen activator (r-tPA) indications should help in early intervention when correct diagnosis is promptly made, but as the list of contraindications as well has changed staff neuroscientists should consider all possible medical and or surgical options for treatment. With prompt actions to try to reinstate perfusion we should always try to do so within the first 4 h, and having a maximal additional 2 h in reserve to consider surgical therapeutic options (should the clinic/unit's infrastructure allow it). Treatment modalities, therapeutic/endovascular and or surgical (embolectomy, bypass, decompression) are the alternatives among which we should wisely chose to treat our patients based on the best medical practice not in the skills of the individuals performing each or either procedure. It is of critical importance to know when surgery should be performed, how to calculate craniotomy size, what are the intra-, extra-cranial surgical landmarks and when should we put the bone back in cases of decompression. We should be able to correctly predict at what extent volume and intracranial pressure values will change by the size of decompressive craniectomy and its effect on the patient's prognosis. Clinic is the best indicator for timing of surgical decompression as it is the sole determinant of any other treatment option, and what high risk and major risk factors are present (if any) at the time of diagnosis will predict the clinical outcome of the patient, but not the age (which should not be the limit).

Keywords: Cerebrovascular Anatomy, Neuropathology, Clinics of Stroke, Embolectomy, Vascular Bypass, Decompression Techniques

1. Stroke syndrome, preamble

In this chapter, we try to explain through principles of anatomy, physiology, and hemodynamics of fluids how does it happen and why these are the series of pathological events following a cerebrovascular occlusion. What can we do differently to treat stroke syndrome? The main focus is on the invasive modalities of the treatment of stroke syndrome, specifically endovascular and surgical techniques.

Is it the best possible way to treat stroke syndrome itself by preventing and treating all the disease processes that risk and cause stroke syndrome?

2. Epidemiology, facts, stroke

Some of the facts of stroke syndrome are as follows:

1. Major neurological disease of our times
2. Second leading cause of death worldwide
3. Second largest contributor to hospital care cost among cardiovascular diseases
4. The leading cause of serious long-term disability
5. Its risk varies by race, ethnicity, and age and geography.

According to World Health Organization (WHO), 15 million people suffer stroke worldwide annually, and of these

1. 5 million die, 5 million are permanently disabled;
2. Stroke can and do occur at any age;
3. Hypertension contributes to more than 12.7 million strokes worldwide;
4. Atrial fibrillation is an independent risk factor for stroke, increasing risk by fivefold;
5. Incidence is 1.5/1000/year and rising rapidly with age to 10/1000/year at 75 years;
6. Male/female ratio of >1:1 (male>female);
7. Life-threatening complete middle cerebral artery (MCA) infarction—up to 10%, with mortality from malignant infarction—up to 80%;

Early action is important, the chances of survival are greater when treatment begins quickly (within 3 h cutoff), and these patients tend to have less disability 3 months after stroke [1].

3. Brain anatomy, physiology, facts

At any moment in normal conditions (*Monro-Kellie equation*):

$$Volume_{Intracranial\ space} = Vol_{Brain} + Vol_{Blood} + Vol_{CSF} \quad (1)$$

Average human brain of an adult, weight	1300–1400 g [2]
	– Comprising 80% of brain weight
Hemisphere of an adult, weight	400 g
	– 55% of blood supplied by MCA
	– 25% supplied by ACA
	– 15% supplied by PCA
	– 5% supplied by anastomotic branches
Average weight of an adult cerebellum	150 g
Inside skull volume	≈1600 ml
	– 80% made by brain tissue
	– 20%
	– 55% CSF
	– 45% blood
	– <5% (60–80 ml) virtual space between cranial bone, meningeal layers, and brain
Cerebral blood flow (CBF)	750 ml/min (≈20% cardiac output)
	50 ml/100 g/min
Changes in intracranial volume before:	– ≥60 ml
– Clinical signs appear	– ≥80 ml
– Imagery signs appear	
Volume of adult human brain	1200 cm ³
	– 1100 cm ³ female
	– 1200 cm ³ male
Cerebrospinal fluid (CSF) volume, adult	150–270 ml
	– 25 ml, volume of ventricles
CSF production rate	0.2–0.7 ml/min
	600–700 ml/day
Cerebral metabolic rate of O ₂ consumption (CMRO ₂)	3–4 ml/100 g tissue/min

Average human brain of an adult, weight	1300–1400 g [2] <ul style="list-style-type: none">– Comprising 80% of brain weight
Normal intracranial pressure (ICP)	5–15 mmHg <ul style="list-style-type: none">– 1–5 mmHg, infants– 5–10 mmHg, children– 5–15 mmHg, adolescents, adults
Critically raised ICP	≥20 mmHg

Table 1. Brain anatomy, physiology, facts.

$$CBF = \frac{CPP}{CVR} = \frac{MAP - ICP}{CVR}$$

The only parameters in which we have some medical and or surgical control (however, with extreme limitations).	
	Constantly changing variables
CBF, cerebral blood flow	Yes
CPP, cerebral perfusion pressure	Yes
CVR, cerebrovascular resistance	Yes
MAP, mean arterial pressure	No, within a wide normal range
ICP, intracranial pressure	Yes, but has a very narrow range
Main factors influencing cerebral blood flow circulation are as follows:	
<ul style="list-style-type: none">– Systemic blood pressure (BP)– The arterial blood gas levels	
In the range of 60–140 mmHg, systemic BP has minimal effect on the CBF, due to autoregulation (via cerebral blood vessel dilation and contraction). MAP has the widest range of autoregulation.	
↑ in BP ≥ 150 mmHg ⇒ ↑ CBF, ↑ ICP	
↓ in BP ≤ 50 mmHg ⇒ ↓ CBF, and can potentially cause cerebral ischemia.	
<i>Hypercapnic vasodilation:</i>	
PaCO ₂ , the most important regulator.	
Control—central chemoreceptors, medulla, brain stem.	
Except in patients with medullary damage, or long-standing COPD (chronic obstructive pulmonary disease), when PaO ₂ levels become a significant contributor to the respiratory drive.	
<i>Hypoxic vasodilation:</i>	
PaO ₂ has a less profound effect, only when	
PaO ₂ ↓ ≤ 50 mmHg ⇒ ↑cerebral perfusion.	
Control—peripheral chemoreceptors, carotid and aortic bodies.	

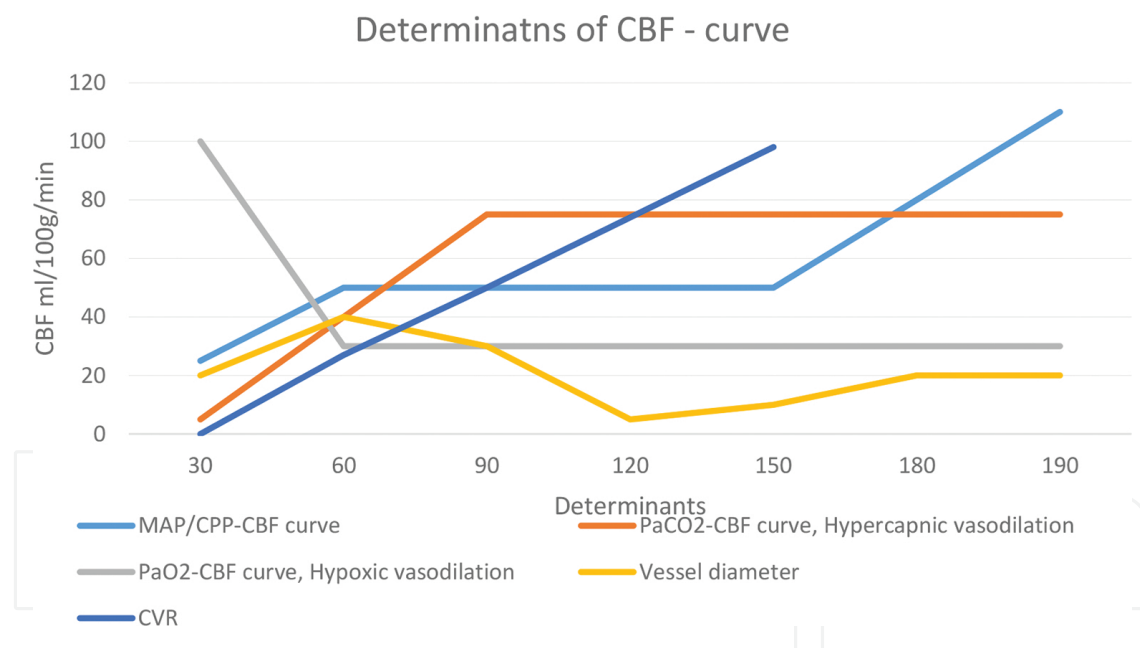
Table 2. Determinants of cerebral blood flow.

All three variables, components in this equation, are inversely related in normal autoregulation. Changes in the increase of at least one of the variables that are not accompanied with inverse relations of the other variables will results in \uparrow intracranial volume and pressure (\uparrow ICP) eventually.

For these mathematical reasons that any increase in the intracranial volume up to 60 ml can be accommodated first by spinal movements of cerebrospinal fluid (CSF) before clinical (>60 ml \uparrow in volume) and radiological (>80 ml \uparrow in volume) signs of herniation occur (**Table 1**).

In their review, Schaller et al. revoked the classical equation of Kellie-Monro and suggested a more differentiated description for the dynamic of ICP, and its relation to cerebral blood flow (CBF). Several experimental and clinical studies have given evidence that this equation and the consideration of the intracranial volume to be a closed system are not entirely true from the physiological and pathophysiological point of view; even so the understanding of this phenomenon is incomplete [3].

CBF and blood pressure have a direct relation, and the main determinants of CBF are mean arterial pressure (MAP) and cerebrovascular resistance (CVR) (**Table 2**) (**Graphic 1**).



Graphic 1. Determinants of cerebral blood flow, correlation.

The arterial blood gases have a more powerful effect on the CBF. The medullary respiratory center controls the depth and the rate of respiration based on input from

- Chemoreceptors, located at
- Centrally, brain stem;
- Peripherally.

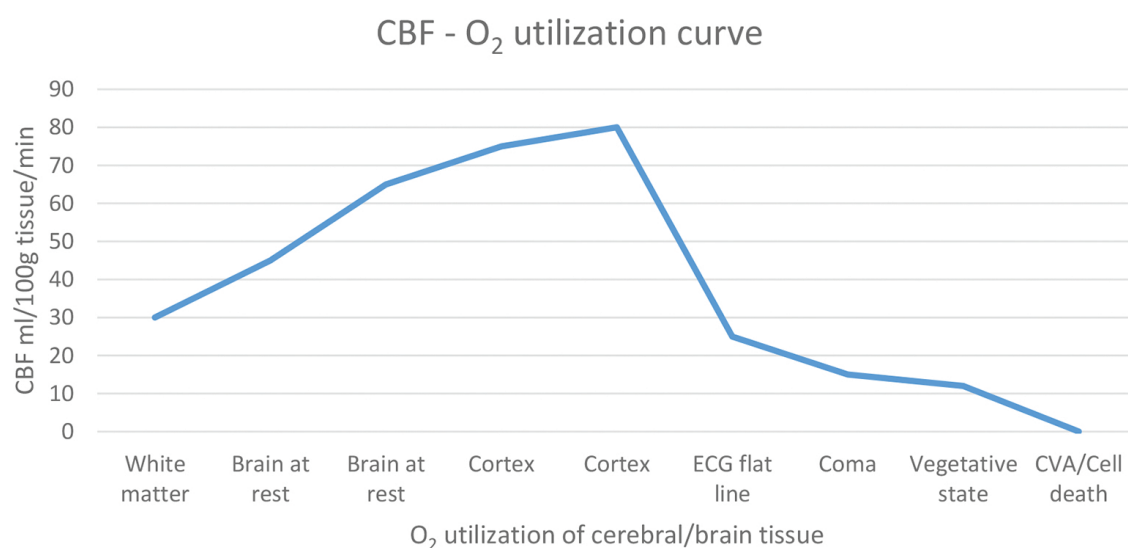
- Airway mechanoreceptors, regulate the duration of inspiration (Hering-Breuer reflex).

Cerebrovascular resistance (CVR) is affected by changes in

- PaCO_2 ;
- CPP (cerebral perfusion pressure).

The ratio, $\frac{\text{CBF}}{\text{CMRO}_2}$, is 14–18 (coupling ratio), when the brain is at the point of lowest O_2 consumption/g tissue.

For every region of cortex activated, the required \uparrow of CBF by $\approx 30\%$ will require a minimum \uparrow of cerebral metabolic rate of oxygen consumption (CMRO_2) by $\approx 5\%$ [4] (**Graphic 2**).



Graphic 2. Cerebral blood flow- O_2 utilization correlation.

Brain-tissue oxygen extraction exceeds that of any other tissue/organ (except for myocardial tissue); therefore, \uparrow in the brain O_2 demand are met by a nearly proportional \uparrow in vascular blood flow.

We can assume that by reducing the metabolic rate of the brain tissue, we may try and reach lower levels of oxygen consumptions during disease processes. The steps that can be taken to manipulate to some degree and reduce the CMRO_2 are by

1. Reducing the electrical activity of neurons (e.g., the use of barbiturates, general anesthesia);
2. Reducing the maintenance energy of neurons (e.g., hypothermia);
 - Deep hypothermia ($\approx 20^\circ\text{C}$) permits the brain to tolerate up to 1 h of circulatory arrest (more data required).

4. Cerebrovascular anatomy

We will use stroke imagery, and demonstrate simultaneously patent and occluded vessel as they mirror in the Circle of Willis, labeling the vessels most often affected (of particular interest for this chapter) in the stroke syndrome (**Figure 1**). A computerized tomography (CT) scan without contrast is the first diagnostic imagery, followed when possible by angio/angio-CT/magnetic resonance imaging (MRI) scan. Angiography has its superiority in stroke syndrome as the diagnostic standard following the CT scan when possible; it can lead the way to endovascular procedures, should the infrastructure of the clinics support it [5, 6]. Successful endovascular treatment of the occluded vessel can save life. **Limitations** in the use of endovascular treatment exist in many clinics; they rely mostly on medical treatment options and surgical bypass and or decompression modalities for their patients.

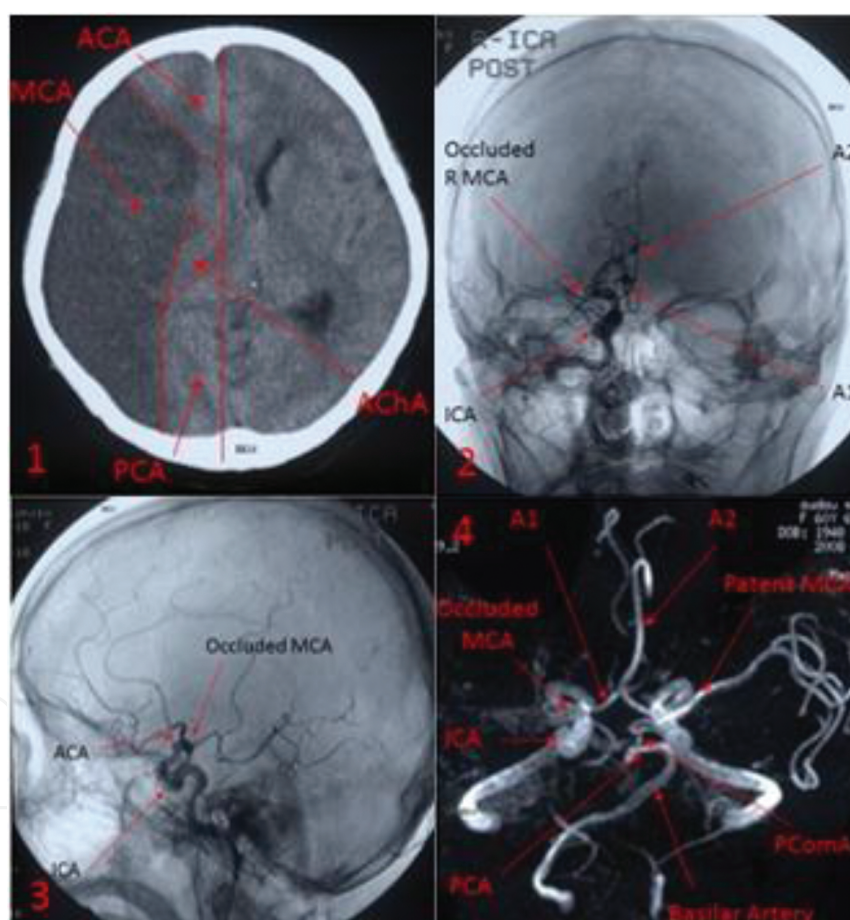


Figure 1. Imagery findings during stroke event, anatomical correlations. 1. A CT scan without contrast, illustrating main hemispheric cerebrovascular territories and ischemic zone under pathological progression in the MCA territory. 2. Anteroposterior view. 3. Lateral view, early diagnostic angiography images, demonstrating patent and occluded vessels. 4. Angio-MRI of Circle of Willis, mirroring the patent and occluded vessel after an acute ischemic accident.

Following internal carotid artery (ICA), MCA is the largest vessel in the anterior circulation. It supplies the largest brain-tissue territory, and it is for this anatomical reason that its occlusion

is “malignant.” Of its two branches (superior and inferior), occlusion of the superior has a devastating clinical course, if not the main MCA, and it supplies almost 60% of the main territory of the MCA main:

- There is considerable variability of the major arteries, and the central distribution [7];
- A balanced configuration of the Circle of Willis is present in only 18% of the population;
- Hypoplasia of one or both posterior communicating (P-comm) occurs in 22–32%;
- Absent or hypoplastic A1 segments occurs in 25%;
- 15–35% of patients supply their posterior cerebral artery on one or both sides from the carotid (via P-comm) instead of via the vertebrobasilar system (*fetal circulation*);
- Large arteries are the primary conduit for blood delivery to the tissues, and contain a large amount of smooth muscle in their walls to regulate blood pressure and withstand high pressure/stress;
- Small arteries and arterioles are the primary site of hormonal regulation of systemic blood pressure and the primary vascular site of vasoactive anti-HTN (hypertension) drugs such as Ca^{2+} channel blockers or alpha-adrenergic blockers.

5. Biophysics of fluids and flow hemodynamics in normal vasculature

Cerebral blood flow is supplied by vessels connected in series and in parallel (**Figure 4**).

For each individual vessel, the law of the conservation of mass applied to the steady state of an incompressible fluid through a system of cylinders of varying cross-sectional areas tells us that

$$\text{Total flow} = \text{flow velocity}(V) \times \text{cross sectional area}(A) = \text{constant} \quad (2)$$

This principle may be applied to blood flow in the cerebrovascular system. The law of conservation of mass as applied to fluid dynamics tells us that the total flow of mass into a contained system (before any vessel is damaged) must be equal to the total outflow of mass from the system steady state (**Figure 3**).

Applying this principle:

$\text{Flow}/Q_{\text{in}} = \text{grams of fluid material in/unit time} = \text{volume in} \times \text{density (in)}/\text{time};$

$\text{Flow}/Q_{\text{out}} = \text{grams of fluid material out/unit time} = \text{volume out} \times \text{density (out)}/\text{time}.$

For a relatively incompressible fluid (e.g., blood), density may be considered constant; therefore, in a steady state,

$\text{Volume in (Vol in)} = \text{Volume out (Vol out)}$

$$\text{Vol in} = A1 \times V1 = \text{Vol out} = A2 \times V2$$

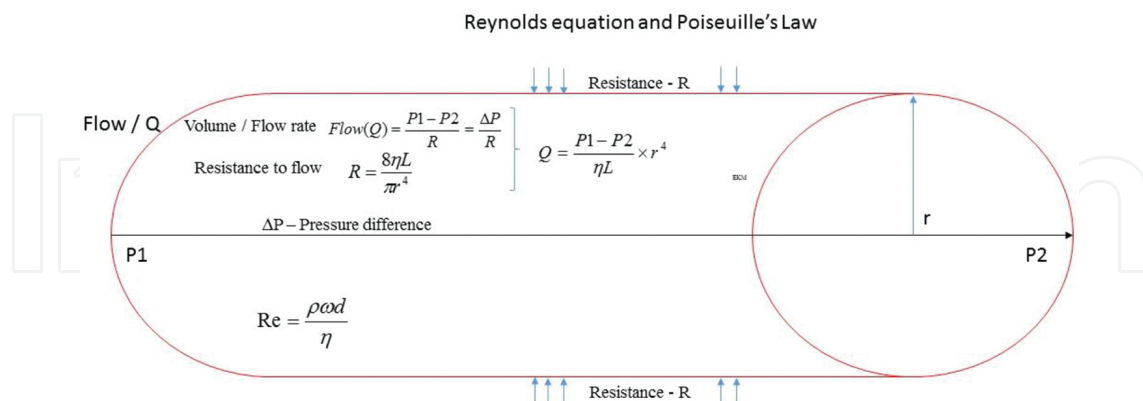


Figure 2. Biophysics of fluids and hemodynamic in normal vasculature.




Figure 3. Relation of section area with flow velocity, in a steady state.

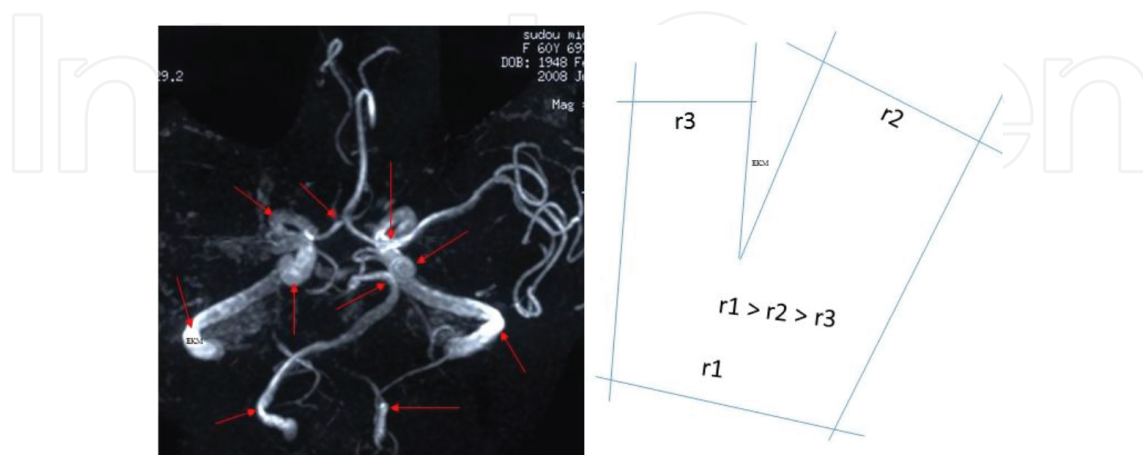


Figure 4. The most common sites of atherosclerotic events in the Circle of Willis. r1 – vessel radius proximal to bifurcation. r2, r3 – vessel radius distal to bifurcation.

In a steady state, the flow at a given point is directly proportional/related to the cross-sectional (A) area at that point (**Figure 2**) (**Table 3**). This explains why immediate distal to bifurcation, wall tension is higher/greater than proximal. This principle of hemodynamics of fluids in cylinders explains the reason of increased frequency of vascular-wall changes (atherosclerosis) at points of narrowing and or curvatures (red arrows), in the Circle of Willis (**Figure 4**). The same principles are used in Doppler echographic measurements.

$Re = \frac{\rho \omega d}{\eta} Q = \frac{P1 - P2}{\eta L} \times r^4$	Constantly changing variables
Re, Reynolds number	No
ρ , density of the liquid	No, it has a very narrow range
ω , flow velocity of the liquid	Yes
d , orifice/vessel diameter	Yes
r , radius of the vessel	Yes
η , viscosity	Yes, but to a narrow range
L , length of the blood vessel	No
ΔP , pressure gradient between two points in the vessel	Yes
R , resistance to flow in the vessel	Yes

A small change in blood vessel radius can have a profound effect on the flow through a vessel; it is based on these simple principles of hemodynamics that we can explain the changes in the flow and pressure when larger vessels bifurcate to smaller ones (**Figures 3 and 4**).

Table 3. Variables in the Reynolds equation and Poiseuille’s law/equation.

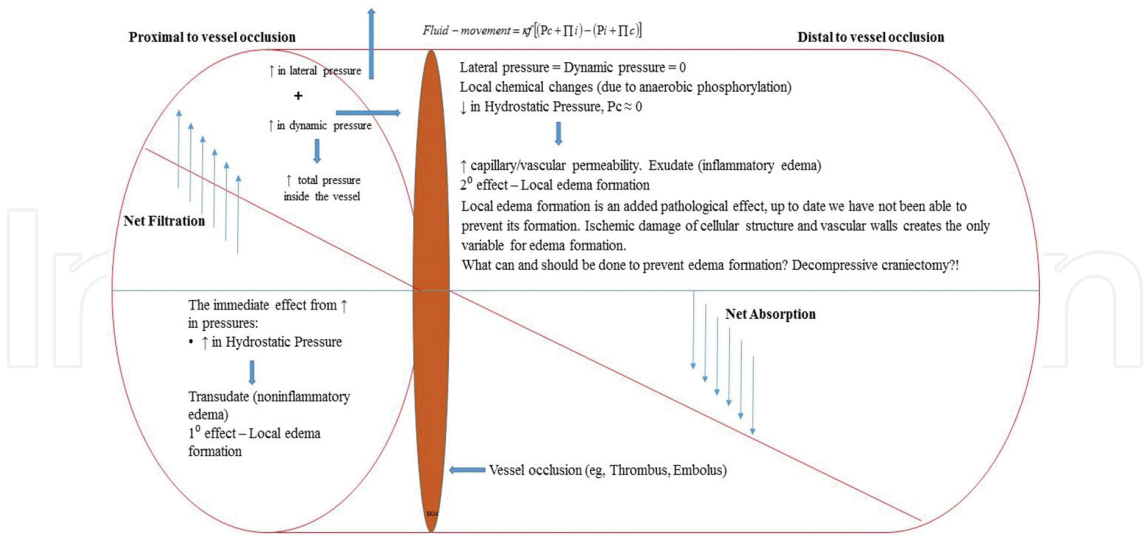


Figure 5. Biophysics of occlusive cerebrovascular disease pathology.

Note: although individual capillaries have a small cross-sectional area, the flow velocity through these vessels is slow. This is because numerous capillaries *arranged in parallel* receive flow from a given feeder vessel; thus, the functional cross-sectional area combined is actually

much larger than that of the feeder vessel from which they receive their flow. Applying this principle, we can explain why:

Blocking of one of the vessels in parallel in this system (e.g., thrombus) \Rightarrow \uparrow pressure and flow in the rest of the system

This is due to the fact that the resistance to flow in a blood vessel is inversely proportional to the radius raised to the fourth power (**Figure 2**).

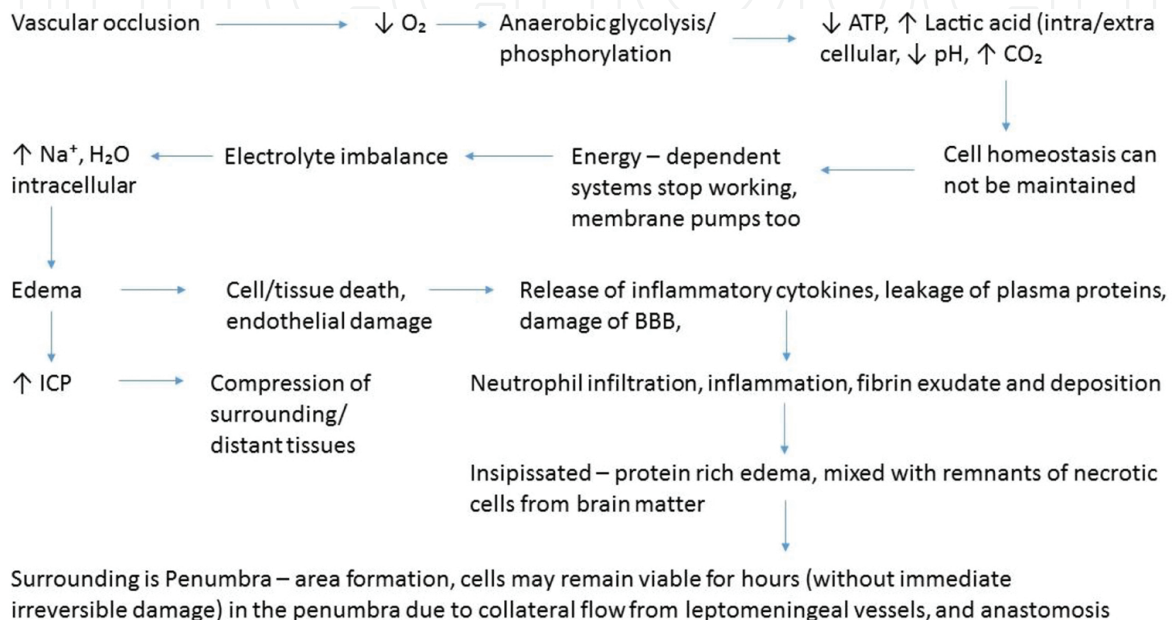


Diagram 1. Stroke-event progression.

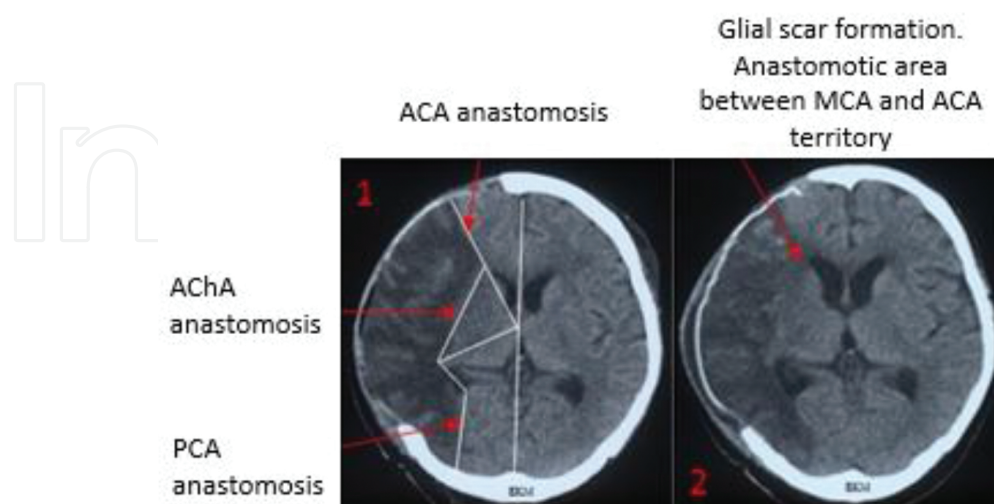


Figure 6. Reactive gliosis and glial scar formation. Cleaning of debris starts from the periphery (where possible anastomoses supply the area with blood and metabolites first, this is the route for neutrophils and macrophages to arrive and signal for more astrocytes stimulation/activation) to the center. 1. Non-contrast CT scan, second week of stroke event.

Reactive gliosis and vascular proliferation around the necrotic area are indicated. 2. Non-contrast CT scan, third week of stroke event.

The cerebral metabolic rate of oxygen consumption arises from neurons utilizing energy for two functions:

- 1. Maintenance of cell integrity, cell homeostasis, which normally accounts for ≈40% of energy consumption;
- 2. Conduction of electrical impulses (neuronal work, ≈ 60%).

Oxidative phosphorylation produces ≈99.99% of energy/adenosine triphosphate (ATP). Anaerobic phosphorylation produces only ≈0.01% of energy required for utilization by neurons. In an event of stroke, it is the 0.01% time-energy during which we depend to try and reverse hypoxia and/or treat stroke and its consequences (**Figure 5**) (**Diagram 1**).

6. Neuropathology of occlusive cerebrovascular disease

- Probably/regardless of proper treatment, the transudate of edema proximal to vascular occlusion tends to resolve (**Figure 5**). But our patient’s progressive clinical and pathological deterioration suggests a less reversible exudation process (**Table 4**).

Time from injury/event	Microscopic changes	Macroscopic changes (Figure 7)
12–24 h	“Red neurons” eosinophilic cytoplasm, pyknotic nuclei, loss of Nissl substance. <i>Sings of irreversible damage, from this moment onward.</i>	First changes appear that can be seen macroscopically as well. At any time, the patient is at risk for extracranial complication and superimposed conditions.
24–72 h	Neutrophils infiltrate the area after the interruption of blood supply; they do not phagocytize myelin remnants.	
3–7 days	Macrophage/microglia infiltration and phagocytosis begin. Neutrophils continue moving into the area, followed by microglia.	
1–2 weeks	Reactive gliosis and vascular proliferation around the necrotic area. Repair is performed by astrocytes that migrate to the area during this time [8].	Liquefactive necrosis (1–4 weeks) (Figure 6)
>2 weeks	Glial scar formation. As necrotic tissue is resorbed, a cystic space forms, which is then surrounded by astrocyte and newly formed capillaries. The enlargement and proliferation of astrocytes peripherally around the area of necrosis forms the glial scar.	Cystic area surrounded by dense glial fibers (>4 weeks) (Figure 6)

Table 4. Stroke phenomenon—event, neuropathological time line.

7. Cerebrovascular Accidents (CVAs)

7.1. Clinical signs

Sudden onset, or a step-wise progression over hours (even days), is typical presentation. In theory, focal signs relate to the distribution of the artery and or arteriole affected, but when collateral supplies have the capacity to supply their territory it will cloud the issue of a pure clinical presentation depending on the vascular territory of the vessel involved as we know its anatomy.

Clinical presentation includes the following:

- 1° signs of vascular territory affected;
- 2° signs due to mass effect from edema formation and or brain herniation, and clinical signs of increased ICP (Cushing syndrome), bradycardia, hypertension, and bradypnea.

7.2. Neurological and/or psychiatric new focal deficits

From all emergencies, abrupt onset of a new focal neurological deficit [9] occurs

- 95% are vascular pathologies:
 - 85% ischemic infarcts;
 - 15% hemorrhagic.
- 5% are nonvascular pathologies:
 - seizure, tumors, psychogenic.

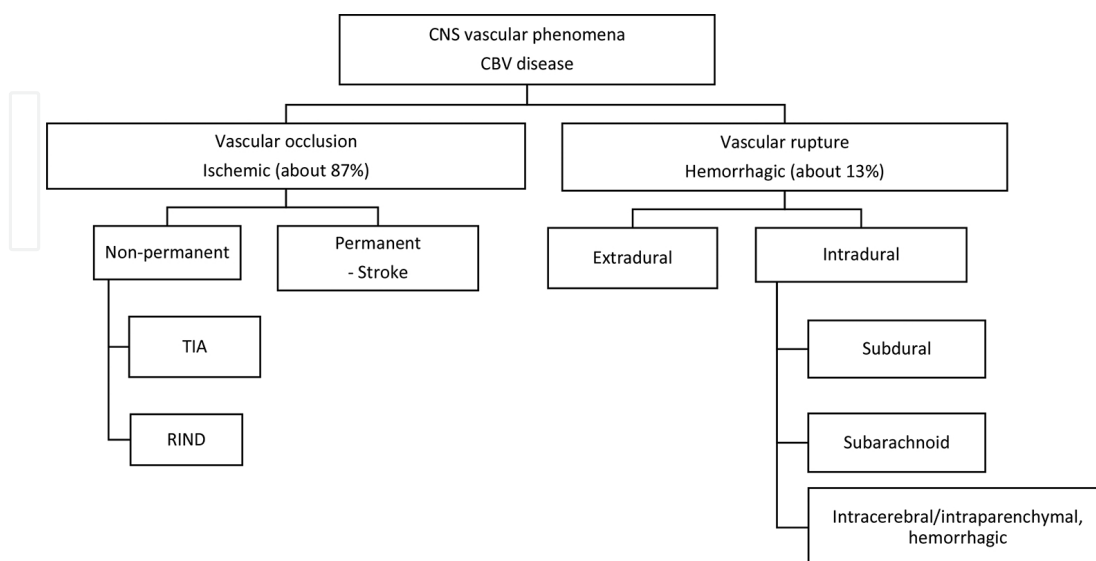


Diagram 2. Cerebrovascular accidents.

7.3. Stroke syndrome

This is caused by inadequate perfusion of a region of CNS. Many causes but same clinic/end results (**Diagram 3**) can occur.

7.4. Occlusive cerebrovascular disease

TIA (transient ischemic attack): a focal neurologic deficit that lasts ≤ 24 h (by definition), but in up to 70% of cases lasts only ≤ 10 min [10] (**Diagram 2**) (**Tables 5** and **6**). Of patients with a deficit persisting >60 min, only 14% will resolve with 24 h [11]. Ninety percent of patients with TIAs will have had reversal within 4 h of onset. An ischemic deficit resolves rapidly.

Infarct types/classification		Major causes of stroke (Diagram 3):	
- Lacunar		- Thrombosis in situ/local	
- Territorial (e.g., MCA, ACA)		- Atherothromboembolism distant/nonlocal	
		- Heart emboli	
- End-zone infarcts		• Atrial fibrillation	
- Border-zone/watershed infarcts		• Infective endocarditis	
		• MI	
- Global cerebral hypoxia/ischemia		- CNS bleed	
		• ↑ in BP	
		• Trauma	
		• Aneurysms/AVMs	
		Arteries with a diameter ≥ of MCA, superior branch of MCA included	Arteries with a diameter < of MCA
The most important risk factors are		Atrial fibrillation	- HTN (associate long-standing HTN with time and severity. Hence the age effect)
			- Diabetes
			- Smoking
Treatment, options		- r-tPA	Therapeutic, preventive.
		- Mechanical thrombectomy	
		- Embolectomy, surgically	
		- Vascular bypass	
		- Decompression	

Table 5. Infarct types, major causes of stroke, and treatment options.

The major clinical types of cerebrovascular diseases:	Vascular distribution:
– Thrombosis (atherothrombotic)-carotid (most common site of origin)	– ≈50% cerebral hemisphere infarcts
– Embolism-MCA (most commonly occluded vessel)	– ≈25% brainstem infarcts
– Hemorrhage	– ≈25% lacunar infarcts

Table 6. Major clinical types of cerebrovascular diseases and vascular distribution.

RIND (reversible ischemic neurologic deficit): a focal deficit lasting ≥ 24 h but less than 1 week. It comprises only 2.5% of patients admitted with TIA, RIND, or CVA [11].

Cerebrovascular accidents: also known as stroke. A permanent (irreversible) neurologic deficit caused by inadequate perfusion of a region of the brain or brain stem.

7.5. Common clinical problems in cerebrovascular disease

- The patient with a history of an ischemic attack or small stroke in the past;
- The patient with atrial fibrillation;
- The patient with a recent stroke that may not be complete;
- The non-evident or misconstrued syndromes of cerebrovascular disease;
- The comatose-stroke patient:
- The most common cause (MCC) of vascular coma is intracranial hemorrhage
 - Usually deep in the hemisphere
 - Less often in the
 - Cerebellum/brainstem
 - Extensive subarachnoid hemorrhage
 - Basilar artery occlusion.
- Seizure following stroke

7.6. “Malignant” middle cerebral artery territory infarction

- Occurs in up to 10% of stroke patients [12];
- Mortality of up to 80% (mostly due to severe postischemic cerebral edema) [13].

7.7. Cerebellar infarction

Relatively rare, seen on up to 1% of all CTs obtained for any reason [14].

7.8. Cardiogenic brain emboli

About one stroke in six is cardioemb [15]

- Fibrin-rich thrombi (mural thrombi);
- Platelets (nonbacterial thrombotic endocarditis);
- Calcified material (aortic stenosis);
- Tumor particles (atrial myxoma).

7.9. Following acute myocardial infarction (MI)

- 2.5% of patients will have a CVA within 1–2 weeks, higher risk with anterior wall MI ($\approx 6\%$) versus inferior wall MI ($\approx 1\%$ risk).

7.10. Atrial fibrillation (A-fib)

Nonrheumatic patients with A-fib have a three- to five fold increased risk of stroke [16]:

- With a 4.5% rate of stroke/year without treatment [17];
- About 75% of CVAs in patients with A-fib are due to left atrial thrombi [18].

Independent risk factors for CVA in patients with A-fib are as follows:

- Advanced age;
- Prior embolism (CVA or TIA);
- HTN;
- Diabetes mellitus (DM);
- Echocardiographic evidence of left atrial enlargement or left ventricular dysfunction.

Prosthetic heart valves: patients with mechanical prosthetic heart valves on long-term anticoagulation have an embolism rate of

- 3%/year for mitral valve, and $\sim 1.5\%$ /year for aortic valve;
- with bioprosthetic heart valves and no anticoagulation, the risk is 2–4%/year.

Paradoxical embolism can occur with a patent foramen ovale, which is present in 10–18% of the general population, but in up to 56% of young adults with unexplained CVA [19]; for this process to occur,

- The defect must be old enough to create a reverse of shunt (Eisenmenger syndrome);
- Or there should be moments where differences in pressure from the right side of the heart are greater than those on the left.

A cerebrovascular event in the setting of a known venous thromboembolic disease is suspicious for paradoxical embolism, and they can occur in patients with

- patent foramen ovale, atrial septal defects, ventricular septal defects;
- large pulmonary arteriovenous malformations (AVMs) [20].

Lacunar strokes: They are small infarcts resulting from the occlusion of penetrating branches. The size of infarcts ranges from 3 to 20 mm. Although their clinic might be devastating, they are the object of prevention and/or medical treatment alone.

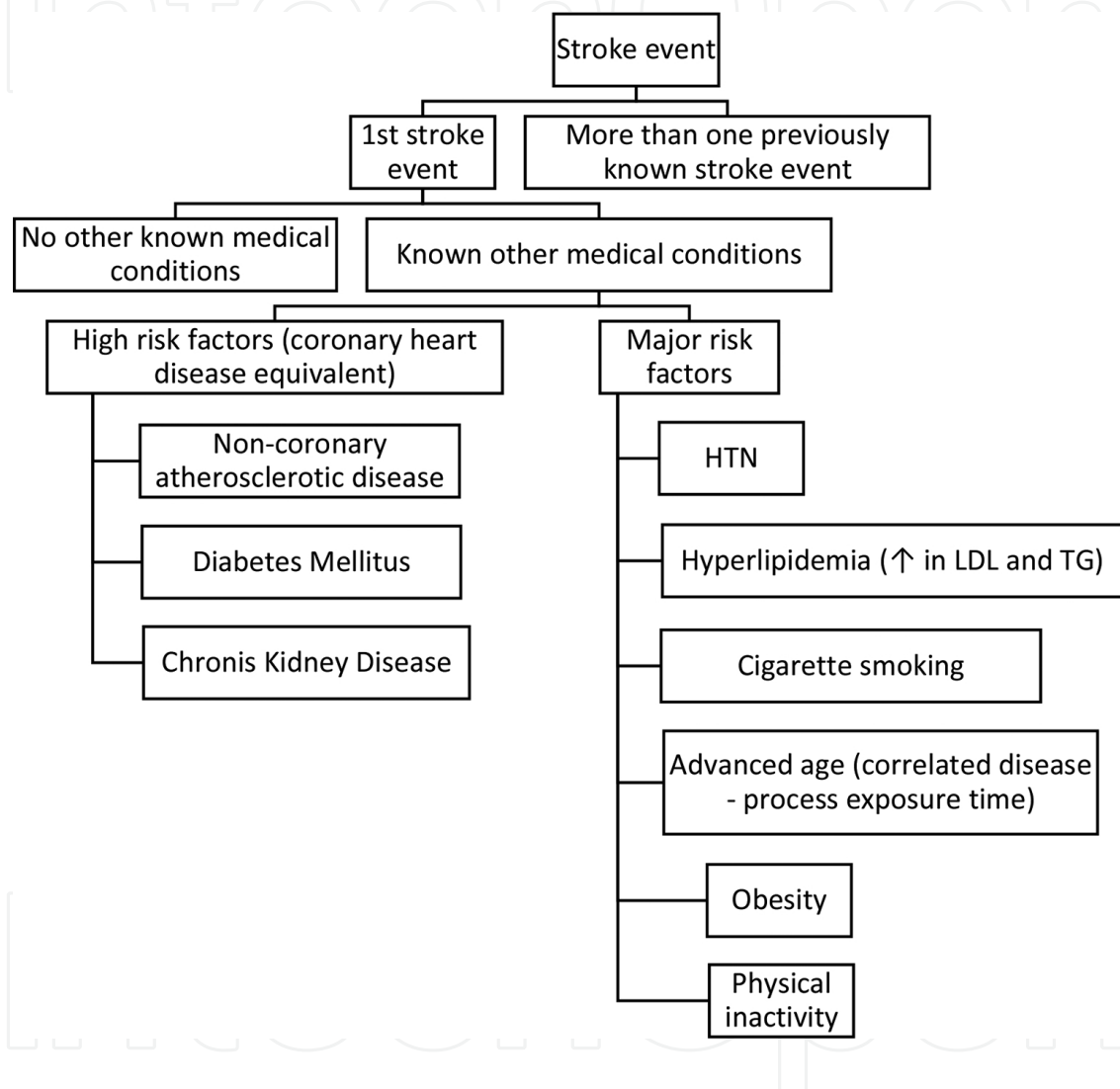


Diagram 3. Stroke event.

8. Diagnosis

Many centers now have strict protocols for the diagnosis and treatment of any stroke event, and such steps should be seriously considered even when a patient presents with minimal clinical signs because the next event might be fatal (**Table 7**).

Steps to the right path:	Prompt investigation to confirm the diagnosis and avoid further stroke events, but consider whether results will affect management. Must Search for
– Epidemiological data	• HTN
– Clinical event	• Cardiac sources of emboli
– Medical history	• Noncardiac sources of emboli
– Medical examination	• Carotid artery stenosis (carotid causes of stroke are the source in >30% of patients affected, they may recur)
– Physical	• Hypoglycemia, hyperglycemia
– Instrumental	• Lipid metabolism disorders
– Blood work	• Vasculitis
– Imagery	• Infectious sources of emboli
– CT scan/angio	• Coagulopathies
– Angio/angio-MRI/MRI	• Hematological diseases (most commonly) <ul style="list-style-type: none"> ◦ Polycythemia vera ◦ Sickle cell disease
– Doppler	◦ Multiple myeloma
– Use NIH Stroke Scale	

Table 7. Diagnosis of stroke and tests used.

8.1. Imaging

1. Emergency imaging of the brain is recommended before initiating any specific treatment for acute stroke [21]. In most instances, nonenhanced CT will provide the necessary information to make decisions about emergency management.
2. If endovascular therapy is contemplated, a noninvasive intracranial vascular study is strongly recommended during the initial imaging evaluation of the acute stroke patient but should not delay intravenous (IV) recombinant tissue plasminogen activator (r-tPA) if indicated. For patients who qualify for intravenous r-tPA according to guidelines from professional medical societies, initiating intravenous r-tPA before noninvasive vascular imaging is recommended for patients who have not had noninvasive vascular imaging as part of their initial imaging assessment for stroke. Noninvasive intracranial vascular imaging should then be obtained as quickly as possible.
3. The benefits of additional imaging beyond CT and CTA or MR and MRA, such as CT perfusion or diffusion- and perfusion-weighted imaging, for selecting patients for endovascular therapy are unknown. Further randomized, controlled trials may be helpful to determine whether advanced-imaging paradigms employing CT perfusion, CTA, and MRI perfusion and diffusion imaging, including measures of infarct core, collateral flow status, and penumbra, are beneficial for selecting patients for acute reperfusion therapy

who are within 6 h of symptom onset and have an ASPECTS (Alberta Stroke Program Early CT score).

8.1.1. CT scan

It is the emergency procedure, and we should always try to perform a non-contrast brain CT scan within 6 h of clinic occurrence, to help us rule out the following (**Figure 7**):

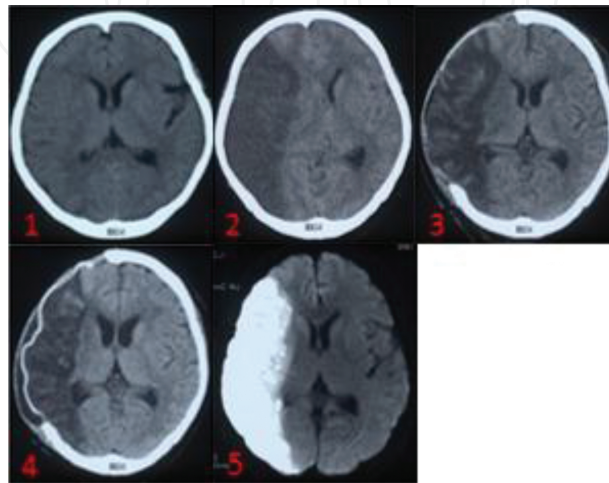


Figure 7. Stroke evolution followed with imagery, CT, and MRI. Non-contrast CT scan images at hour 2 (image 1), day 2 (image 2), week 2 (image 3), and week 3 (image 4) of stroke event. Non-contrast MRI at hour 12 of stroke event (image 5). CT scan findings in ischemic CVAs: *Note: These principles do not apply to small lacunar infarcts, or hemorrhagic CVAs.*

- Hemorrhage (intraparenchymal or SAH);
- Hematoma;
- Lesions (tumors, vascular).

CT scan, indicated in almost all situations of emergency, is strongly suggested in cases when

- Anticoagulation or thrombolytic therapy is indicated (first, we must rule out hemorrhage);
- ICH is suspected;
- Surgical lesions are suspected (vascular, tumoral).

First 12–24-h normal scan can be seen in between 10 and 70% of patients with MCA-CVAs. Early findings of imagery include the following:

1. Hyperdense artery sign (of the vessel involved, indicative of intra-arterial (IA) clot), 12% of patients, within 24 h of CVA, and in 23% of scans done within the first 6 h [22].
2. Focal low attenuation within the gray matter.
3. Mass effect (seen commonly from day 1 to week 4) as
 - a. Effacement of cerebral sulci (often this change is subtle);

- b. Midline shift (maximal effect: end of the first week, with a range between 2 and 5 days).
- 4. Loss of gray-white interface.
- 5. Attenuation/reduction in the strength of the signal of the lentiform nucleus.
- 6. Hypodensity involving the insular region.
- 7. Enhancement, 33% of the patients. CVA becomes isodense (masking effect) or hyperdense with normal brain, which rarely may be the only indication of the infarction.

At 48 h, most of CVAs can be seen as areas of low density.

In 1–2 weeks, we see a sharp demarcation of the CVA area.

In up to 10% of CVAs, there may be a short window, between the first and second weeks where the CVA becomes isodense (called fogging effect). An IV contrast scan and/or an MRI will demonstrate these.

Atrophy is usually seen by the end of the second week to the fifth.

At 3 weeks, the density of the CVA will approach that of the CSF.

Hyperdense artery sign on CT scan: This test has a low sensitivity, but a high specificity when the most common differential diagnosis of carotid dissection, calcified atherosclerosis of vessels (usually bilateral), or high hematocrit has been ruled out first. However, this test does not have independent prognostic significance [23].

8.1.1.1. CT enhancement with IV contrast in CVA:

- Many will enhance by day 6;
- Most will enhance by day 10;
- Some will enhance up to 5 months;
- Enhancement of gyri is common, seen by 1 week usually, predominantly in the gray matter. Differentiate with inflammatory infiltrating lesions due to the breakdown of blood-brain barrier (BBB).
- *Note: there should not be enhancement at the same time as there is mass effect.*

8.1.2. Magnetic resonance imaging

- More sensitive than CT scan, especially between hours 8 and 24, specifically for brain stem and cerebellar CVAs.

MRI enhancement patterns [24]:

1. Intravascular enhancement, 75% of patients, may indicate areas of the brain at risk of infarction.

2. Meningeal enhancement, especially with dural involvement, in 35% of cortical CVAs between days 1 and 3.
3. Transitional enhancement, two types coexist with early evidence of BBB breakdown, usually seen on days 3–6.
4. Parenchymal enhancement classically appears as a cortical/subcortical gyral enhancement. May not be apparent for the first 1–2 days, and gradually approaches 100% by 1 week. Enhancement may eliminate “fogging effect” (as on CT scan), which may obscure some CVAs at about 2 weeks on unenhanced T2WI.

8.1.3. *Emergency cerebral angiography is used in the diagnosis of:*

- Pathologies with early CVA in carotid distribution;
- If diagnosis is still questionable (e.g., aneurysms, vasculitis);
- Pathologies with rapid recovery, suggesting carotid TIA in the face of increasing stenosis.

Note: Avoid angio if the patient is

- Unstable or with severe disabling neurological deficit.

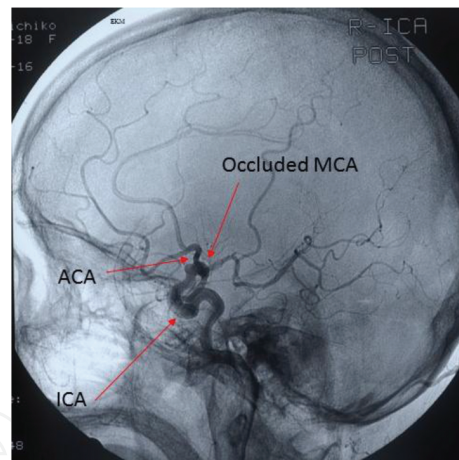


Figure 8. Emergency cerebral angiography. Cutoff sign: vessel ending abruptly at the point of the MCA occlusion.

Findings include the following:

1. Cutoff sign: vessel ends abruptly at the point of obstruction (**Figure 8**).
2. String sign: narrow strand of contrast in a vessel with high-grade stenosis.
3. “**Luxury perfusion**”: reactive hyperemia is a recognized response of cerebral tissue to injury (trauma, infarction, epileptogenic focus/foci). It is blood flow in excess of demand due to the abolition of CBF autoregulation due to acidosis [25]. It shows as accelerated circulation adjacent to the infarct with a stain or blush and early venous drainage.

9. Stroke prevention

As a general principle to prevent primary and or secondary stroke or TIA events, we must identify and control all modifiable risk factors and treat all comorbid diseases (**Table 8**).

Preventing stroke = Risk factor prevention
Preventing and treating:
– Diabetes
– HTN
– Lipid disorders
– Chronic kidney disease
– Atherosclerotic plaque formation
– Smoking

Table 8. How to prevent stroke

Patients with highest/strongest risk factors (coronary heart disease equivalent) (**Diagram 3**) are at the same risk of CV events (e.g., MI, stroke) as patients with known coronary heart disease.

Cardiovascular mortality in patients with type 2 DM increases by two to four times, of which

- 40% of patients die 2° to coronary heart disease;
- Coronary heart disease, not stroke, is the MCC of death.

In patients with type 2 DM,

- 40% die from coronary heart disease;
- 10% die from cerebrovascular accidents;
- 85% from stroke.

It will be of great pharmacological importance to study the chemical structure of thrombi, from autopsy studies. The study of chemical structure of the local-occluding thrombus and the possible site of its release and their comparison as well will help

- determine their nature (chemically) and how we can treat these elements (anticlot-drug development or thrombolytic/clot-lytic strategies);
- make a comparison between the locally found thrombus on the occluded vessel with the location of its release/formation and how different they are and local tissue changes from the site of origin with time.

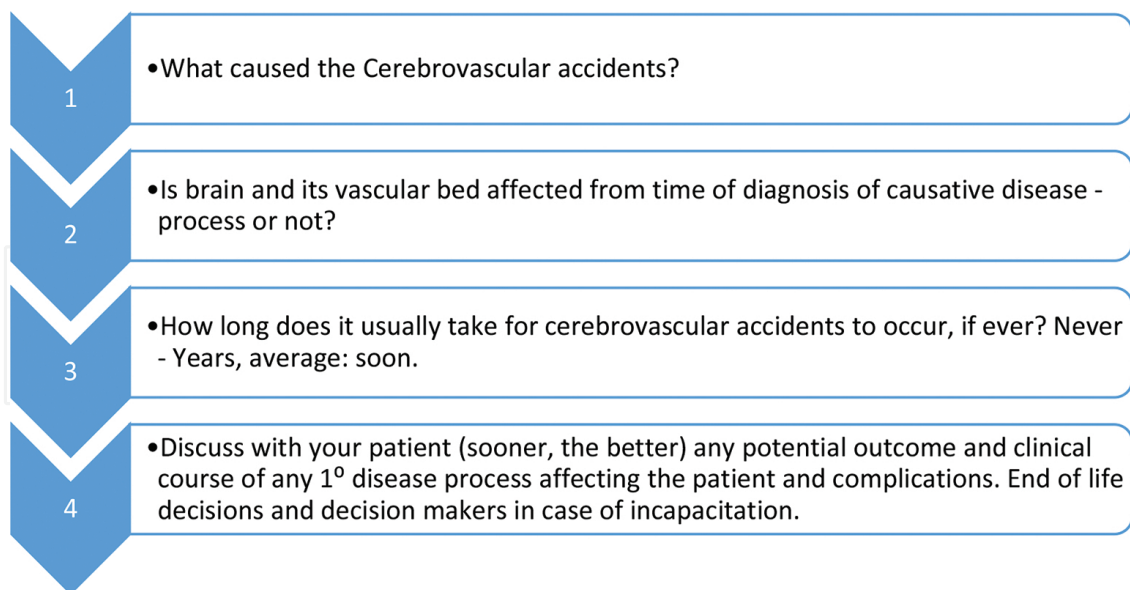


Diagram 4. Questioner of the first clinical encounter with the patient.

In a recent trial involving patients without diabetes who had insulin resistance along with a recent history of ischemic stroke or TIA, the risk of stroke or myocardial infarction was lower among patients who received pioglitazone than among those who received placebo. Pioglitazone was also associated with a lower risk of diabetes but with higher risks of weight gain, edema, and fracture [26]. Every clinic must have a systemic approach in preventive diseases, steps that answer important questions for future preventive measurements (**Diagram 4**).

10. Treatment

Start treatment after the first event and define vascular risks—do not wait for another one, it could be a stroke. Control risk factors for stroke and myocardial infarction, the commonest mode of death after TIA.

Protocols, treatment modalities (**Diagrams 5 and 6**) are designed in their simplicity to be applicable everywhere, although some limitations apply [5, 6]. We have to consider all standards and suggest applications accordingly, in simple steps that can be implemented anywhere. This is what in science we would call “Ideal.”

Treatment of atherothrombotic infarction and TIAs includes the following:

- Preventive measures
- Management of the acute phase
- Measures to restore the circulation and arrest the pathological process
- Thrombolytic agents

- Acute surgical revascularization
- Treatment of cerebral-infarction edema, and raised intracranial pressure
- Anticoagulation drugs
- Antiplatelet drugs
- Other forms of medical treatment
- Surgery and angioplasty for symptomatic carotid stenosis
- Asymptomatic carotid stenosis evaluation
- Physical therapy and rehabilitation.

Of these modalities, surgical and endovascular treatment are technically indicated for stroke events caused by vascular accidents in arteries with diameter as or greater than MCA, of anterior and or posterior circulation. Smaller-size arteries have technical limitations in performing any of these modalities, except for r-tPA and in selected cases of bypass surgery when it can help restore flow in smaller-size arteries that are occluded (should the size allow the technique to be performed).

We know now that thrombus formation can occur in the absence of fibrin/fibrinogen and or vWF (von Willebrand Factor) or both, and either or both are target/s of pharmacological treatments. This might be one of the reasons why drug/medical thrombolysis and or prophylaxis were not successful for all the patients within the same risk group, giving us new trajectories to look in and think of new and better strategies in the medical treatment of stroke [27–31].

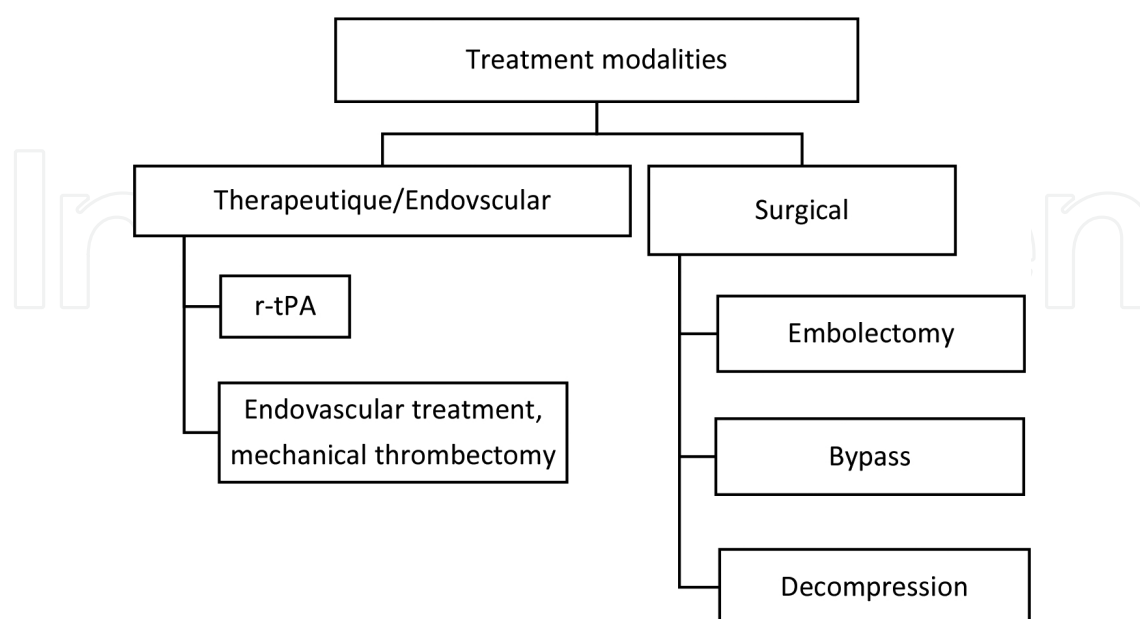


Diagram 5. Treatment modalities of stroke.

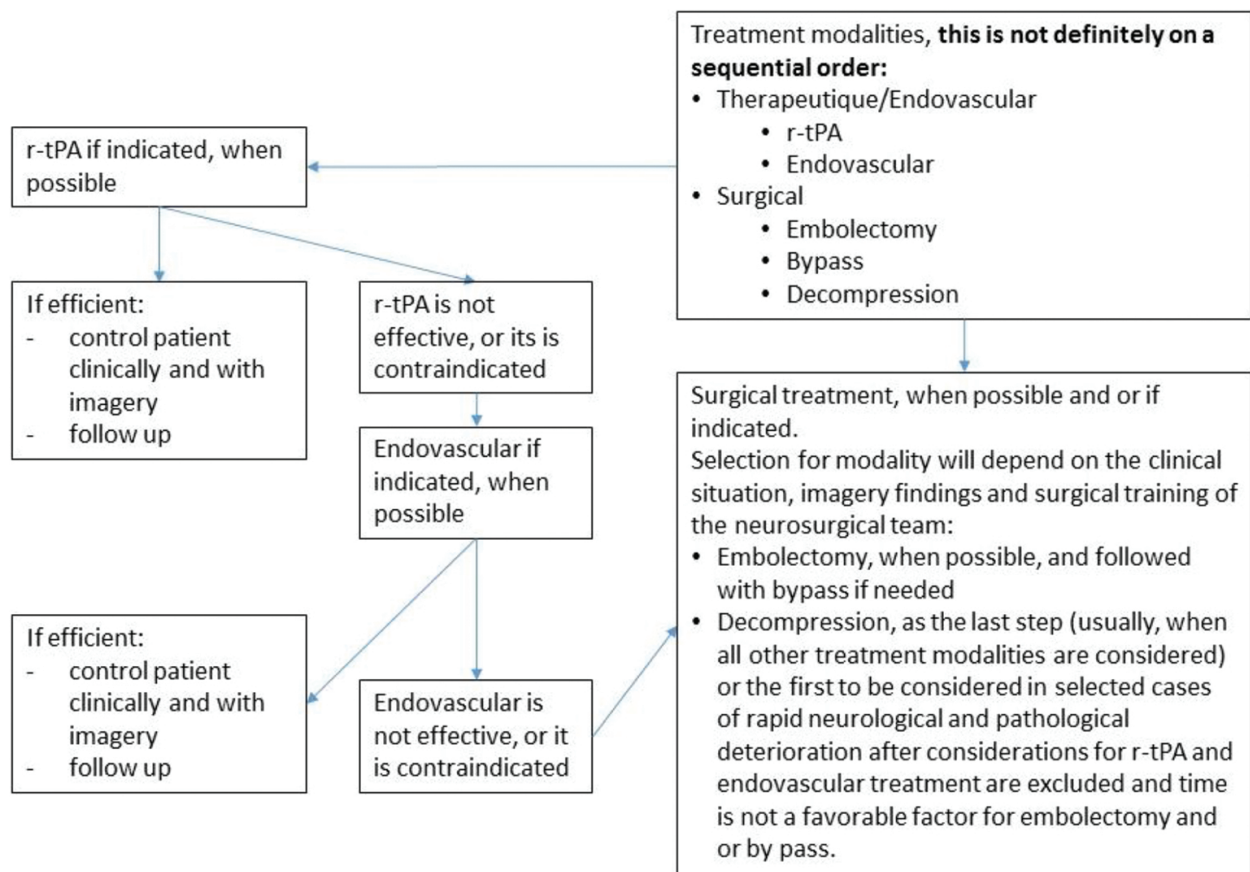


Diagram 6. Treatment modality steps followed during a (stroke) vascular accident.

10.1. Therapeutic/endovascular treatment for acute ischemic stroke – current concepts:

10.1.1. Ischemic penumbra

In 1981, Astrup *et al.* reported a reversible non-functioning brain tissue due to ischemia which is known as “ischemic penumbra” [32]. This ischemic but non-infarcted tissue is potentially salvageable. Without rapid reperfusion, however, the penumbral tissue goes to cell death, that is, infarction. As the purpose of ischemic stroke is to regain the lost neurological deficits, the salvage of penumbral tissue is a goal of acute stroke treatment.

How is penumbra identified?

Penumbral tissue can be inferred by showing both of underperfused brain tissue within a threshold of functional impairment and of infarction (ischemic core) [33]. The hypoperfused brain tissue without infarction can be considered as penumbra [33].

Cerebral blood flow is measurable by a single-photon emission CT (SPECT); however, performing SPECT is quite difficult in an emergent clinical setting. Perfusion CT and/or MRI is rather feasible compared to SPECT, and they can provide perfusion image of the brain. MR diffusion-weighted image (DWI) can visualize cytotoxic edema and are useful to detect

hyperacute ischemic brain tissue. As a rule of thumb, significant underperfused brain tissue with symptoms without showing abnormalities in MR diffusion-weighted image is considered as “ischemic penumbra” [33, 34].

10.1.2. Approval of IV r-tPA

In 1995, the efficacy of intravenous (IV) thrombolysis in patients with acute ischemic stroke (AIS) was first reported (the National Institute of Neurological Disorders and Stroke (NINDS) study) [35] (**Table 9**). In the study, patients with AIS who were treated with IV recombinant tissue plasminogen activator (r-tPA) had a better prognosis compared to those without IV r-tPA [35]. In 1996, the next year, the US Food and Drug Administration approved the intravenous administration of rt-PA in patients with AIS within 3 h after the onset. After that, ECASS III reported an efficacy of IV r-tPA within 4.5 h in 2008 [46]; IV r-tPA is eligible for AIS patients within 4.5 h at the present time.

Indications	Contraindications
<ul style="list-style-type: none"> – Acute ischemic stroke age, 18–85 [21, 38–40] – Onset of symptoms 3–4.5 h before r-tPA administration – Stroke symptoms present for at least 30 min with no significant improvement before treatment – IV r-tPA should not be withheld from patients because of microbleeds seen on MRI [41] 	<p>Absolute:</p> <ul style="list-style-type: none"> – Acute or history of intracranial hemorrhage (intraparenchymal, subarachnoid (even if CT scan was normal), intraventricular hemorrhage, epidural, subdural hematoma, hemorrhagic conversion of infarction) – Severe uncontrolled hypertension (systolic pressure >185 mmHg or diastolic pressure >110 mmHg, or aggressive treatment (IV medication) necessary to reduce blood pressure to these limits) – Serious head trauma or stroke in the previous 3 months – Thrombocytopenia (platelet count <100,000/ml³) and coagulopathy – Current use of anticoagulant with international normalization ratio (INR) >1.7 or partial thromboplastin (PT) >15 s – Administration of heparin within the 48 h preceding the onset of stroke, with an activated partial thromboplastin time at presentation exceeding the upper limit of the normal range – Low-molecular-weight heparin (LMWHs) within 24 h [43] – Oral anticoagulant treatment, direct thrombin inhibitors, and factor Xa inhibitors – Severe hypo- or hyperglycemia (blood glucose <50 mg/dl or >400 mg/dl) – Early radiographic ischemic changes
<p>5. Severe hypertension does not need to preclude treatment with IV r-tPA for patients with acute stroke, provided it can be safely controlled with antihypertensive medications [38, 42, 43]</p>	

Indications	Contraindications
	Relative
	<ul style="list-style-type: none"> – Advanced age (older than 80 years [21, 43]) – Mild or improving stroke symptoms (symptoms rapidly improving or only minor before start of infusion) – Severe stroke as assessed clinically (NIHSS score of >25) or by appropriate imaging techniques, or coma [44, 45] – Major surgery or severe trauma within the previous 3 months [44] – Arterial puncture of noncompressible vessel – Recent gastrointestinal or genitourinary hemorrhage – Seizure at the onset of stroke – Recent myocardial infarction – CNS structural lesions – Time of symptoms onset unknown – Combination of previous stroke and diabetes mellitus – Other major disorders associated within and increased risk of bleeding

Table 9. Indications and contraindications for treatment with r-tPA [36–38].

10.1.3. Drawbacks of IV r-tPA

One of the major drawbacks of IV r-tPA is systemic hemorrhagic complication. The clinicians should be cautious when using IV r-tPA in patients with AIS presenting with laterality in blood pressure of arms. Although it is very occasionally, some patients with acute aortic dissection presents with symptoms of AIS [47]. As the clinical feature of AIS can outweigh those of aortic dissection in an emergent clinical setting, IV r-tPA can be administered before a diagnosis of aortic dissection is established [47]. The number of reported cases is small; however, more than half of AIS associated with aortic dissection are reported to be fatal [47]. As intravenously infused r-tPA will be delivered to anywhere in a body, hemorrhage of any organs can develop. We experienced a case of AIS which developed fatal intraperitoneal hemorrhage following IV r-tPA [48]. The bleeding point was considered to be biopsied liver [48].

10.1.4. Limitation of r-tPA

After IV r-tPA was approved, findings of recanalization rate by occlusion site have been obtained. Recanalization rate just after IV r-tPA varies depending on reports; however, roughly it is reported as 10% in the internal carotid artery, 30% in the middle cerebral artery, M1, and 70% in the middle cerebral artery, M2 [49]. It is really less surprising when we consider a

volume of a thrombus. Assuming that the diameter of the internal carotid artery is 4 mm and those of the distal middle cerebral artery is 2 mm and a thrombus is a sphere, a ratio of the volume of a thrombus lodging to the internal carotid artery to a thrombus lodging to the distal middle cerebral artery becomes 8. However, a dose of IV r-tPA is determined not by a size of thrombus but by a patient's body weight.

To overcome the drawbacks of IV r-tPA, a concept of additional neurointervention for patients who are refractory or not eligible to IV r-tPA has emerged. In 2004, the Interventional Management of Stroke (IMS) study investigators reported the feasibility and safety of a combination therapy (IV r-tPA alone vs. IV r-tPA plus intra-arterial (IA) administration of r-tPA) [50]. IMS-3, a final version of bridging study conducted by IMS study investigators, failed to show any benefits of additional neurointervention following IV r-tPA [51]. However, in 2015, another five randomized controlled trials succeeded in showing the effectiveness of the additional neurointervention [52–56].

10.1.5. Illustrative case

A 75-year-old man suddenly developed right hemiplegia and total aphasia. On examination, his National Institutes of Health Stroke Scale (NIHSS) score was 20. About 4.5 h had already past when he arrived at our hospital, and IV r-tPA was not eligible. Diffusion-weighted MR image showed a moderate ischemic change of the left middle cerebral artery (**Figure 9**); however, it was difficult to explain all of his neurological symptoms by the ischemic change. Neurointervention was performed, and a complete recanalization was obtained by a stent retriever (**Figure 10**). Improvement of his neurological deficits was obtained. The complete recovery of the right hemiplegia was obtained, and he was discharged with mRS2.

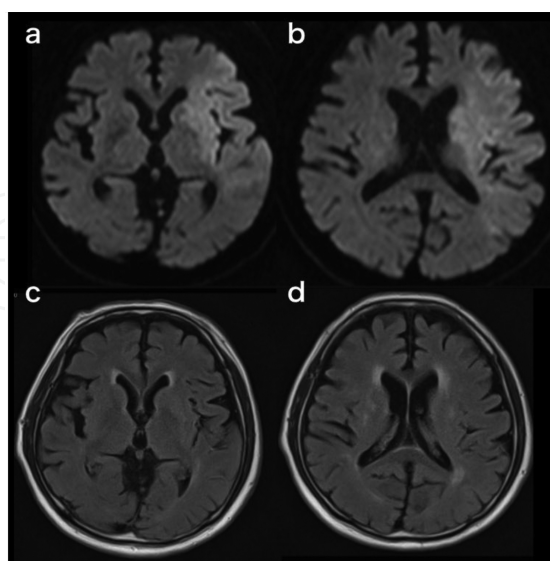


Figure 9. Diffusion-weighted MR image (a, b) and FLAIR image (c, d) on admission. Acute ischemia was noted in the left middle cerebral artery on diffusion-weighted MR image (a, b); however, no lesions were detected on FLAIR image (c, d), suggesting hyperacute ischemia.

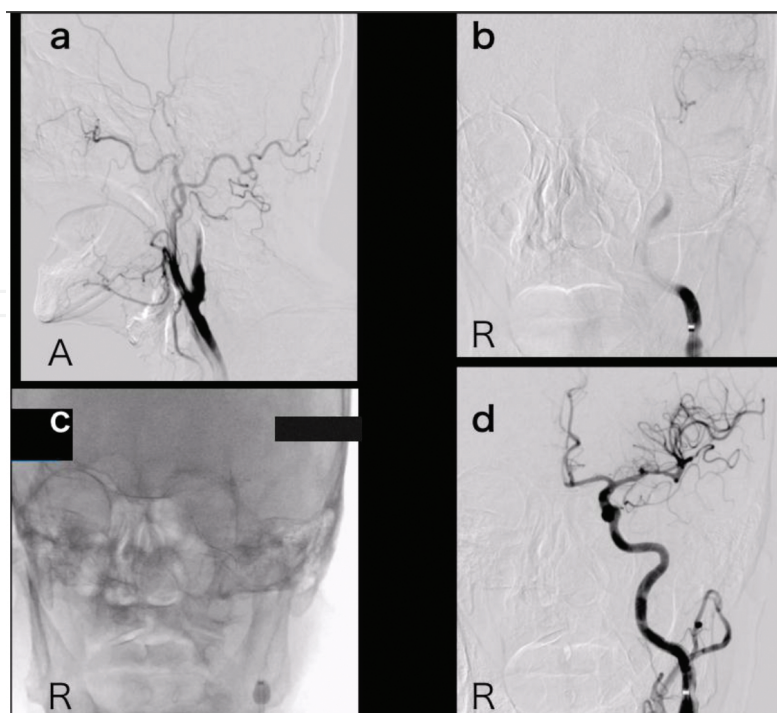


Figure 10. Lateral view of the left carotid angiogram before the neuroendovascular procedure (a). Microcatheter injection confirmed that a tip of the microcatheter was in distal to a thrombus (b). Solitaire FR 6 × 30 mm was deployed, and the Solitaire was pulled with a proximal flow control (c). After one passage of the Solitaire FR, a complete recanalization was obtained (d).

10.1.6. Future issues

Twenty years has been passed since the publication of NINDS study. It is quite evident that r-tPA is effective in patients with AIS within 4.5 h. It is and will be impossible to conduct randomized controlled trial comparing neurointervention and medical management without r-tPA in patients with AIS within 4.5 h. Thus, further issues to be addressed should be the methodology of how to recanalize occluded vessels in conjunction with IV r-tPA. Should we puncture a femoral artery during IV r-tPA? Which devices are most suitable to recanalize? Are there any necessary to choose devices depending on an occlusion site or nature? The next decade will answer these questions, we believe.

A recent trial involving predominantly an Asian patient with acute ischemic stroke did not show the noninferiority of low-dose alteplase to standard-dose alteplase with respect to death and disability at 90 days. There were significantly fewer symptomatic intracerebral hemorrhages with low-dose alteplase [57].

Although the INR and pTT are not adequately reliable indicators of the anticoagulation effect of direct thrombin inhibitors (dabigatran), the thrombin time (TT) is sensitive to the presence of dabigatran activity. Based on the current understanding of pharmacokinetics, IV r-tPA may be considered reasonable in some cases if patients have normal TT, aPTT, and PT, but this should be a subject of future research [38, 58].

10.1.7. The guidelines for the Early Management of Patients with Acute Ischemic Stroke Regarding Endovascular Treatment, Endovascular Interventions:

1. Patients eligible for intravenous r-tPA should receive intravenous r-tPA even if endovascular treatments are being considered (Class I; Level of Evidence A) [21, 59].
2. Patients should receive endovascular therapy with a stent retriever if they meet all the following criteria (Class I; Level of Evidence A):
 - a. prestroke mRS scores 0–1,
 - b. acute ischemic stroke receiving intravenous r-tPA within 4.5 h of onset according to guidelines from professional medical societies,
 - c. causative occlusion of the internal carotid artery or proximal MCA (M1),
 - d. age ≥ 18 years,
 - e. NIHSS score of ≥ 6 ,
 - f. ASPECTS of ≥ 6 , and
 - g. treatment can be initiated (groin puncture) within 6 h of symptom onset.
3. As with intravenous r-tPA, reduced time from symptom onset to reperfusion with endovascular therapies is highly associated with better clinical outcomes. To ensure benefit, reperfusion to TICI grade 2b/3 should be achieved as early as possible and within 6 h of stroke onset (Class I; Level of Evidence B-R).
4. When treatment is initiated beyond 6 h from symptom onset, the effectiveness of endovascular therapy is uncertain for patients with acute ischemic stroke who have causative occlusion of the internal carotid artery or proximal MCA (M1) (Class IIb; Level of Evidence C).
5. In carefully selected patients with anterior circulation occlusion who have contraindications to intravenous r-tPA, endovascular therapy with stent retrievers completed within 6 h of stroke onset is reasonable (Class IIa; Level of Evidence C). There are inadequate data available at this time to determine the clinical efficacy of endovascular therapy with stent retrievers for those patients whose contraindications are time-based or nontime-based (e.g., prior stroke, serious head trauma, hemorrhagic coagulopathy, or receiving anticoagulant medications).
6. Although the benefits are uncertain, the use of endovascular therapy with stent retrievers may be reasonable for carefully selected patients with acute ischemic stroke in whom treatment can be initiated (groin puncture) within 6 h of symptom onset and who have causative occlusion of the M2 or M3 portion of the MCAs, anterior cerebral arteries, vertebral arteries, basilar artery, or posterior cerebral arteries (Class IIb; Level of Evidence C).
7. Endovascular therapy with stent retrievers may be reasonable for some patients <18 years of age with acute ischemic stroke who have demonstrated large vessel occlusion in whom

treatment can be initiated (groin puncture) within 6 h of symptom onset, but the benefits are not established in this age group (Class IIb; Level of Evidence C).

8. Although the benefits are uncertain, the use of endovascular therapy with stent retrievers may be reasonable for patients with acute ischemic stroke in whom treatment can be initiated (groin puncture) within 6 h of symptom onset and who have prestroke mRS score of >1 , ASPECTS.
9. Observing patients after intravenous r-tPA to assess for clinical response before pursuing endovascular therapy is not required to achieve beneficial outcomes and is not recommended (Class III; Level of Evidence B-R).
10. The use of stent retrievers is indicated in preference to the MERCI device (Class I; Level of Evidence A). The use of mechanical thrombectomy devices other than stent retrievers may be reasonable in some circumstances (Class IIb, Level B-NR).
11. The use of proximal balloon-guide catheter or a large bore distal access catheter rather than a cervical guide catheter alone in conjunction with stent retrievers may be beneficial (Class IIa; Level of Evidence C). Future studies should examine which systems provide the highest recanalization rates with the lowest risk for nontarget embolization.
12. The technical goal of the thrombectomy procedure should be a TICI 2b/3 angiographic result to maximize the probability of a good functional clinical outcome (Class I; Level of Evidence A). The use of salvage technical adjuncts including intra-arterial fibrinolysis may be reasonable to achieve these angiographic results, if completed within 6 h of symptom onset (Class IIb; Level of Evidence B-R).
13. Angioplasty and stenting of proximal cervical atherosclerotic stenosis or complete occlusion at the time of thrombectomy may be considered but the usefulness is unknown (Class IIb; Level of Evidence C). Future randomized studies are needed.
14. Initial treatment with intra-arterial fibrinolysis is beneficial for carefully selected patients with major ischemic strokes of <6 -h duration caused by occlusions of the MCA (Class I; Level of Evidence B-R). However, these data derive from clinical trials that no longer reflect current practice, including the use of fibrinolytic drugs that are not available. A clinically beneficial dose of intra-arterial r-tPA is not established, and r-tPA does not have FDA approval for intra-arterial use. As a consequence, endovascular therapy with stent retrievers is recommended over intra-arterial fibrinolysis as first-line therapy (Class I; Level of Evidence E).
15. Intra-arterial fibrinolysis initiated within 6 h of stroke onset in carefully selected patients who have contraindications to the use of intravenous r-tPA might be considered, but the consequences are unknown (Class IIb; Level of Evidence C).
16. It might be reasonable to favor conscious sedation over general anesthesia during endovascular therapy for acute ischemic stroke. However, the ultimate selection of anesthetic technique during endovascular therapy for acute ischemic stroke should be individualized based on patient risk factors, tolerance of the procedure, and other clinical characteristics. Randomized trial data are needed (Class IIb; Level of Evidence C).

General anesthesia with intubation and conscious sedation are the two most frequently used anesthetic approaches for patients with an acute ischemic stroke receiving endovascular therapy.

An expert consensus statement of the Society of Neurointerventional Surgery and the Neurocritical Care Society recommends the use of general anesthesia for patients with severe agitation, low level of consciousness (the Glasgow Coma Scale (GCS) of <8), loss of airway protective reflexes, respiratory compromise, and in selected posterior circulation stroke presenting with these features [60].

10.1.8. Patient selection

- Intracranial vessel occlusion must be diagnosed with noninvasive imaging whenever possible before considering treatment with mechanical thrombectomy (Grade A, Level 1a, KSU Grade A) [59].
- If vessel imaging is not available at baseline, an NIHSS score of ≥ 9 within 3 h, and ≥ 7 points within 6 h may indicate the presence of large vessel occlusion (Grade B, Level 2a, KSU Grade B).
- Patients with radiological signs of large infarcts (e.g., using the ASPECTS score) may be unsuitable for thrombectomy (Grade B, Level 2a, KSU Grade B).
- Imaging techniques for determining infarct and penumbra sizes can be used for patient selection and correlate with functional outcome after mechanical thrombectomy (Grade B, Level 1b, KSU Grade B).
- High age alone is not a reason to withhold mechanical thrombectomy as an adjunctive treatment (Grade A, Level 1a, KSU Grade A).

10.2. Surgical treatment

10.2.1. Embolectomy and extracranial – intracranial (EC/IC) bypass; STA – MCA bypass is this the solution or a treatment – procedure?

Surgical embolectomy in conjunction with ligation of the cervical ICA followed by STA-MCA bypass might be a safe alternative method to endovascular recanalization, when the cervical dissection of ICA is extensive and when huge secondary emboli are present along the MCA when it is clinically indicated and or in centers that do not have a 24-h endovascular service [61]. In these centers, microsurgery is recommended as a first-line treatment, after exclusion of malignant profile based on MRI findings (i.e., minimal DWI lesion less than one-third of the entire MCA region despite large ICA/MCA occlusion on MRA) [5, 6, 62–64]. Spontaneous dissection of the internal carotid artery (ICA) is one of the main causes of ischemic stroke in young- to middle-aged patients. It can cause malignant brain infarction [65], and in addition tandem ICA and MCA occlusion independently predict poor outcomes in response to intravenous r-tPA [66–68]. We know that theoretically stent deployment for cervical ICA

dissection could cause distal migration of secondary emboli, vessel laceration, and in-stent thrombosis [64, 69]. When other criteria are not meet, surgical embolectomy is recommended.

CBF increases significantly after bypass, and flow reservation improves significantly. Patients with TIA experience less or no recurrence of such episodes after bypass and the neurologic deficit remains unchanged in patients with complete stroke after bypass, with a very high satisfaction rate after surgery as assessed by the patients themselves, in comparison to the conservative treatment [70].

10.2.2. Bypass may be indicated and may be helpful in restoring CBF and reducing the risk of stroke in:

- Atherosclerotic plaque non treatable by endovascular or other means;
- Failure of medications to control TIA symptoms or stroke;
- Imagery (angio, CTA, and MRA) showing intra- and or extracranial arterial stenosis/occlusion;
- CBF studies (CT perfusion, positron emission tomography (PET), and SPECT) show insufficient blood flow due to arterial stenosis [5, 64, 68-70]..

Bypass surgery might improve CBF, but it does not cure (with some exceptions) the underlying disease.

Outside	Inside
Frontal sinus, 1-cm superior	Superior sagittal sinus
Sagittal suture, 1-cm lateral	Transverse sinus
Lambda and lambdoid suture 1-cm superior	
Asterion and pterion	
With an extensive craniectomy, we can remove an area of bone≈60 cm ² .	
At this range, the volume calculated to protrude through the opening will be a minimum of 60 ml.	
This technique has a greater decompression effect on frontal, precentral, superior cerebral, and parietal veins, with the greatest effects expected on the superior sagittal sinus and the confluence of sinuses.	
Sixty milliliter is the maximal volume of compensation before clinical signs of herniation appear during stroke event.	

Table 10. Craniectomy landmarks to consider.

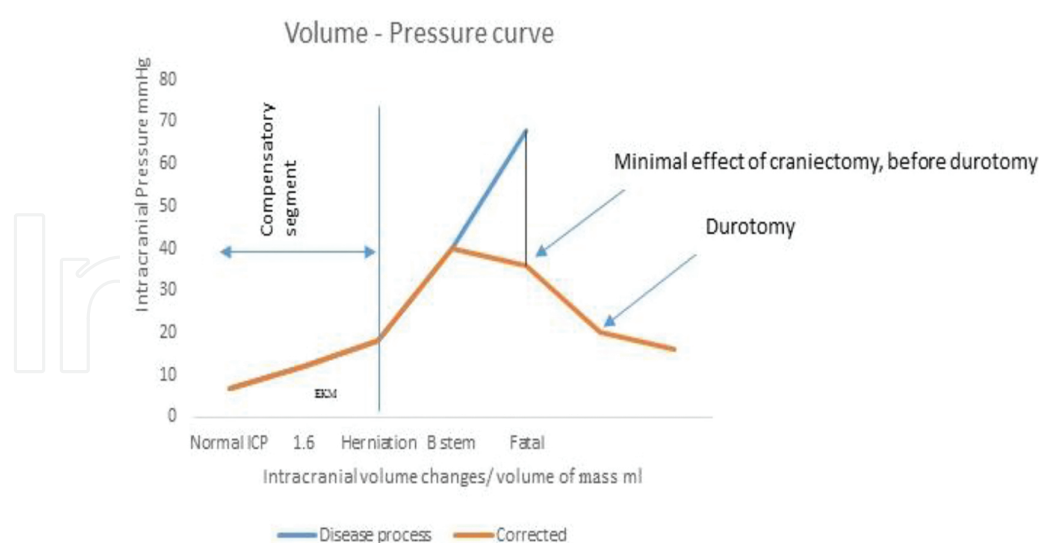
10.3. Decompressive craniectomy (DC)

10.3.1. Age is not the limit! DC is nor the solution, nor the cure! Hemicraniectomy for malignant MCA territory infarction

Treatment modalities for stroke has progressed and substantially changed from what we knew two decades ago; we have now the possibility to use noninvasive treatment options and/or a combination with surgical techniques as well. Although none of the surgical techniques is the first to be considered, they are absolutely the last options we can use to treat stroke event and complications (**Table 11**) (**Diagram 6**).

Indications	Contraindications
Failure of r-tPA and or endovascular treatment	Prestroke mRS score of ≥ 2
Failure of bypass	Prestroke score Barthel Index of < 95
Refractory increase in ICP despite treatment (Graphic 3)	GCS of < 8
	Brain stem involvement and or signs of herniation
Brain stem not involved and before signs of herniation	Hemorrhagic transformation of the infarct
Disease affecting ICA, and or MCA, M1, M2, or either of the last in combination with ACA or PCA (rare occurrence) ipsilateral	Related disease/conditions affecting outcome.
	Coagulopathy/systemic-blooding disorders.

Table 11. Hemicraniectomy indications and contraindications in brain malignant infarction.



Graphic 3. Volume-pressure changes, graphic.

It may reduce mortality to as low as 32% in nondominant hemisphere CVAs [71], and it can reduce mortality up to 37% in all corners, with surprising clinical results. Better results occur with early surgery, before any changes associated with herniation occur [72], but it does not

treat the underlying cause/s of the edema formation (being it transudate or exudate). It is a very important treatment procedure that must be considered. As decompression has never been the first treatment modality, it has mostly been considered the last and in many clinical situations the first as well.

10.3.2. Surgical techniques and notes

Preferred skin incisions for a large decompressive craniectomy (**Table 8, Figure 11**) are as follows:

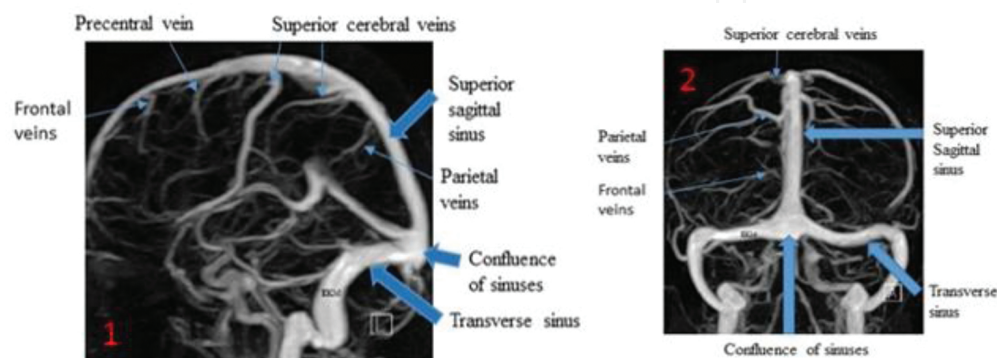


Figure 11. Images 1 and 2 identify the major intracranial surgical landmarks to be considered.

- Question mark extended;
- U shape extended.

Both incisions expose the scalp greatly, with its borders along the anastomotic segments. U-shape incision traumatizes the vascular supply to a lesser degree [73]. However, due to the extensive vascular collateral circulation in the scalp area, scalp necrosis is uncommon.

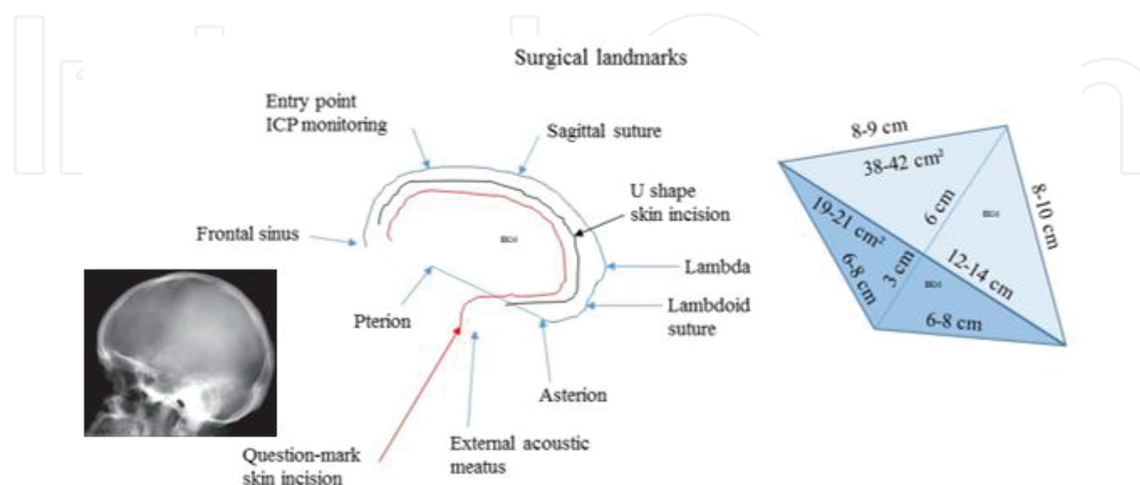


Figure 12. Surgical landmarks and area measurements [74, 75].

Craniectomy landmarks and indications are listed in **Tables 10** and **11** (**Figure 12**).

A larger craniectomy does not always mean better; however, a smaller craniectomy (the lower threshold of 12 cm for hemicraniectomy and decompression to the temporal base) is effective in relieving ICP. The size should always consider the risk of complications, including the parenchymal shear stress and hemorrhage [74, 75] (**Figure 12**).

Age should not be the limit (each disease categories), for medical and or surgical modality treatment decisions, but the existing and past medical conditions of the patient. By contrast, we should push the limit and provide support for longer life expectancy with a better quality for stroke-related diseases [76] (**Table 11**).

Hemicraniectomy is increasingly used as treatment option in stroke and in head trauma, but little is known on the physiological regional effects of hemicraniectomy in the normal brain. In their work, Schaller et al. [77] measured in consecutive hours regional CBF, CMR of O₂, and glucose from the brain tissue underneath the craniectomy (hemicraniectomy) of the animals used in the study. They demonstrated for the first time that decompressive hemicraniectomy decreases CBF, and to a lesser extent CMR of O₂ and glucose 2 h after hemicraniectomy in the normal brain tissues that last for at least 1 day. The underlying basis of these phenomena is not fully understood; however, their findings implied that persisting pathophysiological processes are induced by hemicraniectomy and should be taken into consideration for surgical indications [77].

We can use clinical findings and imagery, and analyze volumetric changes before neuronal injury and predict which patients may benefit from hemicraniectomy. It is a life-saving surgery when performed correctly; it can reduce disability and mortality and improve functional outcome as proved in several controlled trials [75, 78].

10.3.3. Dural incisions and duraplasty

- Cross, extended (**Figure 13 f**) or standard (**Figure 13 d, e**) [73, 79]. These incisions create two smaller triangles superiorly (one and two) (**Figure 13 d, e**), thus creating the possibility for a better supply from the anastomotic vessels opposite. If the axial plane of the dural incision creates equal half's 1–2 and 3–4), the area requiring blood supply from the anastomotic branches (one and two) will be greater than what the vasculature can supply, and this might create the risk of necrosis at the distal margins of each incision.
- “Maple leaf” (**Figure 13 a–c**): the incisions in this technique follow parallel with the vasculature of the major branches of the middle meningeal artery supplying the dura, and respect their segments of anastomosis. At the same time, the wide opening of the dural leafs exposes the brain-herniating tissue to a lesser pressure.

Standard duraplasty can be performed at the end of the decompression procedure, with a loose graft.

10.3.4. When should we put the bone back?

With the patient in stable clinical conditions, we should prepare to put the bone back any time after gliosis starts forming (≥ 4 weeks). Although ICP helps to set a baseline of when we should decide to put the bone back (**Graphic 3**), it is pathologically correct to do so during gliosis and scar formation (**Table 4**), usually >2 weeks when glial scar starts to form, and best after the fourth week when cystic area is surrounded by dense glial fibers.

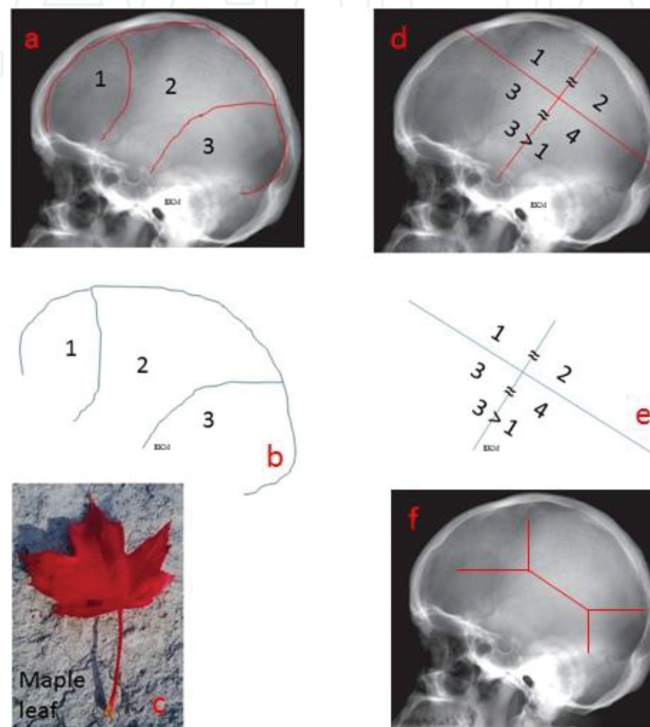


Figure 13. Dural incision's techniques.

10.3.5. Suturing of the skin (at the end of the surgery/craniectomy)

The most productive results are with a continuous suture, if a second surgical procedure will be required; this technique allows you to remove the suture with only two cuts, and pull.

10.4. Possible modality treatments of the future

In the last couple of years, the use of transcranial ultrasound has been modified for therapeutic use as well [80]. Its promising results will open doors for application in thrombus destruction during the ischemic event. Its use in trans-BBB (Blood Brain Barrier) delivery of medical therapy has been published now, as well as its use in functional neurosurgery. This is a novel technique, noninvasive that is starting to take shape beyond its initial plan of application and is promising.

We recommend the use of **Diagram 6** that indicates in a step-wise manner all possible treatment modalities we can chose based on clinical and imagery indications.

Acknowledgements

We thank our medical illustrators for their work and support.

Conflict of interest: The authors declare no conflict of interest.

Author details

Erion Musabelliu^{1*}, Masahiro Oomura² and Yoko Kato¹

*Address all correspondence to: erionmusabelliu@gmail.com

¹ Department of Neurosurgery, Fujita Health University, Toyoake, Aichi, Japan

² Department of Neurology and Neuroscience, Nagoya City University Graduate School of Medical Sciences, Mizuho-cho, Mizuho-ku, Nagoya, Japan

References

- [1] The ATLANTIS, ECASS, and NINDS rt-PA Study Group Investigators. Association of outcome with early stroke treatment: pooled analysis of ATLANTIS, ECASS, and NINDS rt-PA stroke trials. *Lancet* 363: 768–74, 2004.
- [2] Hartmann P, Ramseier A, Gudat F, Mihatsch MJ, Polasek W. Normal weight of the brain in adults in relation to age, sex, body height and weight [article in German]. *Pathologe* 15(3): 165–70, 1994.
- [3] Schaller B, Graf R. Different compartments of intracranial pressure and its relationship to cerebral blood flow. *J Trauma* 59(6): 1521–31, 2005.
- [4] Raichle ME, Grubb RL, Gado MH, et al. Correlation between regional cerebral blood flow and oxidative metabolism. In vivo studies in man. *Arch Neurol* 33: 523–6, 1976. (Reference Henegar MM, Sillbergeld DL: *Pharmacology for Neurosurgeons, Part II: Anesthetic Agents, ICP Management, Corticosteroids, Cerebral Protectants*. *Contemp Neurosurg* 18 (10): 1–6, 1996.)
- [5] Inoue T, Saito I, Tamura A. Emergent surgical embolectomy in conjunction with cervical internal carotid ligation and superficial temporal artery-middle cerebral artery bypass to treat acute tandem internal carotid and middle cerebral artery occlusion due to cervical internal carotid artery dissection. *Surg Neurol Int* 6: 191, 2015. DOI: 10.4103/2152-7806.

- [6] Inoue T, Tamura A, Tsutsumi K, Saito I, Saito N. Surgical embolectomy for internal carotid artery terminus occlusion. *Neurosurg Rev* 38: 661, 2015. doi: 10.1007/s10143-015-0640-4.
- [7] van der Zwan A, Hillen B, Tulleken CAF, et al. Variability of the territories of the major cerebral arteries. *J Neurosurg* 77: 927–40, 1992.
- [8] Evans RJ, Wyllie FS, Wynford-Thomas D, Kipling D, Jones CJ. A P53-dependent, telomere-independent proliferative life span barrier in human astrocytes consistent with the molecular genetics of glioma development. *Cancer Res* 63(16): 4854–61, 2003.
- [9] del Zoppo GJ, Poeck K, Pessin MS, et al. Recombinant tissue plasminogen activator in acute thrombotic and embolic stroke. *Ann Neurol* 32: 78–86, 1992.
- [10] Werdelin L, Juhler M. The course of transient ischemic attacks. *Neurology* 38: 677–80, 1988.
- [11] Levy DE. How transient are transient ischemic attacks? *Neurology* 38: 674–7, 1998.
- [12] Moulin DE, Lo R, Chiang J, et al. Prognosis in middle cerebral artery occlusion. *Stroke* 16: 282–4, 1985.
- [13] Hacke W, Schawb S, Horn M, et al. Malignant middle cerebral artery territory infarction: clinical course and prognostic signs. *Arch Neurol* 53: 309–15, 1996.
- [14] Tomaszek DE, Rosner MJ. Cerebellar infarction: analysis of twenty-one cases. *Surg Neurol* 24: 223–6, 1985.
- [15] Cerebral Embolism Task Force. Cardiogenic brain embolism. *Arch Neurol* 43: 71084, 1986.
- [16] Blackshear JL, Kopecky SL, Litin SC, et al. Management of atrial fibrillation in adults: prevention of thromboembolism and symptomatic treatment. *Mayo Clin Proc* 71: 150–60, 1996.
- [17] Atrial Fibrillation Investigators. Risk factors for stroke and efficacy of antithrombotic therapy in atrial fibrillation: analysis of pooled data from five randomized controlled trials. *Arch Intern Med* 154: 1449–57, 1994.
- [18] Hart RG, Helperin JL. Atrial fibrillation and stroke: revisiting the dilemmas. *Stroke* 25: 1337–41, 1994.
- [19] Lechat P, Mas JL, Lascault G, et al. Prevalence of patent foramen ovale in patients with stroke. *N Engl J Med* 318: 1148–52, 1988.
- [20] Windecker S, Stortecky S, Meier B. Paradoxical embolism. *J Am Coll Cardiol* 29;64(4): 403–15, 2014. doi: 10.1016/j.jacc.2014.04.063.
- [21] Powers WJ, Derdeyn CP, Biller J, Coffey CS, Hoh BL, Jauch EC, Johnston KC, Johnston SC, Khalessi AA, Kidwell CS, Meschia JF, Ovbiagele B, Yavagal DR; American Heart Association Stroke Council. 2015 American Heart Association/

- American Stroke Association Focused Update of the 2013 Guidelines for the early management of patients with acute ischemic stroke regarding endovascular treatment: a guideline for health professionals from the American Heart Association/American Stroke Association. *Stroke* 46(10): 3020–35, 2015. doi: 10.1161/STR.0000000000000074.
- [22] Tomsick TA, Brott TG, Olinger CP, et al. Hyperdense middle cerebral artery: incidence and quantitative significance. *Neuroradiology* 31: 312–5, 1989.
 - [23] Manelfe C, Larrue V, von Kummer R, et al. Association of hyperdense middle cerebral artery sign with clinical outcome in patients treated with plasminogen activator. *Stroke* 30: 760–72, 1999.
 - [24] Elster AD, Moody DM. Early cerebral infarction: gadopentetate dimeglumine enhancement. *Radiology* 177: 627–32, 1990.
 - [25] Lassen NA. Control of cerebral circulation in health and disease. *Circ Res* 34: 749–60, 1974.
 - [26] Kernan WN, Viscoli CM, Furie KL, Young LH, et al, for the IRIS Trial Investigators. Pioglitazone after ischemic stroke or transient ischemic attack. *N Engl J Med* 374: 1321–1331, 2016. doi: 10.1056/NEJMoa1506930.
 - [27] Hou Y, Carrim N, Wang Y, Gallant RC, Marshall AH, Ni H. Platelets in hemostasis and thrombosis: novel mechanisms of fibrinogen-independent platelet aggregation and fibronectin-mediated protein wave of hemostasis. *J Biomed Res* 2015. doi: 10.7555/JBR.29.20150121.
 - [28] Reheman A, Xu X, Reddy E, Ni H. Targeting activated platelets and fibrinolysis: hitting two birds with one stone. *Circ Res* 114: 1070–3, 2014. doi:10.1161/CIRCRESAHA.114.303600.
 - [29] Wang Y, Reheman A, Spring CM, Kalantari J, Marshall AH, Wolberg AS, Gross PL, Weitz JL, Rand ML, Mosher DF, Freedman J, Ni H. Plasma fibronectin supports hemostasis and regulates thrombosis. *J Clin Invest* 124: 4281–93, 2014. doi: 10.1172/JCI74630.
 - [30] Murphy AJ, Bijl N, Yvan-Charvet L, Welch CB, Bhagwat N, Reheman A, Wang Y, Levine R, Ni H, Tall AR, Wang N. Cholesterol efflux in megakaryocyte progenitors suppresses platelet production and thrombosis. *Nat Med* 19: 586–94, 2013. doi: 10.1038/nm.3150.
 - [31] Wang Y, Andrews M, Lang S, Jin JW, Cameron-Vendrig A, Zhu G, Reheman A, Ni H. Platelets in thrombosis and hemostasis. Old topic with new mechanisms. *Cardiovascular & haematological disorders. Drug Targets* 12: 126–132, 2012.
 - [32] Astrup J, Siesjo BK, Symon L. Thresholds in cerebral ischemia — the ischemic penumbra. *Stroke* 12(6): 723–5, 1981.

- [33] Heiss WD. The ischemic penumbra: correlates in imaging and implications for treatment of ischemic stroke. The Johann Jacob Wepfer award 2011. *Cerebrovasc Dis* 32(4): 307–20, 2011. doi: 10.1159/000330462.
- [34] Davalos A, Blanco M, Pedraza S, Leira R, Castellanos M, Pumar J M, et al. The clinical-DWI mismatch: a new diagnostic approach to the brain tissue at risk of infarction. *Neurology* 62(12): 2187–92, 2004.
- [35] Group TNIoNDaSr-PSS. Tissue plasminogen activator for acute ischemic stroke. The National Institute of Neurological Disorders and Stroke rt-PA Stroke Study Group. *N Engl J Med* 333(24): 1581–7, 1995.
- [36] Hacke W, Kaste M, Bluhmki E, Brozman M, Dávalos A, Guidetti D, Larrue V, Lees KR, Medeghri Z, Machnig T, Schneider D, von Kummer R, Wahlgren N, Toni D, ECASS Investigators. Thrombolysis with alteplase 3 to 4.5 hours after acute ischemic stroke. *N Engl J Med* 359(13): 1317–29, 2008.
- [37] Del Zoppo GJ, Saver JL, Jauch EC, Adams HP, Jr. American Heart Association Stroke Council Expansion of the time window for treatment of acute ischemic stroke with intravenous tissue plasminogen activator: a science advisory from the American Heart Association/American Stroke Association. *Stroke* 40(8): 2945–8, 2009.
- [38] Fugate JE, Rabinstein AA. Absolute and relative contraindications to IV rt-PA for acute ishcmic stroke. *Neurohospitalist* 5(3): 110–121, 2015. doi: 10.1177/1941874415578532.
- [39] Mishra NK, Ahmed N, Andersen G, et al. Thrombolysis in very elderly people: controlled comparison of SITS International Stroke Thrombolysis Registry and Virtual International Stroke Trials Archive. *BMJ* 341: c6046, 2010.
- [40] Berruscho J, Rother J, Glahn J, Kucinski T, Fiehler J, Thomalla G. Outcome and severe hemorrhagic complications of intravenous thrombolysis with tissue plasminogen activator in very old (> or =80 years) stroke patients. *Stroke* 36(11): 2421–5, 2005.
- [41] Fiehler J, Albers GW, Boulanger JM, et al. Bleeding risk analysis in stroke imaging before thrombolysis (BRASIL): pooled analysis of T2-weighted magnetic resonance imaging data from 570 patients. *Stroke* 38(10): 2738–44, 2007.
- [42] Katzan IL, Furlan AJ, Lloyd LE, et al. Use of tissue-type plasminogen activator for acute ischemic stroke: the Cleveland area experience. *JAMA* 283(9): 1151–8, 2000.
- [43] Jauch EC, Saver JL, Adams HP, Jr, et al. Guidelines for the early management of patients with acute ischemic stroke: a guideline for healthcare professionals from the American Heart Association/American Stroke Association. *Stroke* 44(3): 870–947, 2013.
- [44] Tissue plasminogen activator for acute ischemic stroke. The National Institute of Neurological Disorders and Stroke rt-PA Stroke Study Group. *N Engl J Med* 333(24): 1581–7, 1995.

- [45] Shinton RA, Gill JS, Melnick SC, Gupta AK, Beevers DG. The frequency, characteristics and prognosis of epileptic seizures at the onset of stroke. *J Neurol Neurosurg Psychiatry* 51(2): 273–6, 1988.
- [46] Bluhmki E, Chamorro A, Davalos A, Machnig T, Sauce C, Wahlgren N, et al. Stroke treatment with alteplase given 3.0–4.5 h after onset of acute ischaemic stroke (ECASS III): additional outcomes and subgroup analysis of a randomised controlled trial. *Lancet Neurol* 8(12): 1095–102, 2009.
- [47] Iguchi Y, Kimura K, Sakai K, Matsumoto N, Aoki J, Yamashita S, et al. Hyper-acute stroke patients associated with aortic dissection. *Intern Med* 49(6): 543–7, 2010.
- [48] Anan C, Oomura M, Saeki T, Ikeda T, Sato C, Yamada K. Fatal intraperitoneal bleeding after intravenous administration of tissue plasminogen activator. *J Stroke Cerebrovasc Dis* 24(7): e177–8, 2015. doi: 10.1016/j.jstrokecerebrovasdis.2015.03.025.
- [49] Saqqur M, Uchino K, Demchuk AM, Molina CA, Garami Z, Calleja S, et al. Site of arterial occlusion identified by transcranial Doppler predicts the response to intravenous thrombolysis for stroke. *Stroke*. 38(3): 948–54, 2007.
- [50] Investigators TIS. Combined intravenous and intra-arterial recanalization for acute ischemic stroke: the Interventional Management of Stroke Study. *Stroke* 35(4): 904–11, 2004.
- [51] Broderick JP, Palesch YY, Demchuk AM, Yeatts SD, Khatri P, Hill MD, et al. Endovascular therapy after intravenous t-PA versus t-PA alone for stroke. *N Engl J Med* 368(10): 893–903, 2013. doi: 10.1056/NEJMoa1214300.
- [52] Berkhemer OA, Fransen PS, Beumer D, van den Berg LA, Lingsma HF, Yoo AJ, et al. A randomized trial of intraarterial treatment for acute ischemic stroke. *N Engl J Med* 372(1): 11–20, 2015. doi: 10.1056/NEJMoa1411587.
- [53] Campbell BC, Mitchell PJ. Endovascular therapy for ischemic stroke. *N Engl J Med* 372(24): 2365–6, 2015. doi: 10.1056/NEJMc1504715.
- [54] Goyal M, Demchuk AM, Menon BK, Eesa M, Rempel JL, Thornton J, et al. Randomized assessment of rapid endovascular treatment of ischemic stroke. *N Engl J Med* 372(11): 1019–30, 2015. doi: 10.1056/NEJMoa1414905.
- [55] Jovin TG, Chamorro A, Cobo E, de Miquel MA, Molina CA, Rovira A, et al. Thrombectomy within 8 hours after symptom onset in ischemic stroke. *N Engl J Med* 372(24): 2296–306, 2015. doi: 10.1056/NEJMoa1503780.
- [56] Saver JL, Goyal M, Bonafe A, Diener HC, Levy EI, Pereira VM, et al. Stent-retriever thrombectomy after intravenous t-PA vs. t-PA alone in stroke. *N Engl J Med* 372(24): 2285–95, 2015. doi: 10.1056/NEJMoa1415061.
- [57] Anderson CS, Robinson T, Lindley RI, Arima H, Lavados PM, Lee TH, Broderick JP, Chen X, Chen G, Sharma VK, Kim JS, Thang NH, Cao Y, Parsons MW, Levi C, Huang Y, Olavarria VV, Demchuk AM, Bath PM, Donnan GA, Martins S, Pontes-Neto OM,

- Silva F, Ricci S, Roffe C, Pandian J, Billot L, Woodward M, Li Q, Wang X, Wang J, Chalmers J. Low-dose versus standard-dose intravenous alteplase in acute ischemic stroke. *N Engl J Med* 2016, May 10 [Epub ahead of print].
- [58] Granger CB, Alexander JH, McMurray JJ, et al. Apixaban versus warfarin in patients with atrial fibrillation. *N Engl J Med* 365(11): 981–92, 2011.
- [59] Wahlgren N, Moreira T, Michel P, Steiner T, Jansen O, Cognard C, Mattle HP, van Zwam W, Holmin S, Tatlisumak T, Petersson J, Caso V, Hacke W, Mazighi M, Arnold M, Fischer U, Szikora I, Pierot L, Fiehler J, Gralla J, Fazekas F, Lees KR; ESO-KSU, ESO, ESMINT, ESNR and EAN. Mechanical thrombectomy in acute ischemic stroke: consensus statement by ESO-Karolinska Stroke Update 2014/2015, supported by ESO, ESMINT, ESNR and EAN. *Int J Stroke* 11(1): 134–47, 2016. doi: 10.1177/1747493015609778.
- [60] Zhu G, Michel P, Aghaebrahim A, Patrie JT, Xin W, Eskandari A, et al. Prediction of recanalization trumps prediction of tissue fate: the penumbra: a dual-edged sword. *Stroke J Cerebral Circ* 44: 1014–9, 2013. doi: 10.1161/STROKEAHA.111.000229.
- [61] EC/IC Study Group. Failure of EC-IC bypass to reduce the risk of ischemic stroke. *N Engl J Med* 313: 1191–200, 1985.
- [62] Lavallée PC, Mazighi M, Saint-Maurice JP, Meseguer E, Abboud H, Klein IF. Stent-assisted endovascular thrombolysis versus intravenous thrombolysis in internal carotid artery dissection with tandem internal carotid and middle cerebral artery occlusion. *Stroke* 38: 2270–4, 2007.
- [63] Inoue T, Tamura A, Tsutsumi K, Saito I, Saito N. Surgical embolectomy for large vessel occlusion of anterior circulation. *Br J Neurosurg* 27: 783–90, 2013. doi: 10.3109/02688697.2013.793286.
- [64] Powers WJ, Clarke WR, Grubb RL, Videen TO, Adams HP, Derdeyn CP. Extracranial-intracranial bypass surgery for stroke prevention in hemodynamic cerebral ischemia: the carotid occlusion surgery study randomized trial. *JAMA* 306: 1983–92, 2011. doi: 10.1001/jama.2011.1610.
- [65] Fusco MR, Harrigan MR. Cerebrovascular dissections—a review part I: spontaneous dissections. *Neurosurgery* 68: 242, 2011. doi: 10.1227/NEU.0b013e3182012323.
- [66] Kim YS, Garami Z, Mikulik R, Molina CA, Alexandrov AV. Early recanalization rates and clinical outcomes in patients with tandem internal carotid artery/middle cerebral artery occlusion and isolated middle cerebral artery occlusion. *Stroke* 36: 869–71, 2005.
- [67] Rubiera M, Ribo M, Delgado-Mederos R, Santamarina E, Delgado P, Montaner J. Tandem internal carotid artery/middle cerebral artery occlusion: an independent predictor of poor outcome after systemic thrombolysis. *Stroke* 37: 2301–5, 2006.
- [68] Nussbaum ES, Janjua TM, Defillo A, Lowary JL, Nussbaum LA. Emergency extracranial-intracranial bypass surgery for acute ischemic stroke. *J Neurosurg* 112: 666–73, 2010.

- [69] Amin-Hanjani S, Barker FG, Charbel FT, Connolly ES, Morcos JJ, Thompson BG. Cerebrovascular section of the American Association of Neurological Surgeons; Congress of Neurological Surgeons. Extracranial-intracranial bypass for stroke-is this the end of the line or a bump in the road? *Neurosurgery* 71: 557–61, 2012.
- [70] Kanamaru K, Araki T, Kawakita F, Hamada K, Kanamaru H, Matsuura K, Sato A, Suzuki H. STA-MCA bypass for the treatment of ischemic stroke. *Acta Neurochir Suppl* 112: 55–7, 2011. doi: 10.1007/978-3-7091-0661-7_10.
- [71] Carter BS, Ogilvy CS, Candia GJ, et al. One-year outcome after decompressive surgery for massive nondominant hemispheric infarction. *Neurosurgery* 40: 1168–76, 1997.
- [72] Schwab S, Steiner T, Aschoff A, et al. Early hemicraniectomy in patients with complete middle cerebral artery infarction. *Stroke* 29: 1888–93, 1998.
- [73] Bruni EJ, Montemurro DG, editors. *Human Neuroanatomy: A Text, Brain Atlas, and Laboratory Dissection Guide*. Oxford University Press; 2009. p. 33–51. ISBN: 978-0-19-537142-0.
- [74] Tanrikulu L, Oez-Tanrikulu A, Weiss C, Scholz T, Schiefer J, Clusmann H, Schubert GA. The bigger, the better? About the size of decompressive hemicraniectomies. *Clin Neurol Neurosurg* 135: 15–21, 2015. doi: 10.1016/j.clineuro.2015.04.019. Epub 2015, May 5.
- [75] Zweckberger K, Juettler E, Bösel J, Unterberg WA. Surgical aspects of decompression craniectomy in malignant stroke: review. *Cerebrovasc Dis* 38(5): 313–23, 2014. doi: 10.1159/000365864.
- [76] Inamasu J, Kaito T, Watabe T, Ganaha T, Yamada Y, Tanaka T, Imizu S, Hayashi T, Hayakawa M, Kato Y, Hirose Y. Decompressive hemicraniectomy for malignant hemispheric stroke in the elderly: comparison of outcomes between individuals 61–70 and >70 years of age. *J Stroke Cerebrovasc Dis* 22(8): 1350–4, 2013.
- [77] Schaller B, Graf R, Sanada Y, Rosner G, Wienhard K, Heiss WD. Hemodynamic and metabolic effects of decompressive hemicraniectomy in normal brain. An experimental PET-study in cats. *Brain Res* 982(1): 31–7, 2003.
- [78] Vahedi K, Vicaut E, Mateo J, Kurtz A, Orabi M, Guichard JP, Boutron C, Couvreur G, Rouanet F, Touzé E, Guillon B, Carpentier A, Yelnik A, George B, Payen D, Bousser MG; DECIMAL Investigators. Sequential-design, multicenter, randomized, controlled trial of early decompressive craniectomy in malignant middle cerebral artery infarction (DECIMAL Trial). *Stroke* 38(9): 2506–17, 2007. doi: 10.1161/STROKEAHA.107.485235.
- [79] Cappabianca P, Califano L, Iaconetta G, editors. *Cranial, Craniofacial and Skull Base Surgery*. Springer-Verlag Italia; 2010. p. 159–165. doi: 10.1007/978-88-470-1167-0.
- [80] Lipsman N, Mainprize TG, Schwartz ML, Hynynen K, Lozano AM. Intracranial applications of magnetic resonance-guided focused ultrasound. *Neurotherapeutics* 11(3): 593–605, 2014. doi: 10.1007/s13311-014-0281-2.