

# We are IntechOpen, the world's leading publisher of Open Access books Built by scientists, for scientists

6,900

Open access books available

186,000

International authors and editors

200M

Downloads

Our authors are among the

154

Countries delivered to

TOP 1%

most cited scientists

12.2%

Contributors from top 500 universities



WEB OF SCIENCE™

Selection of our books indexed in the Book Citation Index  
in Web of Science™ Core Collection (BKCI)

Interested in publishing with us?  
Contact [book.department@intechopen.com](mailto:book.department@intechopen.com)

Numbers displayed above are based on latest data collected.  
For more information visit [www.intechopen.com](http://www.intechopen.com)



---

## Pneumodissection: Enhancement of the Receptor Area before Fat Grafting

---

Guillermo Blugerman, Diego Schavelzon,  
Gabriel Wexler, Marcelo Lotocki,  
Victoria Schavelzon and Guido Blugerman

Additional information is available at the end of the chapter

<http://dx.doi.org/10.5772/64838>

---

### Abstract

**Introduction:** Fat grafts have become a frequent procedure among plastic surgeons due to their versatility for different pathologies. Different techniques have been described about graft enhancement to increase survival; in this chapter, with CO<sub>2</sub> pneumodissection, a technique for improving the biological conditions of the receptor area is exposed. Already known effects of carboxitherapy, such as vasodilation, enhanced Bohr effect and neoangiogenesis, are applied to increase the chance of graft survival. Tissue pneumodissection reduces the fat infiltration pain, thus reducing the sedation requirements.

**Materials and methods:** Carbon dioxide is infiltrated in the subcutaneous tissue with a needle before grafting procedure. The amount of CO<sub>2</sub> injected varies according to the recipient area. Sixty patients treated in past 15 months were included in the study. Patients were followed up every week for the first month, 3 and 6 months postoperative.

**Results:** Grafts survived in all 40 patients according to clinical observation and follow-up. Sedation requirements were minimal. Special interest is the use of this technique when a scar is adherent to deep planes and skin elasticity is reduced.

**Keywords:** fat graft, carboxitherapy, receptor area, graft survival, lipofilling, fat graft enhancement, pneumodissection

## 1. Introduction

The introduction of grafts and/or fillers within the subcutaneous tissue implies the creation of tunnels or planes of dissection within tissue. However, this is not without some significant degree of trauma to the dermis and hypodermis cellular structure and the fragile microcirculation and nerves found within these layers.

In addition, the struggle of the instrument against the resistance of these solid cellular tissues produces pain by transecting nerve endings or compression of the pressure sensors and/or direct distension of these fragile receptors within the skin.

Until now, the only possible solution to reduce these effects was the application of local anesthesia of different modalities, that is, blockades, infiltration or tumescent anesthesia. This implies the introduction of a set volume of liquid and chemicals, which modify the tissue composition both physically and chemically. This alteration to the biophysical composition of the host tissue and the direct limitation of surround tissue elasticity and expandability makes for a suboptimal graft host environment. The ideal environment for graft uptake includes contact with living tissue for nutrition, abundant vascularization in living tissue and consistent blood flow through this vascular net. These characteristics provide for nutrition of the graft and also remove free radicals, toxic for the grafts. We propose a new technique of pneumo-dissection using carbon dioxide in the gas state to expand and dissect tissue planes while preserving delicate microcirculation at the site, enhancing the host area conditions and decreasing pain to the patient.

## 2. Characteristics of carbon dioxide

Carbonic acid gas, is also known as carbon dioxide, carbonic anhydride and dry ice in its solid phase, is composed of one carbon atom and two oxygen atoms, with a chemical formula of  $\text{CO}_2$ .

Its properties have stamped its use as an industrial material as may be seen in fire extinguishers and welding gas. Commercially, it is added to carbonated beverages, including beer and champagne, and its solid form, known as “dry ice,” has been used as a refrigerant and as an abrasive in dry ice blasting.

Within the living cell, a series of reactions in the effort to generate energy in the form of adenosine triphosphate (ATP) produces one of the main by-products of aerobic respiration, that is, carbon dioxide gas ( $\text{CO}_2$ ). Within the presence of oxygen, each molecule of glucose produces 6 molecules of carbon dioxide, 6 molecules of water and up to 30 molecules of ATP. This  $\text{CO}_2$  is then excreted through diffusion from the cells into the blood stream, whereby its binding to hemoglobin ensures its passage to the lungs for exhalation.

Due to the increased solubility of carbon dioxide over oxygen in plasma, each time blood circulates through the body, 4 vol% of carbon dioxide is removed from the tissues and delivered to the lungs to be exhaled. However, this can increase 10 times during physical exercise.

### 3. Uses of carbon dioxide gas in medicine

Carbon dioxide was first described in 1648 by the chemist Jan Baptist van Helmont upon observing the mass discrepancy when burning charcoal within a closed vessel. He surmised that the difference in mass of the ash to the original charcoal had been transmuted into an invisible substance, which he referred to as a “gas” or “spiritus sylvestre.” Following Jan Helmont, much work was carried out on the niche properties of carbon dioxide in the 1700s and 1800s with Adrien-Jean-Pierre Thilorier in 1835, describing solid carbon “snow” CO<sub>2</sub>.

Carbon dioxide’s high purity of 99.9% and nontoxic properties makes it suitable for therapeutic use. Most commonly employed in insufflation gas for minimal invasive surgery (laparoscopy, endoscopy and arthroscopies) [1–4] in order to enlarge body cavities, protect and facilitate manipulation of intra-abdominal structures.

Possessing no hypersensitivity response, regardless of the volume used, it has been used as a contrast medium in angiography and venograms [5–7]. Its applicability as a supercritical fluid state has been marketed within the medical sterilization realm and also when temperatures of –60°C are reached its therapeutic use in cryotherapy or as local analgesia by external application onto the skin surface.

In 1964, Kumar Patel from the USA invented the CO<sub>2</sub> laser, which is still available and which is one of the most useful varieties of medical, surgical, industrial and military applications.

Other uses have, in the addition to pure oxygen in medical grade oxygen, to help provoke breathing and stabilize the O<sub>2</sub>/CO<sub>2</sub> balance within blood.

The uses of carbon dioxide gas on the surface and in the depth of the human body have proven to be highly safe and beneficial in different areas of medicine and surgery. The history of therapeutic use of carbon dioxide gas by either percutaneous or subcutaneous injection, otherwise known as carboxitherapy, began in 1932 at a thermal waters station in the Spy of Royat, France. There, a group of cardiologists utilized CO<sub>2</sub> on patients with peripheral and functional artheropathies (arterosclerotics, Buerger, Raynaud) with significant success. In 1940, Jean Baptiste Romuef [8], a respected cardiologist published his 20-year experience with carboxitherapy. By the mid-1980s, over 400,000 patients had been treated at Royat providing carboxitherapy as not only an efficient therapeutic method but also a safe one.

The known therapeutic effects of CO<sub>2</sub>, such as arterial and capillary vasodilation, enhancement of Bohr and lipolytic effect, increased sympatholytic action and with experimental work demonstrating its neoangiogenetic effect means that its use continues to expand within the realms of its therapeutic properties to medicine. There is abundant bibliography that describes the utilization of carbon dioxide gas in patients with chronic obstructive artery disease and gangrene who were treated with CO<sub>2</sub> injection with significantly good results [9–13].

Also acting on vascular pathologies, in 2002, Toryama et al. [14] showed an excellent improvement in the peripheral circulation in patients with critical ischemia, with a reduction of 83% of amputation cases.

For several decades, we have used the subcutaneous injection of carbon dioxide gas to improve local circulation of the skin and subcutaneous tissues, to produce detachment of fibrous tissues and to promote the formation of new collagen in the treated areas [15]. It is also used in its cryogenic state to perform procedures in cryosurgery.

## 4. Physiological effects

### 4.1. Stimulation of blood circulation

Blood circulation is locally increased with pneumodissection due to a vasodilator effect and a neoangiogenic effect. Vasodilation is produced through two main mechanisms:

- Inflammation
- Acidification

The inflammatory response to an “aggression” is immediate. It physically acts to destroy, dilute or block the offending agent, but, in turn, this triggers a series of events at the vascularized connective tissue level, including plasma, in cells circulating in the blood vessels and in the extravascular components of connective tissue, with the objective to heal and rebuild the damaged tissue. Acute phase inflammatory mediators, such as histamine, bradykinins and prostaglandins, produce vasodilation to increase to the local blood flow in order to deliver white blood cells to the insulted area. Changes in microcirculation occur, increasing the vascular permeability to cells and proteins.

Histological aspects in the repair process demonstrated the proliferation of small newly formed blood vessels and fibroblasts [16].

Inside the body, carbon dioxide reacts with water producing carbonic acid. This reaction acidifies the local medium where  $\text{CO}_2$  is injected. The local increase of  $\text{H}^+$  stimulates vasodilation. In this way, carbon dioxide directly in microcirculation of the vascular connective tissue, promoting vasodilation [17, 18] and an increase in the venous and lymphatic drainage. According to researchers, this can be a reflection of the increase in parasympathetic activity by the decrease in sympathetic activity in these tissues. In addition to that, the persistence of clinical improvement or “temporary cure” of the blood vessel conditions can be explained by the neoangiogenesis [19], due to the formation of angiogenic factors, and vascular endothelial growth and fibroblast growth triggered by hypercapnia tissue.

With carboxitherapy, through the infusion of  $\text{CO}_2$ , it is demonstrated that a persistent vasodilation is identified during assisted laparoscopy, which leads to a significant rise in the concentration of oxygen ( $\text{O}_2$ ) in the local body cavity. Studies with Doppler flow monometry have demonstrated the action of the carboxitherapy in improving blood flow locally.

### 4.2. Bohr effect

The affinity of hemoglobin for oxygen depends on the pH of the medium; the acidity stimulates the release of oxygen thus reducing this affinity. In addition to the acidity, the increase in the

concentration of carbon dioxide ( $\text{CO}_2$ ) as described in the oxygen-hemoglobin dissociation curve also lowers the oxygen affinity. The presence of higher levels of  $\text{CO}_2$  and protons ( $\text{H}^+$ ) in the capillaries of tissues in active metabolism promotes the release of  $\text{O}_2$  of hemoglobin, the reciprocal effect occurs in the capillaries of the alveoli of the lungs and the high concentration of  $\text{O}_2$  releases  $\text{CO}_2$  and  $\text{H}^+$  of the hemoglobin. This relationship is known as Bohr effect [20, 21].

There is a consensus among authors about the existence of a significant increase in the concentration of oxygen ( $\text{O}_2$ ) locally after subcutaneous infusion of  $\text{CO}_2$  demonstrating an increase in the partial pressure of  $\text{O}_2$ . These authors [22, 23] have reported that a decrease in affinity of hemoglobin for oxygen in the presence of carbon dioxide gas leading to more oxygen delivery to the cells, which would boost the metabolism of tissues in the region being treated (potentiation of the Bohr effect).

#### **4.3. Role of $\text{CO}_2$ in connective tissue**

Carboxitherapy produces a “mechanical trauma” post the insertion of the insufflation cannula and the direct trauma of the  $\text{CO}_2$  gas insufflating between tissue planes and creating a form of pneumodissection. This pneumodissection produces an inflammatory process and the consequent migration of fibroblasts to the region of insufflation, leading to the subsequent proliferation of fibroblasts and therefore the synthesis of collagen and activation of other extracellular matrix proteins such as fibronectin and glycoprotein, which are essential in the biological processes such as adhesion and cell differentiation, tissue repair, serving as a substrate for fibrinolytic enzymes and clotting.

Histological studies of the tissues treated with carboxitherapy have found an increase in the thickness of the dermis, as evidenced by the increased stimulus of neocollagenases. There is total preservation of the connective tissue layers, including its vascular and neurovascular structures as evident within these collagen fibers.

### **5. Carbon dioxide gas as pneumodissector of tissues – carboxitherapy**

Insufflating gases within tissue is not an innovative idea in current medicine. Iván Goni Moreno, an Argentinean surgeon from the early 1900s, is credited with his operation of introducing progressive preoperative pneumoperitoneum for the repair of large hernias in 1940. Moreno progressively placed large amounts of room air preoperatively into the peritoneal cavity over a period of weeks. With this technique, the patient became adjusted to an increased intra-abdominal pressure and tolerated the sudden reduction of the viscera during the repair, free from respiratory distress.

Currently, with the widespread of laparoscopic procedures, insufflation with carbon dioxide is widespread in all therapeutic and diagnostic laparoscopy as utilized in general, gynecological and urological surgeries.

Due to carbon dioxide's high degree of diffusion, this gas is rapidly absorbed and eliminated, leaving only the vasodilator effect (pneumodissection) in the tissues, without the increased risk of fatal air embolism.

Subcutaneous infiltration of CO<sub>2</sub> began to be used for aesthetic purposes in the 1970s in France, with the object of treating cellulite and localized areas of adiposities in the subcutaneous tissue. More recent work of Brandi et al. [24, 25] showed measurable reductions in maximum circumference of abdomen, thigh and knee regions with the transcutaneous administration of CO<sub>2</sub> and improved skin irregularity after repeated sessions of carboxitherapy.


## **6. Theory behind the use of carboxitherapy for pneumodissection during fat grafting**

The ideal conditions for adipose (fat) grafting within tissue includes (1) ease of dissection of tissue planes with the advancement of the infiltrating cannula, (2) the ability to layer this fat by placing minimal amounts of adipocytes in multiple tunnels in order to maximize contact with the surrounding tissues therefore increasing the grafts survival rate, (3) good vascularization and oxygenation of tissue recipient site, (4) minimal trauma to reduce the risk of bruising, (5) the absence of vasoconstriction, (6) the absence of toxic chemicals in the recipient tissue and (7) good elasticity of the adjacent tissues to comply with the additional volume. The use of carbon dioxide gas as a pneumodissector of the tissue planes may be the one way to achieve these ideal conditions in the host tissue.

The resistance of the tissues to the advancement of a needle or cannula is predetermined by the density of cell structures and fibrosis of the tissue area on the body. Some of the causes of pain during the introduction of fluids and grafts into tissues are due to the compression of pressure receptors (baroreceptors) and also by the stretching of the nerve endings by direct mechanical pressure from the advancing cannula or needle. Also, the pH of the solutions being injected produces pain and burning. The slow insufflation of the carbon dioxide in its gaseous state by percutaneous injection produces tissue plane dissection, which subsequently decreases the tissues' overall resistance while increasing its three-dimensional space, yet preserving the neurovascular characteristics of that tissue by pneumodissecting these structures away with the advancement of the needle/cannula and therefore decreasing the possibility of direct pain.

## **7. Clinical experience**

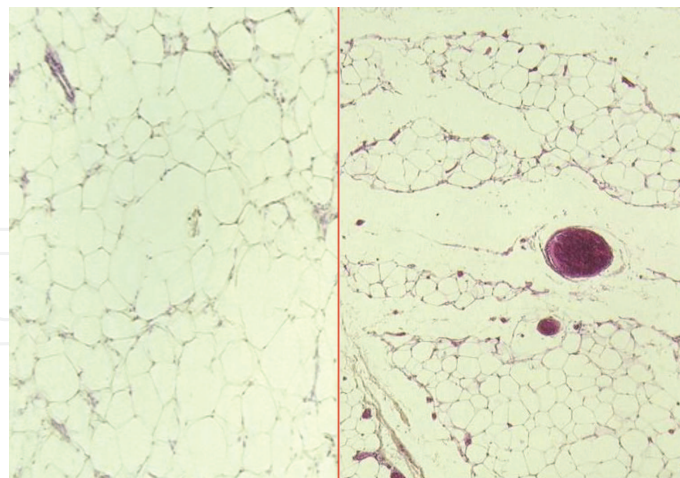
The pneumodissection flow and the total volume of gas infiltrated subcutaneously are controlled with CARBOTECH F650 from Axt Medical Systems®, with complete control over the speed and volume of CO<sub>2</sub> gas infiltrated (**Figure 1**).



**Figure 1.** Pneumodissector console.

The pneumodissector console is connected to the pure carbon dioxide gas tank. The CO<sub>2</sub> is injected under the control of the surgeon for speed of flow, time of injection and overall administered dose through a disposable tube with 25G needle attached through luer-lock. This needle is then inserted directly under the skin of the patient within the designated site.

The flow of CO<sub>2</sub> through the pneumodissector is fixed at 80 ml per minute. Insufflation between 100 and 1000 ml per area depending on the procedure to be carried out and the site on the body to be performed is undertaken. CO<sub>2</sub> easily distributes to all of the injected area and its surrounding tissue (**Figure 2**).



**Figure 2.** Histology of pneumodissected tissue (hematoxylin-eosin). Left, Normal subcutaneous tissue. Right, Subcutaneous tissue after pneumodissection, note the air spaces between septums and vessels.

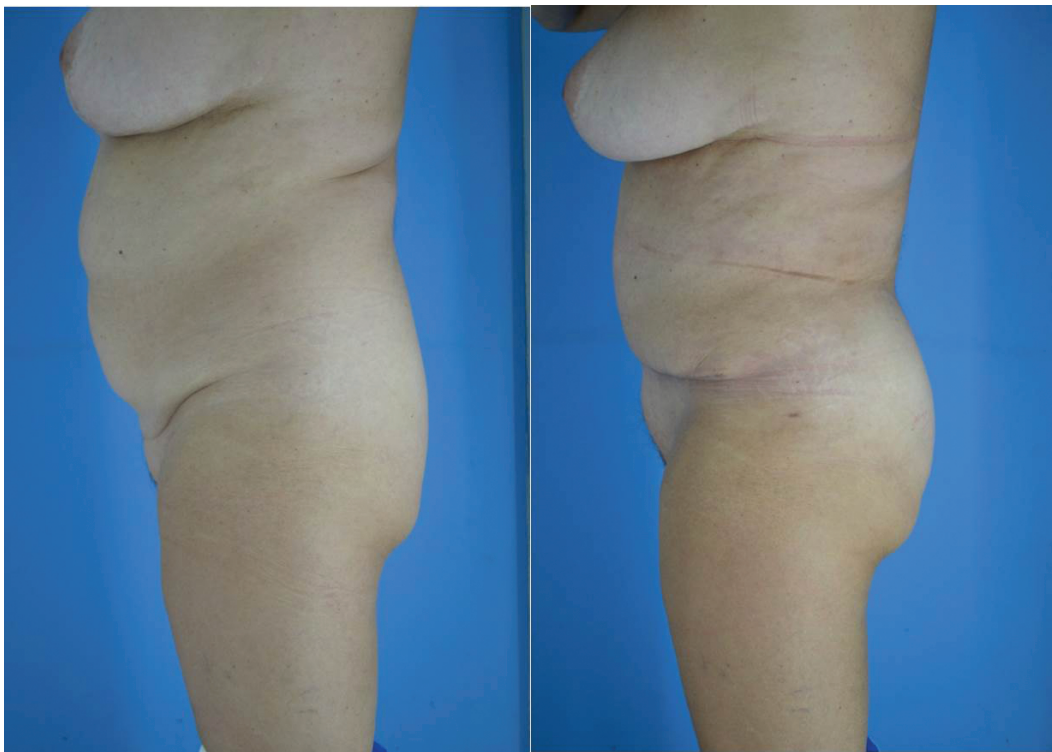During the past 12 months, we have used the pneumodissection technique intraoperatively prior to the grafting of adipocytes at various quantities in 60 patients (**Table 1**).

Area	Amount injected (cc)	Volume of CO <sub>2</sub> infused (cc)
Breast	210	333
Breast	600	707
Breast	560	765
Buttocks	400	580
Buttocks	700	765
Buttocks	800	1000
Buttocks	480	580
Buttocks	550	595
Buttocks	840	843
Buttocks	780	865
Buttocks	440	564
Buttocks	620	789
Buttocks	680	721
Arms	240	469
Arms	225	342
Facial	26	45
Facial	54	89
Facial	32	48
Facial	38	74
Facial	49	107
Buttocks	200	378
Buttocks	680	731
Buttocks	250	379
Buttocks	540	763
Buttocks	780	893
Buttocks	300	389
Breast	150	333
Breast	400	586
Breast	520	555
Breast	460	632
Breast	380	509
Hand	40	100
Hand	50	104
Hand	40	132
Genitalia	30	105
Abdomen	12	40
Abdomen	20	57
Abdomen	10	58
Thigh	180	287
Calf	110	215
Breast	250	380
Breast	550	647
Breast	610	805
Buttocks	450	640
Buttocks	650	700
Buttocks	840	999

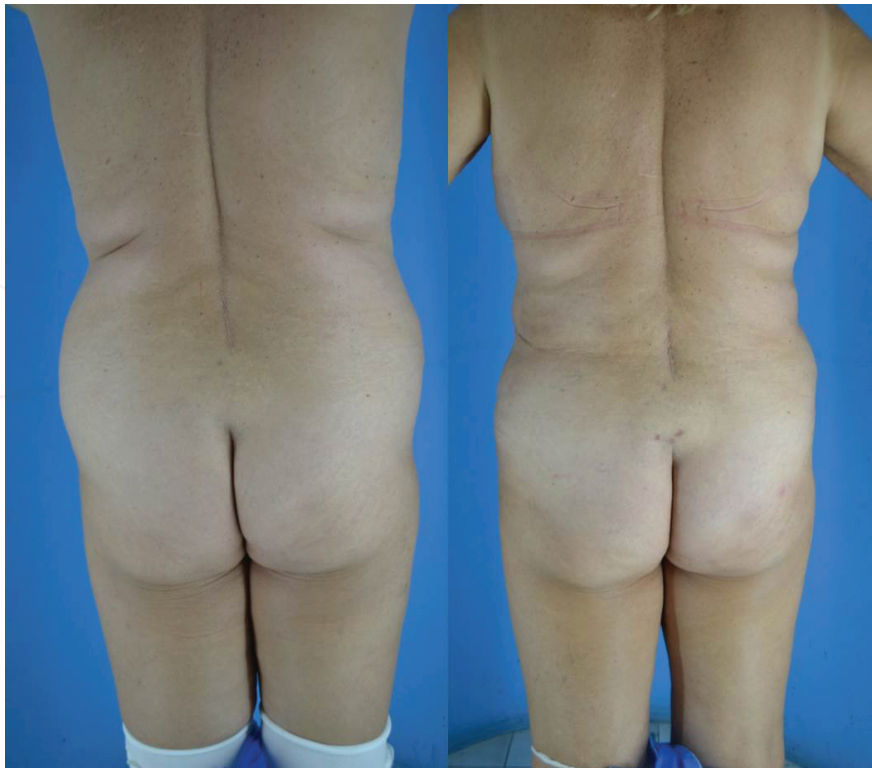Area	Amount injected (cc)	Volume of CO <sub>2</sub> infused (cc)
Buttocks	430	520
Buttocks	600	700
Buttocks	780	900
Buttocks	700	800
Buttocks	445	507
Buttocks	635	885
Buttocks	600	651
Arms	200	461
Arms	221	302
Facial	22	41
Facial	55	91
Facial	30	44
Facial	34	70
Facial	45	101

**Table 1.** Patients table. Details of volume of fat grafted and CO<sub>2</sub> infused.

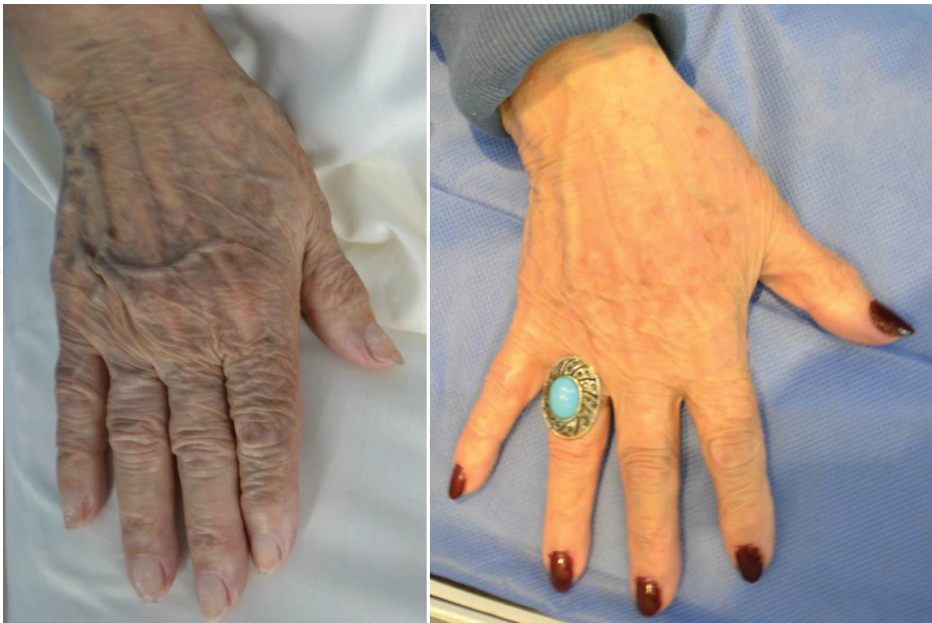Areas of both the body (abdomen, buttocks, arms, breast, and legs) and face have been successfully pneumodissected prior to fat grafting with clinically superior results compared to commonly used hydrodissection technique (**Figures 3–11**).



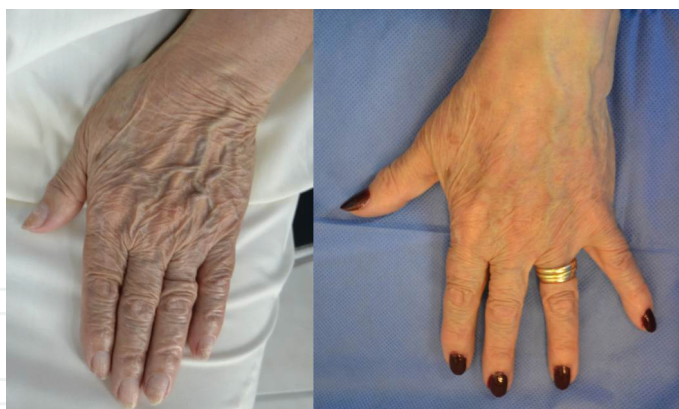**Figure 3.** Patient with abdominal flaccidity, lipodystrophy and gluteal hypoplasia. Preoperative (left) and 3 months postoperative of TULUA, liposuction and pneumodissection-assisted fat grafting to gluteal area in the subcutaneous plane (right).



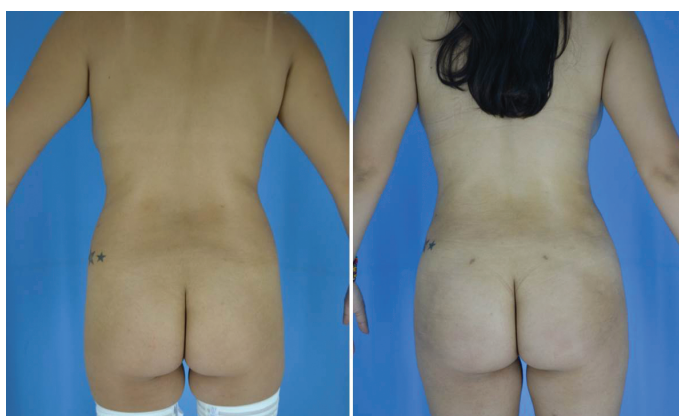**Figure 4.** Patient with abdominal flaccidity, lipodystrophy and gluteal hypoplasia. Preoperative (left) and 3 months postoperative of TULUA, liposuction and pneumodissection-assisted fat grafting to gluteal area in the subcutaneous plane (right).



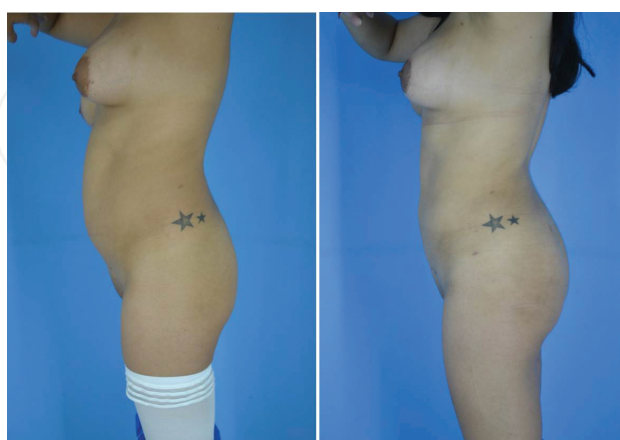
**Figure 5.** Patient with hand aging. Note skin quality, flaccidity and prominence of vascular network (left). Three months postoperative of pneumodissection-assisted fat grafting in hands in the subcutaneous plane (right).



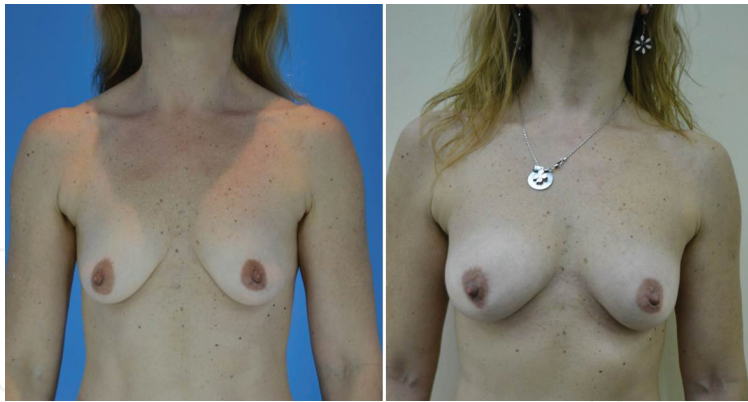**Figure 6.** Patient with hand aging. Note skin quality, flaccidity and prominence of vascular network (left). Three months postoperative of pneumodissection-assisted fat grafting in hands in the subcutaneous plane (right).



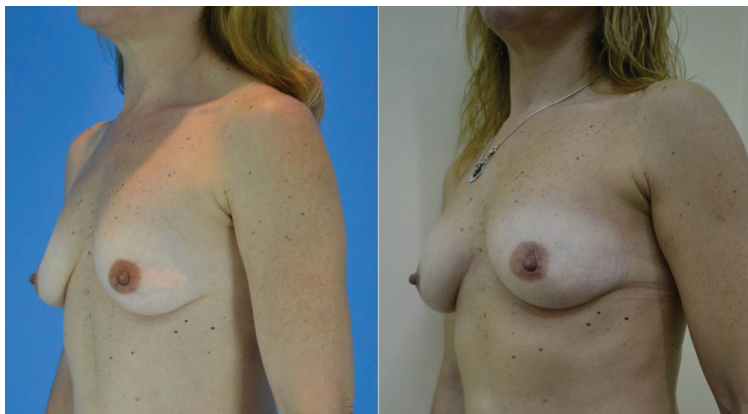**Figure 7.** Patient with gluteal hypoplasia (left). After 3 months of pneumodissection-assisted fat grafting in the gluteal area in the subcutaneous plane (right).



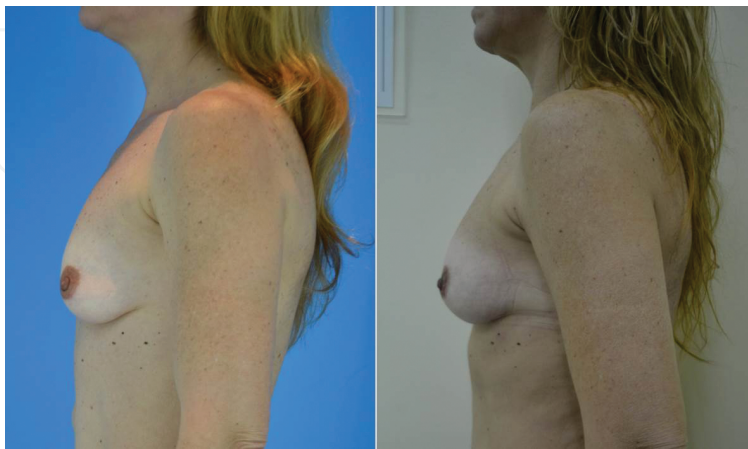**Figure 8.** Patient with gluteal hypoplasia (left). After 3 months of pneumodissection-assisted fat grafting in the gluteal area in the subcutaneous plane (right).



**Figure 9.** Patient with breast hypoplasia (left). After 3 months of pneumodissection-assisted fat grafting in breasts in the subcutaneous plane (right).



**Figure 10.** Patient with breast hypoplasia (left). After 3 months of pneumodissection-assisted fat grafting in breasts in the subcutaneous plane (right).



**Figure 11.** Patient with breast hypoplasia (left). After 3 months of pneumodissection-assisted fat grafting in breasts in the subcutaneous plane (right).

Upon pneumodissection of the tissue planes, the subsequent ease with which the introduction and advancement of the infiltrating cannula allows for ease of larger amounts of grafting tissue (adipocytes) with greater uniformity to be placed, less resistance from normal tissue planes and decrease in both intra- and postoperative discomfort to the patient. There was less bruising of the skin noted within the postoperative period.

## 8. Complications and adverse events of carboxitherapy

As already mentioned, carbon dioxide gas is a versatile gas utilized within many industries. It is a by-product present in the blood circulation as a consequence of aerobic respiration. Based on current literature, carboxitherapy can be considered as a safe therapeutic treatment, without adverse effects or major complications, both local and systemic.

The amount of gas injected during a therapeutic dose of carboxitherapy is below the volume produced by the body itself. Our body produces 200 cc of CO<sub>2</sub> when at rest and during vigorous exercise this amount may rise to 10 times that value. In addition, the patients in our study subjected to subcutaneous injections of CO<sub>2</sub> show no damage to the connective tissue or its microcirculation.

Therefore, we know that CO<sub>2</sub> works in the affected area and is rapidly eliminated from the body with no possibility of air embolus. However, in our study, minimal complications were noted with the administration of subcutaneous CO<sub>2</sub> therapy. These included and were limited to (1) local pain at the injection site of the 25G needle, (2) small bruising and ecchymosis from the needle entering the dermis, (3) A “cracking sensation” experienced by patients due to the formation of local emphysema that disappears within 30 minutes of the procedure.

## 9. Contraindications to carboxitherapy

Contraindications to the treatment include acute myocardial infarction, unstable angina, heart failure, hypertension, acute thrombophlebitis, gangrene or localized infections at the site therapy, epilepsy, respiratory failure, renal failure, pregnancy and psychiatric disorder. But in any case, these patients would not be candidates for an elective body contouring surgery. So, in healthy patients with usual comorbidities, there are no contraindications.

## 10. Conclusion

Carbon dioxide is an abundant gas found in every living species on Earth. Its role in many industries, including medicine, have stemmed from its early discovery in 1648. With respect to its effect on both the skin and subdermal layers, CO<sub>2</sub> has sound physiological principles confirmed through histological studies.

Our technique of pneumodissection prior to adipocyte grafting has worked with these principles in mind. Using CO<sub>2</sub> to establish volume within given tissue planes yet preserving the fragile microcirculation of the tissue is a valuable prerequisite to the survival of the graft.

## Author details

Guillermo Blugerman<sup>1\*</sup>, Diego Schavelzon<sup>1</sup>, Gabriel Wexler<sup>2</sup>, Marcelo Lotocki<sup>3</sup>, Victoria Schavelzon<sup>1</sup> and Guido Blugerman<sup>1</sup>

\*Address all correspondence to: drblugerman@gmail.com

1 Centro ByS, Buenos Aires, Argentina

2 Estetica Wexler, Cordoba, Argentina

3 Genesis, Obera, Misiones, Argentina

## References

- [1] McMahon, AJ, Baxter, JN, Murray, W, Imrie, CW, Kenny, G, O'Dwyer, PJ. Helium pneumoperitoneum for laparoscopic cholecystectomy: ventilatory and blood gas changes. *Br J Surg* 1994; 81: 1033-1036.
- [2] Wolf, JS Jr, Carrier, S, Stoller, ML. Gas embolism: helium is more lethal than carbon dioxide. *J Laparoendosc Surg* 1994; 4: 173-177.
- [3] Yau, P, Watson, DI, Lafullarde, T, Jamilson, GG. An experimental study of the effect of gas embolism using different laparoscopy insufflation gases. *J Laparoendosc Adv Surg Tech* 2000; 10: 211-216.
- [4] Vilos, GA, Vilos, AG. Safe laparoscopic entry guided by Veress needle CO<sub>2</sub> insufflation pressure. *J Am Assoc Gynecol Laparosc*, 2003 Aug; 10(3): 415-420.
- [5] Zwaan W, Kloess W, Kagel C, Kummer-Kloess DR, Matthies-Zwaan S, Schutz RM, Weiss HD. Carbon dioxide as an alternative contrast medium in peripheral angiography, *Rofo Fortschr Geb Rontgenstr Neuen Bildgeb Verfahr.* 1996; 165(2): 180.
- [6] Roberts, MW, Mathiesen, KA, Ho, HS, Wolfe, BM. Cardiopulmonary responses to intravenous infusion of soluble and relatively insoluble gases. *Surg Endosc* 1997; 11: 341-346.

- [7] Lang EV, Gossler AA, Fick LJ, Barnhart W, Lacey DL. Carbon dioxide angiography: effect of injection parameters on bolus configuration. *J Vasc Interv Radiol.* 1999 Jan; 10(1): 41-49.
- [8] Romeuf, JB. Study of subcutaneous injections of thermal gas from Royat. Clermont Ferrand, Imp Moderne, 15 rue du Port 31, Mars 1940.
- [9] Ambrosi C, Delanoe G. Therapeutic effect of CO<sub>2</sub> injected subcutaneously in arteriopathies of the limbs. Experimental research (author's transl). *Ann Cardiol Angeiol (Paris).* 1976; 25(2): 93-98.
- [10] Fabry R, Dubost JJ, Schmidt J, Body J, Schaff G, Baguet JC. Thermal treatment in arterial diseases: an expensive placebo or an effective therapy? *Therapie.* 1995; 50(2): 113-122.
- [11] Savin, E, Bailliar, O, Bonnin, P, Bedu, M, Cheynel, J, Coudert, J, Martineaud, JP. Vasomotor effects of transcutaneous CO<sub>2</sub> in stage II peripheral occlusive arterial disease. *Angiology* 1995; 46(9): 785-791.
- [12] Hartman, B, Bassenge, E, Hartman, M. Effects of serial percutaneous application of carbon dioxide in intermittent claudication: results of a controlled trial. *Angiology.* 1997, 48(11): 957-963.
- [13] Castex M, Di Cio A, Lista GA. Plantar ulcer with arterial calcification: results of treatments with carbogen. *Revista de la Asociacion Medica Argentina*, 30 de diciembre de 1934.
- [14] Toryama T, Kumada Y, Matsubara T, Murata A, Ogino A, Hayash H, Nakashima H, Takahashi H, Matsuo H, Kawahara H. Effect of artificial carbon dioxide foot bathing on critical limb ischemia (Fontaine IV) in peripheral arterial disease patients. *Int Angiol.* 2002; 21(4): 367-373.
- [15] Ferreira, JCT, Haddad, MD, Tavares, SAN. Increase in collagen turnover induced by intradermal injection of carbon dioxide in rats. *J Drugs Dermatol.* 2008;7(3): 201-6.
- [16] Colin, C, Lagneaux, D, Lecomte, J. Local vasodilating effects of carbon dioxide on cutaneous blood vessels. *J Belge Med Phys Rehabil*, 1978; 1(4): 326-334.
- [17] Ito, T, Moore, J, Koss, M, Topical application of CO<sub>2</sub> increases skin blood flow. *J Invest Dermatol.* 1989; 93(2): 259-262.
- [18] Schnizer, W, Erdl, R, Schops, P, Seichert, N. The effects of external CO<sub>2</sub> application on human skin microcirculation investigate by laser Doppler flowmetry. In *J Microcirc Clin Exp*, 1995, 4(4): 343-350.
- [19] Hidekazul I, Tatsumi T, Takamiya M, Zen K, Takahashi T, Azuma A, Tateishi K, Nomura T, Hayashi H, Nakajima N, Okigaki M, Matsubara T. Carbon dioxide-rich water bathing enhances collateral blood flow in ischemia limb via mobilization of endothelial progenitor cells and activation of NO-cGMP system. *Circulation* 29, 2005; 1523-1529.
- [20] Guyton et al. *Textbook of Medica Physiology*, Rio de Janeiro, Guanabara Koogan, 2002.

- [21] Houssay, BA. Human Physiology 5 ed. Rio de Janeiro. Guanabara Koogan, 1984, p. 346-349.
- [22] Hartman, BR, Bassenge, E, Pittler, M. Effect of carbon dioxide – enriched water and fresh water on the cutaneous microcirculation and oxygen tension in the skin of the foot. *Angiology*, 1997; 48(4): 337-343.
- [23] Hartmann, B, Drews, B, Burnus, C, Bassenge, E. Increase in skin blood circulation and transcutaneous oxygen partial pressure of the top of the foot in lower leg immersion in water containing carbon dioxide in patients with arterial occlusive disease. Results of a controlled study compared with fresh water. *Vasa* 1991; 20(4): 382-387.
- [24] Brandi, C, D’Aniello, C, Grimaldi, L, Bosi, B, Dei, I, Lattarulo, P, Alessandrini, C. Carbon dioxide therapy in the treatment of localized adiposities: clinical study and histopathological correlations, *Aesthetic Plast Surg*. 2001; 25(3): 170-174.
- [25] Brandi, CD, Aniello, C, Grimaldi, L, Caiazzo, E, Stanghellini, E. Carbon dioxide therapy: Effects on skin irregularity and its use as a complement to liposuction. *Aesth Plast Surg*. 2004; 28(4): 222–5.