

We are IntechOpen, the world's leading publisher of Open Access books Built by scientists, for scientists

6,900

Open access books available

186,000

International authors and editors

200M

Downloads

Our authors are among the

154

Countries delivered to

TOP 1%

most cited scientists

12.2%

Contributors from top 500 universities



WEB OF SCIENCE™

Selection of our books indexed in the Book Citation Index
in Web of Science™ Core Collection (BKCI)

Interested in publishing with us?
Contact book.department@intechopen.com

Numbers displayed above are based on latest data collected.
For more information visit www.intechopen.com



Diagnosis of Hepatocellular Carcinoma

Ayse Kefeli, Sebahat Basyigit and
Abdullah Ozgur Yeniova

Additional information is available at the end of the chapter

<http://dx.doi.org/10.5772/64992>

Abstract

Hepatocellular carcinoma (HCC) is one of the commonest cancers worldwide, particularly in the developing countries HCC occurs predominantly in patients with underlying chronic liver disease and cirrhosis, especially due to chronic hepatitis C virus (HCV) and hepatitis B virus (HBV) infection. Tumors progress with local expansion, intrahepatic spread, and distant metastases, and the life expectancy of patients with HCC is poor, with a mean survival of 6–20 months. Thus, developing effective and efficient care for patients with HCC must become a significant subject. Removal of HCC by surgical, transplantation or resection of the tumors, means offers the best chance for possible cure. Criteria for such intervention have been refined over the last decade to optimize long-term survival in selected patients with Milan criteria. Not many patients are candidate given the advanced stage of their cancer at diagnosis or degree of liver disease. The other main limiting factor is inadequate organ storage. Unfortunately, many patients die when they are waiting a donor organ. Local ablative therapies may be effective for time saving as a bridge therapy, and may provide palliation, in these patients. Diagnostic tools commonly used include radiographic imaging, and rarely serum markers and liver biopsy. A suspicious lesion on the ultrasound generally requires additional imaging studies to confirm the diagnosis of the tumor. Histologic confirmation is not required in a patient at increased risk for hepatocellular carcinoma whose lesion(s) fulfill criteria for hepatocellular carcinoma which are presence of typical features, including hypervascularity during arterial phase followed by decreased enhancement (washout) during portal venous phases on computerized tomography or has increased T2 signal intensity on magnetic resonance imaging.

Keywords: hepatocellular carcinoma, alpha fetoprotein, computerized tomography, magnetic resonance imaging

1. Introduction

Hepatocellular carcinoma (HCC) is the most common primary tumor of the liver that usually develops in the setting of chronic liver disease. It is the fifth most common cancer in men and the eighth most common in women and is the second leading cause of cancer-related death in the world [1]. Moreover, incidence of HCC is increasing despite limited number of cancer registries, underdiagnosis of HCC, particularly in developing countries. Therefore, the ability to make a diagnosis of HCC at an early time has a critical role to providing effective treatment, including curative treatment such as surgical resection, liver transplantation. Hereby, surveillance program has been developed to provide early treatment and updated guidelines recommend that groups were specified for which surveillance who has chronic liver disease, was likely to be cost-effective because the HCC incidence was high enough [2–6]. Eventually, surveillance programs with the purpose of early detection of HCC, primarily through serum markers as alpha-fetoprotein (AFP) assessment and hepatic imaging, have led to archive to early diagnosis and curative treatment in patients with HCC [7]. When hepatic lesion is identified by surveillance program, the diagnosis of HCC can be made by the use of dynamic imaging series, tumor markers, and rarely liver biopsy. Imaging modalities have primary role to establishing the diagnosis of HCC but serum tumor markers and liver biopsy continue to have important role, particularly in the setting of small or atypical hepatic lesion. On the other hand, unfortunately, no universal guidelines for diagnosis exist, which may be because of the differences in the diagnostic approach between Eastern and Western institutions. The aim of this chapter is to provide an extensive review of the current modalities employed for the diagnosis of HCC, including serum markers, radiological techniques and histological evaluation, and comparison international guidelines for the diagnostic approach to HCC.

2. Diagnosis of Hepatocellular Carcinoma

The diagnostic approach to the solid liver lesion is commonly determined by the size of the lesion. The diagnostic approach differs according to whether lesion is lesser or larger than 1 cm. The American Association for the Study of Liver Diseases (ASLD) and Korean Liver Cancer study Group-National Cancer Centre Korea (KLCSG-NCC) guidelines recommend follow-up ultrasound (US) every three-six months if the lesions are lesser than 1 cm and require definitive contrast-enhanced imaging with either 4-phase computed tomography (CT) or magnetic resonance imaging (MRI) (**Figure 1**) if the lesions are larger than 1 cm; otherwise European Association for the Study of the Liver (EASL) guidelines have different algorithm which had three ways; first one is which nodules are lesser than 1 cm, second one is in diameter 1–2 cm, and third one is larger than 2 cm. On the other hand, Asian Pacific Association for the Study of the Liver the Asian Pacific Association for the Study of the Liver (APASL) guideline ignores the size of the liver lesion. Recent guidelines have some diversity, and thus, all algorithms of guidelines were presented in figures (**Figures 1–4**) [2–6].

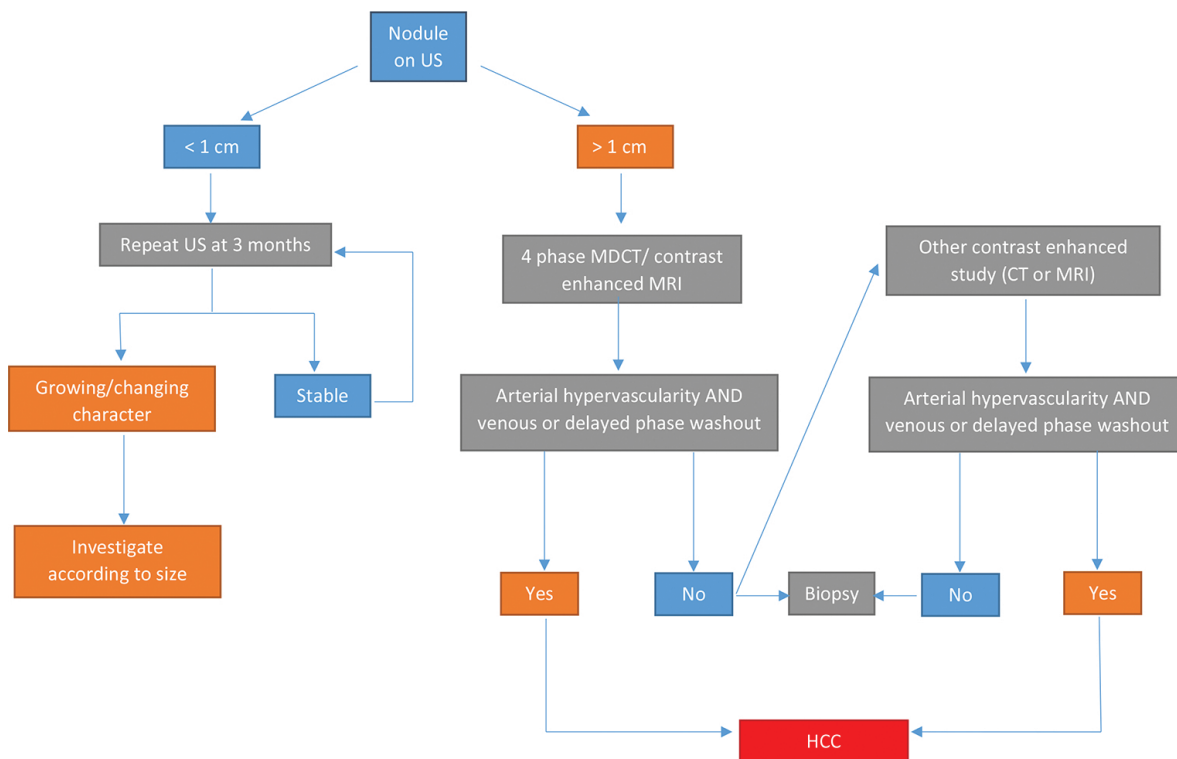
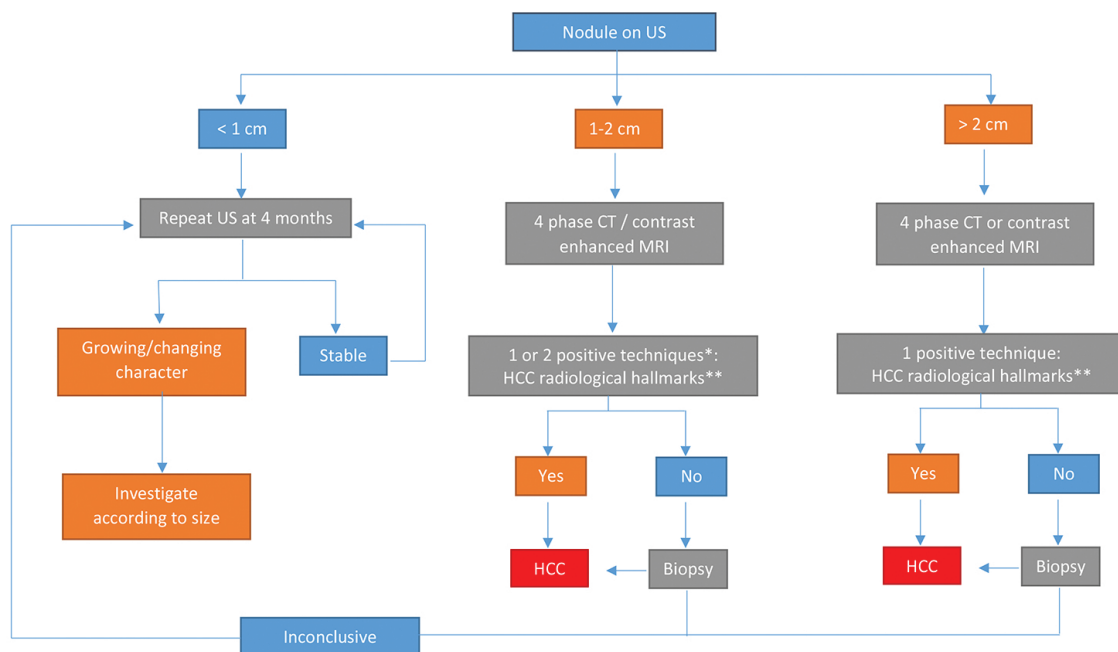


Figure 1. Diagnostic algorithm of AASLD guideline for nodule by detected US in patients at risk of HCC.



* One imaging technique only recommended in centers of excellence with high-end radiological equipment.
 ** HCC radiological hallmark arterial hypervascularity and venous/late phase washout.

Figure 2. Diagnostic algorithm of EASL guideline for nodule by detected US in patients at risk of HCC.

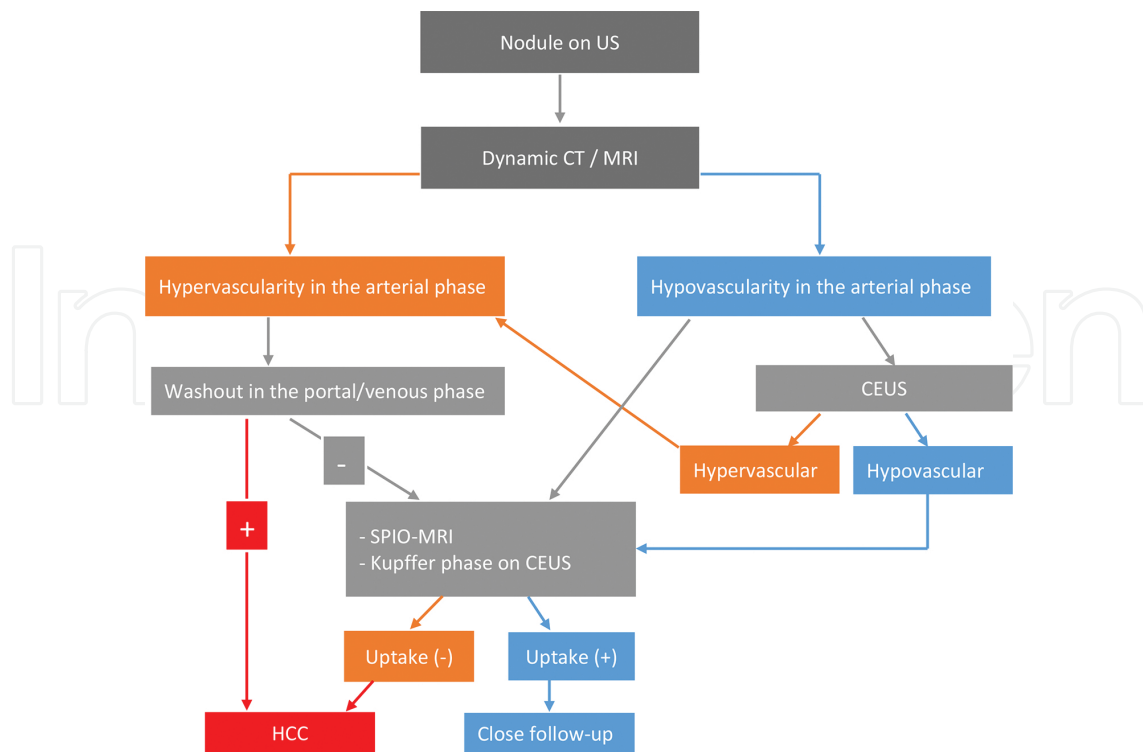


Figure 3. Diagnostic algorithm of APASL guideline for nodule by detected US in patients at risk of HCC.

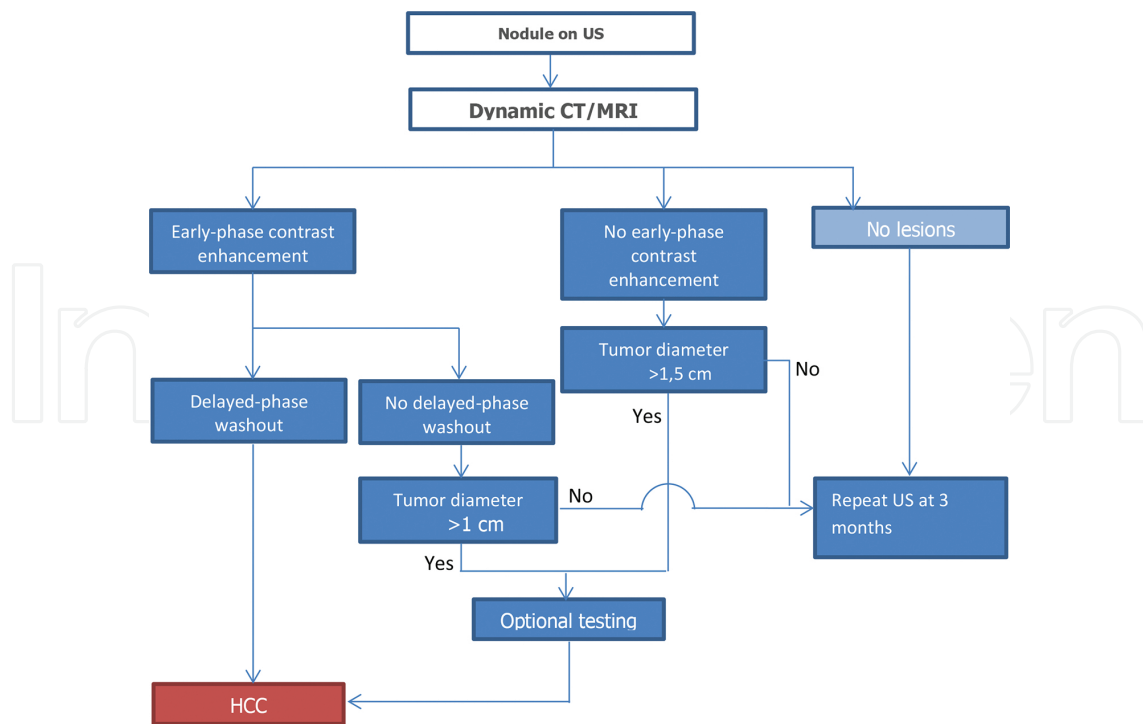


Figure 4. Diagnostic algorithm of JAPAN for nodule guideline by detected US in patients at risk of HCC.

Histologic confirmation is not required in a patient at increased risk of hepatocellular carcinoma whose lesion(s) fulfill criteria for hepatocellular carcinoma which are the presence of typical features on 4-phase CT or MRI, including hypervascularity during arterial phase followed by decreased enhancement (washout) during portal venous phases on CT or has increased T2 signal intensity on MRI. However, if the diagnosis remains unclear, the lesions did not have these specific features, and the results will affect the patient's management, and a biopsy of the lesions is indicated. Biopsy is rarely needed due to valuable contribution of serum markers on diagnosis of HCC. Although elevated serum AFP levels had been evaluated in guidelines previously, almost all of recent guidelines no longer include measurement of serum AFP in the diagnostic algorithm for hepatic nodules found on surveillance program [2, 3].

With the Asian, American, and European guidelines, Liver Imaging Reporting and Data System (LI-RADS) has been developed to address the limitations of prior imaging-based criteria including the lack of established consensus regarding the exact definitions of imaging features, binary categorization (either definite or not definite HCC), and failure to consider non-HCC malignancies [8].

Comparison of the EASL, AASLD, APASL, and LI-RADS guidelines are summarized in **Table 1**.

	EASL	AASLD	APASL	JAPAN	LI-RADS
Target population	Cirrhosis	Hep B carriers, cirrhosis	Cirrhosis only with Hep B or Hep C	All patients at high risk of HCC	All patients at high risk of HCC
Targeted lesion	Detected nodule by US	Detected nodule by US	Detected nodule by US and elevated AFP	Detected nodule by US and elevated AFP, AFP-L3, DCP	All nodules
Imaging modality	4-phase MDCT, CE-MRI	4-phase MDCT, CE-MRI	CT, CEUS, SPIO-MRI	CT, CEUS, Gd-EOB-DTPA-enhanced MRI, CT angiography	CT, MRI with extracellular and hepatobiliary agent
Diagnostic criteria	Larger than 1 cm	Larger than 1 cm	Washout on PVP, DP or	AP enhancement	AP enhancement
	AP enhancement	AP enhancement	High SPIO-MR signal or	Washout on DP	Washout on PVP, DP
	Washout on PVP, DP	Washout on PVP, DP	Defect in KP on CEUS *Regardless of the size	Larger than 1 or 1.5 cm	Capsule appearance
Number of required exam	≥2 cm: one exam 1–2 cm: two exams	One exam	One exam	One exam	One exam
Serum marker	N/A	N/A	Only for small nodules (<1 cm)	Yes	N/A
Category of diagnosis	HCC	HCC	HCC	HCC	LR-1 definitely benign
	Not HCC	Not HCC	Not HCC	Not HCC	LR-2 probably benign
	Indeterminate	Indeterminate	Indeterminate	Indeterminate	LR-3 indeterminate

	EASL	AASLD	APASL	JAPAN	LI-RADS
					LR-4 probably HCC
					LR-5 definitely HCC
					LR-5V definitely tumor invading vein
					LR-M probably malignancy but not specific for HCC
Diagnosis of subcentimetre HCC without biopsy	No	No	Yes (tumor marker + imaging)	No	Yes (probably HCC)
Biopsy required	Yes	Yes	No	Yes	Yes (LR-4, LR-M)

AASLD: Association for the Study of Liver Diseases; AFP: alpha-fetoprotein; AP: arterial phase; CHB: chronic hepatitis B; CHC: chronic hepatitis C; DP: delayed phase; EASL: European Association for the Study of the Liver; 4-phase MDCT: +phase multidetector computerized tomography; CE-MRI: contrast-enhanced magnetic resonance imaging; HCC: hepatocellular carcinoma; KLCSCG-NCC: Korean Liver Cancer Study Group-National Cancer Center; LC: liver cirrhosis; LI-RADS: Liver Imaging Reporting and Data System; N/A: not applicable; PVP: portal venous phase; TP: transitional phase; US: ultrasonography; KP: Kupfer.

Table 1. Comparison of EASL, AASLD, APASL guidelines, and LI-RADS.

2.1. Serum markers

Ideal biomarkers should provide or contribute to diagnose and to monitor a disease, with a sufficient sensibility and specificity, to define its stage as well as to allow an easy and reproducible screening in the target population, with a low cost.

Serum AFP concentration is the most commonly used marker for HCC. Although several other serologic markers [such as des-gamma-carboxyprothrombin (DCP), glypican 3] may signify the presence of HCC, they are just used in combination with the serum AFP which may improve the diagnostic accuracy. These markers are not common used in alone in routine clinical practice.

2.1.1. Alpha-fetoprotein

However, serum levels of AFP do not correlate always with other clinical features of HCC such as size, stage, or prognosis, and AFP is the most common used marker for HCC. Because of AFP is normally produced during gestation by the fetal liver and yolk sac, the serum concentration of AFP can be increased during pregnancy with tumors of gonadal origin (both germ cell and non-germ cell) and in a variety of other malignancies [9]. Elevated serum AFP can also be seen in patients with chronic liver disease without HCC such as acute or chronic viral hepatitis, particularly in hepatitis C [10].

However, the accuracy of AFP has been critically challenged, and there is growing debate about its continued use in HCC surveillance programs, and AFP appears to be beneficial in clinical practice. In addition, many guidelines including EASL and ASLD no longer recommend measuring AFP level for surveillance of HCC. Only Asian Guideline recommends US and AFP every 6 months. However, a rise in serum AFP in a patient with cirrhosis or hepatitis B alerts the physician on possible HCC development.

In practice, it is generally accepted that serum levels greater than 500 mcg/L (normal in most laboratories is between 10 and 20 mcg/L) in a high-risk patient are diagnostic of HCC [11]. On the other hand, HCC is often diagnosed at a lower AFP level in patients undergoing screening [9] because all tumors do not secrete AFP, and serum concentrations are normal in up to 40% of small HCCs [12]. Elevated serum levels of AFP are commonly associated with HCC causing on advanced-stage fibrosis. Persistently elevated AFP values in a patient with cirrhosis have an increased risk of developing HCC compared with those who have fluctuating or normal levels (29% vs 13 and 2.4%, respectively, in one report) [13].

The sensitivity, specificity, and predictive value for the serum AFP in the diagnosis of HCC is still controversial issue. There is no strict cutoff value. Commonly accepted value is >20 mcg/L and a review which have five studies showed that sensitivity was 41–65% and specificity was 80–94% based upon a cutoff value of >20 mcg/L [14].

An increase in AFP level may be has a greater diagnostic accuracy than one time measurement of AFP whether higher than cutoff value. Using longitudinal AFP measurements could have identified an increase in AFP. Requiring an increase in AFP level of ≥ 2 from its nadir in the prior year maintained high sensitivity of surveillance while increasing specificity. This finding confirms prior studies [15].

Although ASLD and EASL guidelines recommend using US alone to achieve this goal given concerns about the suboptimal sensitivity and specificity of AFP [2, 3], and when AFP used in combination with US, its sensitivity reaches up to 63% for early-stage HCC [16].

Despite the poor reliability and low sensitivity of serum AFP for the diagnosis of HCC, it has emerged as an important prognostic marker, especially in patients undergoing resection and those being considered for liver transplantation. In addition, an increase in AFP is associated with increased tumor size and stage, extrahepatic metastasis, portal vein thrombosis, and decreased survey. Patients with AFP levels >1000 mcg/L have an extremely high risk of recurrent disease following transplantation, irrespective of the tumor size [17, 18].

2.1.2. AFP-L3

AFP-L3 is molecular variant of AFP, in which different isoforms of AFP, which can be identified through electrophoretic techniques relied on specific lectins, have long been reported in the biomedical literature [19]. Because of the limitations of serum AFP measurements, several other molecular variants of AFP, such as AFP-L3, have been evaluated for diagnosis or estimating prognosis in patients with HCC. Lens culinaris agglutinin-reactive AFP (AFP-L3) is a newly developed assay, highly sensitive fraction of AFP (hs-AFP-L3) that has been used as a diagnostic and prognostic marker of HCC. In patients with AFP <20 ng/mL, measurements of AFP-L3% by the highly sensitive method before treatment was more useful for diagnosis and prognosis of HCC than by the conventional method [20].

Furthermore, since hs-AFP-L3% increases before HCC is detectable by various advanced imaging modalities, this assay may help identify benign liver disease patients with a higher risk of HCC [21].

2.1.3. *MicroRNAs*

Recently, miRNAs have been widely reported as a new class of clinical biomarkers and potential therapeutic targets for cancers. Because miRNAs act as key factors in several biological processes, such as growth, cell proliferation, differentiation, apoptosis, and carcinogenesis. HBV- or HCV-related HCC development and progression are associated with a significant and important deregulation of serum/plasma and liver tissues' profiles of miRNAs, as it has been widely reported by several studies. Thus, this evidence makes miRNAs potential and useful biomarkers for diagnosis, staging, progression, prognosis, and response to treatment. Therefore, in the last years, a large series of studies has been performed to investigate the correlation between specific miRNAs levels and/or profiles in body fluids and HCC [22, 23].

miRNAs have some usefulness characteristics, including the possibility to detect these molecules in serum/plasma samples, that may be easily collected, and their high stability, even in conditions that are generally known to induce RNAs degradation, such as fluctuations in temperature and pH levels as well as long-term storage [24, 25]. Although some studies showed that miRNA panels can be used to discriminate HCC patients from cancer-free controls, and could be a blood-based early detection biomarker for HCC screening, and demonstrated as important regulators in HCC pathogenesis, definitive conclusions about relationship between the majority of miRNAs and HCC remain to be explored [26–28].

2.1.4. *Des-gamma-carboxyprothrombin*

DCP, also known as the protein induced by vitamin K absence or antagonist II (PIVKA-II), is an abnormal form of the coagulation protein, prothrombin. The vitamin K-dependent carboxylase responsible for the carboxylation is absent in many HCC cells, and an abnormal prothrombin with all or some of unconverted glutamic acid is secreted. Therefore, this non-carboxylated form (DCP) has been used as an HCC biomarker [29, 30].

The sensitivities for AFP, AFP-L3%, and DCP were 68, 62, and 73%, respectively. When the three markers were combined, the sensitivity was increased to 86%. In another study, DCP levels were shown to correlate with tumor size and metastatic HCC. Several studies that are compared to AFP and DCP had the highest sensitivity (67–63% vs 73–87% for DCP), specificity was the highest in DCP in comparison with AFP (91% vs 78% respectively), and the highest positive predictive value (87%) in patients with HCC [31, 32]. APASL guideline recommends simultaneous measurement of AFP and DCP [4]. In addition, elevated serum DCP is significantly related to portal vein invasion and/or intrahepatic metastasis. It recommends simultaneous measurements of serum alpha-fetoprotein and protein induced by vitamin K absence for detecting hepatocellular carcinoma [31, 32].

DCP can be elevated in other conditions besides HCC. Conditions such as obstructive jaundice, intrahepatic cholestasis causing chronic decrease in vitamin K, and ingestion of drugs such as warfarin or wide-spectrum antibiotics can result in high concentrations of DCP. In addition, 25–50% of patients with HCC will have a DCP value within the reference range. Because of this, a normal DCP value does not rule out HCC.

Simultaneous determinations of AFP and DCP are useful for monitoring recurrence in patients with HCC after treatment, but the decrease to normal levels of a single marker does not always indicate the absence of tumor recurrence [33].

2.1.5. *Glypican-3*

Glypican (GPC) is a family of heparan sulfate proteoglycans that are bound to the cell surface by a lipid anchor. Six members (GPC1~6) of this family have been identified. New finding of recent research is that GPC-3 expression is closely associated with hepatocyte malignant transformation [34] and is a specific oncofetal biomarker for HCC diagnosis [35].

A number of studies showed that a very high specificity (90–100%) associated with serum GPC-3 in patients with HCC, but the sensitivity of serum GPC-3 remained relatively low; however, if GPC-3 measured combined with AFP, sensitivity appears to improve [36, 37].

2.1.6. *Proteomic profiling*

The fields of proteomic-based biomarker discovery have applied advanced tools to identify early changes in protein and metabolite expression in HCC. Although, with robust validation, it is anticipated that from these candidates will rise a high-performance noninvasive test able to diagnose early HCC and related condition, a meta-analysis which is reviewed 22 studies, showed only six assessed the diagnostic performance of the biomarker candidates proposed [38]. Therefore, these biomarkers have not been currently recommended for surveillance or diagnosis.

2.1.7. *Other serum markers*

Other serum markers of HCC that have been studied include the following:

- Tumor-associated isoenzymes of gamma-glutamyl transpeptidase: Isoenzymes were present in 42% of hepatocellular carcinoma patients with a normal serum alpha-fetoprotein concentration and in 50% of those with a non-diagnostic value [39].
- Urinary transforming growth factor beta-1: Transforming Growth Factor (TGF)-beta1 showed a high specificity (99%), but the sensitivity was 53.1%. The determination of both markers TGF-beta1 and AFP in parallel significantly increased the diagnostic accuracy (90.1%) and sensitivity (84%), with a high specificity (98%) and positive likelihood ratio [40].
- Serum alpha-L-fucosidase activity [41].
- Human carboxylesterase 1 [42].
- Acetylcarnitine [43].

2.2. **Imaging studies**

Imaging studies have main role to make a diagnosis of HCC. While Japan, and KLCSSG-NCC guidelines' recommendations are based on serum biomarkers and imaging studies, APASL,

EASL guideline and ASLD guidelines' recommendations are just based on imaging findings for diagnosis of HCC. US, CT, MRI, and angiography are the imaging tests which are most commonly used for the diagnosis of HCC. Basically, a unique dynamic radiological behavior (contrast uptake in the arterial phase and early washout on portal phase or delayed phase by CT, MRI, angiography, or contrast-enhanced US) represented the backbone of radiological diagnosis of early HCC [2–6].

HCC can have a variety of size and appearances on imaging studies; such as small hypo-hyper vascular nodules or massive mass, which may have necrosis, fat and/or calcification, nodular multiple masses of variable attenuation which may also have central necrosis, and infiltrative diffuse lesion [44].

2.2.1. *Ultrasound*

US is the preferred modality for surveillance of HCC in patients with chronic liver disease, and if a lesion is found on US, the lesion/lesions is/are evaluated by advance imaging tests [2–6].

While US has many advantages including low-cost, noninvasive, high availability, and high specificity, it has several disadvantages such as low sensitivity and depending on the operator. Thus, US should be used as a screening test, not as a diagnostic test for HCC. Otherwise, contrast-enhanced ultrasound (CEUS) can be used as a diagnostic test because it is as sensitive as dynamic CT or MRI in the diagnosis of HCC [4].

HCC can be appeared variable imaging structure; mostly small focal HCC appears hypoechoic compared with normal liver, larger lesions which are heterogeneous due to fibrosis, fatty change, necrosis, and calcification [45]. A peripheral halo of hypoechogenicity may be seen with focal fatty sparing, diffuse lesion which may be difficult to identify or distinguish from background cirrhosis [46].

2.2.2. *Computerized tomography*

Accurate technical performance of 4-phase CT scanning with imaging in the hepatic arterial and venous–portal venous, as well as delayed contrast images, is extremely important to characterize the lesions in detecting HCC because there are sequential changes in the supplying vessels and hemodynamic state during hepatocarcinogenesis [47]. If early vascular imaging is not performed, some lesions can be missed. It is important to use high injection rates and appropriate bolus timing. Sensitivity of good-quality 4-phase CT scanning for the detection of patients with tumors is 60–94.4%, in tumor larger than 1 cm, and its sensitivity reduced by 33–45% for detecting tumors smaller than 1 cm [48]. The hallmark of HCC during CT scan is the presence of arterial enhancement followed by washout meaning becoming indistinct or hypoattenuating of the tumor in the portal-venous and/or delayed. The presence of arterial enhancement followed by washout has a sensitivity and specificity of 90 and 95%, respectively [49–52].

Small, arterially enhancing nodules are common in the cirrhotic liver, and majority of these nodules are benign [53, 54]. Thus, every attempt, including imaging follow-up or biopsy, should be made to characterize these nodules [55].

In patients with HCC, unenhanced CT typically shows an isohypodense mass. If the mass is large, central areas of necrosis may be seen that are typically hypodense during this imaging phase.

In the hepatic arterial phase, HCCs typically are hyperdense (relative to hepatic parenchyma) and arteriportal shunt can occur as they are hypervascular tumors. Therefore, wedge-shaped perfusion abnormality due to arteriportal shunts can be seen and can result in a focal fatty change in the normal liver or focal fatty sparing in the diffusely fatty liver [56]. A halo of focal fatty sparing may also be seen around an HCC in an otherwise fatty liver [57].

The portal venous phase coincides with peak parenchymal enhancement is characterized by enhancement of hepatic veins as well as portal veins. In this phase, small lesions may be isodense or hypodense and distinguish from the parenchyma is difficult, as the remainder of the liver increases in attenuation. Larger lesions with necrotic regions remain hypodense [58].

The portal venous and delayed phases can also evaluate nodule diameter, depicting hypovascular nodules including low- or high-grade dysplastic nodules, early HCCs, and well-differentiated HCC. Portal blood flow may be maintained in some cases of dysplastic nodules and early HCC but reduced in other nodules, although the pathology remains because of early HCC, in which arterial blood flow has not yet increased. In addition, these phases can also identify complication of HCC, such as portal venous or hepatic invasion and vascular thrombosis [59]. Moreover, CT can be assessed to establish for other complications such as bleeding and hemoperitoneum.

A vascular mass or a large necrotic mass strongly suggests HCC; however, other hepatic lesions, benign or malignant, can mimic HCC on CT. On the other hand, false-negative CT imaging also can occur. In case of a cirrhotic liver with elevated AFP, and if the diagnosis is not absolute, MRI or other imaging modalities can assist in this differentiation.

2.2.3. *Magnetic resonance imaging*

MRI is the best test for evaluating HCC in patients with liver lesion detected by abnormal US. HCC appearance varies on MRI depending on multiple factors, such as hemorrhage, degree of fibrosis, histologic pattern, degree of necrosis, and the amount of fatty change.

HCC on T1-weighted images may be isointense, hypointense, or hyperintense relative to the liver. On T2-weighted images, HCC is usually hyperintense. Precontrast and postcontrast MRI has a 70–85% chance of detecting a solitary mass of HCC [60]. However, MRI sensitivity is the lowest when evaluating tumors <2 cm in diameter [51].

MRI can help differentiate cirrhotic nodules from HCC: (1) If the mass is bright on T2-weighted images, it is HCC until proven otherwise; (2) if the mass is dark on T1- and T2-weighted images, it is a siderotic regenerative nodule or siderotic dysplastic nodule; (3) if the mass is bright on T1-weighted images and dark or isointense on T2-weighted images, it is a dysplastic nodule or low-grade HCC [61].

Hepatocyte-specific contrast-enhanced MRI including such as gadolinium-enhanced MRI typically demonstrates an increasing number of subcentimetre cirrhotic nodules and that are

often confirmed as HCCs or high-grade dysplastic nodules by these techniques [62]. The diagnosis can be confirmed as HCC nodules if these subcentimetre hypervascular nodules show arterial phase enhancement and “washout”, diffusion restriction or hyperintensity on T2-weighted imaging and hypointensity on the hepatobiliary phase.

However, dysplastic nodules and, less likely, regenerative nodules can show similar enhancement. The degree of enhancement varies, particularly with the degree of necrosis in larger tumors. In addition, a “flash filling” haemangioma can have rapid arterial enhancement but could be differentiated by lack of washout on delayed images. Besides, keep in mind that gadolinium-based contrast agents have been linked to the development of nephrogenic systemic fibrosis or nephrogenic fibrosing dermopathy [63].

Recent studies showed that contrast agents other than gadolinium-based contrast media might demonstrate HCC. Super paramagnetic iron oxide (SPIO) particles used alone or in conjunction with gadolinium-based contrast agents [64] have been shown to be highly sensitive for the detection of HCC, particularly for small tumors. Double-contrast MR imaging (SPIO and gadolinium) is highly sensitive (92%) in the diagnosis of hepatocellular carcinomas of 10 mm or larger, but success in the definition of tumors smaller than 10 mm is still problematic [64, 65]. When uptake by Kupffer cells is reduced in the Kupffer phase of SPIO-enhanced MRI, malignancy should be highly suspected [64, 66].

A recent study showed that dynamic gadobenate dimeglumine (which is hepatocyte selective agent and shows extracellular distribution)-enhanced MRI has a sensitivity of 80–85% and a positive predictive value of 65–66% in the detection of HCC. The technique, however, is of limited value for detecting and characterizing lesions smaller than 1 cm in diameter [67].

The only hepatocyte-selective contrast agent that has been approved for clinical use is mangafodipir trisodium can evaluate questionable lesions in the liver. Mangafodipir trisodium is taken up by normal hepatocytes and masses that contain hepatocytes, causing increased signal intensity on T1-weighted images. This agent may help differentiate a tumor of hepatocellular origin, such as HCC, from secondary hepatic masses [68].

Although MRI is the most useful test to make a diagnosis, the nodules sometimes might not distinguish. In case the nodules have not specific features of HCC and the diagnosis is still unclear, advance imaging modalities or histological examination is needed.

2.2.4. Other imaging modalities

The less invasive imaging studies including dynamic CT, MRI, and CEUS have replaced conventional angiography for the diagnosis of HCC [69]. The role of positron emission tomography (PET) in the diagnostic and staging evaluation of HCC still remains uncertain. Several studies have suggested a role for [18F] fluorodeoxyglucose (FDG)-PET scanning for the detection of primary HCCs, tumor staging, assessing response to therapy, and for predicting prognosis as an adjunct to CT [70, 71]. The sensitivity of PET in diagnosis of HCC was 55% compared with 90% for CT scanning, although only PET detected some tumors (including distant metastases). Well-differentiated and low-grade tumors had lower activity on PET and

correspondingly lower PET scores [71, 72]. However, FDG-PET might be a useful imaging modality for identifying extrahepatic metastases, although sensitivity is limited for lesions 1 cm or smaller [73].

2.3. Pathology

Pathological diagnosis of HCC is recommended for all nodules occurring in non-cirrhotic livers, and for those patients with inconclusive or atypical imaging appearance in cirrhotic livers. While taking a biopsy in lesions 1–2 cm and in lesions >2 cm with atypical vascularization on dynamic imaging was recommended by EASL, ASLD, and Japan guideline, APASL and KLCSSG-NCC guidelines recommend either biopsy or follow-up could be used for indeterminate nodules on imaging workup [2–7].

Sensitivity of liver biopsy depends upon location, size, and expertise and might range between 70 and 90% for all tumor sizes. However, there is no recommendation on prioritizing strategy for indeterminate nodules. The issue is also related to the need of risk stratification of atypical nodules in cirrhosis using ancillary findings. Importantly, “threshold growth” is included as a main diagnostic criterion in LI-RADS and the Organ Procurement and Transplantation Network (OPTN) system introduced by the United Network for Organ Sharing (UNOS). OPTN-UNOS guidelines allow the diagnosis of arterial-phase hyperenhancing HCCs using threshold growth, defined as growth >50% in ≤6 months [74].

Pathological diagnosis is particularly complex for small nodules because minute biopsy specimens may not contain intratumoral portal tracts, thus precluding the detection of stromal invasion. Therefore, core biopsy is commonly used to diagnosis for these small nodules. Core liver biopsy is definitely superior to fine-needle aspiration, because the increased amount of tissue obtained is appropriate for the valuation of both architectural and cytologic features. Furthermore, the tissue block obtained obtains materials for marker studies. Fine-needle aspiration is usually used for the evaluation of large lesions that are likely to be moderately to poorly differentiate [75].

The histologic appearance of HCC can range from well differentiated (with individual hepatocytes appearing nearly identical to normal hepatocytes) to poorly differentiated lesions consisting of large multinucleate anaplastic tumor giant cells. Central necrosis of large tumors is common. Bile globules and acidophilic (hyaline) inclusions are occasionally present.

In some cases, dysplasia rather than carcinoma is diagnosed. There is an ongoing debate about the usefulness of various grades of dysplasia in predicting the ultimate development of HCC in dysplastic nodules.

In case of, the diagnosis is not clearly HCC, and sample should be stained with CD34, CK7, glypican 3, HSP-70, and glutamine synthetase to improve diagnostic accuracy [3]. Additional staining can be considered to detect progenitor cell features (K19 and EpCAM) or assess neovascularization (CD34) [2].

3. Summary

Early diagnosis of HCC is too important because early diagnosis of HCC provides curative treatment of HCC. The risk population for HCC should be determined and these patients should be entered into a surveillance program. When a nodule/nodules detected, convenient test should be used to identify the nodule. Recent guidelines are practical and recommend noninvasive criteria in terms of implementing diagnostic criteria using four-phase CT or contrast-enhanced MRI, and establishing criteria for subcentimetre-sized HCCs. Although there are several remaining issues including diagnostic criteria of non-hypervascular hypointense nodules, almost all suspicious lesion of liver can be defined by serum markers, imaging series, and contribution of biopsy because the characteristics of HCC are sufficiently clear.

Conflict of interest

No conflict of interest was declared by the authors.

Financial disclosure

The authors declared that this study has received no financial support.

Author details

Ayse Kefeli^{1*}, Sebahat Basyigit² and Abdullah Ozgur Yeniova¹

*Address all correspondence to: aysekefeli@hotmail.com

1 Gastroenterology Department, Gaziosmanpasa University, Tokat, Turkey

2 Gastroenterology Department, Artvin State Hospital, Artvin, Turkey

References

- [1] Jemal A, Bray F, Center MM, Ferlay J, Ward E, Forman CA. Global cancer statistics. *Cancer J Clin.* 2011;61(2):69.
- [2] European Association for the Study of the Liver, European Organisation for Research and Treatment of Cancer. EASL-EORTC clinical practice guidelines: management of hepatocellular carcinoma. *J Hepatol.* 2012;56:908–943.

- [3] Bruix J, Sherman M. American Association for the Study of Liver Diseases. Management of hepatocellular carcinoma: an update. *Hepatology*. 2011;53:1020–1022.
- [4] Omata M, Lesmana L, Tateishi R, Chen P, Lin S et al. Asian Pacific Association for the Study of the Liver consensus recommendations on hepatocellular carcinoma. *Hepatol Int*. 2010;4:439–474
- [5] Kudo M, Matsui O, Izumi N, Iijima H, Kadoya M, Imai Y, et al. JSH consensus-based clinical practice guidelines for the management of hepatocellular carcinoma: 2014 update by the Liver Cancer Study Group of Japan. *Liver Cancer*. 2014;3:458–468.
- [6] Korean Liver Cancer Study Group (KLCSG); National Cancer Center, Korea (NCC) 2014 Korean Liver Cancer Study Group-National Cancer Center Korea practice guideline for the management of hepatocellular carcinoma. *Korean J Radiol*. 2015;16:465–522.
- [7] Sangiovanni A, Del Ninno E, Fasani P, De Fazio C, Ronchi G, et al. Increased survival of cirrhotic patients with a hepatocellular carcinoma detected during surveillance. *Gastroenterology*. 2004;126(4):1005–1014.
- [8] American College of Radiology. Liver imaging reporting and data system (LI-RADS). American College of Radiology. [Accessed August 1, 2015]. Web site. <http://www.acr.org/Quality-Safety/Resources/LIRADS> Published May 25, 2014.
- [9] El-Bahrawy M. Alpha-fetoprotein-producing non-germ cell tumours of the female genital tract. *Eur J Cancer*. 2010;46:1317.
- [10] Collier J, Sherman M. Screening for hepatocellular carcinoma. *Hepatology*. 1998;27:273.
- [11] Wu JT. Serum alpha-fetoprotein and its lectin reactivity in liver diseases: a review. *Ann Clin Lab Sci*. 1990;20:98.
- [12] Chen DS, Sung JL, Sheu JC, Lai MY, How SW, et al. Serum alpha-fetoprotein in the early stage of human hepatocellular carcinoma. *Gastroenterology*. 1984;86:1404.
- [13] Colombo M, de Franchis R, Del Ninno E, Sangiovanni A, De Fazio C et al. Hepatocellular carcinoma in Italian patients with cirrhosis. *N Engl J Med*. 1991;325:675.
- [14] Gupta S, Bent S, Kohlwes J. Test characteristics of alpha-fetoprotein for detecting hepatocellular carcinoma in patients with hepatitis C. A systematic review and critical analysis. *Ann Intern Med*. 2003;139:46.
- [15] Lee E1, Edward S, Singal AG, Lavieri MS, Volk M. Improving screening for hepatocellular carcinoma by incorporating data on levels of α -fetoprotein, over time. *Clin Gastroenterol Hepatol*. 2013;11:437–440.
- [16] Mehta A, Singal AG. Hepatocellular carcinoma surveillance: does alpha-fetoprotein have a role? *Gastroenterology*. 2015;149(3):816–8817.

- [17] Ioannou GN, Perkins JD, Carithers RL Jr. Liver transplantation for hepatocellular carcinoma: impact of the MELD allocation system and predictors of survival. *Gastroenterology*. 2008;134:1342.
- [18] Pomfret EA, Washburn K, Wald C, Nalesnik MA, Douglas D et al. Report of a national conference on liver allocation in patients with hepatocellular carcinoma in the United States. *Liver Transpl*. 2010;16:262.
- [19] Mizejewski GJ. Alpha-fetoprotein structure and function: relevance to isoforms, epitopes, and conformational variants. *Exp Biol Med*. 2001;226(5):377–408.
- [20] Toyoda H, Kumada T, Tada T, Kaneoka Y, Maeda A, et al. Clinical utility of highly sensitive *Lens culinaris* agglutinin-reactive alpha-fetoprotein in hepatocellular carcinoma patients with alpha-fetoprotein <20 ng/mL. *Cancer Sci*. 2011;102(5):1025–1031.
- [21] Oda K, Ido A, Tamai T, Matsushita M, Kumagai K, et al. Highly sensitive lens culinaris agglutinin-reactive α -fetoprotein is useful for early detection of hepatocellular carcinoma in patients with chronic liver disease. *Oncol Rep*. 2011;26(5):1227–1233.
- [22] Chen X, Ba Y, Ma L, Cai X, Yin Y, et al. Characterization of microRNAs in serum: a novel class of biomarkers for diagnosis of cancer and other diseases. *Cell Res*. 2008;18(10):997–1006.
- [23] Yu L, Gong X, Sun L, Zhou Q, Lu B, Zhu L. The circular RNA Cdr1as act as an oncogene in hepatocellular carcinoma through targeting miR-7 expression. *PLoS One*. 2016;11(7):e0158347.
- [24] Arroyo JD, Chevillet JR, Kroh EM, Ruf IK, Pritchard CC, et al. Argonaute2 complexes carry a population of circulating microRNAs independent of vesicles in human plasma. *Proc Natl Acad Sci USA*. 2011;108:5003–5008.
- [25] Boeri M, Verri C, Conte D, Roz L, Modena P, et al. MicroRNA signatures in tissues and plasma predict development and prognosis of computed tomography detected lung cancer. *Proc Natl Acad Sci USA*. 2011;108:3713–3718.
- [26] Cho WC. MicroRNAs: potential biomarkers for cancer diagnosis, prognosis and targets for therapy. *Int J Biochem Cell Biol*. 2010;42:1273–1281.
- [27] Wen Y, Han J, Chen J, Dong J, Xia Y, et al. Plasma miRNAs as early biomarkers for detecting hepatocellular carcinoma. *Int J Cancer*. 2015;137(7):1679–1690. doi:10.1002/ijc.29544.
- [28] Khoury S, Tran N. Circulating microRNAs: potential biomarkers for common malignancies. *Biomarkers Med*. 2015;9:131–151.
- [29] Carr B, Kanke F, Wise M, Satomura S. Clinical evaluation of *Lens culinaris* agglutinin-reactive alpha-fetoprotein and des-gamma-carboxyprothrombin in histologically proven hepatocellular carcinoma in the United States. *Dig Dis Sci*. 2007;52:776–778.

- [30] Ishii M, Gama H, Chida N, Ueno Y, Shinzawa H, et al. South Tohoku District Study Group. *Am J Gastroenterol*. 2000;95(4):1036–1040.
- [31] Bertino G, Ardirdi AM, Calvagno GS, Bertino N, Boemi PM. Prognostic and diagnostic value of des-gamma-carboxyprothrombin in liver cancer. *Drug News Perspect*. 2010;23(8):498–508.
- [32] Durazo FA, Blatt LM, Corey WG, Lin JH, Han S, et al. Des-gamma-carboxyprothrombin, alpha-fetoprotein and AFP-L3 in patients with chronic hepatitis, cirrhosis and hepatocellular carcinoma. *J Gastroenterol Hepatol*. 2008;23:1541–1548.
- [33] Aoyagi Y, Oguro M, Yanagi M, Mita Y, Suda T, et al. Clinical significance of simultaneous determinations of alpha-fetoprotein and des-gamma-carboxyprothrombin in monitoring recurrence in patients with hepatocellular carcinoma. *Cancer*. 1996;77(9):1781.
- [34] Yao M, Yao DF, Bian YZ, Zhang CG, Qiu LW, et al. Oncofetal antigen glypican-3 as a promising early diagnostic marker for hepatocellular carcinoma. *Hepatobiliary Pancreat Dis Int*. 2011;10:289–294.
- [35] Li B, Liu H, Shang HW, Li P, Li N, Ding HG. Diagnostic value of glypican-3 in alpha fetoprotein negative hepatocellular carcinoma patients. *Afr Health Sci*. 2013;13:703–709.
- [36] Hippo Y, Watanabe K, Watanabe A, Midorikawa Y, Yamamoto S, et al. Identification of soluble NH2-terminal fragment of glypican-3 as a serological marker for early-stage hepatocellular carcinoma. *Cancer Res*. 2004;64(7):2418–2423.
- [37] Hui Liu, Peng Li, Yun Zhai, Chun-Feng Qu, Li-Jie Zhang, et al. Diagnostic value of glypican-3 in serum and liver for primary hepatocellular carcinoma. *World J Gastroenterol*. 2010;16(35):4410–4415.
- [38] Kimhofer T, Fye H, Taylor-Robinson S, Thursz M, and Holmes E. Proteomic and metabolomic biomarkers for hepatocellular carcinoma: a comprehensive review. *Br J Cancer*. 2015;112(7):1141–1156.
- [39] Kew MC, Wolf P, Whittaker D, Rowe P. Tumour-associated isoenzymes of gamma-glutamyl transferase in the serum of patients with hepatocellular carcinoma. *Br J Cancer*. 1984;50(4):451.
- [40] Tsai JF, Jeng JE, Chuang LY, Yang ML, Ho MS, et al. Clinical evaluation of urinary transforming growth factor-beta1 and serum alpha-fetoprotein as tumour markers of hepatocellular carcinoma. *Br J Cancer*. 1997;75(10):1460.
- [41] Takahashi H, Saibara T, Iwamura S, Tomita A, Maeda T, et al. Serum alpha-L-fucosidase activity and tumor size in hepatocellular carcinoma. *Hepatology*. 1994;19(6):1414.

- [42] Na K, Jeong SK, Lee MJ, Cho SY, Kim SA, et al. Human liver carboxylesterase 1 outperforms alpha-fetoprotein as biomarker to discriminate hepatocellular carcinoma from other liver diseases in Korean patients. *Int J Cancer*. 2013;133(2):408–415.
- [43] Lu Y, Li N, Gao L, Xu YJ, Huang C, et al. Acetylcarnitine is a candidate diagnostic and prognostic biomarker of hepatocellular carcinoma. *Canc Res*. 2016;76(10):2912–2920.
- [44] Reynolds AR, Furlan A, Fetzer DT, asatomi E, Borhani AA, et-al. Infiltrative hepatocellular carcinoma: what radiologists need to know. *Radiographics*. 2015;35(2):371–386.
- [45] Lau WY. *Hepatocellular Carcinoma*. World Scientific Pub Pte Ltd Co Inc., Singapore 596224; 2008. ISBN: 9812707999. P. 193–199
- [46] Malhi H, Grant EG, Duddalwar V. Contrast-enhanced ultrasound of the liver and kidney. *Radiol. Clin. North Am*. 2014;52(6):1177–1190.
- [47] Kim TK, Jang HJ, Wilson SR. Imaging diagnosis of hepato-cellular carcinoma with differentiation from other pathology. *Clin Liver Dis*. 2005;9:253–279.
- [48] Ma Y, Zhang XL, Li XY, Zhang L, Su HH, Zhan CY. Value of computed tomography and magnetic resonance imaging in diagnosis and differential diagnosis of small hepatocellular carcinoma. *Nan Fang Yi Ke Da XueXueBao*. 2008;28(12):2235–2238.
- [49] Marrero JA, Hussain HK, Nghiem HV, Umar R, Fontana RJ, Lok AS. Improving the prediction of hepatocellular carcinoma in cirrhotic patients with an arterially-enhancing liver mass. *Liver Transpl*. 2005;11:281–289.
- [50] Kim SH, Choi BI, Lee JY, Kim SJ, So YH, Eun HW. Diagnostic accuracy of multi-/single-detector CT and contrast- enhanced MRI in the detection of hepatocellular carcinomas meeting the Milan criteria before liver transplantation. *Intervirolgy*. 2008;51(Suppl 1): 52–60.
- [51] Krinsky GA, Lee VS, Theise ND, Weinreb JC, Rofsky NM, et al. Hepatocellular carcinoma and dysplastic nodules in patients with cirrhosis: prospective diagnosis with MR imaging and explantation correlation. *Radiology*. 2001;219:445–454.
- [52] Ebara M, Ohto M, Watanabe Y, Kimura K, Saisho H, et al. Diagnosis of small hepatocellular carcinoma: correlation of MR imaging and tumor histologic studies. *Radiology*. 1986;159:371–377.
- [53] Holland AE, Hecht EM, Hahn WY, Kim DC, Babb JS, et al. Importance of small (B20-mm) enhancing lesions seen only during the hepatic arterial phase at MR imaging of the cirrhotic liver: evaluation and comparison with whole explanted liver. *Radiology*. 2005;237:938–944.
- [54] Baron RL, Peterson MS. From the RSNA refresher courses: screening the cirrhotic liver for hepatocellular carcinoma with CT and MR imaging: opportunities and pitfalls. *Radiographics*. 2001;21:117–132.

- [55] Willatt JM, Hussain HK, Adusumilli S, Marrero JA. MR Imaging of hepatocellular carcinoma in the cirrhotic liver: challenges and controversies. *Radiology*. 2008;247:311–330.
- [56] Choi BI, Lee KH, Han JK, Lee JM. Hepatic arterioportal shunts: dynamic CT and MR features. *Korean J Radiol*. 2002;3(1):1–15.
- [57] Kim KW, Kim MJ, Lee SS, Kim HJ, Shin YM, et-al. Sparing of fatty infiltration around focal hepatic lesions in patients with hepatic steatosis: sonographic appearance with CT and MRI correlation. *AJR Am J Roentgenol*. 2008;190(4):1018–1027.
- [58] Hong HS, Kim HS, Kim MJ, De Becker J, Mitchell DG, Kanematsu M. Single breath-hold multiarterial dynamic MRI of the liver at 3T using a 3D fat-suppressed keyhole technique. *J Magn Reson Imaging*. 2008;28(2):396–402.
- [59] Takayasu K, Furukawa H, Wakao F, Muramatsu Y, Abe H et al. CT diagnosis of early hepatocellular carcinoma: sensitivity, findings, and CT-pathologic correlation. *AJR Am J Roentgenol*. 1995;164(4):885–890.
- [60] Bialecki ES, Di Bisceglie AM. Diagnosis of hepatocellular carcinoma. *HPB (Oxford)*. 2005;7(1):26–34.
- [61] Hanna RF, Aguirre DA, Kased N, Emery SC, Peterson MR, Sirlin CB. Cirrhosis-associated hepatocellular nodules: correlation of histopathologic and MR imaging features. *RadioGraphics*. 2008;28(3):747–769.
- [62] Golfieri R, Grazioli L, Orlando E, Dormi A, Lucidi V, et al. Which is the best MRI marker of malignancy for atypical cirrhotic nodules: hypointensity in hepatobiliary phase alone or combined with other features? Classification after Gd-EOB-DTPA administration. *J Magn Reson Imaging*. 2012;36:648–657.
- [63] Marckmann P, Skov L, Rossen K, Dupont A, Damholt MB, et al. Nephrogenic systemic fibrosis: suspected causative role of gadodiamide used for contrast-enhanced magnetic resonance imaging. *J Am SocNephrol*. 2006;17(9):2359–2362.
- [64] Bhartia B, Ward J, Guthrie JA, Robinson PJ. Hepatocellular carcinoma in cirrhotic livers: double-contrast thin-section MR imaging with pathologic correlation of explanted tissue. *AJR Am J Roentgenol*. 2003;180:577–584.
- [65] Ward J, Guthrie JA, Scott DJ, Atchley J, Wilson D, et al. Hepatocellular carcinoma in the cirrhotic liver: double- contrast MR imaging for diagnosis. *Radiology*. 2000;216:154–162.
- [66] Imai Y, Murakami T, Yoshida S, Nishikawa M, Ohsawa M, et al. Super paramagnetic iron oxide-enhanced magnetic resonance images of hepatocellular carcinoma: correlation with histological grading. *Hepatology*. 2000;32:205–212.

- [67] Choi SH, Lee JM, Yu NC, Suh KS, Jang JJ, et al. Hepatocellular carcinoma in liver transplantation candidates: detection with gadobenate dimeglumine-enhanced MRI. *AJR Am J Roentgenol*. 2008;191:529–536.
- [68] Semelka RC, Helmberger TK. Contrast agents for MR imaging of the liver. *Radiology*. 2001;218:27–38.
- [69] Kanematsu M, Hoshi H, Imaeda T, Murakami T, Inaba Y, et al. Detection and characterization of hepatic tumors: value of combined helical CT hepatic arteriography and CT during arterial portography. *AJR Am J Roentgenol*. 1997;168:1193–1198.
- [70] Yang SH, Suh KS, Lee HW, Cho EH, Cho JY, et al. The role of (18)F-FDG-PET imaging for the selection of liver transplantation candidates among hepatocellular carcinoma patients. *Liver Transpl*. 2006;12:1655–1660.
- [71] Khan MA, Combs CS, Brunt EM, Lowe VJ, Wolverson MK, et al. Positron emission tomography scanning in the evaluation of hepatocellular carcinoma. *J Hepatol*. 2000;32:792–797.
- [72] Trojan J, Schroeder O, Raedle J, Baum RP, Herrmann G, et al. Fluorine-18 FDG positron emission tomography for imaging of hepatocellular carcinoma. *Am J Gastroenterol*. 1999;94:3314–3319.
- [73] Sugiyama M, Sakahara H, Torizuka T, Kanno T, Nakamura F, et al. 18F-FDG PET in the detection of extra- hepatic metastases from hepatocellular carcinoma. *J Gastroenterol*. 2004;39:961–968.
- [74] Wald C, Russo MW, Heimbach JK, Hussain HK, Pomfret EA, Bruix J. New OPTN/UNOS policy for liver transplant allocation: standardization of liver imaging, diagnosis, classification, and reporting of hepatocellular carcinoma. *Radiology*. 2013;266:376–382.
- [75] International Consensus Group for Hepatocellular Neoplasia. Pathologic diagnosis of early hepatocellular carcinoma: a report of the international consensus group for hepatocellular neoplasia. *Hepatol*. 2009;49:658–664.