

We are IntechOpen, the world's leading publisher of Open Access books Built by scientists, for scientists

6,900

Open access books available

186,000

International authors and editors

200M

Downloads

Our authors are among the

154

Countries delivered to

TOP 1%

most cited scientists

12.2%

Contributors from top 500 universities



WEB OF SCIENCE™

Selection of our books indexed in the Book Citation Index
in Web of Science™ Core Collection (BKCI)

Interested in publishing with us?
Contact book.department@intechopen.com

Numbers displayed above are based on latest data collected.
For more information visit www.intechopen.com



The Role of EUS in Pancreatic Cysts

Amir Houshang Mohammad Alizadeh

Additional information is available at the end of the chapter

<http://dx.doi.org/10.5772/65126>

Abstract

Pancreatic cystic lesions (PCLs) comprise various pathologically different groups of lesions that usually share many common clinical features. Cystic lesions and fluid collections of the pancreas often present a diagnostic and therapeutic challenge. Pancreatic cystic lesions are being diagnosed with increasing frequency owing to the widespread use of cross-sectional imaging. The differential diagnosis for cystic lesions of the pancreas is broad, and the role of endoscopic ultrasonography (EUS) is becoming more clearly defined. EUS has become an important tool in the diagnosis and risk stratification of pancreatic cysts. The ability of EUS to provide detailed imaging, tissue, and cyst fluid for analysis makes it a seemingly powerful diagnostic tool for PCLs. It can accurately visualize the cyst morphology, assess vascular pattern by contrast harmonic scan, and perform fine-needle aspiration (FNA) for evaluation of cytology and molecular markers. Furthermore, several studies have shown the therapeutic applications of endoscopic ultrasound in management of PCLs, including EUS-guided ablation of cystic pancreatic tumors by injection of alcohol, aiding in pancreatic pseudocyst drainage.

Keywords: pancreatic cysts, EUS, IPMN, mucinous cytadenoma, serous cystadenoma

1. Introduction

Pancreatic cystic lesions (PCLs) are being diagnosed with increasing frequency, including a wide spectrum from benign to malignant and invasive lesions. The most commonly observed PCL types include intraductal papillary mucinous neoplasms (IPMN), mucinous cystic neoplasms (MCN), serous cystic neoplasms (SCN), and pseudocysts (PC) [1, 2]. Differentiation of neoplastic mucinous from non-mucinous cysts that are managed quite differently is important. If non-mucinous pancreatic lesions such as inflammatory pseudocysts and neoplastic lesions are

accurately characterized, most does not require resection or long-term follow-up. Mucinous neoplasms have a known pre-malignant potential and, therefore, are either resected or monitored in a surveillance program [3, 4].

Preoperative diagnosis of PCLs must be reliable as the current standard treatment, major or total pancreatectomy, dramatically affects quality of life. Additionally, early diagnosis of malignancy is essential to an improved prognosis. Despite being the most common modality to identify cystic pancreatic lesions, cross-sectional imaging plays a variable role in characterizing these lesions. Endoscopic ultrasonography (EUS) has become an important tool in the diagnosis and risk stratification of pancreatic cysts [5–7].

EUS was first introduced by Dr. Eugene DiMagno in the 1980s by combining a high frequency ultrasound transducer to an endoscope. In 1991, convex linear-array echoendoscope was introduced by Pentax. These linear scopes scan parallel to the longitudinal axis of the scope and enable fine-needle aspiration (FNA) and different therapeutic applications. EUS provides real-time high-resolution images of cystic pancreatic lesions with morphological details [6, 8]. The combination of fine-needle aspiration (FNA) cytology with the other recently available diagnostic markers has further increased its diagnostic accuracy. The current diagnostic evaluation of PCL often includes EUS-guided fine-needle aspiration (EUS-FNA) for cyst fluid analysis. In addition to the role of EUS in the differential diagnosis of pancreatic cystic lesions, EUS-FNA is also important in management of cystic tumors of the pancreas [9, 10].

2. Diagnostic role of EUS

The critical issue being faced in routine clinical practice is accurate preoperative characterization of cystic lesions. Histology remains the gold standard but requires resection. Since that is impractical for most low risk lesions, imaging provides indirect evidence of morphology. Pancreatic cysts can be diagnosed and assessed by using computer tomography (CT) and magnetic resonance (MR), but these imaging modalities have been inconsistent in differentiating them [3, 11]. CT scan, MRI, and MRCP are generally considered safe and reliable in providing follow-up data on cyst and pancreatic duct size but are less sensitive in detecting intra-mural nodules, which are better evaluated by EUS-FNA [6, 12]. The accuracy of MRI and CT to make a specific diagnosis is suboptimal, with reports of 39–50 and 40–44%, respectively. Efforts to differentiate pancreatic cystic lesions from imaging tests have met with mixed success, with up to 40% of neoplastic cysts misdiagnosed as pseudocyst [3, 7]. EUS, particularly as a means of EUS-guided cyst aspiration, has become an important tool in the diagnosis and risk stratification of pancreatic cysts. The diagnostic accuracy of EUS for identification of malignant or pre-malignant pancreatic cysts reaches 95%, although this method has significant limitations for the differential diagnosis of benign and malignant cysts with overall accuracy rates of 40–93% [7, 11].

The goal in assessing pancreatic cysts by EUS is to avoid characterizing a mucinous cyst as a benign serous cyst and erroneously opting for simple observation instead of potentially curable surgical resection. Endoscopic ultrasound is increasingly used for the differential diagnosis of

pancreatic cystic lesions either alone or in combination with fine-needle aspiration. EUS allows close and high-resolution imaging of cystic pancreatic lesion morphology. The appearances of the cyst wall, the presence of septate or solid components, the number of cysts, and concomitant lymphadenopathy have been used to distinguish between benign and malignant cystic lesions [6, 13]. EUS-FNA has the added advantage of allowing aspiration of the cyst contents and sampling of the cyst wall or septa, as well as mural nodules. Cyst fluid aspiration can be more studied to analyze cytology, tumor markers, enzymes, as well as DNA analysis of DNA quality/content or mutational analysis [9, 14].

2.1. EUS morphology

Some PCLs have a very typical morphology and may thus be easily diagnosed by imaging. Diagnosis based on the findings of EUS requires attention to the number and size of cysts, shapes of whole cysts, state of the cyst wall, internal state of the cysts, communication between the pancreatic duct and the cyst, and existence of any background lesions (**Table 1**). It is generally believed that a differential diagnosis is practicable partly by collating these findings with the above features of the various pancreatic cystic lesions [15, 16].

Cyst type	Location	Morphology/EUS findings	Fluid color and viscosity	Cytology	CEA ¹	Amylase
Mucinous cystadenoma	Body/tail more than head	Macrocytic, occasionally septated; peripheral calcifications, soli components and regional adenopathy when malignant	Colorless, thick fluid	Extracellular mucin. Mucinous epithelial cells may be seen in a background of ovarian stroma	Moderate to very high	Variable
IPMN ²	Main duct or side branch; head more than body and tail	Dilated main pancreatic duct or side branches; may appear as a septated cyst; may have a solid component	Colorless, thick fluid	Extracellular mucin. Mucinous epithelial cells may be seen with papillary projections and variable atypia	Moderate to very high	Elevated
Serous cystadenoma	Body/tail more than head	Microcystic with a honeycomb appearance; rarely has a macrocystic component; central calcification	Colorless, often contain blood	Typically acellular. Small glycogen staining cuboidal cells in the background may be seen	Undetectable to low	Low
Pseudocyst	Anywhere	Anechoic, thick-walled, rare septations, regional inflammatory nodes may be seen	Yellow to brown thin fluid	Macrophages with no mucin. Mixed inflammatory infiltrate may be seen	Low to at least increase	Elevated

¹Carcinoembryonic antigen.

²Intraductal papillary mucinous neoplasm.

Table 1. Characteristics of cyst fluid in the main types of cystic pancreatic lesions [2, 6].

Several EUS findings have been evaluated to diagnose pancreatic cystic lesions. Studies have shown that small cyst size does not exclude malignancy. Some features do appear to be more

predictive in diagnosing specific types of cystic lesions. The existence of multiple small compartments (<3 mm) within a cystic lesion (also called a microcystic lesion) is indicative of a serous cystic neoplasm, with an accuracy of 92–96%, and this feature is not seen in mucinous cystadenomas. A cystic lesion without septations or solid components and seen within a pancreas having parenchymal features suggestive of a pseudocyst with sensitivity and specificity of 94 and 85%, respectively. However, EUS morphology alone does not appear to be very reliable to establish a specific diagnosis or to differentiate between benign and malignant diseases (**Figures 1 and 2**) [2, 6, 7].

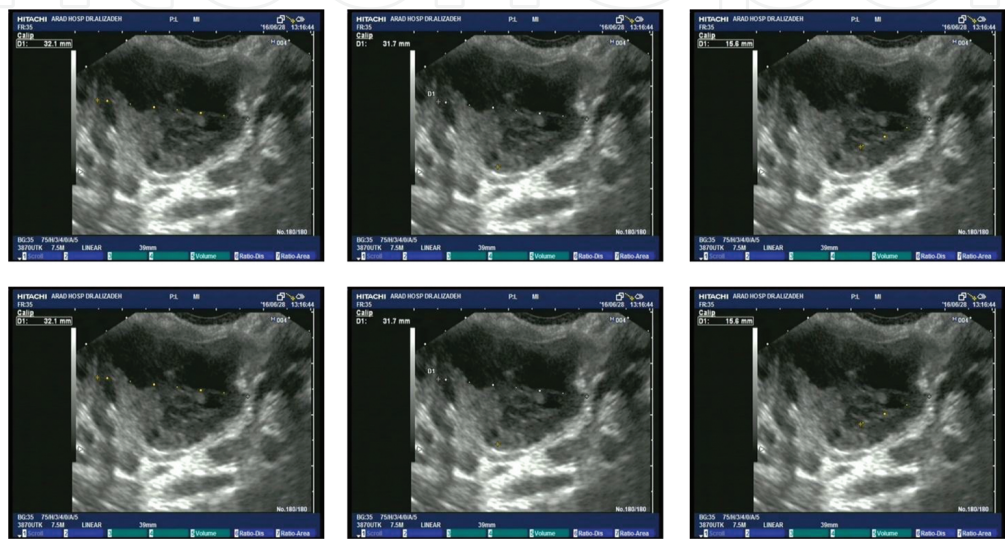


Figure 1. Main-duct intraductal papillary mucinous neoplasm (MD-IPMN): thick wall with mural nodules—by Prof. Alizadeh.

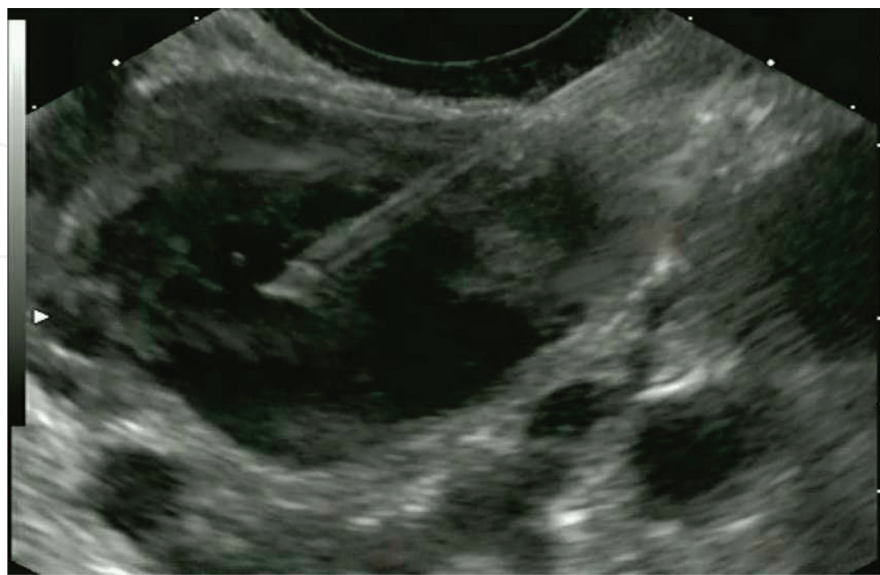


Figure 2. Cyst fluid evaluation-EUS/FNA—by Prof. Alizadeh.

2.2. Cyst fluid evaluation

EUS-FNA allows aspiration of the cyst contents and plays an important role in differential diagnosis of doubtful cases of pancreatic cysts. Cyst fluid analysis is useful in differential diagnosis between mucinous and non-mucinous pancreatic cystic tumors. Cystic fluid aspirate is acellular or with minimal cellularity in up to 72% of aspirated cysts. Cyst fluid can be studied after aspiration to analyze cytology, viscosity, extracellular mucin, tumor markers (CEA, CA 19-9, CA 153, CA 72-4, etc.), enzymes (amylase, lipase), and DNA analysis. Analysis of cystic fluid aspirate can be used to differentiate mucinous from non-mucinous cysts with a sensitivity, specificity, and accuracy of 12.5–27, 90–100, and 55%, respectively [7, 17].

2.2.1. EUS-FNA with cyst fluid cytology

Due to the shortcomings of EUS alone, the use of EUS-FNA has been extensively evaluated for fluid analysis and cytology of pancreatic cystic lesions. EUS-FNA cytology provides excellent specificity (more than 90%) for the diagnosis of cystic pancreatic lesions. However, the sensitivity of EUS-FNA remains widely variable with most studies reporting sensitivity under 50% [6, 7].

EUS-FNA can provide material for a cytologic diagnosis in up to 80% of cases of pancreatic cystic lesions. Viscosity is usually lower in pseudocysts and serous cystadenomas when compared with mucinous cystadenoma and mucinous cystadenocarcinoma. Furthermore, the presence of extracellular mucin in aspirated cyst fluid is moderately predictive of a mucinous neoplasm. Findings suggestive of a pseudocyst include macrophages, histiocytes, and neutrophils. The presence of mucin indicates a mucinous neoplasm and is seen in 35% or more of cases. FNA from a minority of serous cystadenoma may reveal the presence of glycogen-rich cuboidal cells (**Table 1**) [2, 11, 18].

2.2.2. Cystic fluid analysis and tumor markers

Because of the limited sensitivity of cytology, cyst fluid may be analyzed for levels of amylase, lipase, and tumor markers, such as carcinoembryonic antigen (CEA) and carbohydrate antigen (CA) 19-9. Early studies in the 1980s suggested the role of CEA and CA 19-9 in the differentiation of pancreatic cystic lesions [9, 18].

Cyst fluid contains glycoproteins, such as CEA, CA 19-9, CA 125, CA 15-3, and CA 72-4, which are secreted from the epithelial lining. CEA is currently considered the most reliable for the diagnosis of mucinous cystic pancreatic lesions. This marker is typically elevated in mucinous lesions but is lower in pseudocysts and non-mucinous tumors [6, 7]. CA 19-9 also has wide overlapping of results with pseudocysts and serous cystadenomas. Furthermore, other markers such as amylase and lipase may be important in the evaluation of cystic pancreatic lesions. Amylase is useful in the differentiation of pseudocysts from cystic neoplasm and usually elevated not only in inflammatory cysts like pseudocysts but also in mucinous neoplasm due to communication with the pancreatic duct (**Table 2**) [6, 9, 13].

Cyst	Viscosity	Amylase	CA 72-4	CEA	CA 15-3	CA 19-9
Pseudocyst	Low	High	Low	Low	Low	Low
Serous cystadenoma	Low	Variable	Low	Low	Low	Low
Mucinous cystadenoma	Often high	Variable	Low	High	High	High
Mucinous cystadenocarcinoma	High	Variable	High	High	High	High

Table 2. Cyst fluid analysis for differentiation of pancreatic cystic lesions [19].

2.2.3. Cystic fluid analysis and genetic markers

Another differential diagnosis of pancreatic cystic lesions is DNA and mutational analysis in the cystic fluid aspirated by EUS-FNA. Molecular analysis of pancreatic cyst aspirated fluid may be helpful in predicting malignancy. The detection of loss of heterozygosity (LOH) by using microsatellite markers closely linked to key tumor suppressor genes can serve as a surrogate marker for gene inactivation and mutation [11, 18].

Molecular markers are greatly sought as a more reliable alternative diagnostic marker for many malignancies, due to the revolution in translational science. Specific genetic markers are increasingly identified and used to measure the risk of malignancy in pancreatic cystic lesions. It is believed that IPMNs should follow a transformation process similar to the adenoma-carcinoma sequence in colon cancer, where hyperplastic lesions progress to dysplastic and carcinoma cells. Recently, the oncogene GNAS was detected in IPMN tissue. Some reports have indicated that GNAS mutations are prevalent especially in the intestinal and invasive form of IPMN. Furthermore, mutations in *K-ras*, *p16*, and *p53* have been reported in associated with progression of cystic pancreatic lesion from non-dysplastic to dysplastic cysts [6, 7, 18].

3. Therapeutic role of EUS

Management of incidentally detected pancreatic cysts with malignant potential is a common clinical challenge. Surgical resection is the treatment of choice for most suspicious cystic lesions of the pancreas [12, 19]. Surgical resection of pancreatic cyst is associated with a perioperative morbidity rate of 20–40% and a mortality rate of 2%. EUS can be used to mark the optimal puncture site or to perform EUS-guided cyst puncture and drainage. Moreover, EUS-guided anti-tumor therapy may be applied to cystic pancreatic tumors, and early results of EUS-guided alcohol injection into pancreatic cystic tumors were recently reported [2, 10, 19].

3.1. Endoscopic drainage

A pancreatic pseudocyst is the most common cystic lesion of the pancreas. Pseudocysts should be drained when symptomatic, progressively enlarging, or infected. Pseudocysts have been drained through stenting of the pancreatic duct (transpapillary drainage) or stenting of a drainage tract created between the pseudocyst and the gastroduodenal lumen (transmural drainage). Drainage can be achieved through endoscopic, radiologic, or surgical techniques. Endoscopic drainage of pancreatic pseudocysts is less invasive than surgery [14, 20].

Endoscopic methods for pancreatic pseudocyst drainage are associated with low mortality and acceptable success rates. EUS-guided drainage is associated with a low rate of complications. Prior to the availability of EUS, transmural endoscopic cyst drainage was reliant on a combination of radiologic imaging to ensure a distance of less than 10 mm between gastrointestinal lumen and cyst. Endoscopic drainage may be performed as so-called single-step endo-ultrasonography (EUS)-guided and two-(multi)-step EUS-guided drainage techniques [14, 17]. EUS has the theoretical advantage of reducing the risks of bleeding, perforation, and, potentially, infection. Furthermore, this technique can provide important information in aiding pancreatic pseudocyst drainage. It allows accurate measurement of the distance between the gut lumen and the cystic cavity of the pseudocyst. EUS is helpful in identifying debris within a pseudocyst, which may not be drainable and which may increase the risk of infection [21, 22].

3.2. EUS-guided pancreatic cyst ablation

EUS-guided pancreatic cyst ablation is practically an alternative treatment in selected patients who are not candidates for or who refuse surgery. Based on the accumulated experiences of endoscopic ultrasonography-guided fine-needle aspiration (EUS-FNA), EUS-guided pancreatic tissue ablation with ethanol or other ablative agents was performed safely, with few procedure-related complications [12, 23]. Complications of cyst ablation were reported as rare and mild. The most common acute complication was abdominal pain after cyst ablation (7.9%) and acute pancreatitis developed in 2%. Although a novel technique such as radiofrequency ablation was recently reported, it is still unclear whether or not cyst ablation is justified. Safety, efficacy, and cost-effectiveness of EUS-guided pancreatic cyst ablation should be further validated [7, 24].

To date, ethanol (80–99%) and paclitaxel have been investigated as ablative agents in pancreatic cysts. A commonly used ablative agent is ethanol owing to its cost-effectiveness, ready availability, and rapid ablative effect. The low viscosity of ethanol permits repeated filling and emptying of the cyst [7, 23].

Ablation of the epithelial lining of a pancreatic cystic neoplasm has been proposed as a way to reduce or eliminate malignant or metastatic potential in benign and malignant lesions, respectively. Ethanol lavage of MCN and IPMN cystic lesions by using EUS guidance appears to be safe, but its efficacy has not yet been determined. The mechanisms involved in destruction of cyst epithelium include cell membrane lysis, rapid protein precipitation, and vascular occlusion. Treatment response is further supported by adding a chemotherapeutic agent (most commonly paclitaxel), which acts as an inhibitor of the disassembly process of microtubules during cell division and subsequently inducing apoptosis [18, 25].

4. Conclusion

Pancreatic cystic lesions (PCLs) comprise a diverse group of histopathologic bodies possessing varying degrees of malignancy. PCLs range from benign abnormalities needing minimal follow-up to pre-malignant or malignant lesions requiring careful monitoring or resection. The

diagnosis and management of pancreatic cystic lesions are a common problem. EUS and EUS-guided fine-needle aspiration (FNA) can play an important role in the differential diagnosis of pancreatic cystic lesions and decision about referral for possible surgery by evaluating cytology and tumor markers. There is some emerging evidence that EUS-guided pancreatic cyst ablation by injection of alcohol can help to treatment of the cystic pancreatic tumors. Furthermore, EUS can provide important information in aiding pancreatic pseudocyst drainage.

Author details

Amir Houshang Mohammad Alizadeh*

Address all correspondence to: ahmaliver@yahoo.com

Endoscopy Department, Research Center for Gastroenterology and Liver Diseases, Taleghani Hospital, Shahid Beheshti University of Medical Sciences, Evin, Tehran, Iran

References

- [1] Barresi L, Tarantino I, Granata A, Curcio G, Traina M. Pancreatic cystic lesions: How endoscopic ultrasound morphology and endoscopic ultrasound fine-needle aspiration help unlock the diagnostic puzzle. *World Journal of Gastrointestinal Endoscopy*. 2012;4(6):247-59.
- [2] Jacobson BC, Baron TH, Adler DG, Davila RE, Egan J, Hirota WK, et al. ASGE guideline: The role of endoscopy in the diagnosis and the management of cystic lesions and inflammatory fluid collections of the pancreas. *Gastrointestinal Endoscopy*. 2005;61(3): 363-70.
- [3] Kwon RS, Scheiman JM. EUS and pancreatic cyst fluid analysis: Is the juice worth the aqueeze? *Journal of Gastrointestinal Oncology*. 2011;2(4):199.
- [4] Thiruvengadam N, Park WG. Systematic review of pancreatic cyst fluid biomarkers: The path forward. *Clinical and Translational Gastroenterology*. 2015;6(6):e88.
- [5] Wang Q-X, Xiao J, Orange M, Zhang H, Zhu Y-Q. EUS-guided FNA for diagnosis of pancreatic cystic lesions: A meta-analysis. *Cellular Physiology and Biochemistry*. 2015;36(3):1197-209.
- [6] Al-Haddad M, El Hajj II, Eloubeidi MA. Endoscopic ultrasound for the evaluation of cystic lesions of the pancreas. *Journal of the Pancreas*. 2010;11(4):299-309.
- [7] Kelvin YMC, Park J-S, Seo D-W. Role of endosonography in the management of incidental pancreatic cystic lesions. *Gastrointestinal Intervention*. 2014;3(1):40-5.

- [8] Iqbal S, Friedel D, Gupta M, Ogden L, Stavropoulos SN. Endoscopic-ultrasound-guided fine-needle aspiration and the role of the cytopathologist in solid pancreatic lesion diagnosis. *Pathology Research International*. 2012;2012.
- [9] Rockacya M, Khalida A. Update on pancreatic cyst fluid analysis. *Annals of Gastroenterology*. 2012;26:1-6.
- [10] Bhutani MS. Role of endoscopic ultrasonography in the diagnosis and treatment of cystic tumors of the pancreas. *Journal of the Pancreas*. 2004;5(4):266-72.
- [11] Snow P. Pancreatic cyst fluid analysis – A review. *Journal of Gastrointestinal and Liver Diseases*. 2011;20(2):175-80.
- [12] Oh HC, Seo DW. Endoscopic ultrasonography-guided pancreatic cyst ablation (with video). *Journal of Hepato-Biliary-Pancreatic Sciences*. 2015;22(1):16-9.
- [13] Sand J, Nordback I. The differentiation between pancreatic neoplastic cysts and pancreatic pseudocyst. *Scandinavian Journal of Surgery*. 2005;94(2):161-4.
- [14] Breslin N, Wallace MB. Diagnosis and fine-needle aspiration of pancreatic pseudocysts: The role of endoscopic ultrasound. *Gastrointestinal Endoscopy Clinics of North America*. 2002;12(4):781-90.
- [15] Okabe Y, Kaji R, Ishida Y, Tsuruta O, Sata M. The management of the pancreatic cystic neoplasm: The role of the EUS in Japan. *Digestive Endoscopy*. 2011;23(s1):39-42.
- [16] Jenssen C, Kahl S. Management of incidental pancreatic cystic lesions. *Viszeralmedizin*. 2015;31(1):14-24.
- [17] Jabłońska B. Pancreatic cysts: Etiology, diagnosis and management. *Central European Journal of Medicine*. 2014;9(1):92-107.
- [18] Khalid A, Brugge W. ACG practice guidelines for the diagnosis and management of neoplastic pancreatic cysts. *The American Journal of Gastroenterology*. 2007;102(10):2339-49.
- [19] Van Dam J. EUS in cystic lesions of the pancreas. *Gastrointestinal Endoscopy*. 2002;56(4):S91-S3.
- [20] Buscail L, Faure P, Bournet B, Selves J, Escourrou J. Interventional endoscopic ultrasound in pancreatic diseases. *Pancreatology*. 2006;6(1-2):7-16.
- [21] Fazel A, Draganov P. Interventional endoscopic ultrasound in pancreatic disease. *Current Gastroenterology Reports*. 2004;6(2):104-10.
- [22] Raj M, Chen RY. Interventional applications of endoscopic ultrasound. *Journal of Gastroenterology and Hepatology*. 2006;21(2):348-57.
- [23] Cho M-K, Choi J-H, Seo D-W. Endoscopic ultrasound-guided ablation therapy for pancreatic cysts. *Endoscopic Ultrasound*. 2015;4(4):293.

- [24] Nakai Y, Isayama H, Itoi T, Yamamoto N, Kogure H, Sasaki T, et al. Role of endoscopic ultrasonography in pancreatic cystic neoplasms: Where do we stand and where will we go? *Digestive Endoscopy*. 2014;26(2):135-43.
- [25] Zhang W-Y, Li Z-S, Jin Z-D. Endoscopic ultrasound-guided ethanol ablation therapy for tumors. *World Journal of Gastroenterology*. 2013;19(22):3397-403.

IntechOpen

IntechOpen