

We are IntechOpen, the world's leading publisher of Open Access books Built by scientists, for scientists

6,900

Open access books available

185,000

International authors and editors

200M

Downloads

Our authors are among the

154

Countries delivered to

TOP 1%

most cited scientists

12.2%

Contributors from top 500 universities



WEB OF SCIENCE™

Selection of our books indexed in the Book Citation Index
in Web of Science™ Core Collection (BKCI)

Interested in publishing with us?
Contact book.department@intechopen.com

Numbers displayed above are based on latest data collected.
For more information visit www.intechopen.com



Laser-Assisted Liposuction in Body Contouring

Zoran Žgaljardić and Ivonne Žgaljardić

Additional information is available at the end of the chapter

<http://dx.doi.org/10.5772/64841>

Abstract

Laser liposuction was initially developed as a technique for laser lipolysis. In 1992, Apfelberg was the first to describe the direct action of laser in the adipose tissue. Initially, the technique was developed only for lipolysis of unwanted fat in a small region without suction of dissolved fat. Later, it evolved as laser-assisted liposuction, which is a technique that combines adipocyte disruption with laser beam and suction of the dissolved fat from the treated area with different types of cannulas. The neodymium-doped yttrium aluminum garnet (Nd:YAG) 1064 nm has been introduced as first laser for lipolysis. Blugerman, Schavelzon, and Goldman introduced the concept of the pulsed 1064-nm Nd:YAG system for laser lipolysis. They proved the effect of the laser energy on fatty tissue as well as the on surrounding tissues (dermis, vasculature, apocrine, and eccrine gland). After tissue damage with photo-optical thermal energy, the following histological changes have been noted: (1) adipocyte cells have been disrupted, (2) blood vessels have been coagulated, (3) new collagen has been induced. All those histological changes induce better clinical outcome such as less ecchymosis, less bleeding, smoother, and firmer skin as result of new collagen formation followed by skin retraction. Laser liposuction was developed as a minimally invasive liposuction technique, where energy breaks adipocytes (comparing with traditional liposuction, in which disruption is manual). Wave length of 1064 nm has hemoglobin as a target for its photo-optical energy, and new wave length of 1470 nm has water molecules (H₂O) as a target. Infiltration of the Klein's solution helps laser to dissolving of fatty tissue faster and more energy to accumulate, followed by new collagen formation. Laser-assisted liposuction in all types of lipodystrophies and cellulite can be successfully applied. High definition of the body is a result of the energy as well as the technique of liposuction. Laser liposuction can be applied on the face for fat removal and as a part of face lifting or better to say endolight lifting. Today, we have lot of companies that have developed different liposuction lasers (Nd:YAG; diode) with different wave lengths.

Keywords: laser, liposuction, lipolysis, skin tightening, high-definition

1. Introduction

According to the statistics of the American Society for Aesthetic Plastic Surgery (ASAPS) for 2014, liposuction has been most commonly performed cosmetic surgical procedure [1]. The technique of fat removal using a curette subcutaneously connected to a suction device was created in the 1970 and 1980. Various surgeons concurrently were performing the similar method, but the Italian gynecologist Giorgio Fischer in 1974 presented a prototype machine [2, 3]. Illouz introduced the liposuction technique in 1982 at the Annual Meeting of the American Society of Plastic and Reconstructive Surgeons [4]. Since then, there have been various attempts in improving this technique. With the progress of technology, various methods have been described in addition to traditional suction-assisted liposuction in order to improve the final cosmetic result and diminish complications.

In this chapter, we describe the use of laser energy in traditional suction-assisted liposuction and body contouring.

2. Laser

A laser is a device that emits light through a process of optical amplification based on the stimulated emission of electromagnetic radiation. The term “laser” originated as an acronym for “light amplification by stimulated emission of radiation” [5, 6]. Theodore H. Maiman in 1960 produced the first laser using ruby as a medium that was stimulated using high energy flashes of intense light. Laser light is monochromatic, bright, unidirectional, and coherent [7].

3. Laser-assisted liposuction—history overview

Dr. Leon Goldman is called the father of laser medicine. He was the first to introduce lasers in medicine shortly after the first laser was invented. In 1963, he published first scientific article on the pathology of the effect of the laser beam on the skin [8]. Hukki et al. were first to describe the tissue effects of different Nd:YAG contact laser scalpels on pig skin and subcutaneous fat in 1988 [9]. Dressel was first to perform laser lipolysis procedure in 1990 on a 34-year-old man with abdominal adiposity [10]. Formally, laser-assisted liposuction was first introduced by Apfelberg in 1992 when he described direct action of laser in the fat tissue [11]. In 1994, Apfelberg et al. performed FDA-approved study on fifty-one patients in five plastic surgery centers. Nd: YAG (neodymium-doped yttrium aluminum garnet) laser was used. The 600 μm fiber was enclosed in 4 or 6 mm cannula. The energy used was 40 W. Pulse duration was 0.2 s. The laser fiber was not in direct contact with the tissue [12]. The study showed slight benefit for ecchymosis, pain and discomfort, and edema, but it was not enough for the FDA to approve the technology so in that time, it was abandoned and the development of the technology transferred to South America and Europe.

The current principles for the use of laser energy in laser lipolysis/liposuction were founded by Blugerman, Schavelzon, and Goldman in the early 2000. They were first to describe the effects of laser on adipose tissue and surrounding structures—dermis, vasculature, and interstitial tissue [13–16]. Badin et al. also reported their findings in 2002. They found laser lipolysis to be superior to the conventional suction-assisted liposuction in terms of reduced bleeding, disrupted adipose cell membranes, and introduction of new collagen. Its histological findings correlated with their clinical observation—less ecchymoses, decrease in local adiposity and skin tightening (badin-flaccidity under control) [17].

On 31 October of 2006 FDA-approved a 1064 nm Nd: YAG laser (smartLipo, Cynosure) for the surgical excision, vaporization, ablation, and coagulation of soft tissues. That caused the market to explode and various companies introduced their laser lipolysis machines with various wavelengths as well as the laser source. That also enabled new studies to be performed, and it was followed with a number of articles that advocated the benefits of laser-assisted liposuction.

Around the same time of the FDA approval, laser lipolysis was also approved in Japan where Ichikawa et al. were first to demonstrate the histologic and photonic relationship of energy absorption and lipolysis using a pulsed Nd:YAG laser. Scanning electron microscopy after irradiation showed greater destruction of human adipocytes than in the control. Degenerated cell membrane, vaporization, liquefaction, carbonization, and heat coagulated collagen fibers were observed [18]. In 2005, Badin demonstrated that laser-assisted liposuction produces more major irreversible damage on the adipose cells with less bleeding than the traditional suction-assisted liposuction [19]. In 2007, Mordon et al. represented mathematical model of laser lipolysis. The importance of that article was actually in their conclusion that heat rather than particular wavelength leads to lipolysis and skin tightening. They concluded that the temperature of 48–50°C inside the lower dermis is sufficient to induce skin tightening, which corresponds to external temperature of 38–41°C [20]. Finally, in 2008, McBean and Katz were first to evaluate the skin tightening effect by photographic documentation and measurement. Subjects had 4 × 4 cm temporary India ink tattoos placed at the treatment site and measurements showed 18% decrease in surface area. They also performed histological evaluation that indicated new collagen and myofibroblast compared to the baseline [21]. Until today, various studies have been performed and articles have been published regarding superiority of laser-assisted liposuction but also complications have been described. Therefore, it should be remembered that laser is just a tool in a surgeon's hand and care must be taken to use the maximum from the energy tool but also not to endanger patient's safety.

4. Mechanism of action

Basic mechanism of action in laser lipolysis is photothermal [20, 22]. Targeted tissue absorbs laser energy and converts it into heat. During laser lipolysis and constant moving of the laser beam, two parallel processes occur: absorption and scattering. Absorption occurs momentarily and, in biological tissue, is mainly caused by water molecules, proteins, and pigments.

Absorbed laser light energy converts into heat, thus producing desired thermal damage. The heat acts on adipose cells and the extracellular matrix to produce both reversible and irreversible cellular damage. For low-energy settings, heat generated by the laser alters the balance of sodium and potassium of the cellular membrane, allowing the free transport of extracellular liquid to intracellular space. For higher energy, settings rupture of adipose cells, coagulation of collagen fibers, and small vessels are observed. Cell lipases are liberated in the surrounding area, thus liquefying the tissue [23–25].

At the same time, scattering occurs. Scattered parts of the laser beam are refracted and finally also absorbed. This effect broadens the final volume of tissue where the absorption and thermal damage finally occur.

In human skin and subcutaneous adipose tissue, scattering predominates over direct absorption for the wavelengths between 450 and 1800 nm [24]. When there is higher absorption, scattering is mitigated, which results in low thermal effect. Considering all of the above, the optimal choice of wavelength for laser lipolysis is one that is scattered as well as absorbed in tissue. As the wavelength increases, the absorption increases also and scattering decreases.

The photothermal process of fat cell disruption occurs with the tissue heated on 50–65°C. Lower temperatures do not result in destruction of adipocytes. Higher temperatures are not advisable due to complications—tissue necrosis and scarring [23, 26]. To achieve skin tightening, temperatures of 48–50°C must be reached within the dermis to induce collagen contraction. Collagen injury from thermal damage promotes collagen remodeling, leading to increases in skin tone and texture. Whenever a controlled, reversible thermal injury is created, the body's response is to release mediators responsible for the healing process. In turn, fibroblasts are stimulated to generate and lay a bed of newly formed collagen [27–29].

Different wavelengths have been selected for laser lipolysis in an attempt to specifically target: adipose tissue, collagen (water), and blood vessels. There are not enough reports in current literature for a final conclusion to be made but some have been made. According to Perlette and Kaminer, the most selective wavelength for adipocyte cell disruption is 924 nm. Since the technology used is not only to diminish the subcutaneous fat layer but also to use it in an optimal way for body contouring which includes the skin during the procedure. The wavelength should be used that manages to disrupt fat cells but also achieves substantial skin tightening. With the wavelengths tested in the report, authors state that the 1064-nm wavelength has lower fat absorption but a better tissue disruption and there for produces better skin tightening effect. In that sense, for the treatment of fragile areas, authors suggest the use of 1320 nm because it has lower penetration and is safer to use [23, 30].

The final result of laser-assisted liposuction/lipolysis is visible after 90 days. For the certain amount of adipose cells that were irreversibly damaged (but not ruptured at the time of the lysis) and were not suction during liposuction, the process of adipocytolysis occurs through macrophage activity and this process takes approximately 90 days.

Also, after the initial thermal effect on the interstitial tissue, healing process is activated and fibroblast is stimulated to form new collagen. Neocollagenesis takes about 3–10 weeks.

5. Advantages of laser-assisted liposuction

The most significant advantage of laser energy in liposuction is the skin tightening effect. The physiology of action has previously been described. Most candidates that undergo liposuction have significant adipose tissue amount and generally have moderate excess of skin. In cases where skin excision is not indicated the amount of skin tightening that evolves from using the laser energy is generally enough to achieve satisfactory result. Therefore, it is always indicated in patients that could result in excess skin after aspirating the subcutaneous fat. Surgeons should also remember that effects of laser energy are prolonged. Skin tightening occurs during several months after the procedure. The patients should also know that definitive result can be seen after several months [21, 27, 30, 31].

During laser-assisted lipolysis/liposuction, smaller cannula sizes are used. The adipose tissue is liquefacted; thus, it takes up less volume and the incision site can therefore be smaller. Smaller cannulas result in less trauma to the surrounding tissue resulting in less pain and discomfort after the procedure that enables the patient to recover faster and return to normal everyday activity. Smaller cannulas also enable to perform liposuction in smaller areas where much more precision is needed. That combined with the uniform liquefaction of the adipose tissue makes perfect combination for treating localized adiposity in thigh and knee area, arms, and submental and facial fat. Also, smaller cannulas can be especially useful in areas like male chest, back, or hips. Those areas are very fibrous; therefore, the fat is trapped in smaller compartments. The smaller is the cannula used for lipolysis and it facilitates fat melting in fibrous locations. In the same time, smaller cannula size diminishes trauma to the surrounding tissue experienced with larger sized cannulas. Only laser lipolysis without aspiration of the liquefied content is described in the literature. Dudelzak, Hussain, and Goldberg reported study with 20 patients that underwent laser lipolysis of extensor arm fat pads. The liquefied fat was removed in 50% of the patients, and the results were observed 6 months after the procedure. Their conclusion was that the results were identical whether or not post-laser lipolysis aspiration was undertaken [32]. Individual case reports can be found describing masses after laser lipolysis alone [33]. Fat necrosis is usually a gradual process that is noticed by the patient or physician as a mass. Radiologically, it can imitate cancer. Complications from necrosis of any kind are in direct correlation with the amount of necrotic tissue. Larger amounts of necrosis create a greater inflammatory response. If the amount of necrotic tissue is too big, in time, macrophages will not be able to resolve all of the necrosis but only that which is placed peripherally and is in contact with the viable tissue. The central part will remain, and the immune system will encapsulate the remaining necrosis [34]. The authors advocate the use of aspiration whenever possible to avoid such complications. Laser lipolysis alone should be reserved only to small treated areas where aspiration could result in irregularities.

Laser-assisted lipolysis/liposuction results in reduced blood loss due to coagulation effect of the laser energy. Abdelaal and Aboelatta conducted a study on 56 patients. Equal amounts of liposuction were performed – traditional-assisted liposuction on one side and laser-assisted liposuction on the contralateral side. Blood loss volumes were calculated from the lipoaspirates by measuring hemoglobin and red blood cell content. Laser lipolysis reduced the blood loss

by more than 50% compared to the traditional liposuction [35]. Considering the reduced blood loss, laser-assisted liposuction is indicated in large-volume liposuctions (>5 L of lipoaspirate) to prevent secondary anemia due to blood loss during surgery. Reduced blood loss diminishes the need for postoperative blood transfusions and therefore results in faster recovery. Reduced blood loss is especially important in patients who previously underwent bariatric surgery. In those patients, preoperative anemia is often present [36]. Coagulation of the vessels also contributes to less bruising and edema, which also results in faster recovery and higher patient satisfaction [25].

Many surgeons have noted an improvement of cellulite after laser lipolysis procedures. The causes of cellulite are multifactorial, including changes in fibrous septae within the hypodermis that macroscopically show herniation of subcutaneous fat into the dermis [37]. In 2008, Goldman et al. published a new treatment approach combining subdermal Nd: YAG laser lipolysis and autologous fat transplantation that resulted in significant clinical improvement in cellulite. A majority of patients (84.6%) rated the results of treatment as either good or excellent [38]. In 2016, Petti et al. reported the use of the Nd:YAG laser at a wavelength of 1440 nm, along with an innovative 1000- μ m directional side-firing fiber-optic laser system for single stage contouring of the lower body and concluded that both problems could be addressed at a same time with high satisfaction rate using different laser energy that according to their specifications have better effect on fat melting or collagen heating [39]. These findings are in correlation with findings reported by Forman Taub and Friedman [23].

Last, but not least, because the adipose tissue is liquefied, fatty tissue removal should be hastened creating less strain for the surgeon. Aspiration of the liquefied adipose tissue should be smooth, and large surgeon's strength should not be involved.

6. Complications specific to laser-assisted liposuction

Due to photothermal effect of the laser energy and the heat accumulated in the tissue during the procedure, laser burns or skin necrosis can occur. Accumulating the heat in one place which happens if you do not move around the tissue with the fiber fast enough and you remain on one place overaccumulation of the heat will happen in one place and thermal injury will develop. It can start as a blister and in the beginning can appear as a partial skin thickness burn, but you must remember that the damage came from the inside; therefore, it will result in full skin thickness burn and will definitely leave a mark. As it was described before, there is a thin line between the desired effect and adverse event. To avoid this complication when beginning using laser energy in liposuction, the authors suggest to start with lower energy levels and avoid very superficial areas of the subcutaneous tissue to avoid direct dermal as well as dermal vascular plexus injury. An infrared thermometer (some devices are equipped with an internal subcutaneous thermometer) can be used to control the heat. Outside control of the temperature can be done but in reality is unreliable. Some surgeons also advise cold compresses on the treated area to diminish the effect of the laser on the skin [40]. The authors suggest continuous movement of the fiber with contralateral hand on the treated skin area to

control the applied energy, and therefore, the accumulated heat to minimize the risk of laser burns.

In cases where laser lipolysis without aspiration is done, fat necrosis may occur. As mentioned before, fat necrosis is possible. In reasonable small amounts, the body is able to process and remove the cellular debris and biochemical by-products of the melted fat cells. In larger amounts, the results are unpredictable with hard nodules, lumps, and uneven scarring. The risk of fat necrosis is diminished with the use of aspiration but is not completely disappeared. As it was mentioned before, the prolonged effect of thermal injury happens in cases where adipose cells' membrane was not disrupted but the cell accumulated enough energy to produce irreversible damage and that kind of tissue was not aspirated subsequently but left inside. During time, adipocytolysis via the macrophages starts. If the area of irreversible damage is larger with no blood flow, then the macrophage delivery to the point of injury is impossible and body starts to localize the process and the fat necrosis present like a mass. To avoid these kind of complications, authors suggest the uniform lipolysis with the laser as well as uniform aspiration following lipolysis.

Overaccumulation of the heat can result in hyperfibrotic reaction that can be visible as a strain or palpable or patient can complain of the straining in some of the treated parts especially during movement. These adverse reactions can be treated with injection of the triamcinolone acetonide injections in the strains but mostly resolve during time with compressive massage.

At the beginning of the use of lasers in liposuction, there has been concern regarding the increase of serum lipids due to degradation of the adipose cells. Mordon et al. published an article in 2009. They studied standard lipid profile (total cholesterol, HDL cholesterol, LDL cholesterol, and triglycerides) before the procedure and 1 day, 3 days, 2 weeks, and 1 month after the laser lipolysis procedure. They concluded that serum cholesterol and triglyceride levels remained in the normal range after laser lipolysis. They proposed two hypotheses: fat elimination is so gradual that an increase in circulating lipid levels is not measurable and/or the damaged adipocytes are undergoing apoptosis and being removed by phagocytosis, presumably via activated macrophages [41].

Recently, in August of 2015, Shin and Chang reported a case of a 34-year-old patient that was diagnosed with rhabdomyolysis with acute kidney injury after laser-assisted liposuction. No similar reports until now have been made [42].

7. Description of the technique

Preoperative evaluation of the patient must be done. Pinch test should be performed to evaluate the amount of excess skin and to exclude the need for surgical excision of the excessive skin. Irregularities of the skin should be marked, while patient is standing to avoid losing the 3D relations once the patient is on the operating table. Preoperative photographs should be taken with emphasis on the skin irregularities.

Targeted area should always be larger than the aspiration site to achieve better skin tightening effect and to allow the overlying skin to attach to the infrastructure uniformly. For example, when treating gynecomastia/pseudogynecomastia, laser energy should be applied to whole chest area to achieve better skin retraction and accommodation (see **Figures 1–5**).

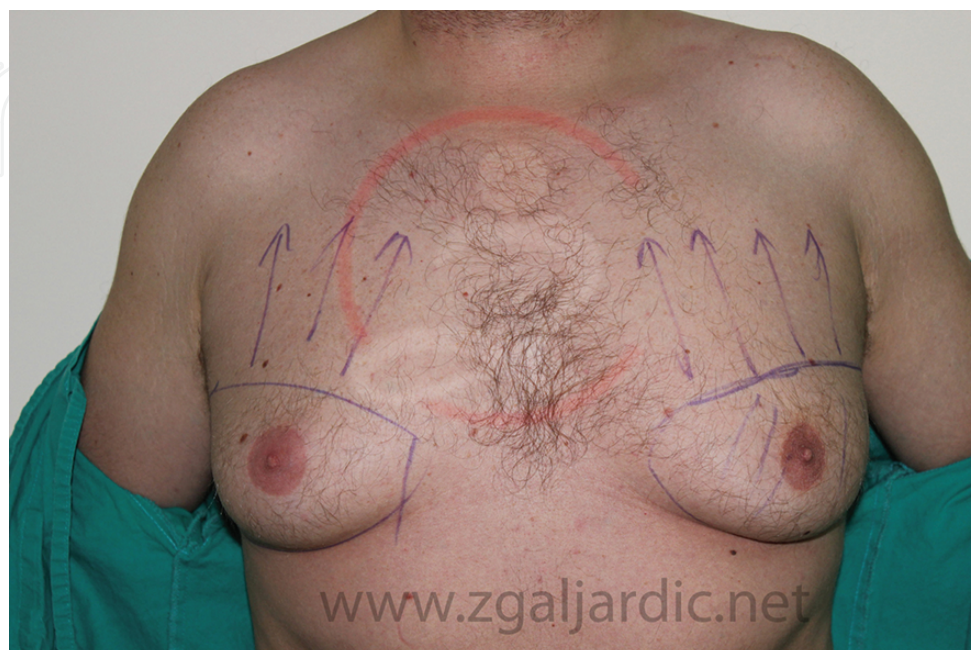

Figure 1. Preoperative markings—case 1.

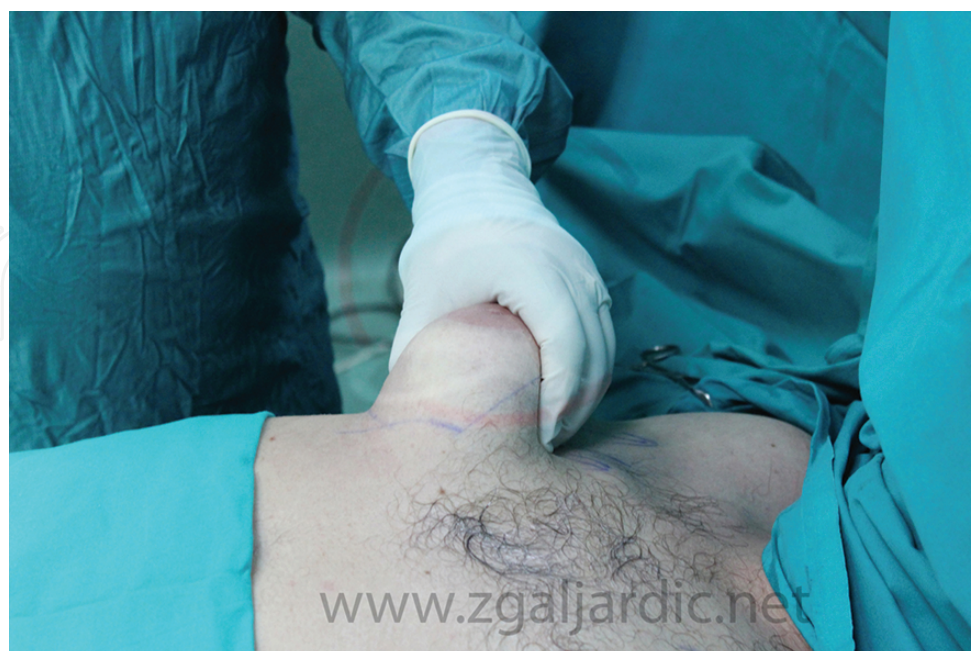

Figure 2. Intraoperative “pinch test” to evaluate the amount of the fat tissue during the procedure—case 1.

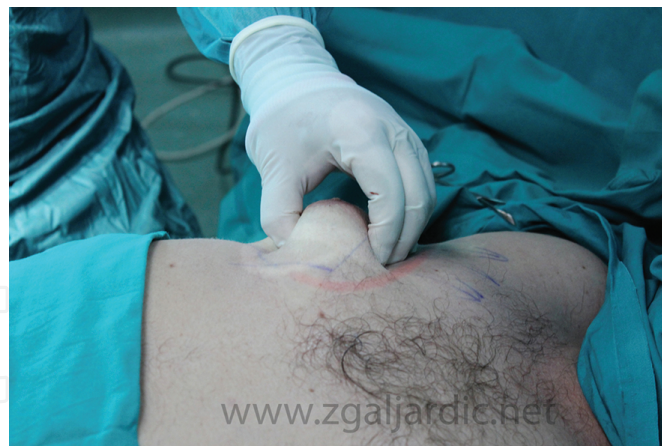

Figure 3. Intraoperative “pinch test” to evaluate the amount of the fat tissue during the procedure—case 1.

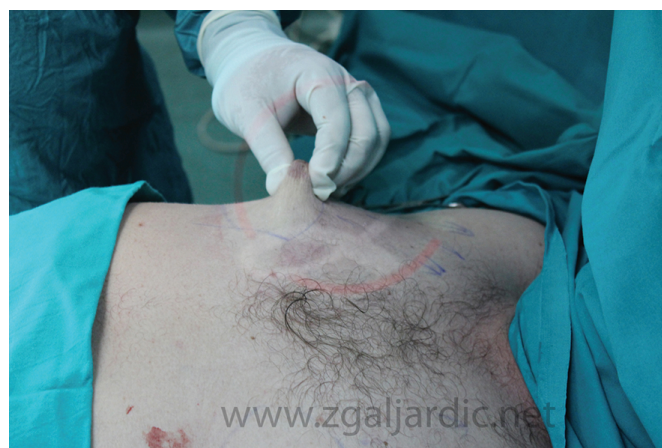

Figure 4. Intraoperative “pinch test” to evaluate the amount of the fat tissue during the procedure—case 1.

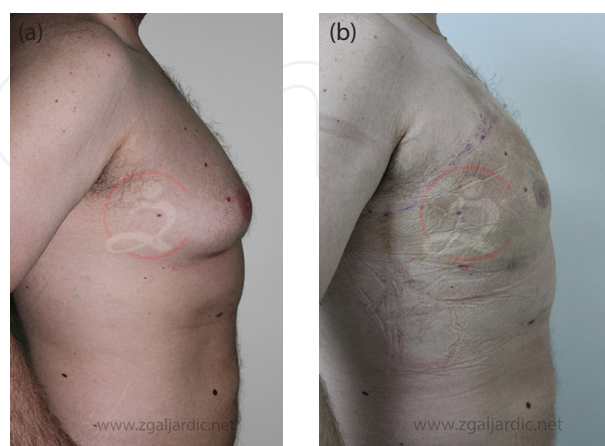


Figure 5. (a) Before photographs—case 1. (b) After 7 days—case 1.

Although there are many advocates of liposuction done solely in tumescent anesthesia, the authors prefer general anesthesia due to their comfort as well as the patients. The authors advise tumescent anesthesia only in cases of localized adiposity in one treated area. Authors also recommend 12- to 24-h observation after the whole-body procedure to administer the loss of intravascular volume as well as to help patients in early postoperative period.

In cases when the whole body (e.g. legs, abdomen, flanks, back) is treated, we recommend the disinfection of the skin in the treated areas should be done while patient is in the standing position and awake to be able to disinfect the whole circumference of the body and once finished patient should be laid down on the operating table previously covered sterilely.

Perioperatively single dose of 2 g cephazoline should be administered and continued orally with second-generation cephalosporin antibiotics.

Infiltration is done with the infiltration pump to minimize the time needed for the infiltration as well to deliver the infiltration uniquely. In case of tumescent anesthesia only standard Klein's solution is used. If the patient is in general anesthesia, only epinephrine can be used (1 ml of 1:1000 on 1 L of normal saline) to avoid the toxicity of lidocaine but still achieve vasoconstriction. Fifteen minutes after the infiltration, the laser lipolysis can be started (that is the approximate time needed for the infiltration process so once the infiltration is done normally you can start the laser lipolysis on the area firstly infiltrated).

The authors use the diode 1470 nm laser for the last 6 years. Energy applied normally is set to 12 W (for abdomen, flanks, back, legs, pseudogynecomastia), 10 W for the arms, and 6 W for the facial area and the submental fat. Pulse wave is continuous. As opposed to other laser wavelengths, which are absorbed by both water and oxyhemoglobin, 1470 nm demonstrates a greater water absorption coefficient. Sliding of the fiber should be smooth without surgeons' strength involvement. Thus, when strength should be applied, one should wait for a second in the place while the laser delivers the energy and the resistance in the tissue should ease up and allow us to slide through the tissue without mechanically disrupting the tissue fibers. Care must be taken all the time to avoid thermal injuries. The authors suggest to always have the opposite hand on the treated area to evaluate the temperature of the area. Devices equipped with internal subcutaneous thermometer can be used to monitor the temperature, or infrared thermometer can be used to measure outside temperature being careful not to exceed 38–40°C. Cold packs on the surface can diminish the temperature on the surface and thus avoiding the thermal injury of the skin. In 2009, Reynaud et al. published a retrospective analysis of 534 procedures of lipolysis using a 980-nm diode laser and calculated mean amount of energy and tumescent fluid infiltration for each location [25]. The lysis should first be done in deep layer parallel to the underlying structures radially covering the whole area available from the incisional site. Once the liquefaction in the deeper layer is achieved, the fiber should be moved to the upper layer starting from the incisional site.

The authors always advise to aspirate the liquefied adipose tissue after lipolysis to avoid complications described before. The aspiration starts with the bigger cannula moving to the smaller once to accelerate the aspiration but to avoid irregularities.

The incisional sites could be left open in large-volume liposuctions to allow the additional drainage.

To achieve the best skin tightening result, the authors advise applying the laser energy in the tissue once more after the aspiration process is done.

Compressive plates as well as the compressive garments should be applied at the end of the procedure to maximize the result. Postoperative instructions are explained later on in the chapter.

8. High-definition liposuction

Small size of the laser fiber enables the use of cannulas of small diameter. That facilitates the melting of the adipose tissue in delicate places so it allows us to melt the fat very superficial under the skin and enclosed in small fibrous compartments. Those specifications allow us to perform high-definition liposuction. It is reserved for the individuals who seek more defined and athletic look but cannot get rid of the small amount of the stubborn unwanted adipose envelope.

Preoperative markings are very important. Surgeon should mark the patient in the standing position. Goal is to mark the borders of the defining muscles such as m. rectus abdominis, m. pectoralis major, m. obliquus abdominis, m. deltoideus especially their tendinous parts. That can be achieved by asking the patient to contract the specific muscles or to perform the movement that emphasizes a specific muscle. During contraction or movement, you should mark the borders of the muscles and their tendinous parts.

Intraoperative process is the same as with the standard laser-assisted liposuction. During laser lipolysis, care must be taken not to make thermal injury of the skin so the movements of the laser fiber should be precise, smooth, and fast moving. Here is when the preoperative markings are important. To achieve highly defined structure, the intention is to apply more laser energy and thus more heat at the area where you marked the tendinous parts. More heat applied over the tendinous parts serves to promote collagen formation in the fibrous septa over the underlying tendinous structure so that those parts macroscopically look defined. Aspiration should be done with small diameter cannulas to ensure precise work and to avoid irregularities that can easily be done in already athlete patient. Postoperatively adhesive bandages can be placed with small amount of pressure on the previously mentioned tendinous parts to guide the healing process in the early postoperative period (7 days).

High-definition laser liposuction is a precise method and should not be performed if you are just beginning to use the laser device. There is no place for mistakes in high-definition liposuction. Too much energy applied subcutaneously can easily make thermal injury of the skin that will leave a mark. Also overaspiration of even small amount of the subcutaneous fat can result in a visible irregularity. You have to remember that individuals seeking high-definition liposuction are highly demanding and seeking only the perfect result. High-

definition laser liposuction should be reserved for the physicians who are familiar with the technique.

9. Laser lipolysis/liposuction of the face and neck

Due to the skin tightening effect of the laser energy, the technique has also found its place in contouring face and neck. Submental region, cervicomandibular angle, Periparotid fat, and perinasolabial area are the treated areas. Energy applied in these areas is smaller than in the other parts of the body —6 W. As with the high-definition laser-assisted liposuction, this is not the technique for the beginners.

This technique is useful not only in treating facial adiposity but also for patients seeking facial rejuvenation procedures and with proper indication can replace traditional face and neck lift [43, 44]. There are no long incisions, only incisional places for the laser fiber and subsequently used microcannulas. The results are long lasting and comparable to those of traditional surgery. Recovery time is faster and can be done in tumescent anesthesia.

10. Postoperative instructions

1. Compression garments should be worn for 3 weeks.
2. Compression plates that can be found on the market or should be made at the end of the procedure by individual's structural characteristics (costal arch, iliac crest, sizes of the flanks, back, or chest) of hard, yet flexible material that allows movements (should be dressed up in compresses) should be worn for 7 days during whole day and for the next 2 weeks during the night.
3. In cases of high-definition laser-assisted liposuction adhesive bandages mentioned before are worn for 7 days.
4. Showering of the treated area is allowed after check up on 7th postoperative day only with cold water to avoid vasodilatation and subsequent edema.
5. Peroral antibiotics of second generation of cephalosporin are given during 5 days.

Postoperative measurements are important in obtaining the best result possible. It should be carefully explained to the patient the importance of those instructions as they are in their best interest. They should be explained that all those postoperative measures have important role in their recovery and that they allow us to guide the healing process and that is in their best interest to follow them carefully. Postoperative measurements serve as a tool in obtaining best skin tightening effect and to avoid contour irregularities.

11. Results

The authors have been using laser-assisted lipolysis for the last 10 years. Laser used for the last 6 years was diode 1470 nm laser. 1470 nm has proved to be very safe. This wavelength shows high absorption rate for water molecules and fat cells; therefore, there is no need for high power settings during the procedure. That enables to work faster and also prevents damages to the surrounding tissue. In that way, it diminishes complication rates. During that time, no significant complication specific to laser has been seen. The authors are very satisfied with the results that are achieved with the use of laser in body contouring procedures. Satisfaction rate among the patients treated is extremely high, and they claim the postoperative period to be painless and fast (see **Figures 6–35**).

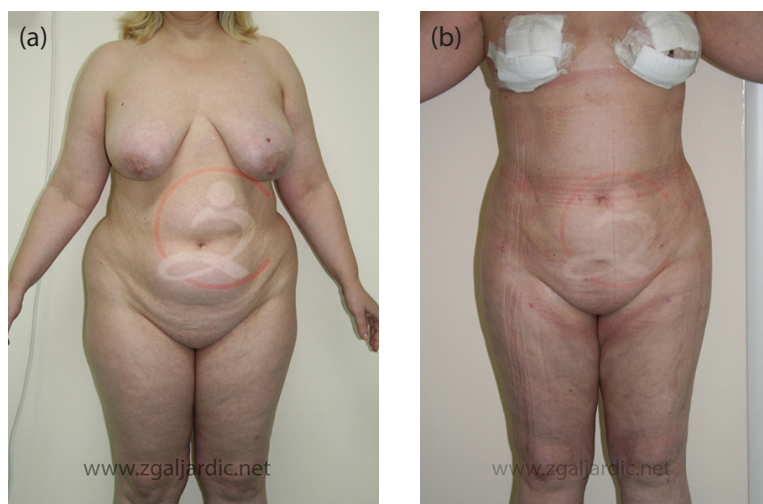


Figure 6. (a). Before photograph(front)- case 2. (b). Case 2(front) after 7 days.

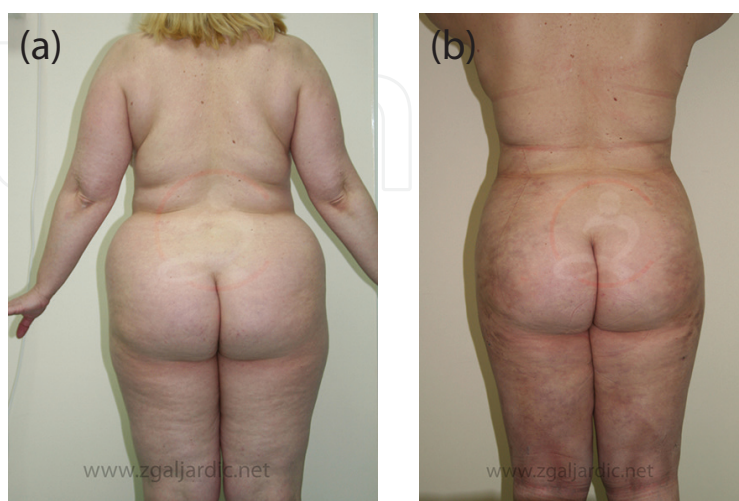

Figure 7. (a). Before photograph(back)- case 2. (b). Case 2(back) after 7 days.

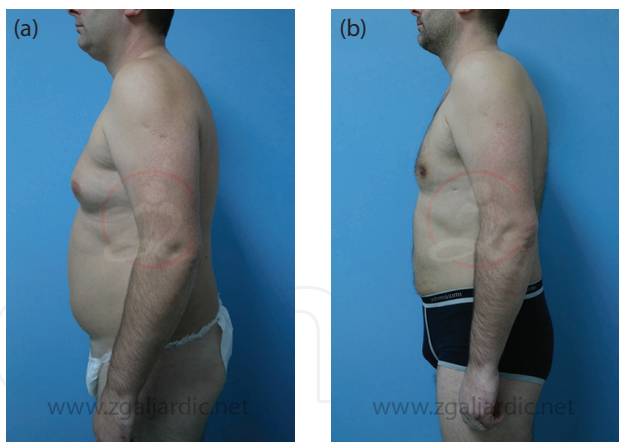


Figure 8. (a). Before photograph- case 3. (b). Case 3- after 3 weeks.

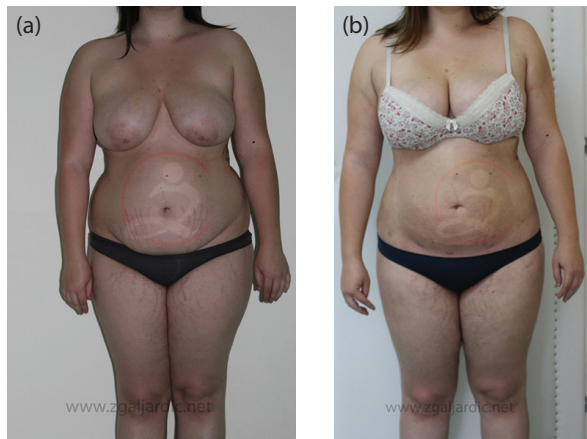


Figure 9. (a). Before photograph (front)—case 4. (b). Case 4 (front)-after 2 weeks.

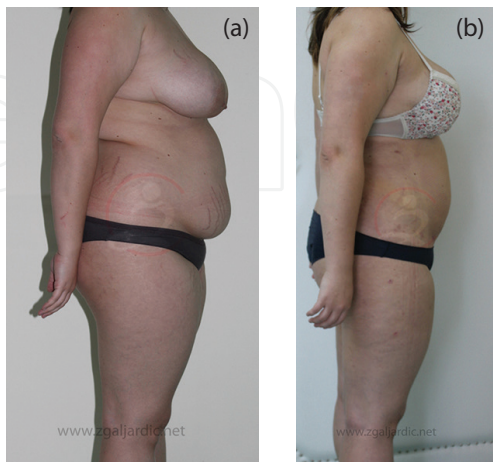


Figure 10. (a). Before photograph (profile)- case 4. (b). Case 4 (profile)- after 2 weeks.

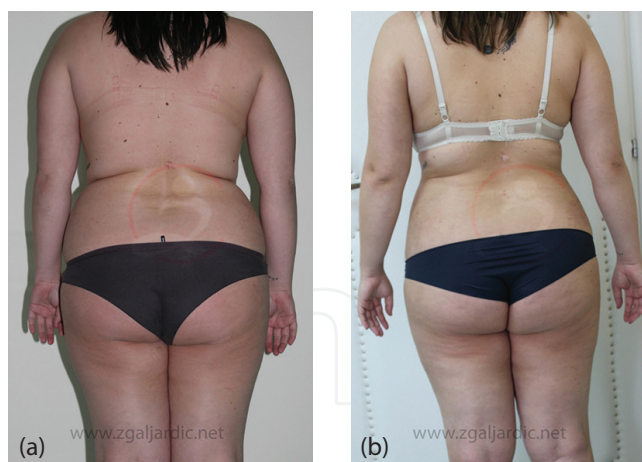

Figure 11. (a). Before photograph (back)-case 4. (b). Case 4 (back)-after 2 weeks.

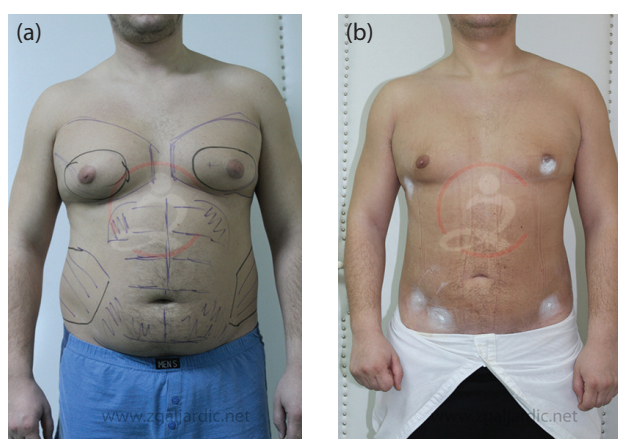


Figure 12. (a). Before photograph (front)-case 5. (b). Case 5 (front)-after 7 days.

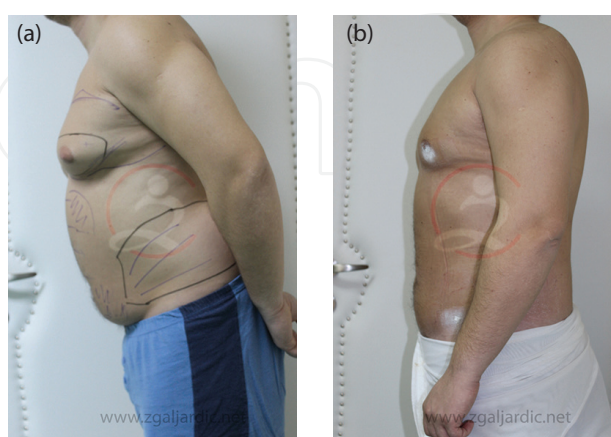


Figure 13. (a). Before photograph (profile)-case 5. (b). Case 5 (profile)-after 7 days.

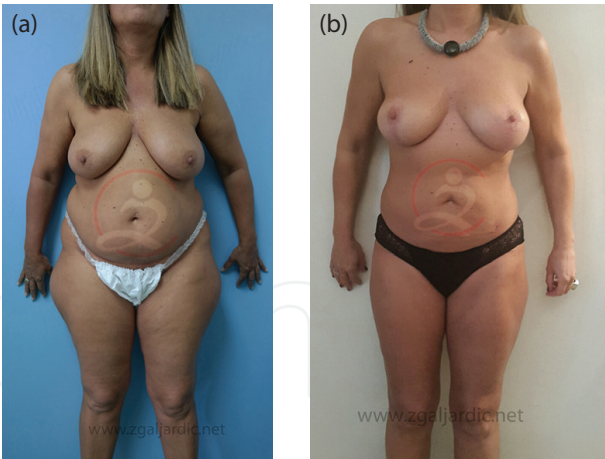


Figure 14. (a). Before photograph (front)- case 6. (b). Case 6 (front)-after 3 weeks.

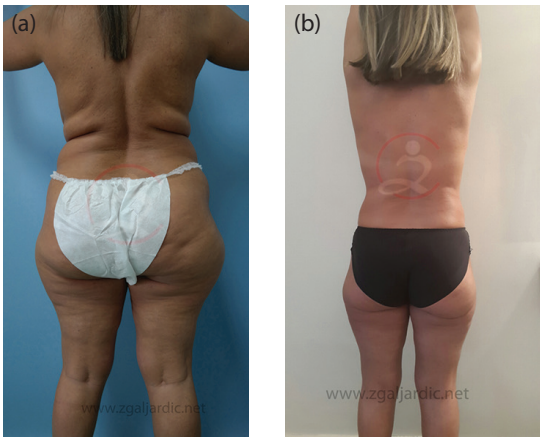

Figure 15. (a). Before photograph (back)- case 6. (b). Case 6 (back)-after 3 weeks.

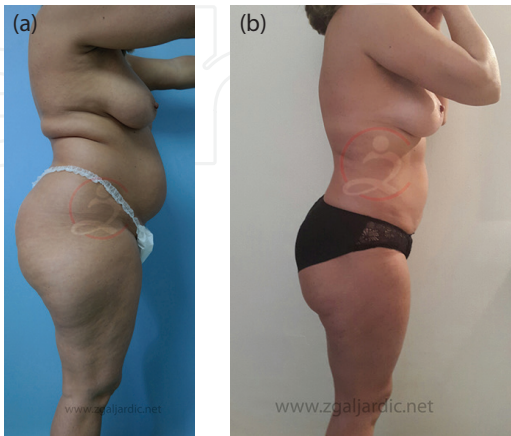


Figure 16. (a). Before photograph (profile)- case 6. (b). Case 6 (profile)-after 3 weeks.

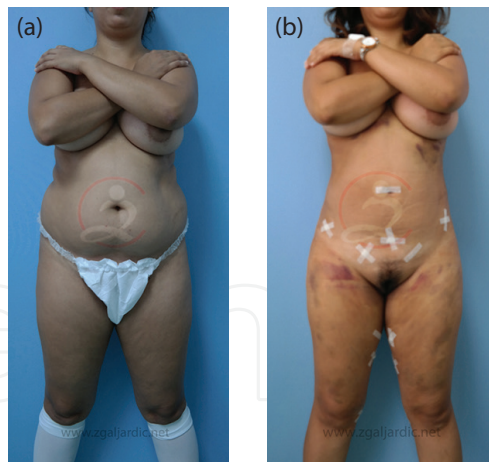


Figure 17. (a). Before photograph (front)- case 7. (b). Case 7-(front)- after 7 days.

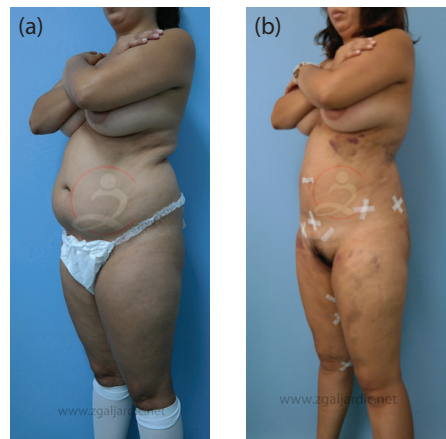


Figure 18. (a). Before photograph (semiprofile)- case 7. (b). Case 7 (semiprofile)- after 7 days.

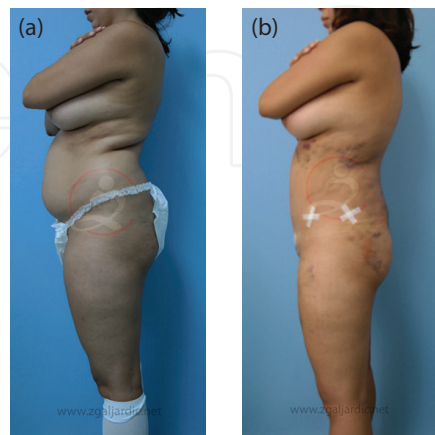


Figure 19. (a). Before photograph (profile)- case 7. (b). Case 7 (profile)-after 7 days.

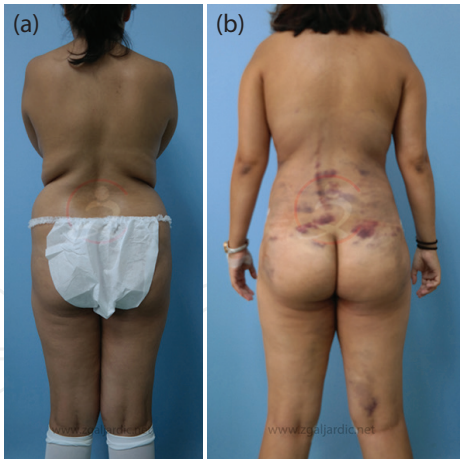


Figure 20. (a). Before photograph (back)- case 7. (b). Case 7 (back)- after 7 days.

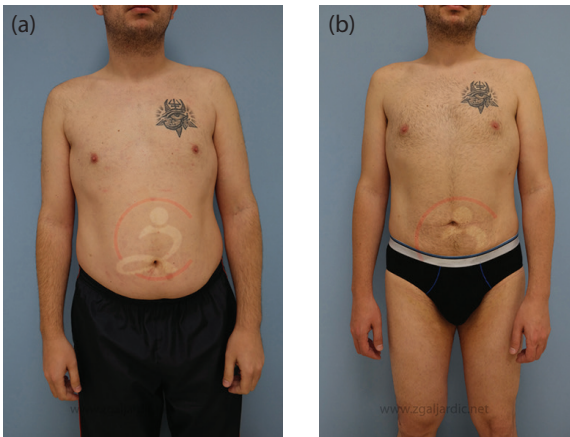


Figure 21. (a). Before photograph (front)- case 8. (b). Case 8 (front)-after 2 weeks.

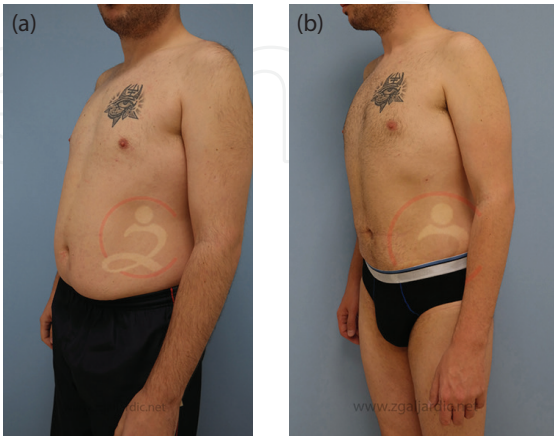


Figure 22. (a). Before photograph (semiprofile)- case 8. (b). Case 8 (semiprofile)- after 2 weeks.

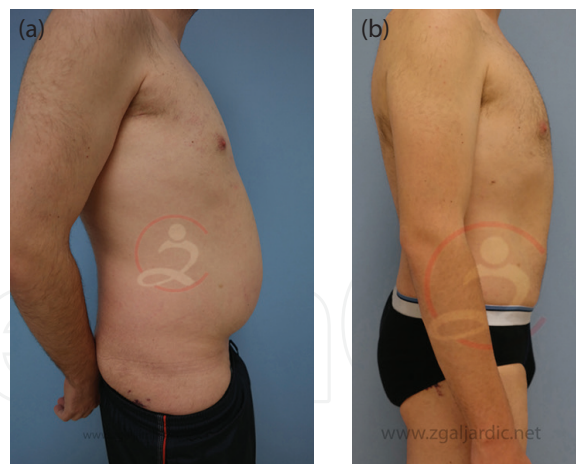


Figure 23. (a). Before photograph (profile)-case 8. (b). Case 8 (profile)- after 2 weeks.

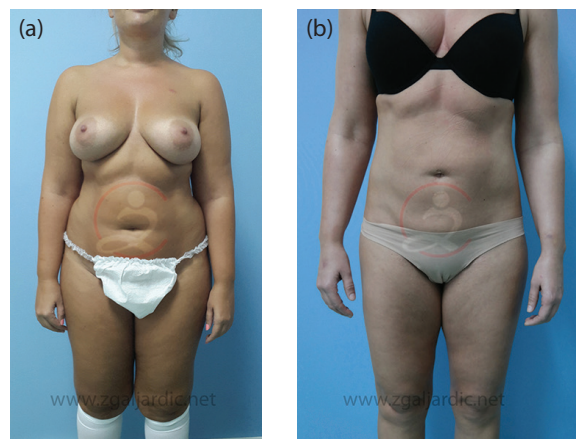


Figure 24. (a). Before photograph (front)- case 9. (b). Case 9 (front)- after 6 weeks.

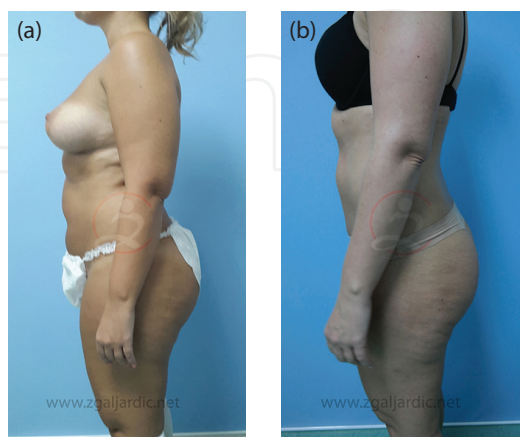

Figure 25. (a). Before photograph (profile)- case 9. (b). Case 9 (profile)- after 6 weeks.

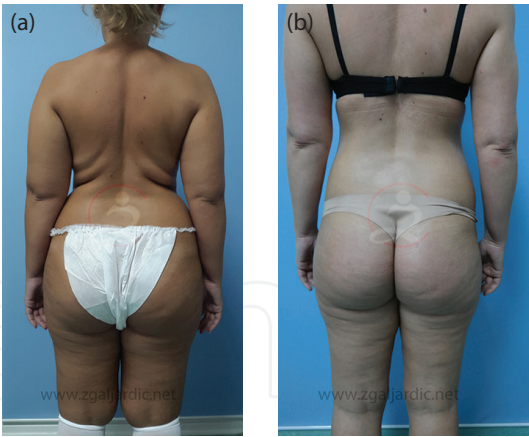

Figure 26. (a). Before photograph (back)- case 9. (b). Case 9 after (back)- 6 weeks.

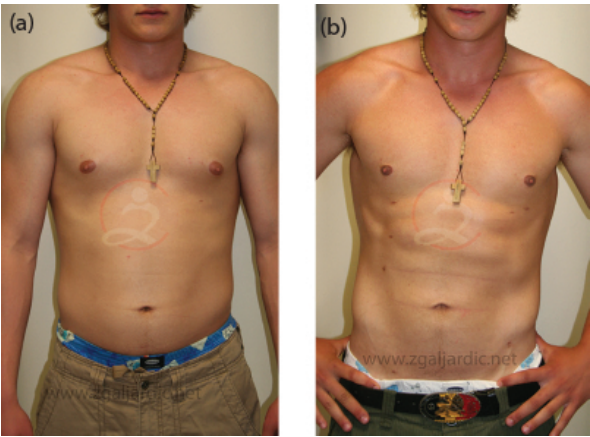


Figure 27. (a). Before photograph (front)-case 10. (b). Case 10 (front)- after 3 weeks.

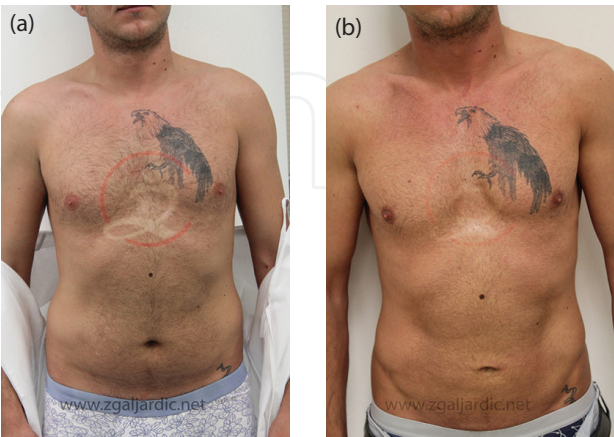


Figure 28. (a). Before photograph (front)- case 11. (b). Case 11 (front)- after 3 weeks.

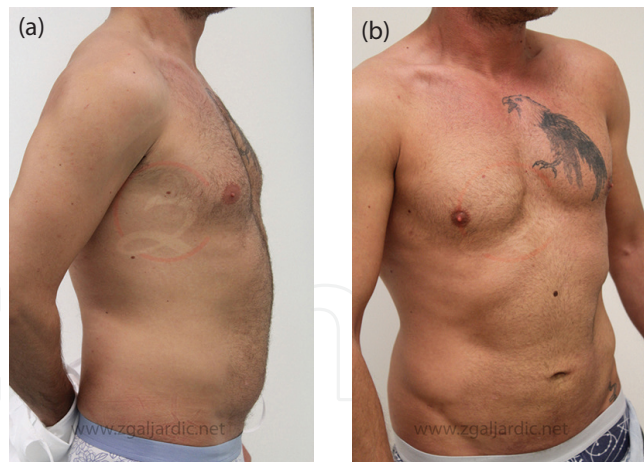


Figure 29. (a). Before photograph (profile)- case 11. (b). Case 11 (semiprofile)- after 3 weeks.

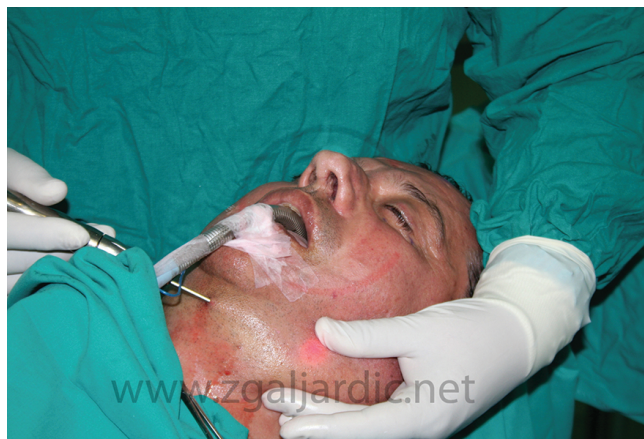

Figure 30. Laser lipolysis of the neck: always be aware of the probe's position to avoid injuries of the marginal nerve.

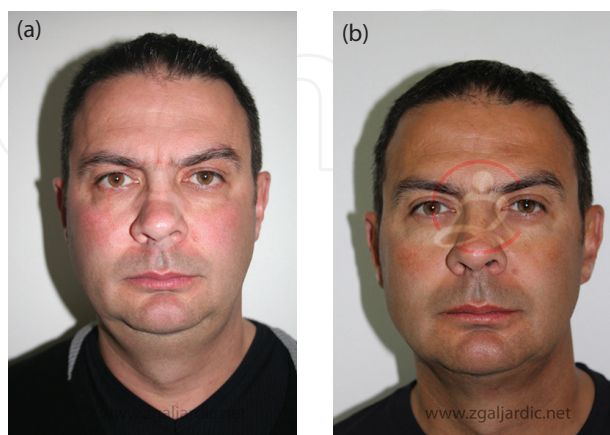

Figure 31. (a). Before photograph(front)- case 12. (b). Case 13 (front)- after 3 weeks.

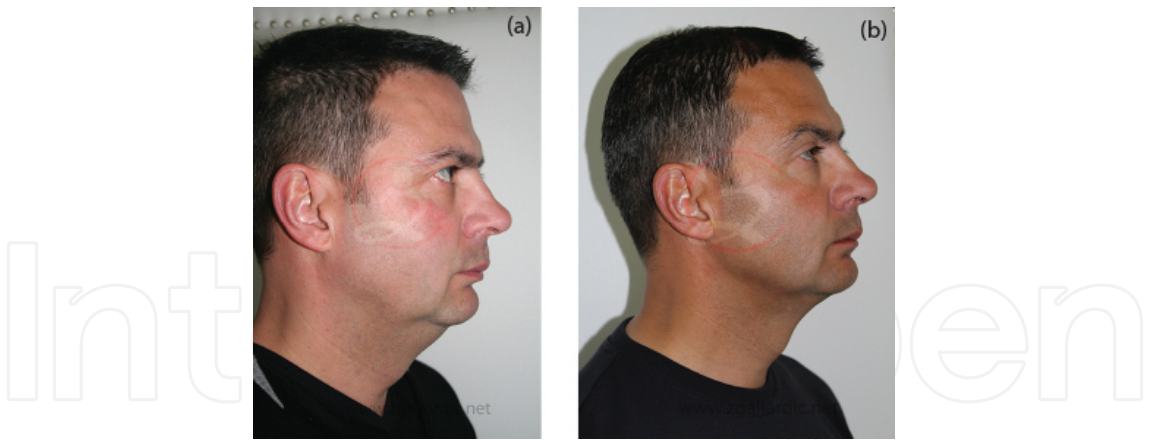

Figure 32. (a). Before photograph (profile)—case 12. (b). Case 13 (profile)- after 3 weeks.

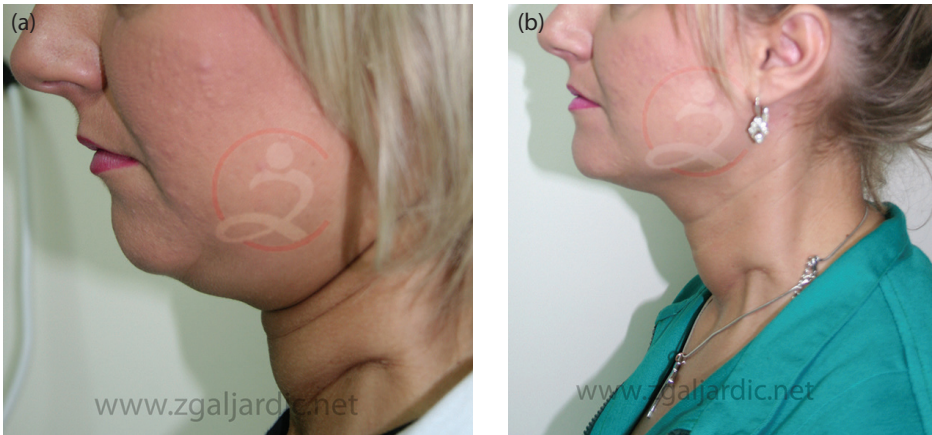


Figure 33. (a). Before photograph (profile)- case 14. (b). Case 14 (profile)- after 1 month.

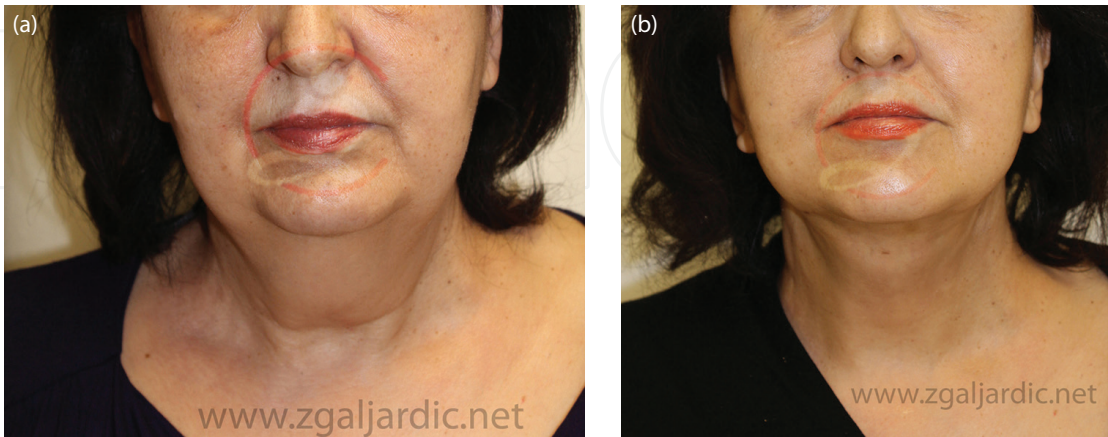

Figure 34. (a). Before photograph (front)—case 13. (b). Case 13 (front)- after one month.

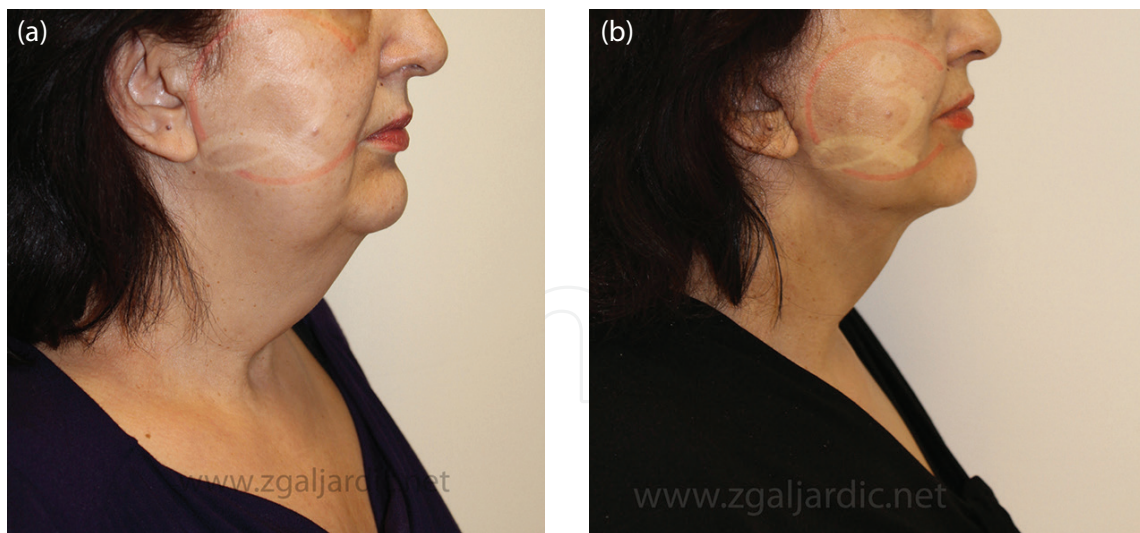

Figure 35. (a). Before photograph (profile)- case 13. (b). Case 13 (profile)- after one month.

12. Conclusion

Laser-assisted liposuction is a big step forward in body sculpting. Since the laser was introduced in this area, various studies have been made and showed its benefits. The superiority of laser-assisted liposuction over traditional liposuction can be summarized as follows:

1. Superior skin tightening effect: changes occur in the tissue after absorption of laser energy due to photothermal effect. That characteristic enables us to treat any area with the excessive adipose tissue and modest skin laxity with obtaining better cosmetic result.
2. Coagulation of blood vessel: the use of laser reduced the blood loss after the liposuction and also reduces bruising after the procedure. That enables the patient to recover faster which leads to higher satisfaction rate.
3. Disruption of the adipose cells: the lipoaspirate is liquefied that enables the smoother aspect of the treated area.
4. Use of smaller cannulas: after the laser lipolysis has been done, the aspiration can be made with smaller cannulas that allows us to aspirate the areas of the fat that cannot be reached with traditional liposuction.

The specific complications of the laser energy should not be forgotten. Although laser allows us to reach results beyond the results of traditional liposuction, one should always have in mind that technology is just a tool in a physician's hand. The goal is to optimize the amount of energy delivered to the tissue thus maximizing the final result but avoiding possible side effects and complications.

Author details

Zoran Žgaljardić* and Ivonne Žgaljardić

*Address all correspondence to: zoran.zgaljardic@gmail.com

Aestehtic Surgery Center Dr. Žgaljardić Opatija, Zagreb, Croatia

References

- [1] The American Society for Aesthetic Plastic Surgery's cosmetic surgery statistics [Internet]. Available from: <http://www.surgery.org/sites/default/files/ASAPS-Stats2015.pdf> [Accessed: 2016-06-15]
- [2] Shridharani SM, Broyles JM, Matarasso A: Liposuction devices: technology update. *Med Devices (Auckl)* 2014;7:241–251.
- [3] Shiffman MA, Aiache AE: *Atlas of Liposuction*. 1st ed. New Delhi: Jaypee Brothers Medical Publishers (P) Ltd.; 2013. p. 1.
- [4] Illouz Y. *Liposuction: The Franco-American Experience*. Beverly Hills, Calif: Medical Aesthetics, 1985.
- [5] Einstein A. On the Quantum Thoery of Radiation. *Physikalische Gesellschaft Zürich Miteilungen* 1916;18:47–62 published in *Physikalische Zeitschrift* 1917;18:121–128. Reprinted in Kox AJ et al., eds. *The collected papers of Albert Einstein: The Berlin Years, Writings, 1914–1917*, Princeton: Princeton University Press, 1966:381–397.
- [6] Einstein A. On a Heuristic Point of View Concerning the Production and Transformation of Light. *Annalen der Physik*. 1905;17:132–184.
- [7] Alster TS. Preface. In: *Manual of Cutaneous Laser Techniques*. Philadelphia: Lippincott Williams and Wilkins, 2000. p. 11.
- [8] Goldman L. Pathology of the effect of the laser beam on the skin. *Nature* 1963;197:912–914.
- [9] Hukki J, Krogerus L, Castren M, Schroder T: Effects of different contact laser scalpels on skin and subcutaneous fat. *Lasers Surg Med*. 1988;8:276–282.
- [10] Goldberg DJ, Berlin AL: *Disorders of Fat and Cellulite: Advances in Diagnosis and Treatment*. Boca Raton: CRC Press; 2011. p. 103.
- [11] Apfelberg, D. Laser-assisted liposuction may benefit surgeons and subjects. *Clin Laser Mon*. 1992;10:259.

- [12] Apfelberg DB, Rosenthal S, Hunstad JP, et al.: Progress report on multicenter study of laser-assisted liposuction. *Aesthetic Plast Surg.* 1994;18(3):259–264.
- [13] Blugerman GB. Abstracts of World Congress on Liposuction Surgery. Dearborn, Michigan: 2000. Laser lipolysis for the treatment of localized adiposity and “cellulite.”
- [14] Schavelzon DS, Blugerman G, Goldman A, Abstracts of the 10th International Symposium on Cosmetic Laser Surgery. Las Vegas: 2001. Laser lipolysis.
- [15] Goldman AG, Schavelzon D, Blugerman G. Laser lipolysis: liposuction using Nd:YAG laser. *Revista da Sociedade Brasileira de Cirurgia Plástica.* 2002;17:17–26.
- [16] Goldman AG, Schavelzon D, Blugerman G. Liposuction using neodimium:yttrium-aluminiumgarnet laser. Abstract in *Plast Reconstr Surg.* 2003;111:2497.
- [17] Badin AZ, Moraes LM, Gondek L, et al. Laser lipolysis: flaccidity under control. *Aesthetic Plast Surg.* 2002;26(5):335–339.
- [18] Ichikawa K, Tanino R, Wakaki M: Histologic and photonic evaluation of a pulsed Nd:YAG laser for ablation of subcutaneous adipose tissue. *Tokai J Exp Clin Med.* 2006;31(4):136–40.
- [19] Badin AZ, Gondek LB, Garcia MJ, Valle LC, Flizikowski FB, de Noronha L: Analysis of laser lipolysis effects on human tissue samples obtained from liposuction. *Aesthetic Plast Surg.* 2005;29(4):281–6. Epub 2005 Jul 19.
- [20] Mordon SR, Wassmer B, Reynaud JP, Zemmouri J: Mathematical modeling of laser lipolysis. *Biomed Eng Online.* 2008;7:10.
- [21] McBean JC, Katz BE: A pilot study of the efficacy of a 1064 and 1320 nm sequentially firing Nd:YAG laser device for lipolysis and skin tightening. *Lasers Surg Med.* 2009;41(10):779–84.
- [22] Khoury JG, Saluja R, Keel D, Detwiler S, Goldman MP: Histologic evaluation of interstitial lipolysis comparing a 1064, 1320 and 2100 nm laser in an *ex vivo* model. *Lasers Surg Med.* 2008;40(6):402–6.
- [23] Forman Taub A, Friedman A: Laser lipolysis with a 980 nm diode laser. *J Drugs Dermatol.* 2010;9(5 Suppl ODAC Conf Pt 1):s58–61.
- [24] Lukac M, Vizintin Z, Zabkar J, and Pirnat S. QCW Pulsed Nd:YAG 1064 nm Laser Lipolysis, *J Laser Health Acad.* 2009;4/1:5–17.
- [25] Reynaud JP, Skibinski M, Wassmer B, Rochon P, Mordon S: Lipolysis using a 980-nm diode laser: a retrospective analysis of 534 procedures. *Aesthetic Plast Surg.* 2009;33(1): 28–36.
- [26] Tagliolatto S, Barcellos Medeiros V, Gerin Leite O: Laserlipolysis: update and literature review. *Surg Cosmet Dermatol.* 2012;4(2):164–74.

- [27] Badin AZ, Moraes LM, Gondek L, Chiaratti MG, Canta L: Laser lipolysis: flaccidity under control. *Aesthetic Plast Surg.* 2002;26(5):335–9.
- [28] Ichikawa K, Miyasaka M, Tanaka R, Tanino R, Mizukami K, Wakaki M: Histologic evaluation of the pulsed Nd:YAG laser for laser lipolysis. *Lasers Surg Med.* 2005;36(1):43–6.
- [29] Goldman A, Wollina U, de Mundstock EC: Evaluation of tissue tightening by the subdermal Nd: YAG laser-assisted liposuction versus liposuction alone. *J Cutan Aesthet Surg.* 2011;4(2):122–8.
- [30] Parlette EC, Kaminer ME: Laser-assisted liposuction: here's the skinny. *Semin Cutan Med Surg.* 2008;27(4):259–63.
- [31] DiBernardo BE, Reyes J: Evaluation of skin tightening after laser-assisted liposuction. *Aesthet Surg J.* 2009;29(5):400–7.
- [32] Dudelzak J, Hussain M, Goldberg DJ: Laser lipolysis of the arm, with and without suction aspiration: clinical and histologic changes. *J Cosmet Laser Ther.* 2009;11(2):70–3.
- [33] Gentileschi S, Servillo M, D'Ettorre M, Salgarello M: Abdominal subcutaneous mass after laser-assisted lipolysis and immediate multiple treatments with a dual-wave-length laser, vacuum and massage device. *Aesthet Surg J.* 2016;36(4):NP144–9.
- [34] Bingol UA, Cinar C: Laser lipolysis without suction: reality or myth? *Photomed Laser Surg.* 2014;32(11):642–5.
- [35] Abdelaal MM, Aboelatta YA: Comparison of Blood Loss in Laser Lipolysis vs Traditional Liposuction. *Aesthet Surg J.* 2014;34(6):907–12.
- [36] von Drygalski A, Andris DA: Anemia after bariatric surgery: more than just iron deficiency. *Nutr Clin Pract.* 2009;24(2):217–26.
- [37] Proebstle TM: [Cellulite]. *Hautarzt.* 2010;61(10):864–72.
- [38] Goldman A, Gotkin RH, Sarnoff DS, Prati C, Rossato F: Cellulite: a new treatment approach combining subdermal Nd: YAG laser lipolysis and autologous fat transplantation. *Aesthet Surg J.* 2008;28(6):656–62.
- [39] Petti C, Stoneburner J, McLaughlin L: Laser cellulite treatment and laser-assisted lipoplasty of the thighs and buttocks: combined modalities for single stage contouring of the lower body. *Lasers Surg Med.* 2016;48(1):14–22.
- [40] McBean JC, Katz BE: Laser lipolysis: an update. *J Clin Aesthet Dermatol.* 2011;4(7):25–34.
- [41] Mordon S, Wassmer B, Rochon P, Desmyttere J, Grard C, Stalnikiewicz G, Reynaud JP: Serum lipid changes following laser lipolysis. *J Cosmet Laser Ther.* 2009;11(2):74–7.

- [42] Shin JY, Chang H: Rhabdomyolysis after cosmetic laser-assisted liposuction. *Aesthetic Plast Surg.* 2015;39(4):635–8.
- [43] Gentile RD: Laser-assisted neck-lift: high-tech contouring and tightening. *Facial Plast Surg.* 2011;27(4):331–45.
- [44] McMenamin P: Laser face-lifts: a new paradigm in face-lift surgery. *Facial Plast Surg.* 2011;27(4):299–307.

