

# We are IntechOpen, the world's leading publisher of Open Access books Built by scientists, for scientists

6,900

Open access books available

186,000

International authors and editors

200M

Downloads

Our authors are among the

154

Countries delivered to

TOP 1%

most cited scientists

12.2%

Contributors from top 500 universities



WEB OF SCIENCE™

Selection of our books indexed in the Book Citation Index  
in Web of Science™ Core Collection (BKCI)

Interested in publishing with us?  
Contact [book.department@intechopen.com](mailto:book.department@intechopen.com)

Numbers displayed above are based on latest data collected.  
For more information visit [www.intechopen.com](http://www.intechopen.com)



---

## Eye Coinfections

---

Carlos Alberto Pantoja-Meléndez, Victor M. Bautista-de Lucio,  
Mariana Ortiz-Casas, Jonathan Quevedo-Martínez and  
Herlinda Mejía-López

Additional information is available at the end of the chapter

<http://dx.doi.org/10.5772/64702>

---

### Abstract

Ocular infections are an *ophthalmologic* emergency that threatens the eye's integrity, which may result in a poor visual outcome; hence, it requires prompt treatment. The most common microorganisms involved in eye infection are the bacteria, followed by virus and fungi; however the prevalence depends on the geographic location. It is essential to know The etiologic agent of the ocular infection ocular infections and their antibiotic sensitivity because the geographical situation and the urbanization level of the studied population will determine their prevalence. Recently have been described eye coinfections, where at least two microorganisms can infect at the same time and the same anatomic site. Several coinfections have been published, bacteria-bacteria, bacteria-fungus, bacteria-virus, fungus-yeast, fungus-virus, parasite-bacteria, etc. Eye coinfections represent a particular challenge for the ophthalmologists; coinfections are difficult to diagnose because often the clinical characteristic is atypical and mimics different clinical pictures. In addition, eye coinfections respond poorly to antibiotics and usually present an aggressive clinical course. In these circumstances, it is common for patients to receive multiple treatments when they should be receiving a specific treatment. Several risk factors are important to develop coinfections, e.g., trauma, dry eye, use of contact lenses, and comorbidities (diabetes and immunosuppression). Coinfections have been described in keratitis, conjunctivitis, and endophthalmitis. The study of polymicrobial biofilms has been increasing, and in the medical area, the role played by biofilms in confections has been associated with virulence factors; hence, biofilm formation is also considered a determinant virulence factor for pathogenesis in the host. Coinfection diagnosis is an important topic in order to obtain a specific and timely diagnosis. Microbiological and molecular approaches are proposed to identify etiological agents. Delay in diagnosis affects the sensitivity to specific treatments and the evolution of infection. Treatment and prognosis are supported by a specific diagnosis.

**Keywords:** Coinfection, polyinfections, biofilm

## 1. Introduction

An infected eye is one of the major causes of corneal blindness after cataract in developing countries [1]. This is mainly induced by bacteria, fungi, yeast, and parasites. However, an increasing number of coinfections, which involve the presence of two or more pathogens, in the same place at the same time, affecting one or both eyes, are being reported. Comparing the single-microorganism infections, in which theoretically there is no competition, the coinfections have been proven to have more mechanisms competing against the host resources. This competition is the main factor influencing the clinical course and evolution of the infection [2].

Eye coinfections represent a particular challenge for ophthalmologists; coinfections are difficult to diagnose because often the clinical picture is atypical and mimics different clinical pictures. In addition, eye coinfections respond poorly to antibiotics and usually present a slow clinical course. In these circumstances, it is common for patients to receive multiple treatments when they should be receiving a specific treatment; this can cause a refractory infection and need for surgical treatments.

Although eye infections are common in immunocompetent patients, coinfection can compromise the immune system of the host [3, 4]. Therefore, the strategies used by each microorganism to survive against different treatments and the self-host immune response have important implications for the diagnosis and prognosis of the infection [5].

This chapter provides a systematic review of the frequency and epidemiological characteristics, with reports of the most common clinical entities, produced by coinfection in the eye.

## 2. Epidemiological characteristics

### 2.1. Epidemiological significance

Ocular infectious processes are among the clinical entities that are relevant to the epidemiology. The high incidence of infections in patient care institutions has resulted in high-quality infection control processes and monitoring of various entities of epidemiological relevancy. For example, viral conjunctivitis primarily represents a challenge for management and prevention. Thus, it is common for diseases such as hemorrhagic conjunctivitis and follicular conjunctivitis to be part of the epidemiological surveillance.

The difficulty of the epidemiological surveillance of ophthalmic diseases lies in the limitation of performing a specific etiologic diagnosis of infection, since in practice ophthalmic infections are treated empirically based on the clinical picture and the physician's experience. Ophthalmologists and laboratory staff should not forget that care of patients with endophthalmitis is usually performed at the first level of care, where the general practice is responsible for the greatest amount of attention to this disease. Thus, control programs for conditions such as trachoma are necessary to prevent them from reemerging and being attentive and vigilant regarding emerging diseases.

Within emerging diseases, changes are observed in response to treatment but more important in the modification to the incidence and prevalence to disease. Reports of bacterial strain resistant to antibiotics and changes in the behavior expected of diseases are increasing. Therefore, new mechanisms of resistance of microorganisms, comorbidity states in individuals, new mechanisms of transmission, etc., that explain what changes in the conditions have occurred are sought. One explanation is the presence of more than one causal agent of infectious disease, coinfections.

The mechanisms developed by various microorganisms when present concurrently can alter significantly the clinical presentation, diagnosis, and treatment.

Coinfections resemble clinical pictures presented by other clinical entities and have an adverse effect, as the usual outcome is the use of multi-treatment that fails, causing refractory management and in many cases ending in loss of vision or surgical interventions. This reveals the importance of presenting cases of coinfections of the eye.

Although eye coinfections are not the subject of epidemiological surveillance, they are not as rare as previously thought and can represent 3.88 % of endophthalmitis cases, for example, and more than 50 % in some series of patients with conjunctivitis reported in the literature [6, 7].

### 3. Agents

Associated microorganisms may occur in different combinations. This association is predominantly bacteria-bacteria and to a lesser extent bacteria-fungus and bacteria-virus.

*Acanthamoeba* spp. and *Pseudomonas* spp. are associated because of their high resistance to empirical antibiotics and ulceration, which occurs primarily in association with *Acanthamoeba* spp., which is associated with *Legionella* spp., *Streptococcus* spp., herpes virus, *Moraxella* spp., *Candida* spp., etc.

Several viruses, bacteria, or fungi cause eye infections, but the pathogenic agent is modified extensively at presentation as a coinfection especially when the bacterium is coinfecting with different bacteria or a virus. In the case of fungi, when they are present with bacteria, only small changes are observed [3]. The clinical spectrum of keratitis can change when there is a coinfection between bacteria and *Candida* spp., mainly occurs; however, when endophthalmitis involves coinfection of a fungus and Gram-negative bacteria, the result is more unfavorable [6].

### 4. Risk factors

The core components of the presentation of coinfections are risk factors. However, studies have not shown high causality for association. Coinfections have been diagnosed in patients with no reports of comorbidities (diabetes, immunosuppressive processes, etc.) although coinfections can occur in patients with human immunodeficiency virus (HIV); however, this risk factor was not significant in the patients reported.

One risk factor for coinfection of fungus and bacteria is trauma. Dry eye also seems to be a risk factor.

The most frequently reported risk factor is the use of contact lenses, especially soft lenses. Coinfection with *Acanthamoeba* spp. and *Pseudomonas* spp. has been reported in contact lens-associated keratitis. Poor response to treatment has been observed in young people with greater frequency in women.

### 5. Challenges

The most important challenge in the emergence of this clinical entity is the identification of a new form of presentation of eye infections. The standard method of causality associates the disease with a single causative agent. However, in this new scenario, more than one causal agent is observed. The new entity must be monitored and addressed as a new disease, which requires a new diagnostic approach, prognosis, and treatment.

### 6. Keratitis due to coinfections

#### 6.1. Bacteria and fungus

Bacteria and fungus represent the most frequent type of coinfection in the eye (Table 1). The main microorganisms that produce coinfections are bacteria, such as *Staphylococcus* spp., *Streptococcus* spp., *Pseudomonas* spp., *Haemophilus* spp., *Klebsiella* spp., *Bacillus* spp., and *Corynebacterium* spp. The fungi genera microorganisms include *Aspergillus* spp., *Fusarium* spp., *Curvularia* spp., *Cladosporium* spp., *Bipolaris* spp., *Alternaria* spp., and the yeast *Candida* spp. Most of these microorganisms are normal microbiota in the conjunctival sac or the lids [8]. Their presence depends on the geographic area. However, bacteria and fungus coinfections that have been reported more frequently in a large series of cases are the genera *Staphylococcus* spp. with *Aspergillus* spp. or *Fusarium* spp., [3, 9, 10, 11, 12, 13].

Organisms	Study type	Infection caused	Reference
Bacteria and fungus	Transversal	Keratitis	Gopinathan <i>et. al.</i> 2009
	Transversal	Keratitis	Basak <i>et. al.</i> 2005
	Transversal	Keratitis	Pate <i>et. al.</i> 2006
	Transversal	Keratitis	Bharathi <i>et. al.</i> 2002
Bacteria and bacteria	Transversal	Keratitis	Fröhlich <i>et. al.</i> 1999
	Transversal	Keratitis	Yeh <i>et. al.</i> 2006
	Case	Keratitis	Jones 1981

Organisms	Study type	Infection caused	Reference
Bacteria and yeast	Case	Keratitis	Kim <i>et. al.</i> 2006
Filamentous fungus and yeast	Case	Keratitis	Qui <i>et. al.</i> 2013
Filamentous fungus and filamentous fungus	Case	Keratitis	Hayashi <i>et. al.</i> 2014
<i>Acanthamoeba</i> and bacteria	Transversal	Keratitis	Tu <i>et. al.</i> 2009
	Case	Keratitis	Hong <i>et. al.</i> 2014
	Case	Keratitis	Dini <i>et. al.</i> 2000
	Transversal	Keratitis	Iovieno <i>et. al.</i> 2010
	Case	Keratitis	Lone <i>et. al.</i> 2009
<i>Acanthamoeba</i> and fungus	Transversal	Keratitis	Froumis <i>et. al.</i> 2008
	Case	Keratitis	Gupta <i>et. al.</i> 2011
	Case	Keratitis	Slade <i>et. al.</i> 2008
Virus and bacteria	Case	Conjunctivitis	Mellman-Rubin <i>et. al.</i> 1995
	Case	Conjunctivitis	Tappe <i>et. al.</i> 2013
Bacteria and bacteria	Transversal	Conjunctivitis	Iwalokun <i>et. al.</i> 2011
Bacteria and bacteria	Transversal	Endophthalmitis	Gharamah <i>et. al.</i> 2012
	Transversal	Endophthalmitis	Jindal <i>et. al.</i> 3013
	Transversal	Endophthalmitis	Gupta <i>et. al.</i> 2002
	Transversal	Endophthalmitis	Long <i>et. al.</i> 2014
Bacteria and fungus	Transversal	Endophthalmitis	Gupta <i>et. al.</i> 2003
HIV and herpes	Transversal	Retinal necrosis syndrome	Liesegang 2001
HIV and cytomegalovirus	Transversal	Retinitis	Faber <i>et. al.</i> 1992
HIV, Epstein-Barr, and cytomegalovirus	Transversal	Retinitis	Freigassner <i>et. al.</i> 2002
HIV, cytomegalovirus, and herpes	Case	Retinitis	Skolnik <i>et. al.</i> 1989
HIV and several microorganisms (including <i>Acanthamoeba</i> )	Case	Keratitis	Tandon <i>et. al.</i> 2003
HIV and <i>Treponema pallidum</i>	Case	Severe bilateral retinal vasculitis	Albini <i>et. al.</i> 2011
Virus and worm	Case	Perilimbal and conjunctival infection and HZV lesion	Seo <i>et. al.</i> 2014

**Table 1.** Main reports of human eye coinfections.



Bacterial and fungal keratitis often is not clinically distinguishable from monomicrobial infections, because they override the pathognomonic picture typical of bacterial or fungal keratitis [14]. Because of the difficulty of clinical diagnosis, other factors are added; many patients use traditional medicine (with the risk of adding other microorganisms to the infection) or initiate topical medication without a medical prescription. These therapeutic interventions delay the specific treatment, and the prognosis of infection is poor [14].

Bacteria and fungus coinfection can be incidental in the first instance. However, this condition favors the development in the participating pathogens of adaptive mechanisms that strengthen their protection versus the immune system host or the antimicrobial drug. This phenomenon is explained by the ability of fungi and bacteria to form biofilms. Studies recently showed that 99 % of microorganisms can form biofilms; only 10 % live as planktonic cells (unicellular cells) [15, 16, 17].

The characteristic that best distinguishes chronic infections from acute infections is the response to treatment with antibiotics. While acute infections can be removed after a short treatment with antibiotics, the biofilm in keratitis coinfections normally fails to be completely eliminated, produces recurrent episodes, and often must be solved with keratoplasty. The etiologic agents form biofilms that can be up to 1,000 times more resistant to antibiotics [17, 18, 19]. The issue of biofilms will be fully explained in the following section.

## 7. Bacteria and bacteria

Several reports in the literature have described this coinfection. Fröhlich *et. al.* studied patients with and without clinical history of contact lens use and showed that 51 of the 275 samples (18.5 %) from patients with bacteria keratitis were coinfections. The most common pathogens isolated were *Staphylococcus epidermidis* (44 %), *Staphylococcus aureus* (18 %), *Streptococcus* spp. (10 %), *Propionibacterium acnes* (7 %), and *Pseudomonas aeruginosa* (6 %) [20]. Yeh *et. al.* presented a study of 307 samples, of which 21 % were keratitis bacteria-bacteria coinfections with similar bacterial genera [21]. Jones reported coinfections between *Streptococcus pneumoniae* with *Corynebacterium* spp. or *Staphylococcus epidermidis* and isolated three microorganisms from one case, *Staphylococcus aureus* and *Streptococcus pneumoniae*, *Corynebacterium* spp., and *Micrococcus* spp., and, finally, *Streptococcus equinus* and *Haemophilus influenzae* from another patient.

## 8. Bacteria and yeast

Coinfections that involve *Candida* spp. or a filamentous fungus are usually difficult to treat, and the prognosis is poor. A coinfection of *Stenotrophomonas maltophilia* (Gram (-) bacteria) and a yeast has been documented. The corneal injury presented as an ulcer that quickly progressed despite treatment with proven sensitivity. The case was treated with penetrating keratoplasty [22].

## 9. Filamentous fungi and yeast

In a case with clinically distinguishable corneal infiltrates, *Exserohilum mcginnisii* and *Candida parapsilosis*, an unusual coinfection, were isolated. The infection showed torpid evolution with severe damage in the visual area [23]. Katragkou *et. al.* conducted a review that showed *Exserohilum* spp. produces a wide spectrum of diseases, including atopic, cutaneous, subcutaneous, systemic, and corneal infections; the most common factor was immunocompromised status [24]. In addition, *Candida* spp. is an opportunistic pathogen that affects immunocompromised and immunocompetent patients. This genus generates biofilms responsible for resistance to a wide range of antifungal drugs and often affects the cornea [25, 26]. *Exserohilum* spp. and *Candida* spp. can acquire a filamentous form that invades the stroma or produces endophthalmitis and has the capability of assembling biofilms.

## 10. Filamentous fungus and filamentous fungus

A case of sclerokeratitis produced by *Scedosporium apiospermum* and *Aspergillus cibarius* was recently reported. The case, which was characterized by insidious keratitis and liquefied sclera, was successfully treated with topical and systemic antifungal drugs [27].

## 11. *Acanthamoeba* spp. and coinfections

*Acanthamoeba* spp., a protozoon, is a free-living amoeba that can live in diverse environments. It has been isolated from soil, water for domestic use, salt or freshwater sewage, estuaries, hot springs, and swimming pools, among others, which highlight the microorganism's ability to live in extreme heat and pH conditions. Schuster and Visvesvara described *Acanthamoeba* spp. producing keratitis as non-opportunistic and thus occur in immunocompetent humans [28]. Galarza *et. al.*, described this amoeba as *amphizoic* due to its ability to live in the environment and parasitize humans [29].

The life cycle of *Acanthamoeba* spp. includes two stages: the cyst, a form of resistance to adverse environmental conditions, and the trophozoite, the amoeboid free-living stage. Due to the organism's phagocytic condition, *Acanthamoeba* spp. can feed of bacteria, algae, yeast, fungi, etc [30]; but some of these microorganisms have developed mechanisms to avoid intracellular death and take advantage of the amoeba (endosymbiosis). These circumstances make *Acanthamoeba* spp. a vector of almost any type of microorganism; Barket *et. al.*, in studies of the host-parasite relationship, called it a "Trojan horse" [31, 32].

## 12. *Acanthamoeba* and bacteria

The association of *Acanthamoeba* spp. with other microorganisms is most significant from the ophthalmological point of view. This species can generate corneal injuries that remain for



months or years and are difficult to treat with diamine and biguanide drugs in developing countries (chlorhexidine and polyhexamethylene biguanide, respectively) [33].

Some of the bacteria mechanisms within *Acanthamoeba* spp. have been described. Scheid *et al.*, using an *in vitro* model with electronic microscopy, showed the cycle of a coccoid-like organism in the free-living amoebae *Vannella* spp. The coccoid microorganism is a phagocyte and is transported by phagocytic vacuoles through the cytosol until reaching the amoeba nucleus where the microorganism proliferates and is released by rupture of the host membrane. In the beginning of the life cycle, coccoid microorganisms are phagocytes for other amoeba [34]. In addition, endosymbiont bacteria can replicate only into the amoeba cytosol, can break the cells, and can be ingested by neighboring amoeba [35]. However, the intrusion of bacteria into *Acanthamoeba polyphaga* has consequences for both microorganisms. A protein bellows the amoeba that adheres to the surface of *Legionella pneumophila*. The authors discussed the possibility that the liberation of the bacteria from the amoeba integrates amoeba antigens in its membrane. However, *Pseudomonas aeruginosa* and its liberated products kill *Acanthamoeba* spp. [30, 32, 36]. Another study showed that endosymbiont bacteria favor the growth of different species of *Acanthamoeba*, and all microorganisms isolated from contact lens care solutions contained numerous trophozoites [37].

*Acanthamoeba* spp. by itself causes severe inflammation in the cornea. Aggressive keratolysis or sclerokeratitis is a common complication. The most frequently reported symptoms are pain, photophobia, and tearing [38]. The association of *Acanthamoeba* spp. with bacteria or a fungus presents a coinfection that can mimic bacterial, fungal, or herpetic keratitis, which can delay the time to diagnosis and increase the pathogenicity of the *Acanthamoeba* spp. infection.

Several molecular methods and electronic microscopy have facilitated the observation of bacteria within *Acanthamoeba*, including *Pseudomonas aeruginosa*, *Listeria monocytogenes*, *Mycobacterium* spp., *Escherichia coli*, *Legionella pneumophila*, *Chlamydia* spp., and *Aeromonas* spp. They are also capable of producing keratitis themselves [30, 32, 39, 40, 41]. In addition, there are many reports in the literature of cases of *Acanthamoeba* and bacteria coinfection isolated from patients with or without contact lens-associated keratitis [39, 42, 43, 44].

### 13. *Acanthamoeba* and fungi

This type of coinfection is uncommon. Similar to bacteria, fungi have a complex relationship with *Acanthamoeba* spp. and generate lesions that can be confused with bacterial or herpetic keratitis; the prognosis is discouraging. In all cases reported, penetrating keratoplasty was performed. These coinfections require immediate and aggressive treatment with antifungal and antiamoebic drugs [45, 46, 47, 48, 49].

### 14. Conjunctivitis due to coinfection

Conjunctivitis is the most common eye infection in the world. Usually, the normal microbiota in the conjunctiva participates in infectious diseases of the ocular surface, and it has been

reported that diversity in the conjunctival microbiota varies depending on geographic region or occupational activity [50, 51, 52, 53]. Moreover, the pathogenesis of infectious conjunctivitis depends on the circumstances and intrinsic mechanisms to the microorganism and the host.

Although there are high diversity of microorganisms on the conjunctiva, few coinfections have been reported. This lack of reports could be due to confusing clinical manifestations or the low sensitivity of the methods used or simply because two or more microorganisms are not usually searched in an infection.

In a patient with conjunctivitis, an uncommon relationship between an adenovirus and *Chlamydia* spp. was reported. The study showed three patients positive for *Chlamydia* spp. in a sample of 100 patients with adenoviral conjunctivitis, using polymerase chain reaction (PCR) [54, 55]. Another report showed the presence of adenovirus type 53 with a multiple resistant strain of *Neisseria gonorrhoeae* in a patient with severe bilateral conjunctivitis.

Iwalokun *et. al.*, presented interesting results in a study conducted in Lagos, Nigeria. They analyzed 83 samples from patients with conjunctivitis and isolated 155 bacteria from the samples; the resistance patterns and the plasmid profile were evaluated. The authors found coinfections of two, three, or more pathogens (51.8 % and 18.1 %, respectively) and were able to identify three infection patterns that were significantly different [7]. This work emphasizes the possibility that multiple microorganisms can cause conjunctivitis.

## 15. Endophthalmitis due to coinfection

Endophthalmitis is an inflammatory intraocular reaction and is the most important complication for an ophthalmologist following surgery, trauma, and between others. The common presentation of the clinical picture is characterized by pain and decreased vision. As previously discussed in the section on keratitis due to bacteria and fungus coinfections, endophthalmitis due to coinfection can be confused with single bacterial or fungal infections. Thus, to facilitate successful interventions, the microorganisms responsible must be identified and antimicrobial sensitivity examined. Studies of several large series have shown the frequency of endophthalmitis due to bacteria and fungus and bacteria and bacteria coinfections.

Depending on patients' geographic region, consecutive case studies have found various incidence rates for this coinfection ranging from 2.4 % to 50 % [56, 57, 58, 59].

The most commonly isolated pathogens are Gram-positive cocci bacteria with filamentous fungi [60, 61]. However, Gram-negative or Gram-positive bacilli related to fungi are also responsible for endophthalmitis [60, 61, 62].

## 16. Coinfections in immunocompromised patients

The outcome of coinfection is the result of diverse interactions involving the host and the parasite's genetic background and the environment. In these infections, few reports have

explained the immune mechanisms implicated, because there is considerable variability in each combination of microorganisms that produces an infection.

The immunological mechanisms that occur in the eye are similar to the rest of the immune system. However, there is more regulation in the silencing response in order to prevent damage from infection and inflammation, and immune mechanisms preserve the functionality of the cornea [63].

In the following, studies that investigated the most common corneal coinfections are reviewed. These reports show the critical role of pathogens and the pathogenesis generated by the host immune response.

Vernal conjunctivitis is an example of how the immune phenotype affects the response to the infection. Patients with vernal keratoconjunctivitis have a family history of atopic diseases such as allergic rhinitis, asthma, and eczema [64]. A theory suggests that patients with a history of atopy are susceptible to intracellular infections because they have a Th2 immune phenotype [65, 66]. Kerr and Stern showed a polymicrobial infection in two patients with vernal keratoconjunctivitis and corneal ulcers [67].

Although regulation of the immune response in the eye is controlled locally, in immunocompromised patients with human immunodeficiency virus (HIV), it is evident that the privilege is broken by the depletion of T CD4<sup>+</sup> cells, and infections can occur. In addition, several pathogens can remain latent (herpes virus, bacteria, fungi, parasites). The clinical manifestation produced by the herpes virus can be conjunctivitis, blepharitis, intraocular inflammation, retinitis, or keratitis [68]. In particular, herpes simplex virus types 1 and 2 (HSV-1 and HSV-2) infect 50 % to 90 % of the population infected with HIV, causing ocular herpes and genital orofacial herpes in different geographic regions [69]. Herpetic retinitis has a high incidence; however, few cases have been reported. Faber *et. al.*, studied eyes from 25 cases with AIDS with an immunohistochemical test. *Cytomegalovirus* was found in 60 % of the cases and was related to retinitis, while in another case series, 36.64 % of 131 patients were diagnosed with *Cytomegalovirus* retinitis [70, 71]. Freigassner *et. al.*, documented a case with the Epstein-Barr virus and *Cytomegalovirus* in a patient with AIDS [72]. Other studies showed *Cytomegalovirus* or herpes in isolated cases [73, 74, 75].

Opportunistic microorganisms such as *Toxoplasma* spp., herpes zoster virus (HZV), and *Pneumocystis* spp., participates the least in coinfections.

## 17. Coinfections produced by strange conjunction of pathogens

*Burkholderia ambifaria*, *Enterococcus*, and *Staphylococcus aureus* were found in a patient with herpetic stromal keratitis. *Burkholderia ambifaria* is a Proteobacteria, which comprises strains with a virulence potential toward immunocompromised patients [76]. In a report on keratitis, *Acanthamoeba* spp., *Fusarium solani*, and Gram-negative cocci were identified in a patient who had unprotected sexual contact with multiple commercial sex workers [77].

## 18. Pharmacodynamics of antimicrobials used in eye coinfections

There is little information about the pharmacodynamics of antimicrobials used for coinfections of the human eye. The activity of antimicrobial drugs against yeast, bacteria, and fungi has been evaluated with a standardized microdilution assay in a culture medium [78]. The lowest concentration of an antimicrobial that completely inhibits the growth of any microorganism is known as the minimal inhibitory concentration (MIC), which can be used to determine the sensitivity or resistance.

Based on MICs with microdilutions and the growth radial technique on solid medium using Potato Dextrose Agar (PDA) dishes (using the percent mycelial inhibition) [79], our group reported that *S. aureus* cocultured with *F. solani* or *A. fumigatus* (all isolated from patients) significantly inhibited fungal growth (66.5 % and 55.6 %, respectively). gatifloxacin and moxifloxacin in the cocultures eliminated the bacterial effect on both growth fungi ( $p < 0.001$ ). amphotericin B, natamycin, and itraconazole inhibited fungal growth partially or completely, depending on the fungus. In contrast, the effect of amphotericin B or natamycin in the presence of quinolones significantly favored the growth of fungi; this effect was more evident in *F. solani* [80].

Nevertheless, the MIC does not reflect physiological concentrations of drugs because *in vivo* drug concentrations may vary due to many factors such as absorption, metabolism, half-life, elimination, etc. [81, 82, 83]. In addition, in treatments with prophylactic and therapeutic purposes for coinfections, fortified or coadministered agents are used that may affect the efficacy of the other agent [84, 85].

Attempts to understand the magnitude and type of interactions between drugs have enabled the development in isobolographic analysis of the “gold standard” for drug interactions, which define the interactions as follows: *Additive effect*: The combined effect of two drugs (A and B) equals the sum of the equivalent doses (depending on the relative potency of each drug). *Synergism*: The effect of A and B is greater than that of the two separate drugs. *Antagonism*: The addition of a second drug decreases the effectiveness of the first. *Indifferent*: No interaction between the drugs. The calculation is aided by an isobologram graph. This facilitates visual evaluation of the interaction but requires a separate statistical analysis. The isobolographic analysis for the MIC is more sensitive because the analysis evaluates the dose effects and is the prelude to studies in *in vivo* pharmacodynamics [86].

In coinfections, patients are exposed to simultaneous antifungal and antibacterial therapeutic treatment. Quinolones and antifungals are commonly used in bacteria and fungi or bacteria and yeast coinfections. Nakajima *et. al.*, reported the synergistic effect of DU-9859a fluoroquinolone enhanced the *in vitro* antifungal activity of amphotericin B and fluconazole against *Candida* spp. growth and decreased the load in mice infected with yeast. The last result was also observed in mice infected with *Aspergillus fumigatus* [87]. Similar results were obtained with ciprofloxacin, amphotericin B, levofloxacin, voriconazole, or caspofungin combinations, which has a synergistic effect against *Candida albicans* and *Aspergillus fumigatus* [88]. In another report, ofloxacin had a synergic effect on fluconazole versus a fluconazole-resistant *Candida albicans* strain [89].

Analysis of drug interactions with simultaneous application is still developing. Modified methods have been proposed related to more accurate isobolographic analysis, and *in vitro* models approach physiological conditions. Animal models have also been used. This area will revolutionize therapeutic interventions.

## 19. Biofilms

An appreciation for the fact that in nature bacteria adhere to many abiotic or biotic surfaces, embedded in an extracellular matrix, and form communities known as “biofilms” has emerged over the past few decades [90]. Biofilm formation conferred on individual bacteria the ability to collaborate and to adapt to a range of harsh environmental conditions and, perhaps most of all, to evade predation by phagocytic microbes. The formation of a biofilm provides a microbe with a small measure of control over the local environment, including fluctuations in temperature, pH, ultraviolet light, starvation, and exposure to toxic agents [91, 92].

Advances in medical biofilm research have led to the understanding that biofilms represent the prevalent form of bacterial life during tissue colonization and may occur in more than 80 % of microbial infections in the body [93].

Members of a biofilm community, which can be of the same or multiple species, show varying stages of differentiation and exchange information, metabolites, and genes with each other. As a result, members of the biofilm community are in a diversity of physiologies influenced by the unequal sharing of nutrients and metabolic by-products, which results in subpopulations with increased tolerance to antimicrobials and environmental stresses, the host immune system, and predatory microorganisms [19, 94, 95, 96, 97, 98].

Canonically, biofilm development has been grouped into five stages that are reflective of conditions in many, but not all, biofilms: (1) reversible aggregation of planktonic cells on a surface, (2) irreversible adhesion, (3) formation of microcolonies, (4) biofilm maturation, and (5) detachment and dispersion of cells [99]. The events that are of special significance for ocular infections and the treatment of biofilm infections will be discussed in greater detail, while the reader is referred to several excellent reviews for details on other biofilm-related subjects [19, 100, 101].

The biofilms involve the production of an extracellular matrix (ECM) that embedded the cells and, in some cases, binds the cells together and that can be composed of polysaccharides, lipopolysaccharides, proteins, or extracellular DNA [10]. This process may be active or passive, in that cells on the surface of an adherent colony that are lysed by the ejection of neutrophil antimicrobial factors may encase and protect siblings below in a matrix consisting simply of cell lysate. Whatever the nature of the matrix, its chemical and physical properties contribute to the differentiation of cells within the encased population, a process that can protect the bacteria from the action of antimicrobial agents, host immune responses, bacteriophages, and phagocytic amoeba [19].



As the microcolony grows through cell division or the recruitment of more planktonic cells, the biofilm grows and takes on a three-dimensional structure that often includes open water channels [19, 103].

The three-dimensional organization of the biofilm causes gradients of oxygen, pH, and nutrients, resulting in the development of different microniches [104, 105, 106]. The cell's individual physiological adaptations to these microniches result in physiological heterogeneity [98]. Cells near the surface of the biofilm will be exposed to more nutrients and oxygen and are therefore more metabolically active, while cells in the deep regions will be less active or even dormant. This heterogeneity results in a range of responses to antimicrobial agents, with metabolically active cells at the surface being rapidly killed, while more internal, dormant cells are comparatively unaffected [106]. This, together with potential effects on the diffusion of antimicrobial molecules within the biofilm, causes some cells in a biofilm to be recalcitrant to antimicrobial treatment, with antibiotic susceptibilities reduced by 10- to 1,000-fold compared to their planktonic counterparts [106].

The high local concentration of cells in a biofilm creates an ideal environment for information exchange through cell-to-cell communication and lateral gene transfer. Cell signaling mediated by secreted, accumulating messenger molecules, known as quorum sensing, allows bacteria to sense and respond to their environment and couple cell density and other environmental cues with gene expression in ways that allow adaptive phenotypic responses. Quorum sensing has been shown to be involved in the control of biofilm formation and the production of virulence and colonization factors in a variety of organisms of medical importance [106]. Cell-to-cell signaling is also involved in biofilm dispersion, which is of general and medical interest [107].

## 20. Practical strategies for coinfection diagnosis

The two leading causes of vision impairment worldwide are uncorrected refractive errors and cataract. Measures for managing those eye abnormalities frequently include the use of contact lenses and the placement of intraocular lenses and have enhanced the quality of life of millions of patients. Although the use of such devices is the great importance for correction of a variety of visual aberrations, these devices also provide a new surface on which many microbial pathogens can form biofilms (Table 2). As a result, device-related ocular infections are an important limitation of the success of such procedures. Moreover, many infections progress to secondary permanent sequelae that may lead to poor visual outcomes and occasionally loss of sight, such as acute bacterial endophthalmitis or corneal ulceration.

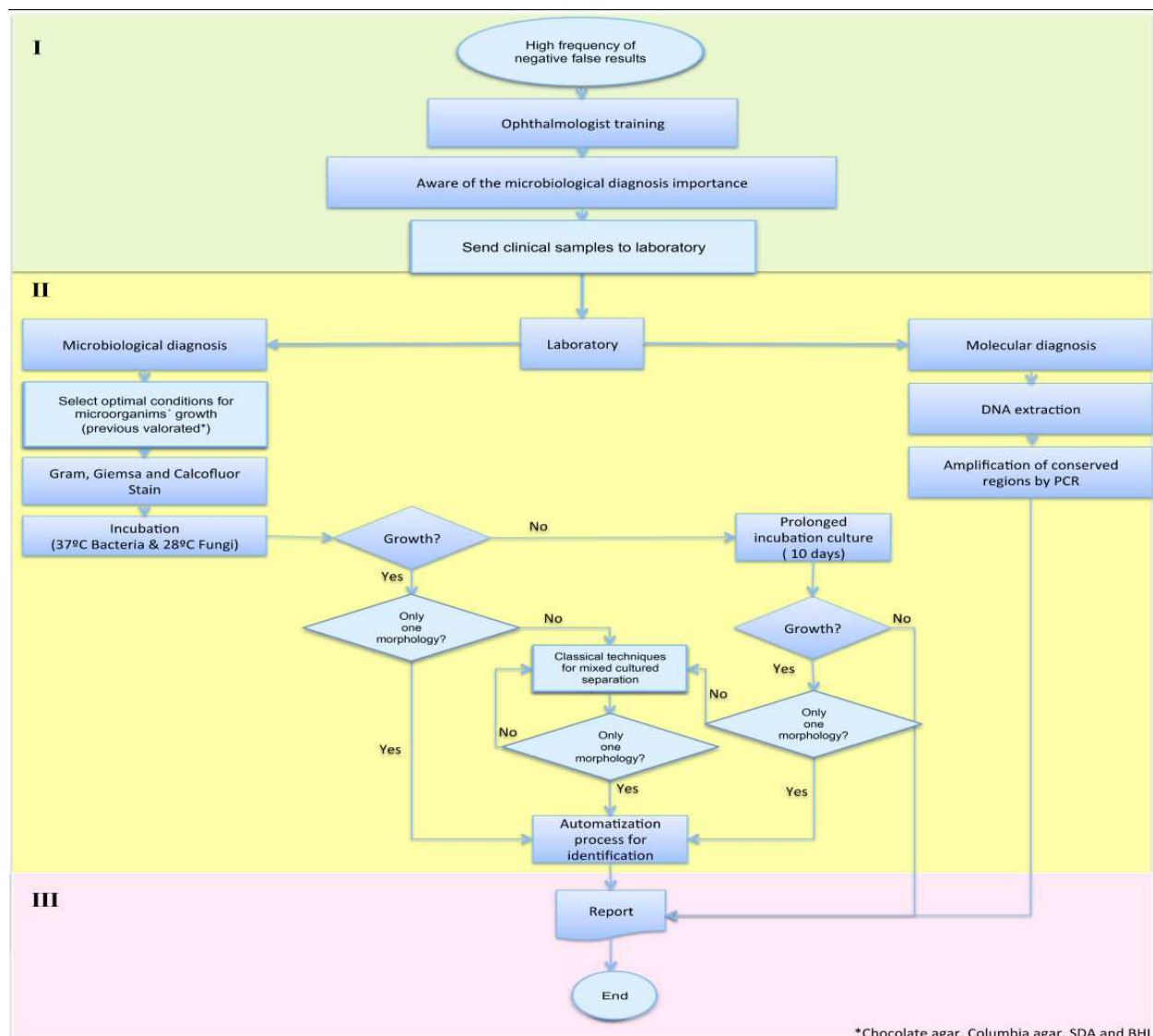
In all infection diseases, not only ocular infection, it is important to make sure of the microbiological diagnosis, especially when the coinfections are a large percentage of the total infections. The results will provide a report on the distribution and trends in microbiological and antibiotic sensitivity patterns that will affect the patient's treatment and prognosis. We have developed simple and practical strategies in each phase for ocular infection diagnosis, including the coinfections summarized in Figure 1.



Disease	Main causative agents of infection and/or found in the biofilms	Biofilm localization
Endophthalmitis	Coagulase-negative staphylococci and <i>Propionibacterium acnes</i>	Intraocular lens posterior capsule
Keratitis	<i>Staphylococcus aureus</i> and other staphylococcal species, <i>Pseudomonas aeruginosa</i> and <i>Serratia</i> spp. Fungi and <i>Acanthamoeba</i> spp. less frequently	Contact lens
	Viridans group Streptococci. Gram-negative bacilli and yeasts less frequently	Corneal stroma (crystalline keratopathy)
Scleral buckle infection	Gram-positive cocci and nontuberculous <i>Mycobacterium</i> spp.	Scleral buckles
Lacrimal system infections	<i>Staphylococcus</i> spp., <i>P. aeruginosa</i> , and <i>M. chelonae</i>	Lacrimal intubation devices
	<i>Staphylococcus</i> spp.	Punctual plugs
Periorbital infections	<i>Staphylococcus</i> spp. and mixed species biofilms	Sockets and orbital plates

**Table 2.** Biofilm-associated infections of the eye

A successful microbiological study consists in a correct identification, but, it begins since the pre-analytic phase, where the ophthalmologist plays an important role, so that, in our laboratory, we have improved an initial lesson to emphasize two principal things. The first thing is awareness of the importance to take the ocular sample before the intensive topical antibiotic treatment. It allows us to have greater chance of bacterial growth, although it has been described that scraping may accelerate disease resolution by enhancing antibiotic penetration and the therapeutic debridement of the necrotic tissue [108]. The second thing is that during the lesson we teach to the ophthalmologist the properly way to select, collect, and transport the sample to optimize the analysis and interpretation. For the collection, we prepared kits with all the necessary to take the sample for a molecular and microbiological diagnosis; the kit contains chocolate agar (ChA), Columbia agar (CA), and Brain-Heart Infusion (BHI); these are enrichment mediums for the exigent bacteria growth, like *Streptococcus* spp. and *Kocuria* spp.; the kit also contains Sabouraud dextrose agar (SDA), for fungi growth; different types of applicators (cotton, alginate, and rayon), a glass slide for the frotis, and finally a transport media for the molecular diagnosis are also included. On the other hand, we have accord with the ophthalmologist the conditions for the sample collection and storage that are summarized in Table 3, and especially, we have established the sequence for seeded the sample because of the small amount of material and small numbers of organisms obtainable from the eye: one swab for ChA, CA, and BHI, another swab for SDA, and the frotis for Gram, Wright, and Calcofluor stain. In conclusion, the pre-analytic phase is a continuous team work between the ophthalmologist and the laboratory staff.



**Figure 1.** Practical strategies for coinfection diagnosis during the three analytic phases. (I) The pre-analytic phase, when the ophthalmologist is training for selecting, collecting, and transporting the sample, plays an important role. (II) The analytic phase with microbiological and molecular techniques. In the microbiological diagnosis, the laboratory staff's experience is important to discern a pure from a mixed culture; molecular techniques are used to determine non-cultivable microorganisms. (III) The post-analytic phase, the final result in which the partnership between the ophthalmologist and the laboratory staff is reflected in the best outcomes for patients.

In the analytic phase, the sample could be processed by microbiology or by molecular techniques. About the microbiological diagnosis, the agar plates are checked every day, looking for bacterial or fungal growth. We have implemented a prolonged microorganism cultured of up to 15 days, because most of the hospital population includes multi-treatment patients, so that the microorganisms begin to grow until a week of incubation. Most of the times, the microorganisms involved in a coinfection are closely interacting, being impossible the identification in the automatized system (Vitek 2C, bioMérieux, France). The use of simple and classical microbiological techniques has allowed us to separate these interactions, for

Ocular infection	Sample	Equipment	Storage conditions
Keratitis/corneal ulcer	Limit of the corneal ulcer	Alginate applicator	37 °C→ChA, CA, BHI 28 °C→SDA
Conjunctivitis	Upper and lower eyelid conjunctiva	Cotton applicator	37 °C→ChA, CA, BHI 28 °C→SDA
Endophthalmitis and uveitis	Anterior chamber (aqueous humor)	Sterile syringes	4 °C→ syringes
	Vitreous humor		

Chocolate agar (ChA), Columbia agar (CA), Brain-Heart Infusion (BHI), Sabouraud dextrose agar (SDA), 37 °C for bacteria growth, 28 °C for fungi growth, and 4 °C for sample conservation

**Table 3.** Conditions for the sample collection and storage from ocular infections

example, the sonication (physical separation technique based on ultrasonic waves) and the use of selective media as MacConkey agar (MCK) and mannitol-salt agar (MSA) seeded by a perfect open streak for a good separation of the microorganisms, for positive and negative Gram bacteria, respectively. Talking about the fungi infections, the good sample collected by the ophthalmologists has been sufficient for a fungi growth and a direct observation of the macromorphology and micromorphology for the identification. However, the molecular techniques have revolutionized the ocular infection and coinfection diagnosis; these techniques are more sensitive, specific, and rapid and impact in the best outcome for the patient. The molecular techniques consist in the amplification of conserved regions of the different microorganisms involved in ocular infection, for example, Gram (+)/Gram (–) bacteria; Generic Fungi; herpes viruses I, II, and zoster; Cytomegalovirus; *Chlamydia* sp.; adenovirus; *Mycobacterium tuberculosis* complex (MTC) and no *Mycobacterium tuberculosis* complex (NTC); *Toxoplasma gondii*; and *Acanthamoeba* spp. by polymerase chain reaction (PCR). The PCR helps us for the identification of coinfection caused not only bacteria-bacteria or bacteria-fungi but also coinfection caused by viruses and parasites with bacteria or fungi.

Finally, the post-analytic phase consists of the interpretation of the results. Most laboratories do not report *Staphylococcus epidermidis* and *Staphylococcus aureus*, because they are part of the ocular surface microbiota; however, the laboratory staff of ocular microbiology knows that these microorganisms can be involved directly in the ocular infection, and these two microorganisms have been reported as the microorganisms most frequently isolated in infectious keratitis [109, 110]. It is important to consider the risk factor associated before deciding whether the microorganisms isolated are responsible for the infection or are a contamination.

In conclusion, the diagnosis of infectious disease is best achieved by applying in-depth knowledge of medical and laboratory science by integrating a strategic view of host-parasite interactions. Clearly, the best outcomes for patients are the result of strong partnerships between the clinician and the laboratory specialist [111].

## 21. Conclusion

The relationship between microorganisms has a long evolutionary history. The ability of microorganisms to interact conferred the possibility to collaborate and to adapt within a wider spectrum of environmental conditions. These circumstances have a direct impact on the clinical presentation as well as the dynamics of infection in the population.

Delay in diagnosis affects the sensitivity to specific treatments and the evolution of infection. The rate of recovery could be slow and morbid, leaving serious sequelae with the risk of loss of vision. Advances in methods for detecting infectious organisms and molecular microbiology have facilitated the recognition of the interactions among pathogens found in coinfections in the human eye. The acute period of coinfection is determinant to identify the coinfecting microorganisms. Awareness in the medical field and particularly in ophthalmology of lesions that do not cover the conditions of a pathognomonic clinical picture should be resolved with molecular biology techniques together with classical techniques of microorganism recognition, until final identification, if possible.

In this chapter, we proposed a strategy for reducing the uncertainty of the presence of two or more microorganisms affecting the eye. This has been implemented in our laboratory and has increased the possibility of isolation and identification.

In addition, the biofilm of each combination of pathogens must be studied molecularly to understand its particular adhesion and aggregation, possible mutations, and strategies for evasion or elimination of antimicrobial. Together with pharmacodynamics, *in vivo* studies will facilitate the application of different antimicrobial dosages to successfully remove coinfecting microorganisms.

## Author details

Carlos Alberto Pantoja-Meléndez<sup>1,2\*</sup>, Victor M. Bautista-de Lucio<sup>1</sup>, Mariana Ortiz-Casas<sup>1</sup>, Jonathan Quevedo-Martínez<sup>1</sup> and Herlinda Mejía-López<sup>1</sup>

\*Address all correspondence to: [linda.mejia@institutodeoftalmologia.org](mailto:linda.mejia@institutodeoftalmologia.org)

1 Institute of Ophthalmology Conde de Valenciana, Mexico

2 National Autonomous University of Mexico, School of Medicine, Public Health Department, Mexico

## References

- [1] Whitcher J, Srinivasan M. "Corneal blindness: a global perspective". Bull World Health Organ. 2001; 79: p. 214-221.

- [2] Birger R, Kouyos R, Cohen T, Griffiths S, Huijben S, Mina M, *et. al.* The potential impact of coinfection on antimicrobial chemotherapy and drug resistance. *Trends Microbiol.* 2015; 15: p. 106-107.
- [3] Frey-Klett P, Burlinson P, Deveau A, Barret M, Tarkka M, Sarniguet A. Bacterial-Fungal Interactions: Hyphens between Agricultural, Clinical, Environmental, and Food Microbiologists. *Microbiol Mol Biol Rev.* 2011 Dec; 75 (4): 583–609
- [4] Russler S, Tapper M, Knox K, Liepins A, Carrigan D. Pneumonitis associated with coinfection by human herpesvirus 6 and *Legionella* in an immunocompetent adult. *Am J Pathol.* 1991; 138: p. 1405-1411.
- [5] Day T, Graham A, A R. Evolution of parasite virulence when host responses cause disease. *Proc Biol Sci.* 2007; 274: p. 2685-2692.
- [6] Jindal A, Moreker M, Pathengay A, Khera M, Jalali A, Majji A, *et. al.* Polymicrobial endophthalmitis: prevalence, causative organisms, and visual outcomes. *J Ophtalmic Inflamm Infect.* 2013; 3: p. 6.
- [7] Iwalokun B, Oluwadum A, Akisinde K, Niemogha M, Nwaokorie F. Bacteriologic and plasmid analysis of etiologic agents of conjunctivitis in Lagos, Nigeria. *J Ophthalmic Inflamm Infect.* 2011; 3: p. 95-103.
- [8] Huang Y, Yang B, Li W. Defining the normal core microbiome of conjunctival microbial communities. *Clin Microbiol Infect.* 2016; 16: p. 30065-30069.
- [9] Lim N, Lim D, Ray M. Polymicrobial versus monomicrobial keratitis: a retrospective comparative study. *Eye Contact Lens.* 2013; 39: p. 348-354.
- [10] Gopinathan U, Sharma S, Garg P, Rao G. Review of epidemiological features, microbiological diagnosis and treatment outcome of microbial keratitis: experience of over a decade. *Indian J Ophthalmol.* 2009; 57: p. 273-279.
- [11] Basak S, Mohanta A, Bhowmick A. Epidemiological and microbiological diagnosis of suppurative keratitis in Gangetic West Bengal, eastern India. *Indian J Ophthalmol.* 2005; 53: p. 17-22.
- [12] Bharathi M, Ramakrishnan R, Vasu R, Meenakshi PR. Aetiological diagnosis of microbial keratitis in South India - A study of 1618 cases. *Indian J Med Microbiol.* 2002; 20: p. 19-24.
- [13] Jones D. Polymicrobial keratitis. *Tr Am Ophth Soc.* 1981; 79: p. 153-157.
- [14] Brand A, Barnes J, K M, Odds F, Gow N. Cell wall glycans and soluble factors determine the interactions between the hyphae of *Candida albicans* and *Pseudomonas aeruginosa*. *FEMS Microbiol Lett.* 2008; 287: p. 48-55.
- [15] Seidler M, Salvenmoser S, Muller F. *Aspergillus fumigatus* forms biofilms with reduced antifungal drug susceptibility on bronchial epithelial cells. *Antimicrob Agents Chemother.* 2008; 52: p. 4130-4136.



- [16] Loussert C, Schmitt C, Prevost M. In vivo biofilm composition of *Aspergillus fumigatus*. *Cell Microbiol*. 2010; 12: p. 405-410.
- [17] Mah T, O'Toole G. Mechanisms of biofilm resistance to antimicrobial agents. *Trends Microbiol*. 2001; 9: p. 34-39.
- [18] Steward P, Costerton J. Antibiotic resistance of bacteria in biofilms. *Lancet*. 2001; 14: p. 135-138.
- [19] Kıvanç SA, Kıvanç M, Bayramlar H. Microbiology of corneal wounds after cataract surgery: biofilm formation and antibiotic resistance patterns. *J Wound Care*. 2016; 25: 12: p. 14-19.
- [20] Fröhlich S, Miño de Kaspar H, Grasbon T, Möhring C, Klauss V, Kampik A. Bacterial keratitis. Microbiological analysis as a principle for therapeutic recommendations. *Ophthalmologe*. 1999; 7: p. 459-464.
- [21] Yeh D, Stinnett S, Afshari N. Analysis of bacterial cultures in infectious keratitis, 1997 to 2004. *Am J Ophthalmol*. 2006; 6: p. 1066-1068.
- [22] Kim J, H S, Song J. Infectious keratitis caused by *Stenotrophomonas maltophilia* and yeast simultaneously. *Cornea*. 2006; 10: p. 1234-1236.
- [23] Qiu W, Yao Y. Mycotic keratitis caused by concurrent infections of *Exserohilum mcginnsii* and *Candida parapsilosis*. *BMC Ophthalmol*. 2013; 13: p. 37-40.
- [24] Katragkou A, Z P, Perlin D, Kontoyiannis D, Walsh T, Roilides E. *Exserohilum* infection Review of 48 cases before the 2012 United States outbreak. *The pediatric Infectious Disease Journal*. 2005; 24: p. 939-941.
- [25] Yokoi N, Okada K, Sugita J, Kinoshita S. Acute conjunctivitis associated with biofilm formation on a punctal plug. *Jpn J Ophthalmol*. 2000; 44: p. 559-560.
- [26] Taff HMK, Edward J, Andes D. Mechanisms of *Candida* biofilm drug resistance. *Future Microbiol*. 2013; 8: p. 1325-1337.
- [27] Hayashi Y, Eguchi H, Toibana T, Mitamura Y, Yaguchi T. Polymicrobial sclerokeratitis caused by *Scedosporium apiospermum* and *Aspergillus cibarius*. *Cornea*. 2014; 33: p. 875-877.
- [28] Schuster F, Visvesvara G. Free-living amoebae as opportunistic and non-opportunistic pathogens of human and animals. *Int J Parasitol*. 2004; 34: p. 1001-1027.
- [29] Galarza C, Gutiérrez E, Uribe M, Ramos W, Ortega A, Ávila J, *et. al.* Amebas de vida libre en lesiones cutaneas. Reporte de 4 casos. *Dermatol Perú*. 2006; 16: p. 36-40.
- [30] Scheid P. Relevance of free-living amoebae as hosts for phylogenetically diverse microorganisms. *parasitol Res*. 2014; 113: p. 2407-2414.



- [31] Barker J, Lambert P, Brown M. Influence of intra-amoebic and other growth conditions on the surface properties of *Legionella pneumophila*. *Infect Immun*. 1993; 61: p. 3503-3510.
- [32] Lim N, Goh D, Bunce C, Xing W, Fraenkel G, Poole T, *et. al*. Comparison of polyhexamethylene biguanide and chlorhexidine as monotherapy agents in the treatment of *Acanthamoeba* keratitis. *Am J Ophthalmol*. 2008; 145: p. 130-135.
- [33] Scheid P. Mechanism of intrusion of a microsporidian-like organism into the nucleus of host amoebae (*Vannella* sp.) isolated from a keratitis patient. *Parasitol Res*. 2007; 101: p. 1097-1102.
- [34] Scheid P, Hauröder B, Michel R. Investigations of an extraordinary endocytobiont in *Acanthamoeba* sp., development and replication. *Parasitol Res*. 2010; 106: p. 1371-1377.
- [35] Qureshi M, Perez A, Madayag R, Bottone E. Inhibition of *Acanthamoeba* species by *Pseudomonas aeruginosa*: rationale for their selective exclusion in corneal ulcers and contact lens care systems. *J Clin Microbiol*. 1993; 31: p. 1908-1910.
- [36] Bottone E, R M, Qureshi M. *Acanthamoeba* keratitis: synergy between amebic and bacterial cocontaminants in contact lens care systems as a prelude to infection. *J Clin Microbiol*. 1992; 30: p. 2447-2450.
- [37] Lorenzo-Morales J, Khan N, Walochnik J. An update on *Acanthamoeba* keratitis: diagnosis, pathogenesis and treatment. *Parasite*. 2015; 22: p. 10.
- [38] Sharma R, Jhanji V, Satpathy G, Sharma N, Khokhar S, Agarwal T. Coinfection with *Acanthamoeba* and *Pseudomonas* in contact lens-associated keratitis. *Optom Vis Sci*. 2013; 90: p. 53-55.
- [39] Michel R, Hauröder B. Isolation of an *Acanthamoeba* strain with intracellular *Burkholderia pickettii* infection. *Zentralbl Bakteriol*. 1997; 285: p. 541-547.
- [40] Mauger T, Craig E. Combined *acanthamoeba* and *Stenotrophomonas maltophilia* keratitis treated with a conjunctival flap followed by penetrating keratoplasty. *Cornea*. 2006; 25: p. 631-633.
- [41] Hong J, Ji J, Xu J, Cao W, Liu Z, Sun X. An unusual case of *Acanthamoeba Polyphaga* and *Pseudomonas Aeruginosa* keratitis. *Diagn Pathol*. 2014; 9: p. 105.
- [42] Lone R, Syed K, Abdul R, Sheikh S, Shah F. Unusual case of methicillin resistant *staphylococcus aureus* and *Acanthamoeba* keratitis in a non-contact lens wearer from Kashmir, India. *BMJ Case Re*. 2009; p. 8.
- [43] Dini L, Cockinos C, Frean J, Niszl I, Markus M. Unusual case of *acanthamoeba polyphaga* and *Pseudomonas aeruginosa* keratitis in a contact lens wearer from Gauteng, South Africa. *L Clin Microbiol*. 2000; 38: p. 826-829.
- [44] Tu E, Joslin C, Nijm L, Feder R, Jain S, Shoff M. Polymicrobial keratitis: *Acanthamoeba* and infectious crystalline keratopathy. *Am J Ophthalmol*. 2009; 148: p. 13.

- [45] Gupta S, Shrivastava R, tandom R, Gogia V, Agarwal P, Satpathy G. Role of voriconazole in combined acanthamoeba and fungal corneal ulcer. *Cont Lnes Anterior Eye*. 2011; 34: p. 287-289.
- [46] Rumelt S, Cohen I, Lefler E, Rehany U. Corneal co-infection with *Scedosporium apiospermum* and *Acanthamoeba* after sewage-contaminated ocular injury. *Cornea*. 2001; 20: p. 112-116.
- [47] Tien S, Sheu M. Treatment of *Acanthamoeba* keratitis combined with fungal infection with polyhexamethylene biguanide. *Kaohsiung J Med Sci*. 1999; 15: p. 665-673.
- [48] Froumis N, Mondino B, Glaswos B. *Acanthamoeba* keratitis associated with fungal keratitis. *Eye Contact Lens*. 2008; 34: p. 185-187.
- [49] Slade D, Johnson J, Tabin G. *Acanthamoeba* and fungal keratitis in a woman with a history of Intacs corneal implants. *Eye Contact Lens*. 2008; 34: p. 185-187.
- [50] Dong Q, Brulc J, Iovieno A, Bates B GA, Miller D, Revanna K, *et. al.* Diversity of bacteria at healthy human conjunctiva. *Invest Ophthalmol Vis Sci*. 2011; 52: p. 5408-5413.
- [51] Dalfré J, Rodrigues J, Donato B, Giancoli A, De Carvalho J, De Andrade D, *et. al.* Fungal microbiota of normal conjunctiva, sugar-cane and anemophilous fungi of the region of Monte Belo- Minas Gerais. *Arq Bras Oftalmol*. 2007; 70: p. 445-449.
- [52] Moreno N, Moreno R, Sousa L. Aerobic bacterial microbiota of the conjunctiva in diabetic patients with normal and altered glycated hemoglobin levels in two regions in Brazil. *Arq Bras Oftalmol*. 2014; 77: p. 351-354.
- [53] Schabereiter-Gurtner C, Maca S, Rölleke S, Nigl K, Lukas J, Hirschl A, *et. al.* 16S rDNA-based identification of bacteria from conjunctival swabs by PCR and DGGE fingerprinting. *Invest Ophthalmol Vis Sci*. 2001; 42: p. 1164-1171.
- [54] Tappe D, Mueller A, WeiBbrich B, Schubert J, Schargus M, Stich A. Severe conjunctivitis due to multidrug-resistant *Neisseria gonorrhoeae* and adenovirus 53 coinfection in a traveler returning from Thailand. *J Travel Med*. 2013; 20: p. 403-406.
- [55] Mellman-Rubin T, Kowaski R, Uhrin M, Gordon Y. Incidence of adenoviral and chlamydial coinfection in acute follicular conjunctivitis. 1995; 119: p. 652-654.
- [56] Galvis V, Tello A, Guerra A, Acuña M, Villarreal D. Antibiotic susceptibility patterns of bacteria isolated from keratitis and intraocular infections at Fundación Oftalmológica de Santander (FOSCAL. Florida Blanca Colombia Biomedica. 2014; 34: p. 23-33.
- [57] Gupta A, Gupta V, Dogra M, Panday S, Ray P. Chkraborty A. Spectrum and clinical profile of post cataract surgery endophthalmitis in north India. *Indian J Ophthalmol*. 2003;51: p.139-145.

- [58] Pijl B, Theelen T, Tilanus M, Rentenaar R, Crama N. Acute endophthalmitis after cataract surgery: 250 consecutive cases treated at a tertiary referral center in the Netherlands. *Am J Ophthalmol*. 2010; 149: p. 482-487.
- [59] Gharamah AA, Moharram AM, Ismail MA, Al-Hussaini AK. Bacterial and fungal endophthalmitis in upper Egypt: related species and risk factors. *Asian Pac J Trop Biomed*. 2012; 2: p. 655-659.
- [60] Kunimoto D, Das T, Sharma S, Jalali S, Majji A, Gopinathan U, *et. al*. Microbiologic spectrum and susceptibility of isolates: part II. Posttraumatic endophthalmitis. Endophthalmitis Research Group. *Am J Ophthalmol*. 1999; 128: p. 242-244.
- [61] Long C, Liu B, Xu C, Jing Y, Yuan Z, Lin X. Causative organisms of post-traumatic endophthalmitis: a 20-year retrospective study. *BMC Ophthalmol*. 2014; 25: p. 34.
- [62] Duan F, Wu K, Liao J, Zheng Y, Yuan Z, Tan J, Lin X. Causative Microorganisms of Infectious Endophthalmitis: A 5-Year Retrospective Study. *J Ophthalmol*. 2016; 2016: 1-7.
- [63] Streilen J. Ocular immune privilege: the eye takes a dim but practical view of immunity and inflammation. *J Leukoc Biol*. 2003; 74: p. 179-185.
- [64] Matricardi P, Rosmini F, Riondino S, Fortini M, Ferrigno L, Rapicetta M, *et. al*. Exposure to foodborne and orofecal microbes versus airborne viruses in relation to atopy and allergic asthma: epidemiological study. *BMJ*. 2000; 320: p. 412-417.
- [65] Kurata A. Hygiene hypothesis: why south/north geographical differences in prevalence of asthma and sarcoidosis? *Med Hypotheses*. 2012; 79: p. 363-364.
- [66] von Hertzen LC. Puzzling associations between childhood infections and the later occurrence of asthma and atopy. *Ann Med*. 2000; 32: p. 397-400.
- [67] Kerr N, Stern G. Bacterial keratitis associated with vernal keratoconjunctivitis. *Cornea*. 1992; 11: p. 355-359.
- [68] Rolinski J, Hus I. Immunological aspects of acute and recurrent herpes simplex keratitis. *J Immunol Res*. 2014; p. 51.
- [69] Stric L, Wald A, Celum C. Management of herpes simplex virus type 2 infection in HIV type 1-infected persons. *Clin Infect Dis*. 2006; 43: p. 347-356.
- [70] Faber D, Wiley C, Lynn G, Gross J, Freeman W. Role of HIV and CMV in the pathogenesis of retinitis and retinal vasculopathy in AIDS patients. *Invest Ophthalmol Vis Sci*. 1992; 33: p. 2345-2353.
- [71] Radu L, Serban R, Cornăcel C, Cioboata M, Anghel A. Cytomegalovirus retinitis in HIV/AIDS patients. *J Med Life*. 2014; 15: p. 237-240.

- [72] Freigassner P, Ardjomand N, Radner H, El-Shabrawi Y. Coinfection of the retina by Epstein-Barr virus and cytomegalovirus in an AIDS patient. *Am J Ophthalmol.* 2002; 134: p. 275-257.
- [73] Skolnik P, Pomerantz R, De la Monte S, Lee S, Hsiung G, Foos R, *et. al.* Dual infection of retina with human immunodeficiency virus type 1 and cytomegalovirus. *Am J Ophthalmol.* 1989; 107: p. 361-372.
- [74] Rummelt V, Rummelt C, Jahn G, Wenkel H, Sinzger C, Mayer U, *et. al.* Triple retinal infection with human immunodeficiency virus type 1, cytomegalovirus, and herpes simplex virus type 1. Light and electron microscopy, immunohistochemistry, and in situ hybridization. *Ophthalmology.* 1994; 101: p. 270-279.
- [75] Kim J, Singer E, Bonelli L, Klausner J. A case of primary HIV type 1 and cytomegalovirus coinfection presenting with widespread clinical disease. *J Int Assoc Provid AIDS Care.* 2014; 13: p. 196-199.
- [76] Matoba A. Polymicrobial keratitis secondary to *Burkholderia ambifaria*, enterococcus, and staphylococcus aureus in a patient with herpetic stromal keratitis. *Am J Ophthalmol.* 2003; 136: p. 748-749.
- [77] Tandon R, Vajpayee R, Gupta V, Vajpayee M, Satpathy G, Dada T. Polymicrobial keratitis in an HIV-positive patient. *Indian J Ophthalmol.* 2003; 51: p. 87-88.
- [78] Wayne P. Reference Method for Broth dilution antifungal susceptibility testing of filamentous fungi. 2nd ed. USA; 2008.
- [79] Abdelillah A, Houcine B, Halima D, Meriem C, Imane Z, Eddine S, *et. al.* Evaluation of antifungal activity of free fatty acids methyl esters fraction isolated from Algerian *Linum usitatissimum* L. seeds against toxigenic *Aspergillus*. *Asian Pac J Trop Biomed.* 2013; 3: p. 443-448.
- [80] Ponce D, Bautista-de-Lucio V, Santacruz-Valdés C, Climent-Flores A, Rodríguez-Tovar A, Robles-Contreras A, *et. al.* Effect of simultaneous treatment of quinolones and antifungal drugs on fungal-bacterial coculture. In ARVO 2012.
- [81] Pradhan L, Sharma S, Nalamada S, Sahu S, DS, Garg P. Natamycin in the treatment of keratomycosis: correlation of treatment outcome and in vitro susceptibility of fungal isolates. *Indian J Ophthalmol.* 2011; 59: p. 512-514.
- [82] Pate J, Jones D, Wilhelmus K. Prevalence and spectrum of bacterial co-infection during fungal keratitis. *Br J Ophthalmol.* 2006; 90: p. 289-292.
- [83] Mosquera J, Denning D. Azole cross-resistance in *Aspergillus fumigatus*. *Antimicrob Agents Chemother.* 2002; 46: p. 556-557.
- [84] Hanet M, Jamart J, Chaves A. Fluoroquinolones or fortified antibiotics for treating bacterial keratitis: systematic review and meta-analysis of comparative studies. *Can J Ophthalmol.* 2012; 47: p. 493-499.

- [85] Jin K, Jeon H, Hyon J, Wee W, Suh W, Shin Y, *et. al.* A case of fungal keratitis and onychomycosis simultaneously infected by *Trichophyton* species. *BMC*. 2014; 11: p. 37-90.
- [86] Tallarida R. Drug synergism: its detection and applications. *J Pharmacol Exp Ther*. 2001; 298: p. 865-872.
- [87] Nakajima R, Kitamura A, Someya K, Tanaka M, Sato K. In vitro and in vivo antifungal activities of DU-6859a, a fluoroquinolone, in combination with amphotericin B and fluconazole against pathogenic fungi. *Antimicrob Agents Chemother*. 1995; 39: p. 1517-1521.
- [88] Stergiopoulou T, Meletiadis J, Sein T, Papaioannidou P, Tsiouris I, Roilides E, *et. al.* Comparative pharmacodynamic interaction analysis between ciprofloxacin, moxifloxacin and levofloxacin and antifungal agents against *Candida albicans* and *Aspergillus fumigatus*. *J Antimicrob Chemother*. 2009; 63: p. 343-348.
- [89] Sasaki E, Maesaki S, Miyazaki Y, Yanagihara K, Tomono K, Tashiro T, *et. al.* Synergistic effect of ofloxacin and fluconazole against azole-resistant *Candida albicans*. *J Infect Chemother*. 2000; 6: p. 151-154.
- [90] Costerton J, Geesey G, Cheng K. How bacteria stick. *Sci Am*. 1978; 238: p. 86-95.
- [91] Hall-Stoodley L, Costerton J, Stoodley P. Bacterial biofilms: From the natural environment to infectious diseases. *Nat Rev Microbiol*. 2004; 2: p. 95-108.
- [92] Harrison J, Ceri H, Turner R. Multimetal resistance and tolerance in microbial biofilms. *Nat Rev Microbiol*. 2007; 5: p. 928-938.
- [93] Health. NLo. Research on microbial biofilms (PA-03-047). [Online] . 2002; [cited 2015 January 10.] Available from: HYPERLINK "<http://grants.nih.gov/grants/guide/pafiles/PA-03-047.html>"<http://grants.nih.gov/grants/guide/pa-files/PA-03-047.html>.
- [94] Donlan R, Costerton J. Biofilms: Survival mechanisms of clinically relevant microorganisms. *Clin Microbiol Rev*. 2002; 15: p. 167-193.
- [95] Annous B, Fratamico P, Smith J. Scientific status summary. *J Food Sci*. 2009; 74: p. R24-37.
- [96] Hooshangi S, Bentley W. From unicellular properties to multicellular behavior: Bacteria quorum sensing circuitry and applications. *Curr Opin Biotechnol*. 2008; 19: p. 550-555.
- [97] Stewart P, Franklin M. Physiological heterogeneity in biofilms. *Nat Rev Microbiol*. 2008; 6: p. 199-210.
- [98] Watnick P, Kolter R. Biofilm, city of microbes. *J Bacteriol*. 2000; 182: p. 2675-2679.
- [99] Fux CA, Costerton JW, Stewart PS, Stoodley P. Survival strategies of infectious biofilms. *Trends Microbiol*. 2005; 13: p. 34-40.



- [100] Costerton J, Stewart P, biofilms B. Battling biofilms. *Sci Am.* 2001; 285: p. 74-81.
- [101] Behlau I, Gilmore M. Microbial biofilms in ophthalmology and infectious disease. *Arch Ophthalmol.* 2008; 126: p. 1572-1581.
- [102] H, Wingender J. The biofilm matrix. *Nat Rev Microbiol.* 2010; 8: p. 623-633.
- [103] Sauer K, Camper A, Ehrlich G, Costerton J, Davies D. *Pseudomonas aeruginosa* displays multiple phenotypes during development as a biofilm. *J Bacteriol.* 2002; 184: p. 1140-1154.
- [104] Hall-Stoodley L, Stoodley P. Evolving concepts in biofilm infections. *Cell Microbiol.* 2009; 11: p. 1034-1043.
- [105] Davies D. Understanding biofilm resistance to antibacterial agents. *Nat Rev Drug Discov.* 2003; 2: p. 114-122.
- [106] Spoering A, Gilmore M. Quorum sensing and DNA release in bacterial biofilms. *Curr Opin Microbiol.* 2006; 9: p. 133-137.
- [107] Kaplan J. Biofilm dispersal: Mechanisms, clinical implications, and potential therapeutic uses. *J Dent Res.* 2010; 89: p. 205-218.
- [108] Allan B, Garth J. Strategies for the management of microbial keratitis. *Br J Ophthalmol.* 1995; 79: p. 777-786.
- [109] Hernandez-Camarena JC, Graue-Hernandez EO, Ortiz-Casas M, Ramirez-Miranda A, Navas A, Pedro-Aguilar L, *et al.* Trends in Microbiological and Antibiotic Sensitivity Patterns in Infectious Keratitis: 10-Year Experience in Mexico City. *Cornea.* 2015; 34: p. 778-785.
- [110] Lichtinger A, Yeung S, Kim P. Shifting trends in bacterial keratitis in Toronto: an 11-18 year review. *Ophthalmology.* 2012; 119: p. 1785-1790.
- [111] Baron E, Miller M, Weinstein M. A Guide to Utilization of the Microbiology Laboratory for Diagnosis of Infectious Diseases: 2013 Recommendations by the Infectious Diseases Society of America (IDSA) and the American Society for Microbiology; 2013.



