

We are IntechOpen, the world's leading publisher of Open Access books Built by scientists, for scientists

6,900

Open access books available

186,000

International authors and editors

200M

Downloads

Our authors are among the

154

Countries delivered to

TOP 1%

most cited scientists

12.2%

Contributors from top 500 universities



WEB OF SCIENCE™

Selection of our books indexed in the Book Citation Index
in Web of Science™ Core Collection (BKCI)

Interested in publishing with us?
Contact book.department@intechopen.com

Numbers displayed above are based on latest data collected.
For more information visit www.intechopen.com



Epidemiology and Emergence of Schmallenberg Virus

Part 1: Origin, Transmission and Differential Diagnosis

Fernando Esteves, João Rodrigo Mesquita,
Cármén Nóbrega, Carla Santos, António Monteiro,
Rita Cruz, Helena Vala and Ana Cláudia Coelho

Additional information is available at the end of the chapter

<http://dx.doi.org/10.5772/64741>

Abstract

Schmallenberg virus (SBV) is a novel *Orthobunyavirus* causing mild clinical signs in cows and malformations in aborted and neonatal ruminants in Europe. SBV belongs to the family Bunyaviridae and is transmitted by biting midges. This new virus was identified for the first time in the blood samples of cows in the city of Schmallenberg in North-Rhine-Westphalia in November 2011. Since then the virus spread to several European countries. Here we describe the origin and emergence, as well as the transmission and the differential diagnosis of this virus, now known to be a serious threat to Veterinary Public Health.

Keywords: Schmallenberg virus, emerging infections, epidemiology

1. Introduction

1.1. The origin of Schmallenberg virus

In 2011, an unidentified disease in cattle was reported in Germany and the Netherlands [1]. Hyperthermia and drop in milk production were reported in adult dairy cows in north-west Germany and the Netherlands, and in some cases, transient diarrhoea was also recorded in the Netherlands [2]. Farmers and veterinarians in North Rhine-Westphalia, Germany, and in the Netherlands reported an unidentified disease in dairy cattle with a short period of clear clinical signs to the animal health services, local diagnostic laboratories and national research institutes

[1]. All classical endemic and emerging viruses, such as pestiviruses, bovine herpesvirus type-1 (BHV-1), foot-and-mouth disease (FMD) virus, bluetongue virus (BTV), epizootic haemorrhagic disease (EHD) virus, Rift Valley fever (RVF) virus and bovine ephemeral fever (BEF) virus, could be excluded as the causative agent [1].

The first identification of this new virus succeeded in samples of cattle housed next to a small town in Germany with 25,000 inhabitants, called Schmallenberg, in North Rhine-Westphalia (Figure 1).

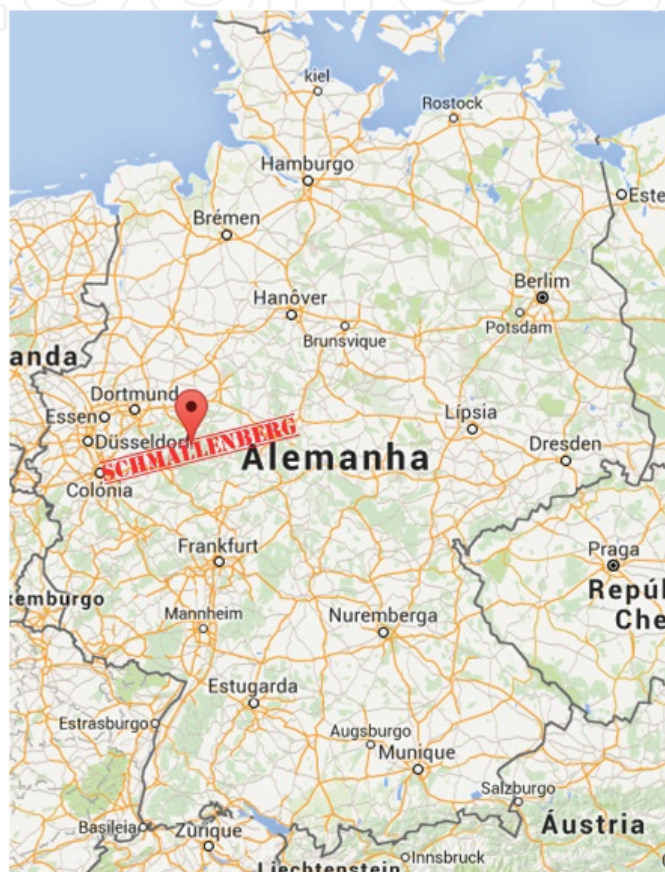


Figure 1. Location of Schmallenberg city, North Rhine-Westphalia, Germany.

At that time and following elimination of the usual causes of such clinical signs in cattle, blood samples from three bovine were subjected to the new technology of deep sequencing known as metagenomic analysis, which allows the sequencing of all nucleic acids present in a sample [3]. Metagenomics is the application of modern genomics techniques to the study of communities of microbial organisms directly in their natural environments, bypassing the need for isolation and lab cultivation of individual species [4]. As is typical with this approach, a large amount of host genomic and known bacterial sequences were identified, the latter most likely as a consequence of prolonged sample storage. However, present within the samples were genetic sequences from a novel *Bunyavirus* which had the highest homology to viruses of the Simbu serogroup virus [3]. This novel virus was named as Schmallenberg virus (SBV),

characterized by a syndrome in ruminants referred to the arthrogryposis–hydranencephaly syndrome (AHS), resulting in abortions, stillbirths and congenital defects in newborn ruminants after infection during pregnancy [5].

1.2. Structure and taxonomy

SBV is now known to belong to the genus *Orthobunyavirus* and the Bunyaviridae family, as confirmed from electron microscopy [1, 3, 6]. Most viruses of this genus have not yet been well characterized [3]. SBV is also a member of Simbu serogroup, one of the largest of the 18 serogroups which constitute the genus [3]. Simbu serogroup includes the virus Shamonda, Akabane and Aino; however, the most related to SBV are virus Sathuperi and Douglas [6]. Its reorganization capability has also been suggested [1], especially when taken into account that many strains of *Orthobunyavirus* suffered re-assortment [3, 7].

SBV is typical of the Bunyaviridae, characterized by a tripartite negative-sense RNA genome that encodes four structural and two non-structural proteins [8]. The SBV is an enveloped virus with a surface of glycoproteins [6]. The diameter of these viruses is approximately 100 nm. Their genetic structure comprises of three segments of single-stranded negative-sense RNA: large (L) with 6865 nucleotides, medium (M) with 4415 nucleotides and small (S) with 830 nucleotides (**Figure 2**) [1, 3].

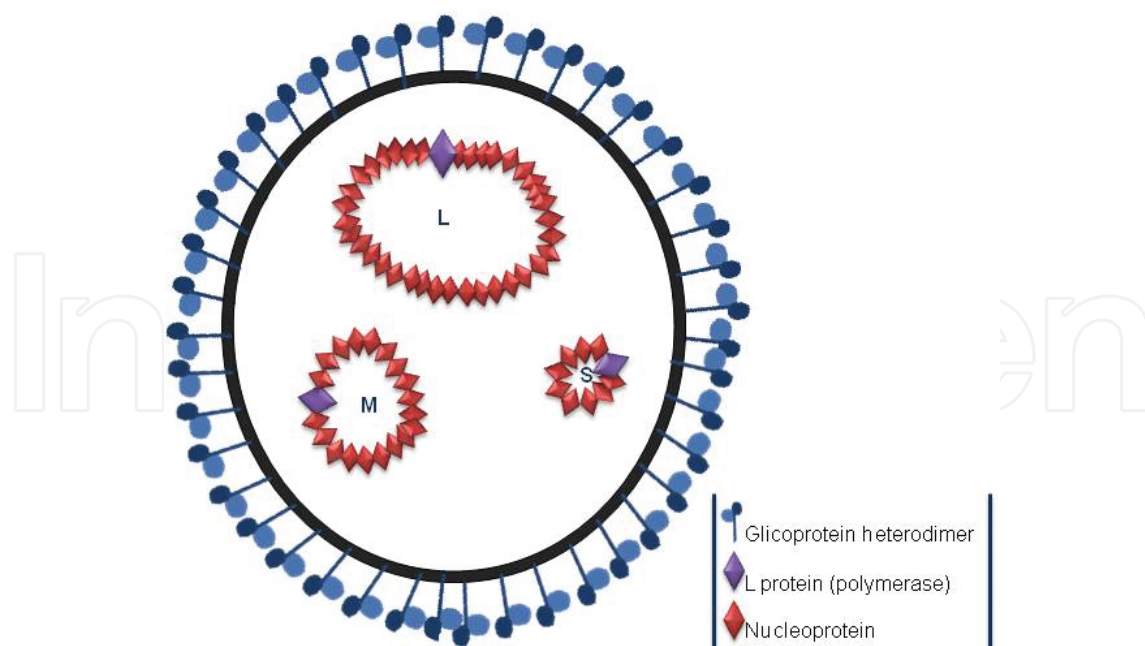


Figure 2. Diagram illustrating a particle of Schmallenberg virus with glycoproteins (Gn and Gc) and the three segments of RNA (small (S), medium (M) and large (L) in a circular form in association with nucleoprotein and the 'L' polymerase protein (adapted from Tarlinton et al. [3]).

The large (L) segment encodes the viral RNA-dependent RNA-polymerase or L protein, the medium (M) segment encodes the virion glycoproteins Gn and Gc, and the small (S) segment encodes the nucleoprotein (N). Non-structural proteins are encoded by some viruses on the M (NSm protein) and by some on the S (NSs protein) segment [8].

The full genome sequence of the first described SBV is provided under the Genbank accession number HE649912 and has a length of 6864 base pairs [1].

1.3. The emergence of Schmallenberg virus

From November 2011 to date, the disease spread rapidly and widely throughout Europe. Since 2011 cases have been reported: Belgium (December 2011), the UK and France (January 2012), Luxembourg and Italy (February 2012), Spain (March 2012), Denmark (June 2012), Switzerland and Sweden (July 2012), Austria and Finland (September 2012), Ireland and Poland (October 2012), Norway (November 2012), Czech Republic (December 2012), Estonia, Slovenia, Hungary and Croatia (January 2013), Latvia (April 2013), Greece (March 2013), Russia (May 2013), Serbia (June 2013) and Romania (July 2013) [9]. There are also reports of cases outside Europe [10]. Recently a new study shows the circulation of the virus in Portugal [11] (**Figure 3**).

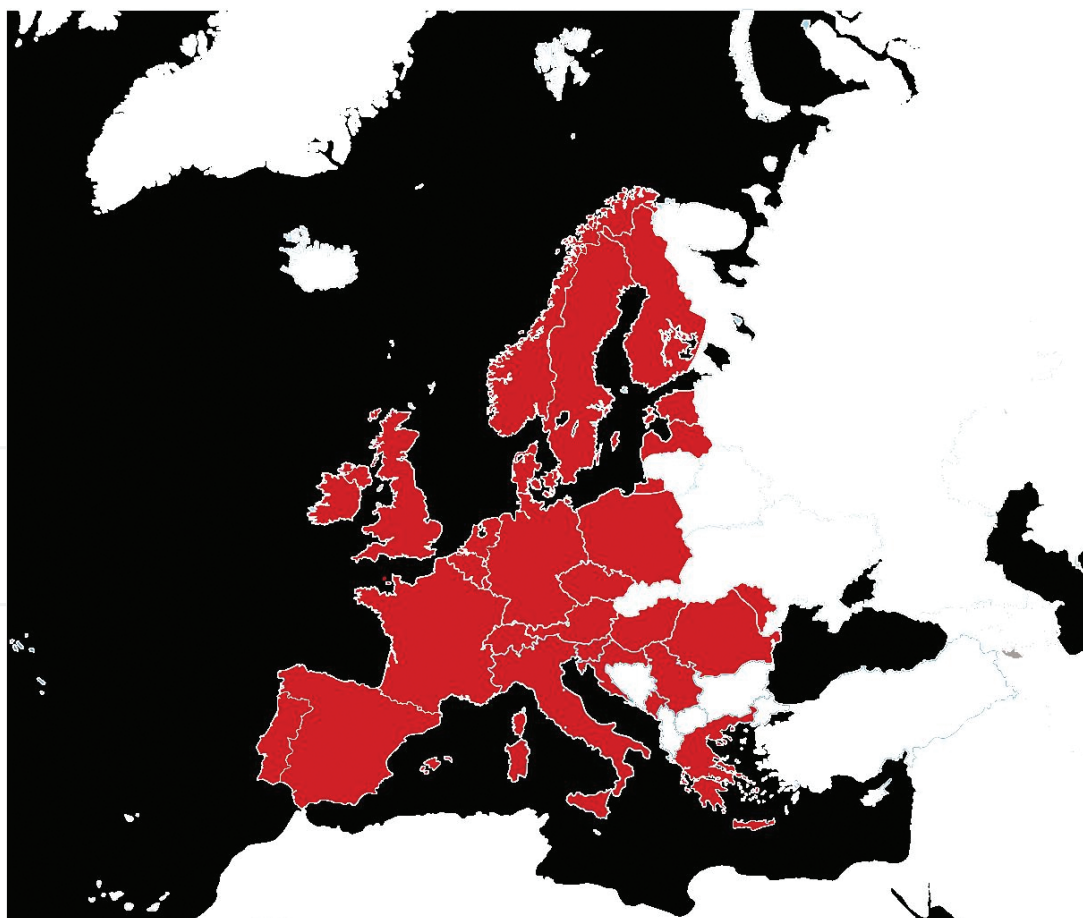


Figure 3. Distribution of the disease caused by SBV in Europe.

In the future, new outbreaks are expected depending on many conditions like the vector transmission [9].

1.4. Disease transmission

As viruses belonging to the genus *Orthobunyavirus* (e.g. Akabane virus) are widespread in Africa and Asia, and biting midges (*Culicoides* spp.) and mosquitoes are responsible for transmitting these viruses [12], it was assumed that an array of European *Culicoides* might be responsible for transmitting SBV within Europe.

Rasmussen et al. [13] demonstrated the presence of SBV RNA in *Culicoides obsoletus* group midges caught in Denmark during October 2011. The low C_t values (i.e. high SBV RNA levels) and the absence of ruminant β -actin mRNA in these samples strongly suggest that SBV replicates in these midges, and hence that the *C. obsoletus* group midges are natural vectors for this virus [12]. Field studies have shown the presence of SBV RNA in *Culicoides* species in several affected countries [13, 14], and a vector-competence study demonstrated replication and dissemination of SBV in laboratory *Culicoides* strains. Midges including *Culicoides scoticus*, *C. chiopterus* and *C. obsoletus* sensu stricto were collected in the field and tested positive for SBV in Belgium [14]. SBV-positive *Culicoides dewulfi* and *C. obsoletus* were also detected in Belgium and Denmark [13].

The transmission by a wide range of *Culicoides* spp. may explain the rapid spread of SBV.

Viruses more closely related to SBV are not considered zoonoses; hence, most authorities have concluded that the probability of SBV infecting humans is minimal [3]. Because SBV emerged recently, transmission from animals to human cannot yet be completely excluded. A seroprevalence study by Ducomble et al. [15] conducted among exposed shepherds in the area of Germany most affected by SBV showed no evidence of transmission to humans. However, further studies on whether SBV poses a risk to humans are vital [15].

1.5. Schmallenberg virus impact on ruminant health

SBV has the ability to infect exclusively ruminant species [9]. Within the domestic ruminants, the most affected are cattle, followed by sheep and goats [16]. Horizontal transmission occurs through various *Culicoides* biting midges, and subsequent transplacental transmission causes teratogenic effects. Despite infection being mostly asymptomatic, foetal Schmallenberg virus infection in naïve ewes and goats can result in stillborn offspring, showing a congenital arthrogryposis-hydranencephaly syndrome. The economic impact of infection depends on the number of malformed lambs but is generally limited [9]. It was shown that SBV infection in meat sheep herds caused increased rates of abortion, malformations, dystocia, lamb mortality and reduced fertility rate [16]. A study conducted by Wüthrich et al. [17] revealed that the average calculated loss after SBV infection for a standardized farm was EUR 1338, which can be considered low at the national level, but the losses were subject to great fluctuations between farms, so individual farms could have very high losses (EUR 8333). The overall prevalence of infected animals within a herd is an important factor [17], and the economic impact of the infection depends on several aspects, such as, the number of malformed lambs, days where

milk production is lower and stage of pregnancy on which the infection occurred [9, 17]. However, the emergence of SVB has a financial impact on international trade in live sheep and goats, for example, with some countries (USA, Mexico and Japan), to place restrictions on the import of embryos and semen of Europe [9]. In conclusion, the impact of SBV on animal population and the associated economic losses are still much discussed, though surveillance activities (syndromic surveillance, abortion surveillance, sentinel herd and *Culicoides* surveillance) and databases as well as cross-sectional epidemiological studies on disease outbreaks are essential to analyse the real impact of these and define action steps [10, 18].

2. Differential diagnosis of SBV

The clinical symptoms of acute SBV infection are unspecific and vary among animal populations. Thus, possible causes of high fever, diarrhoea, decrease in milk production, increased incidence of abortion and congenital malformations should be taken into account in the establishment of the differential diagnosis and consequently in obtaining definitive diagnosis. In contrary to cattle, clinical signs reported in adult small ruminants may be present only during the viraemic phase, but in most cases the infection is mostly asymptomatic [9].

Malformation in newborn or stillborn lambs and clinical signs correlate with the stage of development at which the foetus was infected but these are also not specific of SBV infection. Foetal Schmallenberg virus infection in naïve ewes and goats can result in stillborn offspring, showing a congenital arthrogryposis-hydranencephaly syndrome [9]; however, other congenital malformations may be present such as hydrocephaly, brachygnathia inferior, ankylosis, torticollis and scoliosis.

The lack of specificity of the observed clinical signs in infected adults, stillborn foetuses and malformed neonates means that a definitive diagnosis of SBV infection can only be made accurately based on clinical evaluation and specific laboratory examinations [9].

Although several differential diagnosis for abortion and congenital abnormalities have been suggested to include several factors such as genetic (spider lamb syndrome), teratogenic chemicals or toxins (*Veratrum californicum*, *Lupinus* spp., pregnancy toxaemia, lead poisoning) nutritional conditions such as vitamin (vitamin A, vitamin B1) or mineral deficiencies (hypocalcaemia, hypomagnesaemia, copper) and infectious agents [19], in this section we are going to emphasize infectious causes of this condition. In general, a sudden onset of clustered cases of abortion, premature and at term, live or stillborn foetuses with arthrogryposis and hydranencephaly suggests a teratogenic virus as possible cause.

The main infectious diseases to consider include:

- **Bluetongue disease**

Bluetongue is an arthropod-borne disease affecting wild and domestic ruminants although clinical disease is present mostly in sheep; cattle and goats hosts [20, 21]. The disease occurs

worldwide and is caused by bluetongue virus (BTV), which belongs to the genus *Orbivirus* within the family Reoviridae [20].

BTV infection of livestock is distinctly seasonal (late summer and fall) in the temperate region once is transmitted biologically by certain species of *Culicoides* midges that consequently show maximum activity in high temperature and high humidity [21–23], and these conditions can influence the activity of the vector as well as the viability of the virus. Some authors propose that the global climate changes as well as geography and altitude affect the activity of the vector and are responsible for sudden outbreaks worldwide [21, 23, 24].

The types of characteristic lesions of BTV in affected sheep include: haemorrhage and erosion/ulcers on mucous membrane of the oral cavity and upper gastrointestinal tract, necrotic lesions on the lips, dental footpad and tongue as well as oedema [20], necrosis of skeletal and cardiac muscle, coronitis, subintimal haemorrhage in the pulmonary artery; oedema of the lungs, ventral subcutis and fascia of the muscles of the neck and abdominal wall; and pericardial, pleural and abdominal effusions [25].

Other unspecific signs include drop in milk production, loss of body weight, fever, depression, excessive salivation, serous to bloody nasal discharge, facial oedema, hyperaemia, lameness and death [20, 26]. In goats, the infection demonstrated an acute drop in milk production, oedema of the lips and head, nasal discharge and erythema of the skin and udder [20]; however, in goats and cattle infection may be unapparent [20]. Newborn lambs may reveal porencephaly and cerebral necrosis; however, this type of lesions is more frequent after vaccination using an attenuated virus. The severities of clinical signs seem to vary with the species, breed, age, immune status and the serotype/strain of the infecting virus and with certain rather ill-defined interactions with the environment. Bluetongue typically occurs when susceptible animal species are introduced into areas with circulating virulent BTV strains, or when virulent BTV strains extend their range to previously unexposed populations of ruminants [24, 27].

The outcome of BTV infection of foetal ruminants is age-dependent and transplacental infection [28], which may result in either stillbirths, abortions or the birth of non-viable lambs with severe lesions of the central nervous system [20, 25]. In cattle, most infections are unapparent [20, 21]; however, a few animals may develop clinical signs that include fever, salivation, facial oedema, lesions on lips and nostrils, ulcerations in the oral and nasal mucosa, including tongue and gingiva, and coronitis [29, 30]. In utero transmission occurs in cattle and can result in birth of viraemic calves, abortion, congenital defects such as cerebellar hypoplasia, hydranencephaly or porencephaly accompanied with behavioural abnormalities (head pressing, ataxia, inability to stand and suck well, dullness, disorientation and impaired vision) and congenital musculoskeletal deformities (agnathia, brachygnathia and arthrogryposis) [29–31].

• Epizootic haemorrhagic disease (EHD)

Epizootic haemorrhagic disease virus is a member of the genus *Orbivirus*, family Reoviridae, and is closely related to bluetongue virus [32–34]. The virus is transmitted between susceptible ruminants in temperate regions by biological vectors from the genus *Culicoides* spp. [35];

therefore, this infection is most common in the late summer and autumn during peak vector population [36, 37]. Another factor that may contribute to the dissemination of this disease is the introduction of ruminants from neighbouring farms without quarantine and the presence of organic and other waste-water lagoons on the farm that can act as attraction for the mosquito [35, 37]. The main source of the virus is the blood of viraemic animals. The clinical signs of EHD in cattle are fever, anorexia, dysphagia, prostration, nasal discharge, ulcerative and necrotic lesions of the oral mucosa, hyperaemia and oedema of the conjunctival mucosae, muzzle, hyperaemia of the teats and udder, haemorrhage, dehydration and lameness [33, 35]. Abortions [38] and stillbirths have also been reported in some epidemics [39].

- **Foot and mouth disease (FMD)**

FMD is a highly contagious disease caused by an aphthovirus that belongs to the Picornaviridae family [40, 41], which affects cloven-hoofed animals, mostly cattle, swine, sheep, goats and many species of wild ungulates; however, sheep and goats can be carriers, some studies reveal that the last two species are infrequent carriers. In adult cattle, the main symptoms are characterized by a sudden decrease in milk production, fever (40–41°C), lameness, as well as severe diarrhoea and anorexia, followed by the appearance of vesicles and erosions in the mouth, teats and feet [42], and abortion in pregnant animals. Secondary infections can appear in these areas in which the more notable one is the acute painful stomatitis. Although FMDV rarely causes death in adult animals, young animals are more susceptible and may suffer from severe lesions in the myocardium [42]. Reproductive failure and abortion may also be reported [43–45].

In sheep and goats, the disease is generally mild and is important mainly because of the risk of transmission to cattle and can be difficult to distinguish from other common conditions [41, 46]. The more common syndrome in this species is the appearance of a few small lesions, but with a more severe involvement of all four feet. The principal mechanism of transmission is the respiratory route [41, 47] or by ingestion through direct or indirect contact with secretions or excretions from infected animals; however, the possibility of aerogenous infection exists between cloven-hoofed species [48]. Cattle are the most susceptible, followed by sheep, whereas pigs are very resistant [47]. The period of maximum infectivity occurs during the early clinical phase of the disease when there is contact with the vesicular fluid when vesicles are discharged.

- **Bovine viral diarrhoea (BVD) and Border disease virus of sheep**

These viruses are members of the Flaviviridae family and belong to *Pestivirus* genus. BVD infects a range of domestic and wild ruminants [49]. Among the ruminant pestiviruses, there are two biotypes designated as non-cytopathic and cytopathic depending on their effect on tissue culture cells. Only the non-cytopathic, which is ubiquitous in nature, has the ability to establish persistent infection, once this type crosses the placenta invades the foetus and establishes persistent infection due to the non-recognition of the virus, at the age of infection, by the immature immune system. This condition is determinant for the spread of the virus [50,

51]. Cytopathic bovine viral diarrhoea virus (BVDV) is rare and seldom isolated unless accompanied by non-cytopathic BVDV.

Although clinical presentations depend on several factors, such as on strain of virus, species of host, immune status of host, reproductive status of host, age of host, concomitant infections and time of gestation [49], BVD virus is known to produce from subclinical infections (persistently infected animals) to a large number of diverse diseases, including reproductive disorders (decrease in conception rate and pregnancy rate, increased embryonic mortality), early embryonic death, foetal reabsorption abortion, stillbirths, central nervous system defects (microencephaly, cerebellar hypoplasia, hydranencephaly, hydrocephalus, hypomyelination, hypomyelination, cerebellar-ocular agenesis, ocular abnormalities), ocular abnormalities (microphthalmia, cataracts, retinal degeneration, optic neuritis), musculoskeletal deformities (brachygnathism), thymic aplasia, hypotrichosis, alopecia, pulmonary and renal hypoplasia [29, 50], growth retardation [29], enteritis and mucosal disease [51–53]. The most dramatic clinical symptoms are associated with the peracute form of the disease that is characterized by a sudden decrease in milk production, fever, watery and bloody diarrhoea, dehydration, tenesmus, tachypnea, tachycardia, drooping ears, anorexia, excessive lacrimation, nasal discharge, hypersalivation, petechial and ecchymotic haemorrhages of the visible mucosa, and development of ulcers of the nares, muzzle, lips and oral cavity [54] mucous membranes as well as skin lesions around the inguinal and perineal regions, the inner thighs and inside the ears [55]. Thrombocytopenia and haemorrhagic syndrome [54] may also be present in animals affected with the disease. Mucosal disease may also appear as a chronic form which persists for weeks to months and is manifested by inappetence, intermittent to chronic diarrhoea and weight loss. Cattle that have chronic mucosal disease appear unthrifty, may show lameness due to laminitis or interdigital necrosis, and may develop alopecia and hyperkeratinization. Acute or chronic mucosal disease usually occurs in cattle younger than 3 years of age [55].

The virus is transmitted by direct contact between animals and by transplacental transmission to the foetuses. The primary source of infection is the introduction of persistently infected animals into the farm [56]. Nose-to-nose contact is the most effective method of transmitting the virus. Another way of transmission is through contact with fomites such as contaminated needles, obstetric gloves or other equipment [53, 57]. Another indirect way of contact is the transmission through blood-feeding flies and artificial insemination [56].

Border disease (BD) is a congenital virus disease of sheep and goats and is caused by a pestivirus closely related to classical swine fever virus and bovine viral diarrhoea virus [58]. Ewes in acute infection are clinically normal, and viraemia is transient and difficult to detect, and the infection in goats is rare and mainly characterized by abortion. Clinical signs in sheep include barren ewes, abortions, stillbirths, birth of unviable lambs, foetal death with resorption and mummification [58–60]. Affected newborn lambs can show clonic rhythmic tremors, abnormal body conformation, inability to stand, gait anomalies and abnormally hairy birthcoat so-called 'hairy-shaker' or 'fuzzy' lambs which is due to hypertrophy of primary follicles and medullation of wool fibres [61]. Nervous signs are due to a defective myelinogenesis and tend to disappear at a later age [61–63]. Some authors showed that major skeletal abnormalities are brachygnathia, prognathia and arthrogryposis [59]. Although some lambs die shortly after

birth, surviving lambs, as well as apparently normal lambs, can be persistently infected with the virus and excrete it constantly for the rest of their lives. The virus is excreted with saliva, nasal discharge, urine and faeces [63]. Persistently infected animals are the major source of infection and are responsible for the vertical transmission to other susceptible flock or even cattle when mixed grazing is present [60]. The surviving lambs are persistently infected with the virus. Acute infection is usually subclinical, and sheep may also be infected following a close contact with cattle excreting the closely related BVDV [60].

- **Bovine herpesvirus type-1 and other herpesviruses**

Infectious bovine rhinotracheitis/infectious pustularvulvovaginitis (IBR/IPV) is caused by bovine herpesvirus type-1 (BHV-1) [64], and is a disease of domestic and wild cattle. BoHV-1 is a member of the genus *Varicellovirus*, which belongs to the Herpesviridae family, subfamily Alphaherpesvirinae [50, 64]. BHV-1 shares antigenic and genetic close relationships with other ruminant alphaherpesviruses [64]: BoHV-5, caprine herpesvirus-1, cervid herpesvirus-1 (red deer), cervid herpesvirus-2 (reindeer), bubaline herpesvirus-1 and elk herpesvirus-1 [65]. The virus has been associated with a wide range of clinical symptoms, including rhinotracheitis, abortion, infertility and occasionally encephalitis in calves [50, 66]. However, the clinical symptoms may be mild and localized or include severe generalized disease, leading eventually to death [67]. Infection of cattle by bovine herpesvirus type-1 (BHV-1) can lead to upper respiratory tract disorders (rhinitis, tracheitis, mucopurulent nasal discharge and conjunctivitis) [68], conjunctivitis, genital disorders (endometritis, poor conception rates, pustularvulvovaginitis, balanoposthitis) and immune suppression [65]. The main sources of infection to susceptible animals are those with a latent BHV-1 and the contact with nasal secretions, coughed-up droplets, genital secretions, semen, genital fluids and tissues of infected animals [69].

In adult goats, infection with caprineherpesvirus-1 (BHV-6) is responsible for abortion during the second half of pregnancy, stillbirth and neonatal deaths, and the infection leads to vulvovaginitis [70] or balanoposthitis [65]. In newborn kids, ulcerative and necrotic lesions [71] are distributed throughout the enteric tract, and a complex and purulent respiratory compromise and systemic disease is present [65].

- **Rift Valley fever**

Rift Valley fever (RVF) virus belongs to the *Phlebovirus* genus and Bunyaviridae family and is a vector-borne disease of sheep, cattle and goats [72]. The disease is usually present in epizootic form over large areas of a country following heavy rains and sustained flooding, and is characterized by high rates of abortion, neonatal mortality, primarily in sheep once these are more susceptible than cattle and goats [73]. Besides domestic and wild ruminants, humans can also be infected [72]. The disease is also characterized by foetal malformation accompanied by high mortality, bloody diarrhoea, haemorrhages and acute hepatic necrosis [72, 73]. The most frequent foetal abnormalities include cerebellar hypoplasia, por- or hydranencephaly and skeletal deformities such as brachygnathia and arthrogryposis [31].

Many species of mosquitoes have been identified as vectors [73, 74]. Some *Aedes* species act as reservoirs for the virus during inter-epidemic periods, and increased rainfall in dry areas leads to an explosive hatching of mosquito eggs, many of which contain the virus. The infected *Aedes* spp. feed preferentially on domestic ruminants which act as an amplifier of the virus [74]. Humans infect themselves through direct or indirect (aerosols) contact with blood, secretions or tissues of infected animals, which occurs in veterinary procedures (obstetrical manoeuvres, medical treatments), animal husbandry [75], slaughtering, consumption of raw milk and in food preparation. Another source of infection for humans and livestock is the infected blood sucking mosquitoes' vector [76].

In general, clinical signs of the disease tend to be unspecific; however, the sudden onset of numerous abortions (with rates near 100%) and high mortality among young animals along with the clinical history and the environmental factors can help in the establishment of the clinical diagnoses. In sheep, the most common symptoms are (highly susceptible) fever (40–41°C), inappetence, nasal discharge, incoordination, weakness, depression, bloody or fetid diarrhoea [76]. Newborn lambs are considered extremely susceptible, and the main symptoms are: sudden death, fever prior to death (40–42°C), weakness, depression, listless, abdominal pain, tachypnea, increased respiratory rate abdominal respiration prior to death [72].

• Bovine ephemeral fever (BEF)

BEF is an arthropod-borne rhabdovirus that causes a debilitating disease of cattle and water buffaloes with considerable economic impact [77–79]. Bovine ephemeral fever virus belongs to *Ephemerovirus* genus from the Rhabdoviridae family. The virus has been isolated from a range of potential insect vectors, including a large number of species of Culicoides and several species of mosquitoes such as *Aedes* spp., *Culex* spp. and *Anopheles* spp. [79]. Bovine ephemeral fever virus causes a febrile illness affecting mainly mature animals [80]. The onset of clinical signs is usually rapid: a sudden sharp drop in milk production, loss of condition fever stiffness, lameness, nasal and ocular discharges, periorbital swelling, sialorrhea, tachypnea, dyspnoea, nasal and ocular discharges, depression, cessation of rumination and constipation [77, 81, 82]. Cows in advanced pregnancy may abort [77].

• Akabane virus

Akabane virus is an *Orthobunyavirus* and member of the Simbu serogroup of the family Bunyaviridae. Akabane is an insect-transmitted virus that causes congenital abnormalities of the neurological system in ruminants and one of the most potent teratogen viruses affecting cattle, sheep and goats [29, 83]. The incidence of Akabane virus-induced disease is influenced by the species and time of gestation at which infection occurs [29] and by the strain of the virus. Infection in adult cattle has usually no specific signs while infection of pregnant cattle often causes foetal damage, resulting in abortion, stillbirth or various congenital abnormalities [84–86]. A distinct tropism for immature rapidly dividing cells of the foetal central nervous system and skeletal muscle results in direct virus-induced necrotizing encephalomyelitis and polymyositis. The most severe defects are seen after susceptible cows have been infected in earlier gestation. Infection during organogenesis may substantially disrupt structural development

in target organs [87] causing arthrogryposis [88], and sometimes also torticollis, kyphosis and scoliosis [29, 84] with associated neurogenic muscle atrophy due to depletion of spinal ventral horn motor neurons, a loss of axons, and depletion of myelin in the lateral and ventral tracts [89]. Calves infected late in pregnancy may be born alive but unable to stand and may have a flaccid paralysis of the limbs, or may be incoordinated and on necropsy show a disseminated encephalomyelitis [90]. These calves have varying degrees of cavitation of cerebral hemispheres. Some calves may be affected with both arthrogryposis and hydranencephaly.

In 1979, Hashiguchi et al. [91] demonstrated that foetal infection in sheep, between 30 and 50 days pregnancy, result in most congenital abnormalities such as ankylosis of the limbs, scoliosis, hydranencephaly, porencephaly, stillbirth with dwarfism and death after birth with dwarfism and weakness. Few, if any, clinical findings are seen after infection in adult animals [84, 91]. In small ruminants, the lesions of arthrogryposis and hydranencephaly are often seen concurrently and are common in the same animals as well as cerebellar hypoplasia, porencephaly, brachygnathia [31, 92]. This type of lesions may or may not be accompanied by inflammation of the central nervous system [31]. Most Akabane-infected lambs or kids are stillborn or die soon after birth.

• Aino virus

Aino virus is a member of the Simbu serogroup of the genus *Orthobunyavirus*, family *Bunyaviridae* [29, 93]. This virus infection is closely related to the Akabane and SBV infection; therefore, confirmatory diagnosis requires viral detection to differentiate infection between these three viruses [98]. Aino virus is transmitted between animals by insect vectors from *Culicoides* genus mosquitoes [90, 95].

Aino virus infection in adult animals is subclinical, and newborn calves infected can exhibit a wide variety of skeletal and neurological abnormalities [29, 93, 96]. This virus infection is closely related to the Akabane and SBV infection; therefore, confirmatory diagnosis requires viral detection to differentiate infection between these three viruses [94, 98].

In naturally infected pregnant cattle, Aino virus has been associated with abortion [97], stillbirths, premature births and birth congenital malformation, including severe hydranencephaly [98] and/or arthrogryposis [99], unilateral cavitation in the cerebrum, microcephaly and cerebellar hypoplasia [92, 93]. The type of abnormality seen can be related to the time of infection of the foetus [93]: early infection results in hydranencephaly and later infection results in arthrogryposis [99]. Scoliosis [93], sunken eyes, cataracts, maxillary retraction and dental irregularities are also clinical findings. Surviving calves may be weak and can have difficulty suckling or standing. They may also be blind or have poor eyesight. In addition, they may display a variety of neurologic signs, including ataxia, torticollis, tetany, paresis, swimming movements, opisthotonus and circular walking.

• Cache Valley virus

Cache Valley virus (CVV) is a mosquito-borne [100], teratogenic *Bunyavirus* in the *Orthobunyavirus* genus of the Bunyamwera group [1, 101], affecting mainly sheep [106]. Previous

studies describing experimental CVV-induced malformations in ovine foetuses showed that the development of foetal lesions is age-dependent. If the virus is inoculated between 28 and 48 days of gestation, foetal death and abortion occur among other lesions [102]; however, foetuses are susceptible at any age demonstrating the tropism of many Orthobunyaviruses for foetal tissues [1, 103]. In general, malformations involve central nervous and musculoskeletal system. Some morphological studies showed necrosis in the central nervous system and skeletal muscle of infected foetuses evaluated after 7–14 days post-infection, and hydrocephalus, micromyelia and muscular loss were observed in infected foetuses after 21–28 days post-infection [1]. Gross pathology of the musculoskeletal system includes arthrogryposis (of one or more limbs), torticollis, scoliosis of the vertebral column and muscular hypoplasia. Central nervous system lesions include hydranencephaly, hydrocephalus, porencephaly, microencephaly, cerebral and cerebellar hypoplasia and micromyelia [1, 103, 104]. Dead embryos and stillborn or mummified lambs are also found [104]. Anasarca is seen, as is oligohydramnios [103]. Limb defects are also due to neurodegenerative changes seen histopathologically as areas of necrosis and loss of paraventricular neutrophils in the brain together with a reduction in the number of motor neurons. Skeletal muscle changes involve poorly developed myotubularmyocytes [104].

• Chuzan virus

Chuzan virus is a member of Palymserogroup from genus *Orbivirus*, family Reoviridae, and it is closely related to the Akabane virus and Aino viruses [29, 99]. Chuzan virus is transmitted between animals by insect vectors such as *Culicoides* spp. [105–107] and is considered a teratogen virus once pregnant cows result in foetal congenital abnormalities [96, 108, 109]. Chuzan virus infection in adult animals is subclinical; however, foetal abnormalities in newborn calves infected with Chuzan virus during gestation can exhibit a wide range of skeletal and neurological abnormalities [106]. The most common clinical signs in deformed calves are arthrogryposis, vertebral malformations, brachygnathia inferior and malformations of the central nervous system, including hydranencephaly, porencephaly, hydrocephalus, cerebellar hypoplasia and micromyelia [110].

• Wesselsbron disease

Wesselsbron disease is an acute, arthropod-borne infection caused by a flavivirus, member of the Flaviridae family. This virus affects sheep, goats and sporadically cattle [50, 111]. Infection in adult animals and calves is usually subclinical or inapparent [112–114], although in sheep with preexisting liver disease clinical findings can be more expressive and severe. Newborn lambs and kids are most susceptible, and it is often accompanied by a high mortality rate [112, 115]. Outbreaks of congenital abnormalities in foetal or newborn ruminants, musculoskeletal deformities, neonatal deaths [112], abortion in adult animals [31, 50, 112] as well as hydropsamni [116] in ewes, stillbirths and mummified foetuses [31] have been related. The main lesions found in foetuses are arthrogryposis, brachygnathia inferior, hydranencephaly, hydranencephaly, porencephaly, cerebellar hypoplasia [31], hypoplasia or segmental aplasia of the spinal cord and neurogenic muscular atrophy [116].

Author details

Fernando Esteves^{1,2}, João Rodrigo Mesquita^{1,2,3*}, Cármen Nóbrega^{1,2}, Carla Santos^{1,2}, António Monteiro^{1,2}, Rita Cruz^{1,2}, Helena Vala^{1,2,4} and Ana Cláudia Coelho⁵

*Address all correspondence to: jmesquita@esav.ipv.pt

1 Agrarian Superior School of Viseu, Polytechnic Institute of Viseu, Viseu, Portugal

2 Centre for the Study of Education, Technologies and Health (CI&DETS), Polytechnic Institute of Viseu, Viseu, Portugal

3 CIBIO/UP, Research Center in Biodiversity and Genetic Resources/University of Porto, Vairão, Portugal

4 Centre for the Research and Technology of Agro-Environmental and Biological Sciences (CITAB), Vila Real, Portugal

5 Department of Veterinary Sciences, University of Trás-os-Montes and Alto Douro, Vila Real, Portugal

References

- [1] Hoffmann B, Scheuch M, Höper D, Jungblut R, Holsteg M, Schirrmeier H, Eschbaumer M, Goller K, Wernike K, Fischer M, Breithaupt A, Mettenleiter T and Lievaart-Peterson K, Luttikholt S, Peperkamp K, Van Den Brom R, Vellema P. (2012). Schmallenberg disease in sheep or goats: Past, present and future. *Vet Microbiol.* 181, 147-153.
- [2] Doceul V, Lara E, Sailleau C, Belbis G, Richardson J, Bréard E, Viarouge C, Dominguez M, Hendrikx P, Calavas D, Desprat A, Languille J, Comtet L, Pourquier P, Eléouët JF. (2013). Epidemiology, molecular virology and diagnostics of Schmallenberg virus, an emerging orthobunyavirus in Europe. *Vet Res.* 44(1), 31.
- [3] Tarlinton R, Daly J, Dunham S, Kydd J. (2012). The challenge of Schmallenberg virus emergence in Europe. *Vet J.* 194(1), 10-18.
- [4] Chen K, Lior P. (2005). Bioinformatics for whole-genome shotgun sequencing of microbial communities. *Plos Comput Biol.* 1, 106-1012.
- [5] Muskens J, Smolenaars A, Van der Poel W, Mars M, Van Wuijckhuise L, Holzhauer M, Kock P. (2012). Diarrhea and loss of production on Dutch dairy farms caused by the Schmallenberg virus. *Tijdschr Diergeneeskd.* 137(2), 112-115.

- [6] OIE. (2013). Oie technicalfactsheet: Schmallenberg virus. [cited 04 January 2016]. Available from: <http://www.oie.int/our-scientific-expertise/specific-information-and-recommendations/schmallenbergvirus/>
- [7] Yanase T, Kato M, Aizawa M, Shuto Y, Shirafuji H, Yamakawa M, Tsuda T. (2012). Genetic reassortment between Sathuperi and Shamonda viruses of the genus Orthobunyavirus in mature: Implications for their genetic relationship to Schmallenberg virus. *Acch. Virol.* 157, 1611-1616.
- [8] Elliott RM, Blakqori G, Van Knippenberg IC, Koudriakova E, Li P, McLees A, Shi X, Szemiel AM. (2012). Establishment of a reverse genetics system for Schmallenberg virus, a newly emerged orthobunyavirus in Europe. *J Gen Virol.* 2013 Apr; 94(Pt 4), 851-859. doi: 10.1099/vir.0.049981-0. Epub 2012 Dec 19.
- [9] Lievaart-Peterson K, Luttikholt S, Peperkamp K, Van den Brom R, Vellema P. (2015). Schmallenberg disease in sheep or goats: Past, present and future. *Vet Microbiol.* 14;181(1-2), 147-153
- [10] Poskin A, Théron L, Hanon JB, Saegerman C, Vervaeke M, Van der Stede Y, De Regge N. (2016). Reconstruction of the Schmallenberg virus epidemic in Belgium: Complementary use of disease surveillance approaches. *Vet Microbiol.* 183, 50-61.
- [11] Esteves F, Mesquita JR, Vala H, Abreu-Silva J, van der Poel WH, Nascimento MS. (2016). Serological evidence for Schmallenberg virus infection in sheep of Portugal. *Vector Borne Zoonotic Dis.* 16(1), 63-65.
- [12] Rasmussen LD, Kirkeby C, Bødker R, Kristensen B, Rasmussen TB, Belsham GJ, Bøtner A. (2014). Rapid spread of Schmallenberg virus-infected biting midges (*Culicoides* spp.) across Denmark in 2012. *Transbound Emerg Dis.* 61(1), 12-16.
- [13] Rasmussen L, Kristensen B, Kirkeby C, Rasmussen T B, Belsham GJ, Bødker R, Bøtner A. (2012). Culicoids as vectors of schmallenberg virus. *Emerg Infect Dis.* 18, 1204-1206.
- [14] Elbers AR, Meiswinkel R, Van Weezep E, Kooi EA, van der Poel WH. (2013) Schmallenberg virus in *Culicoides* biting midges in the Netherlands in 2012. *Transbound Emerg Dis.* 62(3), 339-342.
- [15] Ducomble T, Wilking H, Stark K, Takla A, Askar M, Schaade L, Nitsche A, Kurth A. (2012). Lack of evidence for Schmallenberg virus infection in highly exposed persons, Germany, 2012. *Emerg Infect Dis.* 18(8), 1333-1335.
- [16] Herder V, Hansmann F, Wohlsein P, Peters M, Varela M, Palmarini M, Baumgärtner W. (2013). Immunophenotyping of inflammatory cells associated with Schmallenberg virus infection of the central nervous system of ruminants. *PLoS One.* 7;8(5), e62939.
- [17] Wüthrich M, Lechner I, Aebi M, Vögtlin A, Posthaus H, Schüpbach-Regula G, Meylan M. (2016). A case-control study to estimate the effects of acute clinical infection with the Schmallenberg virus on milk yield, fertility and veterinary costs in Swiss dairy herds. *Prev Vet Med.* 126:54-65.

- [18] Afonso, A, Abrahantes, JC, Conraths, F, Veldhuis, A, Elbers, A, Roberts, H Richardson, J. (2014). The Schmallenberg virus epidemic in Europe—2011–2013. *Prev Vet Med.* 116, 391-403.
- [19] Parsonson IM, Della-Porta AJ, Snowdon WA. (1977). Congenital abnormalities in newborn lambs after infection of pregnant sheep with Akabane virus. *Infect Immun.* 15(1), 254-262.
- [20] Coetzee P, Stokstad M, Venter EH, Myrmel M, Van Vuuren M. (2012). Bluetongue: A historical and epidemiological perspective with the emphasis on South Africa. *Virol J.* 9, 198.
- [21] MacLachlan NJ. (1994). The pathogenesis and immunology of bluetongue virus infection of ruminants. *Comp Immunol Microbiol Infect Dis.* Aug-Nov; 17(3-4), 197-206.
- [22] Osborne CJ, Mayo CE, Mullens BA, McDermott EG, Gerry AC, Reisen WK, MacLachlan NJ. (2015). Lack of evidence for laboratory and natural vertical transmission of bluetongue virus in *Culicoides sonorensis* (Diptera: Ceratopogonidae). *J Med Entomol.* 52(2), 274-277.
- [23] Mayo CE, Gardner IA, Mullens BA, Barker CM, Gerry AC, Guthrie AJ, MacLachlan NJ. (2012). Anthropogenic and meteorological factors influence vector abundance and prevalence of bluetongue virus infection of dairy cattle in California. *Vet Microbiol.* Mar 23; 155(2-4), 158-164. doi: 10.1016/j.vetmic.2011.08.029.
- [24] Caporale M, Di Gialleonardo L, Janowicz A, Wilkie G, Shaw A, Savini G, Van Rijn PA, Mertens P, Di Ventura M, Palmarini M. (2014). Virus and host factors affecting the clinical outcome of bluetongue virus infection. *J Virol.* 88(18), 10399-10411.
- [25] MacLachlan NJ, Drew CP, Darpel KE, Worwa G. (2009). The pathology and pathogenesis of bluetongue. *J Comp Pathol.* Jul; 141(1), 1-16.
- [26] van Wuijckhuise L, Dercksen D, Muskens J, de Bruijn J, Scheepers M, Vroenenraets R. (2006). Bluetongue in the Netherlands; description of the first clinical cases and differential diagnosis. Common symptoms just a little different and in too many herds. *Tijdschr Diergeneeskd.* 131(18), 649-654
- [27] Najarnejhad V, Rajae M. (2013). Seroepidemiology of bluetongue disease in small ruminants of north-east of Iran. *Asian Pac J Trop Biomed.* 3(6), 492-495.
- [28] Darpel KE, Batten CA, Veronesi E, Williamson S, Anderson P, Dennison M, Clifford S, Smith C, Philips L, Bidewell C, Bachanek-Bankowska K, Sanders A, Bin-Tarif A, Wilson AJ, Gubbins S, Mertens PP, Oura CA, Mellor PS. (2009). Transplacental transmission of bluetongue virus 8 in cattle, UK. *Emerg Infect Dis.* 15(12), 2025-2028.
- [29] Agerholm JS, Hewicker-Trautwein M, Peperkamp K, Windsor PA. (2015) Virus-induced congenital malformations in cattle. *Acta Vet Scand.* Sep 24; 57, 54.

- [30] Wilson WC, Bawa B, Drolet BS, Lehiy C, Faburay B, Jaspersen DC, Reister L, Gaudreault NN, Carlson J, Ma W, Morozov I, McVey DS, Richt JA. (2014). Evaluation of lamb and calf responses to Rift Valley fever MP-12 vaccination. *Vet Microbiol.* Aug 6; 172(1-2), 44-50.
- [31] Javanbakht J, Mardjanmehr SH, Tavasoly A, Nazemshirazi MH. (2014). Neuropathological microscopic features of abortions induced by Bunyavirus / or Flavivirus infections. *Diagn Pathol.* 9, 223
- [32] Eschbaumer M, Wernike K, Batten CA, Savini G, Edwards L, Di Gennaro A, Teodori L, Oura CA, Beer M, Hoffmann B. (2012). Epizootic hemorrhagic disease virus serotype 7 in European cattle and sheep: Diagnostic considerations and effect of previous BTV exposure. *Vet Microbiol.* 159(3-4), 298-306.
- [33] Temizel EM, Yesilbag K, Batten C, Senturk S, Maan NS, Mertens PPC. (2009). Epizootic hemorrhagic disease in cattle, western Turkey. *Emerg Infect Dis.* 15, 2.
- [34] Brodie SJ, Bardsley KD, Diem K, Mecham JO, Norelius SE, Wilson WC. (1988). Epizootic hemorrhagic disease: Analysis of tissues by amplification and in situ hybridization reveals widespread orbivirus infection at low copy numbers. *J Virol.* 72(5), 3863-3871.
- [35] Cêtre-Sossah C, Roger M, Sailleau C, Rieau L, Zientara S, Bréard E, Viarouge C, Beral M, Esnault O, Cardinale E. (2014). Epizootic haemorrhagic disease virus in Reunion Island: Evidence for the circulation of a new serotype and associated risk factors. *Vet Microbiol.* Jun 4; 170(3-4), 383-390.
- [36] Maclachlan NJ, Guthrie A (2010). Re-emergence of bluetongue, African horse sickness, and other Orbivirus diseases. *Vet Res.* 41(6): 35.
- [37] Maclachlan NJ, Zientara S, Savini G, Daniels PW. (2015). Epizootic haemorrhagic disease. *Rev Sci Tech.* Aug; 34(2), 341-351
- [38] Anbalagan S, Hause BM. (2014). Characterization of epizootic hemorrhagic disease virus from a bovine with clinical disease with high nucleotide sequence identity to white-tailed deer isolates. *Arch Virol.* Oct; 159(10), 2737-2740.
- [39] OIE Terrestrial Manual. (2014). Epizootic haemorrhagic disease. [cited 04 January 2016]. Available from: http://www.oie.int/fileadmin/Home/fr/Health_standards/tahm/2.01.04b_EHD.pdf.
- [40] Longjam N, Deb R, Sarmah AK, Tayo T, Awachat VB, Saxena VK. (2011). A brief review on diagnosis of foot-and-mouth disease of livestock: Conventional to molecular tools. *Vet Med Int.* 2011, 905768.
- [41] Grubman MJ, Baxt B. (2004). Foot-and-mouth disease. *Clin Microbiol Rev.* April; 17(2), 465-493.
- [42] Doll K. (2001). Clinical picture and differential diagnosis of foot and mouth disease in cattle. *Dtsch Tierarztl Wochenschr.* 108(12), 494-498.

- [43] Lyons NA, Alexander N, Stärk K, Dulu TD, Rushton J, Fine PEM. (2015). Impact of foot-and-mouth disease on mastitis and culling on a large-scale dairy farm in Kenya. *Vet Res.* 46(1), 41
- [44] Knight-Jones TJD, Rushtonb J. (2013). The economic impacts of foot and mouth disease – What are they, how big are they and where do they occur? *Prev Vet Med.* 1;112(3-4), 161-173.
- [45] Weir E. (2001). Foot-and-mouth disease in animals and humans. *CMAJ.* 1;164(9), 1338.
- [46] Kitching RP, Hughes GJ. (2002). Clinical variation in foot and mouth disease: Sheep and goats. *Rev Sci Tech.* Dec; 21(3), 505-512.
- [47] Donaldson AI, Alexandersen S. (2002). Predicting the spread of foot and mouth disease by airborne virus. *Rev Sci Tech.* Dec; 21(3), 569-575.
- [48] Meyer RF, Knudsen RC. (2001). Foot-and-mouth disease: a review of the virus and the symptoms. *J Environ Health.* 64(4):21–3.
- [49] Ridpath JF. (2010). Bovine viral diarrhoea virus: Global status. *Vet Clin North Am Food Anim Pract.* Mar; 26(1), 105-121.
- [50] Ali H, Ali AA, Atta MS, Cepica A. (2011). Common, emerging, vector-borne and infrequent abortogenic virus infections of cattle. *Transbound Emerg Dis.* 59(1), 11-25.
- [51] Deregts D, Loewen KG. (1995). Bovine viral diarrhoea virus: Biotypes and disease. *Can Vet J.* 36(6), 371-378.
- [52] Grooms DL. (2004). Reproductive consequences of infection with bovine viral diarrhoea virus. *Vet Clin North Am Food Anim Pract.* Mar; 20(1), 5-19.
- [53] Houe H. (1995). Epidemiology of bovine viral diarrhoea virus. *Vet Clin North Am Food Anim Pract.* Nov; 11(3), 521-547.
- [54] Hessman BE, Sjeklocha DB, Fulton RW, Ridpath JF, Johnson BJ, McElroy DR. (2012). Acute bovine viral diarrhoea associated with extensive mucosal lesions, high morbidity, and mortality in a commercial feedlot. *J Vet Diagn Invest.* 24, 397.
- [55] Goens DS. (2002). The evolution of bovine viral diarrhoea: A review. *Can Vet J.* Dec; 43(12), 946-954.
- [56] Meyling A, Jensen AM. (1988). Transmission of bovine virus diarrhoea virus (BVDV) by artificial insemination (AI) with semen from a persistently-infected bull. *Vet Microbiol.* Jun; 17(2), 97-105.
- [57] Niskanen R, Lindberg A. (2003). Transmission of bovine viral diarrhoea virus by unhygienic vaccination procedures, ambient air, and from contaminated pens. *Vet J.* Mar; 165(2), 125-130.
- [58] Nettleton PF, Gilray JA, Russo P, Dliissi E. (1998). Border disease of sheep and goats. *Vet Res.* May-Aug; 29(3-4), 327-340.

- [59] García-Pérez AL, Minguijón E, Estévez L, Barandika JF, Aduriz G, Juste RA, Hurtado A. (2009). Clinical and laboratorial findings in pregnant ewes and their progeny infected with Border disease virus (BDV-4 genotype). *Res Vet Sci.* Apr; 86(2), 345-352.
- [60] Nettleton PF. (1987). Pathogenesis and epidemiology of border disease. *Ann Rech Vet.* 18(2), 147-155.
- [61] Lim CF, Carnegie PR. (1984). A survey of hairy shaker disease (border disease, hypomyelinogenesiscongenita) in sheep. *Aust Vet J.* Jun; 61(6), 174-177.
- [62] Osburn BI, Castrucci G. (1991). Diaplacental infections with ruminant pestiviruses. *Arch Virol Suppl.* 3, 71-78.
- [63] Terpstra C. (1980). Border disease: a persistent virus infection in sheep (author's transl). *Tijdschr Diergeneeskd.* Aug 15; 105(16), 650-656.
- [64] Lemaire M, Meyer G, Baranowski E, Schynts F, Wellemans G, Kerkhofs, Thiry E. (2000). Production of Bovine herpesvirus type 1-seronegative latent carriers by administration of a live-attenuated vaccine in passively immunized calves. *J Clin Microbiol.* Nov; 38(11), 4233-4238.
- [65] Thiry J, Keuser V, Muylkens B, Meurens F, Gogev S, Vanderplasschen A, Thiry E. (2006). Ruminant alphaherpesviruses related to bovine herpesvirus 1. *Vet Res.* Mar-Apr; 37(2), 169-190.
- [66] Furuoka H, Izumida N, Horiuchi M, Osame S, Matsui T. (1995). Bovine herpesvirusmeningoencephalitis association with infectious bovine rhinotracheitis (IBR) vaccine. *Acta Neuropathol.* 90(6), 565-571
- [67] Engels M1, Ackermann M. (1996). Pathogenesis of ruminant herpesvirus infections. *Vet Microbiol.* 1996 Nov; 53(1-2), 3-15.
- [68] Jones C1, Chowdhury S. (2007). A review of the biology of bovine herpesvirus type 1 (BHV-1), its role as a cofactor in the bovine respiratory disease complex and development of improved vaccines. *Anim Health Res Rev.* Dec; 8(2), 187-205.
- [69] Nuotio L, Neuvonen E, Hyytiäinen M. (2007). Epidemiology and eradication of infectious bovine rhinotracheitis/infectious pustularvulvovaginitis (IBR/IPV) virus in Finland. *Acta Vet Scand.* 49(1), 3
- [70] Grewal AS, Wells R. (1986). Vulvovaginitis of goats due to a herpesvirus. *Aust Vet J.* Mar; 63(3), 79-82.
- [71] Chénier S, Montpetit C, Hélie P. (2004). Caprine herpesvirus-1 abortion storm in a goat herd in Quebec. *Can Vet J.* Mar; 45(3), 241-243.
- [72] Ikegami T, Makino S. (2011). The pathogenesis of Rift Valley fever. *Viruses.* 3, 493-519; doi: 10.3390/v3050493

- [73] Chamchod F, Cosner C, Cantrell RS, Beier JC, Ruan S. (2015). Transmission dynamics of Rift Valley fever virus: Effects of live and killed vaccines on epizootic outbreaks and enzootic maintenance. *Front Microbiol.* 6, 1568.
- [74] Lutomiah J, Omondi D, Masiga D, Mutai C, Mireji PO, Ongus J, Linthicum KJ, Sang R. (2014). Blood meal analysis and virus detection in blood-fed mosquitoes collected during the 2006–2007 Rift Valley fever outbreak in Kenya. *Vector Borne Zoonotic Dis.* 14(9), 656–364.
- [75] LaBeaud D, Pfeil F, Traylor Z, Hise G, Kazura JW, Gildengorin G, Muiruri S, Muchiri EM, King CH. (2015). Factors associated with severe human Rift Valley fever in Sangailu, Garissa County, Kenya. *PLOS Negl Trop Dis.* 12;9(3):e0003548.
- [76] Munyua P, Murithi RM, Wainwright S, Githinji J, Hightower A, Mutonga D, Macharia J, Ithondeka PM, Musaa J, Breiman RF, Bloland P, Njenga MK. (2010). Rift Valley fever outbreak in Livestock in Kenya, 2006–2007. *Am J Trop Med Hyg.* 5;83(2 Suppl), 58-64.
- [77] Bakhshesh M, Abdollahi D. (2015). Bovine Ephemeral fever in Iran: Diagnosis, isolation and molecular characterization. *J Arthropod Borne Dis.* 9(2), 195-203.
- [78] Trinidad L, Blasdel KR, Joubert DA, Davis SS, Melville L, Kirkland PD, Coulibaly F, Holmes EC, Walke PJ. (2014). Evolution of bovine ephemeral fever virus in the Australian Episystem. *J Virol.* 88(3), 1525-1535.
- [79] Nandi S, Negi BS. (1999). Bovine ephemeral fever: A review. *Comp Immunol Microbiol Infect Dis.* Apr; 22(2), 81-91.
- [80] Kirkland PD (2002). Akabane and bovine ephemeral fever virus infections. *Vet Clin North Am Food Anim Pract.* Nov; 18(3), 501-514, viii-ix.
- [81] Walker PJ (2005). Bovine ephemeral fever in Australia and the world. *Curr Top Microbiol Immunol.* 292, 57-80.
- [82] Liao YK, Inaba Y, Li NJ, Chain CY, Lee SL, Liou PP. (1998). Epidemiology of bovine ephemeral fever virus infection in Taiwan. *Microbiol Res.* Nov; 153(3), 289-295.
- [83] Beer M, Conraths FJ, van der Poel WH. (2013). 'Schmallenberg virus' – A novel orthobunyavirus emerging in Europe. *Epidemiol Infect.* Jan; 141(1), 1-8.
- [84] Oluwayelu DO, Aiki-Raji CO, Umeh EC, Mustapha SO, Adebisi AI. (2016). Serological investigation of Akabane virus infection in cattle and sheep in Nigeria. *Adv Virol.* 2016, 2936082. Published online 2016 January 26.
- [85] Kirkland PD. (2015). Akabane virus infection. *Rev Sci Tech.* Aug; 34(2), 403-410.
- [86] Elhassan AM, Mansour MEA, Shamon AAA, El Hussein AM. (2014). A serological survey of Akabane virus infection in cattle in Sudan. *ISRN Vet Sci.* 2014, 123904. Published online 2014 January 21.

- [87] Charles JA. (1994). Akabane virus. *Vet Clin North Am Food Anim Pract.* Nov; 10(3), 525-546.
- [88] Kurogi H, Inaba Y, Takahashi E, Sato K, Satoda K. (1977). Congenital abnormalities in newborn calves after inoculation of pregnant cows with Akabane virus. *Infect Immun.* 17(2), 338-343.
- [89] Gundlach AL, Grabara CS, Johnston GA, Harper PA. (1990). Receptor alterations associated with spinal motoneuron degeneration in bovine Akabane disease. *Ann Neurol.* May; 27(5), 513-519.
- [90] Kono R, Hirata M, Kaji M, Goto Y, Ikeda S, Yanase T, Kato T, Tanaka S, Tsutsui T, Imada T, Yamakawa M. (2008). Bovine epizootic encephalomyelitis caused by Akabane virus in southern Japan. *BMC Vet Res.* 4, 20.
- [91] Hashiguchi Y, Nanba K, Kumagai T. (1979). Congenital abnormalities in newborn lambs following Akabane virus infection in pregnant ewes. *Natl Inst Anim Health Q*, 19(1-2), 1-11.
- [92] Haughey KG, Hartley WJ, Della-Porta AJ, Murray MD. (1988). Akabane disease in sheep. *Aust Vet J.* May; 65(5), 136-140.
- [93] Tsuda T, Yoshida K, Ohashi S, Yanase T, Sueyoshi M, Kamimura S, Misumi K, Hamana K, Sakamoto H, Yamakawa M. (2004). Arthrogryposis, hydranencephaly and cerebellar hypoplasia syndrome in neonatal calves resulting from intrauterine infection with Aino virus. *Vet Res.* 35(5), 531-538.
- [94] Lee JH, Seo HJ, Park JY, Kim SH, Cho YS, Kim YJ, Cho IS, Jeoung HY. (2015). Detection and differentiation of Schmallerberg, Akabane and Aino viruses by one-step multiplex reverse-transcriptase quantitative PCR assay. *BMC Vet Res.* 24;11, 270.
- [95] Kim YH, Kweon CH, Tark DS, Lim SI, Yang DK, Hyun BH, Song JY, Hur W, Park SC. (2011). Development of inactivated trivalent vaccine for the teratogenic Aino, Akabane and Chuzan viruses. *Biologicals.* May; 39(3), 152-157.
- [96] Hechinger S, Wernike K, Beer M. (2013). Evaluating the protective efficacy of a trivalent vaccine containing Akabane virus, Aino virus and Chuzan virus against Schmallerberg virus infection. *Vet Res.* 5;44, 114.
- [97] Uchinuno Y, Noda Y, Ishibashi K, Nagasue S, Shirakawa H, Nagano M, Ohe R. (1998). Isolation of Aino virus from an aborted bovine fetus. *J Vet Med Sci.* 60(10), 1139-1140.
- [98] Kitano Y, Yamashita S, Makinoda K. (1994). A congenital abnormality of calves, suggestive of a new type of arthropod-borne virus infection. *J Comp Pathol.* Nov; 111(4), 427-437.
- [99] Noda Y, Uchinuno Y, Shirakawa H, Nagasue S, Nagano N, Ohe R, Narita M. (1998). Aino virus antigen in brain lesions of a naturally aborted bovine fetus. *Vet Pathol.* 35(5), 409-411.

- [100] Andreadis TG, Armstrong PM, Anderson JF, Main AJ. (2014). Spatial-temporal analysis of Cache Valley virus (Bunyaviridae: Orthobunyavirus) infection in anopheline and culicine mosquitoes (Diptera: Culicidae) in the northeastern United States, 1997-2012. *Vector Borne Zoonotic Dis.* 14(10), 763-773.
- [101] Edwards JF. (1994). Cache Valley virus. *Vet Clin North Am Food Anim Pract.* Nov; 10(3), 515-524.
- [102] Rodrigues Hoffmann A, Dorniak P, Filant J, Dunlap KA, Bazer FW, de la Concha-Bermejillo A, Welsh CJ, Varner P, Edwards JF. (2013). Ovine fetal immune response to Cache Valley virus infection. *J Virol.* 87(10), 5586-5592.
- [103] Chung SI, Livingston CW Jr, Edwards JF, Gauer BB, Collisson EW. (1990). Congenital malformations in sheep resulting from in utero inoculation of Cache Valley virus. *Am J Vet Res.* Oct; 51(10), 1645-1648.
- [104] Edwards JF, Karabatsos N, Collisson EW, de la Concha Bermejillo A. (1997). Ovine fetal malformations induced by in utero inoculation with Main Drain, San Angelo, and LaCrosse viruses. *Emerg Infect Dis.* 3(2), 195-197.
- [105] Lim SI, Kweon CH, Tark DS, Kim SH, Yang DK. (2007). Sero-survey on Aino, Akabane, Chuzan, bovine ephemeral fever and Japanese encephalitis virus of cattle and swine in Korea. *J Vet Sci.* Mar; 8(1), 45-49.
- [106] Kim YH, Kweon CH, Tark DS, Lim SI, Yang DK, Hyun BH, Song JY, Hur W, Park SC. (2011). Development of inactivated trivalent vaccine for the teratogenic Aino, Akabane and Chuzan viruses. *Biologicals.* May; 39(3), 152-157.
- [107] Ohashi S, Yoshida K, Yanase T, Kato T, Tsuda T. (2004). Simultaneous detection of bovine arboviruses using single-tube multiplex reverse transcription-polymerase chain reaction. *J Virol Methods.* 1;120(1), 79-85.
- [108] Oberst RD. (1993). Viruses as teratogens. *The veterinary clinics of North America. Food Anim Pract.* 9(1), 23-31
- [109] Miura Y, Kubo M, Goto Y, Kono Y. (1990). Hydranencephaly-cerebellar hypoplasia in a newborn calf after infection of its dam with Chuzan virus. *Nihon Juigaku Zasshi.* Aug; 52(4), 689-694.
- [110] Goto Y, Miura Y, Kono Y. (1988). Serologic evidence for the etiologic role of Chuzan virus in an epizootic of congenital abnormalities with hydranencephaly-cerebellar hypoplasia syndrome of calves in Japan. *Am J Vet Res.* Dec; 49(12), 2026-2029.
- [111] Blackburn NK, Swanepoel R. (1980). An investigation of flavivirus infections of cattle in Zimbabwe Rhodesia with particular reference to Wesselsbron virus. *J Hyg (Lond).* 85(1), 1-33.
- [112] Mushi EZ, Binta MG, Raborokgwe M. (1998). Wesselsbron disease virus associated with abortions in goats in Botswana. *J Vet Diagn Invest.* 10(2), 191.

- [113] Coetzer JA, Theodoridis A. (1982). Clinical and pathological studies in adult sheep and goats experimentally infected with Wesselsbron disease virus. Onderstepoort J Vet Res. 49(1), 19-22.
- [114] Coetzer JA, Theodoridis A, Herr S, Kritzinger L. (1979). Wesselsbron disease: A cause of congenital porencephaly and cerebellar hypoplasia in calves. Onderstepoort J Vet Res. 46(3), 165-169
- [115] Jupp PG, Kemp A. (1998). Studies on an outbreak of Wesselsbron virus in the Free State Province, South Africa. J Am Mosq Control Assoc. 14(1), 40-45
- [116] Coetzer JA, Barnard BJ. (1977). Hydropsamnii in sheep associated with hydranencephaly and arthrogryposis with Wesselsbron disease and Rift Valley fever viruses as aetiological agents. Onderstepoort J Vet Res. Jun; 44(2), 119-126.

