Chapter 4

Occupational Acne

Betul Demir and Demet Cicek

Additional information is available at the end of the chapter

http://dx.doi.org/10.5772/64905

Abstract

Occupational and environmental acne is a dermatological disorder associated with industrial exposure. Polyhalogenated hydrocarbons, coal tar and products, petrol, and other physical, chemical, and environmental agents are suggested to play a role in the etiology of occupational acne. The people working in the field of machine, chemistry, and electrical industry are at high risk. The various occupational acne includes chloracne, coal tar, and oil acne. The most common type in clinic is the comedones, and it is also seen as papule, pustule, and cystic lesions. Histopathological examination shows epidermal hyperplasia, while follicular and sebaceous glands are replaced by keratinized epidermal cells. Topical or oral retinoic acids and oral antibiotics could be used in treatment. The improvement in working conditions, taking preventive measures, and education of the workers could eliminate occupational acne as a problem.

Keywords: Chloracne, coal-tar acne, environmental acne, occupational acne, oil acne

1. Introduction

Occupational and environmental acne is a dermatological disorder associated with industrial exposure. Polyhalogenated hydrocarbons, coal tar and products, petrol, and other physical, chemical, and environmental agents are suggested to play a role in the etiology of occupational acne [1]. The people working in the field of machine, chemistry and electrical industry are at high risk [2]. The various occupational acne includes chloracne, coal tar, and oil acne. Chloracne is an acneiform eruption that is observed as a result of intoxication with chlorinated hydrocarbons [3] and clinical signs might be severe [4]. It could also arise due to industrial, agricultural, and environmental contamination and even due to eating contaminated foods [2]. Oils used in the industry such as cutting oils (paraffin/oil mixtures), tars (pitch and creosote), and crude petroleum oil (diesel oil) can cause oil and tar acne. Occupational acne is a type of

acne that develops as a result of exposure to insoluble materials causing follicle obstruction. The most common clinical feature is the open and closed comedones, noninflamed nodules, and cystic lesions [5]. Histopathological examination shows epidermal hyperplasia, while follicular and sebaceous glands are replaced by keratinized epidermal cells. [6] In occupational acne, contact should be prevented in individuals working at high risk. In case of contact, the chemical agent should be removed. Topical or oral retinoic acids and oral antibiotics could be used for treatment [7].

2. Classification of occupational acne

2.1. Chloracne

2.1.1. Introduction

Chloracne was first defined by Herxheimer in 1889 [8]. Occupational acne is considered one of the sensitive indicators of systemic intoxication caused by an exposure to certain halogenated aromatic hydrocarbons called chloracnegen. Although the majority of cases with chloracnegen intoxication are associated with occupational exposure, there are also cases with chloracnegen intoxication associated with non-occupational exposure to the industrial wastes and contaminated foods [6].

2.1.2. Etiology

Halogenated aromatic hydrocarbons are the most potent chloracnegen agents [9]. Polychlorinated naphthalenes, polychlorinated biphenyls (PBBs), polychlorinated dibenzofurans (PCDFs), polychlorinated phenols, contaminants of polychlorophenol compounds (especially herbicides), and chlorinated azo- and azoxybenzene are among the chloracnegens [2]. Electrical conductor and insulators, insecticide, fungicide, herbicide, and wood protectors are the agents that cause chloracne [7]. With the introduction of synthetic resins in the 1960s, a high incidence of chloracne after the exposure to polychlorinated naphthalenes and PCBs showed a decline. In later years, the majority of cases exposed to chloracnegens were caused by accidents [10, 11]. The condition has been recently reported in chemical industry workers exposed to chloracne chlorophenols [12, 13] and agricultural workers exposed to pesticides [14].

2,3,7,8-Tetrachlorodibenzo-p-dioxin (TCDD), which is the prototype of polyhalogenated aromatic hydrocarbons is an important cause of chloracne [9]. In the 1970s, chloracne outbreak occurred in a chemical plant in Austria after the exposure of mostly male workers to TCDD, and the workplace was closed for cleaning and reconstruction activities to take place [15]. In 1976, an accident occurred in a chemical plant in Seveso (Italy), known as "ICMESA plant explosion," and 2 kg TCDD was released to the atmosphere, causing chloracne outbreak which mostly affected children [11]. In addition, PCBs and PCDFs are other chloracnegens, and PCBs have been shown to result in direct toxicity by contaminating the cooking oil, and transplacental transmission has also been demonstrated [9]. The largest food pollution of Japan which

occurred in 1968 and currently known as "Yusho" has developed due to the contamination of rice bran oil with polychlorinated hydrocarbons, and it is remembered as an intoxication of a crowd. Although initial analyses failed to detect a chemical substance, biopsy samples obtained from the fat tissues showed deposition of PCBs [16]. In 1979, the incidence of chloracne was reported to be 17.5% in 2000 patients with Yucheng disease (oil disease), which resulted from consuming the food products contaminated by PCBs and PCDFs in Taiwan [17]. Earlier, PCBs have been used frequently as wood preservatives [18].

In modern times, occupational exposure to PCBs often occurs in the fields of construction, paint, ink, adhesive, paper products [19–21], mining, recycling and waste incineration, and hydraulic and transformer systems [22]. Furthermore, PCBs have been detected in plasma and exhaled air in individuals exposed to power transformer oil spilled after an accident during the shipment of the waste products, and these individuals also suffered from acneiform skin lesions [23]. On the other hand, Gawkrodger et al. [24] reported chloracne outbreak in seven chemists working in the pharmaceutical industry exposed to triazoloquinoxaline, a polycyclic halogenated chemical substance, which was not previously reported in association with chloracne. In addition, weed killer containing 2,4-dichloro- and 2,4,5-trichlorophenoxyacetic acid and sodium tetrachlorophenate used for the wood preservatives are the other chloracnegens [9].

2.1.3. Pathogenesis

Although cellular and molecular mechanisms still remain to be elucidated, the major effect is hypoplastic or hyperplastic response of the skin caused by cellular changes triggered by chloracnegens. Epidermis and infundibulum are also involved. Sebaceous and sweat glands lose their secretory functions and are replaced by keratinized cells. According to the epidermal stem cell theory of Panteleyev, chloracnegens activate epidermal stem cells which result in the transformation of the pilosebaceous unit by accelerating the cellular output [3]. TCDD demonstrates its biological effect by binding to cytosolic aryl hydrocarbon receptors. Exposure to TCDD increases keratinocyte proliferation [2].

Genetic studies carried out in patients with chloracne evaluated aryl-hydrocarbon receptor (AhR), transcription, and downstream genes such as CYP1A1, GSTA1, c-fos, and TGF-α expression in the epidermis using the real-time PCR method. These studies showed a high AhR, CYP1A1, GSTA1, and c-fos transactivation in the epidermal tissue associated with long-term exposure to TCDD and dibenzofuran. Therefore, AhR activation has been suggested to play an important role in the pathogenesis of the chloracne pathway and that increased activity might disrupt the normal epidermal cellular proliferation and differentiation [25].

2.1.4. Clinical features

The lesions appear as erythema and edema in the affected areas such as head, neck, malar and retroauricular, and mandibular areas, extremities, axilla, trunk, hip, and scrotum 2–4 weeks after exposure [10] and, then, turn into non-inflammatory black and white comedones and straw-colored cysts, papules (**Figures 1** and **2**) [24], and nodules within a few days. Pustules,

non-infectious abscess, and scar formation after healing can be observed in severe cases. In addition, the lesions can relapse [7, 26, 27] and become generalized. Chloracne has a chronic disease course, and the severity of the disease is associated with the exposure dose, potency of the chloracnegen, and individual susceptibility [6]. A correlation has been reported between half-life and body mass index, body fat mass, TCDD mass, and chloracne response [28]. Systemic symptoms and severe chloracne may occur after the TCDD exposure [9]. Additional dermatological findings may also present, such as brownish hyperpigmentation of the nails, hypertrichosis, and hyperpigmentation in the involved areas. Severe cases may exhibit symptoms of systemic intoxication, such as impaired liver functions, porphyria cutanea tarda, and peripheral neuropathy [10], while some cases may suffer from fatigue, anorexia, impotence, hyperlipidemia, anemia, arthritis, and ophthalmopathy [29]. Indeed, diagnostic criteria for Yusho were established after Yusho disaster in Japan, and clinical findings were categorized as subjective, ocular, dermatological manifestations, and overall symptoms. The most important clinical manifestations of this situation have been chloracne and ocular damage [16].

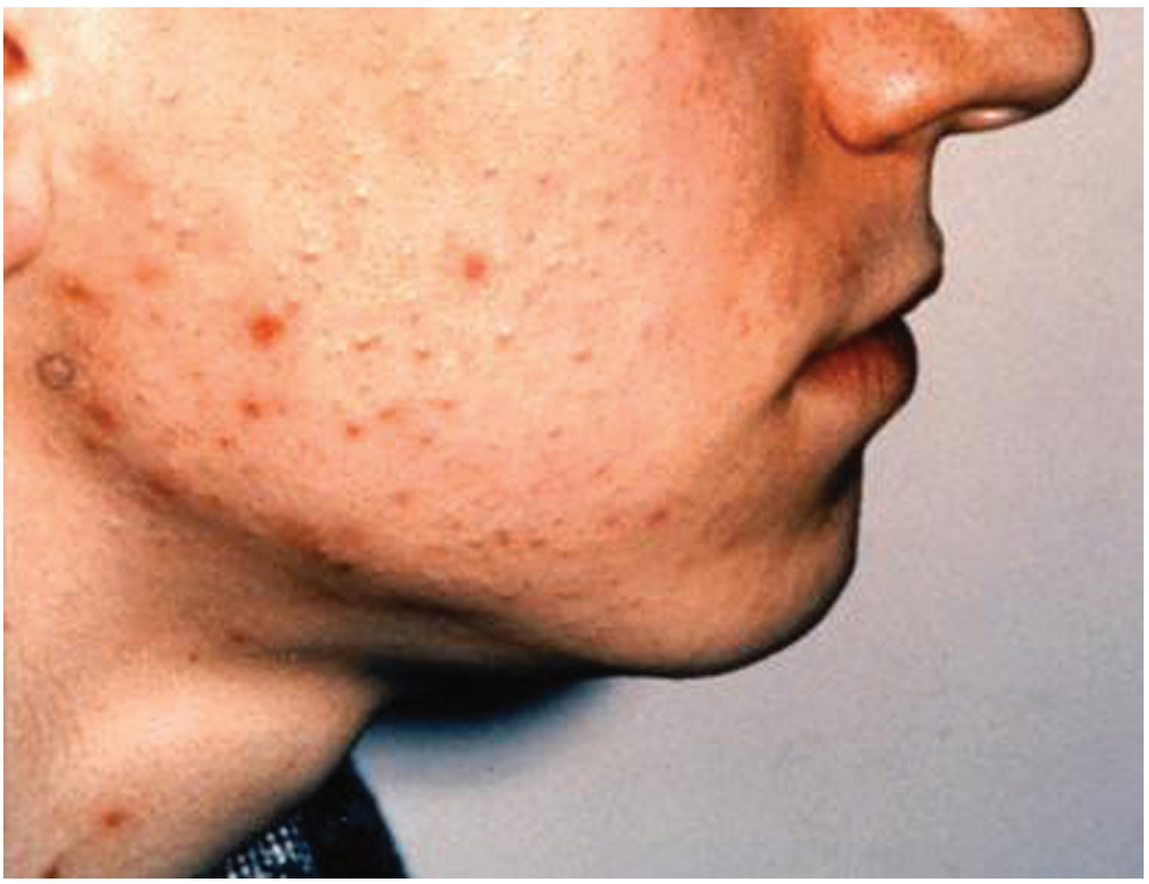

Figure 1. Clinical photograph, showing a combination of small cysts, closed and open comedones, and some inflammatory papules.[1]

[1] Reprinted from Wiley, 161,Gawkrodger DJ, Harris G, Bojar RA. Chloracne in seven organic chemists exposed to novel polycyclic halogenated chemical compounds (triazoloquinoxalines), 939-943, 2009, with permission from John Wiley. (reproduced with permission of the patient).

http://dx.doi.org/10.5772/64905

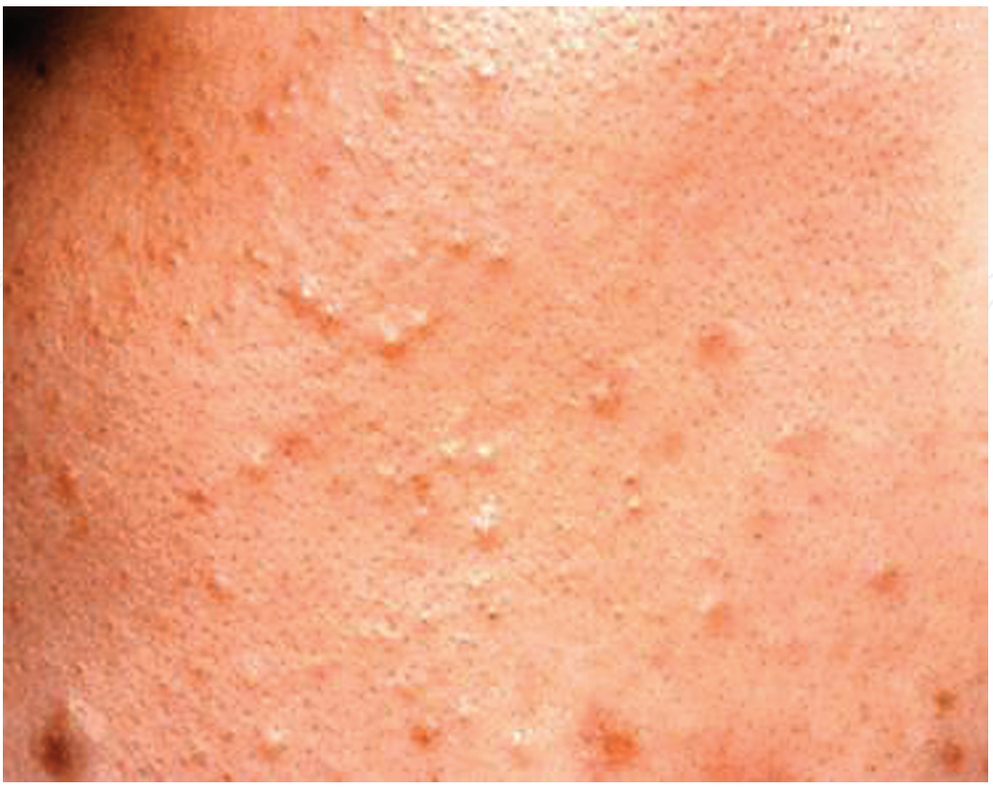

Figure 2. Close up showing small cysts, keratin plugs in pores, and comedones in more detail.[2]

According to the diagnostic criteria revised in 2004, dermatological manifestations were reported as acneiform eruptions and pigmentation (**Table 1**) [30]. It has been suggested that Yucheng disease manifest with dermatological symptoms, such as hyperpigmentation and nail changes, similar to chloracne; however, it may also manifest systemic symptoms such as headache, neuropathy, goiter, arthritis, and anemia [17]. TCDD can stay in the body for many years due to its high lipophilic characteristic and low metabolic rate [31]. Previous studies reported a half-life of 7–11 years [32]. The lesions may persist for 15–30 years after the discontinuation of the chloracnegen exposure [28]. In a study that was conducted in Japan, it was reported that chloracne lesions stay in the body for more than 30 years and are correlated with the blood levels of hydrocarbon [31]. In addition, TCDD was detected in the plasma of the victims 20 years after the Seveso accident [11]. On the other hand, systemic toxicity develops at higher doses than the dose necessary for the development of chloracne. Systemic toxicity is not generally expected in the absence of chloracne [2]. Chloracne is accepted as a sensitive marker of systemic absorption [27]. Hence Geusau et al. [33] detected generalized and severe chloracne lesions together with systemic signs of severe TCDD intoxication and high blood levels of TCDD in one of two female patients who have chloracne together with TCDD intoxication, whereas they have detected moderate facial chloracne in spite of high blood levels of TCDD and systemic signs in the other patient.

[2] Reprinted from Wiley, 161,Gawkrodger DJ, Harris G, Bojar RA. Chloracne in seven organic chemists exposed to novel polycyclic halogenated chemical compounds (triazoloquinoxalines), 939-943, 2009, with permission from John Wiley. (reproduced with permission of the patient).

The diagnostic criteria for Yusho have been revised according to some changes in the symptoms and signs, as well as advances in analytical techniques. The diagnostic criteria for Yusho were revised on October 26, 1972. A supplement was added to the diagnostic criteria on June 14, 1976, and the concentration of polychlorinated quarterphenyls (PCQs) in the blood was added to the diagnostic criteria on June 16, 1981. The concentration of 2,3,4,7,8-pentachlorodibenzofuran (2,3,4,7,8-PeCDF) was added to the diagnostic criteria on September 29, 2004.

Conditions of the incident

- Proof that Kanemi® rice bran oil contaminated with PCBs was ingested.
- There are also some cases in which PCB is transferred from mothers with Yusho to their children.
- Familial occurrence is also seen in many cases.

Important manifestations

1. Acneiform eruptions

Black comedones seen on the face, buttocks, and other intertriginous sites; comedones with inflammatory manifestations; and subcutaneous cysts with atheroma-like contents that tend to suppurate.

2. Pigmentation

Pigmentation of the face, palpebral conjunctivae, and nails of both the fingers and the toes (including babies).

3. Hypersecretion by the meibomian glands.

4. Unusual composition and concentration of PCBs in the blood.

5. Unusual concentration of PCQs in the blood (reference 1).

6. Unusual concentration of 2,3,4,7,8-PeCDF in the blood (reference 2).

Symptoms and signs

1. Subjective symptoms

- A feeling of lassitude
- A feeling of heaviness in the head or headache
- Paresthesia of the limbs (abnormal sensation)
- Increased eye discharge
- Cough and sputum
- Inconsistent abdominal pain
- Altered menstruation

2. Objective manifestations

- Manifestations of bronchitis
- Deformation of the nails
- Bursitis
- Increased neutral fat in the serum
- Serum γ-glutamyl transpeptidase (γ-GTP)

- Decrease of serum bilirubin
- Neonatal small-for-date baby
- Growth retardation and dental abnormality (retarded eruption of permanent teeth)

Reference 1.

The following conclusions have been made in regard to the concentration of PCQs in the blood:

1. ≥0.1 ppb: an abnormally high concentration
2. 0.03–0.09 ppb: the boundary between high and normal concentrations
3. ≤0.02 ppb (detection limit): normal concentration

Reference 2.

The following conclusions have been made in regard to the concentration of 2,3,4,7,8-PeCDF in the blood:

1. ≥50 pg/g lipids: an abnormally high concentration
2. 30–50 pg/g lipids: slightly high concentration
3. ≤30 pg/g lipids: normal concentration

Both age and sex of patients should also be considered.

Notes:

- With reference to the above-mentioned conditions of the incident, symptoms, and manifestations, and taking into account the age of the examinees and the temporal progress of their illness, a diagnosis is comprehensively made.
- These diagnostic criteria are to be used to determine whether a patient is affected by Yusho, but they do not necessarily relate to its severity.
- In regard to the abnormal properties of PCBs and the concentrations of PCBs and 2,3,4,7,8-PeCDF in the blood, regional differences as well as the patient's occupation should also be considered.
- Measurements should be performed by inspection agencies recognized by the Study Group of Yusho, at which quality control is carried out.

Table 1. Diagnostic criteria for Yusho (2004)[3].

2.1.5. Pathology

Histopathologically, hyperplasia in outer root sheath keratinocytes and the sebaceous canal is the first sign. Hyperplastic outer root sheath and hyperkeratinized dilated follicle structure are observed in the proximal part of the infundibulum of the involved hair follicles. Dilated infundibulum is filled with keratinized cells and comedones consisting of sebum. Sebaceous glands have disappeared or they have become quite small. Then the wall of the hair follicles gets thinner and abscess formation develops due to rupture toward dermis (**Figure 3**).

[3]. Reprinted from Elsevier, 82, Mitoma C, Uchi H, Tsukimori K, Yamada H, Akahane M, Imamura T, Utani A, Furue M, Yusho and its latest findings-A review in studies conducted by the Yusho Group, 41-48, 2015, with permission from Elsevier.

Furthermore, TCDD has been suggested to be a factor irritating directly the follicular wall and determining atypical keratinization and squamous metaplasia in the follicle epithelium. The involution of the sebaceous glands is not a direct chemical effect, but rather a condition secondary to the follicular obstruction [2]. Hyperpigmentation due to increased melanin production throughout the epidermis and epithelial basal layer of infundibulum has been reported [34]. From the perspective of dermatopathology, chloracne must be differentiated from acne vulgaris, nodular elastosis accompanied by cysts and comedones (Favre-Racouchot syndrome), acne rosacea, pilar keratosis, lichen planopilaris, chronic discoid lupus erythematosus due to loss of sebaceous glands, and hyperpigmentation in the stratum corneum [35].

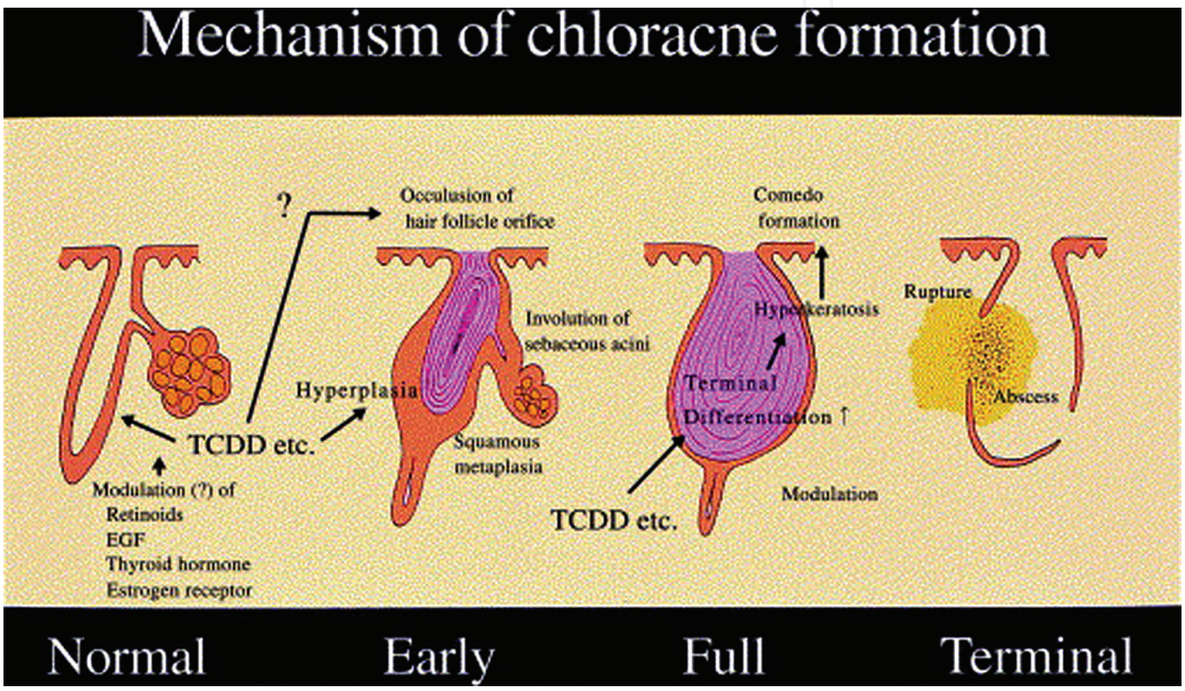

Figure 3. Mechanism of chloracne.[4]

2.1.6. Treatment

Chloracne may resolve gradually after the discontinuation of the chloracnegen exposure. It often weakly responds to acne medications, such as retinoic acid and antibiotics [10]. Corticosteroids, dermabrasion, and electrodessication may yield success to a certain extent. However, chloracne is resistant to therapy, and therefore, protection is of utmost importance [6]. Earlier studies attempted to prevent the chloracnegen exposure and facilitate the elimination from the body. A study evaluated the fecal excretion of chloracnegen using a synthetic dietary fat substitute called olestra [36]. Another study demonstrated 30-fold higher excretion of chloracnegen with the use of olestra diet and calorie restriction [37].

[4] Reprinted from Elsevier, 32, Yamamoto O, Tokura Y. Photocontact dermatitis and chloracne: two major occupational and environmental skin diseases induced by different actions of halogenated chemicals, 85-94, 2003, with permission from Elsevier.

2.2. Coal-tar acne

2.2.1. Introduction

It is a form of acne due to the obstruction of sebaceous glands by the mixture of coal tar and keratin products. In a study investigating the frequency of occupational dermatosis in Greece, coal-tar acne was detected at a rate of 23% in workers exposed to coal tar [38].

2.2.2. Etiology

Coal tar is a fatty fluid that is dark brown-nearly black in color, heavier than water, with a naphthalene-like odor and a sharp burning taste. This is a by-product that is formed as a result of distillation of hazardous parts of coal. Creosote, coal tar pitch, crude naphthalene, and anthracene oils are by-products of the coal tar, which are produced from the crude coal tar. The exposure to the coal tar occurs through the respiratory and gastrointestinal tract and the skin [39]. Coal tar was first described by Becker and Serle in 1681 and its use in dermatological disorders was described by Fishel in 1894 and Goeckerman in 1925 [40]. Coal tar has anti-inflammatory, antimicrobial, antipruritic, and cytostatic effects. Thus, for many decades it has been used as a therapeutic agent in skin diseases, such as psoriasis, and dermatitis [41]. Coal tar is also found in the cleansing bars, creams, gels, lotions, ointments, shampoo, and topical solutions and suspensions [39]. On the other hand, occupation exposure is more prevalent than the therapeutic use and environmental contamination [41]. Coal tar has a wide range of utility in the industry and consumer products. It is used as fuel in open-hearth furnaces and furnaces in the steel industry, as a filling material ingredient of surface coating formulations, and as a modifying agent ingredient of epoxy-resin surface coatings [39]. Coal tar exposure usually occurs in the workers working in the aluminum production, iron-steel foundry, coal tar refinery, road paving, roof insulation, pavement seal coat, and wood surfaces painting [41]. Pitch and creosote is the cause of acne in canal and road construction workers [42].

2.2.3. Pathogenesis

Keratin production and accumulation of fatty fluid causes an obstruction of the sebaceous glands and comedone formation [4, 41].

2.2.4. Clinical features

Clinically it is observed as multiple open comedones in the malar regions of face. The absence of inflammatory papules and pustules and big yellow cysts helps to distinguish coal-tar acne from oil acne and chloracne. It is found in extensor surfaces of the arm and thigh. The relationship between coal tar and periorbital comedone formation was investigated and the incidence of periorbital comedone was found to be high in people exposed to coal tar [1]. Under the experimental conditions, crude coal tar was reported to show a higher inflammatory activity in white-skinned people, compared to dark-skinned individuals [42].

2.2.5. Pathology

There are widened follicular openings with keratin plugs and there are no inflammatory infiltrates [1].

2.2.6. Treatment

Cold tar workers were recommended avoiding hazardous doses of exposure, wearing protective work clothes, receiving training on how to keep their outwear clean with frequent changing, using cleansers at the work places, working equipped with shower facilities and ventilation systems, and undergoing regular health check-ups. The response to therapy was reported to be higher than in chloracne [4, 41].

2.3. Oil acne

2.3.1. Introduction

Oil acne is the most common type of occupational acne [5]. Oil acne generally develops in people exposed to oil circuit breaker. It is due to oil circuit breaker and grease oil, which are used to lubricate machines and which contains a great amount of insoluble mineral oil [1].

2.3.2. Etiology

It has been reported in people working in prefabricated panel production and automobile industry. Moreover, it may be seen in ready-mixed concrete workers [43–45], engine drivers, roofers, and coal tar workers [10]. Oil mist exposure has also been considered a cause of industrial disease, and cases with systemic toxicity and oil acne have been reported to be associated with the oil mist exposure [46]. Actors (applying stage make-up), fast food workers (McDonald 's acne), and workers applying the facemask for prolonged periods as part of their jobs are at a high risk [10]. Acneiform eruptions have been reported more commonly in marine engineers, compared to other seaman due to the use of solvents or diesel fuel as hand cleanser and these lesions were reported to be oil acne [47]. Impure paraffin oil mixtures are the most widely available acnegen chemical agents with a varying degree of acnegen capacity, and they are commonly used in the engineering industry [43]. Brilliantine also shows similar effects due to their impure paraffin content [48]. Concentrated mineral oil is an emulsion of water in oil containing additives and water. Organic substrates and water constitute an environment for the microbial growth. Bacterial endotoxins are, therefore, commonly detected in the metal-working fluids. In a study investigating the exposure to biological agents in the metal-working industry in Poland, oil acne on the skin was reported [49].

2.3.3. Pathogenesis

Exposure to solvent and grease oil causes mechanical obstruction of pilosebaceous glands and development of oil acne [50].

2.3.4. Clinical features

The typical clinical findings are comedones and inflammatory lesions in the dorsum of hand and extensor surfaces of the arm [1]. Clinical presentation, lesions often involve the arms and thighs, depending on the contact of the oily clothing [10]. Of note, males are more commonly affected than females. This can be attributed to the fact that males are more vulnerable to the development of acne [43]. Comedones and cysts associated with the use of brilliantine can be found in the retroauricular area, unless rinsed thoroughly [48].

2.3.5. Treatment

Previous studies reported favorable effects of systemic tetracycline for 3 months in the treatment of oil acne [51]. Isotretinoin is also known to play a role in the treatment of oil acne [52]. Avoiding contact is also one of the prevention methods. [1] Additional protective measures may be also required, such as changing cloths and showering on a daily basis. Improved engineering control with a more emphasis on personal hygiene, there has been a decline in the prevalence of oil acne, compared to the previous years [10].

3. Conclusion

When the literature was reviewed, it was observed that occupational acne is a severe health problem. The improvement in working conditions, taking preventive measures, and education of the workers could eliminate occupational acne as a problem.

Acknowledgements

We thank 'NOVA Language Services' for the English language edition.

Author details

Betul Demir* and Demet Cicek

*Address all correspondence to: drbkaraca@yahoo.com

Department of Dermatology, Firat University Hospital, Elazig, Turkey

References

[1] Adams BB, Chetty VB, Mutasim DF. Periorbital comedones and their relationship to pitch tar: a cross-sectional analysis and a review of the literature. J Am Acad Dermatol. 2000;42:624-627. DOI:10.1067/mjd.2000.101600

[2] Yamamoto O, Tokura Y. Photocontact dermatitis and chloracne: two major occupational and environmental skin diseases induced by different actions of halogenated chemicals. J Dermatol Sci. 2003;32:85-94. DOI: 10.1016/S0923-1811(03)00097-5

[3] Panteleyev AA, Bickers DR. Dioxin-induced chloracne—reconstructing the cellular and molecular mechanisms of a classic environmental disease. Exp Dermatol. 2006;15:705-730. DOI: 10.1111/j.1600-0625.2006.00476.x

[4] Ancona AA. Occupational acne. Occup Med 1986;1:229-243.

[5] Friedmann PS, Wilkinson M. Occupational Dermatoses. In: Bolognia JL, Jorizzo JL, Rapini RP, editors. Dermatology. 2nd ed. New York: Mosby; 2008. p. 231-242.

[6] Ju Q, Zouboulis CC, Xia L. Environmental pollution and acne: Chloracne. Dermatoendocrinol. 2009;1:125-128.

[7] Zaenglein AL, Thiboutot DM. Acne Vulgaris. In: Bolognia JL, Jorizzo JL, Rapini RP, editors. Dermatology. 2nd ed. New York: Mosby; 2008. p. 495-508.

[8] Herxheimer K. Uber chloracne. Munch Med Wochenschr. 1899;46:278.

[9] Rycroft RJG. Occupational Dermatoses. In: Champion RH, Burton JL, Burns DA, Breathnach SM, editors. Rook/Wilkinson/Ebling Textbook of Dermatology. 6th ed. Oxford: Blackwell; 1998. p. 861-881.

[10] Adams RM. Occupational Skin Disease. In: Freedberg IM, Eisen AZ, Wolff K, Austen KF, Goldsmith LA, Katz SI, Fitzpatrick TB, editors. Fitzpatrick's Dermatology in General Medicine. 5th ed. New York: McGraw-Hill; 1999. p. 1609-1632.

[11] Baccarelli A, Pesatori AC, Consonni D, Mocarelli P, Patterson DG Jr, Caporaso NE, Bertazzi PA, Landi MT. Health status and plasma dioxin levels in chloracne cases 20 years after the Seveso, Italy accident. Br J Dermatol. 2005;152:459-465. DOI: 10.1111/j.1365-2133.2005.06444.x

[12] Collins JJ, Budinsky RA, Burns CJ, Lamparski LL, Carson ML, Martin GD, Wilken M. Serum dioxin levels in former chlorophenol workers. J Expo Anal Environ Epidemiol. 2006;16:76-84. DOI:10.1038/sj.jea.7500439

[13] Violante FS, Milani S, Malenchini G, Barbieri A. Reply to the comments by Coenraads and Tang 'Chloracne due to o-dichlorobenzene in a laboratory worker', Contact Dermatitis. 2005:52:108. 2005;53:65. DOI: 10.1111/j.0105-1873.2005.00633.x

[14] Cellini A, Offidani A. An epidemiological study on cutaneous diseases of agricultural workers authorized to use pesticides. Dermatology. 1994;189:129-132.

[15] Neuberger M, Rappe C, Bergek S, Cai H, Hansson M, Jäger R, Kundi M, Lim CK, Wingfors H, Smith AG. Persistent health effects of dioxin contamination in herbicide production. Environ Res. 1999;81:206-214. DOI: 10.1006/enrs.1999.3983

[16] Yoshimura T. Yusho in Japan. Ind Health. 2003;41:139-148. DOI: 10.2486/indhealth.41.139

[17] Guo YL, Yu ML, Hsu CC, Rogan WJ. Chloracne, goiter, arthritis and anemia after polychlorinated biphenyl poisoning: 14-year follow-up of the Taiwan Yucheng cohort. Environ Health Perspect. 1999;107:715-719. DOI: 10.2307/3434656

[18] Hryhorczuk DO, Wallace WH, Persky V, Furner S, Webster JR Jr, Oleske D, Haselhorst B, Ellefson R, Zugerman C. A morbidity study of former pentachlorophenol-production workers. Environ Health Perspect. 1998;106:401-408. DOI: 10.1289/ehp.98106401

[19] Robson M, Melymuk L, Csiszar SA, Giang A, Diamond ML, Helm PA. Continuing sources of PCBs: the significance of building sealants. Environ Int. 2010;36:513. DOI: 10.1016/j.envint.2010.03.009

[20] Herrick RF, Meeker JD, Hauser R, Altshul L, Weymouth GA. Serum PCB levels and congener profiles among US construction workers. Environ Health. 2007;6:25. DOI: 10.1186/1476-069X-6-25

[21] Selden A, Lundholm C, Johansson N, Wingfors H. Polychlorinated biphenyls (PCB), thyroid hormones and cytokines in construction workers removing old elastic sealants. Int Arch Occup Environ Health. 2008;82:99-106. DOI 10.1007/s00420-008-0313-5

[22] Breivik K, Gioia R, Chakraborty P, Zhang G, Jones KC. Are reductions in industrial organic contaminants emissions in rich countries achieved partly by export of toxic wastes? Environ Sci Technol. 2011;45:9154-9160. DOI: 10.1021/es202320c

[23] Budnik LT, Wegner R, Rogall U, Baur X. Accidental exposure to polychlorinated biphenyls (PCB) in waste cargo after heavy seas. Global waste transport as a source of PCB exposure. Int Arch Occup Environ Health. 2014;87:125-135. DOI: 10.1007/s00420-012-0841-x

[24] Gawkrodger DJ, Harris G, Bojar RA. Chloracne in seven organic chemists exposed to novel polycyclic halogenated chemical compounds (triazoloquinoxalines). Br J Dermatol. 2009;161:939-943. DOI: 10.1111/j.1365-2133.2009.09302.x.

[25] Tang NJ, Liu J, Coenraads PJ, Dong L, Zhao LJ, Ma SW, Chen X, Zhang CM, Ma XM, Wei WG, Zhang P, Bai ZP. Expression of AhR, CYP1A1, GSTA1, c-fos and TGF-alpha in skin lesions from dioxin-exposed humans with chloracne. Toxicol Lett. 2008;177:182-187. DOI:10.1016/j.toxlet.2008.01.011

[26] Zugerman C. Chloracne. Clinical manifestations and etiology. Dermatol Clin. 1990;8:209-213.

[27] McDonagh AJ, Gawkrodger DJ, Walker AE. Chloracne—study of an outbreak with new clinical observations. Clin Exp Dermatol. 1993;18:523-525. DOI: 10.1111/j.1365-2230.1993.tb01021.x

[28] Kerger BD, Leung HW, Scott P, Paustenbach DJ, Needham LL, Patterson DG Jr, Gerthoux PM, Mocarelli P. Age- and concentration-dependent elimination half-life of 2,3,7,8-tetrachlorodibenzo-p-dioxin in Seveso children. Environ Health Perspect. 2006; 114:1596-1602. DOI: 10.1289/ehp.8884

[29] Pelclová D, Urban P, Preiss J, Lukás E, Fenclová Z, Navrátil T, Dubská Z, Senholdová Z. Adverse health effects in humans exposed to 2,3,7,8-tetrachlorodibenzo-p-dioxin (TCDD). Rev Environ Health. 2006;21:119-138.

[30] Mitoma C, Uchi H, Tsukimori K, Yamada H, Akahane M, Imamura T, Utani A, Furue M. Yusho and its latest findings—A review in studies conducted by the Yusho Group. Environ Int. 2015;82:41-48. DOI: 10.1016/j.envint.2015.05.004.

[31] Imamura T, Kanagawa Y, Matsumoto S, Tajima B, Uenotsuchi T, Shibata S, Furue M. Relationship between clinical features and blood levels of pentachlorodibenzofuran in patients with Yusho Environ. Toxicology. 2007;22:124-131. DOI: 10.1002/tox.20251

[32] Wolfe WH, Michalek JE, Miner JC, Pirkle JL, Caudill SP, Patterson DG Jr, Needham LL. Determinants of TCDD half-life in veterans of operation ranch hand. J Toxicol Environ Health. 1994;41:481-488. DOI:10.1080/15287399409531858

[33] Geusau A, Abraham K, Geissler K, Sator MO, Stingl G, Tschachler E. Severe 2,3,7,8-tetrachlorodibenzo-p-dioxin (TCDD) intoxication: clinical and laboratory effects. Environ Health Perspect. 2001;109:865-869. DOI: 10.2307/3454832

[34] Pastor MA, Carrasco L, Izquierdo MJ, Fariña MC, Martín L, Renedo G, Requena L. Chloracne: histopathologic findings in one case. J Cutan Pathol. 2002;29:193-199. DOI: 10.1034/j.1600-0560.2002.290401.x

[35] Passarini B, Infusino SD, Kasapi E. Chloracne: still cause for concern. Dermatology. 2010;221:63-70. DOI: 10.1159/000290694

[36] Geusau A, Tschachler E, Meixner M, Sandermann S, Päpke O, Wolf C, Valic E, Stingl G, McLachlan M. Olestra increases faecal excretion of 2,3,7,8-tetrachlorodibenzo-p-dioxin. Lancet. 1999;354:1266-1267. DOI: 10.1016/S0140-6736(99)04271-3

[37] Redgrave TG, Wallace P, Jandacek RJ, Tso P. Treatment with a dietary fat substitute decreased Arochlor 1254 contamination in an obese diabetic male. J Nutr Biochem. 2005;16:383-384. DOI: 10.1016/j.jnutbio.2004.12.014

[38] Zorba E, Karpouzis A, Zorbas A, Bazas T, Zorbas S, Alexopoulos E, Zorbas I, Kouskoukis K, Konstandinidis T. Occupational dermatoses by type of work in Greece. Saf Health Work. 2013;4:142-148. DOI: 10.1016/j.shaw.2013.06.001

[39] National Toxicology Program. Coal tars and coal-tar pitches. Rep Carcinog. 2011;12:111-113. Available from: http://ntp.niehs.nih.gov/go/roc13

[40] Thami G, Sarkar R. Coal tar: past, present and future. Clin Exp Dermatol. 2002;27:99-103. DOI: 10.1046/j.1365-2230.2002.00995.x

[41] Moustafa GA, Xanthopoulou E, Riza E, Linos A. Skin disease after occupational dermal exposure to coal tar: a review of the scientific literature. Int J Dermatol. 2015;54:868-879. DOI: 10.1111/ijd.12903

[42] Kaidbey KH, Kligman AM. A human model of coal tar acne. Arch Dermatol. 1974;109:212-215. DOI:10.1001/archderm.1974.01630020028006.

[43] Farkas J. Oil acne from mineral oil among workers making prefabricated concrete panels. Contact Dermatitis. 1982;8:141. DOI: 10.1111/j.1600-0536.1982.tb04167.x

[44] Santarius-Kaczur D. Oil-induced acne in workers in the automobile industry. Med Pr. 1984;35:309-311.

[45] Upreti RK, Das M, Shanker R. Dermal exposure to kerosene. Vet Hum Toxicol. 1989;31:16-20.

[46] Karube H, Aizawa Y, Nakamura K, Maeda A, Hashimoto K, Takata T. Oil mist exposure in industrial health—a review. Sangyo Eiseigaku Zasshi. 1995;37:113-122.

[47] Svendsen K, Hilt B. Skin disorders in ship's engineers exposed to oils and solvents. Contact Dermatitis. 1997;36:216-220. DOI: 10.1111/j.1600-0536.1997.tb00273.x

[48] Plewig G, Fulton JE, Kligman AM. Pomade acne. Arch Dermatol. 1970;101:580-584. DOI:10.1001/archderm.1970.04000050084011.

[49] Cyprowski M, Kozajda A, Zielińska-Jankiewicz K, Szadkowska-Stańczyk I. Harmful impact of biological agents released at metalworking. Med Pr. 2006;57:139-147.

[50] Kokelj F. Occupational acne. Clin Dermatol. 1992;10:213-217.

[51] Czernielewski A, Skwarczyńska-Banyś E. Oral treatment of acne vulgaris and oil acne with tetracycline. Dermatologica. 1982;165:62-65.

[52] Finkelstein E, Lazarov A, Cagnano M, Halevy S. Oil acne: successful treatment with isotretinoin. J Am Acad Dermatol. 1994;30:491-492.

IntechOpen