

We are IntechOpen, the world's leading publisher of Open Access books Built by scientists, for scientists

6,900

Open access books available

186,000

International authors and editors

200M

Downloads

Our authors are among the

154

Countries delivered to

TOP 1%

most cited scientists

12.2%

Contributors from top 500 universities



WEB OF SCIENCE™

Selection of our books indexed in the Book Citation Index
in Web of Science™ Core Collection (BKCI)

Interested in publishing with us?
Contact book.department@intechopen.com

Numbers displayed above are based on latest data collected.
For more information visit www.intechopen.com



How Effective and Safe is Botulinum Toxin Therapy in Cervical Dystonia: The Current Stand

Roland Dominic G. Jamora and Anthony N. Piano

Additional information is available at the end of the chapter

<http://dx.doi.org/10.5772/64717>

Abstract

Cervical dystonia (CD) is the most common focal dystonia that is characterized by involuntary contraction of cervical muscles causing abnormal head movements and postures. The treatment for CD was previously limited to oral medications, however, with consequent systemic side effects. In recent years, botulinum toxin (BoNT) has demonstrated efficacy in several studies and thus has received level A recommendation from both the American Academy of Neurology and the European Federation of Neurological Sciences in the treatment of dystonia. In many countries, it is the first-line treatment for CD. There are four types of toxin approved for the use in CD, three type A [OnabotulinumtoxinA (OnaBoNTA), AbobotulinumtoxinA (AboBoNTA), and Incobotulinumtoxin A (IncoBoNTA)] and one type B [RimabotulinumtoxinB (RimaBoNTB)]. Proper selection of affected muscles and dose of toxin are important parameters in successfully providing symptomatic treatment. Good response rate is defined as improvement of more than 25 % from baseline using the Toronto Western Torticollis Rating Scale. The most common side effect of chemodenervation with BoNT for CD is dysphagia.

Keywords: cervical dystonia, OnaBoNTA, AboBoNTA, IncoBoNTA, RimaBoNTB, botulinum toxin

1. Introduction

Cervical dystonia (CD) is a movement disorder characterized by involuntary contractions of cervical muscles causing abnormal head movements and postures, at times associated with head tremor and chronic pain [1, 2]. The prevalence of CD in the general population is

estimated to vary from 0.006% from a clinic-based study in eight European countries to 0.4% in the USA, based on a consumer database survey [3, 4].

CD remains the most common of the focal dystonias [3, 5]. Classifications of CD include torticollis (turning or rotation of the head towards one side); laterocollis (tilting of the head towards one side); anterocollis (head and neck flexion); and retrocollis (head and neck extension) or a combination of these movements [1, 2]. The peak age of onset is around 41.8 years, although it can occur in all ages and is slightly more common in females [6]. Most cases of CD are idiopathic, and there is a family history in about 12% of cases [2]. It can also be secondary to trauma or musculoskeletal, spinal cord, intracranial, ocular, and vestibular disorders [7].

For objective rating of CD, the clinician has to use dedicated scales. Scoring at baseline, at the time of peak effect (approximately 1 month after injection) and before retreatment would allow the injectors to assess the outcome of the previous injection and make the necessary adjustment in the dosing and targeting in the next injection cycle [8]. The most frequently used instrument to assess the response to therapeutic interventions in patients with CD is the Toronto Western Spasmodic Torticollis Rating Scale (TWSTRS) [9]. The TWSTRS, together with the Cervical Dystonia Impact Scale (CDIP-58) and the Cervical Dystonia Questionnaire (CDQ-24), is “recommended” for CD, while the Functional Disability Questionnaire, the Tsui Scale and the Body Concept Scale have been rated as “suggested” [10].

2. Muscle selection

Upon diagnosis of CD, a proper clinical examination is warranted. One has to identify the primary muscles involved as opposed to compensatory activity as well as dose selection by the injector [8, 11].

The proper identification of muscles involved in CD cannot be overemphasized and requires an understanding of the different actions of the neck muscles. When examining the patient, dystonic muscles are best assessed when the neck is at rest or in submaximal contraction [8, 12]. More often than not, the dystonic muscles will show hypertrophy and are quite prominent. Superficial muscles are easily identified and palpated, making it easier to identify and inject. However, with deeper muscles, co-contraction of superficial muscles, or in certain cases where there is relative small muscle bulk, identification can be difficult.

Isolated postural deviations of the head occur in less than one-third of patients, while complex deviations occur in 66–80% of patients [1, 2]. There are generally four planes of movement in CD. However, most cases are compounded involving a combination of at least two movements, making muscle and dose selection more difficult.

Torticollis is when the neck turns from left to right or right to left along the horizontal axis in the coronal plane [22] (**Figure 1A**). Effector muscles for this action include the contralateral sternocleidomastoid and the ipsilateral splenius capitis, as well as other supporting neck muscles. In laterocollis, the head tilts to one side along the vertical plane (**Figure 1B**). The

movement is facilitated by the contractions of the ipsilateral splenius, sternocleidomastoid, scalene complex, levator scapulae, and posterior paravertebral muscles. In anterocollis, the head tilts forward (**Figure 1C**) and there is contraction of both sternocleidomastoids, scalene complex and the submental complex. Retrocollis is the opposite of the anterocollis, where the head tilts backwards (**Figure 1D**) and there are bilateral contractions of the splenius, deep paravertebral muscles, and upper trapezius. When compounded movements are present, muscle selection becomes more tedious and varying doses may prove beneficial. This includes identifying the more active dystonic muscles and preferentially giving these muscles a higher dose. In a patient who presents with both retrocollis and left torticollis (**Figure 1E**), the contralateral sternocleidomastoid and both splenius capitis muscles are chemodenervated, with the ipsilateral splenius receiving a higher dose than the contralateral counterpart. Another compound movement involves the lateral displacement of the neck along the horizontal axis (**Figure 1F**). A summary of involved muscles in the four general planes and some compound movements is seen in **Table 1**.

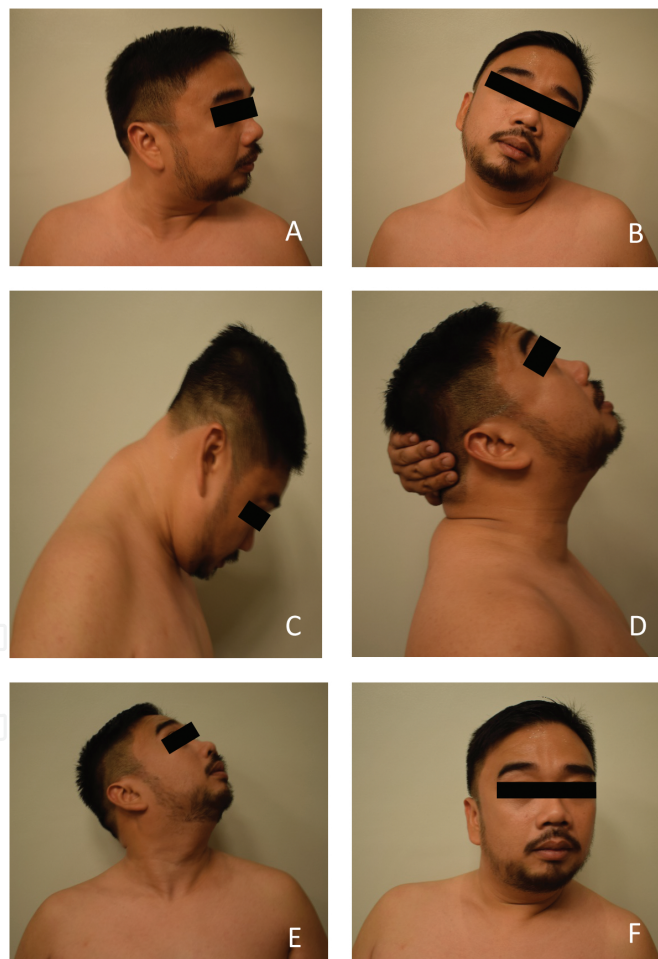


Figure 1. Different types of cervical dystonia. (A) Left torticollis, where the neck rotates to the left along the horizontal axis; (B) left laterocollis with the neck turned to the left along the vertical axis; (C) anterocollis with the neck bent forward; (D) retrocollis with the neck bent backwards; (E) compound movement of both torticollis and retrocollis to the left with left shoulder elevation; and (F) lateral displacement of the neck along the horizontal axis.

	OnaBoNTA (Botox) [8, 41]	AboBoNTA (Dysport) [8, 42]	IncoBoNTA (Xeomin) [8, 43]	RimaBoNTB (NeuroBloc/Myobloc) [8, 44]
Torticollis				
CL SCM	20–50	40–120	20–50	1000–3000
CL Anterior scalene	5–30	20–100	5–30	500–2000
CL Middle scalene	5–30	20–100	5–30	500–2000
CL Semispinalis capitis	20–100	60–250	20–100	1000–2000
CL Levator scapulae	20–100	60–200	20–100	1000–2000
IP Splenius capitis	40–100	100–350	40–100	1000–4000
IP Longus capitis	15–30	20–60	15–30	ND
Laterocollis				
IP SCM	20–50	40–120	20–50	1000–3000
IP Anterior scalene	5–30	20–100	5–30	500–2000
IP Middle scalene	5–30	20–100	5–30	500–2000
IP Posterior scalene	5–30	20–100	5–30	500–2000
IP Splenius capitis	40–100	100–350	40–100	1000–4000
IP Semispinalis capitis	20–100	60–250	20–100	1000–2000
IP Levator scapulae	20–100	60–250	20–100	1000–2000
IP Trapezius	25–100	60–300	25–100	1000–4000
Retrocollis				
IP Splenius capitis	40–100	100–350	40–100	1000–4000
CL Splenius capitis	40–100	100–350	40–100	1000–4000
IP Semispinalis capitis	20–100	60–250	20–100	1000–2000
CL Semispinalis capitis	20–100	60–250	20–100	1000–2000
IP Trapezius	25–100	60–300	25–100	1000–4000
CL Trapezius	25–100	60–300	25–100	1000–4000
Anterocollis				
IP SCM	20–50	40–120	20–50	1000–3000
CL SCM	20–50	40–120	20–50	1000–3000
IP Longus collis	15–30	20–60	15–30	ND
CL Longus collis	15–30	20–60	15–30	ND
IP Anterior scalene	5–30	20–100	5–30	500–2000
CL Anterior scalene	5–30	20–100	5–30	500–2000

IP: ipsilateral; CL: contralateral; ND: No Data; SCM: sternocleidomastoid.

Table 1. Target muscles and dose of BoNT for CD.

The use of equipment such as electromyography (EMG), ultrasonography, endoscopic/fluoroscopic, and even computed tomography guidance may help to locate the target muscles and thus lessen occurrence of unintended weakness of uninjected muscles [8, 13–16]. This is discussed in another chapter.

3. Treatment of cervical dystonia

The treatment of CD was initially limited to oral medication and eventually surgery.

These medications include anticholinergics, benzodiazepines, and antispasticity medications [17]. As much as 40% of patients reported improvement with trihexyphenidyl [18, 19]. However, these medications are often of limited benefit due to systemic side effects. Surgery with deep brain stimulation or selective peripheral denervation surgery for CD has shown inconsistent results [20–23].

The efficacy of Botulinum toxin (BoNT) has been demonstrated, warranting both European Federation of Neurological Societies (EFNS) and the American Association of Neurology (AAN) level A recommendations as first-line treatment [24, 25]. BoNT has been approved for use in many countries and remains the treatment of choice for CD [8, 18, 26, 27]. Recent studies also provided level A evidence supporting for the treatment of CD [28].

In its updated guideline, the AAN has now differentiated the different serotypes/preparations of BoNT and its level of evidence for CD: AboBoNTA and RimaBoNTB should be offered (Level A) while OnaBoNTA and IncoBoNTA should be considered (Level B), as options for the treatment of CD [26].

Reviews of BoNT treatment for CD suggest that 70–90% of patients derive symptomatic benefit from BoNT with at least one injection [29–31]. In a meta-analysis (8 trials with 361 patients using OnaBoNTA; 5 trials with 319 patients using AboBoNTA), it was shown that there was a statistically and clinically significant improvement on objective rating scales and subjective rating scales as well as for pain relief in subjective scales [7]. The same was also seen in a real-world design study (1046 patients) showing robust improvement in clinical ratings as measured via both physician- and subject-reported outcomes and excellent tolerability following OnaBoNTA treatment of CD [30].

There is no consensus on the duration of effect of the various BoNT in the treatment of CD. The minimum treatment duration was 7.8 ± 1.4 weeks, and maximum treatment duration was 21.0 ± 3.9 weeks [32]. Only 49.3% of patients rated the duration of response of >12 weeks for all BoNTA preparations [33]. In a comparative study of BoNT preparations for the treatment of CD, a significant difference in overall duration of effect was seen between the various groups with a mean duration of 104.3 days for the current formulation of OnaBoNTA, 75.7 days for AboBoNTA, and 91.2 days for RimaBoNTB [34].

OnaBoNTA and IncoBoNTA have comparable efficacies with a 1:1 conversion ratio and have demonstrated therapeutic equivalence in different indications including CD. An OnaBoNTA to AboBoNTA conversion ratio of 1:3, or even less, should be considered the most appropriate [35–38]. It is interesting that an Asian study found a clinical equivalent ratio of 1:2.5 [39]. A robust conversion factor of estimating the equivalent doses of BoNTA and Botulinum toxin B (BoNTB) remains to be tested in the clinics.

The injection interval of BoNT for the treatment of CD is typically 3–4 months in most clinical practices [40]. In one study (59 subjects), the inter-injection interval was 15.4 ± 3.4 weeks [32].

In the CD-PROBE registry, the mean time between treatments increased from 14.6 ± 4.1 weeks following treatment session 1 to 15.1 ± 5.2 weeks after treatment session 2 [30].

A single injection cycle of BoNT is effective and safe for treating CD, and further injection cycles continue to work for most patients [7].

4. Botulinum toxin therapy dosing

The appropriate dose given to the target muscles is equally important in a successful injection session. There are several types of BoNTs available; however, only four types have been approved for use in CD: three type A and one type B toxin. The approved toxins for use are OnaBoNTA (Botox), AboBoNTA (Dysport), IncoBoNTA (Xeomin), and RimaBoNTB (NeuroBloc/Myobloc). Although three of these are type A toxins, they are not equivalent. A summary of the common muscles to be injected according to the type of CD and its BoNT doses is presented in **Table 1**. Generally, in the initial treatment session, each muscle injected should not exceed 200 units for OnaBoNTA and IncoBoNTA, 500 units for AboBoNTA, and 5000 units for RimaBoNTB. The total dose given per patient per session should also not exceed 400 units for OnaBoNTA and IncoBoNTA, 1000 units for AboBoNTA, and 10,000 units for RimaBoNTB [8, 36].

5. Challenges with BoNT therapy

Responders to BoNT therapy is based on four criteria: magnitude of effect defined as more than 25% improvement in the TWSTRS, at least 12-week duration of effect as reported by the patient, tolerability defined as absence of severe related adverse events, and subjective perception of improvement [33].

For nonresponders, the clinician has to know whether the patient is a primary or secondary nonresponder or is a poor responder (treatment failure) [45]. Common determinants for an unsuccessful chemodenervation session/poor responder include suboptimal doses, suboptimal muscle targeting, intolerable side effects, and complex movement patterns, discordant expectations, and an incorrect diagnosis [46].

Although BoNTA resistance is a recognized entity, secondary nonresponse maybe due to other factors including the underlying severity of the CD [27, 47]. When confronted with these situations, it is prudent to investigate with neuroimaging techniques before the next injection session. A CT scan of the neck to visualize the cervical spine may help define the nature of dystonia. Employing this imaging technique is based on the new phenomenological classification for CD by Reichel with reference to the position of the cervical vertebrae from the head position. Torticollis and laterocollis involves the same angle of rotation from across all cervical vertebrae; however, when there is torticaput or laterocaput, the base of the skull and C1 are

on the same degree of rotation but differ from the rest of the cervical spine [48, 49]. The challenge for the injector confronted with these movements is to target deeper and smaller muscles. In patients with torticollis, it has been shown that 73% of cases involve the obliquus capitis inferior [49]. It is important to keep this in mind and to discuss the planned session with the patient including expected results to optimize treatment [8].

6. Adverse events

BoNT has a favorable safety profile. There is often a delicate balance to be found between achieving optimal efficacy and avoiding adverse events (AEs) [50]. The AEs of BoNT treatment are usually mild and self-limiting and similar in both nature and severity between the different formulations [8]. However, in some cases the outcome is disappointing or side effects occur. This can be due to the fact that either the target muscles were not injected accurately or unintended weakness of nontarget muscles occurred [15].

The most common AEs related to BoNT type A are as follows: dysphagia; neck muscle weakness; injection site pain; and “flu-like” symptoms [51]. AEs of BoNT type A are dose-related and mostly due to contiguous or distant spread of toxin. Therefore, it is important that injections are located precisely so that potential spread of toxin is minimized.

A meta-analysis of 36 randomized controlled studies reported AEs in 25% (353/1425) of the OnaBoNTA-treated patient versus 15% (133/884) in controls [52].

In a systematic review of the various preparations of BoNT in the treatment of CD, a significantly higher rate of dysphagia and positive dose-related effect were reported with AboBoNTA compared with the current formulation of OnaBoNTA or RimaBoNTB [34]. However, in another study, it was mentioned that the dysphagia did not appear to be dose- or treatment cycle-related [53].

In the CD-PROBE registry, 185 patients (17.8%) given OnaBoNTA experienced treatment-related adverse events. The most common events were weakness (6.9%, 185 subjects), dysphagia (6.2%, 65 subjects), and neck pain (2.3%, 24 subjects) [30].

For IncoBoNTA, the most frequently reported adverse events were dysphagia, neck pain, and muscle weakness which were usually mild [54].

Dry mouth was reported more frequently in the studies of RimaBoNTB compared to the formulations of BoNT type A; however, a dose-related effect was not seen with RimaBoNTB [34].

Most of these complications resolve spontaneously, usually within 2 weeks. Dysphagia was most frequently related to bilateral injection into sternocleidomastoid muscles [55, 56]. Measures to minimize these adverse events include always using the lowest effective dose.

7. Conclusion

BoNT remains the treatment of choice for CD. There are three BoNT type A and one BoNT type B formulations that are currently approved, and each has its own unique pharmacologic properties that may confer different side effect profiles, duration of therapeutic effects, and dosing recommendations [57,58].

A number of factors need to be considered in BoNT treatment. These include the correct diagnosis of CD, number and selection of neck and adjacent muscles to inject, the amount dose to use, and the length of intervals of reinjection. One has to remember that each patient will have to be individually assessed for dose and response optimization.

Acknowledgements

The authors wish to thank Dr. Jennifer Justice Manzano for her help.

Author details

Roland Dominic G. Jamora^{1,2*} and Anthony N. Piano³

*Address all correspondence to: rgjamora@up.edu.ph

1 Department of Neurosciences, College of Medicine – Philippine General Hospital, University of the Philippines Manila, Manila, Philippines

2 Movement Disorders Service and Section of Adult Neurology, Institute for Neurosciences, St. Luke's Medical Center, Quezon City and Global City, Philippines

3 Movement Disorders Clinic and Section of Neurology, Department of Medicine, The Medical City, Pasig City, Philippines

References

- [1] Chan J, Brin MF, Fahn S. Idiopathic cervical dystonia: clinical characteristics. *Mov Disord.* 1991;6:119–126. doi:<http://dx.doi.org/10.1002/mds.870060206>
- [2] Jankovic J, Leder S, Warner D, Schwartz K. Cervical dystonia: clinical findings and associated movement disorders. *Neurology.* 1991;41:1088–1091. doi:<http://dx.doi.org/10.1212/WNL.41.7.1088>

- [3] Epidemiological Study of Dystonia in Europe (ESDE) Collaborative Group. A prevalence study of primary dystonia in eight European countries. *J Neurol.* 2000;247:787–792. doi:<http://dx.doi.org/10.1007/s004150070094>
- [4] Jankovic J, Tsui J, Bergeron C. Prevalence of cervical dystonia and spasmodic torticollis in the United States general population. *Parkinsonism Relat Disord.* 2007;13:411–416. doi:<http://dx.doi.org/10.1016/j.parkreldis.2007.02.005>
- [5] Jamora RD, Tan AK, Tan LC. A 9-year review of dystonia from a movement disorders clinic in Singapore. *Eur J Neurol.* 2006;13:77–81. doi:10.1111/j.1468-1331.2006.01150.x
- [6] Kessler KR, Skutta M, Benecke R. Long-term treatment of cervical dystonia with botulinum toxin A: efficacy, safety, and antibody frequency. German Dystonia Study Group. *J Neurol.* 1999;246:265–274. doi:10.1007/s004150050345
- [7] Costa J, Espírito-Santo C, Borges A, Ferreira J, Coelho M, Moore P, Sampaio C. Botulinum toxin type A therapy for cervical dystonia. *Cochrane Database Syst Rev.* 2005;(1): CD003633. doi:10.1002/14651858.CD003633.pub2
- [8] Albanese A, Abbruzzese G, Dressler D, Duzynski W, Khatkova S, Marti MJ, Mir P, Montecucco C, Moro E, Pinter M, Relja M, Roze E, Skogseid IM, Timerbaeva S, Tzoulis C. Practical guidance for CD management involving treatment of botulinum toxin: a consensus statement. *J Neurol.* 2015;262:2201–2213. doi:10.1007/s00415-015-7703-x
- [9] Comella CL, Stebbins GT, Goetz CG, Chmura TA, Bressman SB, Lang AE. Teaching tape for the motor section of the Toronto Western Spasmodic Torticollis Scale. *Mov Disord.* 1997;12:570–575. doi:10.1002/mds.870120414
- [10] Albanese A, Sorbo FD, Comella C, Jinnah HA, Mink JW, Post B, Vidailhet M, Volkmann J, Warner TT, Leentjens AF, Martinez-Martin P, Stebbins GT, Goetz CG, Schrag A. Dystonia rating scale: critique and recommendations. *Mov Disord.* 2013;28:874–883. doi:10.1002/mds.25579
- [11] Jankovic J. Treatment of cervical dystonia with botulinum toxin. *Mov Disord.* 2004;19:S109–S115. DOI:10.1002/mds.20024
- [12] De Bruijn E, Nijmeijer SW, Forbes PA, Koelman JH, van der Helm FC, Tijssen MA, Happee R. Improved identification of dystonic cervical muscles via abnormal muscle activity during isometric contractions. *J Neurol Sci.* 2015;354:10–16. doi:10.1016/j.jns.2015.03.047
- [13] Allison SK, Odderson IR. Ultrasound and electromyography guidance for injection of the longus colli with botulinum toxin for the treatment of cervical dystonia. *Ultrasound Q.* 2016; doi:10.1097/RUQ.0000000000000226
- [14] Grigoriu AI, Dinomais M, Remy-Neris O, Brochard S. Impact of injection-guiding techniques on the effectiveness of botulinum toxin for the treatment of focal spasticity and dystonia: a systematic review. *Arch Phys Med Rehabil.* 2015;96:2067–2078. doi:10.1016/j.apmr.2015.05.002

- [15] Schramm A, Baumer T, Fietzek U, Heitmann S, Walter U, Jost WH. Relevance of sonography for botulinum toxin treatment of cervical dystonia: an expert statement. *J Neural Transm (Vienna)*. 2015;122:1457–1463. doi:10.1007/s00702-014-1356-2
- [16] Lim EC, Quek AM, Seet RC. Accurate targeting of botulinum toxin injections: how to and why. *Parkinsonism Relat Disord*. 2011;17:S34–S39. doi:10.1016/j.parkreldis.2011.06.016
- [17] Bressman SB. Dystonia update. *Clin Neuropharmacol*. 2000;23:239–251
- [18] Brans JW, Lindeboom R, Snoek JW, Zwarts MJ, van Weerden TW, Brunt ER, van Hilten JJ, van der Kamp W, Prins MH, Speelman JD. Botulinum toxin versus trihexyphenidyl in cervical dystonia: a prospective, randomized, double-blind controlled trial. *Neurology*. 1996;46:1066–1072. doi:10.1212/WNL.46.4.1066
- [19] Balash Y, Giladi N. Efficacy of pharmacological treatment of dystonia: evidence-based review including meta-analysis of the effect of botulinum toxin and other cure options. *Eur J Neurol*. 2004;11:361–370. doi:10.1111/j.1468-1331.2004.00845.x
- [20] Tagliati M, Krack P, Volkmann J, Aziz T, Krauss JK, Kupsch A, Vidailhet AM. Long-term management of DBS in dystonia: response to stimulation, adverse events, battery changes, and special considerations. *Mov Disord*. 2011;26:S54–S62. doi:10.1002/mds.23535
- [21] Ford B, Louis ED, Greene P, Fahn S. Outcome of selective ramisectomy for botulinum toxin resistant torticollis. *J Neurol Neurosurg Psychiatry*. 1998;65:472–478. doi:10.1136/jnnp.65.4.472
- [22] Münchau A, Palmer JD, Dressler D, O'Sullivan JD, Tsang KL, Jahanshahi M, Quinn NP, Lees AJ, Bhatia KP. Prospective study of selective peripheral denervation for botulinum-toxin resistant patients with cervical dystonia. *Brain*. 2001;124:769–783. doi:http://dx.doi.org/10.1093/brain/124.4.769
- [23] Braun V, Richter HP. Selective peripheral denervation for spasmodic torticollis: 13-year experience with 155 patients. *J Neurosurg*. 2002;97:207–212.
- [24] Simpson DM, Blitzer A, Brashear A, Comella C, Dubinsky R, Hallett M, Jankovic J, Karp B, Ludlow CL, Miyasaki JM, Naumann M, So Y. Assessment: botulinum neurotoxin for the treatment of movement disorders (an evidence-based review): report of the Therapeutics and Technology Assessment Subcommittee of the American Academy of Neurology. *Neurology*. 2008;70:1699–1706. doi:http://dx. doi.org/10.1212/01.wnl.0000311389.26145.95
- [25] Albanese A, Barnes MP, Bhatia KP, Fernandez-Alvarez E, Filippini G, Gasser T, Krauss JK, Newton A, Rektor I, Savoirdo M, Valls-Solè J. A systematic review on the diagnosis and treatment of primary (idiopathic) dystonia and dystonia plus syndromes: report of an EFNS/MDS-ES task force. *Eur J Neurol*. 2006;13:433–444. doi:10.1111/j.1468-1331.2006.01537.x

- [26] Simpson DM, Hallett M, Ashman EJ, Comella CL, Green MW, Gronseth GS, Armstrong MJ, Gloss D, Potrebic S, Jankovic J, Karp BP, Naumann M, So YT, Yablon SA. Practice guideline update summary: botulinum neurotoxin for the treatment of blepharospasm, cervical dystonia, adult spasticity, and headache. Report of the Guideline Development Subcommittee of the American Academy of Neurology. *Neurology*. 2016;86:1–9. doi:[http:// dx. doi. org/ 10. 1212/ WNL. 0000000000002560](http://dx.doi.org/10.1212/WNL.0000000000002560)
- [27] Bledsoe IO, Comella CL. Botulinum toxin treatment of cervical dystonia. *Semin Neurol*. 2016;36:47–53. doi:[http://dx.doi.org/ 10.1055/s-0035-1571210](http://dx.doi.org/10.1055/s-0035-1571210)
- [28] Hallett M, Albanese A, Dressler D, Segal KR, Simpson DM, Truong D, Jankovic J. Evidence-based review and assessment of botulinum neurotoxin for the treatment of movement disorders. *Toxicon*. 2013;67:94–114
- [29] Swope D, Barbano R. Treatment recommendations and practical applications of botulinum toxin treatment of cervical dystonia. *Neurol Clin*. 2008;26:54–65. doi:[http:// dx.doi.org/10.1016/S0733-8619\(08\)80005-9](http://dx.doi.org/10.1016/S0733-8619(08)80005-9)
- [30] Jankovic J, Adler CH, Charles D, Comella C, Stacy M, Schwarts M, Adams AM, Brin MF. Primary results from the Cervical Dystonia Patient Registry for Observation of Onabotulinumtoxin A Efficacy (CD PROBE). *J Neurol Sci*. 2015;349:84–93. doi:10.1016/j.jns.2014.12.030
- [31] Zoons E, Dijkgraaf MG, Dijk JM, van Schaik IN, Tijssen MA. Botulinum toxin as treatment for focal dystonia: a systematic review of the pharmaco-therapeutic and pharmaco-economic value. *J Neurol*. 2012;259:2519–2526. doi:<http://dx.doi.org/10.1007/s00415-012-6510-x>
- [32] Dressler D, Tacik P, Saberi FA. Botulinum toxin therapy of cervical dystonia. *J Neural Transm (Vienna)*. 2015;122:297–300. doi:10.1007/s00702-014-1253-8
- [33] Misra VP, Ehler E, Zakine B, Maisonnobe P, Simonetta-Moreau M; INTEREST IN CD group. Factors influencing response to Botulinum toxin type A in patients with idiopathic cervical dystonia: results from an international observational study. *BMJ Open*. 2012;2(3).pii: e000881. doi:10.1136/bmjopen-2012-000881
- [34] Chapman MA, Barron R, Tanis DC, Gill CE, Charles PD. Comparison of botulinum neurotoxin preparations for the treatment of cervical dystonia. *Clin Ther*. 2007;29:1325–1337. doi:<http://dx.doi.org/10.1016/j.clinthera.2007.07.020>
- [35] Scaglione F. Conversion ratio between Botox, Dysport, and Xeomin in clinical practice. *Toxins (Basel)*. 2016;8(3). pii: E65. doi:10.3390/toxins8030065
- [36] Poewe W, Deuschl G, Nebe A, Feifel E, Wissel J, Benecke R, Kressler KR, Ceballos? Baumann AO, Ohly A, Oertel W, Ku?niget G. What is the optimal dose of botulinum toxin A in the treatment of cervical dystonia? Results of a double blind, placebo controlled, dose ranging study using Dysport. *J Neurol Neurosurg Psychiatry*. 1998;64:13–17. doi:10.1136/jnnp.64.1.13

- [37] Odergren T, Hjalatason H, Kaakkola S, Solders G, Hanko J, Fehling C, Marttila RJ, Lundh H, Gedin S, Westergren I, Richardson A, Dott C, Cohen H. A double blind, randomised, parallel group study to investigate the dose equivalence of Dysport and Botox in the treatment of cervical dystonia. *J Neurol Neurosurg Psychiatry*. 1998;64:6-12. doi:10.1136/jnnp.64.1.6
- [38] Ranoux D, Gury C, Fondarai J, Mas JL, Zuberet M. Respective potencies of Botox and Dysport: a double-blind, randomized, cross-over study in cervical dystonia. *J Neurol Neurosurg Psychiatry*. 2002;72:459-462. doi:10.1136/jnnp.72.4.459
- [39] Yun JY, Kim JW, Kim HT, Chung SJ, Kim JM, Cho JW, Lee JY, Lee HN, You S, Oh E, Jeong H, Kim YE, Kim HJ, Lee WY, Jeon BS. Dysport and Botox at a ratio of 2.5:1 units in cervical dystonia: a double-blind, randomized study. *Mov Disord*. 2015;30:206-213. doi:10.1002/mds.26085
- [40] Marsh WA, Monroe DM, Brin MF, Gallagher CJ. Systematic review and meta-analysis of the duration of clinical effect of onabotulinumtoxinA in cervical dystonia. *BMC Neurol*. 2014;14:91. doi:10.1186/1471-2377-14-91
- [41] Botox 100 Units. Available from: <http://www.medicine.org.uk/emc/medicine/112> [Accessed: 2016-05-14]
- [42] Dysport 300 Units. Available from: <http://www.medicine.org.uk/emc/medicine/870>. [Accessed: 2016-05-14]
- [43] Xeomin 100 Units powder for solution for injection. Available from: <http://www.medicine.org.uk/emc/medicine/20666> [Accessed: 2016-05-14]
- [44] NeuroBloc 5000 U/ml solution for injection. Available from: <http://www.medicine.org.uk/emc/medicine/20568/SPC> [Accessed: 2016-05-14]
- [45] Marion MH, Humberstone M, Grunewald R, Wimalaratna S. British Neurotoxin Network recommendations for managing cervical dystonia in patients with a poor response to botulinum toxin. *Pract Neurol*. 2016;16:288-295. doi: 10.1136/practneurol-2015-001335
- [46] Jinnah HA, Goodman E, Rosen AR, Evatt M, Freeman A, Factor S. Botulinum toxin treatment failures in cervical dystonia: causes, management, and outcomes. *J Neurol*. 2016;263:1188-1194. doi:10.1007/s00415-016-8136-x
- [47] Ferreira JJ, Colosimo C, Bhidayasiri R, Marti MJ, Maisonobe P, Om S. Factors influencing secondary non-response to botulinum toxin type A injections in cervical dystonia. *Parkinsonism Relat Disord*. 2015;21:111-115. doi:10.1016/j.parkreldis.2014.09.034
- [48] Reichel G. Dystonias of the Neck: clinico-radiologic correlations. In: RL Rosales (Editor). *Dystonia: The Many Facets*. (Intech Open Access Publishers, Croatia), 2012, ISBN: 978-953-307-1116-8 (www.intechopen.com) (pp 17-32)

- [49] Reichel G. Cervical dystonia: a new phenomenological classification for botulinum toxin therapy. *Basal Ganglia*. 2011;5:12. doi: 10.1016/j.baga.2011.01.001
- [50] Brashear A. Botulinum toxin type A in the treatment of patients with cervical dystonia. *Biologics*. 2009;3:1–7. doi:<http://dx.doi.org/10.2147/BTT.S3113>
- [51] Truong D. Botulinum toxins in the treatment of primary focal dystonias. *J Neurol Sci*. 2012;316:9–14. doi:10.1016/j.jns.2012.01.019
- [52] Naumann M, Jankovic J. Safety of botulinum toxin type A: a systematic review and meta-analysis. *Curr Med Res Opin*. 2004;20:981–990. doi:10.1185/030079904125003962
- [53] Truong D, Brodsky M, Lew M, Brashear A, Jankovic J, Molho E, Orlova O, Timerbaeva S; Global Dysport Cervical Dystonia Study Group. Long-term efficacy and safety of botulinum toxin type A (Dysport) in cervical dystonia. *Parkinsonism Relat Disord*. 2010;16(5): 316–323. doi:10.1016/j.parkreldis.2010.03.002
- [54] Comella CL, Jankovic J, Truong DD, Hanschmann A, Grafe S; U.S. XEOMIN Cervical Dystonia Study Group. Efficacy and safety of IncobotulinumtoxinA (NT 201, XEOMIN®, botulinum neurotoxin type A, without accessory proteins) in patients with cervical dystonia. *J Neurol Sci*. 2011;308:103–109. doi:10.1016/j.jns.2011.05.041
- [55] Jankovic J, Schwartz KS. Clinical correlates of response to botulinum toxin injections. *Arch Neurol*. 1991;48:1253–1256. doi:10.1001/archneur.1991.00530240057020
- [56] Comella CL, Tanner CM, DeFoor-Hill L, Smith C. Dysphagia after botulinum toxin injections for spasmodic torticollis. Clinical and radiologic findings. *Neurology*. 1992;42:1307–1310. doi:10.1212/WNL.42.7.1307
- [57] Mills RR, Pagan FL. Patient considerations in the treatment of cervical dystonia: focus on botulinum toxin A. *Patient Prefer Adherence*. 2015;9:725–731. doi:10.2147/PPA.S75459
- [58] Han Y, Stevens AL, Dashtipour K, Hauser RA, Mari Z. A mixed treatment comparison to compare the efficacy and safety of botulinum toxin treatments for cervical dystonia. *J Neurol*. 2016;263:772–780. doi 10.1007/s00415-016-8050-2

