

We are IntechOpen, the world's leading publisher of Open Access books Built by scientists, for scientists

6,900

Open access books available

186,000

International authors and editors

200M

Downloads

Our authors are among the

154

Countries delivered to

TOP 1%

most cited scientists

12.2%

Contributors from top 500 universities



WEB OF SCIENCE™

Selection of our books indexed in the Book Citation Index
in Web of Science™ Core Collection (BKCI)

Interested in publishing with us?
Contact book.department@intechopen.com

Numbers displayed above are based on latest data collected.
For more information visit www.intechopen.com



Antimicrobial Therapy and Surgical Management of Odontogenic Infections

Robert Pellecchia, Curtis Holmes,
Golaleh Barzani and Francesco R. Sebastiani

Additional information is available at the end of the chapter

<http://dx.doi.org/10.5772/63317>

Abstract

Dentoalveolar infections include a wide range of conditions from localized abscesses to deep-neck space infections or more severe cases of necrotizing fasciitis. Odontogenic infections and emergencies are a significant part of an oral and maxillofacial surgeon's daily practice. On a daily basis, an oral surgeon needs to be prepared to deal with any infection-related emergencies ranging from a toothache, localized vestibular abscess to deep head and neck abscesses. Management of these odontogenic infections could propose a challenge due to complex microbiology of the odontogenic infection and the potential for advancement to a life-threatening emergency. It is crucial that the oral and maxillofacial surgeon has knowledge of anatomic boundaries and fascial spaces to be able to make an accurate diagnosis and perform prompt surgical management. For the patient, odontogenic infections may carry high incidence of morbidity and mortality if not treated promptly. Management of patient with an odontogenic infection is a multifaceted approach involving (1) an examination and assessment of the patient, (2) identifying the source of the infection, (3) anatomic considerations, (4) surgical intervention, (5) administration of the appropriate antimicrobial therapy, and (6) referral to an appropriate provider if indicated. This chapter provides the clinician with a better understanding of diagnosis and pharmacological management as well as surgical treatment of patients with odontogenic infections.

Keywords: odontogenic infection, cellulitis, abscess, multifascial space abscess, management of odontogenic infections, Ludwig's angina

1. Introduction

1.1. Patient examination and assessment: review

A comprehensive and thorough clinical examination is a critical component of treatment of odontogenic infections. A good clinician will need to accurately evaluate and examine the patient, to formulate a prompt diagnosis and plan for surgical management accordingly. Every examination should begin with an accurate history and physical examination with focus on the evaluation of airway. Airway evaluation perhaps is the most important step in evaluating odontogenic infections and will guide the clinician and dictate the next appropriate course of treatment. Information on the timing of initiation of symptoms will give the clinician an understanding on how quickly the infection is progressing. It is absolutely crucial that the clinician promptly recognize any signs of impending airway and take necessary steps to take control over the airway as soon as possible. Once the airway is deemed stable, the clinician can proceed to accessing patient's oral examination focusing on dentition, floor of the mouth, oral pharyngeal, pharyngeal space, and palatopharyngeal fold. This is then followed by a diagnosis and development of a treatment plan for patient care. Failure to complete a comprehensive history and examination of the patient can lead to improper treatment and/or delayed treatment of infections. This potentially leads to serious complications, including but not limited to airway compromise, mediastinitis, sepsis, and death [1].

A patient history includes attaining information regarding the symptoms, onset, and duration of the present illness. This information helps form an understanding of the severity of the patient's infection. Common signs and symptoms that should alert a provider of a developing or established infection include trismus, fever, difficulty swallowing, pain, difficulty breathing, dysphonia, and pain on swallowing [1–3]. The patient's medical history and current medications are key in assessing the patient's ability to fight infection as well as providing an insight to potential drug interactions.

The physical examination can start by the recording of vital signs; any fever chills or malaise should be the warning sign for a well-established infection. Oftentimes, clinicians can quickly assess the patient and severity of their situation over the initial few minutes they meet with the patient. Clinicians can quickly assess for airway compromise by observing patient's posture for sniffing position, any difficulty breathing, tolerating secretions, tongue position, and changes in voice, along with any obvious facial swelling. Clinicians should keep in mind that airway assessment is the most critical component of this examination and will help the clinician quickly determine should the patient require urgent surgical intervention. Clinicians should first establish whether the patient has a stable airway. Failure to recognize this crucial information will lead to more complications. Palpation, percussion, and thorough visual examination of the extra- and intraoral cavity provide necessary information for identifying the source and location of the infection. Providers should pay close attention to size swelling, tongue position, floor of the mouth swelling or elevation, visual disturbances, voice changes, vestibule, and uvula position. This should be followed by radiographic examination. If the clinician suspects that infection is diffused and involves multiple fascial spaces, then a maxillofacial or neck computed tomography (CT) with contrast should be obtained. The use

of contrast should be avoided should the patient have any renal problems or any allergies to intravenous dye. A complete laboratory workup consisting of complete blood cell count and basic metabolic panel must be done. C-reactive protein levels must also be measured as markers to assess the severity of infection and response to treatment. It is important to note that the use of blood cultures is not indicated in dentoalveolar infections as they yield negative results. After gathering all clinical and radiographic findings, clinician should quickly establish a plan of care that can vary from establishing a secure and stable airway, emergent or urgent surgical management with intravenous or oral antibiotic therapy. These treatments could vary based on the clinical and radiographic findings. Clinicians should keep in mind that clinical-radiographic examination is the most crucial step in helping clinicians establish whether the patient will require to be managed in a hospital setting or in an outpatient setting. It is important to note that if the clinician suspects any possibility of airway embarrassment or quick progression to a toxic patient, prompt establishment of a secure airway should be the first and most important priority.

2. Stages of abscess development

Odontogenic infections are commonly caused by bacteria native to the oral cavity. They arise from either periapical or periodontal sources. Periapical infections are the most common cause of odontogenic infections. In periodontal infections, attachment loss of the gingival fibers and destruction of supportive structures expose the teeth and tissues to bacterial introduction. Periapical infections begin with a carious lesion causing pulpal necrosis that introduces the pulp to microorganisms. The infection can quickly spread to periapical tissues and may spread to other fascial spaces. Upon accessing the periapical tissues, the process can remain localized to the bony structures as a cystic lesion, granuloma, or focal osteomyelitis. Periapical infection can also spread through cortical bone causing cellulitis, localized and or deep-space abscess formation.

After inoculation of bacteria into deeper tissues, abscess development progresses from cellulitis to abscess formation without early intervention. Cellulitis is an acute disorder associated with warm, diffuse, painful, indurated swelling of soft tissues that also may present with erythema. Indurated swelling begins to soften as an abscess develops represented by localized area of fluctuation (**Table 1**). An abscess is a collection of purulent material containing necrotic tissue, bacteria, and dead white blood cells. Patients may present at varying stages of the process. Bacteria responsible for odontogenic infections have the ability to spread hematogenously due to the high vascularity of head and neck structures allowing infections to present in distant sites including the orbit, brain, and spine [2, 4].

2.1. Anatomic considerations

Odontogenic infections spread from the bony structures through the cortical bone along the path of least resistance with the affected fascial spaces determined by the structures in proximity to the tooth roots [5]. This necessitates an understanding of fascial spaces and

anatomy to effectively diagnose and develop a surgical plan for the management of infections. The spaces that are primarily affected by odontogenic infections are located adjacent to the origin. Those spaces are categorized as primary fascial spaces. They include buccal, canine, sublingual, submandibular, submental, and vestibular spaces.

Characteristics	Cellulitis	Abscess
Duration	1-5 days	4-10 days
Pain	Generalized	Localized
Size	Large	Small
Location	Diffuse	Well circumscribed
Palpation	Doughy-indurated	Fluctuant
Presence of pus	No	Yes
Degree of concern	High	Moderate
Bacteria	Mixed	Anaerobic
Color	Red	Shiny center

Adapted from Flynn TR: Principles of Management and Prevention of Odontogenic Infections. In Peterson LJ, Ellis E, Hupp J, editors: Contemporary Oral and Maxillofacial Surgery, ed 6, St Louis, 2014, Mosby, pp 296–318.

Table 1. Cellulitis versus abscess.

After infection spreads to primary spaces, they can progress to include secondary spaces. Secondary spaces include pterygomandibular, infratemporal, masseteric, lateral pharyngeal, superficial and deep temporal, masticator, and retropharyngeal.

A basic understanding of the spread of infections into the primary spaces is established by understanding the origin and insertions of the buccinator and mylohyoid muscles in relation to the maxilla and the mandible. The buccinator inserts superiorly into the alveolus of the maxilla and inferiorly in the alveolus of the mandible. An infection that spreads within the constraints of those insertions results in a vestibular abscess, and the spread of infection above or below these insertions forms a buccal space infection. The mylohyoid muscle's origin is from the mylohyoid line of the mandible. Teeth with root apices below this origin are the mandibular second and third molars. Infectious spread from these teeth through the lingual plate forms submandibular space infections. The roots of the mandibular premolars and first molars lie above the mylohyoid and therefore infectious spread lingually associated with these teeth creates sublingual space infections. The teeth most frequently identified as the source of an infection are the mandibular molars, followed by the mandibular premolars [1, 3, 5].

A special note should be made of an indurated cellulitis involving bilateral submandibular, sublingual, and submental spaces with drooling, tongue displacement, dysphagia, and patient head positioned in the “sniffing” position. This is the classic description of Ludwig’s angina. This is a medical emergency in need of definitive airway management and timely surgical management and should be referred immediately to the nearest hospital for treatment. Patients

with infections associated with maxillary molars may also present with maxillary sinusitis due to the close proximity of root apices with the floor of the maxillary sinus. Conversely, patients with maxillary sinusitis may also present with symptoms of an infection, so it is prudent to perform an examination to develop the appropriate diagnosis (**Figures 1–5**).

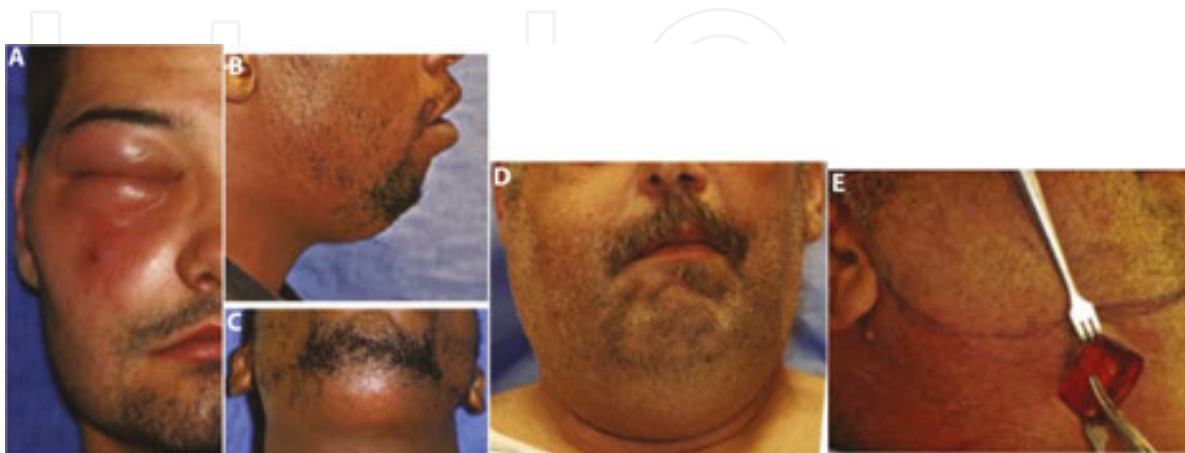

Figure 1. Fascial spaces of face and suprahyoid areas: (A) canine space infection; (B) masseteric space infection; (C) lateral pharyngeal and submandibular space infection; (D) submental space infection; (E) submental space infection surgical approach. Adapted from Cillo JE: Fascial Spaces of the Head and Neck. In Kademani D and Tiwana PS, editors: Atlas of Oral and Maxillofacial Surgery, St. Louis, 2016, Saunders.

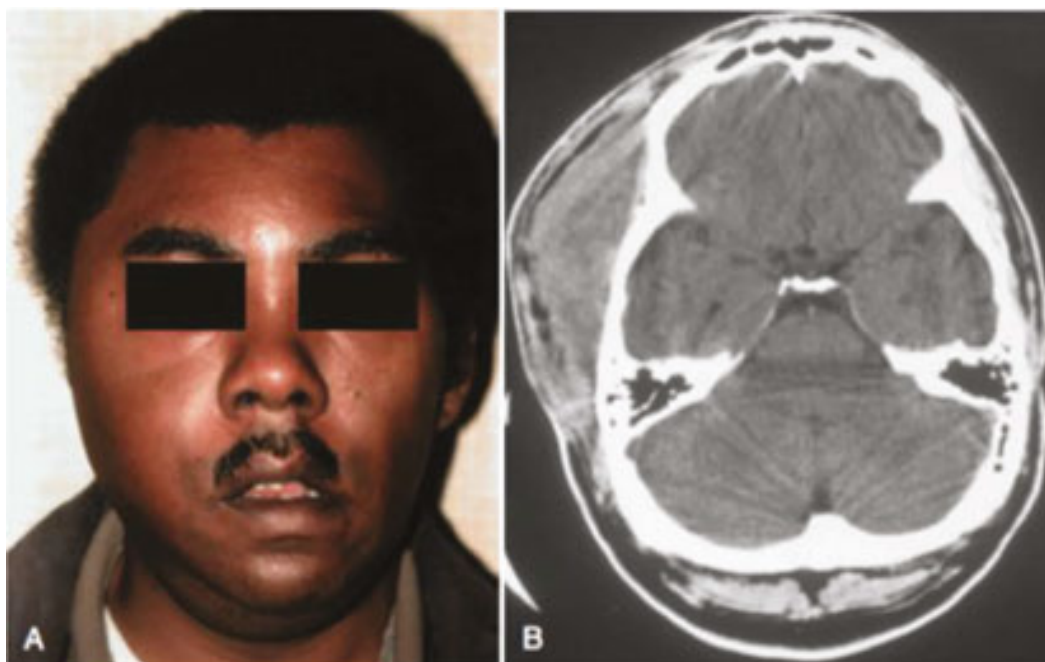

Figure 2. (A) Right masticator space infection (60-day duration); (B) right temporal space CT of abscess (same patient); 60 ml of pus aspirated. (A from Flynn TR: The swollen face. Emerg Med Clin North Am 15:481, 2000. B from Flynn TR: Anatomy of oral and maxillofacial infections. In Topazian RG, Goldberg MH, Hupp JR, editors: Oral and maxillofacial infections, ed 4. Philadelphia, 2002, Saunders.).

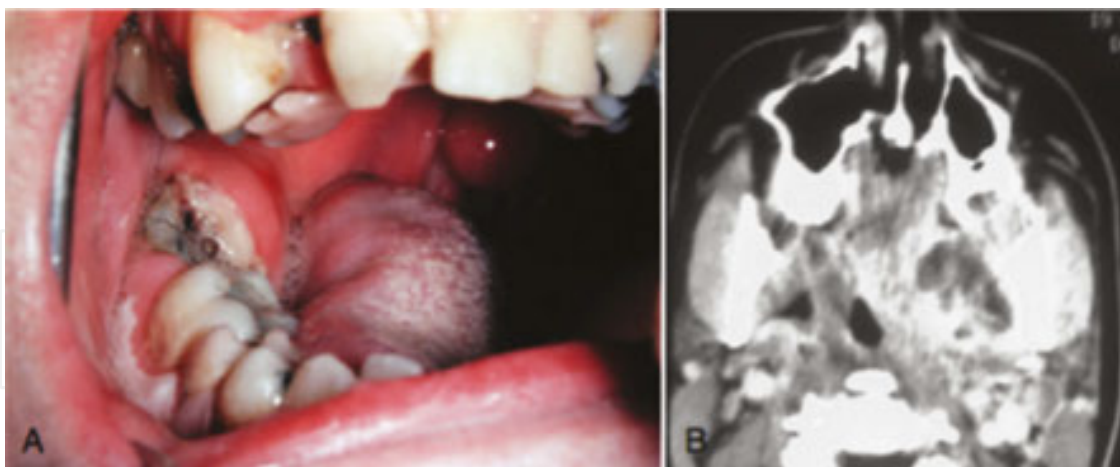


Figure 3. (A) Pterygomandibular space infection. Infected fracture of the mandible involving a partially erupted and carious right lower third molar, which was the source. Significant deviation of the uvula to the opposite side and the swelling of the right anterior tonsillar pillar. (B) CT of a pterygomandibular space abscess. Fluid collection seen between the ascending ramus of the mandible and the medially displaced medial pterygoid muscle. (A from Flynn TR, Topazian RG: Infections of the oral cavity. In Waite D, editor: Textbook of practical oral and maxillofacial surgery. Philadelphia, 1987, Lea & Febiger. B from Flynn TR: The swollen face. Severe odontogenic infections. Emerg Med Clin North Am 15:481, 2000.).

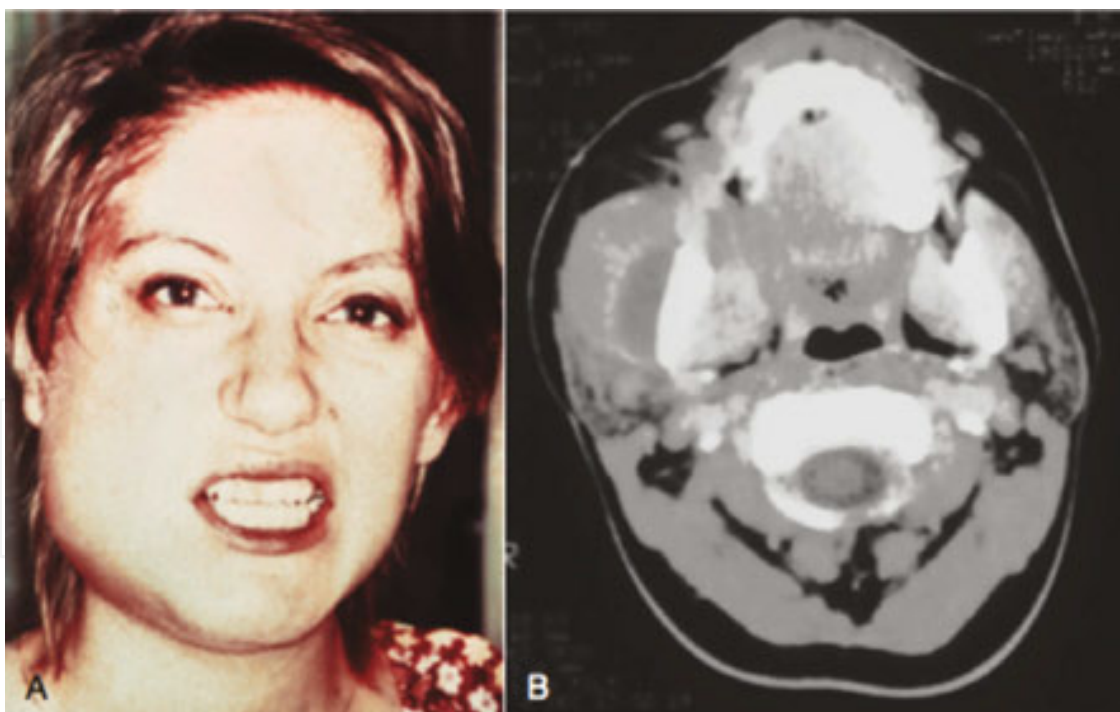


Figure 4. (A) Submasseteric space infection. Significant swelling over the right mandibular ascending ramus seen and severe trismus reported. (B) CT of a submasseteric space abscess. Collection of pus between the ascending ramus of the mandible and the overlying edematous masseter muscle. (A from Goldberg MH: Odontogenic infections. In Topazian RG, Goldberg MH, Hupp JR, editors: Oral and maxillofacial infections, ed 4. Philadelphia, 2002, Saunders. B from Flynn TR: Anatomy of oral and maxillofacial infections. In Topazian RG, Goldberg MH, Hupp JR, editors: Oral and maxillofacial infections, ed 4. Philadelphia, 2002, Saunders.).

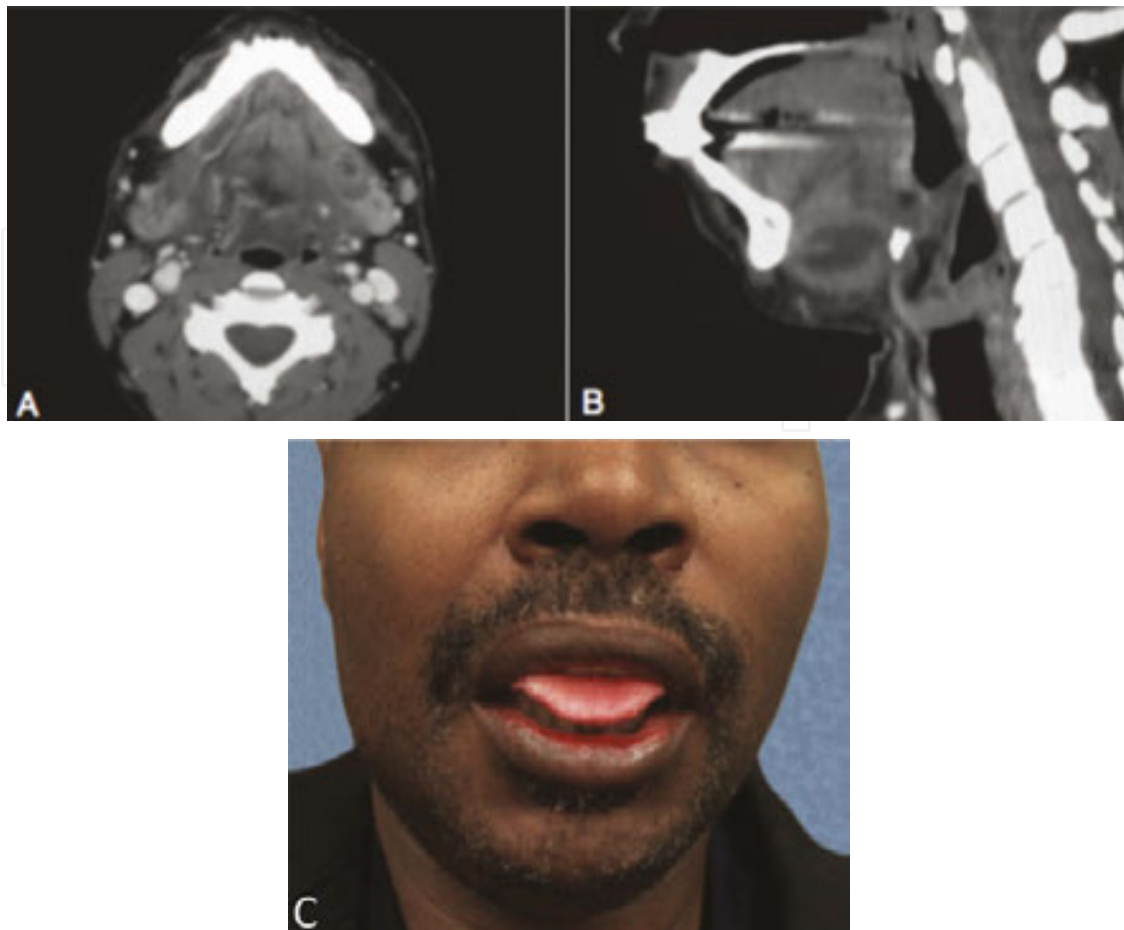


Figure 5. (A and B) Coronal and sagittal CTs with contrast of Ludwig's angina. (C) Inability to protrude the tongue is a sign of an infectious process involving the floor of the mouth. Adapted from Farnish SE: Ludwig's angina. In Bagheri SC, editor: Current Therapy in Oral and Maxillofacial Surgery, St. Louis, 2012, Saunders.

Computed tomography with intravenous contrast dye is the ideal modality for the identification of and delineation of the anatomic spread of severe deep fascial space infections. When the infection involves only the more superficial spaces, CT may not be necessary. Infections involving the deeper structures can be significantly more difficult to delineate using clinical methods alone. Contrast-enhanced CT (CECT) is useful in these cases. In head and neck infections, CECT may demonstrate ring enhancement, which is the hypervascular capsule surrounding a well-established abscess cavity. The combination of CECT and experienced clinical examination was able to identify clinically significant loculations of pus in the head and neck in 85% of cases [6].

2.2. Deep-space neck infection

If deep-space neck infection is suspected, it is imperative that the clinician makes an early diagnosis with a thorough clinical examination. These patients often present with nonspecific systemic signs, symptoms such as fever, chills, generalized malaise, and loss of appetite, but it is imperative that the clinician recognize more localized and specific symptoms such as

dysphagia, trismus, odynophagia, odontalgia, or dysphonia. According to a study by Mayor and colleagues, most commonly shared signs and symptoms shared by patients with deep-space neck infection were odynophagia, followed by dysphagia, fever, neck pain, and neck swelling [7]. In addition, these patients may show signs of neck swelling, floor of the mouth elevation, drooling, and inability to tolerate their secretions, diaphoresis, and bulging of pharyngeal wall. According to Osborn et al. [7], classic description of pharyngeal wall bulging is the presence of a midline bulge for prevertebral infections and a unilateral bulge for retropharyngeal space infections. It is important to note that submandibular space infections are the most common site of deep-neck space infections. Infection of lateral pharyngeal space can also be caused by nonodontogenic source such as tonsillar infections from peritonsillar space. Infection can spread from lateral pharyngeal or prevertebral space into the retropharyngeal space or danger zone (**Figure 6**) [7].

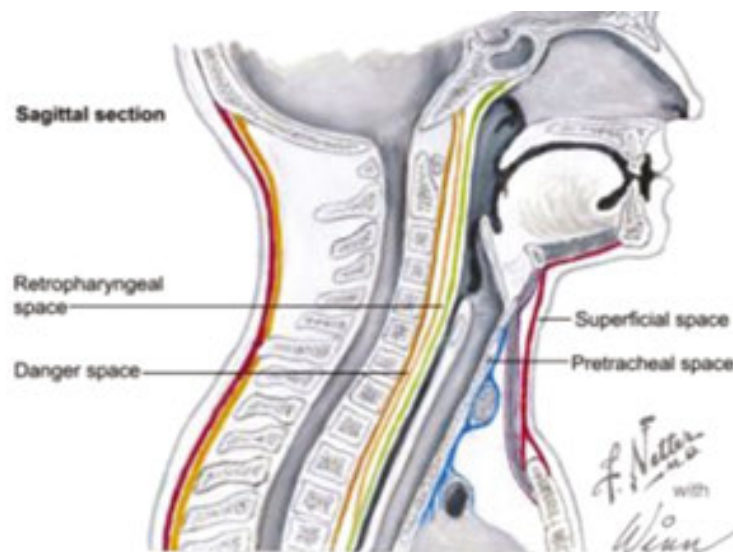


Figure 6. Deep spaces of neck infections. Adapted with permission from Osborn et al. [7]. PubMed PMID: 18603196.

2.3. Surgical intervention

Resolution of an odontogenic infection occurs after pharmacotherapy, but it is often studied in combination with surgical treatment [2, 3, 8]. Surgical intervention is believed by many to be the most important aspect of the management of odontogenic infection.

Odontogenic infection with abscess collection, detected clinically or radiographically, warrants incision and drainage by transcutaneous or transoral approach, in addition to dental extraction. The following eight steps are used to guide treatment of severe odontogenic infections (**Figure 7**).

Location and rate of progression determine the severity of the infection. In the various deep fascial spaces, infection can be classified as low, moderate, and high severity. Diligently taking the patient's medical history leads to proper evaluation of host defenses. Indications for hospitalization of a patient with odontogenic infections are as follows:

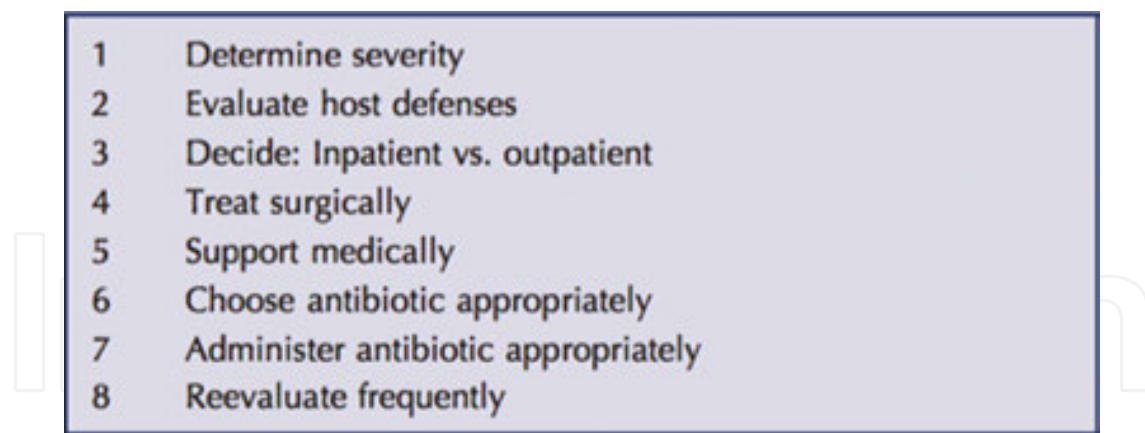


Figure 7. Steps in the management of severe head and neck infections. Adapted from Flynn TR: Principles and Surgical Management of Head and Neck Infections. In Bagheri SC, editor: Current Therapy in Oral and Maxillofacial Surgery, St. Louis, 2012, Saunders.

1. Impending airway compromise or threat to vital structures
2. Infection of deep-neck spaces or masticator space
3. Temperature of $>101^{\circ}\text{F}$
4. Need for general anesthesia
5. Need for inpatient control of systemic disease.

The surgical goals in head and neck infections are (1) to secure the airway, (2) to establish dependent drainage, and (3) to remove the cause of infection. Incision and drainage decreases the bacterial load the immune system must face by physically removing pus. Intraoral incisions are generally made in the oral vestibule at the point of maximum swelling. After surgical treatment, the patient must receive adequate medical support including nutrition, rehydration, and control of systemic disease. Steps six and seven will be discussed in detail later in this chapter. For outpatients, appropriate follow-up is 1–4 days. With hospitalized patients, daily follow-up is standard.

3. Treatment techniques

The initial step in the treatment of odontogenic infections is to assure that a stable airway is established. A topical cleansing agent should then be applied and aspiration of abscess should be completed using a syringe connected to a needle in a sterile fashion. Aspirate should be sent for microbiologic culture examination. Prior to incision, local anesthetic infiltration can be administered. Depending on the involved fascial space, various skin incisions have been described (**Figure 8**).

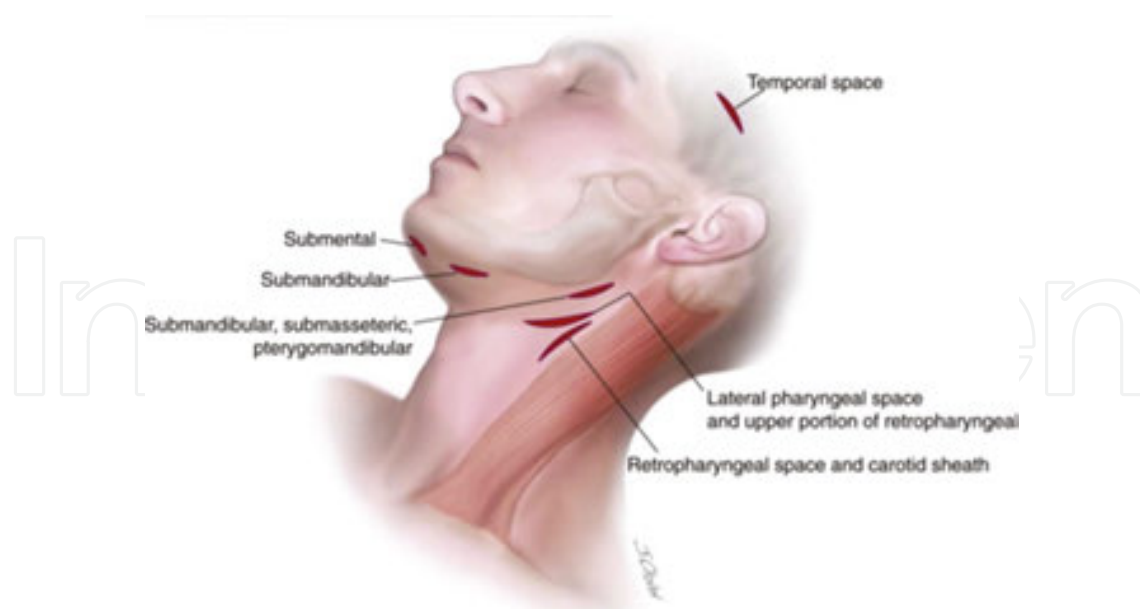


Figure 8. Typical incision sites for extraoral incision and drainage. From Lui DW and Abubaker AO: *Odontogenic Infection*. In Kademani D and Tiwana PS, editors: *Atlas of Oral and Maxillofacial Surgery*, St. Louis, 2016, Saunders.

On treating a submandibular abscess, the neck incision is approximately 2–4 cm below the angle of the mandible following a natural neck crease, inferior to the most inferior extent of inflammation. A mosquito hemostat is introduced through the skin, subcutaneous tissue, platysma muscle, and superficial layer of the deep cervical fascia until the inferior border of the mandible is encountered [9]. Subperiosteal instrumentation of the lateral and medial aspect of the mandibular ramus is then performed if masticator space is also involved. Normal saline solution should be used to irrigate all drainage sites. One-fourth inch penrose drains are then placed via incision sites and subsequently secured with 5/0 Prolene sutures. Dental extraction (removal of the source of infection) should be followed up next. The decision on extubation should be made with the anesthesiologist.

For lateral pharyngeal abscess treatment, the submandibular approach allows exploration of the lateral pharyngeal space by blunt finger dissection. This occurs in the superomedial direction between the posterior belly of digastric and the sternocleidomastoid (SCM) muscles (**Figure 9**).

Finger dissection of the lateral pharyngeal space is complete when the surgeon can palpate the endotracheal tube medially, the ipsilateral transverse processes of the vertebrae posteromedially, and the carotid sheath posterolaterally [9].

On treatment of the retropharyngeal abscess, the submandibular approach allows for exploration of the suprahyoid component. If the infrahyoid portion was also involved, the anterior SCM approach should be used. Finger dissection of the retropharyngeal space is a continuation of the complete dissection of the lateral pharyngeal space. Palpation of the contralateral transverse processes of the vertebrae, the endotracheal tube from its posterior aspect, and, if necessary, the contralateral carotid sheath ensure completion of dissection [9]. If necessary, the

danger space is entered by finger dissection through the alar fascia. It can be safely explored inferiorly as far as the T4 level.

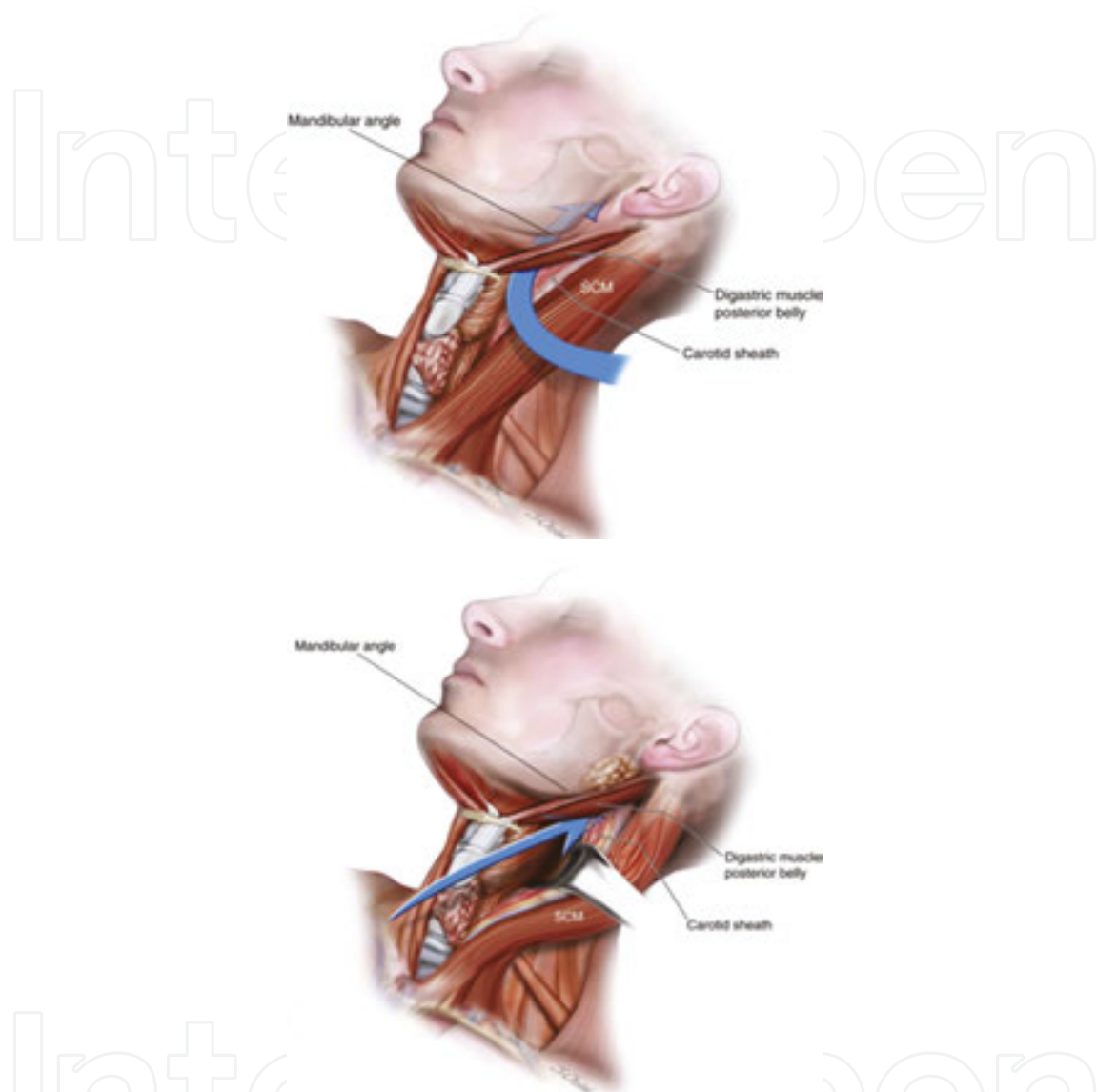


Figure 9. (A) Lateral pharyngeal space abscess incision and drainage. (B) Retropharyngeal abscess surgical access for incision and drainage. Adapted from Lui DW and Abubaker AO: *Odontogenic Infection*. In Kademani D and Tiwana P, editors: *Atlas of Oral and Maxillofacial Surgery*, St. Louis, 2016, Saunders.

Oral and maxillofacial surgeons should keep in mind that on treating descending mediastinal infection, thoracic surgical consultation is necessary. In a series of 10 patients, Freeman and colleagues reported no mortality when using the following treatment regimen: immediate thoracotomy incision and open-direct exploration, debridement, irrigation, and drainage of the mediastinum. Cervical incisions were used to explore and debride infection in the neck when necessary. Postoperative CT scans were obtained every 48–72 h, or more frequently if the clinical condition deteriorated [10]. These were used to guide additional surgeries to

aggressively drain any new loculations of pus. In 30% of cases, extension of the infection into the abdomen through the diaphragm was found. The subjects underwent a mean of six operations and six CT scans. The length of hospital stay was 14–113 days, with a mean of 46 days [10]. In these series cases, early, aggressive, and additional surgeries combined with frequent postoperative CTs reduced the mortality of mediastinitis from 20 to 0% (**Figure 10**).

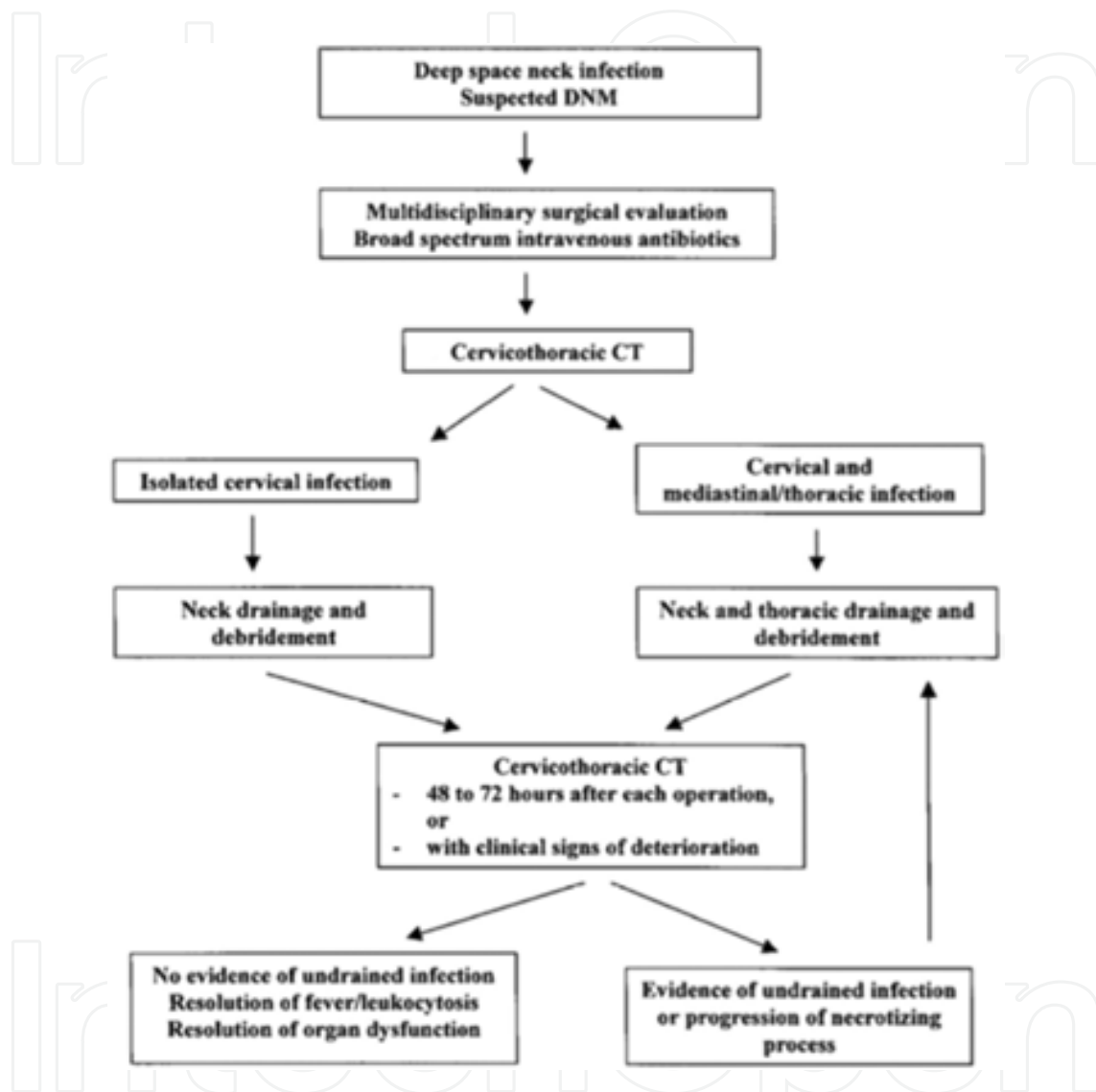


Figure 10. Treatment algorithm for patients with descending necrotizing mediastinitis (DNM). From Freeman RK, Vallieres E, Verrier ED, et al: Descending necrotizing mediastinitis: an analysis of the effects of serial surgical debridement on patient mortality, *J Thorac Cardiovasc Surg* 119:260, 2000.

3.1. Microbiology of an odontogenic infection

It has been stated that odontogenic infections arise from bacterial introduction in the deeper tissues of the head and neck. There is vast array of bacterial species all residing contemporaneously in the oral cavity and contribute to the normal oral flora. Odontogenic infections are characterized as a combination of aerobic and anaerobic bacteria. This is why they are

considered mixed infections. Streptococcal species are often responsible for orofacial cellulitis and abscess. Aerobic bacteria including *Streptococcus viridans*, *S. milleri* group species, beta-hemolytic streptococcus, and coagulase negative staphylococci have been cultured from odontogenic infections. Within the *S. milleri* group, the members *S. anginosus*, *S. intermedius*, and *S. constellatus* are most often associated with cellulitis. Anaerobic bacteria are often isolated from sites with chronic abscess formation. These pathogens include *Peptostreptococcus*, *Prevotella*, *Prophyromonas*, *Fusobacterium*, *Bacteroides*, and *Elkenella* [2, 3, 9, 12, 13, 16]. The most common microorganisms isolated from odontogenic infections have been consistent over the years [3, 8]. However, what has changed is the prevalence, the ability to isolate, and the ability to classify them due to changes in nomenclature [2, 5, 14].

Over the years, studies have shown that there has been a change in the antibiotic susceptibility of isolated organisms. While many streptococci are still penicillin-sensitive, especially those that are prevalent during the first 3 days of clinical symptoms, the gram-negative obligate anaerobes, present abundantly after 3 days, are producing penicillin-resistant strains [12, 17]. Recently, an increase in aerobes and anaerobes that are resistant to clindamycin regimens has been documented [2, 18]. This complicates recommendations for therapeutics for orofacial infections; however, traditionally used empirical antibiotics are excellent options if culture and sensitivity testing are not performed at or prior to the time of surgery. Nonetheless, providers must not forget the potential resistant organisms to empirical antibiotics. As a result of new resistant strains, antibiotic management of odontogenic infections has become increasingly more complex to cover a broader spectrum of offending microorganisms.

3.2. Antibiotics of choice

Antibiotics are antimicrobials used for the treatment and prevention of infections. They are classified as either bactericidal or bacteriostatic. Bactericidal antibiotics kill bacteria by inhibiting cell wall synthesis and bacteriostatic antibiotics inhibit bacterial growth and reproductions. **Table 2** lists common antibiotics and their classification. The choice of antimicrobial therapy for patients with odontogenic infections can be complex due to numerous variables that must be considered. Factors involved in antibiotic selection include host-specific factors and pharmacologic factors.

Host factors include the microbiology of odontogenic infections, history of allergic responses or intolerance, previous antibiotic therapy, age, pregnancy status, and immune system status [12]. Traditional pathogens found to be in association with orofacial infections are mixed in origin and consist of facultative and obligate anaerobic bacteria. The duration of the infectious process aids in deciphering which organisms predominate. Allergy to antibiotics is noted during acquisition of the medical history as well as information regarding antibiotic intolerance. Previous antibiotic therapy, especially on a consistent basis, yields a propensity for resistant organisms to an antibiotic. Certain antibiotics should be avoided in children as well as pregnant patients. The immunocompetence of a patient may direct antibiotic therapy toward bactericidal, rather than bacteriostatic types.

Empiric antibiotics of choice for odontogenic infections in outpatient setting	
No penicillin allergy	Penicillin allergy
PO	PO
-Pen VK 500 mg Q6h 7 days or Amoxicillin 500 mg Q8h, 7 days	
-Clindamycin 300 mg Q6h, 7 days	-Clindamycin 300 mg Q6h, 7 days
-Cephalexin (or first generation cephalosporin) 500 mg Q 12h 7-10 days	-Cephalexin (or first generation cephalosporin) 500 mg Q 12h 7-10 days
-Azithromycin 500 mg Q24, 5 days	-Azithromycin 500 mg Q24, 5 days
	-Metronidazole 500 mg TID, 7 days
	-Moxifloxacin 400 mg Q24 5 days
Empiric antibiotics of choice for odontogenic infections in inpatient setting	
No penicillin allergy	Penicillin allergy
IV	IV
Clindamycin IV, 600 mg Q8h	Clindamycin IV, 600 mg Q8
Ampicillin + metronidazole, 0.5-2 g Q6h/500 mg Q8h	Moxifloxacin 400 mg Q24
Ampicillin + sulbactam, 1.5-3 g Q6h	Cefotaxime, 1-2g Q12
Adapted from Flynn.	

Table 2. Empiric antibiotics of choice for odontogenic infections in outpatient and inpatient setting.

Pharmacologic factors of interest include spectrum of antibiotics, pharmacokinetics, tissue distribution of antimicrobials, cost of antibiotics, adverse reactions, and potential drug interactions [12]. The antibiotic spectrum is of important consideration, because it is best for the patient to receive therapy with antibiotics that are effective against the involved microorganisms. Pharmacokinetically, the effectiveness of such antibiotics is dependent upon serum concentration needed to kill bacteria or the time necessary to maintain adequate serum levels. Beta-lactams and vancomycin are time dependent, whereas fluoroquinolones are concentration dependent. The ability of an antibiotic to reach the site of an infection should be considered, because abscess cavities are avascular. Thus, antibiotic effectiveness is based on the ability to penetrate an abscess. Adverse reactions and potential drug interactions will be discussed later in the chapter.

Pathogen-specific antibiotic therapy is driven by results of culture and sensitivity testing. Site cultures are not obtained until surgical intervention is done; patients with orofacial infections warrant timely therapeutic management. Empirical antibiotic therapy for odontogenic infections is based on an understanding of common pathogens cultured from the infection site. Empiric antibiotics may be difficult to ascertain due to the complex microbiology of such infections; the timing of antibiotic administration and antibiotic resistance are important. **Table 2** shows empiric antibiotics of choice for odontogenic infections in the outpatient setting.

Penicillin still remains the antibiotic of choice in the outpatient setting for the management of odontogenic infections when there is no history of allergy [1–3], especially in infections of less than 3-day duration [3, 12]. Clindamycin is the antibiotic of choice for patients with an allergy to penicillin [1–3, 8]. This may also be considered for infections of longer than 3 days of duration due to the increase in penicillin-resistant organisms present at this stage [12, 17]. Of the macrolides, azithromycin has fewer drug interactions and is used to treat infections; however, resistance to macrolides has been reported [17]. Cephalosporins have been found to be effective in the treatment of orofacial infections, but there are pathogens that produce cephalosporinases. There also must be consideration for cross-allergy in penicillin-allergic patients. Metronidazole is excellent for obligate anaerobes and studies have shown its effectiveness in the outpatient setting; however, it is often used in the inpatient setting in combination with other antibiotics [2, 8, 12]. Moxifloxacin, a fourth-generation fluoroquinolone, has a spectrum of coverage including oral aerobes and anaerobes, including *E. corrodens*, which is clindamycin resistant. Moxifloxacin is an excellent antibiotic choice when initial antibiotics and surgery have remained ineffective (**Table 3**).

Bactericidal	Bacteriostatic
Beta-lactams	Macrolides
Penicillins	Erythromycin
Cephalosporins	Clarithromycin
Carbapenems	Azithromycin
Monobactams	
Aminoglycosides	Clindamycin
Vancomycin	Tetracyclines
Metronidazole	Sulfa antibiotics
Fluoroquinolones	

Adapted from Flynn.

Table 3. Bactericidal and bacteriostatic antibiotics.

3.3. Duration of antibiotics

A common antibiotic course for orofacial infections is 7–10 days. Flynn et al. hypothesized that antibiotic therapy for 4 days or less combined with appropriate surgical treatment results in equal or better clinical outcomes, as measured by time to resolution, morbidity, selections for antibiotic-resistant strains, and expense. In this systematic review, it was found that no clinically significant difference was found at day 7 with antibiotic courses of 7 days or less with appropriately administered surgical treatment. Chardin and colleagues [19] found no significant difference in clinical cure rate of antibiotic therapy after surgical intervention with amoxicillin 1 g for 3 days versus the same therapy for 7 days. Lewis and colleagues [16] found similar results when comparing surgical intervention followed by 3-g amoxicillin for two doses

8 h apart from penicillin V of 250 mg by mouth four times per day for 5 days. These studies support the emphasis on prompt and efficient surgical intervention in combination with antibiotic therapy.

Antibiotic	Usual dose (mg)	Usual interval (h)	Wholesale cost 2010 (\$)	1-week retail cost 2010(\$)	Amoxicillin cost ratio
Penicillins					
Amoxicillin	500	8	0.37	11.99	1.00
Penicillin V	500	6	0.74	12.29	1.03
Augmentin	875	12	5.05	51.99	4.34
Augmentin XR	20,000	12	7.38	108.99	9.09
Cephalosporins					
Cephalexin	500	6	1.23	15.19	1.27
Erythromycins					
Erythromycin	500	6	0.30	17.99	1.50
Clarithromycin	500	24	5.01	34.69	2.89
Azithromycin	250	12	7.78	120.99	10.09
Anaerobic					
Clindamycin (generic)	150	6	1.19	31.79	2.65
Clindamycin (2T)	300	6	2.38	59.99	5.00
Clindamycin (generic)	300	6	3.76	87.59	7.31
Metronidazole	500	6	0.73	34.49	2.88
Other					
Vancomycin	125	6	29.10	849.99	70.89
Ciprofloxacin	500	12	5.13	13.49	1.13
Moxifloxacin (Alyelox)	400	24	16.35	138.99	11.59

Table 4. Cost of oral antibiotics used in odontogenic infections.

3.4. Cost of antibiotics

The cost of antibiotics whether a factor that is often not considered during the treatment of odontogenic infections should be considered. The central focus is the resolution of infectious process with surgical treatment while providing effective and appropriate antibiotic therapy that will reduce the morbidity associated with the infection. Antibiotic cost can be compared based on the cost for a standard prescription for antibiotics of preference in oral formulations.

Amoxicillin is one of the least expensive oral formulations of antibiotics. Flynn considered the retail cost for a 1-week prescription that an uninsured patient would pay for antibiotic therapy. He obtained the cost of commonly prescribed antibiotics from a pharmacy chain in the Boston area. Then, he formulated a numeric cost comparison ratio by dividing the cost of the commonly prescribed medications by the cost of an amoxicillin prescription. This comparison found that the cost of a 150-mg Cleocin prescription is significantly less than the 300-mg prescription with a two 150-mg capsule regimen four times a day being 63% the cost of a 300-mg capsule four times a day therapy [8, 12] (**Table 4**).

3.5. Antibiotic resistance

A problem that has emerged regarding the effectiveness of selected antibiotic therapy for the management of odontogenic infections is antibiotic resistance. Antibiotic resistance occurs by four mechanisms namely alteration of a drug's target site, inability of a drug to reach its target, inactivation of an antimicrobial agent, or active elimination of an antibiotic from the cell [8, 17]. Alteration of the target site for an antibiotic occurs by genes allowing bacteria to synthesize peptides that prevent binding diminishing the affinity of the antibiotic. Some bacteria have bypass pathways that use alternate metabolic pathways when specific antibiotics are present. Antibiotics may be inactivated by bacterial enzymes; these enzymes can result in neutralization. Penicillinase and beta-lactamases are examples of this mechanism. Genes present in some bacteria produce proteins that prevent antibiotic uptake or signal for the removal of the antibiotic from the cell leading to antibiotic resistance as well. The genes necessary to drive antibiotic resistance are acquired through four mechanisms namely spontaneous mutation, gene transfer, bacteriophages, and mosaic genes [4, 8, 17]. Spontaneous mutation is considered the dominate source antibiotic resistance. Gene transfer occurs with transmissible DNA segments that transfer and insert genetic material after bacterial conjugation. Bacteriophages are viruses that infect bacteria and replicate to insert genetic material, subsequently highjacking the control of the bacteria's genetic and bacterial metabolism. Mosaic genomes are formed by bacteria incorporating fragmented DNA directly from dead members of related species. Collectively, these mechanisms allow the spread of genetic material from one bacterial species to another and can result in the resistant strain becoming the predominate strain of the species [8, 17].

Strides have been made to reduce the prevalence and manage antibiotic resistance. Non-antibiotic attempts relate to the hospital setting. This includes reduction of colonization sites, patient isolation, decreased length of hospital stay, and aseptic technique during intervention. Antibiotic-associated attempts include limiting antibiotic therapy to as narrow of a spectrum as possible to effectively manage the offending bacteria and utilizing broader spectrum antibiotics only when indicated. Culture and sensitivity testing of purulent exudate aid in identifying the susceptibility of bacteria to specific antibiotics. Kuriyama et al. examined a relationship between past administration of beta-lactam antibiotics and those patients producing increased amounts of resistant bacteria with odontogenic infections. It is beneficial to the clinician and patient to be diligent in obtaining history of previous odontogenic infections to guide treatment and consideration of possible antibiotic resistance.

4. Complications of antibiotic therapy and drug interactions

Antibiotic drugs have the potential to alter the effectiveness of other drugs and interfere with the metabolism of other drugs. The cytochrome p450 system is a complex set of drug-metabolizing enzymes in the liver and gastrointestinal (GI) system that breaks down many different drugs. When antibiotics that utilize this metabolic pathway inhibit cytochromes that are needed for metabolism of other drugs altering the bioavailability of one of the involved drugs, some of these interactions can lead to some severe adverse effects.

Providers should be mindful of some of the potential adverse reactions associated with antibiotic therapy and other medications. Erythromycin and other macrolides have been found to have drug interactions with numerous drugs including statins, theophylline, warfarin, carbamazepine, triazolam/midazolam, and antiarrhythmic. Side effects of these interactions range from bleeding issues, increased sedation, confusion, and seizures to cardiac dysrhythmias and death. Metronidazole has the potential for increased bleeding with the coadministration of warfarin due a decrease in the metabolism anticoagulants. Clindamycin may destroy gut flora and prevent absorption of vitamin K, which can cause an increase in anticoagulation. Metronidazole can also affect renal clearance of lithium and also has a disulfiram effect in combination with alcohol. Fluoroquinolones have been found to interfere with theophylline metabolism and cause seizures. These drugs have also been found to cause spontaneous tendon rupture. Fluoroquinolones should be avoided in children due to chondrotoxicity in growing cartilage.

Antibiotic allergy should be obtained while obtaining a patient's medical history. It is important to inquire about the nature of an allergy to assess whether a true anaphylactoid allergy exists. Penicillin is a common antibiotic for which patients report an allergy. One to 10% of patients develop an allergic response to penicillin during an initial course and a less than 1% chance of development of an allergic reaction exists with additional courses [8, 21]. There is a possibility for cross-allergy to cephalosporins. This occurs in 10–15% of patients with an allergy to penicillin and often involves patients with a history of anaphylaxis.

Antibiotic-associated colitis (AAC) is another possible adverse effect of antimicrobial therapy. *Clostridium difficile* is an enteric anaerobe that produces an exotoxin found in a stool assay of affected patients. Diagnosis of *C. difficile* occurs after symptoms of fever, abdominal cramping, five or more episodes of diarrhea per day, or positive results in a stool sample. AAC has been found to occur with clindamycin, beta-lactam/beta-lactamase inhibitor combinations, cephalosporins, and other antibiotic therapy, and is treated with the removal of the offending antibiotic and oral metronidazole or vancomycin. If no resolution occurs, these patients should be referred as soon as possible to rule out the potential need for surgical intervention.

A patient who is on oral contraceptive pills should be informed of the necessity to utilize other forms of birth control. Antibiotic therapy may kill enough gut flora that inhibits recirculation of estrogen which reduces the serum levels of estrogen and may allow for the patient to become pregnant. This has been found to only involve oral contraceptives, not implantable or injectable forms [8].

5. Management of medication-related osteonecrosis of the jaw

The American Association of Oral and Maxillofacial Surgeons (AAOMS) in 2014 as described in their position paper changed the nomenclature from bisphosphonate-related osteonecrosis of the jaw (BRONJ) to medication-related osteonecrosis of the jaw (MRONJ). The change in designation signals the increasing number of osteonecrosis cases secondary to the use of alternative antiresorptive and antiangiogenic therapies [23]. The oral and maxillofacial surgeon often encounters patients treated with antiresorptive medications via either oral or parenteral route. Most of those patients who require treatment with antiresorptive medications are afflicted with metastatic bone tumors with primary sites from the breast, prostate, and lung. Lytic bone lesions are more often associated with multiple myeloma. Included in the antiresorptive medication regimen are receptor activator of nuclear factor (RANK) ligand inhibitors and in particular, Denosumab. The RANK ligand inhibitors work by the inhibition of osteoclast formation thus reducing the risk of fracture of vertebral, non-vertebral, and hip in the osteoporotic patient [23]. Controversy persists as to the mechanism and pathophysiology of MRONJ. Theories include altered bone remodeling or oversuppression of bone resorption, angiogenesis inhibition, constant microtrauma, suppression of innate or acquired immunity, vitamin D deficiency, soft-tissue BP toxicity, and inflammation or infection [23]. In the context of managing MRONJ, as a bacterial infection one must be cognizant of postsurgical risks following extraction of teeth especially those with existing periodontal disease and or periapical pathology [23]. Dentoalveolar surgery is still considered a major risk in developing MRONJ. Approximately 52–61% of those patients following dentoalveolar surgery are at risk to develop MRONJ [23]. *Actinomyces* species was one of the first bacteria identified in osteonecrosis of the jaw. Biopsied specimens of bone have recently identified a combination of bacteria and fungi associated with the biofilm on exposed bone [23]. As a result, a regimen of complex therapies is often required to treat the osteonecrosis-related biofilm of bone.

5.1. Staging of MRONJ

Stage 1:

Exposed and necrotic bone asymptomatic with no evidence of infection localized to the alveolus.

Stage 2:

Exposed and necrotic bone with evidence of infection and symptoms.

Stage 3:

Exposed and necrotic bone with evidence of infection and one of the following:

- Exposed and necrotic bone beyond the alveolus with extension to the inferior border of the mandible and or maxillary sinus and zygoma.
- Pathologic fracture.
- Extraoral fistula.

- OA or oronasal fistula.
- Osetolysis beyond the inferior border of the mandible or sinus floor.

Those patients afflicted in Stages 1–3 can be treated empirically with long-term use of Chlorhexidine rinses [23]. Presurgical management with Chlorhexidine and a regimen of broad-spectrum antibiotics have been used as a modality of care with the initial management of symptomatic MRONJ. It appears that a specific antibiotic regimen is not universally accepted and is often the preference of the surgeon as to what is found to be most effective. Clearly, the approach to the use of antibiotics for those afflicted with MRONJ identifies this condition with a bacterial component. Developing a strategy as to what antibiotics would be effective is found on the understanding and identification of the bacterial flora. Coverage for *Actinomyces* is essential, as it is one of the most predictable bacterial organisms isolated in patients with MRONJ. *Actinomyces* is a gram-positive organism that thrives best in an anaerobic environment. This is an opportunistic organism that is best treated with Amoxicillin for 6 months to a year.

6. Summary

Odontogenic infections are emergencies that may present in the outpatient setting. Management of such emergencies can occur in the dental office; however, there are circumstances that warrant referral for definitive treatment. Clinicians treating orofacial infections should be able to effectively examine and assess patients, have an understanding of common microorganisms associated with an abscess, head and neck anatomy, and vectors of development and spread of an abscess. Providers choosing to engage in management should promptly provide treatment of odontogenic infections with a combination approach, involving surgical intervention and antimicrobial therapy. It is important to confirm that the patient does not have any medical condition that necessitates antibiotic prophylaxis prior to surgical intervention. If so, the provider should refer to the current American Heart Association guidelines for antibiotic prophylaxis regimen (**Table 5**).

Antimicrobial therapy is complicated by the mixed flora of an abscess and varied responses of microorganisms to penicillin. Antibiotic therapy selection should be chosen according to safety, cost, consideration for a patient's medical history, effectiveness of antibiotic, and stage in abscess development. The use of clindamycin has increased in dentistry; however, multiple clinical studies comparing clindamycin to penicillin or ampicillin have found clinical success rates of 97% or higher with penicillin [3]. Penicillin continues to be the drug of choice in odontogenic infections, while clindamycin is an excellent alternative in patient with penicillin allergy. A 7-day antibiotic therapy has traditionally been effective; however, studies have shown that a 3- to 4-day regimen should suffice in healthy patients [6]. Regardless of the empirical antibiotic choice, surgical intervention that removes the source of the infection is considered the primary treatment modality.

Situation	Agent	Regimen: single dose 30-60 min before procedure	
		Adults	Children
Oral	Amoxicillin	2 g	50 mg/kg
Unable to take oral medication	Ampicillin OR	2 g IM or IV	50 mg/kg IM or IV
	Cefazolin or ceftriaxone	1 g IM or IV	50 mg/kg IM or IV
Allergic to penicillins or ampicillin oral	Cephalexin OR	2 g	50 mg/kg
	Clindamycin OR	600 mg	20 mg/kg
	Azithromycin or clarithromycin	500 mg	15 mg/kg
Allergic to penicillins or ampicillin and unable to take oral medication	Cefazolin or ceftriaxone OR	1 g IM or IV	50 mg/kg IM or IV
	Clindamycin	600 mg IM or IV	20 mg/kg IM or IV

IM, intramuscular; IV, intravenous.

Table 5. Antibiotic prophylaxis regimen.

Author details

Robert Pellecchia^{1*}, Curtis Holmes², Golaleh Barzani² and Francesco R. Sebastiani²

*Address all correspondence to: rpelloms@gmail.com

1 Department of Dentistry and Oral Maxillofacial Surgery, Geisinger Medical Center, Danville, PA, USA

2 Department of Dentistry and Oral Maxillofacial Surgery, The Brooklyn Hospital Center, Brooklyn, NY, USA

References

- [1] Sato FR, Hajala FA, Freire Filho FW, Moreira RW, de Moraes M. Eight-year retrospective study of odontogenic origin infections in a postgraduation program on oral and maxillofacial surgery. *J Oral Maxillofac Surg* 2009;67:1.

- [2] Lypka M, Hammoudeh J. Dentoalveolar infections. *Oral Maxillofac Surg Clin N Am* 2011;23(3):415–424.
- [3] Flynn TR, Shanti RM, Levi MH, et al. Severe odontogenic infections, part 1: prospective report. *J Oral Maxillofac Surg* 2006;64:1093.
- [4] Levi M. The Microbiology of orofacial abscesses and issues in antimicrobial therapy. In: Piecuch JF, editor. *Oral and maxillofacial surgery knowledge update 2001*. Rosemont, IL: American Association of Oral and Maxillofacial Surgeons; 2001. pp. 5–22.
- [5] Stroe W, Haug RH, Lillich TT. The changing face of odontogenic infections. *J Oral Maxillofac Surg* 2001;59:739.
- [6] Flynn TR. Principles and surgical management of head and neck infections. In: Bagheri SC, editor. *Current therapy in oral and maxillofacial surgery*. St. Louis: Saunders; 2012. pp. 1080–1091.
- [7] Timothy M Osborn, et al. Deep space neck infection: principles of surgical management. *Oral Maxillofac Surg Clin N Am* 2008;20:353–365.
- [8] Flynn T. What are the antibiotics of choice for odontogenic infections, and how long should the treatment course last? *Oral Maxillofac Surg Clin N Am* 2011;23(4):519–536.
- [9] Kuriyama T, Nakagawa K, Karasawa T, et al. Past administration of b-lactam antibiotics and increase in the emergence of b-lactamase-producing bacteria in patients with orofacial odontogenic infections. *Oral Surg Oral Med Oral Pathol Oral Radiol Endod* 2000;89:186–192.
- [10] Lui DW, Abubaker AO. Odontogenic infection. In: Kademani D, Tiwana P, editors. *Atlas of oral and maxillofacial surgery*. St. Louis: Saunders; 2016. pp. 145–152.
- [11] Freeman RK, Vallieres E, Verrier ED, et al: Descending necrotizing mediastinitis: an analysis of the effects of serial surgical debridement on patient mortality. *J Thorac Cardiovasc Surg* 2000;119:260.
- [12] Flynn TR, Halpern LR: Antibiotic selection in head and neck infections. *Oral Maxillofac Surg Clin N Am* 2003;15:17.
- [13] Brook I. Microbiology and management of peritonsillar, retropharyngeal, and parapharyngeal abscesses. *J Oral Maxillofac Surg* 2004;62:1545–1550.
- [14] Haug R. The changing microbiology of maxillofacial infections. *Oral Maxillofac Surg Clin N Am* 2003;15:1–15.
- [15] Kuriyama T, Karasawa T, Nakagawa K, et al. Bacteriologic features and antimicrobial susceptibility in isolates from orofacial odontogenic infections. *Oral Surg Oral Med Oral Pathol Oral Radiol Endod* 2000;90:600–608.
- [16] Rega AJ, Aziz SR, Ziccardi VB. Microbiology and antibiotic sensitivities of head and neck space infections of odontogenic origin. *J Oral Maxillofac Surg* 2006;64:1377–1380.

- [17] Flynn TR. Update on the antibiotic therapy of oral and maxillofacial infections. In: Piecuch JF, editor. Oral and maxillofacial surgery knowledge update 2001. Rosemont, IL: American Association of Oral and Maxillofacial Surgeons; 2001: pp. 23–50.
- [18] Poeschl PW, Spusta L, Russmeuller G, et al. Antibiotic susceptibility and resistance of the odontogenic microbiological spectrum and its clinical impact on severe deep space head and neck infections. *Oral Surg Oral Med Oral Pathol Oral Radiol Endod* 2010;11:151–156.
- [19] Chardin H, Yasukawa K, Nouacer N, et al. Reduced susceptibility to amoxicillin of oral streptococci following amoxicillin exposure. *J Med Microbiol* 2009;58(Pt 8):1092–1097.
- [20] Lewis MA, McGowan DA, MacFarlane TW. Short course high-dosage amoxycillin in the treatment of acute dento-alveolar abscess. *Br Dent J* 1986;161(8):299–302.
- [21] Craig TJ, Mende C. Common allergic and allergic-like reactions to medications: when the cure becomes the curse. *Postgrad Med* 1999;105:173–1781.
- [22] Hersh EV. Adverse drug interactions in dental practice: interactions involving antibiotics. Part II. *J Am Dent Assoc* 1999;130:236–251.
- [23] Ruggiero SL, Dodson TB, et al. Medication related osteonecrosis of the jaws—2014 update. American Association of Oral and Maxillofacial Surgeons; *J Oral Maxillofac Surg*. 2014;72(10): 2–19.

