

We are IntechOpen, the world's leading publisher of Open Access books Built by scientists, for scientists

6,900

Open access books available

185,000

International authors and editors

200M

Downloads

Our authors are among the

154

Countries delivered to

TOP 1%

most cited scientists

12.2%

Contributors from top 500 universities



WEB OF SCIENCE™

Selection of our books indexed in the Book Citation Index
in Web of Science™ Core Collection (BKCI)

Interested in publishing with us?
Contact book.department@intechopen.com

Numbers displayed above are based on latest data collected.
For more information visit www.intechopen.com



How Much Evidence do we have on the Central Effects of Botulinum Toxin in Spasticity and Dystonia?

Tomáš Veverka, Martin Nevrlý, Pavel Otruba,
Petr Hlušík and Petr Kaňovský

Additional information is available at the end of the chapter

<http://dx.doi.org/10.5772/64763>

Abstract

The brain is continually reorganizing (plasticity). Plastic changes within the sensorimotor system are not only beneficial (adaptive plasticity) but may even worsen function (maladaptive plasticity). Conditions such as dystonia and poststroke spasticity (PSS) that interfere with motor performance could be attributed to maladaptive plasticity. Botulinum toxin (BoNT) has been proven to be safe and effective in treating various hyperfunctional cholinergic states. Beside the well-known neuromuscular junction site of action, BoNT also exerts effects through supraspinal mechanisms and can even affect cortical reorganization. The hypothesis of central reorganization following BoNT treatment has been supported by studies using neurophysiological and imaging methods in patients with focal dystonia and PSS. The growing evidence of BoNT-related central (remote) effects make BoNT injections a promising tool to favorably affect maladaptive changes even at the cortical level.

Keywords: stroke, dystonia, spasticity, botulinum toxin, functional magnetic resonance imaging, neuronal plasticity

1. Introduction

Botulinum toxin (BoNT) type A is a valuable therapeutic option for the management of poststroke spasticity (PSS) [1–3] and focal dystonia [4]. BoNT acts at the neuromuscular junction, and the mechanism of action on muscle spindles has been well described [5, 6]. In the periphery, BoNT affects intrafusal fibers as well as extrafusal ones and thus alters pathological sensory inputs to the central nervous system (CNS) by blocking of the neuro-

muscular junction of the gamma motor neurons [6]. This blockade leads to a reduction of Ia afferent signals and indirectly inhibits pre-existing feedback-driven execution mode. This is probably the mechanism by which BoNT injected in the periphery may induce dynamic changes at several hierarchical levels of the sensorimotor system, presumably including cerebral cortex [7]. The hypothesis of central reorganization following BoNT treatment has been supported by studies using neurophysiological and imaging methods in patients with focal dystonia and PSS.

2. Spasticity

Stroke is a leading cause of disability in Western countries [8]. Ischemic lesions of descending tracts result in upper motor neuron syndrome (UMNS) comprising both negative signs (weakness and loss of dexterity) and positive signs (especially spasticity) [9]. Up to two thirds of stroke survivors experience impaired function and spasticity of the upper limb, and wrist and finger impairments usually prevail over involvement of proximal shoulder muscles [10, 11]. The degree of muscle weakness is crucial in determining the movement deficit following stroke, but spasticity may also be contributory [12, 13]. It is generally recognized that PSS may interfere with voluntary movement [14]. Disabling PSS affects patient's quality of life and frequently causes significant reductions in manual dexterity, mobility, walking/falling, and performance of activities of daily living (ADL) [15]. Disabilities associated with PSS place a significant burden on stroke survivors and subsequently on caregivers [16]. Prevalence data for PSS are limited by a lack of population-based studies; however, current estimates range from 19 to 42.6% [15, 17]. Numerous clinical trials have shown that BoNT is a safe and effective therapeutic tool to relieve upper limb PSS and improve function of the affected limb [1, 18, 19]. Recommended treatment strategies to relieve PSS combine physiotherapy procedures with BoNT application [1–3]. Although BoNT acts primarily on muscle spindles [5, 6], there is growing evidence that BoNT also exerts effects through supraspinal mechanisms and can even affect cortical reorganization [7]. The hypothesis of central reorganization following BoNT treatment has been supported mostly by studies using neurophysiological [20–23] and imaging [24–26] methods in patients with focal dystonia. Most of published functional magnetic resonance imaging (fMRI) studies in chronic stroke patients have described changes in task-related cortical activity following physiotherapy treatment [27, 28]. In the last decade, several studies reported central (remote) effects of BoNT in PSS.

Two pilot studies using blood oxygenation level dependent (BOLD) functional magnetic resonance imaging (fMRI) to register and localize BoNT-related changes of cerebral cortex activation were conducted. Both studies showed that effective treatment of spasticity led to a reduction of abnormal extensive bilateral activation of cortical and subcortical areas during actively performed or imagery of finger movement. The between-session contrasts designed to display the specific BoNT effect revealed a significant change in the local BOLD signal magnitude not only in traditional motor areas but also in areas that have been considered to be a part of a “broader” motor system or have only rarely been reported in the context of volitional motor control (posterior cingulate, DLPFC, Broca's area). Finally, the above-

mentioned studies confirmed that fMRI is a suitable tool in studying cortical relief of spasticity and that the three-session study design permits decomposition of BoNT effect from compounding effects of rehabilitation and time [29, 30]. Nevertheless, the promising results have been limited by the small number of subjects.

Manganotti et al. [31], in another fMRI study involving patients with PSS treated with BoNT alone, reported a similar effect representing a trend toward normalization of movement-induced brain activation. Detected pretreatment overactivation in the bilateral sensorimotor cortex (SM1, supplementary motor area (SMA)) and cerebellum was followed by decrease in extent of sensorimotor activation with increase in laterality after BoNT application.

In a subsequent fMRI study based on the pilot results [29, 30], using the combination of rehabilitation and BoNT for completely plegic patients with PSS, the alleviation of spasticity following BoNT treatment was associated with reduction of the brain activation volume in response to a motor imagery. The BOLD signal at week 11, when peripheral effect of BoNT was expected to wane (BoNT-off), revealed further volume reduction (**Figure 1**). The authors hypothesized that BoNT application modifies the process of cerebral plasticity and that this impact might persist despite temporary effect of BoNT on muscle fibers. A notable exception to this trend would be in regard to the cerebellar hemispheres, which either appear similarly active across the three imaging sessions (ipsilesional) or manifest transient activation at the time of maximal BoNT effect (contralesional) [32].

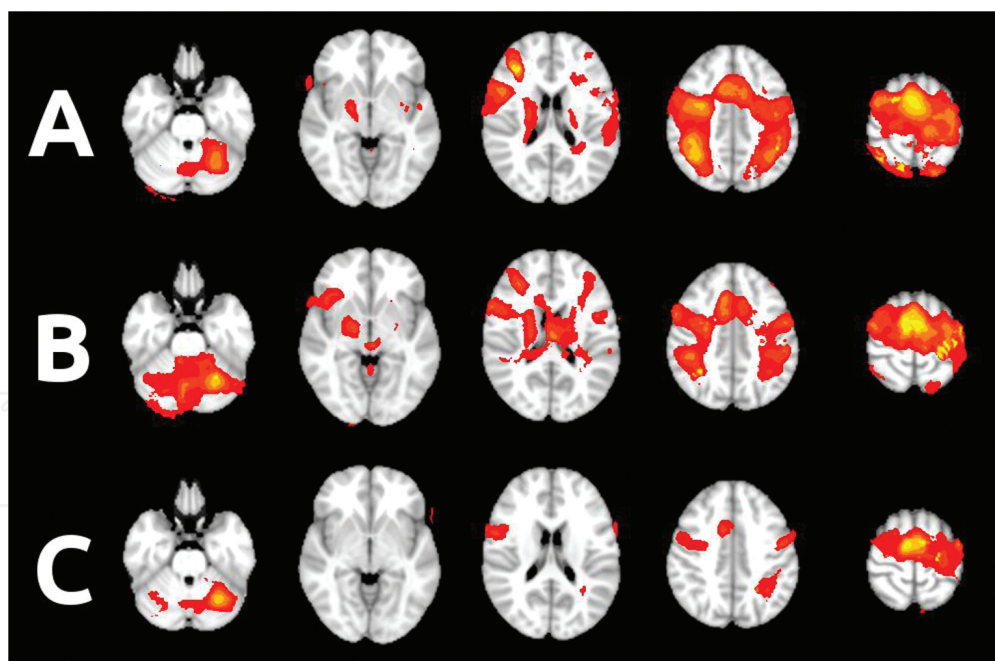


Figure 1. Functional MRI activation during imagery of finger movement (A) before BoNT treatment, (B) 4 and (C) 11 weeks after BoNT application (group mean statistical maps overlaid in color on the MNI anatomical template). Adapted with permission from Veverka et al. [32].

The following study of two age-matched groups with moderate and severe hand weakness demonstrated different effects of BoNT-induced improvement in spasticity on sensorimotor

networks. The plegic group performing movement imagery in MR scanner manifested BoNT-induced reduction of activation in structures associated with visual imagery. Regarding the occipitoparietal changes, the BoNT treatment in plegic subjects might switch their neural processing from visual to kinesthetic imagery pattern. In the paretic group, performing sequential finger movement, overall brain activation was markedly reduced after BoNT. Between-session contrasts yielded significant BoNT-related changes in the ipsilesional DLPFC and Broca's area, similarly as in the study of Tomášová et al. [30]. Both areas have been reported to participate in motor learning, rather than volitional motor performance and control [33]. Several areas with decreased task-related BOLD response after BoNT-induced spasticity relief subsequently increased their activation again as BoNT effect waned. These included the ipsilesional lateral occipital cortex, ipsilesional cortex bordering the intraparietal sulcus, and contralesional cerebellum. Activation reductions over the whole three-month study period were located in bilateral occipital cortex, which may reflect the decreased need to engage visualization in order to perform the movement with the paretic hand.

Another study using a combination of BoNT and rehabilitation in a subgroup of post-stroke spasticity with residual motor activity reported BOLD activity increases in the ipsilesional primary sensorimotor cortex and in the contralesional secondary somatosensory area 14 weeks following BoNT application enhanced by three months of repetitive arm cycling. The authors concluded that observed cortical changes reflect a treatment-induced effect [34].

In a recent study, Bergfeldt et al. [35] reported an increase in brain activation in response to an active motor task in the motor and premotor cortex (predominantly contralesional) at the baseline and an overall decrease in activation with contralesional predominance following comprehensive focal spasticity therapy.

A more recent study [36] engaging severely affected patients with PSS revealed BoNT-related patterns of cerebral cortex activation during passive hand movement. The whole-brain fMRI data were acquired during paced repetitive passive movements of the plegic hand (flexion/extension at the wrist) alternating with rest. Passive movement induces sensorimotor cortex activation in another way, with particular emphasis on afferent inputs to the CNS [37]. Across all the sessions, fMRI activation of the ipsilesional sensorimotor cortex (M1, S1, and SMA) dominated, with notable temporal reduction of activation throughout the study (paired contrast pre-BoNT > BoNT-off). At week 4, when maximal pharmacological effect of BoNT is expected, additional clusters transiently emerged bilaterally in the cerebellum, in the contralesional sensorimotor cortex, and in the contralesional occipital cortex. Paired contrasts demonstrated significant differences post-BoNT > pre-BoNT (bilateral cerebellum and contralesional occipital cortex) and post-BoNT > BoNT-off (ipsilesional cerebellum and SMA) [36].

Stroke triggers a number of processes at various levels of the motor system that can cause spontaneous recovery or motor improvement (adaptive plasticity). Plastic changes within the sensorimotor system are not only beneficial but may even worsen residual function. From this point of view, appearance of poststroke upper limb spasticity that interferes with motor performance could be attributed to so-called maladaptive plasticity. The BoNT injection is a well-established component of multimodal treatment of PSS. The growing evidence of BoNT-

related central (remote) effects makes BoNT a promising tool to favorably affect maladaptive changes even at the cortical level.

3. Dystonia

BoNT types A and B have been proven to be safe and effective in treating various hyperfunctional cholinergic states [38, 39]. BoNT is more effective in blocking active neuromuscular junctions [40]. BoNT disrupts neurotransmission by cleavage of presynaptic vesicle fusion proteins; SNAP-25 for BoNT type A and synaptobrevin for BoNT type B [5]. BoNT is currently considered to be one of the most effective therapeutic options in the management of focal dystonias [4]. The clinical effect of BoNT on dystonia is assumed to be mediated by dynamic changes at multiple levels of the sensorimotor system, from the neuromuscular junction up to the cerebral cortex, as documented by previous behavioral and electrophysiological studies [21, 41]. Some fMRI studies showed significant treatment-related changes in the sensorimotor network in patients with cervical dystonia receiving long-term treatment with BoNT [25, 26]. It is important to stress here that the BoNT experience from the past 20 years brought us nearer to our understanding of the underpinnings of current dystonia pathophysiological concepts. Undoubtedly, the introduction of the first-generation BoNT products (Botox, Allergan Pharmaceuticals, Irvine, CA, USA; Dysport, Ipsen Pharmaceutical, Paris, France) not only led to the breakthrough in dystonia treatment but also the breakthrough in dystonia research. We now know that the dystonic hyperactive and cholinergically sensitive extrafusal, and in parallel, the intrafusal muscle fibers are the prime targets of BoNT therapy [6]. It is in the latter effect of BoNT in muscle spindles that would eventually modify proprioceptive spindle afferents, as these are partly dependent on the intrafusal muscle fiber tensions. A modification of the central programs with BoNT may eventually occur at the spinal and supraspinal levels [6]. Soon, specialists in movement disorders clinics realized that dystonia may behave differently during the course of BoNT treatment. The first reports described the changes of the muscular pattern [42–46] that may have implied a central mechanism of dystonia. Studies that employed the long-latency reflexes and the central SEP components provided support to such central mechanisms in dystonia [21], and this would include TMS [22]. Interestingly, the cortical abnormality in dystonia (either the excitability or intracortical inhibition) changed (i.e., “normalized”) following an efficacious treatment with BoNT. The implication was that a peripheral blockade of effectors may have engaged the central motor programs in dystonia. As we await more data on the probable “direct” retrograde effects of BoNT, the “indirect” effects remain tenable to date, the latter being hinged upon the normalization of abnormal muscle-spindle functioning in dystonia [6]. The consequent and apparent normalization of the cortical disorder following BoNT injections in dystonia may indicate that the manipulation of proprioceptive afferent input has a substantial impact on the disorder directly at the central level [21, 22]. It can be assumed that the abnormalities of Bereitschaft potentials, contingent negative variation, and electroencephalogram desynchronization point (with a high level of probability) to a disorder in the process of motor programming in dystonia and that these occur at the cortical level. What follows is a defective motor performance, as reflected in

abnormalities of reciprocal inhibition, long-latency reflex, cortical excitability, and intracortical inhibition. Taken together, it would seem that an abnormal sensorimotor integration exists in dystonia, and this phenomenon has been alluded to in a number of published works [6, 47, 48]. The sensorimotor integration in the physiological perspective involves all parts of the motor and sensory system, including the motor circuits, in which the basal ganglia and the premotor and motor cortex are the principal components. Recently, it has been hypothesized that sensorimotor integration is, in fact, a function of brain plasticity. Indeed, transcranial stimulation studies have supported the likely occurrence of disordered plasticity in dystonia [49, 50].

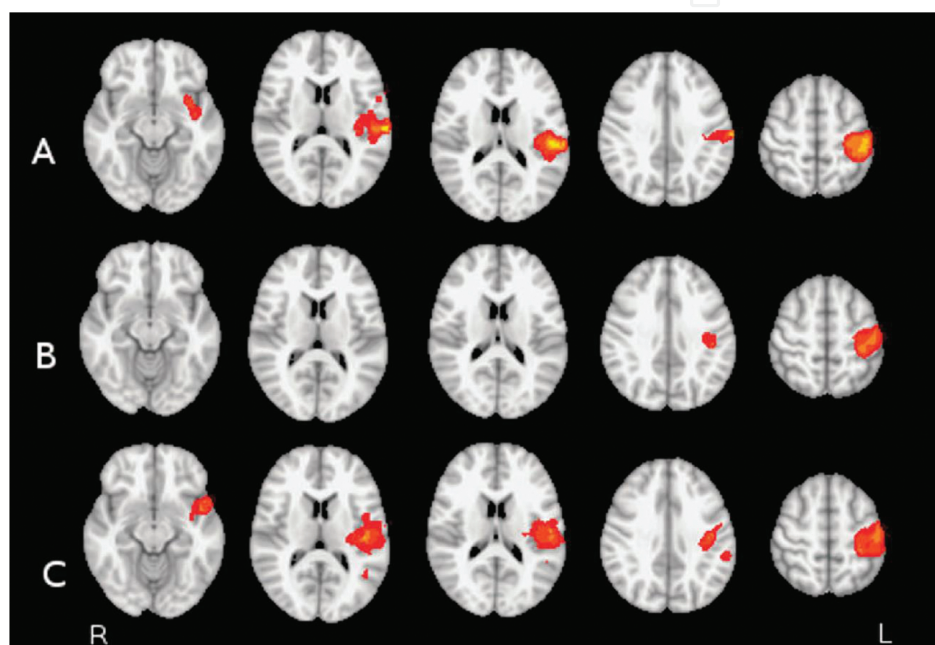


Figure 2. Functional MRI activation during finger movement and simultaneous median nerve stimulation: controls (A), torticollis patients before BoNT treatment (B), and torticollis patients 4 weeks after BoNT treatment (C); group mean statistical maps overlaid in color on MNI anatomical template. Adapted with permission from Opavský et al. [25].

Perhaps to date, the most appropriate tool to investigate brain plasticity would be functional magnetic resonance imaging (fMRI). We have seen the changes that are typical for altered brain plasticity in torticollis patients (when compared with healthy individuals) and their normalization following successful treatment with BoNT. Significant reduction of task-related activation within the ipsilateral supplementary motor area (SMA) and dorsal premotor cortex was observed following successful BoNT treatment. There was also a trend in SMA activation in patients to change lateralization from predominantly ipsilateral to contralateral after BoNT. BoNT treatment was associated with a significant reduction in finger movement-induced fMRI activation (during simultaneous median nerve stimulation) of several brain areas (**Figure 2**), especially in SMA, cingulum, contralateral thalamus, secondary somatosensory cortex, and also in the central part of cerebellum, close to the vermis [25, 26]. These results support previous observations that the BoNT effect has a correlate at the central nervous system level. It is our

belief that further studies will show us that the sensorimotor integration or brain plasticity represents the process of motor preparation itself, even in the expert motor performances.

Acknowledgements

This study was supported by the grants of the Agency for Healthcare Research of Ministry of Health of the Czech Republic (AZV MZ ČR) 15-31921A and 16-30210A. This work was also supported by the Institutional support of the Research Organisation – Ministry of Health, Czech Republic, RVO – FNOL 2016.

Author details

Tomáš Veverka, Martin Nevrlý, Pavel Otruba, Petr Hlušík and Petr Kaňovský*

*Address all correspondence to: petr.kanovsky@fnol.cz

Department of Neurology, Faculty of Medicine and Dentistry, University Hospital, Olomouc, Czech Republic

References

- [1] Wissel J, Ward AB, Erztgaard P, Bensmail D, Hecht MJ, Lejeune TM, et al. European consensus table on the use of botulinum toxin type A in adult spasticity. *J Rehabil Med*. 2009;41(1):13–25.
- [2] Hesse S, Werner C. Poststroke motor dysfunction and spasticity: novel pharmacological and physical treatment strategies. *CNS Drugs*. 2003;17(15):1093–107.
- [3] Ward AB, Aguilar M, De Beyl Z, Gedin S, Kaňovský P, Molteni F, et al. Use of botulinum toxin type A in management of adult spasticity—a European consensus statement. *J Rehab Med*. 2003;35(2):98–9.
- [4] Jankovic J. Treatment of cervical dystonia with botulinum toxin. *Mov Disord*. 2004;19(Suppl 8):S109–115.
- [5] Dressler D, Saberi FA, Barbosa ER. Botulinum toxin: mechanisms of action. *Arq Neuropsiquiatr*. 2005;63(1):180–5.
- [6] Rosales RL, Dressler D. On muscle spindles, dystonia and botulinum toxin. *Eur J Neurol*. 2010;17(Suppl 1):71–80.

- [7] Currà A, Trompetto C, Abbruzzese G, Berardelli A. Central effects of botulinum toxin type A: evidence and supposition. *Mov Disord.* 2004;19(Suppl 8):S60–64.
- [8] Mathers CD, Loncar D. Projections of global mortality and burden of disease from 2002 to 2030. *PLoS Med.* 2006;3(11):e442.
- [9] Sheean G. The pathophysiology of spasticity. *Eur J Neurol.* 2002;9(Suppl 1):3–9; discussion 53–61.
- [10] Colebatch JG, Gandevia SC. The distribution of muscular weakness in upper motor neuron lesions affecting the arm. *Brain.* 1989;112(Pt 3):749–63.
- [11] Jørgensen HS, Nakayama H, Raaschou HO, Vive-Larsen J, Støier M, Olsen TS. Outcome and time course of recovery in stroke. Part I: outcome. The Copenhagen Stroke Study. *Arch Phys Med Rehabil.* 1995;76(5):399–405.
- [12] Ada L, O'Dwyer N, O'Neill E. Relation between spasticity, weakness and contracture of the elbow flexors and upper limb activity after stroke: an observational study. *Disabil Rehabil.* 2006;28(13–14):891–7.
- [13] Kamper DG, Fischer HC, Cruz EG, Rymer WZ. Weakness is the primary contributor to finger impairment in chronic stroke. *Arch Phys Med Rehabil.* 2006;87(9):1262–9.
- [14] Mayer NH, Esquenazi A, Childers MK. Common patterns of clinical motor dysfunction. *Muscle Nerve Suppl.* 1997;6:S21–35.
- [15] Sommerfeld DK, Eek EU-B, Svensson A-K, Holmqvist LW, Von Arbin MH. Spasticity after stroke: its occurrence and association with motor impairments and activity limitations. *Stroke.* 2004;35(1):134–9.
- [16] Zorowitz RD, Gillard PJ, Brainin M. Poststroke spasticity: sequelae and burden on stroke survivors and caregivers. *Neurology.* 2013;80(3 Suppl 2):S45–52.
- [17] Urban PP, Wolf T, Uebele M, Marx JJ, Vogt T, Stoeter P, et al. Occurrence and clinical predictors of spasticity after ischemic stroke. *Stroke.* 2010;41(9):2016–20.
- [18] Sheean G, Lannin NA, Turner-Stokes L, Rawicki B, Snow BJ. Botulinum toxin assessment, intervention and after-care for upper limb hypertonicity in adults: international consensus statement. *Eur J Neurol.* 2010;17(Suppl 2):74–93.
- [19] Sunnerhagen KS, Olver J, Francisco GE. Assessing and treating functional impairment in poststroke spasticity. *Neurology.* 2013;80(3 Suppl 2):S35–44.
- [20] Byrnes ML, Thickbroom GW, Wilson SA, Sacco P, Shipman JM, Stell R, et al. The corticomotor representation of upper limb muscles in writer's cramp and changes following botulinum toxin injection. *Brain.* 1998;121(5):977–88.
- [21] Kaňovský P, Streitová H, Dufek J, Znojil V, Daniel P, Rektor I. Change in lateralization of the P22/N30 cortical component of median nerve somatosensory evoked potentials

in patients with cervical dystonia after successful treatment with botulinum toxin A. *Mov Disord.* 1998;13(1):108–17.

- [22] Gilio F, Currà A, Lorenzano C, Modugno N, Manfredi M, Berardelli A. Effects of botulinum toxin type A on intracortical inhibition in patients with dystonia. *Ann Neurol.* 2000;48(1):20–6.
- [23] Kaňovský P, Bares M, Streitová H, Klajblová H, Daniel P, Rektor I. Abnormalities of cortical excitability and cortical inhibition in cervical dystonia Evidence from somatosensory evoked potentials and paired transcranial magnetic stimulation recordings. *J Neurol.* 2003;250(1):42–50.
- [24] Kaňovský P, Rosales RL. Debunking the pathophysiological puzzle of dystonia--with special reference to botulinum toxin therapy. *Parkinsonism Relat Disord.* 2011;17(Suppl 1):S11–14.
- [25] Opavský R, Hlušík P, Otruba P, Kaňovský P. Sensorimotor network in cervical dystonia and the effect of botulinum toxin treatment: a functional MRI study. *J Neurol Sci.* 2011;306(1–2):71–5.
- [26] Opavský R, Hlušík P, Otruba P, Kaňovský P. Somatosensory cortical activation in cervical dystonia and its modulation with botulinum toxin: an fMRI study. *Int J Neurosci.* 2012;122(1):45–52.
- [27] Johansen-Berg H, Dawes H, Guy C, Smith SM, Wade DT, Matthews PM. Correlation between motor improvements and altered fMRI activity after rehabilitative therapy. *Brain.* 2002;125(Pt 12):2731–42.
- [28] Pundik S, Falchook AD, McCabe J, Litinas K, Daly JJ. Functional Brain Correlates of Upper Limb Spasticity and Its Mitigation following Rehabilitation in Chronic Stroke Survivors. *Stroke Res Treat.* 2014;2014:306325.
- [29] Šenkárová Z, Hlušík P, Otruba P, Herzig R, Kaňovský P. Modulation of cortical activity in patients suffering from upper arm spasticity following stroke and treated with botulinum toxin A: an fMRI study. *J Neuroimaging.* 2010;20(1):9–15.
- [30] Tomášová Z, Hlušík P, Král M, Otruba P, Herzig R, Krobot A, et al. Cortical activation changes in patients suffering from post-stroke arm spasticity and treated with botulinum toxin A. *J Neuroimaging.* 2013;23(3):337–44.
- [31] Manganotti P, Acler M, Formaggio E, Avesani M, Milanese F, Baraldo A, et al. Changes in cerebral activity after decreased upper-limb hypertonus: an EMG-fMRI study. *Magn Reson Imaging.* 2010;28(5):646–52.
- [32] Veverka T, Hlušík P, Tomášová Z, Hok P, Otruba P, Král M, et al. BoNT-A related changes of cortical activity in patients suffering from severe hand paralysis with arm spasticity following ischemic stroke. *J Neurol Sci.* 2012;319(1-2): 89–95.

- [33] Binkofski F, Buccino G. Motor functions of the Broca's region. *Brain Lang.* 2004;89(2):362–9.
- [34] Diserens K, Ruegg D, Kleiser R, Hyde S, Perret N, Vuadens P, et al. Effect of repetitive arm cycling following botulinum toxin injection for poststroke spasticity: evidence from fMRI. *Neurorehabil Neural Repair.* 2010;24(8):753–62.
- [35] Bergfeldt U, Jonsson T, Bergfeldt L, Julin P. Cortical activation changes and improved motor function in stroke patients after focal spasticity therapy – an interventional study applying repeated fMRI. *BMC Neurol.* 2015;15:52.
- [36] Veverka T, Hlušík P, Hok P, Otruba P, Zapletalová J, Tüdös Z, et al. Sensorimotor modulation by botulinum toxin A in post-stroke arm spasticity: Passive hand movement. *J Neurol Sci.* 2016;362:14–20.
- [37] Weiller C, Jüptner M, Fellows S, Rijntjes M, Leonhardt G, Kiebel S, et al. Brain representation of active and passive movements. *Neuroimage.* 1996;4(2):105–10.
- [38] Johnson EA. Clostridial toxins as therapeutic agents: benefits of nature's most toxic proteins. *Annu Rev Microbiol.* 1999;53:551–75.
- [39] Rossetto O, Morbiato L, Caccin P, Rigoni M, Montecucco C. Presynaptic enzymatic neurotoxins. *J Neurochem.* 2006;97(6):1534–45.
- [40] Hallett M, Glocker FX, Deuschl G. Mechanism of action of botulinum toxin. *Ann Neurol.* 1994;36(3):449–50.
- [41] Abbruzzese G, Berardelli A. Neurophysiological effects of botulinum toxin type A. *Neurotox Res.* 2006;9(2–3):109–14.
- [42] Gelb DJ, Yoshimura DM, Olney RK, Lowenstein DH, Aminoff MJ. Change in pattern of muscle activity following botulinum toxin injections for torticollis. *Ann Neurol.* 1991;29(4):370–6.
- [43] Deuschl G, Heinen F, Kleedorfer B, Wagner M, Lücking CH, Poewe W. Clinical and polymyographic investigation of spasmodic torticollis. *J Neurol.* 1992;239(1):9–15.
- [44] Marin C, Martí MJ, Tolosa E, Alvarez R, Montserrat LL, Santamaria J. Modification of muscle activity after BOTOX injections in spasmodic torticollis. *Ann Neurol.* 1992;32(3):411–2.
- [45] Marin C, Martí MJ, Tolosa E, Alvarez R, Montserrat L, Santamaria J. Muscle activity changes in spasmodic torticollis after botulinum toxin treatment. *Eur J Neurol.* 1995;1(3):243–7.
- [46] Kaňovský P, Dufek J, Halačková H, Rektor I. Change in the pattern of cervical dystonia might be the cause of benefit loss during botulinum toxin treatment. *Eur J Neurol.* 1997;4(1):79–84.

- [47] Abbruzzese G, Marchese R, Buccolieri A, Gasparetto B, Trompetto C. Abnormalities of sensorimotor integration in focal dystonia: a transcranial magnetic stimulation study. *Brain*. 2001;124(Pt 3):537–45.
- [48] Frasson E, Priori A, Bertolasi L, Mauguière F, Fiaschi A, Tinazzi M. Somatosensory disinhibition in dystonia. *Mov Disord*. 2001;16(4):674–82.
- [49] Meunier S, Garnero L, Ducorps A, Mazières L, Lehericy S, Du Montcel ST, et al. Human brain mapping in dystonia reveals both endophenotypic traits and adaptive reorganization. *Ann Neurol*. 2001;50(4):521–7.
- [50] Quartarone A, Rizzo V, Bagnato S, Morgante F, Sant'Angelo A, Romano M, et al. Homeostatic-like plasticity of the primary motor hand area is impaired in focal hand dystonia. *Brain*. 2005;128(Pt 8):1943–50.

