

We are IntechOpen, the world's leading publisher of Open Access books Built by scientists, for scientists

6,900

Open access books available

185,000

International authors and editors

200M

Downloads

Our authors are among the

154

Countries delivered to

TOP 1%

most cited scientists

12.2%

Contributors from top 500 universities



WEB OF SCIENCE™

Selection of our books indexed in the Book Citation Index
in Web of Science™ Core Collection (BKCI)

Interested in publishing with us?
Contact book.department@intechopen.com

Numbers displayed above are based on latest data collected.
For more information visit www.intechopen.com



Pediatric Liver Transplantation

Julio Cesar Wiederkehr,
Barbara de Aguiar Wiederkehr and
Henrique de Aguiar Wiederkehr

Additional information is available at the end of the chapter

<http://dx.doi.org/10.5772/63477>

Abstract

Liver transplantation (LT) has become standard management of pediatric liver diseases that lead to acute liver failure or can progress to end-stage liver disease (ESLD). Indications for LT in pediatric patients can be classified into cholestatic disorders, metabolic liver diseases causing liver cirrhosis, metabolic liver diseases without liver cirrhosis, acute liver failure, acute and chronic hepatitis, and liver tumors. The most common indication of PLT is biliary atresia. Generally, the patient is a child with biliary atresia with several prior surgical procedures, extremely malnourished, with stigmata of fat-soluble vitamin deficiency, bleeding diathesis, uncontrolled portal hypertension and massive ascites. Before the technique of liver splitting, pediatric patients were dependent on donors with similar age or size. Partial liver grafts can be obtained either by splitting a cadaveric donor organ or by living-donor liver donation. Living donor liver recipients have a shorter waiting time. The majority of centers employ a regime of triple therapy with prednisolone, mycophenolate and tacrolimus. LT in the pediatric setting is technically challenging due to the reduced size of the vasculature and biliary tree. Strategies for identification and mitigation of risk factors, prevention of technical complications, and protocols for early detection of vascular complications may reduce mortality, morbidity.

Keywords: organ transplant, liver transplant, pediatric liver disease

1. Introduction

The first successful transplant was performed by Starzl in 1967, on a 1-year-old child with hepatoma [13–15]. The patient survived for over 12 months dying from recurrence of the liver tumor. Throughout the next 15 years, liver transplants (LTs) were performed rarely in a very

few centers, with survival rates of only 20–30%. However, the quality of life in pediatric liver transplant (PLT) patients was so good as to support these forerunners to persevere in their efforts and to continue to refine and improve techniques and postoperative care [5].

By March 1980, the liver trials with cyclosporine began in Denver. Twelve patients entered the study between March and September 1980; 11 patients lived for 1 year or longer [2,16]. In 1983, a National Consensus Conference on Liver Transplantation was held in the United States, which became a landmark in the liver transplantation history. This event concluded that liver transplant had advanced from an experimental stage to that of a procedure with a widespread application for patients dying of liver failure. The number of transplants performed both in the United States and elsewhere has grown since then. The number of liver transplant (LT) continues to grow to date as an increasing number of indications for liver replacement are identified [5].

Liver transplantation is the treatment of choice for pediatric liver diseases causing acute liver failure or progressing to end-stage liver disease (ESLD). These include congenital hepatitis, hepatocellular carcinoma, biliary atresia, Wilson's disease (WD), progressive familial intrahepatic cholestasis, and other metabolic syndromes involving injury to the liver [17]. Pediatric acute liver failure (PALF) is a complex, rapidly progressive clinical syndrome that is the final common pathway for many disparate conditions, some known and others yet to be identified. PALF accounts for 10–15% of pediatric liver transplants performed in the United States annually [18–20].

The foremost factor limiting expansion of orthotopic liver transplant (OLT) is donor availability. In small children, scarcity of size-appropriate grafts imposes a significant barrier to PLT. At present, waiting list mortality rate for children less than 6 years of age is four times greater than for children of ages 11–17 years [21]. Living-donor liver transplantation (LDLT) has been developed to address the disparity between the number candidates for transplant and the reduced number of available organs for LT [22].

2. Indications

Various diseases that are indications for LT in pediatric patients can be classified into cholestatic disorders, metabolic liver diseases causing liver cirrhosis, metabolic liver diseases without liver cirrhosis, acute liver failure, acute and chronic hepatitis, and liver tumors. The most common indication of PLT is biliary atresia, approximately 40% of the pediatric candidates [1]. The indications are listed in **Table 1**.

2.1. Biliary atresia

Biliary atresia (BA) is a disease of unknown etiology in which there is obstruction or destruction of the biliary tree [6]. It occurs in approximately 1 of every 15,000 live births [24]. Early diagnosis and palliative surgery—Kasai portoenterostomy are the corner stone for the treatment of BA. In this procedure, the biliary tree is excised to expose biliary channels, and a

Roux-n-Y loop is fashioned for drainage. The procedure is only successful if there is restoration of biliary flow under 6 month of age and is conditional to the age when the operation is performed, the skill of the surgeon, and the degree of fibrosis at operation [25]. BA is the main indication for PLT worldwide and accounts for 76% transplants in children younger than 2 years; 80% of children who have a successful operation do not require transplantation before adolescence [6,23,25].

| Chronic liver failure | Acute liver failure |
|---|-------------------------------|
| Neonatal liver disease | Fulminant hepatitis |
| Biliary atresia | Autoimmune hepatitis |
| Idiopathic neonatal hepatitis | Halothane exposure |
| | Acetaminophen poisoning |
| | Viral hepatitis |
| Cholestatic liver disease | Metabolic liver disease |
| Alagille's syndrome | Fatty acid oxidation defects |
| Familial intrahepatic cholestasis (FIC) | Neonatal hemochromatosis |
| Nonsyndromic biliary hypoplasia | Tyrosinemia type I |
| | Wilson's disease |
| Inherited metabolic liver disease | |
| Alfa1 antitrypsin deficiency | |
| Cystic fibrosis | |
| Glycogen storage disease type IV | |
| Tyrosinemia type I | |
| Wilson's disease | |
| Chronic hepatitis | Inborn errors of metabolism |
| Autoimmune | Crigler-Najjar type I |
| Idiopathic | Familial hypercholesterolemia |
| Postviral (hepatitis B, C, other) | Primary oxalosis |
| | Organic acidemia |
| | Urea cycle defects |
| Other | Liver tumors |
| Cryptogenic cirrhosis | Benign tumors |
| Fibropolycystic liver disease ± Caroli syndrome | Unresectable malignant tumors |

Table 1. Indications for LT in pediatric patients [23].

In several cases, the child needs LT in the first year of life due to the aggressive evolution of the disease leads to cirrhosis accompanied with severe malnutrition. Consequently, technical difficulties related to the limited dimensions of the anatomic structures are faced [26]. Hypoplasia, with or without portal vein thrombosis are relatively frequent in the course of BA. These features are related to a higher incidence of portal vein complications [27]. Previous portoenterostomy procedures cause intra-abdominal adhesions increasing the morbidity due to

intraoperative bleeding and eventual bowel perforation. Previous reports have indicated that BA patients display lower survivals than children undergoing LT for other hepatic diseases [26,28,29].

Infants with suspected BA should be evaluated as rapidly as possible because the success of the surgical intervention (hepatportoenterostomy, the Kasai procedure) diminishes progressively with older age at surgery [30]. The evaluation process involves a series of serologic, laboratory, urine, and imaging tests. The order of diagnostic tests is prioritized based on testing for treatable diseases first, such as biliary obstruction, infections, and some metabolic diseases.

Evaluation of biliary anatomy begins with an ultrasound. The main utility of the ultrasound is to exclude other anatomic causes of cholestasis (i.e., choledochal cyst). In infants with BA, the gallbladder is usually either absent or irregular in shape. When a detailed ultrasonographic protocol is used, additional features can be identified to support the diagnosis of biliary atresia, including abnormal gallbladder size and shape, the “triangular cord” sign, gallbladder contractility, and absence of the common bile duct [31–34]. The triangular cord sign is a triangular echogenic density seen just above the porta hepatis on US scan. Its presence is highly suggestive of biliary atresia [35]. Patency of the extrahepatic biliary tree can be further assessed by hepatobiliary scintigraphy.

The liver biopsy is important for mainly two reasons: to identify histologic changes consistent with obstruction that warrant surgical exploration and to differentiate BA from other causes of intrahepatic cholestasis, which would not need surgical exploration. Biopsy findings that indicate another etiology include bile duct paucity (Alagille syndrome), periodic acid-Schiff (PAS) positive diastase resistant granules (consistent with alpha-one antitrypsin deficiency), or giant cell hepatitis without proliferation of ducts. Characteristic histologic features of BA include expanded portal tracts with bile duct proliferation, portal tract edema, fibrosis and inflammation, and canalicular and bile duct bile plugs. The earliest histological changes associated with BA may be relatively nonspecific, and biopsies done too early may result in a false negative [36].

Histologic findings alone cannot help to distinguish BA from other causes of obstruction, such as choledochal cyst or external compression. Therefore, any evidence of obstruction mandates imaging exploration and a definitive cholangiogram. The intraoperative cholangiogram is the gold standard in the diagnosis of BA. It is essential that patency be investigated both proximally into the liver and distally into the bowel to determine whether BA is present. If the intraoperative cholangiogram demonstrates biliary obstruction (i.e., if the contrast does not fill the biliary tree or reach the intestine), the surgeon should perform a hepatportoenterostomy (Kasai HPE) at that time [37].

An increase in the number of long-term survivors of biliary atresia has been observed. Nevertheless, the disease is still one of the most challenging problems in the field of pediatric surgery because of progressive fibrosis, portal hypertension, and liver cirrhosis [17]. Kasai portoenterostomy (KPE) may play a role in gaining time for liver transplantation [17,38]. Shinkai et al. [39] showed improvement of post-KPE survival rate with almost 90% for 5 years and nearly 80% for 10 years in patients who were operated on in the 1980s. Still, despite early

success with portoenterostomy, a few long-term survivals will present manifestations of portal hypertension, such as esophageal and/or gastric varices, and hypersplenism. Cholangitis and/or hepatic failure caused by progressive ongoing cirrhosis may also occur in patients with long follow-up after KPE. The main cause of comorbidity among long-term survivals of biliary atresia is portal hypertension. Despite the improvement in the long-term survival rate after KPE in biliary atresia, two-thirds of patients who survived over 10 years suffer from various complications including portal hypertension, cholangitis, intrahepatic cyst, and intestinal obstruction in spite of successful KPE. Approximately one-third of these patients will not present any problem. Meticulous follow-up is required since some manifestations of on-going liver cirrhosis will present and therefore planning for liver transplantation is necessary [40].

2.2. Inherited metabolic liver disease

2.2.1. Acute liver failure in inherited metabolic liver disease patients

Metabolic diseases account for at least 10% of acute liver failure cases in North America and Europe [19,41]. While some conditions, such as mitochondrial disease, may present at any age, many metabolic conditions presenting as liver failure segregate within age groups. Metabolic conditions affecting infants in the first few months of life include galactosemia, tyrosinemia, Niemann-Pick type C, mitochondrial hepatopathies, and urea cycle defects [42]. In older infants and young children up to 5 years of age presenting with acute liver failure, metabolic diseases are sometimes identified [18], such as mitochondrial hepatopathies, hereditary fructose intolerance (HFI), argininosuccinate synthetase deficiency (citrullinemia type 1), and ornithine transcarbamylase deficiency. In older children and adolescents, Wilson's disease and mitochondrial disease (fatty acid oxidation defects) may cause acute liver failure [43].

2.2.2. Alpha 1 antitrypsin deficiency

Alpha 1 antitrypsin (AAT) deficiency is the most common form of inherited metabolic liver disease in childhood in Europe. Although 50–70% of children develop persistent liver disease progressing to cirrhosis, only 20–30% require transplantation in childhood or adolescence [44,45].

The presentation of alpha 1 antitrypsin deficiency can include neonatal cholestasis. The frequency of AAT deficiency in infants with neonatal cholestasis ranges from 1 to 10% in different series [46,47]. AAT is an antiprotease and the natural inhibitor of the serine proteases released by activated neutrophils [48]. The “deficiency” state is actually an accumulation of abnormal protein within the endoplasmic reticulum resulting in liver injury in a subset of patients by unclear mechanism [49].

2.2.3. Alagille's syndrome

This autosomal dominant condition has an incidence of 1 case per 100,000 live births. It is a multisystem disorder with cardiac, facial, renal, ocular, and skeletal abnormalities. The condition is caused by mutations in the Jagged 1 gene (JAG1), which encodes a ligand of Notch

1 [50]. The main clinical issues are cholestasis, malnutrition, and cardiac or renal disease [6]. Cholestatic liver disease is of variable severity and may stabilize by school age. It is managed conservatively, with treatment for pruritus and malabsorption as needed. Portoenterostomy (Kasai procedure) is not beneficial and is not recommended [51]. End-stage liver disease develops in approximately 20% of affected children and is amenable to liver transplantation [43,52].

2.2.4. Tyrosinemia type I

Tyrosinemia type I, also known as Hepatorenal tyrosinemia [43], is an autosomal recessive disorder caused by a defect of fumaryl acetoacetase (FAA). There is a lifetime risk of developing hepatocellular carcinoma (HCC) [53]. Clinical features are heterogeneous, even within the same family. Young infants present with cholestasis and coagulopathy, which is often disproportionate to the apparent degree of liver disease. Older infants and children may present with chronic liver disease, with or without cholestasis, and painful crises, mimicking porphyria [44]. Management is with a phenylalanine and tyrosine-restricted diet and nitisone, which prevents the formation of toxic metabolites and allows normal growth and development [55]. The long-term outcome has significantly improved with nitisone therapy and transplantation is now only indicated in those adolescents who do not respond to nitisone, or develop HCC [6,54]. Affected individuals have increased urinary excretion of succinylacetone and markedly elevated blood tyrosine concentration [44].

2.2.5. Cystic fibrosis

Cystic fibrosis (CF) occurs in 1 in every 3000 live births worldwide [55].

The gene defect is an abnormality in the cystic fibrosis transmembrane conductance regulator (CFTR) located on chromosome 7q31. It is a multiorgan disease mainly affecting the lungs and pancreas [6]. The cystic fibrosis transmembrane conductance regulator is located on the apical surface of the biliary epithelium, explaining some of the biliary tract disease seen in patients with cystic fibrosis [56]. Neonatal cholestasis is an uncommon presentation of cystic fibrosis, occurring in fewer than 5% of patients with CF. In affected infants, jaundice and hepatomegaly slowly resolve. Infants with CF are more likely to present with meconium ileus or steatorrhea with failure to thrive [43]. Cystic fibrosis-associated liver disease (CFLD) occurs in 27–35% of patients and usually presents before the age of 18 years [60]. Cirrhosis and portal hypertension occurs in 5–10% of patients during the first decade of life and present with complications in adolescence or early adult life [57]. The indications for LT include malnutrition unresponsive to nutritional support, intractable portal hypertension, and hepatic dysfunction. It is essential that transplantation be carried out before pulmonary disease becomes irreversible [58].

2.2.6. Wilson's disease

Wilson's disease is the most common metabolic condition associated with PALF in children over 5 years of age [18]. It is an autosomal recessive disorder with an incidence of 1 case per 30,000 live births. The defective gene is on chromosome 13 and encodes a copper transporting

P-type adenosinetriphosphatase (ATPase) (ATP7B) [59]. Clinical features in adolescence include hepatic dysfunction (40%) fulminant hepatitis, chronic hepatitis or cirrhosis, and psychiatric symptoms (35%). Neurologic symptoms may be nonspecific, but deteriorating school performance, abnormal behavior, lack of coordination, and dysarthria are common. Renal tubular abnormalities, renal calculi, and hemolytic anemia are associated features [60,61].

The presence of a Coombs-negative hemolytic anemia, marked hyperbilirubinemia, low serum ceruloplasmin, and a normal or subnormal low serum alkaline phosphatase should prompt consideration of WD, but confirming the diagnosis remains a challenge [62]. LT is indicated for those with advanced liver disease (Wilson's score > 6), fulminant liver failure, or progressive hepatic disease despite therapy [60,61].

2.2.7. *Other inborn errors of metabolism*

LT is indicated for those metabolic disorders secondary to hepatic enzyme deficiencies that lead to severe extrahepatic disease such as kernicterus in Crigler-Najjar type I and systemic oxalosis in primary oxaluria. Selection and timing of transplantation depends on the quality of life on medical management and the mortality and morbidity of the primary disease compared with the risks of transplantation [23]. Crigler-Najjar type I is an autosomal recessive condition caused by a deficiency of bilirubin uridine diphosphate glucuronosyltransferase (UDPGT) [63]. Most children require transplantation in early childhood, but those with milder forms may manage with phototherapy into adolescence. Primary hyperoxaluria is a defect of glyoxylate metabolism characterized by the overproduction of oxalate, which is deposited as calcium oxalate in various organs including the kidney [64]. Ideally, liver replacement should be prior to the development of irreversible renal failure. If this is not possible, liver and kidney replacement may be required simultaneously [65]. Children with milder phenotypes will not require intervention until adolescence [6].

2.3. Liver tumors

2.3.1. *Hepatoblastoma*

The most common primary liver tumor in children is hepatoblastoma (HB), accounting for two-thirds of all malignant liver neoplasms in the pediatric population [66]. Neoadjuvant chemotherapy and surgical resection followed by adjuvant chemotherapy is the treatment of choice for patients with HB. When HB shows to be unresectable or unresponsive to chemotherapy, combination of chemotherapy and liver transplantation is an attractive alternative [67]. The United States Surveillance, Epidemiology, and End Results (SEER) from 2002 to 2008 showed an incidence in HB of 10.5 cases/million in children under 1 year of age and 5.2 cases/million in children 1–4 years of age [68]. Histologically, HB cells resemble embryonic liver cells and the incidence is highest at birth suggesting that the process is initiated during gestation [69].

Liver transplantation has resulted in long-term disease-free survival in up to 80% of children with large solitary, and especially multifocal, hepatoblastomas invading all four sectors of the liver [70]. While “extreme” resection of tumors without liver transplant will avoid the need for long-term immunosuppressive therapy, hazardous attempts at partial hepatectomy in children with major venous involvement or with extensive multifocal tumors should be discouraged [71–75]. Only in centers that have a facility for liver transplant extensive hepatic surgery in children should be carried out. In these centers, surgical expertise, as well as willingness to embark on more radical surgery with a transplant “safety net” is likely to be greater [75]. In a review of the United Network for Organ Sharing database in the United States concerning liver transplantation in 135 children transplanted for unresectable or recurrent HB (1987–2004), the 1-, 5-, and 10-year survival was 79, 69, and 66%, respectively [76]. The latest European Liver Transplant Registry (ELTR) report, including 129 patients transplanted for HB, has shown a 1- and 5-year survival of 100 and 74%, respectively [77,78].

The only absolute contraindication for liver transplantation is the persistence of viable extrahepatic tumor deposit after chemotherapy, not amenable to surgical resection. When macroscopic venous invasion occurs (portal vein, hepatic veins, and vena cava), liver resection can be carried on if complete resection of the invaded venous structures is feasible. “En-bloc” and reconstruction should be performed whenever there is evidence or suspicion of invasion of the retrohepatic vena cava. Patients with lung metastases at presentation should not be excluded from liver transplantation if the metastases clear completely after chemotherapy and/or surgical resection. Liver transplant can only be performed after complete eradication of metastatic lesions, by chemotherapy and surgical resection, of any suspicious remnant after chemotherapy [79]. Rescue liver transplantation, after an incomplete partial hepatectomy or when intrahepatic relapse occurs, may be a relative contraindication because of the disappointing results observed in the SIOPEL-I study and in the reported world experience [77].

2.3.2. *Hepatocellular carcinoma*

Unlike the adult population, the frequency of HCC in the pediatric population is low; therefore, the experience in the application of liver transplantation in the pediatric population for HCC is limited [80–83]. Experience with liver transplantation in children with unresectable HCC is somewhat limited but results have significantly improved over the recent years. The Milan criteria—no more than three tumors, each not more than 3 cm in size, or a single tumor, not more than 5 cm in diameter, and no evidence of extrahepatic disease or vascular invasion is commonly used to determine which patients benefit the most with LT [84]. Recently, it has been suggested that the present cut-off for tumor size might be expanded to 6.5 cm or 7 cm, in an otherwise normal liver [89, 90]. Data suggesting that Milan criteria can appropriately identify children with a low-risk tumor recurrence after transplantation is not yet available. The Milan criteria are derivative from experience treating adult patients with cirrhosis, whereas HCC in children usually is not associated with cirrhosis. The role of OLT in noncirrhotic liver is unknown due to lack of prospective trial in children. Furthermore, there are differences in biology of HCC in adults and in children [85]. The different molecular findings include mutation of c-met gene in children; lower levels of glycine D1 (regulatory protein of G1

phase cycle) expression in children; and higher incidence of loss of heterozygosity on chromosomal arm, 13q, in children [85]. In patients whose disease is confined to the liver, the use of liver transplantation is indicated.

2.4. Acute Liver Failure

Viral hepatitis A and B are the most common causes of acute liver failure in the developing world [86,87]. However, in the United Kingdom and United States, indeterminate hepatitis is the most common cause and has the worst prognosis for spontaneous recovery [18]. The main indications for LT for acute liver failure in adolescence are drug induced, infectious hepatitis, or metabolic disease (e.g., Wilson's disease) [18,88]. Many different drugs cause acute liver failure, including antibiotics, antituberculosis therapy, antiepileptic therapy, and acetaminophen poisoning [89]. Adolescents have a lower incidence of liver failure with acetaminophen overdose than adults, possibly because of the effect of hepatic maturation and glutathione production [90]. Transplantation is more likely to be required if the overdose was taken with another drug (e.g., lysergic acid diethylamide [LSD], ecstasy) or with alcohol [91]. Persistent coagulopathy (INR > 4), metabolic acidosis (pH < 7.3), an elevated creatinine (>300 mmol/l), and rapid progression to hepatic coma grade III are indicatives for liver transplant. Cerebral edema may persist despite evidence of hepatic regeneration and recovery and influence postoperative recovery.

Once the diagnosis of liver disease is made, the most important assessment is to determine the severity of the liver disease and its projected outcome. Patients with evidence of end-stage liver disease, including variceal hemorrhage, intractable ascites, hepatorenal syndrome, recurrent infection, and portosystemic encephalopathy, are candidates for immediate listing for transplantation. Selected patients with well-compensated Child's A cirrhosis and isolated variceal bleeding benefit from surgical portosystemic shunting. The success of transplantation in patients with sequel of end-stage liver disease has also heralded an increasing willingness to apply transplantation in patients with life-disabling complications of liver disease consequent to severe metabolic consequences of chronic liver disease [92].

Thus, the indications for PLT are significantly different to indications in adult LT recipients. In the past, PLT was only performed in curative intent. Nowadays, if life expectancy and/or quality of life can be significantly improved, PLT is also performed. Children diagnosed with metabolic liver diseases not resulting in liver cirrhosis, the indication for LT has to be cautiously evaluated. LT should be performed when the disease can either be cured or if extrahepatic manifestations can be significantly improved [1].

3. Contraindications for transplantation

The few contraindications include severe systemic sepsis—particularly fungal sepsis, at the time of operation; malignant hepatic tumors with extrahepatic spread; severe extrahepatic

disease that is not reversible following LT (e.g., severe cardiopulmonary disease for which corrective surgery is not possible), or severe structural brain damage [23].

4. Preoperative management

When transplantation was still perceived as experimental, potential candidates were referred to very late in their course of end-stage liver disease. Generally, the patient was a child with biliary atresia with several prior surgical procedures, who was extremely malnourished, with stigmata of fat-soluble vitamin deficiency, bleeding diathesis, uncontrolled portal hypertension, and massive ascites. One could not imagine a poorer candidate for major surgery. Unfortunately, this is still reality in many centers [2].

Correct preparation before transplantation requires a multidisciplinary approach. The use of new milk formulas specially developed for cholestatic children, parenteral nutrition, may be necessary to correct the nutrition deficit [93]. Gastrointestinal bleeding from esophageal varices should be prevented with sclerotherapy [93], variceal banding [94], and transjugular intrahepatic portosystemic shunt in older children [95]. The remarkable enhancement in the outcomes of liver transplantation, including children, has encouraged an earlier referral, allowing a more elective approach toward liver transplantation [2].

Immunizations should be administered to solid organ transplant candidates as early as possible in the transplant evaluation in order to optimize immune responses and provide immunity to pathogens against which there is only a live vaccine (measles, mumps, rubella, varicella, and zoster). Standard age-appropriate vaccines, as well as vaccines indicated for immunocompromised hosts (e.g., pneumococcal vaccines in adults), should be administered 2–6 months following transplantation, once maintenance immunosuppression levels have been attained. Inactivated vaccines are generally considered to be safe following solid organ transplantation [96].

Live vaccines (measles, mumps, rubella, varicella, zoster, and intranasal influenza vaccine) are not recommended in the majority of solid organ transplant recipients. An exception is varicella-nonimmune pediatric renal or liver transplant recipients who are receiving minimal or no immunosuppression and who have had no recent allograft rejection; such individuals may receive the varicella vaccine [96].

The measles, mumps, and rubella vaccine is considered safe in household contacts of solid organ transplant recipients. We suggest administering the varicella vaccine to nonimmune household contacts. The zoster vaccine should be administered to household contacts when indicated. Vaccinees who develop a rash should avoid contact with transplant recipients for the duration of the rash [1].

In biliary atresia patients, which is the most frequent indication, a sequential strategy with a single attempt at surgical correction, Roux-en-Y portoenterostomy as described by Kasai [97], followed by liver transplantation, when it fails, is consensus by pediatric surgeons [104]. At present, most infants who do not achieve remission following portoenterostomy are referred

to and transplanted under the age of 1 year. Malatack et al. [98] proposed a score to choose the timing of transplantation for children with chronic liver failure. Though such a score can be beneficial, it is suggested that liver transplantation should be performed as soon as an appropriate donor is found, even for children in stable condition, at least when the indication is straightforward at any age of the child.

Due to better understanding of the pathophysiology and/or increased of clinical experience, many contraindications accepted in the past are not presently valid. An example is hepatopulmonary syndrome, which can associate with any type of chronic liver disease. Room air PaO₂ level lower than 60 mmHg has been described to be associated with prohibitive mortality after liver transplant [99]. Differently, regardless of the severity of the syndrome, others have shown complete reversion of hepatopulmonary syndrome after LT [107].

4.1. Psychological preparation

A skilled multidisciplinary team, including a psychologist, is essential for counseling and preparation of the patient and his/hers family. Young people need to be involved in the decision making wherever possible, and previous experience of illness, knowledge about their condition and treatment, previous/current adherence to prescribed medical regimens, and self-management behaviors need to be explored. Parents and appropriate relatives must be fully informed of the necessity for LT in their child and of the risks, complications, and the long-term implications of the operation. Particularly, careful counseling is necessary for parents and children being considered for transplantation because of extrahepatic disease due to an inborn error of metabolism. As these young people are not dying from liver disease, they may find it difficult to accept the risks and complications and the necessity for compliance with long-term immunosuppression [6].

4.2. Psychosocial evaluation of live organ donors

Adequate psychosocial evaluation includes assessment of the motivation for donating, decision making and informed consent process, donor-recipient relationship, adequacy of both financial and social support, behavioral and psychological health, and substance use history. A complete assessment of a potential living donor should also address obstacles such as impression management and explicit deception. It should also include ethical aspects, such as the right to donate, donor autonomy, freedom from coercion, and “reasonable” risks to donors. The Transplantation Society Ethics Committee emphasizes that is essential when considering living organ donation, that the well-being of donors, including survival, quality of life, and psychological and social well-being, outweighs the risks to the donor-recipient pair, which include death and medical, psychological, and social morbidities [100]. Like to the psychosocial evaluation of the recipient, the attention should be on the interaction of risk versus protective factors for each donor [109]. Although recent research identifies the needs for standard criteria [101], live organ donor evaluations should be viewed within both individual and contextual frameworks [22].

5. Surgical techniques

Liver transplantation has gained from the knowledge of anesthesiologists handling babies with serious conditions. The pediatric anesthesiologist is an essential member of the team. As in any long operation, exact correction of blood loss, continual monitoring of electrolytes and blood gases, correct identification and treatment of bleeding diathesis, and maintenance of body temperature and diuresis are fundamental. Alongside a correct comprehension of all the surgical techniques, good tactics and technical expertise, proper attention by the surgeon to hemostasis is essential. Although limitation of graft ischemia time is important, the patient will be better off at the end of surgery if the operative field is dry and the small bowel has been preserved from damage during the tedious dissection of tight adhesions, rather than been rushed through surgery by a hurried surgeon [2].

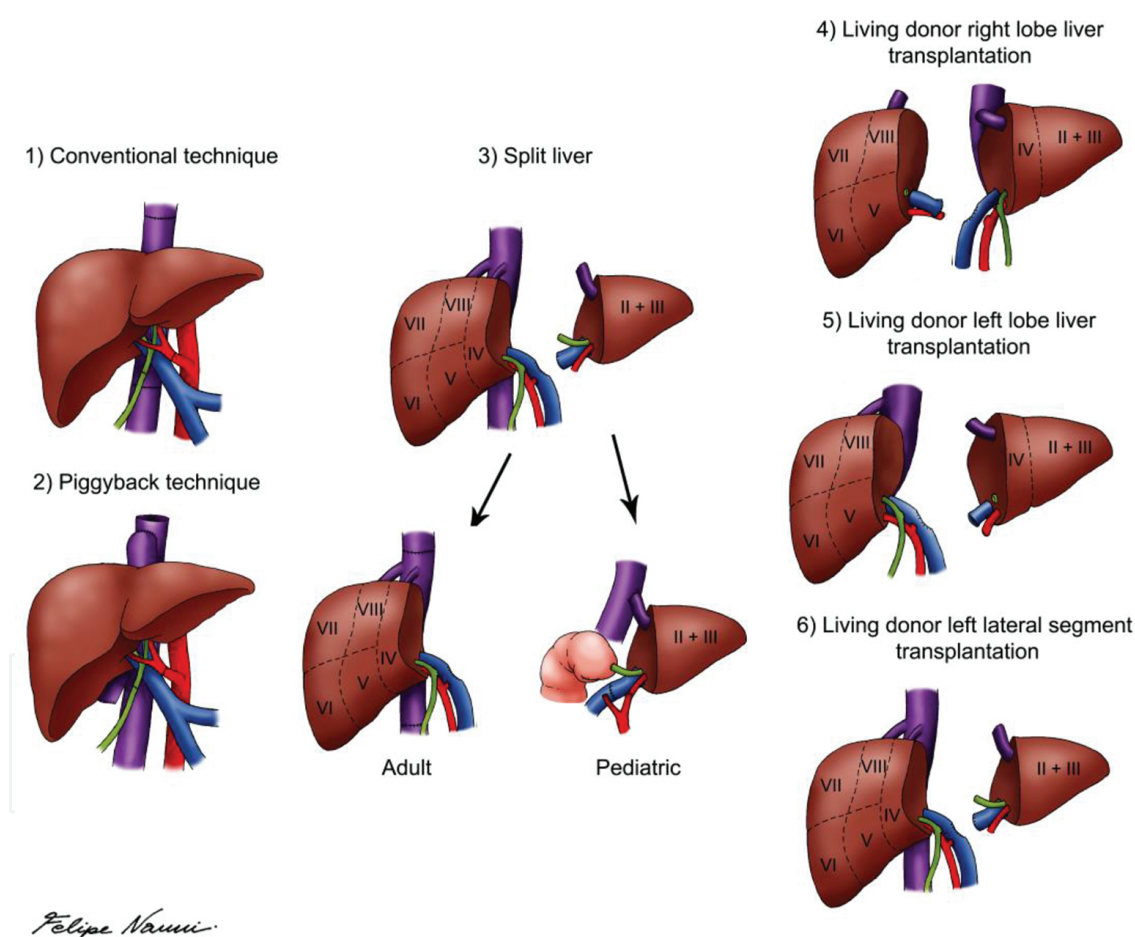


Figure 1. Examples of surgical techniques for orthotopic liver transplantation.

Prior the development of the technique of liver splitting, PLT was dependent on donors with similar age or size. In the early 1980s, Christoph Broelsch and Henri Bismuth were the first applying the technique of reduced-size LT in children [102,103]. Rudolf Pichlmayr performed the first split LT offering one cadaveric liver to two recipients in 1988 [104]. However, pediatric

deceased donors as well as organs suitable for split LT remain rare. The numbers of PLTs performed significantly exceed the number of available pediatric organ donors [1,105].

LT in children is comparable to adult LT (piggy back or conventional technique) when full size grafts are transplanted. Partial liver grafts can be obtained either by splitting a cadaveric donor organ or by living-donor liver donation. When liver-splitting technique is used, the anatomical determination of the eight liver segments first described by Couinaud [106,107] in 1957 is essential. **Figure 1** depicts the surgical options for OLT.

The splitting procedure can be performed as anatomical splitting, dividing the liver at Cantlie's line, and splitting along the falciform ligament [117]. When the left lateral segment divided, the technique is much easier to perform than the true right/left lobe split procedure. Additionally, the left lateral segment is preferentially used in PLT. It is the smallest part of the liver when compared to the extended right, the anatomical left, or the right liver lobe.

In small infants, even the left lateral segment of the liver often is too large and techniques to cut down left lateral lobes may be used to prevent graft-size mismatching and the so-called "large-for-size" syndrome [108]. Not rarely, primary closure of the abdominal wall after PLT is not feasible and should not be enforced in order to avoid increase in intra-abdominal pressure. Excessive increase in intra-abdominal pressure may compromise graft perfusion. In such occasions, abdominal wall closure is performed in stages during the first week post-transplant or accomplished by using mesh grafts. This allows for a continuous recovery of the graft from reperfusion injury and edema [109].

5.1. Auxiliary transplantation

Auxiliary partial orthotopic LT (APOLT) is an alternative technique for LT in patients with acute liver failure or in children with metabolic liver diseases without primary hepatocellular dysfunction or cirrhosis. In this technique, a partial graft is implanted without entirely removing the native liver. Gubernatis et al. reported the first successful case in a patient with acute liver failure. After her recovery, the native liver has regenerated and immunosuppressive treatment could be withdrawn [110,111].

In patients with metabolic diseases, APOLT may provide sufficient liver mass to correct the hepatic metabolic function. If the graft fails, the patient's native liver is still present to secure general liver function [112]. When APOLT is performed in acute fulminant liver failure, the immunosuppressive therapy can be stopped if the native liver recuperates, resulting in an atrophy of the transplanted liver [113].

5.2. Living-donor liver donation

After successful implementation of split-liver LT in PLT, this technique leads to the first living-donor liver transplant (LDLT). In 1989, the first series of LDLT in pediatric recipients was performed in Chicago [114], after the pioneer work of Raia et al. [115] in Brazil. As of today, LDLT is an established procedure and the main form of LT due to scarcity of deceased donor organs in most East-Asian countries [116]. In western countries and especially in the UNOS

area, use of living-donor organs for LT is less frequent and within UNOS constantly <5% of LT over the last years [117]. Within the European Transplant Network, rates of LDLT in PLT are steadily increasing.

Retrospective analyses have shown favorable or equal results as compared to PLT after deceased donor liver transplant (DDLT) [118–126]. When performing LDLT the scenery include an optimal healthy donor, minimal ischemic time, elective surgery, and timing of transplantation according to the recipients' need. This is particularly pertinent for pediatric patients. During a waiting time for PLT, the underlying disease can complicate and psychosocial long-term morbidity may develop pediatric patient. It has been shown that long-term outcome after PLT significantly correlates with the severity of morbidity at PLT. In a early publication, significant independent predictors of survival after OLT in children with end-stage liver disease were bilirubin ($p=0.0024$), lower weight ($p=0.034$), and albumin ($p=0.039$). Post-transplantation survival rates was statistically significant difference at 1 year (57% vs. 90.5%) and 4 years (49% vs. 90.5%) after OLT($p=0.0001$), when one or more of these risk factors - bilirubin $>340 \mu\text{mol/L}$, lower weight <-2.2 and albumin $< 33 \text{ g/L}$, were presente [127]. LDLT offers the possibility and advantage of optimal timing of the transplant procedure before severe morbidity develops.

Living-donor livers recipients have a shorter waiting time when compared to recipients of organs from deceased donors. This reflects in a reduction of waiting list mortality. Nevertheless, live donors are not deprived of risk. Also to considerer is the fact that LDLT is surgically more challenging than whole organ transplantation. Donor major complications, exceeding Clavien's classification grade II, were described in up to 44% after right-lobe LDLT with a mortality risk up to 0.8% [128–130]. Donors of right liver lobe experience operating procedures with longer duration, have significant longer hospital stay and require more blood transfusions [131,132]. For PLT, in most cases, the left lateral segment donation is sufficient. The complication rates after full left lobe or left lateral lobectomy are significantly lower than right lobe donation [133–135]. In order to decrease morbidity and mortality after liver donation, a thorough evaluation of the potential donor is essential to detect and exclude potential increased medical risk factors for the otherwise healthy donor.

5.3. Living related donor liver transplantation in children

5.3.1. Surgical technique

The donor procedure is performed first, except when recipient's diagnosis is malignant liver tumor. The recipient surgery usually starts immediately after the quality of the graft is assured to minimize the cold ischemia time. Left lateral hepatectomy is performed without clamping of the portal triad. The vessels were divided after completion of the parenchymal transection. The whole hilum is dissected and the left hepatic artery is identified. Subsequently, dissection is confined to the left branch of the portal vein and to the left hepatic artery. Minimal dissection was performed around the left hepatic duct to avoid damaging its blood supply. At bench surgery, the graft is perfused with preservation solution.

The liver implantation technique consists of the anastomosis of the left hepatic vein to the native inferior vena cava. This anastomosis can be performed by direct suturing of the donor hepatic veins to the recipient hepatic veins; by a triangular anastomosis after creating a wide triangular orifice in the recipient inferior vena cava at the confluence of all of the hepatic veins; or a wide longitudinal anastomosis in the anterior wall of the inferior vena cava. Subsequently, the portal vein is anastomosed to the trunk of the recipient's portal vein in an end-to-end technique [136].

The liver graft is reperfused after conclusion of the portal vein anastomosis. For the reconstruction of the artery, microsurgical techniques are necessary. The graft hepatic artery is anastomosed to one of the stumps of the main branches or to the trunk of the proper hepatic artery of the recipient in end-to-end fashion using 9-0 or 10-0 prolene sutures. The arterial anastomosis should be performed using microsurgery techniques under surgical microscope (magnification, 8×) or surgical loupes (magnification, 6×), depending on the size of the arteries. Biliary reconstruction is achieved by a Roux-en-Y hepaticojejunostomy. Occasionally, an end-to-end duct anastomosis can be performed [136].

6. Post-transplant care

Immediately after the transplant, the patient is usually ventilated in intensive care for 24-48 h. Graft function is assessed with coagulation studies, blood sugar and acid-base balance, and liver function tests. Initially in the post-operative period, high transaminase levels are usually observed that progressively fall during the first few postoperative days. A rapid reduction of jaundice is an indication of a well-functioning graft.

When abnormal liver function tests are detected, a specific protocol of investigations to determine the cause is necessary. In patients with a t-tube, a cholangiogram will demonstrate patency of the biliary tree. In patients without a t-tube, an ultrasound of the liver can exclude biliary obstruction and demonstrate patency of the portal vein and hepatic artery. In the suspicion of a thrombotic event, angiography should be performed to confirm it. The gold standard for diagnosing a rejection episode is needle biopsy. Liver biopsy should be carried out subsequently. Other diagnoses such as preservation injury or viral hepatitis in the graft can also be diagnosed. For confirmation of viral infections, specific antibody tests usually are necessary [5].

7. Immunossupression

As in adult LT, the introduction of calcineurin inhibitors (CNI) in the early 1980s gave way to long-term survival also for pediatric transplant recipients and until today remains the backbone of immunosuppression practices [1,3,137]. The most popular immunosuppression drugs combination comprises low doses of prednisolone, mycophenolate, and tacrolimus. Despite the high effectiveness of these medications in controlling the immune response, rejection

is a reality in the majority of liver transplant recipients which can be controlled with the intensification of the steroid dose. Higher doses of immunosuppression are usually associated with a lower incidence of rejection. On the other hand, at the same time, a higher infection rate with considerable morbidity and even mortality appears. Moreover, each of the agents has specific toxic effects [5]. Observations made by several groups indicate that after liver transplantation in children require more immunosuppression than adults, with a higher incidence of steroid sensitive and steroid-resistant acute rejection episodes [137].

The period of highest risk for immunologic reactions between graft and host usually is in the early post-transplant phase. Consequently, higher dose of immunosuppression is required during this period. Most protocols include induction therapy, usually interleukin-2 receptor antibodies especially in the pediatric transplant population (Basiliximab® and Daclizumab®), in association with corticosteroids and calcineurin inhibitors (cyclosporine A and tacrolimus) as maintenance therapy [138–143]. In the pediatric transplantation community, the use of other mono- or polyclonal antibodies—monoclonal anti-CD3 antibody preparations (OKT3) and rabbit or equine antithymocyte globulin, for induction therapy has not been adopted. These potent agents can cause undesired short—and uncertain long-term effects on the developing organism and immune system [144]. Several reports showed that the lower doses of immunosuppression can be used based on the individual needs, particularly in pediatric cases which can, *in long-term*, improve the quality of life of these patients minimizing undesired side effects [145–148].

Common side effects of immunosuppressants include diabetes, deficiency of growth, hypertension, nephrotoxicity, hyperlipidemia, neurologic alterations, hypertrichosis, and bone marrow suppression. Ideal levels of immunosuppression are hard to obtain due to great differences between individuals as well as within the same individual over time. Multiple combination protocols, such as mycophenolate-mofetil and mammalian target of rapamycin inhibitors (sirolimus and everolimus), with and without CNIs have been introduced for maintenance therapy also in pediatric solid organ transplant based on increasing data to safety aspects in the use of different immunosuppressant drugs in the adult population [149–156].

It is well established that long-term immunosuppression increases the risk of infectious and malignant complications. Other side effects, such as nephrotoxicity, disturbances of the lipid profile, arterial hypertension, and cardiovascular disease, are also of concern. These side effects can jeopardize both quality of life and life expectancy. Especially in pediatric liver recipients whose survival can be expected to be more than a few decades; consequently prevention of these side effects is a major objective. The reduction of the global immunosuppression in the first months after the procedure, concerning the total amount of steroids and the target blood levels of calcineurin inhibitors, is the main goal. The use of tacrolimus has allowed complete withdrawal of steroids within the first posttransplant year in most patients, which has been proved to be beneficial. New protocols, specifically designed for children to test new immunosuppressive compounds as well as tolerance inducing strategies, have been more easily introduced [2].

Although immunosuppression drugs is still recommended after liver transplantation, several studies have shown that particularly patients who are transplanted in the early years or receive

a parental living liver donation could develop an evident degree of immune tolerance concerning the graft. Single center experiences demonstrate that patients who were withdrawn from immunosuppression because of medical reasons (such as renal insufficiency) or due to noncompliance suggest that around 20% of liver transplant patients develop operationally tolerance regarding the graft [157–162]. Another more aggressive approach to induce immune tolerance in solid organ transplantation is to combine solid organ transplantation with hematopoietic stem cell transplantation from the same donor [1,163–165].

Complete freedom from immunosuppression or significant withdrawal of immunosuppression is possible in long-surviving recipients of liver allografts [159,166,167]. The drug weaning protocol established for pediatric liver transplant patients at the University of Pittsburgh includes long-term survivors who are medically compliant and have normal liver function without recent acute rejection episodes within the past 2 years. Drug withdrawal was begun at a mean time of 6 years after liver transplantation. The baseline immunosuppressant of tacrolimus or cyclosporine was weaned at 2-month to 3-month intervals as long as hepatocellular enzyme tests remained stable. Liver injury tests of aspartate aminotransferase (AST), alanine aminotransferase (ALT), gamma glutamyltransferase (GGTP), and bilirubin are monitored weekly after changes in drug dosage. Tacrolimus or cyclosporine levels are not used in monitoring because baseline levels in this patient population are frequently low or undetectable. Liver biopsy is done for sustained alterations in liver tests. Forty percent (17 of 43) of the patients were off immunosuppression, with a mean time from weaning of 1.7 years. No patient or graft loss has occurred. Rejection has occurred in 14% of patients (6 of 43), being mild in two patients and mild to moderate in four patients, prompting switch to tacrolimus from cyclosporine-based immunosuppression. Pediatric patients have the greatest potential benefit from the significant dosage reductions or complete drug withdrawal that can be potentially realized [2].

However, it is not without risk and it must be done with great care because no marker is available to identify the patients who have developed graft acceptance operational tolerance [168]. Three main objectives should be pursued in PLT regarding immunosuppression: (1) reduction and individualization of immunosuppression in order to diminish long-term side effects; (2) maintenance of long-term allograft function; and (3) monitor and induce tolerance through the development of specific protocols, as well as identify operationally tolerant and nontolerant patients [1].

8. Adherence

Nonadherence to the medical regimen is part of the risk-taking spectrum of behavior [77], and approximately 33–50% of adolescents with a chronic illness are nonadherent in some way with their treatment protocol [169]. There is a clear association between medication nonadherence and unfavorable transplant outcome.

Several studies investigate the role of different factors predisposing to medication nonadherence [170]. In a recent study, 75% of post-LT adolescents were nonadherent and reported

poorer health perceptions, lower self-esteem, more limitations in social and school activities, and poorer mental health than those who were adherent [171]. Factors such as history of substance abuse, previous psychiatric problems, older age, female gender, and living in a one-parent household have been associated with poorer adherence [172,173].

Nonadherence to medication is associated with increased medical complications and higher rates of rejection and graft loss [174–176]. In addition, other aspects of nonadherence include clinic nonattendance, missing routine blood tests, and inconsistent timing of medications. The desire to be like their friends can result in nonadherence to different aspects of the treatment regimen. The monitoring and management of nonadherence can be challenging, necessitating a nonjudgmental approach, with a focus on individual adherence plans, improved education, behavioral strategies to encourage self-management and self-motivation and a recognition of the role of treatment burden for patients, and their families [6,177].

9. Complication

The main causes of graft loss in the first week include primary nonfunction (PNF), hepatic artery or portal vein thrombosis, systemic sepsis, and multiorgan failure (<10%). Other significant early complications are acute (50%) or chronic rejection (10%), biliary leaks/strictures (5–25%), viral infections (especially cytomegalovirus (CMV) and Epstein Barr virus), and acute kidney injury and fluid imbalance [7–12]. The most frequent complications are listed in Table 2.

| Complications after liver transplant |
|--------------------------------------|
| Hemorrhage |
| Primary nonfunction |
| Hepatic artery thrombosis |
| Acute rejection |
| Chronic rejection |
| Biliary leak/stenosis |
| Infection |
| Bacterial |
| Opportunistic |
| Viral (e.g., CMV) |
| Fungal |
| Pneumocystis |
| Acute renal failure |
| Fluid imbalance |

Table 2. Complications after liver transplant.

Intraoperative bleeding in PLT is commonly less of a problem than in adults, even though the majority of the children will have had previous surgery on the liver. This can be explained by

the fact that portal hypertension as measured by portal vein pressure is less severe in the child than in the adult, possibly consequence of more effective collateral vessel formation [5].

Thrombosis of the hepatic artery is a major concern in PLT with rates varying from 10 to 25%. This ischemia, when occurring in the early posttransplant period, produces either acute graft failure or biliary tree infarction with bile leakage and intra- or extrahepatic abscess formation [5]. Early hepatic artery thrombosis (HAT) is the most common form of vascular complication and is the main cause of graft loss in pediatric living-related liver transplantation (LRLT) [178]. Early diagnosis and treatment can prevent biliary tract and parenchymal damage [179]. Bekker et al reported an incidence for early HAT in pediatric LT of 8.3% compared to 2.9% in adults. [180]. Hepatic artery stenosis and thrombosis can result in allograft ischemia, which is associated with high mortality and morbidity rate. Arterial complications are frequently diagnosed first by Doppler ultrasound followed by CT angiogram or angiography. Doppler ultrasound showed a sensitivity of 100%, a specificity of 99.5%, a PPV of 95% and NPV of 100%, and overall accuracy of 99.5% in early diagnosis of HAS [179]. According to the interval between LT and development of thrombosis, HAT can be divided into early (within 4 weeks) and late. Usually, early HAT may be the result of technical problems and can have dramatic presentation [181]. Due to the fact that early HAT has a higher mortality comparing to late HAT, intervention is required as urgent procedure [182]. Late HAT is usually due to ischemic or immunologic injuries. Patients with late symptomatic HAT can be initially treated with biliary stent placement and/or endovascular interventions [181].

Positive CMV antibody in donor and negative CMV recipients has been shown to be associated with late HAT [183–186]. Some authors also suggest that perioperative hypercoagulable state as the possible underlying cause for hepatic artery thrombosis [180–187]. Although urgent retransplantation is considered the main therapy for early HAT, endovascular interventions, including PTA, intra-arterial thrombolysis (IAT), and stent placement, may be alternative treatments.

Venous complications after PLT include caval/hepatic vein and portal problems. Clinical manifestations of portal vein stenosis (PVS) include ascites, anemia, splenomegaly, and gastrointestinal bleeding [188–191]. Platelet counts may be below normal limit in pediatric patients with PVS due to hypersplenism [192]. The incidence of portal vein complications is usually higher in pediatric recipients than in adults. Smaller portal vein diameter, size disparity between donor's and recipient's portal vein, and short pedicle of the donor's portal vein are risk factors for portal vein complications [193–196].

Clinically hepatic vein obstruction (HVO) is analogous to Budd-Chiari syndrome [197]. HVO is a general term reflecting any obstruction of the hepatic veins caused by either compression and twisting of the anastomosis. It can be caused by graft regeneration or by intimal hyperplasia and fibrosis at the anastomotic sites [198]. Risk factors related to portal vein complications include technical problems, young age, body weight <6 kg, the recipient's portal vein size <5 mm, graft rotation, previous splenectomy, simultaneous thrombectomy for pre-existing PVT, and use of venous conduits for portal vein reconstruction [9,193,199–204]. Cold ischemia time longer than 12 h can also be a impose risk for developing venous problems. Portal vein stenosis is mostly associated with cryopreserved vein for portal conduits. Portal vein hypo-

plasia is one of the main risk factors for developing vascular complications in pediatric recipients of LT, particularly when biliary atresia is the indication for LT [205,206]. Suzuki et al. [207] reported a portal vein diameter of <3.5 mm to be the single most sensitive and specific predictor of portal vein stenosis.

Endovascular interventions are less invasive treatment for post-LT vascular complications particularly in pediatric patients. In cases of post-LT HVO, percutaneous endovascular treatment with balloon dilation and/or stent placement can be used as a safe treatment with high success rate. Complications, such as ascites, renal failure, lower limb edema, and splenomegaly, can be resolved after endovascular interventions [208]. Simultaneous obstruction of HV and IVC can also be treated with endovascular interventions. However, isolated HV stenosis is better treated with balloon-expandable stent treatment than with balloon dilation [209].

Although balloon dilation is an effective and relatively safe procedure for treatment of portal vein stenosis, 28–50% of these patients may develop recurrent PVS [210–213]. Previous reports suggest stent placement and repeated balloon dilation as solutions for this problem [212,213]. Sanada et al. [202] showed combined anticoagulant therapy using LMW heparin, warfarin, and aspirin can significantly lower the risk of recurrent PVS [214].

9.1. Biliary complications

The presentation of biliary complications is quite variable. The diagnosis biliary leakages (BL) usually are straightforward and presents early in the posttransplant period. Biliary stenosis (BS) has a more indolent progression and usually is diagnosed later. BS demands a high index of suspicion because in the initial phases the clinical picture can be confused with rejection, infection and primary disease recurrence [215].

Early complications, occurring within 30 days of the transplant, usually are consequence of technical problems. These include handling and harvesting of the graft, preservation injuries, surgical technique of biliary reconstruction, or even vascular insufficiency [216]. Late complications, occurring after 90 days posttransplant, are classified into anastomotic (AS) and nonanastomotic strictures (NAS). NAS are associated to the use of ABO-incompatible grafts, preservation injury, opportunistic infections, recurrent hepatitis, ductopenic rejection, recurrent primary sclerosing cholangitis (PSC), stones or casts, posttransplant lymphoproliferative disorder or other tumors [216].

Long cold ischemia time, hepatic artery thrombosis (HAT), CMV infection, and chronic rejection constitute risk factors for biliary anastomotic complications (leaks and strictures). Also, tissue hypoxia at level of the anastomosis, secondary to hepatopulmonary syndrome, can increase the frequency of biliary complications after liver transplantation [217]. Multiple bile ducts, requiring reconstruction or more than one biliary anastomosis is an independent risk factor for the development of biliary complications with a higher incidence of biliary complications when compared with a single duct (21% versus 9%, respectively) [218].

Treatment strategies are based on the type and severity of the complication and the biliary reconstruction technique applied, duct-to-duct anastomosis or hepaticojejunostomy. Nonoperative management is the first-line approach, and success can be achieved in 70–90% of all BS cases [219–222]. A novel magnetic compression anastomosis has been recently described. Transmural compression with two magnets causes gradual ischemic necrosis, thus creating a new anastomosis between the dilated duct and small intestine or bile duct. This technique has been applied in only few cases, and further experience is necessary before it has broader indications [215,223,224].

The majority of patients will experience at least one episode of acute rejection. However, usually it is treated increasing the steroid. Small bile ducts destruction shown on biopsy is typical finding of chronic rejection. This type of rejection is not reversible by increasing immunosuppression. Repeated biopsy with histological confirmation is necessary to establish this diagnosis. When chronic rejection occurs, the only treatment is retransplantation [5].

Immunosuppressed patients have a higher risk for infection complications. Common bacterial infections, usually in the respiratory and biliary tracts, opportunistic infections are a potential problem. The commonest of these are cytomegalovirus and fungal infections. Donor and recipient CMV status matching of both graft and blood products can minimize CMV infections [5].

When CMV-negative patient receives a CMV-positive graft, prophylactic treatment with acyclovir has been shown to be effective in minimizing the severity of any resulting CMV infection. Fungal infections are not rare after liver transplant, since the majority of children with chronic liver disease are heavily colonized with candida. Limited use of broad-spectrum antibiotics and oral antibiotic prophylaxis may reduce the incidence and severity of fungal sepsis. Pneumocystis infection is an additional risk in these patients. Any of these infections is associated with a high mortality. Prophylaxis with oral cotrimoxazole is nearly always effective for these risks [5].

Another rare complication of LDLT in pediatrics is the graft rotation. Previous studies showed that the graft rotation can lead to venous outflow obstruction and suggested stabilization of the graft to avoid this complication [225,226]. Several surgical factors might have an important role in preventing vascular thrombosis, especially in the transplantation of live donor or split liver allografts. Adequate inflow in the donor vessels is also important to reduce vascular complications. The use of interposition grafts (arteries or veins) is stimulate in the case of small-caliber vessels or a fibrotic and small portal vein, common observed in children with biliary atresia [224].

Oversized grafts are prone to compression after abdominal wall closure, which may compromise the flow in the afferent hepatic vessels increasing the risk for thrombosis. Delayed abdominal wall closure is recommended in these situations, avoiding tight wound closure, and consequently avoiding augmented intra-abdominal pressure. Administration of antiplatelet agents early in posttransplant, such as aspirin, has been advocated to prevent HAT [227, 228].

10. Conclusion

In conclusion, LT in the pediatric setting is technically challenging due to the reduced size of the vasculature and biliary tree. Discrepancies in portal vein and hepatic arterial diameter between the donor and recipient are expected. Despite technical evolution of pediatric liver transplantation, vascular complications are still a significant cause of allograft loss, reflecting in increase of postoperative morbidity and mortality. Arterial complications are more common, occur early in the postoperative period, and are associated with high rates of graft loss and patient mortality. On the other hand, venous complications are less frequent usually occurring in the late postoperative period with no significant effect on graft loss or mortality rates. Important strategies for reduction of mortality, morbidity, and the need for retransplantation include detection and mitigation of risk factors, avoidance of technical complications, and protocols for prompt detection of vascular complications.

Author details

Julio Cesar Wiederkehr^{1,2*}, Barbara de Aguiar Wiederkehr^{2,3} and Henrique de Aguiar Wiederkehr^{3,4}

*Address all correspondence to: julio.wieder@gmail.com

1 Professor of Surgery, Federal University of Parana, Chief, Division of Liver Transplantation Hospital Pequeno Principe, Curitiba, Brazil

2 Resident in Gastrointestinal Surgery, Evangelic University Hospital of Curitiba, Curitiba, Brazil

3 Resident in Gastrointestinal Surgery, Evangelic University Hospital of Curitiba, Curitiba, Brazil

4 Resident in General Surgery Evangelic University Hospital of Curitiba, Curitiba, Brazil

References

- [1] Hackl C. Current developments in pediatric liver transplantation. *World J Hepatol.* 2015;7(11):1509.
- [2] Otte JB. History of pediatric liver transplantation. Where are we coming from? Where do we stand? *Pediatric Transplant.* 2002;6(5):378–387. <http://doi.org/10.1034/j.1399-3046.2002.01082.x>.

- [3] Starzl TE, Iwatsuki S, Klintmalm G, Schröter GP, Weil R, Koep LJ, Porter KA. Liver transplantation, 1980, with particular reference to cyclosporin-A. *Transplant Proc.* 1981;13:281–285 [PMID: 7022839].
- [4] Starzl TE, Todo S, Tzakis AG, Gordon RD, Makowka L, Stieber A, Podesta L, Yanaga K, Concepcion W, Iwatsuki S. Liver transplantation: an unfinished product. *Transplant Proc.* 1989;21:2197–2200 [PMID: 2469232].
- [5] Buckels JA. Paediatric liver transplantation: review of current experience. *J Inherited Metab Dis.* 1991;14(4):596–603.
- [6] Kelly D. The adolescent liver transplant patient pediatric liver transplantation. *Adolescent Adherence. Clin Liver Dis* 2014;18:613–632.
- [7] Duffy JP, Kao K, Ko CY, et al. Long-term patient outcome and quality of life after liver transplantation: analysis of 20-year survivors. *Ann Surg.* 2010;252(4):652–661.
- [8] Kamath BM, Olthoff KM. Liver transplantation in children: update 2010. *Pediatr Clin North Am.* 2010;57(2):401–414.
- [9] Duffy JP, Hong JC, Farmer DG, et al. Vascular complications of orthotopic liver transplantation: experience in more than 4,200 patients. *J Am Coll Surg.* 2009;208(5):896–903 [discussion: 903–905].
- [10] Anderson CD, Turmelle YP, Darcy M, et al. Biliary strictures in pediatric liver transplant recipients – early diagnosis and treatment results in excellent graft outcomes. *Pediatr Transplant.* 2010;14(3):358–363.
- [11] Martin SR, Atkison P, Anand R, et al. Studies of pediatric liver transplantation 2002: patient and graft survival and rejection in pediatric recipients of a first liver transplant in the United States and Canada. *Pediatr Transplant* 2004;8(3):273–283.
- [12] Heffron TG, Pillen T, Smallwood G, et al. Incidence, impact, and treatment of portal and hepatic venous complications following pediatric liver transplantation: a single-center 12-year experience. *Pediatr Transplant.* 2010;14(6):722–729.
- [13] Reyes J, Mazariegos GV. Pediatric transplantation. *Surg Clin N Am.* 1999;79(1):163–189.
- [14] Starzl TE, et al. Orthotopic homotransplantation of the human liver. *Ann Surg.* 1968;1680:392415.
- [15] Starzl TE, Marchioro TL, Von Kaulla K, et al. Homotransplantation of the liver in humans. *Surg Gynecol Obstet.* 1963;117:659.
- [16] Starzl TE, Klintmalm GB, Porter KA, et al. Liver transplantation with use of cyclosporin A and prednisone. *N Engl J Med.* 1981;305:266–269.
- [17] Alpert O, Sharma V, Cama S, Spencer S, Huang H. Liver transplant and quality of life in the pediatric population. *Curr Opin Organ Transplant.* 2015;20(2):216–221.

- [18] Squires RH Jr, Shneider BL, Bucuvalas J, et al. Acute liver failure in children: the first 348 patients in the pediatric acute liver failure study group. *J Pediatr*. 2006;148:652.
- [19] Squires RH Jr. Acute liver failure in children. *Semin Liver Dis*. 2008;28:153.
- [20] Squires RH, Alonso EM. Acute liver failure in children. In: Suchy FJ, Sokol RJ, Balistreri WF (Eds.), *Liver Disease in Children*, 4th ed. Cambridge University Press, New York, 2012.
- [21] OPTN/SRTR 2011 annual data report: liver. Accessed at http://srtr.transplant.hrsa.gov/annual_reports/2011.
- [22] Kruper A, Zanowski SC. Parental live liver donation. *Curr Opin Organ Transplant*. 2015;20(2):140–145.
- [23] Kelly DA. Current results and evolving indications for liver transplantation in children. *J Pediatr Gastroenterol Nutr*. 1998;27:214–221.
- [24] McKiernan PJ, Baker AJ, Kelly DA. The frequency and outcome of biliary atresia in the UK and Ireland. *Lancet* 2000;355:25.
- [25] Hartley JL, Davenport M, Kelly DA. Biliary atresia. *Lancet*. 2009;374(9702):1704–1713.
- [26] Tannuri ACA, Gibelli NEM, Ricardi LRS, Silva MM, Santos MM, Pinho-Apezato ML, et al. Orthotopic liver transplantation in biliary atresia: a single-center experience. *Transplant Proc*. 2011;43(1):181–183.
- [27] Takahashi Y, Nishimoto Y, Matsuura T, et al. Surgical complications after living donor liver transplantation in patients with biliary atresia: a relatively high incidence of portal vein complications. *Pediatr Surg Int*. 2009;25:745.
- [28] Starzl TE, Esquivel V, Gordon R, et al. Pediatric liver transplantation. *Transplant Proc* 1987;19:3230.
- [29] Millis JM, Brems JJ, Hiatt JR, et al. Orthotopic liver transplantation for biliary atresia. *Arch Surg*. 1988;123:1237.
- [30] Serinet MO, Wildhaber BE, Broué P, et al. Impact of age at Kasai operation on its results in late childhood and adolescence: a rational basis for biliary atresia screening. *Pediatrics*. 2009 May;123(5):1280–1286. doi:10.1542/peds.2008-1949.
- [31] Humphrey TM, Stringer MD. Biliary atresia: US diagnosis. *Radiology*. 2007 Sep;244(3):845–851.
- [32] Lee MS, Kim MJ, Lee MJ, et al. Biliary atresia: color Doppler US findings in neonates and infants. *Radiology*. 2009 Jul;252(1):282–289. doi:10.1148/radiol.2522080923.
- [33] Takamizawa S1, Zaima A, Muraji T, et al. Can biliary atresia be diagnosed by ultrasonography alone? *J Pediatr Surg*. 2007 Dec;42(12):2093–2096.

- [34] Mittal V, Saxena AK, Sodhi KS, et al. Role of abdominal sonography in the preoperative diagnosis of extrahepatic biliary atresia in infants younger than 90 days. *AJR Am J Roentgenol.* 2011 Apr;196(4):W438–W445. doi:10.2214/AJR.10.5180.
- [35] Park WH, Choi SO, Lee HJ, et al. A new diagnostic approach to biliary atresia with emphasis on the ultrasonographic triangular cord sign: comparison of ultrasonography, hepatobiliary scintigraphy, and liver needle biopsy in the evaluation of infantile cholestasis. *J Pediatr Surg.* 1997 Nov;32(11):1555–1559.
- [36] Azar G, Beneck D, Lane B, et al. Atypical morphologic presentation of biliary atresia and value of serial liver biopsies. *J Pediatr Gastroenterol Nutr* 2002;34:212.
- [37] UPTODATE found at http://www.uptodate.com/contents/biliary-atresia?source=search_result&search=Histologic+findings+alone+cannot+help+to+distinguish+BA&selectedTitle=1%7E150 in Feb/2016.
- [38] Leonhardt J, Kuebler JF, Leute PJ, Turowski C, Becker T, Pfister ED, et al. Biliary atresia: lessons learned from the voluntary German registry. *Eur J Pediatr Surg* 2011;2(21)82–87.
- [39] Shinkai M, Ohhama Y, Take H, Kitagawa N, Kudo H, Mochizuki K, et al. Long-term outcome of children with biliary atresia who were not transplanted after the Kasai operation: >20-year experience at a children's hospital. *J Pediatr Gastroenterol Nutr.* 2009;48:443–450.
- [40] Jung E, Park WH, Choi SO. Late complications and current status of long-term survivals over 10 years after Kasai portoenterostomy. *J Korean Surg Soc.* 2011;81(4):271–275. <http://doi.org/10.4174/jkss.2011.81.4.271>.
- [41] Helbling D, Buchaklian A, Wang J, et al. Reduced mitochondrial DNA content and heterozygous nuclear gene mutations in patients with acute liver failure. *J Pediatr Gastroenterol Nutr.* 2013;57:438.
- [42] Sundaram SS, Alonso EM, Narkewicz MR, et al. Characterization and outcomes of young infants with acute liver failure. *J Pediatr.* 2011;159:813.
- [43] UPTODATE. <http://www.uptodate.com/contents/acute-liver-failure-in-children-etiology-and-evaluation>.
- [44] Francavilla R, Castellaneta SP, Hadzic N, et al. Prognosis of alpha-1-antitrypsin deficiency-related liver disease in the era of paediatric liver transplantation. *J Hepatol.* 2000;32:986–992.
- [45] Kayler LK, Rasmussen CS, Dykstra DM, et al. Liver transplantation in children with metabolic disorders in the United States. *Am J Transplant* 2003;3(3):334–339.
- [46] Hoerning A, Raub S, Dechêne A, et al. Diversity of disorders causing neonatal cholestasis — the experience of a tertiary pediatric center in Germany. *Front Pediatr.* 2014 Jun 23;2:65. doi:10.3389/fped.2014.00065. eCollection 2014.

- [47] Fischler B, Papadogiannakis N, Nemeth A. Aetiological factors in neonatal cholestasis. *Acta Paediatr.* 2001 Jan;90(1):88–92.
- [48] Coakley RJ, Taggart C, O'Neill S, McElvaney NG. Alpha1-antitrypsin deficiency: biological answers to clinical questions. *Am J Med Sci.* 2001 Jan;321(1):33–41.
- [49] Perlmutter DH. Alpha-1-antitrypsin deficiency. *Semin Liver Dis.* 1998;18(3):217–225.
- [50] McDaniell R, Warthen DM, Sanchez-Lara PA, et al. NOTCH2 mutations cause Alagille syndrome, a heterogeneous disorder of the notch signaling pathway. *Am J Hum Genet.* 2006;79(1):169–173.
- [51] Kaye AJ1, Rand EB, Munoz PS, et al. Effect of Kasai procedure on hepatic outcome in Alagille syndrome. *J Pediatr Gastroenterol Nutr.* 2010 Sep;51(3):319–321. doi:10.1097/MPG.0b013e3181df5fd8.
- [52] Kamath BM, Yin W, Miller H, et al. Outcomes of liver transplantation for patients with Alagille syndrome: the studies of pediatric liver transplantation experience. *Liver Transpl.* 2012 Aug;18(8):940–948. doi:10.1002/lt.23437.
- [53] Weinberg AG, Mize CE, Worthen HG. The occurrence of hepatoma in the chronic form of hereditary tyrosinemia. *J Pediatr* 1976;88:434–438.
- [54] McKiernan PJ. Nitisinone in the treatment of hereditary tyrosinaemia type 1. *Drugs.* 2006;66:743–750.
- [55] Rowe SM, Miller S, Sorscher EJ. Mechanisms of disease, cystic fibrosis. *N Engl J Med.* 2005;352:1992–2001.
- [56] Colombo C, Battezzati PM, Strazzabosco M, Podda M. Liver and biliary problems in cystic fibrosis. *Semin Liver Dis.* 1998;18(3):227–235.
- [57] Debray D, Lykavieris P, Gauthier F, et al. Outcome of cystic fibrosis-associated liver cirrhosis: management of portal hypertension. *J Hepatol.* 1999;31:77–83.
- [58] Milkiewicz P, Skiba G, Kelly D, et al. Transplantation for cystic fibrosis: outcome following early liver transplantation. *J Gastroenterol Hepatol* 2002;17:208.
- [59] Frydman M, Bonne-Tamir B, Farrer LA, et al. Assignment of the gene for Wilson disease to chromosome 13: linkage to the esterase D locus. *Proc Natl Acad Sci USA.* 1985;82:1819–1821.
- [60] Dhawan A, Taylor RM, Cheeseman P, et al. Wilson's disease in children: 37-year experience and revised King's score for liver transplantation. *Liver Transplant* 2005;11:441–448.
- [61] Rela M, Heaton ND, Vougas V, et al. Orthotopic liver transplantation for hepatic complications of Wilson's disease. *Br J Surg.* 1993;80:909–911.
- [62] UPTODATE. Accessed at http://www.uptodate.com/contents/acute-liver-failure-in-children-etiology-and-evaluation?source=search_result&search=%27Acute+liver

+failure+in+children% 3A+Etiology+and+evaluation%27&selectedTitle=1%7E150 in Jan 2016.

- [63] Labrune P, Myara A, Hadchouel M, et al. Genetic heterogeneity of Crigler-Najjar syndrome type I: a study of 14 cases. *Hum Genet.* 1994;94(6):693–697.
- [64] Rezvani I, Auerbach VH. Primary hyperoxaluria. *N Engl J Med.* 2013;369(22):2162–2163.
- [65] Strobele B, Loveland J, Britz R, et al. Combined paediatric liver-kidney transplantation: analysis of our experience and literature review. *S Afr Med J* 2013;103(12):925–929.
- [66] Ries LAG, Smith MA, Gurney JG, Linet M, Tamra T, Young JL, Bunin GR (Eds.), *Cancer Incidence and Survival among Children and Adolescents: United States SEER Program 1975–1995*. National Cancer Institute, SEER Program. Bethesda, MD, NIH. Pub. 1999: 99-4649. Available from: URL: <http://seer.cancer.gov/archive/publications/childhood/>.
- [67] Ismail H, Broniszczak D, Kaliciński P, Dembowska-Bagińska B, Perek D, Teisseyre J, Kluge P, Kościeszka A, Lembas A, Markiewicz M. Changing treatment and outcome of children with hepatoblastoma: analysis of a single center experience over the last 20 years. *J Pediatr Surg.* 2012;47: 1331–1339 [PMID: 22813792, doi:10.1016/j.jpedsurg.2011.11.073].
- [68] Howlader N, Noone AM, Krapcho M, Neyman N, Aminou R, Waldron W, Altekruse SF, Kosary CL, Ruhl J, Tatalovich Z, Cho H, Mariotto A, Eisner MP, Lewis DR, Chen HS, Feuer EJ, Cronin KA (Eds.), *SEER Cancer Statistics Review, 1975–2009 (Vintage 2009 Populations)*. National Cancer Institute. Based on November 2011 SEER data submission, posted to the SEER web site, April 2012 [Updated August 20, 2012]. Available from: URL: http://seer.cancer.gov/archive/csr/1975_2009_pops09/.
- [69] Litten JB, Tomlinson GE. Liver tumors in children. *Oncologist.* 2008;13:812–820 [PMID: 18644850 doi: 10.1634/theoncologist.2008-0011].
- [70] Otte JB, De Ville de Goyet J. The contribution of transplantation to the treatment of liver tumors in children. *Semin Pediatr Surg.* 2015;14:233–238.
- [71] Czauderna P, Otte JB, Aronson DC, et al. Guidelines for surgical treatment of hepatoblastoma in the modern era: recommendations from the childhood liver tumour strategy group of the International Society of Paediatric Oncology (SIO-PEL). *Eur J Cancer.* 2005;41:1031–1036.
- [72] Dall'Igna P, Cecchetto G, Toffolutti T, et al. Multifocal hepatoblastoma is there a place for partial hepatectomy? *Med Pediatr Oncol.* 2003;40:113–116.
- [73] Chardot C, Sant Martin C, Gilles A, et al. Living related liver transplantation and vena cava reconstruction after total hepatectomy including the vena cava for hepatoblastoma. *Transplantation* 2002;73:90–92.

- [74] Czauderna P, Mac Kinley G, Perilongo G, et al. Hepatocellular carcinoma in children: results of the first prospective study of the international society of pediatric oncology group. *J Clin Oncol*. 2002;20:2798–804.
- [75] Millar AJW, Hartley P, Khan D, et al. Extended hepatic resection with transplantation back-up for an unresectable tumor. *Pediatric Surg Int*. 2001;17:378–81.
- [76] Austin MT, Leys CM, Feurer ID, et al. Liver transplantation for childhood hepatic malignancy: a review of the United Network for Organ Sharing (UNOS) database. *J Pediatr Surg*. 2006;41:182–186.
- [77] Otte JB. Progress in the surgical treatment of malignant liver tumors in children. *Cancer Treat Rev*. 2010;36(4):360–371. Elsevier Ltd.
- [78] Wiederkehr JC, Coelho IM, Avilla SG, Wiederkehr BA, Wiederkehr HA. Liver tumors in infancy (n.d.).
- [79] Hoti E, Adam R. Liver transplantation for primary and metastatic liver cancers. *Transplant Int*. 2008;21:1107–1117.
- [80] Srinivasan P, Mc Call J, Pritchard J, et al. Orthotopic liver transplantation for unresectable hepatoblastoma. *Transplantation*. 2002;74:652–655.
- [81] Tagge EP, Tagge DU, Reyes J, et al. Resection, including transplantation, for hepatoblastoma and hepatocellular carcinoma: impact on survival. *J Pediatr Surg*. 1992;27:292–296 [discussion 297].
- [82] Freeman RB, Jr, Edwards EB. Liver transplant waiting time does not correlate with waiting list mortality: implications for liver allocation policy. *Liver Transplant*. 2000;6(5):543–552.
- [83] Organ Procurement and Transplantation Network-HRSA. Final rule with comment period. *Fed Regist*. 1998;63:16296–16338.
- [84] Mazzaferro V, Regalia E, Doci R, et al.. Liver transplantation for the treatment of small hepatocellular carcinoma in patients with cirrhosis. *New Engl J Med*. 1996;334:693–699.
- [85] Terracciano L, Tornillo L. Cytogenetic alteration in liver cell tumors as detected by comparative genomic hybridization. *Pathologica*. 2003;95:71–82.
- [86] Bravo LC, Gregorio GV, Shafi F, et al. Etiology, incidence and outcomes of acute hepatic failure in 0–18 year old Filipino children. *Southeast Asian J Trop Med Public Health*. 2012;43(3):764–772.
- [87] Baris Z, Saltik Temizel IN, Uslu N, et al. Acute liver failure in children: 20-year experience. *Turk J Gastroenterol*. 2012;23(2):127–134.
- [88] Lee WS, McKiernan P, Kelly DA. Etiology, outcome and prognostic indicators of childhood fulminant hepatic failure in the United Kingdom. *J Pediatr Gastroenterol Nutr*. 2005;40:575–581.

- [89] Murray KF, Hadzic N, Wirth S, et al. Drug-related hepatotoxicity and acute liver failure. *J Pediatr Gastroenterol Nutr.* 2008;47:395–405.
- [90] Lauterberg BH, Vaishnar Y, Stillwell WB, et al. The effects of age and glutathione depletion on hepatic glutathione turnover in vivo determined by acetaminophen probe analysis. *J Pharmacol Exp Ther.* 1980;213:54–58.
- [91] Mahadevan SB, McKiernan PJ, Davies P, et al. Paracetamol induced hepatotoxicity. *Arch Dis Child* 2006;91(7):598–603.
- [92] Yao FY, Ferrell L, Bass NM, et al. Liver transplantation for hepatocellular carcinoma: expansion of the tumor size limits does not adversely impact survival. *Hepatology.* 2001;33:1394–1403.
- [93] Sokal EM, Van Hoorebeeck N, Van Obbergh L, et al. Upper gastro-intestinal tract bleeding in cirrhotic children candidates for liver transplantation. *Eur J Pediatr.* 1992;151:326–328.
- [94] Hall RJ, Lilly JR, Stiegmann GV Endoscopic esophageal varix ligation: technique and preliminary results in children. *J Pediatr Surg.* 1988;23:1222–1223.
- [95] Berger H, Bugnon F, Goffette P, et al. Percutaneous transjugular intrahepatic stent shunt for treatment of intractable varicose bleeding in paediatric patients. *Eur J Pediatr.* 1994;153:721–725.
- [96] UPTODATE. Accessed at <http://www.uptodate.com/contents/immunizations-in-solid-organ-transplant-candidates-and-recipients> in Jan 2016.
- [97] Kasai M, Kimura S, Asakura Y, et al. Surgical treatment of biliary atresia. *J Pediatr Surg.* 1968;3:665–675.
- [98] Malatack JJ, Schaid DJ, Urbach AH, et al. Choosing a pediatric recipient for orthotopic liver transplantation. *J Pediatr.* 1987;111:479–489.
- [99] Hobeika J, Houssin D, Bernard O, et al. Orthotopic liver transplantation in children with chronic liver disease and severe hypoxemia. *Transplantation* 1994;57:224–228.
- [100] Ventura K. Ethical considerations in live liver donation to children. *Prog Transplant* 2010; 20:186–190.
- [101] Duerinckx N, Timmerman L, Van Gogh J, et al. Predonation psychosocial & evaluation of living kidney and liver donor candidates: a systematic literature review. *Transplant Int.* 2014;27:2–18.
- [102] Broelsch CE, Emond JC, Thistlethwaite JR, Whittington PF, Zucker AR, Baker AL, Aran PF, Rouch DA, Lichtor JL. Liver transplantation, including the concept of reduced-size liver transplants in children. *Ann Surg.* 1988;208:410–420 [PMID: 3052326].

- [103] Broelsch CE, Emond JC, Thistlethwaite JR, Rouch DA, Whittington PF, Lichtor JL. Liver transplantation with reduced-size donor organs. *Transplantation*. 1988;45:519–524 [PMID: 3279573].
- [104] Pichlmayr R, Ringe B, Gubernatis G, Hauss J, Bunzendahl H. Transplantation of a donor liver to 2 recipients (splitting transplantation)—a new method in the further development of segmental liver transplantation. *Langenbecks Arch Chir*. 1988;373:127–130 [PMID: 3287073].
- [105] Eurotransplant International Foundation. EAR 2013. Available from: http://www.eurotransplant.org/cms/index.php?page=annual_reports.
- [106] Couinaud C. Liver lobes and segments: notes on the anatomical architecture and surgery of the liver. *Presse Med*. 1954;62:709–712 [PMID: 13177441].
- [107] Couinaud C. Liver anatomy: portal (and suprahepatic) or biliary segmentation. *Dig Surg*. 1999; 16:459–467 [PMID: 10805544].
- [108] Kanazawa H, Sakamoto S, Fukuda A, Uchida H, Hamano I, Shigeta T, Kobayashi M, Karaki C, Tanaka H, Kasahara M. Living-donor liver transplantation with hyperreduced left lateral segment grafts: a single-center experience. *Transplantation*. 2013;95:750–754 [PMID: 23503505, doi: 10.1097/TP.0b013e31827a93b4].
- [109] Caso Maestro O, Abradelo de Usera M, Justo Alonso I, Calvo Pulido J, Manrique Municio A, Cambra Molero F, García Sesma A, Loinaz Seguro C, Moreno González E, Jiménez Romero C. Porcine acellular dermal matrix for delayed abdominal wall closure after pediatric liver transplantation. *Pediatr Transplant*. 2014;18:594–598 [PMID: 25039398, doi:10.1111/petr.12319].
- [110] Gubernatis G, Pichlmayr R, Kemnitz J, Gratz K. Auxiliary partial orthotopic liver transplantation (APOLT) for fulminant hepatic failure: first successful case report. *World J Surg*. 1991; 15:660–665; discussion 665–666 [PMID: 1949867].
- [111] Melter M, Grothues D, Knoppke B. Pädiatrische Lebertrans- plantation. *Monatsschr Kinderheilkd*. 2012;160:343–357 [doi:10.1007/s00112-011-2561-9].
- [112] Faraj W, Dar F, Bartlett A, Melendez HV, Marangoni G, Mukherji D, Vergani GM, Dhawan A, Heaton N, Rela M. Auxiliary liver transplantation for acute liver failure in children. *Ann Surg*. 2010; 251: 351–356 [PMID: 20054274, doi:10.1097/SLA.0b013e3181bdfef6].
- [113] Shanmugam NP, Dhawan A. Selection criteria for liver trans- plantation in paediatric acute liver failure: the saga continues. *Pediatr Transplant*. 2011;15:5–6 [PMID: 21241436, doi:10.1111/j.1399-3046.2010.01457.x].
- [114] Broelsch CE, Emond JC, Whittington PF, Thistlethwaite JR, Baker AL, Lichtor JL. Application of reduced-size liver transplants as split grafts, auxiliary orthotopic grafts, and living related segmental transplants. *Ann Surg*. 1990;212:368–375; discussion 375–377 [PMID: 2396888].

- [115] Raia S, et al. Liver transplantation from live donors. *Lancet*. 334(8661):497.
- [116] Lee SG, Moon DB. Living donor liver transplantation for hepatocellular carcinoma. *Recent Results Cancer Res*. 2013;190:165–179 [PMID: 22941020, doi: 10.1007/978-3-642-16037-0_11].
- [117] Organ Procurement and Transplantation Network. [Accessed 2014 Dec 1]. Available from: URL: <http://optn.transplant.hrsa.gov/converge/latestdata/rptData.asp>.
- [118] Bhangui P, Vibert E, Majno P, Salloum C, Andreani P, Zocrato J, Ichai P, Saliba F, Adam R, Castaing D, Azoulay D. Intention-to-treat analysis of liver transplantation for hepatocellular carcinoma: living versus deceased donor transplantation. *Hepatology*. 2011;53:1570–1579 [PMID: 21520172, doi:10.1002/hep.24231].
- [119] Gondolesi GE, Roayaie S, Muñoz L, Kim-Schluger L, Schiano T, Fishbein TM, Emre S, Miller CM, Schwartz ME. Adult living donor liver transplantation for patients with hepatocellular carcinoma: extending UNOS priority criteria. *Ann Surg*. 2004;239:142–149 [PMID: 14745320, doi: 10.1097/01.sla.0000109022.32391.eb].
- [120] Grant RC, Sandhu L, Dixon PR, Greig PD, Grant DR, McGilvray ID. Living vs. deceased donor liver transplantation for hepatocellular carcinoma: a systematic review and meta-analysis. *Clin Transplant*. 2013;27:140–147 [PMID: 23157398, doi:10.1111/ctr.12031].
- [121] Kaihara S, Kiuchi T, Ueda M, Oike F, Fujimoto Y, Ogawa K, Kozaki K, Tanaka K. Living-donor liver transplantation for hepatocellular carcinoma. *Transplantation*. 2003;75:S37–S40 [PMID: 12589138, doi:10.1097/01.TP.0000047029.02806.16].
- [122] Sandhu L, Sandroussi C, Guba M, Selzner M, Ghanekar A, Cattral MS, McGilvray ID, Levy G, Greig PD, Renner EL, Grant DR. Living donor liver transplantation versus deceased donor liver transplantation for hepatocellular carcinoma: comparable survival and recurrence. *Liver Transplant*. 2012;18:315–322 [PMID: 22140013, doi: 10.1002/lt.22477].
- [123] Todo S, Furukawa H. Japanese Study Group on Organ Transplantation. Living donor liver transplantation for adult patients with hepatocellular carcinoma: experience in Japan. *Ann Surg*. 2004; 240:451–459; discussion 459–461 [PMID: 15319716].
- [124] Saidi RF, Jabbour N, Li Y, Shah SA, Bozorgzadeh A. Is left lobe adult-to-adult living donor liver transplantation ready for widespread use? The US experience (1998–2010). *HPB (Oxford)* 2012;14:455–460 [PMID: 22672547, doi:10.1111/j.1477-2574.2012.00475.x].
- [125] Saidi RF, Markmann JF, Jabbour N, Li Y, Shah SA, Cosimi AB, Bozorgzadeh A. The faltering solid organ donor pool in the United States (2001–2010). *World J Surg*. 2012;36(12):2909–2913 [PMID: 22933050, doi: 10.1007/s00268-012-1748-0].
- [126] Muzaale AD, Dagher NN, Montgomery RA, Taranto SE, McBride MA, Segev DL. Estimates of early death, acute liver failure, and long-term mortality among live liver

- donors. *Gastroenterology*. 2012;142:273–280 [PMID: 22108193, doi:10.1053/j. gastro. 2011.11.015].
- [127] Rodeck B, Melter M, Kardorff R, Hoyer PF, Ringe B, Burdelski M, Oldhafer KJ, Pichlmayr R, Brodehl J. Liver transplantation in children with chronic end stage liver disease: factors influencing survival after transplantation. *Transplantation*. 1996;62:1071–1076 [PMID: 8900304].
- [128] Roll GR, Roberts JP. Left versus right lobe liver donation. *Am J Transplant*. 2014;14:251–252 [PMID: 24304562, doi:10.1111/ ajt.12556].
- [129] Roll GR, Parekh JR, Parker WF, Siegler M, Pomfret EA, Ascher NL, Roberts JP. Left hepatectomy versus right hepatectomy for living donor liver transplantation: shifting the risk from the donor to the recipient. *Liver Transplant*. 2013;19:472–481 [PMID: 23447523, doi:10.1002/lt.23608].
- [130] Ghobrial RM, Freise CE, Trotter JF, Tong L, Ojo AO, Fair JH, Fisher RA, Emond JC, Koffron AJ, Pruett TL, Olthoff KM. Donor morbidity after living donation for liver transplantation. *Gastroenterology*. 2008;135:468–476 [PMID: 18505689, doi:10.1053/ j.gastro.2008.04.018].
- [131] Kousoulas L, Becker T, Richter N, Emmanouilidis N, Schrem H, Barg-Hock H, Klempnauer J, Lehner F. Living donor liver transplantation: effect of the type of liver graft donation on donor mortality and morbidity. *Transplant Int*. 2011;24:251–258 [PMID: 21062368, doi:10.1111/j.1432-2277.2010.01183.x].
- [132] Kousoulas L, Emmanouilidis N, Klempnauer J, Lehner F. Living-donor liver transplantation: impact on donor's health-related quality of life. *Transplant Proc*. 2011;43:3584–3587 [PMID: 22172809, doi:10.1016/j.transproceed.2011.10.038].
- [133] Lo CM. Complications and long-term outcome of living liver donors: a survey of 1,508 cases in five Asian centers. *Transplantation*. 2003;75:S12–S15 [PMID: 12589131].
- [134] Morioka D, Egawa H, Kasahara M, Ito T, Haga H, Takada Y, Shimada H, Tanaka K. Outcomes of adult-to-adult living donor liver transplantation: a single institution's experience with 335 consecutive cases. *Ann Surg*. 2007;245:315–325 [PMID: 17245187, doi:10.1097/01.sla.0000236600.24667.a4].
- [135] Umeshita K, Fujiwara K, Kiyosawa K, Makuuchi M, Satomi S, Sugimachi K, Tanaka K, Monden M; Japanese Liver Transplantation Society. Operative morbidity of living liver donors in Japan. *Lancet*. 2003;362:687–690 [PMID: 12957090, doi:10.1016/ S0140-6736(03)14230-4].
- [136] Tannuri ACA, Gibelli NEM, Ricardi LRS, Santos MM, Maksoud-Filho JG, Pinho-Apezato ML et al. Living related donor liver transplantation in children. *Transplant Proc*. 2011;43(1):161–164. <http://doi.org/10.1016/j.transproceed.2010.11.013>.

- [137] McDiarmid SV. Special considerations for pediatric immunosuppression after liver transplantation. In: Busuttil RW, Klintmalm GB (Eds.), *Transplantation of the Liver*. Philadelphia, London: W.B. Saunders Co., 1996. pp. 250–261.
- [138] Ganschow R, Grabhorn E, Burdelski M. Basiliximab in paediatric liver-transplant recipients. *Lancet* 2001;357:388 [PMID: 11211016, doi:10.1016/S0140-6736(00)03654-0].
- [139] Ganschow R, Grabhorn E, Schulz A, Von Hugo A, Rogiers X, Burdelski M. Long-term results of basiliximab induction immunosuppression in pediatric liver transplant recipients. *Pediatr Transplant*. 2005;9:741–745 [PMID: 16269045, doi:10.1111/j.1399-3046.2005.00371.x].
- [140] Grabhorn E, Schulz A, Helmke K, Hinrichs B, Rogiers X, Broering DC, Burdelski M, Ganschow R. Short- and long-term results of liver transplantation in infants aged less than 6 months. *Transplantation*. 2004;78:235–241 [PMID: 15280684].
- [141] Heffron TG, Pillen T, Smallwood GA, Welch D, Oakley B, Romero R. Pediatric liver transplantation with daclizumab induction. *Transplantation*. 2003;75:2040–2043 [PMID: 12829908, doi:10.1097/01.TP.0000065740.69296.DA].
- [142] Schuller S, Wiederkehr JC, Coelho-Lemos IM, Avilla SG, Schultz C. Daclizumab induction therapy associated with tacrolimus-MMF has better outcome compared with tacrolimus-MMF alone in pediatric living donor liver transplantation. *Transplant Proc*. 2005;37:1151–1152 [PMID: 15848653, doi:10.1016/j.transproceed.2005.01.023].
- [143] Strassburg CP, Manns MP. Partial liver transplantation and living donation from the viewpoint of internal medicine. *Der Internist* 2002;43:1551–1558.
- [144] Di Filippo S. Anti-IL-2 receptor antibody vs. polyclonal anti-lymphocyte antibody as induction therapy in pediatric transplantation. *Pediatr Transplant*. 2005;9:373–380 [PMID: 15910396, doi:10.1111/j.1399-3046.2005.00303.x].
- [145] Dell-Olio D, Kelly DA. Calcineurin inhibitor minimization in pediatric liver allograft recipients. *Pediatr Transplant*. 2009;13:670–681 [PMID: 19413716, doi:10.1111/j.1399-3046.2009.01184.x].
- [146] Tönshoff B, Höcker B. Treatment strategies in pediatric solid organ transplant recipients with calcineurin inhibitor-induced nephrotoxicity. *Pediatr Transplant*. 2006;10:721–729 [PMID: 16911497, doi:10.1111/j.1399-3046.2006.00577.x].
- [147] Tredger JM, Brown NW, Dhawan A. Immunosuppression in pediatric solid organ transplantation: opportunities, risks, and management. *Pediatr Transplant*. 2006;10:879–892 [PMID: 17096754, doi:10.1111/j.1399-3046.2006.00604.x].
- [148] Turmelle YP, Nadler ML, Anderson CD, Doyle MB, Lowell JA, Shepherd RW. Towards minimizing immunosuppression in pediatric liver transplant recipients. *Pediatr Transplant*. 2009;13:553–559 [PMID: 19067920, doi:10.1111/j.1399-3046.2008.01061.x].

- [149] Evans HM, McKiernan PJ, Kelly DA. Mycophenolate mofetil for renal dysfunction after pediatric liver transplantation. *Transplantation*. 2005;79:1575–1580 [PMID: 15940048].
- [150] Ferraris JR, Duca P, Prigoshin N, Tambutti ML, Boldrini G, Cardoni RL, D'Agostino D. Mycophenolate mofetil and reduced doses of cyclosporine in pediatric liver transplantation with chronic renal dysfunction: changes in the immune responses. *Pediatr Transplant*. 2004;8:454–459 [PMID: 15367280, doi:10.1111/j.1399-3046.2004.00172.x].
- [151] Filler G, Gellermann J, Zimmering M, Mai I. Effect of adding Mycophenolate mofetil in paediatric renal transplant recipients with chronic cyclosporine nephrotoxicity. *Transplant Int* 2000; 13:201–206 [PMID: 10935703].
- [152] Hoyer PF, Ettenger R, Kovarik JM, Webb NJ, Lemire J, Mentser M, Mahan J, Loirat C, Niaudet P, VanDamme-Lombaerts R, Offner G, Wehr S, Moeller V, Mayer H. Everolimus in pediatric de novo renal transplant patients. *Transplantation*. 2003;75:2082–2085 [PMID: 12829916, doi:10.1097/01.TP.0000070139.63068.54].
- [153] Jiménez-Rivera C, Avitzur Y, Fecteau AH, Jones N, Grant D, Ng VL. Sirolimus for pediatric liver transplant recipients with post-transplant lymphoproliferative disease and hepatoblastoma. *Pediatr Transplant*. 2004;8:243–248 [PMID: 15176961, doi:10.1111/j.1399-3046.2004.00156.x].
- [154] Scheenstra R, Torringa ML, Waalkens HJ, Middelveld EH, Peeters PM, Slooff MJ, Gouw AS, Verkade HJ, Bijleveld CM. Cyclosporine A withdrawal during follow-up after pediatric liver transplantation. *Liver Transplant*. 2006;12:240–246 [PMID: 16447209, doi:10.1002/lt.20591].
- [155] Sindhi R, Ganjoo J, McGhee W, Mazariegos G, Reyes J. Preliminary immunosuppression withdrawal strategies with sirolimus in children with liver transplants. *Transplant Proc*. 2002;34:1972–1973 [PMID: 12176651].
- [156] Vester U, Kranz B, Wehr S, Boger R, Hoyer PF; RAD B 351 Study Group. Everolimus (Certican) in combination with neoral in pediatric renal transplant recipients: interim analysis after 3 months. *Transplant Proc*. 2002;34:2209–2210 [PMID: 12270366].
- [157] Feng S, Ekong UD, Lobritto SJ, Demetris AJ, Roberts JP, Rosenthal P, Alonso EM, Philogene MC, Ikle D, Poole KM, Bridges ND, Turka LA, Tchao NK. Complete immunosuppression withdrawal and subsequent allograft function among pediatric recipients of parental living donor liver transplants. *JAMA*. 2012;307:283–293 [PMID: 22253395, doi: 10.1001/jama.2011.2014].
- [158] Koshiba T, Li Y, Takemura M, Wu Y, Sakaguchi S, Minato N, Wood KJ, Haga H, Ueda M, Uemoto S. Clinical, immunological, and pathological aspects of operational tolerance after pediatric living-donor liver transplantation. *Transplant Immunol*. 2007;17:94–97 [PMID: 17306739, doi:10.1016/j.trim.2006.10.004].

- [159] Mazariegos GV, Reyes J, Marino IR, Demetris AJ, Flynn B, Irish W, McMichael J, Fung JJ, Starzl TE. Weaning of immunosuppression in liver transplant recipients. *Transplantation*. 1997;63:243–249 [PMID: 9020325].
- [160] Mazariegos GV, Sindhi R, Thomson AW, Marcos A. Clinical tolerance following liver transplantation: long term results and future prospects. *Transplant Immunol*. 2007;17:114–119 [PMID: 17306742, doi:10.1016/j.trim.2006.09.033].
- [161] Starzl TE, Demetris AJ, Trucco M, Ricordi C, Murase N, Thomson AW. The role of cell migration and chimerism in organ transplant acceptance and tolerance induction. *Transplant Sci*. 1993;3:47–50 [PMID: 21572595].
- [162] Takatsuki M, Uemoto S, Inomata Y, Egawa H, Kiuchi T, Fujita S, Hayashi M, Kanematsu T, Tanaka K. Weaning of immunosuppression in living donor liver transplant recipients. *Transplantation*. 2001;72:449–454 [PMID: 11502975].
- [163] Donckier V, Troisi R, Le Moine A, Toungouz M, Ricciardi S, Colle I, Van Vlierberghe H, Craciun L, Libin M, Praet M, Noens L, Stordeur P, Andrien M, Lambermont M, Gelin M, Bourgeois N, Adler M, de Hemptinne B, Goldman M. Early immunosuppression withdrawal after living donor liver transplantation and donor stem cell infusion. *Liver Transplant*. 2006;12:1523–1528 [PMID: 17004249, doi:10.1002/lt.20872].
- [164] Kawai T, Cosimi AB, Spitzer TR, Tolkoff-Rubin N, Suthanthiran M, Saidman SL, Shaffer J, Preffer FI, Ding R, Sharma V, Fishman JA, Dey B, Ko DS, Hertl M, Goes NB, Wong W, Williams WW, Colvin RB, Sykes M, Sachs DH. HLA-mismatched renal transplantation without maintenance immunosuppression. *N Engl J Med*. 2008;358:353–361 [PMID: 18216355, doi:10.1056/NEJMoa071074].
- [165] Scandling JD, Busque S, Dejbakhsh-Jones S, Benike C, Millan MT, Shizuru JA, Hoppe RT, Lowsky R, Engleman EG, Strober S. Tolerance and chimerism after renal and hematopoietic-cell transplantation. *N Engl J Med*. 2008;358:362–368 [PMID: 18216356, doi:10.1056/NEJMoa074191].
- [166] Starzl TE, et al. Cell migration and clmerism after whole-organ transplantation: the basis of graft acceptance. *Hepatology*. 1993;17:1127–171152.
- [167] Ramos HC, Reyes J, Abu-Elmagd K, et al. Weaning of immunosuppression in long-term liver transplant recipients. *Transplantation*. 1995;59:212–217
- [168] Wong T, Nouri-Aria K T, Devlin J, et al. Tolerance and latent cellular rejection in long-term liver transplant recipients. *Hepatology*. 1998;28:443–449.
- [169] Smith BA, Shuchman M. Problem of nonadherence in chronically ill adolescents: strategies for assessment and intervention. *Curr Opin Pediatr*. 2005;17:613–618.
- [170] Hind JM, Kelly DA. Pediatric liver transplantation: review of the literature 2007–2008. *Pediatric Transplant*. 2009;13(1):14–24. <http://doi.org/10.1111/j.1399-3046.2009.01238.x>.

- [171] Fredericks EM, Magee JC, Opipari-Arrigan L, et al. Adherence and health-related quality of life in adolescent liver transplant recipients. *Pediatr Transplant*. 2008;12:289–299.
- [172] Berquist RK, Berquist WE, Esquivel CO, et al. Non-adherence to post-transplant care: prevalence, risk factors and outcomes in adolescent liver transplant recipients. *Pediatr Transplant*. 2008;12:194–200.
- [173] Lurie S, Shemesh E, Sheiner PA, et al. Non-adherence in pediatric liver transplant recipients—an assessment of risk factors and natural history. *Pediatr Transplant*. 2000;4:200–206.
- [174] Dew MA, Dabbs AD, Myaskovsky L, et al. Meta-analysis of medical regimen adherence outcomes in pediatric solid organ transplantation. *Transplantation*. 2009;88:736–746.
- [175] Burra P. The adolescent and liver transplantation. *J Hepatol*. 2012;56:714–722.
- [176] Stuber ML, Shemesh E, Seacord D, et al. Evaluating non-adherence to immunosuppressant medications in pediatric liver transplant recipients. *Pediatr Transplant*. 2008;12:284–288.
- [177] O’Grady JG, Asderakis A, Bradley R, et al. Multidisciplinary insights into optimizing adherence after solid organ transplantation. *Transplantation*. 2010;89:627–632.
- [178] Maksoud-Filho JG, Tannuri U, Gibelli NEM, et al. Intimal dissection of the hepatic artery after thrombectomy as a cause of graft loss in pediatric living-related liver transplantation. *Pediatr Transplant*. 2008;12:91–94.
- [179] Uller W, Knoppke B, Schreyer Ag, et al. Interventional radiological treatment of perihepatic vascular stenosis or occlusion in pediatric patients after liver transplantation. *Cardiovasc Intervent Radiol*. 2013;36:1562–1571.
- [180] Bekker J, Ploem S, De Jong K P. Early hepatic artery thrombosis after liver transplantation: a systematic review of the incidence, outcome and risk factors. *Am J Transplant*. 2009;9:746–757.
- [181] Porrett P M, Hsu J, Shaked A. Late surgical complications following liver transplantation. *Liver Transplant*. 2009;15(Suppl 2):S12–S18.
- [182] Oh C K, Pelletier S J, Sawyer R G, et al. Uni- and multi-variate analysis of risk factors for early and late hepatic artery thrombosis after liver transplantation. *Transplantation*. 2001;71:767–772.
- [183] Silva MA, Jambulingam PS, Gunson BK, et al. Hepatic artery thrombosis following orthotopic liver transplantation: a 10-year experience from a single centre in the United Kingdom. *Liver Transplant*. 2006;12:146–151.
- [184] Gunsar F, Rolando N, Pastacaldi S, et al. Late hepatic artery thrombosis after orthotopic liver transplantation. *Liver Transplant*. 2003;9:605–611.

- [185] Valente JF, Alonso MH, Weber FL, Hanto DW. Late hepatic artery thrombosis in liver allograft recipients is associated with intrahepatic biliary necrosis. *Transplantation*. 1996;61:61–65.
- [186] Tzakis AG, Gordon RD, Shaw BW Jr, Iwatsuki S, Starzl TE. Clinical presentation of hepatic artery thrombosis after liver transplantation in the cyclosporine era. *Transplantation*. 1985;40:667–671.
- [187] Singhal A, Stokes K, Sebastian A, et al. Endovascular treatment of hepatic artery thrombosis following liver transplantation. *Transplant Int*. 2010;23:245–256.
- [188] Hasegawa T, Sasaki T, Kimura T, et al. Successful percutaneous transluminal angioplasty for hepatic artery stenosis in an infant undergoing living-related liver transplantation. *Pediatr Transplant*. 2002;6:244–248.
- [189] Maruzzelli L, Miraglia R, Caruso S, et al. Percutaneous endovascular treatment of hepatic artery stenosis in adult and pediatric patients after liver transplantation. *Cardiovasc Intervent Radiol*. 2010; 33:1111–1119.
- [190] Wakiya T, Sanada Y, Mizuta K, et al. Endovascular interventions for hepatic artery complications immediately after pediatric liver transplantation. *Transplant Int*. 2011;24:984–990.
- [191] Wakiya T, Sanada Y, Mizuta K, et al. Interventional radiology for hepatic artery complications soon after living donor liver transplantation in a neonate. *Pediatr Transplant*. 2012;16:E81–E85.
- [192] Carnevale FC, De Tarso Machado A, Moreira AM, et al. Long-term results of the percutaneous transhepatic venoplasty of portal vein stenoses after pediatric liver transplantation. *Pediatr Transplant*. 2011;15:476–481.
- [193] Umehara M, Narumi S, Sugai M, et al. Hepatic venous out-flow obstruction in living donor liver transplantation: Balloon angioplasty or stent placement? *Transplant Proc*. 2012;44:769–771.
- [194] Shibasaki S, Taniguchi M, Shimamura T, et al. Risk factors for portal vein complications in pediatric living donor liver transplantation. *Clin Transplant*. 2010;24:550–556.
- [195] Kawano Y, Mizuta K, Sugawara Y, et al. Diagnosis and treatment of pediatric patients with late-onset portal vein stenosis after living donor liver transplantation. *Transplant Int*. 2009;22:1151–1158.
- [196] Kawano Y, Akimaru K, Taniai N, et al. Successful transjugular balloon dilatation of the hepatic vein stenosis causing hypoalbuminemia after pediatric living-donor liver transplantation. *Hepatogastroenterology*. 2007;54:1821–1824.
- [197] Carnevale FC, Borges MV, Pinto RA, Oliva JL, Andrade WDE C, Maksoud JG. Endovascular treatment of stenosis between hepatic vein and inferior vena cava following liver transplantation in a child: a case report. *Pediatr Transplant*. 2004;8:576–580.

- [198] Carnevale FC, Borges MV, Moreira AM, Cerri GG, Maksoud JG. Endovascular treatment of acute portal vein thrombosis after liver transplantation in a child. *Cardiovasc Intervent Radiol*. 2006;29:457–461.
- [199] Ueda M, Oike F, Kasahara M, et al. Portal vein complications in pediatric living donor liver transplantation using left-side grafts. *Am J Transplant*. 2008;8:2097–2105.
- [200] Azzam A Z, Tanaka K. Management of vascular complications after living donor liver transplantation. *Hepatogastroenterology*. 2012;59:182–186.
- [201] Yilmaz A, Arikan C, Tumgor G, Kilic M, Aydogdu S. Vascular complications in living-related and deceased donation pediatric liver transplantation: Single center's experience from Turkey. *Pediatr Transplant*. 2007;11:160–164.
- [202] Sanada Y, Kawano Y, Mizuta K, et al. Strategy to prevent recurrent portal vein stenosis following interventional radiology in pediatric liver transplantation. *Liver Transplant*. 2010;16:332–339.
- [203] Mitchell A, John PR, Mayer DA, Mirza DF, Buckels JAC, De Ville De Goyet J. Improved technique of portal vein reconstruction in pediatric liver transplant recipients with portal vein hypoplasia. *Transplantation*. 2002;73:1244–1247.
- [204] Millis JM, Seaman DS, Piper JB, et al. Portal vein thrombosis and stenosis in pediatric liver transplantation. *Transplantation*. 1996;62:748–754.
- [205] Orlandini M, Feier FH, Jaeger B, Kieling C, Vieira SG, Zanotelli ML. Frequency of and factors associated with vascular complications after pediatric liver transplantation. *J Pediatr. (Rio J.)* 2013;90:169–175.
- [206] Llad OL, Fabregat J, Castellote J, et al. Management of portal vein thrombosis in liver transplantation: Influence on morbidity and mortality. *Clin Transplant*. 2007;21:716–721.
- [207] Suzuki L, De Oliveira I R S, Widman A, et al. Real-time and Doppler US after pediatric segmental liver transplantation. I. Portal vein stenosis. *Pediatr Radiol*. 2008;38:403–408.
- [208] Uller W, Knoppke B, Schreyer AG, et al. Interventional radiological treatment of perihepatic vascular stenosis or occlusion in pediatric patients after liver transplantation. *Cardiovasc Intervent Radiol*. 2013;36:1562–1571.
- [209] Buell JF, Funaki B, Cronin DC, et al. Long-term venous complications after full-size and segmental pediatric liver transplantation. *Ann Surg*. 2002;236:658–666.
- [210] Shibasaki S, Taniguchi M, Shimamura T, et al. Risk factors for portal vein complications in pediatric living donor liver transplantation. *Clin Transplant*. 2010;24:550–556.
- [211] Kishi Y, Sugawara Y, Matsui Y, Akamatsu N, Makuuchi M. Late onset portal vein thrombosis and its risk factors. *Hepatogastroenterology*. 2008;55:1008–1009.

- [212] Sakamoto S, Nakazawa A, Shigeta T, et al. Devastating outflow obstruction after pediatric split liver transplantation. *Pediatr Transplant*. 2013;17:E25–E28.
- [213] Bertram H, Pfister E-D, Becker T, Schoof S. Transsplenic endovascular therapy of portal vein stenosis and subsequent complete portal vein thrombosis in a 2-year-old child. *J Vasc Interv Radiol*. 2010;21:1760–1764.
- [214] Kamran Hejazi Kenari S, Mirzakhani H, Eslami M, Saidi RF. Current state of the art in management of vascular complications after pediatric liver transplantation. *Pediatr Transplant*. 2015;19(1):18–26. <http://doi.org/10.1111/petr.12407>.
- [215] Feier FH, da Fonseca EA, Seda-Neto J, Chapchap P. Biliary complications after pediatric liver transplantation: risk factors, diagnosis and management. *World J Hepatol*. 2015;7(18):2162–2170. <http://doi.org/10.4254/wjh.v7.i18.2162>.
- [216] Ostroff JW. Management of biliary complications in the liver transplant patient. *Gastroenterol Hepatol (N Y)*. 2010;6:264–272 [PMID: 20567581].
- [217] Gupta S, Castel H, Rao RV, Picard M, Lilly L, Faughnan ME, Pomier-Layrargues G. Improved survival after liver transplantation in patients with hepatopulmonary syndrome. *Am J Transplant*. 2010;10:354–363 [PMID: 19775311, doi:10.1111/j.1600-6143.2009.02822.x].
- [218] Salvalaggio PR, Whittington PF, Alonso EM, Superina RA. Presence of multiple bile ducts in the liver graft increases the incidence of biliary complications in pediatric liver transplantation. *Liver Transplant*. 2005;11:161–166 [PMID: 15666393, doi:10.1002/lt.20288].
- [219] Kling K, Lau H, Colombani P. Biliary complications of living related pediatric liver transplant patients. *Pediatr Transplant*. 2004;8:178–184 [PMID: 15049799, doi:10.1046/j.1399-3046.2003.00127.x].
- [220] Feier FH, Chapchap P, Pugliese R, da Fonseca EA, Carnevale FC, Moreira AM, Zurstrassen C, Santos AC, Miura IK, Baggio V, Porta A, Guimarães T, Cândido H, Benavides M, Godoy A, Leite KM, Porta G, Kondo M, Seda-Neto J. Diagnosis and management of biliary complications in pediatric living donor liver transplant recipients. *Liver Transplant*. 2014;20:882–892 [PMID: 24760734, doi:10.1002/lt.23896].
- [221] Anderson CD, Turmelle YP, Darcy M, Shepherd RW, Weymann A, Nadler M, Guelker S, Chapman WC, Lowell JA. Biliary strictures in pediatric liver transplant recipients—early diagnosis and treatment results in excellent graft outcomes. *Pediatr Transplant*. 2010;14:358–363 [PMID: 20003138, doi:10.1111/j.1399-3046.2009.01246.x].
- [222] Miraglia R, Maruzzelli L, Caruso S, Riva S, Spada M, Luca A, Gridelli B. Percutaneous management of biliary strictures after pediatric liver transplantation. *Cardiovasc Intervent Radiol*. 2008;31:993–998 [PMID: 18574628, doi:10.1007/s00270-008-9378-5].
- [223] Marubashi S, Nagano H, Yamanouchi E, Kobayashi S, Eguchi H, Takeda Y, Tanemura M, Maeda N, Tomoda K, Hikita H, Tsutsui S, Doki Y, Mori M. Salvage cystic duct

anastomosis using a magnetic compression technique for incomplete bile duct reconstruction in living donor liver transplantation. *Liver Transplant*. 2010;16:33–37 [PMID: 20035518, doi:10.1002/lt.21934].

- [224] Muraoka N, Uematsu H, Yamanouchi E, Kinoshita K, Takeda T, Ihara N, Matsunami H, Itoh H. Yamanouchi magnetic compression anastomosis for bilioenteric anastomotic stricture after living-donor liver transplantation. *J Vasc Interv Radiol*. 2005;16:1263–1267 [PMID: 16151070, doi:10.1097/01.RVI.0000173280.56442.9E].
- [225] Wakiya T, Sanada Y, Mizuta K, et al. A comparison of open surgery and endovascular intervention for hepatic artery complications after pediatric liver transplantation. *Transplant Proc*. 2013 45:323–329.
- [226] Funaki B, Rosenblum J D, Leef J A, et al. Percutaneous treatment of portal venous stenosis in children and adolescents with segmental hepatic transplants: long-term results. *Radiology*. 2000;215:147–151.
- [227] Hashikura Y, Kawasaki S, Okumura N, et al. Prevention of hepatic artery thrombosis in pediatric liver transplantation. *Transplantation*. 1995;10:1109–1112.
- [228] Shay R, Taber D, Pilch N, et al. Early aspirin therapy may reduce hepatic artery thrombosis in liver transplantation. *Transplant Proc*. 2013;45:330–334.