

We are IntechOpen, the world's leading publisher of Open Access books Built by scientists, for scientists

6,900

Open access books available

186,000

International authors and editors

200M

Downloads

Our authors are among the

154

Countries delivered to

TOP 1%

most cited scientists

12.2%

Contributors from top 500 universities



WEB OF SCIENCE™

Selection of our books indexed in the Book Citation Index
in Web of Science™ Core Collection (BKCI)

Interested in publishing with us?
Contact book.department@intechopen.com

Numbers displayed above are based on latest data collected.
For more information visit www.intechopen.com



Management of Common Complications in Rhinoplasty and Medical Rhinoplasty

Sebastian Torres and Tito Marianetti

Additional information is available at the end of the chapter

<http://dx.doi.org/10.5772/63130>

Abstract

Rhinoplasty is considered among the most challenging aesthetic operations because many variables have to be taken into consideration to achieve an optimal aesthetic and functional result. This implies that complications are always waiting around the corner. It is of prime importance to know the main minor and major complications related to the procedure to be able to prevent and treat them promptly when required. Septorhinoplasty is a delicate and difficult procedure, which requires accurate anatomical knowledge and important clinical experience. Nevertheless, complications can affect both inexperienced and expert surgeons. Thus, the most frequent complications of rhinoplasty should be known and adequately prevented when possible.

Keywords: Adverse events, rhinoplasty, complications, rhinofiller, Medical Rhinoplasty

1. Introduction

Some post-operative complications are easily treated, whereas others require multiple reconstructive surgeries and sometimes *restituito ad integrum* (a flawless result) is impossible to obtain. Therefore, the best therapy for complications is prevention. The most frequent complications in rhinoplasty are classified according to their nature as traumatic, respiratory, aesthetic, infective or vascular.

2. Traumatic complications

2.1. L-structure or K-area fracture

During septorhinoplasty, whatever approach is used, two fundamental rules must be kept in mind:

1. Respect the Cottle K area, which is anatomically defined as the intersection of the nasal bones, septum and triangular cartilages.
2. Preserve an adequate dorsal-caudal L structure for support.

Damage to these structures causes an inadequate support of the nasal pyramid and with time causes nasal dorsum collapse and dorsum sill deformity spontaneously or after minor trauma. An adequate dorsal-caudal L structure of at least 1 cm is necessary for structural support to prevent this type of complication. The K area should be addressed with extreme care upon dorsal hump removal. Precise subperiosteal dissection is done above the nasal bones with a Joseph dissector. Incremental dorsal hump reduction with a rasp or osteotomes allows for maneuver control and removes the hard tissue while avoiding damage to the triangular cartilages or nasal bones.

Treatment of L-structure fractures of the septum includes the use of robust reconstructive spreader grafts on the dorsal segment and columellar strut grafts on the caudal segment. Septal cartilage grafts are preferred when available; otherwise, conchae or costal cartilage grafts are necessary.

Repair of K-area damage and triangular cartilage detachment from the nasal bones is more complex. If a small residue of cephalic cartilage remains, reattachment of the triangular cartilages is possible with non-resorbable sutures. Otherwise, holes are drilled in the nasal bone to anchor stitches of the triangular cartilages. Permanent surgical sutures (Nylon 4.0) are preferred over Kirchner metal wire, as proposed by other authors, given the fact that the skin is extremely thin in this area and a greater incidence of infection, irregularities and transcutaneous translucency can be expected with the latter technique.

2.2. Dental trauma

Hypoesthesia of the superior central incisors and palatal premaxilla is frequently noted in the post-operative period after septorhinoplasty. This is due to the fact that the incisive nerve, before exiting in the oral cavity through the homonymous canal, lies on the maxillary crest at the base of the nasal septum. This complication frequently arises when septal dislocations close to the anterior nasal spine, nasal septum cartilage resections or anterior nasal spine remodeling procedures are done. Spontaneous resolution of the hypoesthesia is expected for the majority, and sensitivity is reestablished in a variable period between 1 week and 6 months. In the case of abnormal vascular support of superior anterior incisors or long teeth roots, a direct damage to the superior central incisors is possible; this can cause pulpitis or abnormal pigmentation. Prompt dental evaluation and endodontic therapy are advised, if necessary, before intrinsic pigmentation occurs or more complex and expensive prosthetic therapies are needed.

2.3. Intracranial complications

Intracranial complications include rhino-liquoral fistulas and anosmia. **Rhino-liquoral fistulas** are among the major post-rhinoplasty complications.

Given the fact that the superior portion of the septal cartilage is directly abutting the cribriform lamina of the ethmoid and is the direct continuation of this structure, an understanding of why this severe complication is not that uncommon is apparent.

Septoplasty is a delicate phase of the procedure. Very often, surgeons treat the septum aggressively by grabbing the bony portion with Weil forceps and attempting to break or remove the tissue through rotatory movements. Prevention of rhino-liquoral fistulas consists of an accurate and delicate septum dissection, particularly with regard to the superior bone portion. Before pulling a fragment, adequate dissection and freeing is necessary. The clinical symptomatology of rhino-liquoral fistulas includes rhinorrhea and positional cephalus. Diagnosis is confirmed through beta-2 transferrin presence in the fluid, specifically the cerebrospinal fluid.

Such complication requires hospitalization, lumbar drainage positioning by a neurosurgeon and eventual multilayer nasal endoscopic fistula repair.

Anosmia is fortunately very seldom observed due to the damage of the olfactory bulb. Most frequently, this condition is secondary to a persistent respiratory nasal obstructive pathology.

2.4. Orbital complications

Orbital complications related to septorhinoplasty are extremely rare and include blindness and epiphora. Blindness has been reported in some cases and is related to turbinate or nasal dorsum steroid injections. The etiopathogenesis described involves an embolic occlusion of the central retinal artery. Other cases due to vasoconstrictor injections in the septum and turbinates, being the etiology of a spastic response on the central retinal artery, have been described [1–3].

These unfortunate complications are hard to predict and impossible to resolve. For this reason, prevention is done by avoiding steroid infiltration in the turbinates and aspiration prior to injection and injecting a small quantity when treating the dorsum. Epiphora is an extremely rare complication after rhinoplasty. Lateral osteotomies are generally safe if executed in a standard manner. Damage to the lacrimal ducts is possible when the osteotomy direction is incorrect or when motorized instruments or saws are used. It is frequently clinically confused with paralateronasal edema. Spontaneous resolution is often verified, although sporadic cases require dacryocystorhinostomy for complete resolution [4, 5].

3. Respiratory complications

3.1. Internal nasal valve dysfunction

Internal nasal valve dysfunction is a frequent complication secondary to old school destructive rhinoplasty. The principal cause is over-resection of the lateral cartilages during hump

removal. The internal nasal valve angle is formed by the confluence of the nasal septum medially and lateral cartilages externally; its normal value is around 15° [6].

A reduction in this value determines impairment in airway flow. More severe than an excessive resection of the triangular cartilages is scarring in the internal valve area due to transmucosal disjunction of the septum from the triangular cartilages; fortunately, this is an old and discarded technique. Patients with a non-deviated septum are referred for treatment of severe nasal respiratory problems. Moreover, in addition to this severe functional defect, a dorsal inverted V deformity appears after the resolution of the surgical edema due to inferomedial collapse of the triangular cartilages [7].

The remedy for this type of complication is the placement of a spreader graft, whatever the type (auto, mini or classic) and source (septum, concha or rib). The important technical detail is to place the graft so as to raise and reposition the collapsed triangular cartilages and return internal nasal valve function, augmenting the cross-sectional area.

Classic spreader grafts are longitudinal grafts placed in a subperichondrial pocket and fixed to the triangular cartilages and the septum through non-resorbable sutures.

Spreader grafts also allow straightening of a cephalic deviated septum, reconstruction of an open roof deformity or improvement of dorsal aesthetic lines [8].

Auto-spreader grafts are obtained from the triangular cartilages after mucosal dissection and then partially cut and folded medially over themselves; this maneuver is very difficult to perform in secondary cases due to prior over-resection of the cartilages. On the other hand, mini-spreader grafts are obtained from the cephalic portion of the alar cartilages but due to their reduced dimensions are seldom useful for severe reconstruction [9].

3.2. Nasal septal perforation

The etiology of septal perforation is diverse and may be iatrogenic, which is most often the case, due to cocaine abuse, infections, trauma and granulomatous diseases. With subperichondrial septum dissection, caution should be taken not to trespass the mucoperichondrial flaps. It is advisable to start with the easier side to grant integrity in at least one side. When both mucosal flaps are damaged bilaterally, an iatrogenic septal perforation will be produced.

The symptomatology of septal perforation includes crusts, recurrent bleeding, whistling or inspiratory rumors and nasal respiratory obstruction. The more anterior the perforation is, the greater the associated disturbance.

The most ancient solution for the problem was the use of silicone septal buttons, which are less popular among patients nowadays.

Diverse septal perforation repair techniques have been described, with the most effective ones being from Kridel and Castelnovo [10, 11]. Kridel described an open approach for the provision of sliding superior (from the internal nasal valve region) and inferior (from the nasal floor and inferior turbinate) mucoperichondrial flaps. Castelnovo reported an endoscopic approach for an intranasal septal mucosal pedunculated flap to the ethmoidal arteries, which is rotated to obtain defect closure. Both techniques grant a high success rate.

Whatever the case, it is proper to prevent septal perforation and if verified to take time to repair the mucoperichondrial flaps properly. Allotting an additional 10 minutes at the primary surgery is better than performing 3 hours of revision surgery for perforation closure.

3.3. External nasal valve dysfunction

The external nasal valve is an area defined three-dimensionally by the inferior turbinate head, caudal portion of the triangular cartilages, cephalic portion of the alar cartilages and septum. The most common source of post-rhinoplasty dysfunction is related to an excessive resection of lateral crura of the alar cartilages.

This condition is occasionally seen when an attempt to reduce nose tip dimensions is sought at all costs, not leaving enough alar cartilage to support the nasal ala.

Nasal alar collapse can be dynamic if it manifests only during inspiration (forced or not) or static in more severe cases if it is verified at rest. The minimum alar cartilage dimension to preserve varies according to the intrinsic consistency of the cartilage and it is not the same for all patients. Nevertheless, a minimum of 4–5 mm should be kept and old risky, interruptive approaches should be avoided.

Multiple techniques have been described to treat this complication, namely, alar spreader grafts, lateral crura repositioning, alar spanning grafts, barrel roll technique, lateral crura strut grafts and alar batten grafts. Alar batten grafts are the most frequently used, but every case should be analyzed individually and treated accordingly with the most indicated technique [12].

External nasal valve compromise is also verified after maneuvers that cause narinal stenosis. This condition is seen, for example, when a sloppy adaptation of the vestibular skin occurs after rhinoplasty due to a lack of closing sutures in the area, infection or abnormal scarring. Another cause is represented by excessive alar base wedge resection.

Corrections in these cases are complex and foresee the use of local flaps and Z-plasties, but in the majority of cases, auricular composite grafts are necessary to replenish the lack of previously excised tissue.

Residual anterior septal deviations and turbinate hypertrophy can cause external nasal valve dysfunction. Residual anterior septal deviations require surgical revision with a more precise septoplasty. Inferior turbinate hypertrophy is very frequent, especially in allergic patients. In these cases, medical therapy is advised with local steroids and systemic antihistamines, discouraging continuous surgical retouching [13].

Turbinoseptal synechiae (adherences) can also produce external nasal valve stenosis, although they can appear even more posteriorly in the nasal fossae. Silicone splints should be used and kept in place long enough to allow re-epithelization of the turbinate and septum to prevent turbinoseptal synechiae when mucosal lacerations occur.

3.4. Sinusitis

Sinusitis is rare as a post-rhinoplasty complication, but it can become apparent if unrecognized predisposing conditions are present.

The medial meatus protected by the middle turbinate represents the common drainage path for the ducts of paranasal sinuses. Ethmoidal anterior, frontal and maxillary sinuses all drain at this level.

Medial turbinate lateralization maneuvers are extremely dangerous as they may cause rhinoliquoral fistulas and compromise normal paranasal sinus function.

If predisposing conditions are present, the presence of concha bullosa may predispose a patient to post-rhinoplasty sinusitis. It is advisable to assess pre-operative nasal and paranasal sinus CT scans that will give valuable information regarding septal deviation and turbinate hypertrophy and identify sinus alterations suitable to be treated during the surgery through functional endoscopic sinus surgery (FESS) to avoid this complication.

4. Aesthetic complications

4.1. Supratip deformity (polly beak)

Post-operative deformity of the supratip nasal area that assumes a convex shape in relation to the nasal dorsum can have two sources: cartilaginous tissue or scar tissue. Cartilaginous polly beaks are caused by an insufficient resection of the inferior third of the dorsal septum in proximity to the septal angle. Scar tissue polly beaks, on the other hand, are more frequent in cases with sebaceous skin and are due to hypertrophic scarring of the subcutaneous tissue of the supratip region.

Prevention of cartilaginous supratips relies on meticulous assessment of an adequate relation between the dorsum and nasal tip. Normally, the distance between the level of tip-defining points and septal angle is about 6–8 mm, but it is based on the surgeon's experience to define the magnitude [14].

Supratip scarring is more difficult to prevent. Supratip empty spaces that may fill with blood and further scar tissue should be avoided.

Compressive bandaging of the supratip area for 4–5 weeks is of prime importance to reduce the dead space and prevent polly beak deformity from scarring.

The remedy for supratip scarring is based on local steroid injections; they are very effective if done properly with regard to timing and modality. Triamcinolone acetonide (Kenacort, 40 mg/ml injectable suspension) is the steroid of choice. Dosage should be triamcinolone 1–2 mg applied early (2–3 weeks after the surgery) if a tendency for supratip deformity is perceived and not repeated before a 2-month interval. The effect of the therapy is seen in the following 2 months post injection. The injections should be in a deep plane and never intradermal.

Superficial injection causes cutaneous atrophy, telangiectasia, depressions, color modifications and underlying cartilage visibility [15].

Cartilaginous supratips and non-responders with scar-based supratips are treated with revision surgery. An in-depth analysis of tip-dorsum relation and the use of tip-defining grafts (onlays and shields) are useful to avoid recidivism.

4.2. Dorsal irregularities

The nasal dorsum is the region more prone to unexpected and unwanted surprises after a rhinoplasty. It is very difficult for the surgeon to ensure that no dorsum unevenness remains at the end of surgery and that the end result is smooth and with no imperfections in the majority. Nevertheless, months or years after the surgery, it is difficult to find an operated nose that does not show some dorsal irregularities at least upon palpation. The reason for this is that surgical edema will hide small irregularities and mask an adequate palpation evaluation of dorsum smoothness. With time, as nasal tissue swelling disappears, irregularities start to show [16].

Dorsal deformities are among the most common causes of revision rhinoplasty. They are mostly due to excessive or inadequate hump removal, remnant fragments after removal, asymmetric resections, inadequate graft modeling or fixation and dislocation.

Open rhinoplasty can reduce the frequency of these imperfections as it allows for direct vision of the dorsum. Another tip to reduce the percentage of these complications is to perform dorsal index palpation with the surgical gloves wetted with normal saline, augmenting sensitivity for the surgeon. Profuse cleansing and washing of the dorsal area under the skin envelope before suturing is imperative as it eliminates small cartilage residues and bony fragments, avoiding future irregularities.

Avoiding dorsal irregularities in patients with thin skin is still very difficult. In these cases, it may be advisable to use dorsal augmenting materials. These can be autologous (temporal fascia, perichondrium graft), heterologous (equine or bovine pericardium membranes) or alloplastic (Gore-Tex). Autologous materials are preferable due to the lower incidence of infections associated with them; however, at the dorsum level, the risk of infection or extrusion is very small even for non-autologous materials [17].

4.3. Tip deviations and irregularities

Tip deviations and irregularities are among the most common causes of revision rhinoplasty and are more prevalent in the closed approach. They include depressions, irregularities, asymmetries and lateral crura collapse. They can appear due to faulty techniques, excessive or asymmetric lateral crura resections, incorrect graft positioning or scarring [18, 19].

Another particularly anti-aesthetic condition is an altered tip projection, either hyperprojection or hypoprojection. Nose tip deformities often manifest a long time after the surgery (1 or 2 years after). In fact, the nose tip is the last region to swell down in the post-operative period.

Prevention of this complication relies on knowledge of tip supportive mechanics and the tripod theory as well as attention to avoid disruptive or destructive techniques. Nevertheless, the most important factors are still expertise and respecting aesthetic proportions that will grant good results in the long term. Revision rhinoplasty is surely easier and predictable if done via an open approach, but this also depends on the skills and experience of the surgeon [20].

4.4. Skin necrosis

Nasal skin necrosis is among the worst complications that can occur during a septorhinoplasty. It is mainly caused by vascular damage in the vessels that supply the nose tip. Rarely, it can present due to excessive dressing compression. Most frequently, it appears after damage in the lateral nasal arteries due to an incorrect plane of dissection or following excessive nose tip fat tissue reduction, in an attempt to reduce its size.

A new source of skin necrosis of increasing prevalence is the post-operative use of dermal fillers at the nasal pyramid, nasolabial folds or paranasal region to camouflage irregularities. This outcome is more frequently verified when the filler is delivered with needles that may cause direct vessel damage and intravascular occlusion or indirect vascular compression, jeopardizing tip vascularity.

Some rules should be respected to prevent this complication:

1. Avoid injecting fillers with sharp needles (preferably blunt tip cannulas) in paranasal areas.
2. Dissect the nasal tissues attached to the cartilaginous framework without getting superficial.
3. Avoid defatting techniques of the nose tip or reduce it to a minimum.
4. Avoid firm and tight dressings, especially in revision cases.
5. Limit alar wedge resections under the alar crease.

Treatment of skin necrosis is very complex and ranges from conservative approaches (such as second-intention wound healing) to complex reconstruction procedures with local, regional or free flaps. Whatever the approach, skin tropism and elasticity are a primary goal before intending more complex repair. The latter procedure can be achieved through platelet-rich plasma and micro-lipofilling sessions.

5. Infective complications

Rhinoplasty infections are not frequent, probably due to the natural protective mechanisms of the nasal mucosa. Nevertheless, the myriad of infective cases can be very vast and go from small subcutaneous cellulitis due to infected sutures to severe cavernous sinus thrombosis.

Local skin or mucosal infections are treated with local and systemic antibiotics. Abscesses may affect the dorsum, tip or septum, with septal abscess being the most dangerous, and they

should be promptly drained; septal abscess can appear from an undiagnosed septal hematoma that can evolve to a septal perforation if not treated promptly.

High fever, meningeal signs, nausea, vomiting and hypotension are suggestive signs of a severe infection, such as cavernous sinus thrombosis. If the diagnosis is suspected, nasal tampons should be removed immediately (especially if placed several days before) and secretions should be sent for cultural and bacteriological analysis, with the most frequent germ involved being *Staphylococcus aureus*. Patients should be hospitalized and systemic antibiotics should be initiated promptly.

Prophylactic antibiotics in rhinoplasty are a controversial topic but nonetheless highly indicated by the majority of surgeons.

6. Vascular complications

Vascular complications include septal hematoma and epistaxis.

6.1. Septal hematoma

Septal hematoma can occur secondary to trauma or surgery and is a serious complication. Its symptomatology includes nasal obstruction, pain and, occasionally, fever. Anterior rhinoscopy reveals a septal mass that occludes one or both nasal fossae. Immediate therapy is indicated and consists of hematoma drainage, nasal tampons to impede recidivism and proper antibiotic therapy to avoid abscess transformation.

Septal abscesses can evolve to mucosal and/or cartilage necrosis and septal perforation varying in dimension and location according to the underlying infection [21].

6.2. Epistaxis

Bleeding in rhinoplasty patients post-operatively is normal if limited, whereas it can become a complication if profuse or continuous. The condition is more frequent in at-risk patients on anticoagulants or platelet anti-aggregating agents. In these cases, prior consultation with a hematologist and a cardiologist is advisable, and oral clot-altering drugs should be discontinued and subcutaneous LMW heparin initiated several days before the surgery. All patients should be advised to discontinue NSAID or aspirin intake at least 2 weeks prior to operation.

A precise and delicate technique during surgery is desirable to avoid vascular problems. During septoplasty, for example, it is important to avoid mucosal flap lacerations to minimize bleeding. A nasal septum mattress suture can be useful to prevent bleeding and septal hematoma. Turbinate cautery should be gentle. An open technique allows for direct vision and hemostasis of bleeding vessels during the procedure. Epistaxis therapy includes 60° head elevation, nasal packing and gentle nares pressure for 10–15 minutes. Severe epistaxis can require an emergency endoscopic procedure to coagulate the sphenopalatine septal and lateral branches.

7. Medical rhinoplasty

Medical rhinoplasty was first described by Braccini and Dohan Ehrenfest [22] in 2008. The concept, although highly polemical and refused by rhinoplasty surgeons at its onset, developed popularity among aesthetic patients due to its minimally invasive characteristics, with minimal or no downtime and pleasing aesthetic improvements.

The term *medical rhinoplasty* (particularly, *rhinofiller*) is defined as the application of dermal fillers in the external or internal nasal area to modify or improve aesthetics or functionality. It is especially suitable for patients with minor aesthetic or functional concerns that are refractory to surgery [23–26]. It may be combined with the use of botulinum toxin injections around the nose to enhance the results. The procedure is currently a frequent request in aesthetic practice, and many physicians perform it systematically. Nevertheless, it should be considered that it is an advanced technique and should only be attempted by expert practitioners due to the potential for devastating vascular complications [27]. Local anatomical knowledge and advanced technical skills are required to achieve successful and safe corrections.

7.1. Rhinofiller

Rhinofiller specifically involves the infiltration of a dermal filler to modify external or internal nasal structures for aesthetic or functional purposes. Since its introduction in 2008, many temporary and permanent substances have been used to achieve the desired corrections. Successful application mandates adequate anatomical knowledge of the related structures.

Proper patient selection is important to achieve good results. Exclusion criteria include severe nasal airway impairment, permanent filler in the area, history of ischemic/thrombotic events or known hypercoagulability, local infection and recent trauma.

Before the procedure, nasal analysis should be performed clinically and photographically to define needed corrections.

Areas of potential correction include dorsal aesthetic lines, the dorsum, minor hump camouflage, radix enhancement, tip rotation and projection and base augmentation. Details are shown in **Figure 11**.

Functionally, in selected cases, the use of fillers can be useful to augment the aperture of the internal nasal valve as a volumetric spreader graft.

Morphing simulations are advisable before treatment in order to give patients an indication of the post-treatment outcomes, explain the procedure and establish common goals. In addition, specific, informed consent should be properly discussed and obtained.

7.1.1. Technique

Treatments are typically performed with medium-viscosity hyaluronic acid (HA) fillers under local anesthetic (lidocaine intradermal vesicles applied using a 0.3 ml syringe with a 32G needle) with the aid of a 25G (0.5 mm) × 4 cm blunt-tip disposable cannula, manually bent,

maintaining sterility at all times, in order to obtain better compliance of the shapes and silhouette within the nasal area. The distribution of material should be performed as required to follow the treatment plan. Tip refinements can be sporadically carried out through needle infiltration with extreme care.

The specific pattern of anesthetic peripheral blocks and filler infiltration is shown in **Figure 12**.

Generally, the patient satisfaction rate with this correction is very high and, due to the scarce muscular activity in the nose, corrections with Hyaluronic acid dermal fillers last more than 1 year and in many cases even 2 years. A clinical case of rhinofiller is described in **Figures 13 and 14**.

8. Discussion

The nasal area is composed of different interacting tissues, such as the skin, subcutaneous tissue, muscle, bone, cartilage and mucosa, which come together to form a normal, functional and aesthetically pleasing nose. To make things more complicated, there is also a vascular anatomy formed by two main circuits, namely, the supratrochlear and dorsal arteries and the facial circuit that includes the superior labial and angular arteries, all of which are anastomosed in the tip. This has been the subject of recent interest and study because it is believed that a proper technique and anatomical knowledge are of prime importance in order to avoid vascular complications [28–30]. Facial vascular complications were first described in 1991 after collagen injections in the glabellar area [31]. The reported incidence of Nicolau syndrome or embolia cutis medicamentosa (ECM) following glabellar treatments is 9/10,000 procedures (0.09%). The known risk factors associated with this catastrophic event are a high syringe piston pressure, a highly vascularized territory and previously traumatized tissue. The first of these factors can be mitigated using fluid materials of low viscosity. Unfortunately, the entire facial region, especially the nasal area, is considered highly vascularized and many reports of paranasal vascular complications, which vary from mild symptoms of pain and skin color changes to necrosis and even bilateral blindness, have been published [32–41]. The pathophysiology of ECM is an intravascular injection that advances in a retrograde mode to a distant area and, through changes in blood pressure, arrives at a distant vessel and causes a vascular complication. The resulting symptoms vary according to the physiology of the vessel that is compromised; affliction of arteries leads to pallor, whereas occlusion of veins manifests as livedo reticularis. According to the author's experience, there is a second mechanism of vascular compromise in the nose known as *compartmental syndrome*. Due to the low elasticity of the nasal skin (especially after surgical rhinoplasty), there is a chance of producing indirect vascular compromise due to mechanical obstruction when large amounts of filler are positioned, even in the absence of intravascular injection. The former, together with the altered anatomy and possible iatrogenic vascular damage, makes these corrections particularly tricky in this patient setting. Vascular complications can range from mild to severe and therefore prompt recognition and treatment are crucial. Oral aspirin, nitrate cream 2%, heat, massages and intralesional hyaluronidase have all been proven to be beneficial. The author has also used

intralesional heparin mesotherapy with good results (unpublished observations). In severe, unresponsive cases, prostaglandin E₁ (alprostadil) treatment can sometimes limit the extent of the damage. For the remaining scar tissue, occasionally complex reconstruction procedures are necessary [42, 43], although the recent use of stem cells has shown promising results [44]. All of the above have determined nasal augmentation with dermal fillers to be particularly challenging, and mastery of the correct technique is of utmost importance in order to achieve good results and reduce the incidence of adverse reactions. Important factors to consider include the following:

- **Patient selection:** Proper patient selection is vital in order to achieve a good outcome. Rule out individuals with unrealistic expectations and treat post-rhinoplasty patients with extreme care.
- **Materials:** A good technique begins with selection of the correct materials. Only temporary or autologous materials (fat) should be used in the nose. Among temporary materials, HA is the best option because it causes no fibrotic changes in the subcutaneous tissue, such as those that can occur with calcium hydroxyapatite. Moderate-viscosity HA is preferred due to the lower piston pressure in the syringe associated with it.
- **Correct amount of material:** Never exceed the correct quantity of filler used in the nose. It is always better to undercorrect and then repeat as needed. A good safety measure is to stay within 1 ml of filler per session. Remember that the pressure of the material can induce vascular problems even without being intravascular. Place the fingers to position and maintain the product in the target area to avoid migration. Small amounts of material should be placed using low infiltrative pressure and few passes in a retrograde infiltration fashion.
- **Cryotherapy:** It is always wise to favor vasoconstriction in order to limit bruising and edema and reduce intravascular compromise.
- **Cannula, manually curved:** The use of atraumatic cannulas permits gentle dissection of the tissues, reduces the trauma and risks of intravascular injection and delivers the material through a laminar flux that guarantees evenness. The manually curved feature allows for perfect shape compatibility with the nasal dorsum. The use of local anesthetic vesicles and needle skin penetration prior to cannula entry limits pain, trauma and vascular compromise.
- **Needles:** Extreme caution should be used when injecting with needles around the nose; their use should be limited to retouches or refinements and only by very experienced physicians. Perform tunnels (visible entry and exit points created with the needle being used) and allow material to exit if needed. The most risky areas are the tip, glabella, canine fossa and columellar base. Avoid bolus techniques in these regions and inject only when *coming out*. It is preferable to use medium-sized needles and inject into the deep or intermediate plane. Prior aspiration is not useful.
- **Improve; do not attempt a perfect outcome:** This technique should be considered part of the armamentarium of every aesthetic surgeon but not used as a single instrument. Whenever we want to completely correct a surgical deformity with fillers, we get into possible complications.

- **Planning and discussion of potential complications:** It is essential to obtain proper informed consent. Frequently, patients are ill-informed about this procedure and have often read that it is extremely easy and free of risks. Establish a good relationship based on truth and trust with your patient. Morphing software can be of great help in this phase to help communicate with patients and establish common goals; underpromise and overdeliver.
- **Analyze the columellar labial angle:** Analysis of this feature allows for objectivity of the outcome and even the most critical patients will be able to appreciate the improvement.
- **Available kit for potential ECM:** If you intend to treat the nose with dermal fillers, you should be prepared to handle the complications as well.

9. Conclusions

The use of dermal fillers around the nose, although an advanced technique with potentially severe adverse events, is a powerful tool that can be used with a great deal of satisfaction and safety for the benefit of patients who wish to achieve aesthetic or functional improvements without a surgical procedure. The risks and benefits should always be considered and discussed, and complications should be prevented and promptly treated if necessary.

9.1. Nasal botulinum toxin

The onset of the neurotoxin in aesthetics revolutionized the treatment of dynamic facial dynamic wrinkles, producing a reversible paralysis that allows overlying tissues to relax and aesthetically to be flattened and raised. The use of botulinum toxin around the nose differs from the typically recommended indications of the superior facial third, being considered an advanced and off-label technique.

The use of botulinum toxin in the nose is useful in hypermotile noses that typically move with mimic expression. The complications related to this technique are not as severe as those associated with the use of rhinofiller as they are reversible and do not affect nose vascularity. Complications include pain, bruising, swelling, asymmetries, short-lasting effect and resistance. The duration of the corrections is limited (3–4 months) and action takes 2–10 days to establish, but it may enhance the results obtained with a rhinofiller as it removes muscular action and tension over the nasal region. Deep punctures at a muscular level are necessary.

The following muscles suitable for treatment around the nose are as follows:

- The **nasalis transverse muscle** is responsible for the wrinkling in the radix paranasal region known as *bunny lines*. Treatment typically requires 1–2 U per side 1 mm above the angular vessels at the lateral aspect of the radix.
- The **levator anguli oris alaeque nasi muscle** is responsible for gummy smiles. Treatment requires 2–5 U per side at the intersection of the nasolabial fold and the alar region.
- The **depressor septi nasi muscle** is responsible for hypermotile nose tips and an acute columellar labial angle. Treatment requires 1–2 U at the base of the columella.

- The **alar nasalis muscle** acts together with the depressor septi nasi muscle to lower the tip projection and restrict the nasal aperture. Treatment requires 1–2 U per side at the midpoint of the alar area.

A summary of these muscles and their corresponding treatment doses is given in **Figures 15**.

10. Clinical case patients

10.1. Clinical case patient 1

A 28-year-old female patient who previously underwent destructive septorhinoplasty with excessive resection of the alar and triangular cartilages presented to us with an inverted V deformity, right nasal alar collapse, tip asymmetry and a deformed dorsum sill.

Revision rhinoplasty was done using an open approach and harvesting right concha cartilage grafts. Tip de-projection, right lateral reconstruction and bilateral spreader graft positioning were performed (**Figures 1–4**).

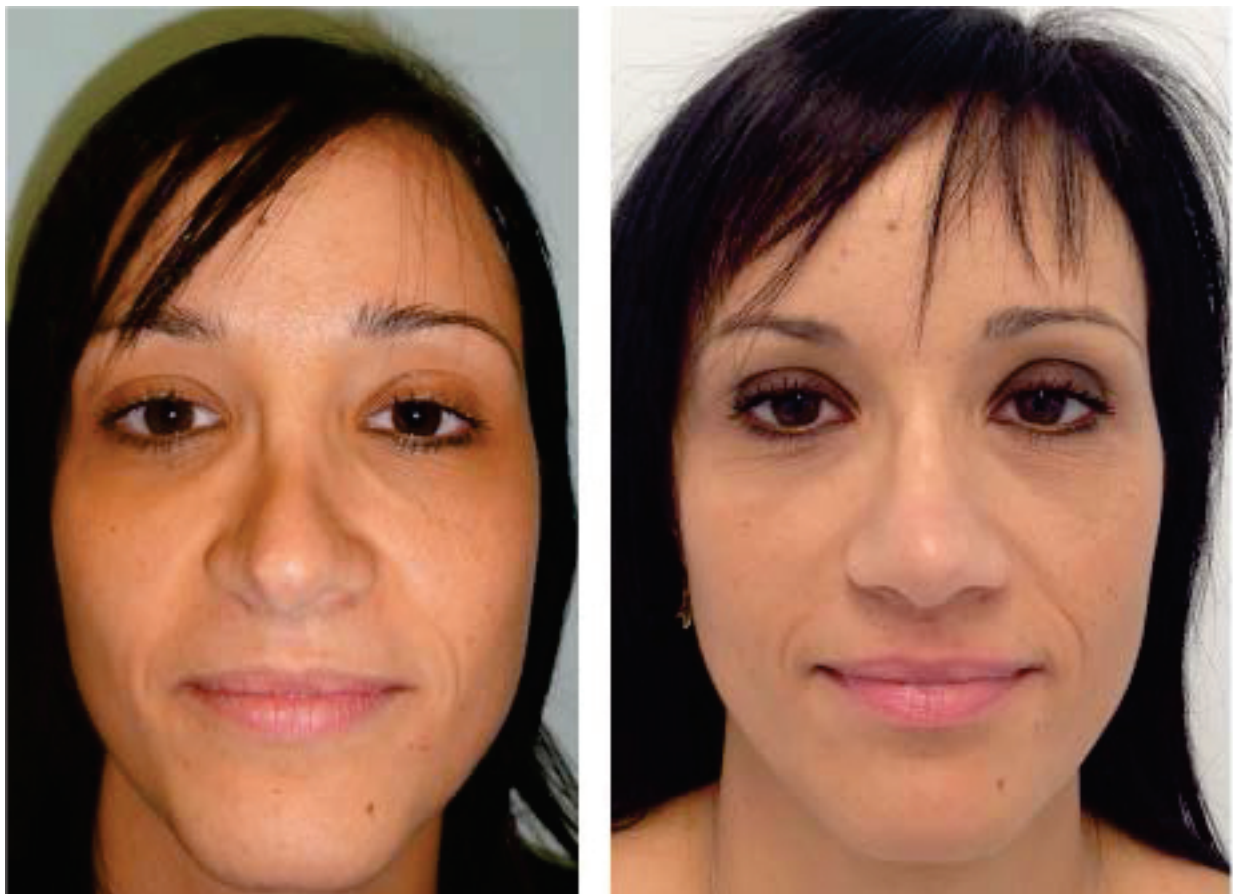

Figure 1. Clinical case 1: Before (right) and after (left) images.

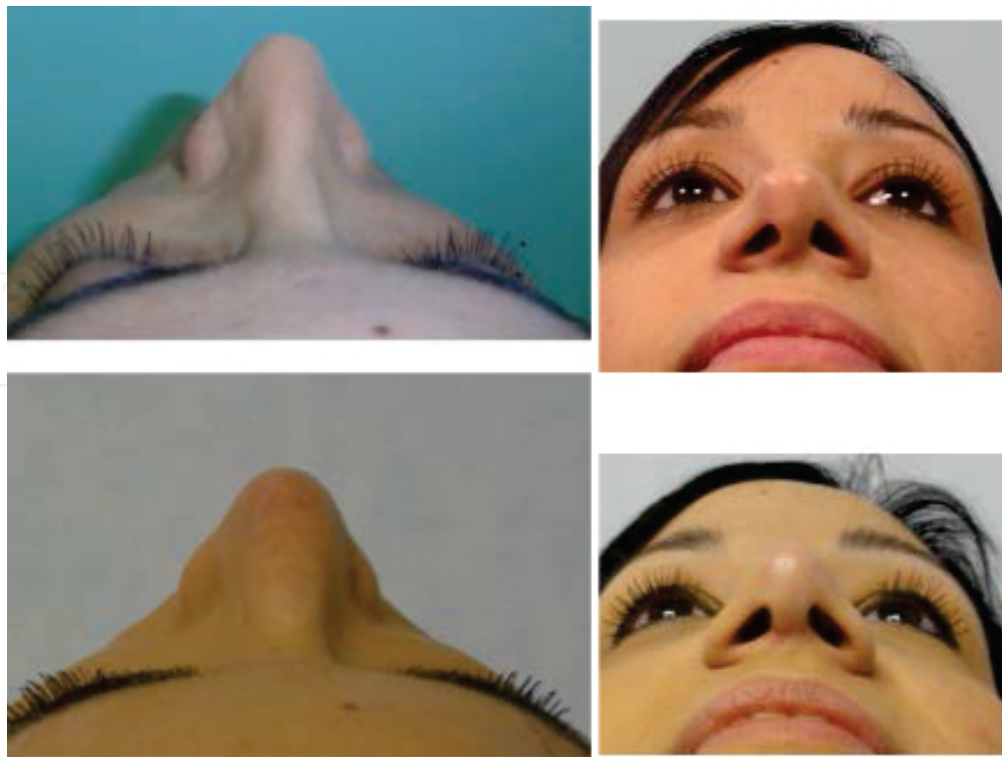


Figure 2. Clinical case 1: Before (upper) and after (below) images.

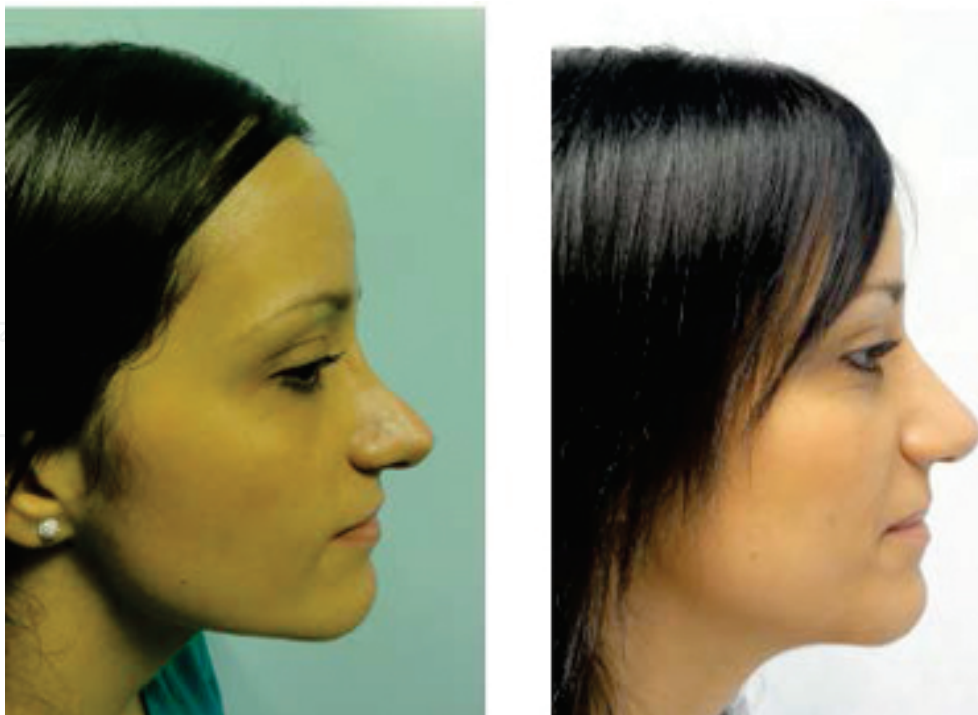

Figure 3. Clinical case 1: Before (left) and after (right) images, lateral view.

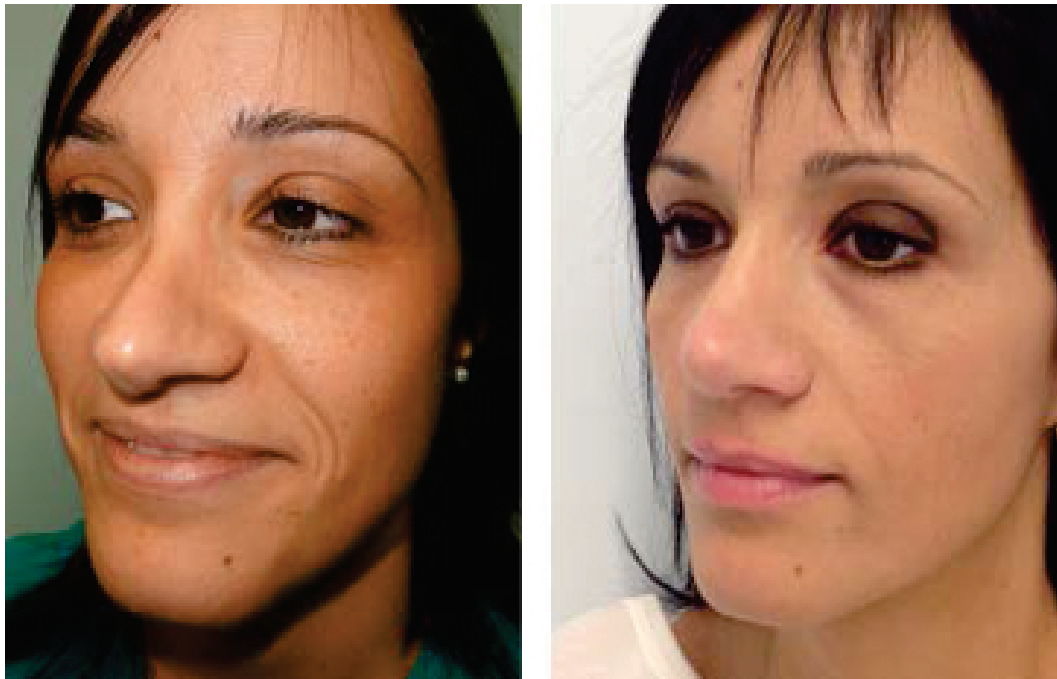

Figure 4. Clinical case 1: Before (left) and after (right) images, oblique view.

10.2. Clinical case patient 2

A 42-year-old female patient who previously underwent septorhinoplasty presented to us with dorsal irregularity, tip asymmetry and a 3 cm diameter anterior septal perforation.

Reconstructive procedure was performed using an open approach and the Kridel septal perforation closure technique. Regularization of the dorsum and tip symmetrization was done (Figures 5–8).

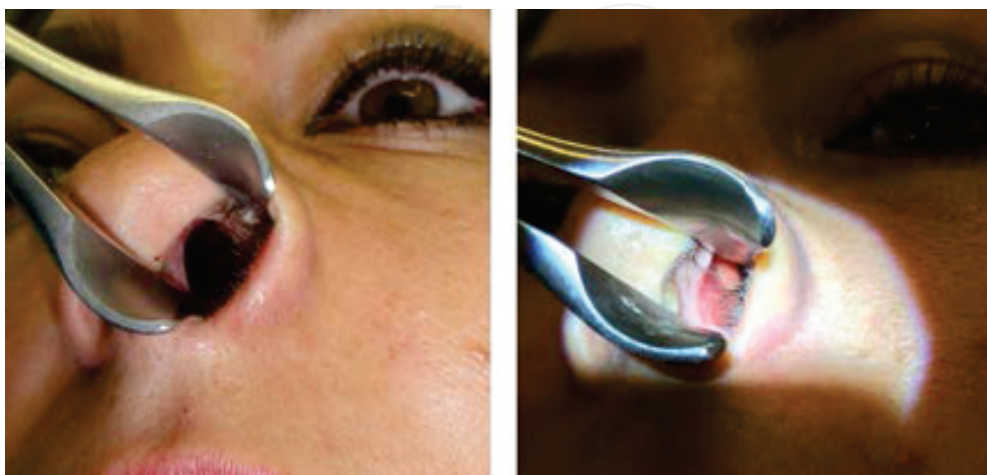

Figure 5. Clinical case 2: Septal perforation.

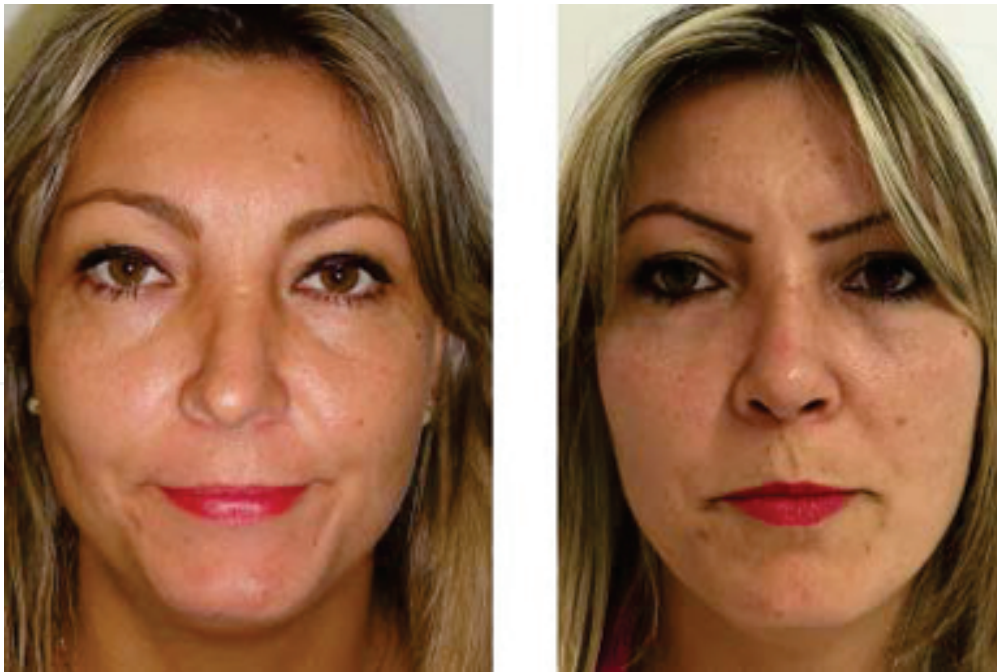

Figure 6. Clinical case 2: Before (right) and after (left) images.

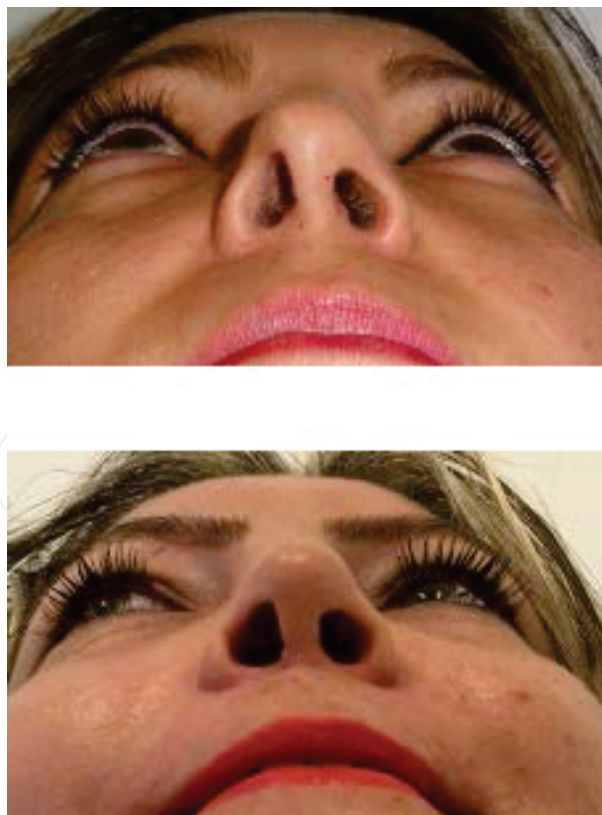

Figure 7. Clinical case 2: Before (upper) and after (lower) images, basal view.

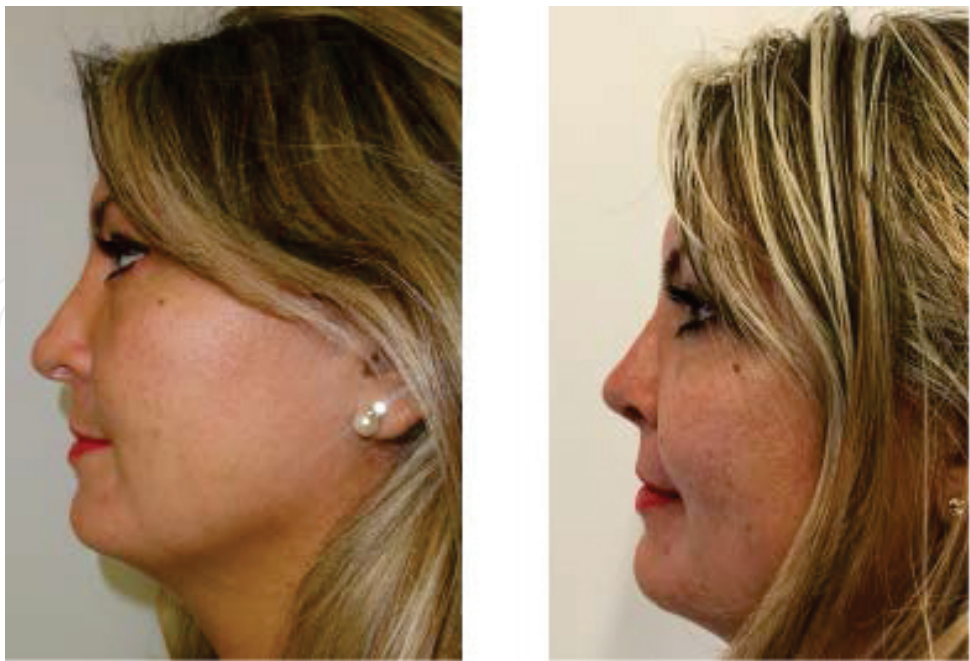

Figure 8. Clinical case 2: Before (right) and after (left) images, lateral view.

10.3. Clinical case patient 3

We also report the case of nasal lipofilling for iatrogenic skin necrosis post-rhinoplasty and filler use in a 22-year-old female patient who previously underwent open rhinoplasty and received several steroids and filler (HA) treatments in the post-operative period until the nose tip, alar cartilages, caudal septum and anterior nasal spine vascularity were jeopardized. The patient was referred with severe scarring and low skin elasticity. She refused reconstruction with a forehead flap. Our treatment plan was initiated with PRP mesotherapy to the nasal region through a dermic pen device. Successive nasal micro-lipofilling sessions (×4) enhanced with a 20% mix of PRP significantly improved skin quality and elasticity for further reconstructive steps (**Figure 9**).

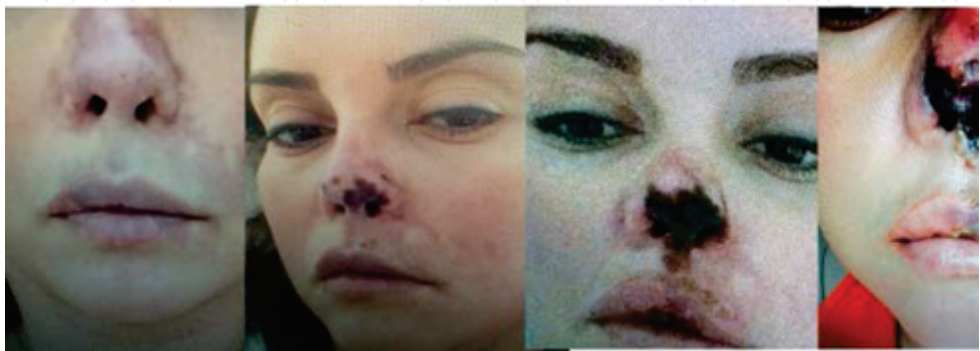

Figure 9. Clinical case 3: Dramatic ischemic progression due to fillers and steroid injections post-rhinoplasty courtesy of Dr Sebastian Torres.

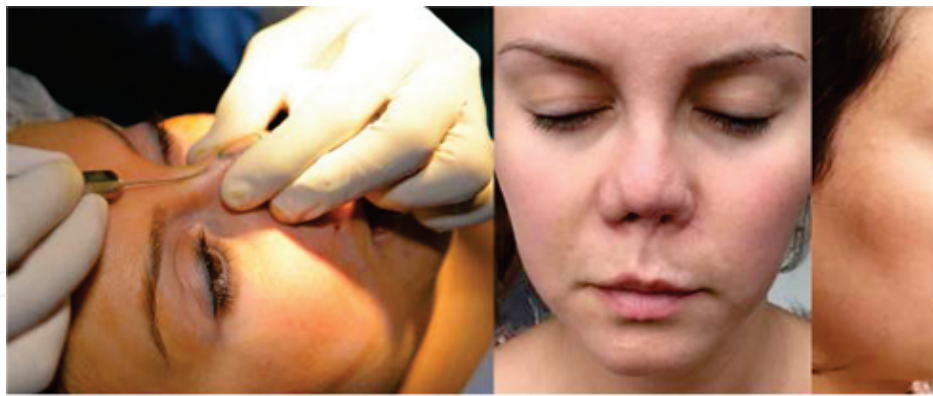

Figure 10. Clinical case 3: Micro-lipofilling technique (left) and post-operative (12 months) reconstructive procedures (center and right) courtesy of Dr Sebastian Torres.

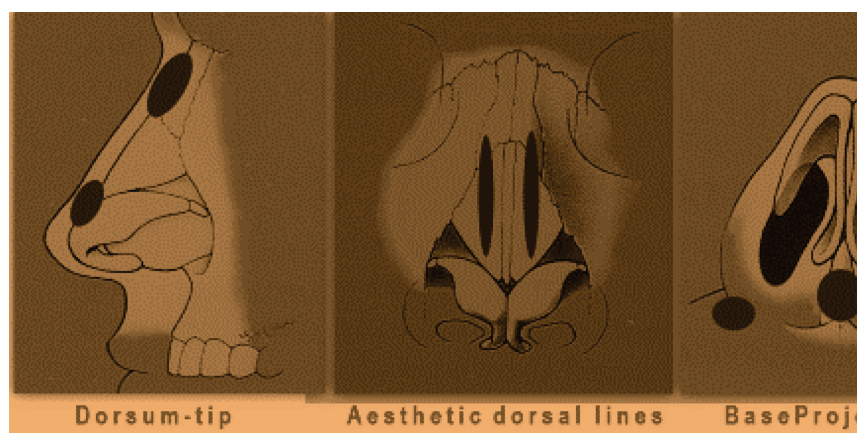


Figure 11. Rhinofiller main treatment areas.

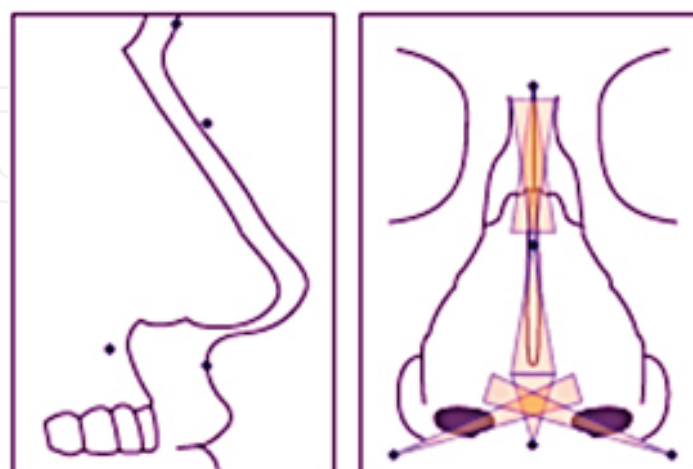
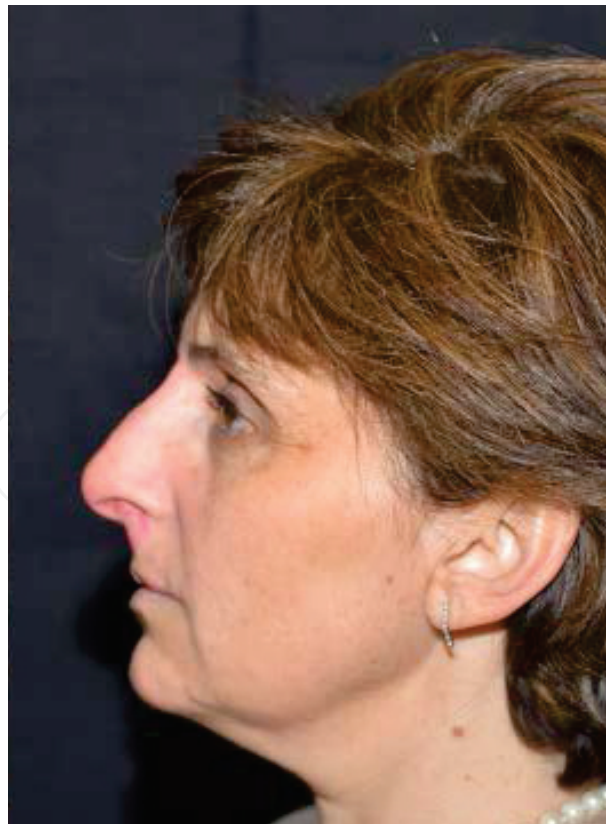
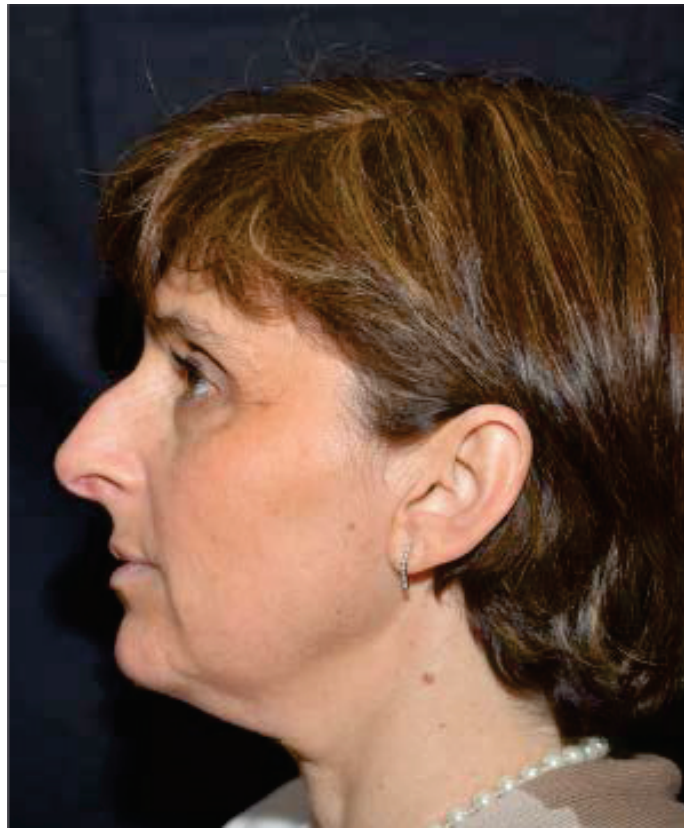
Figure 12. Rhinofiller injection technique. Spots indicate the entry point for cannula; orange triangles indicate material distribution.



Figures 13-14. Rhinofiller pre-operative (upper) and post-operative (lower) immediate results, lateral view.

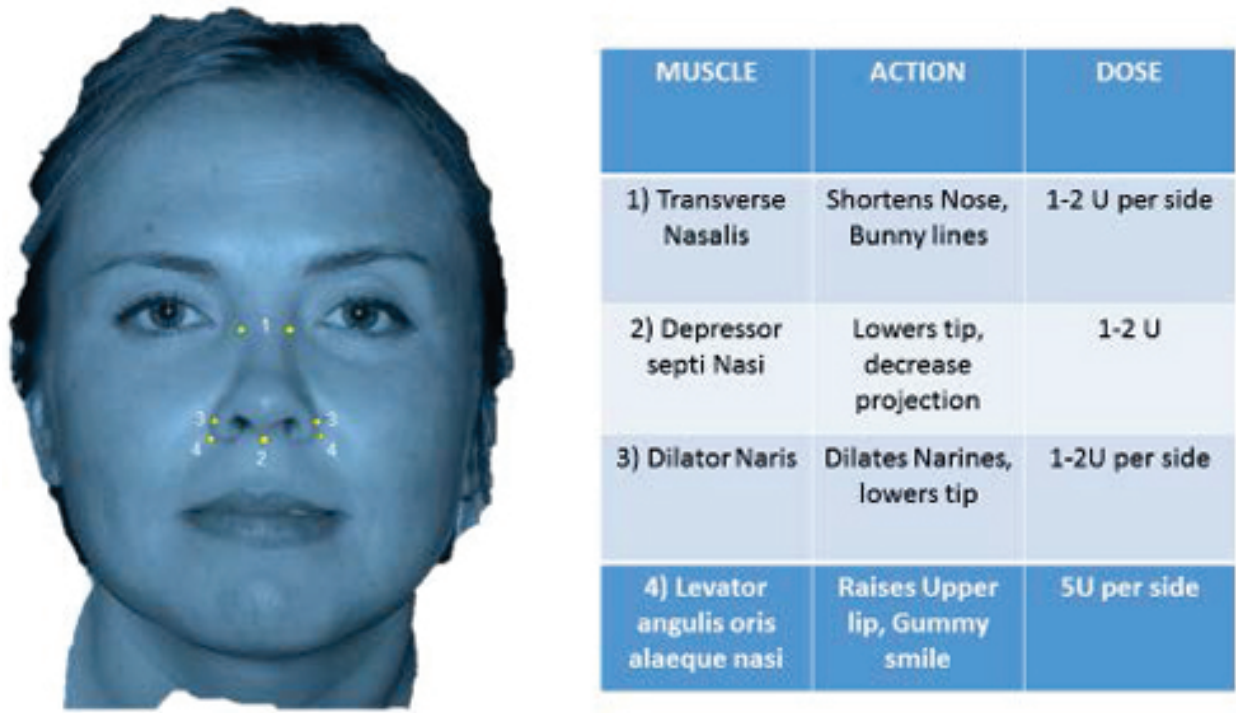


Figure 15. Summary of paranasal muscles and botulinum toxin doses.

Author details

Sebastian Torres^{1*} and Tito Marianetti²

*Address all correspondence to: storres100@gmail.com

1 Plastic and Maxillofacial Surgery, Private Practice, Rome, Italy

2 Consultant in Maxillofacial Surgery, Private practice, Rome, Italy

References

- [1] Rees TD. Aesthetic Plastic Surgery. Philadelphia, PA: WB Saunders; 1980.
- [2] Paun SH, Nolst Trenité G. Revision rhinoplasty: an overview of deformities and techniques. Facial Plast Surg 2008; 24 (3):271–287.
- [3] Adamson PA. The failed rhinoplasty. In: Current Therapy in Otolaryngology Head and Neck Surgery. Toronto, ON: BC Decker; 1990: 137–44.

- [4] Romo THH, Sonne J, Choe KS, Sclafani AP. Revision rhinoplasty. *Facial Plast Surg* 2003; 19: 299–307.
- [5] Rod J. Rohrich, William P. Adams, Jamil Ahmad, Jack Gunter. *Dallas Rhinoplasty: Nasal Surgery by the Masters*, Third Edition. Dallas, TX , USA; 2014. CRC Press.
- [6] Sheen JH. Spreader graft: a method of reconstructing the roof of the middle nasal vault following rhinoplasty. *Facial Plast Surg* 1984; 73: 230–239.
- [7] Bocchieri A, Pascali M. Septal crossbar graft for the correction of the crooked nose. *Plast Reconstr Surg* 2003; 11: 629–638.
- [8] Toriumi DM. Structure approach in rhinoplasty. *Facial Plast Surg Clin North Am* 2005; 13: 93–113.
- [9] Sheen JH. Secondary rhinoplasty. *Plast Reconstr Surg* 1975; 56 (2): 137–145.
- [10] Kridel RW. Septal perforation repair. *Otolaryngol Clin North Am* 1999; 32 (4): 695–724.
- [11] Castelnuovo P, Ferrelli F, Khodaei I, Palma P. Anterior ethmoidal artery septal flap for the management of septal perforation. *Arch Facial Plast Surg* 2011; 13 (6): 411–414.
- [12] Toriumi DM, Josen J, Weinberger M, Tardy ME Jr. Use of alar batten grafts for correction of nasal valve collapse. *Arch Otolaryngol Head Neck Surg* 1997; 123: 802–808.
- [13] Kridel RW, Soliemanzadeh P. Tip grafts in revision rhinoplasty. *Facial Plast Surg Clin North Am* 2006; 14: 331–341.
- [14] Peck GC. The onlay graft for nasal tip projection. *Plast Reconstr Surg* 1983; 71 (1): 27–39.
- [15] Peer LA. Cartilage grafting. *Br J Plast Surg* 1954; 7(3): 250–262.
- [16] Bocchieri A. Subtotal reconstruction of the nasal septum using a conchal reshaped graft. *Ann Plast Surg* 2004; 53(2): 118–125.
- [17] Bocchieri A, Macro C. Septal considerations in revision rhinoplasty. *Facial Plast Surg Clin North Am* 2006; 14: 357–371.
- [18] Soliemanzadeh P, Kridel RW. Nasal tip overprojection: algorithm of surgical deprojection techniques and introduction of medial crural overlay. *Arch Facial Plast Surg* 2005; 7(6): 374–380.
- [19] Kridel RWH. Dome truncation for management of the overprojected nasal tip. *Ann Plast Surg* 1990; 24 (5):385–396.
- [20] Kridel RW, Chiu RJ. The management of alar columellar disproportion in revision rhinoplasty. *Facial Plast Surg Clin North Am* 2006; 14: 313–329.
- [21] Fomon S, Bell JW, Berger EL, Goldman IB, Neivert H, Schattner A. New approach to ventral deflections of the nasal septum. *AMA Arch Otolaryngol* 1951; 54 (4): 357–366.

- [22] Braccini F, Dohan Ehrenfest DM. [Medical rhinoplasty: rational for atraumatic nasal modelling using botulinum toxin and fillers]. *Rev Laryngol Oto Rhinol (Bord)*. 2008;129(4–5):233–238.
- [23] Kurkjian TJ et al. Soft-tissue fillers in rhinoplasty. *Plast Reconstr Surg*. 2014;133(2):121e–126e. 3.
- [24] Wang YF et al. A woman's secret. Filler rhinoplasty with Radiesse (Merz Aesthetics, San Mateo, CA) and gold thread implantation. *Ann Emerg Med*. 2013;62(3):224, 234.
- [25] Jasin ME. Nonsurgical rhinoplasty using dermal fillers. *Facial Plast Surg Clin North Am*. 2013;21(2):241–252.
- [26] Humphrey CD et al. Soft tissue fillers in the nose. *Aesthet Surg J*. 2009;29(6): 477–484.
- [27] Rivkin A. A prospective study of non-surgical primary rhinoplasty using a polymethylmethacrylate injectable implant. *Dermatol Surg*. 2014;40(3): 305–313.
- [28] Kim YS et al. The anatomical origin and course of the angular artery regarding its clinical implications. *Dermatol Surg*. 2014;40(10):1070–1076.
- [29] Saban Y et al. Nasal arterial vasculature: medical and surgical applications. *Arch Facial Plast Surg*. 2012;14(6):429–436.
- [30] Lee HJ et al. Description of a novel anatomic venous structure in the nasoglabellar area. *J Craniofac Surg*. 2014;25(2):633–635.
- [31] Hanke CW et al. Abscess formation and local necrosis after treatment with Zyderm or Zyplast collagen implant. *J Am Acad Dermatol*. 1991;25:319.
- [32] Manafi A et al. Nasal alar necrosis following hyaluronic acid injection into nasolabial folds: a case report. *World J Plast Surg*. 2015;4(1):74–78.
- [33] Chou CC et al. Choroid vascular occlusion and ischemic optic neuropathy after facial calcium hydroxyapatite injection- a case report. *BMC Surg*. 2015;15:21.
- [34] Chen Y et al. Fundus artery occlusion caused by cosmetic facial injections. *Chin Med J (Engl)*. 2014;127(8):1434–1437.
- [35] Kim SN et al. Panophthalmoplegia and vision loss after cosmetic nasal dorsum injection. *J Clin Neurosci*. 2014;21(4): 678–680.
- [36] Honart JF et al. A case of nasal tip necrosis after hyaluronic acid injection. *Ann Chir Plast Esthet*. 2013;58(6):676–679.
- [37] Tracy L et al. Calcium hydroxylapatite associated soft tissue necrosis: a case report and treatment guidelines. *J Plast Reconstr Aesthet Surg*. 2014;67(4):564–568.
- [38] Kim YJ, Choi KS. Bilateral blindness after filler injection. *Plast Reconstr Surg*. 2013;131(2):298e–299e.

- [39] Park SW et al. Iatrogenic retinal artery occlusion caused by cosmetic facial filler injections. *Am J Ophthalmol*. 2012;154(4):653–662.e1.
- [40] Sung MS et al. Ocular ischemia and ischemic oculomotor nerve palsy after vascular embolization of injectable calcium hydroxylapatite filler. *Ophthal Plast Reconstr Surg*. 2010;26(4):289–291.
- [41] Beleznay K et al. Vascular compromise from soft tissue augmentation: experience with 12 cases and recommendations for optimal outcomes. *J Clin Aesthet Dermatol*. 2014;7(9):37–43.
- [42] Kim SG et al. Salvage of nasal skin in a case of venous compromise after hyaluronic acid filler injection using prostaglandin E. *Dermatol Surg*. 2011;37(12):1817–1879.
- [43] Menick FJ. Practical details of nasal reconstruction. *Plast Reconstr Surg*. 2013;131(4):613e–630e.
- [44] Menick FJ. Aesthetic and reconstructive rhinoplasty: a continuum. *J Plast Reconstr Aesthet Surg*. 2012;65(9):1169–1174.
- [45] Sung HM et al. Case reports of adipose-derived stem cell therapy for nasal skin necrosis after filler injection. *Arch Plast Surg*. 2012;39(1):51–54