

We are IntechOpen, the world's leading publisher of Open Access books Built by scientists, for scientists

6,900

Open access books available

185,000

International authors and editors

200M

Downloads

Our authors are among the

154

Countries delivered to

TOP 1%

most cited scientists

12.2%

Contributors from top 500 universities



WEB OF SCIENCE™

Selection of our books indexed in the Book Citation Index
in Web of Science™ Core Collection (BKCI)

Interested in publishing with us?
Contact book.department@intechopen.com

Numbers displayed above are based on latest data collected.
For more information visit www.intechopen.com



Use of Intra-Oral Osmotic Self-Inflating Tissue Expanders for Bone Reconstruction and Rehabilitation of the Jaws

Farzin Sarkarat, Farshid Kavandi,
Rouzbeh Kahali and
Mohammad Hosein Kalantar Motamedi

Additional information is available at the end of the chapter

<http://dx.doi.org/10.5772/63059>

Abstract

Reconstruction of oral and maxillofacial defects is challenging. Insufficient soft tissues may render hard tissue reconstruction problematic. Several surgical techniques have been used over time to address this issue; these techniques are usually complicated and unpredictable. Soft tissue expansion is a physiological process that leads to the formation of new cells and growth of tissue and allows for soft tissue with similar color, texture and function to that of the adjacent tissues. In this article we present the applications of osmotic tissue expanders in facilitating bone graft augmentation. OSMED (Ilmenau, Germany) self-inflating tissue expanders were used prior to bone augmentation in our patients. After making a 1.5 cm full thickness incision, a subperiosteal tunnel was prepared and the tissue expander was implanted subperiosteally. The tissue expanders were removed approximately 6–10 weeks later in the course of augmentation surgery. In all patients after the use of the tissue expander, sufficient soft tissue was available for primary, tension-free, wound closure and there was no need for local or regional flap techniques. No complications such as infection, necrosis, or graft loss occurred and the functional and esthetic outcomes were acceptable. Use of this tissue expander prior to bone augmentation was effective in facilitating bone graft augmentation.

Keywords: Soft tissue expander, bone augmentation, reconstruction, soft tissue management, osmotic-tissue expanders

1. Introduction

Reconstruction of oral and maxillofacial defects is challenging. These defects may be congenital malformations, defects caused by severe atrophy, trauma or oncologic ablation. Such cases can cause considerable esthetics and/or functional problems and may require augmentation, grafting, and implantation procedures that may significantly affect the quality of life of the patients [1].

Insufficient hard and soft tissues may present esthetics or functional problems. Bone grafts, bone substitutes and guided tissue regeneration (GTR) techniques have been used for many years to rebuild the alveolar ridge [2]. Reconstructing large and complex defects are more complicated. One of the common problems is inadequate soft tissue for coverage of the graft. Several surgical techniques such as rotational flaps, pedicle flaps, free flaps and composite flaps have been used over time to address this issue [3, 4]; these techniques are usually complicated and they have limitations, such as donor site morbidity, necrosis and infection [4]. Another problem is the unpleasant functional and esthetics results due to the differences of the grafted tissues from the original tissue. One of the most common problems during reconstruction of bony defects of the jaws is soft tissue dehiscence which leads to the exposure of the bone grafts into the oral cavity and may result in loss of the bone graft [5–9]. Adequate soft tissue coverage of grafted bone is important to avoid graft exposure; thus, primary tension-free closure of the flap without compromising the vascularization is important [10–12]. When a large amount of bone augmentation is required, it is usually hard to achieve tension free soft tissue coverage. A periosteal incision is often used to make it possible to mobilize and stretch the mucoperiosteal flap. This, however, reduces the perfusion of the mucoperiosteal flap [11, 13–16]. Sufficient blood flow is important for tissue survival [17]. Even simple flap elevation can disturb flap perfusion and causes ischemia [18]. Extensive flap preparation and elevation can result in impaired perfusion and increased incidence of necrosis and tissue dehiscence [19, 20]. Inadequate perfusion and dehiscence of the soft tissue can jeopardize the success of bone augmentation.

One possible solution is soft tissue expansion. Tissue expansion was first described by Radovan [21, 22] as a method of creating soft tissue with similar color, texture, thickness, and sensation as the adjacent tissue with minimal scarring and little donor site morbidity. Neumann was the first who mentioned the potential to use tissue expansion for reconstructive surgery [22, 23]. Nowadays tissue expansion is a well-known technique for head and neck reconstructive surgery [24–27]. Soft tissue expansion is a physiological process that leads to the formation of new cells and growth of tissue [28] and allows us to gain extra soft tissue with similar color, texture and function to that of the adjacent tissues for covering grafts [29].

After the tissue expander is inserted, during the expansion process the tissue is under a persistent tensile stress; traction of the surrounding soft tissue leads to extra soft tissue volume [30–32]. Sub-periosteal implantation of the expander is usually preferred over extra-periosteal implantation because of its optimum soft tissue increase [33]. However, sub-periosteal implantation of the expander limits the nutritional supply to the bone [34].

Traditional tissue expanders are silicone envelopes with self-sealing injection ports. They are filled by serial saline injections through the ports at weekly intervals. Volume expansion of the expander puts tension on the overlying tissue [35]. These traditional tissue expanders are now known to be associated with complications because of their intermittent sudden expansion [36]; this led to the development of osmotic tissue expanders (OTEs). The OTE was first described by Austad and Rose [37]. It was made of a semi-permeable membrane filled with hypertonic saline which leads to the entrance of the water by osmotic forces from the surrounding tissues into the expander. Wiese developed an osmotic self-inflating expander [38], which has been used successfully to expand the orbit in the management of enophthalmos, microphthalmos, and cryptophthalmos [39–41].

The osmotic self-filling expander is made of polymeric methyl methacrylate–vinylpyrrolidone which gains volume by absorbing body fluids [42, 43]. The purpose of this chapter is to present some examples of the application of this expander before bone graft augmentation.

2. Technique

We used OTE in various patients. In our study, we used OSMED (Ilmenau, Germany) self-inflating tissue expanders (**Figure 1**) prior to bone augmentation and evaluated its complications and problems.

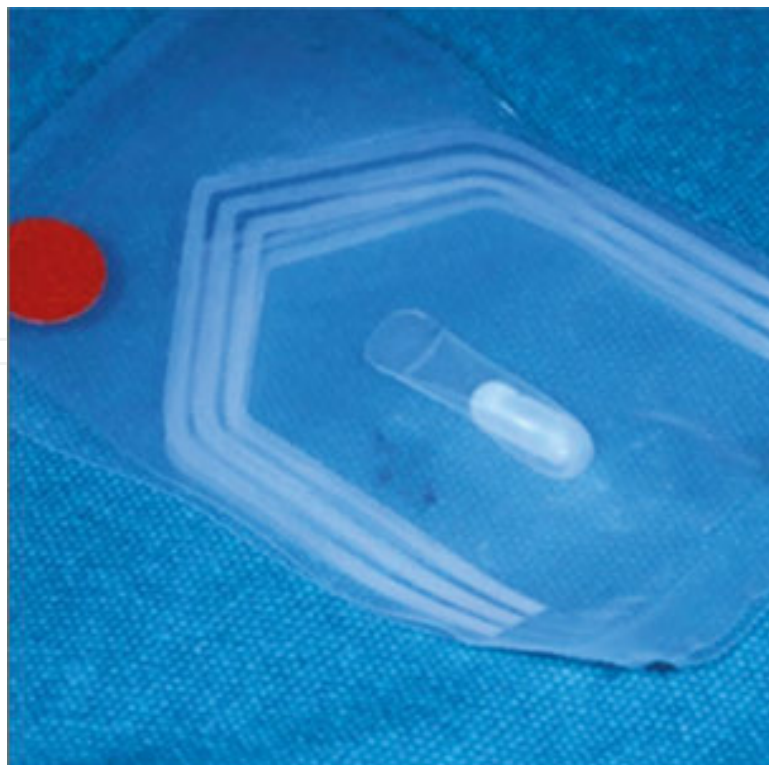


Figure 1. Osmed tissue expander.

2.1. Surgical technique

After making a full thickness incision, a sub-periosteal tunnel was prepared (**Figure 2**). After completion of the tunnel preparation, the tissue expander was placed under the tunnel flap while keeping the surgical field as dry as possible to reduce the risk of contamination with oral fluids. Wound closure was performed to minimize the leakage and contamination. The sutures were removed after 2 weeks. The tissue expanders were removed approximately 6–10 weeks later in the course of augmentation surgery; 1 g of intravenous cefazolin antibiotic was administered pre-operatively and continued every 6 h post-operatively for 24 h then it was replaced by 500 mg of oral cephalexin antibiotic taken every 6 h for the next 7 days. Chlorhexidine mouth-wash was used every 8 h post-operatively and was continued for 14 days.

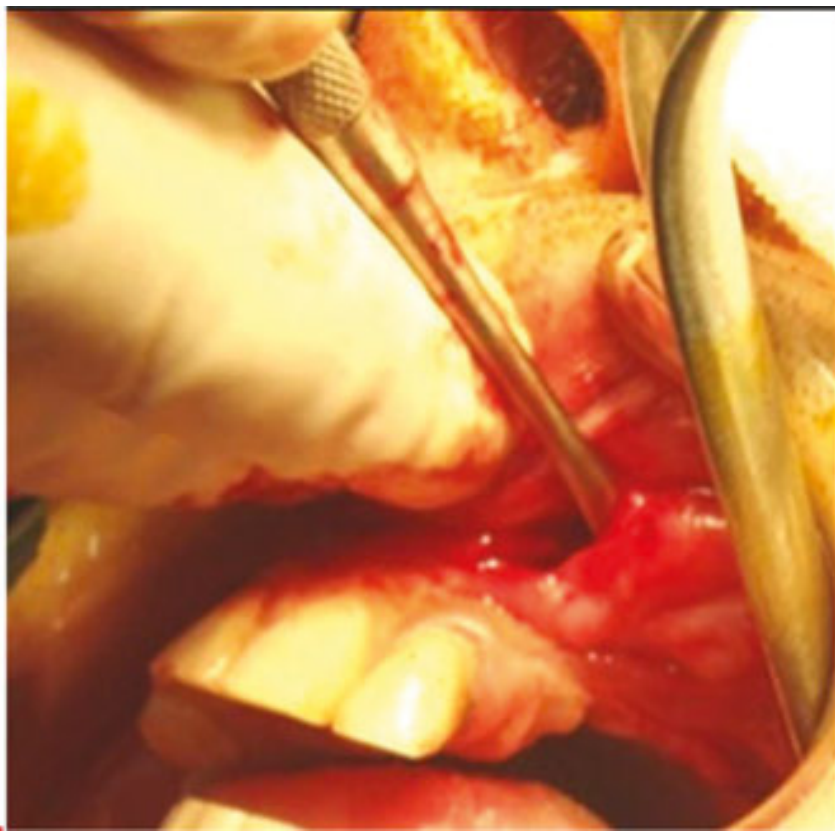


Figure 2. Subperiosteal tunnel preparation.

3. Cases

3.1. Patient 1

A 23-year-old male had partial maxillectomy surgery on the left side due to central giant cell granuloma 12 years ago (**Figure 3**).

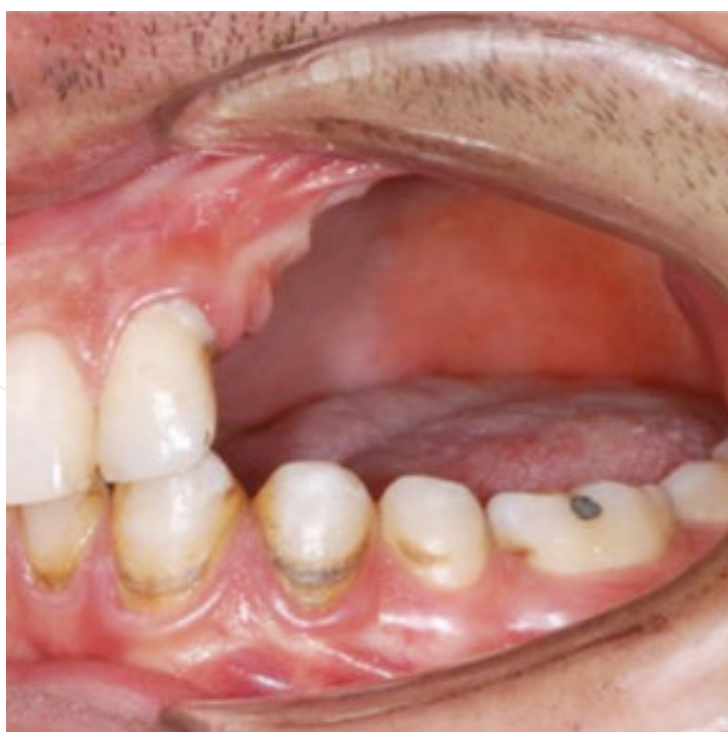

Figure 3. Partial maxillectomy of the left side.

In the first operation, an OSMED tissue expander cylinder 2.1 ml, with initial volume of 0.42 ml and final volume of 2.1 ml was placed sub-periosteally in the defect (**Figure 4**).

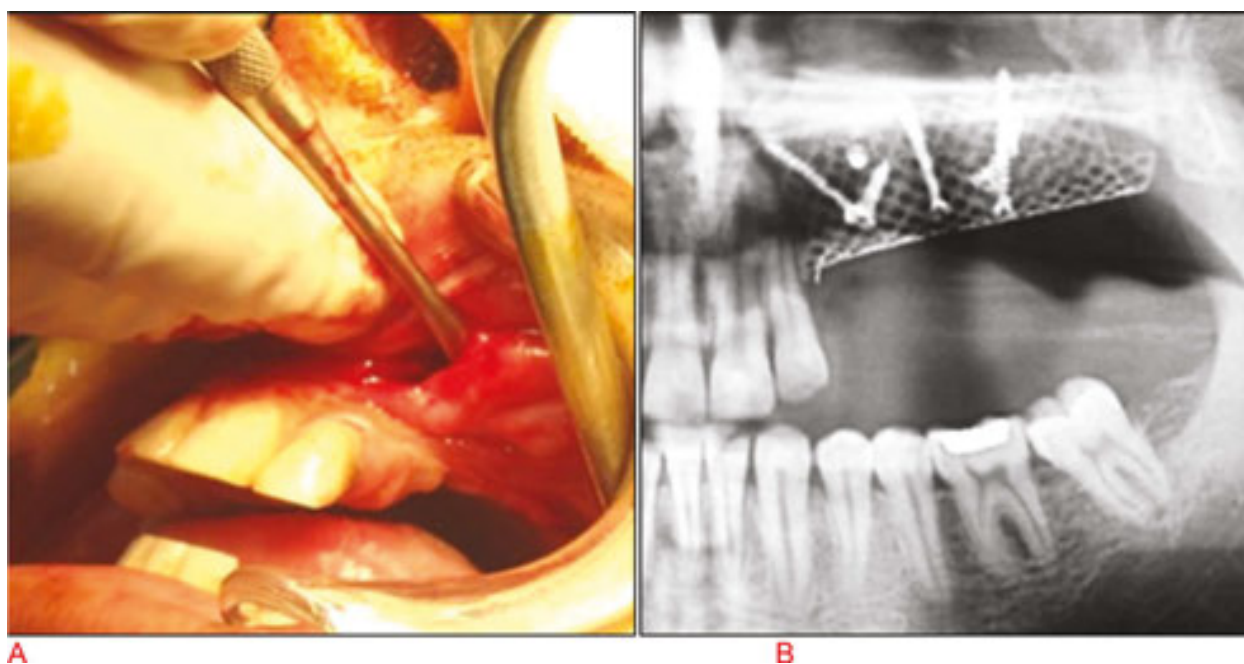


Figure 4. (A) OSMED tissue expander was placed sub-periosteally. (B) 10 weeks later, the tissue expander was removed and the bone was augmented.

In the second operation, done 10 weeks later, the tissue expander was removed and the bone was augmented by iliac bone graft (**Figure 5**).

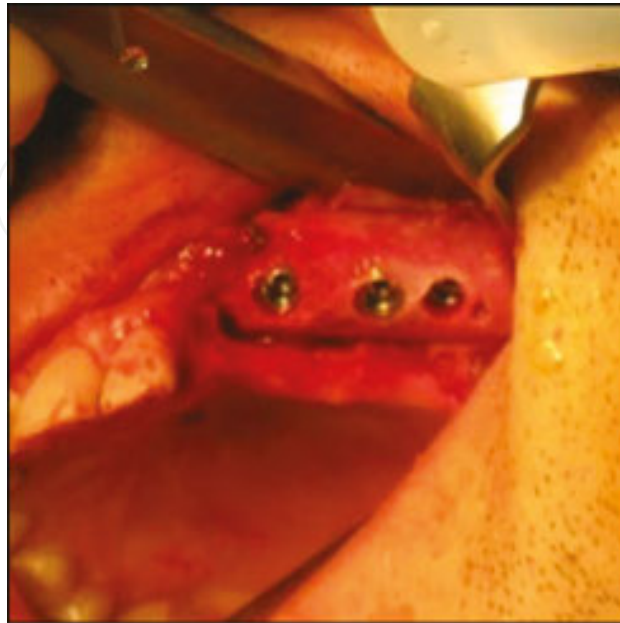

Figure 5. The tissue expander was removed and the bone augmented by iliac bone graft.

In the third operation, done 5 months later, the titanium mesh and fixation screws were removed and three dental implants were inserted (**Figure 6**). No post-operative complications were observed.

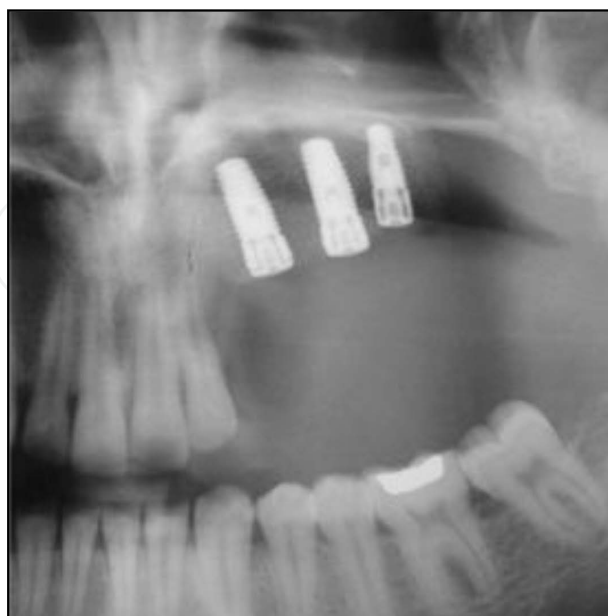

Figure 6. The titanium mesh and fixation screws removed and three dental implants were inserted.

3.2. Patient 2

A 54-year-old woman had severe mandibular atrophy. She had been edentulous for 30 years and had bone augmentation with iliac bone graft on the right side of the mandible 20 years ago. In the first operation, because of the lack of enough soft tissue and the presence of scar tissues from previous surgery, we used an OSMED tissue expander cylinder 1.3 ml, with initial volume of 0.25 ml and final volume of 1.3 ml (**Figure 7**).

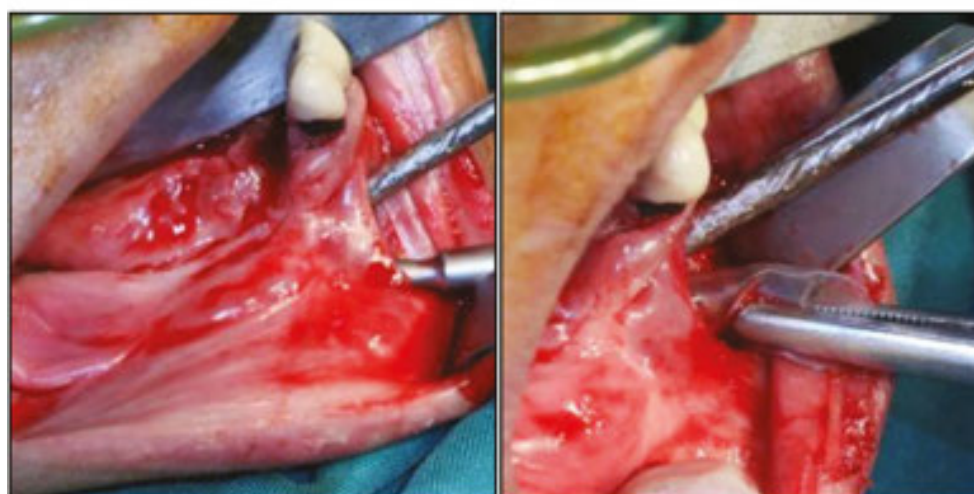
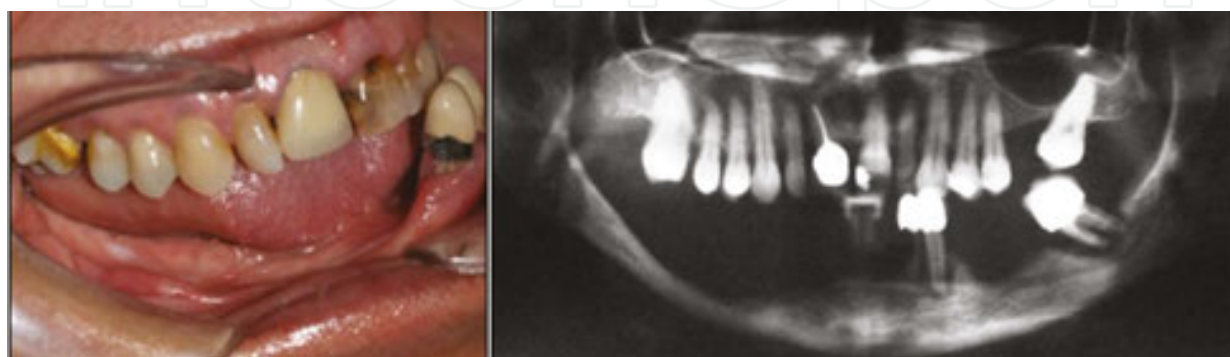

Figure 7. Severe mandibular atrophy. OSMED tissue expander cylinder placed in a sub-periosteal tunnel.

In the second operation, done 6 weeks later, the tissue expander was removed and the bone was augmented with iliac bone graft (**Figure 8**) and later dental implants were inserted (**Figure 9**). In this case, despite of the lack of enough soft tissue and the presence of scar tissues, the hard tissue was augmented vertically and desirable outcome and adequate bone volume for implant placement was achieved.

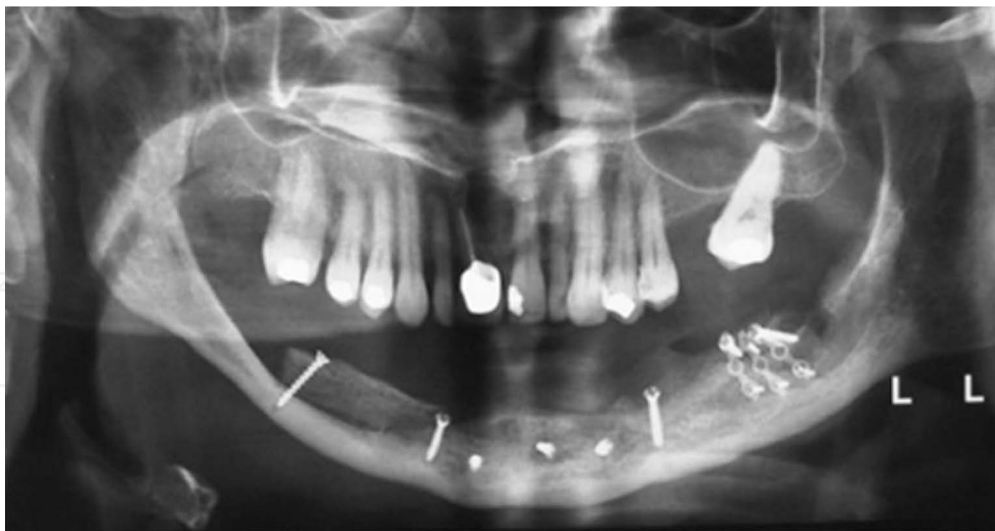

Figure 8. The bone was augmented with iliac bone graft.

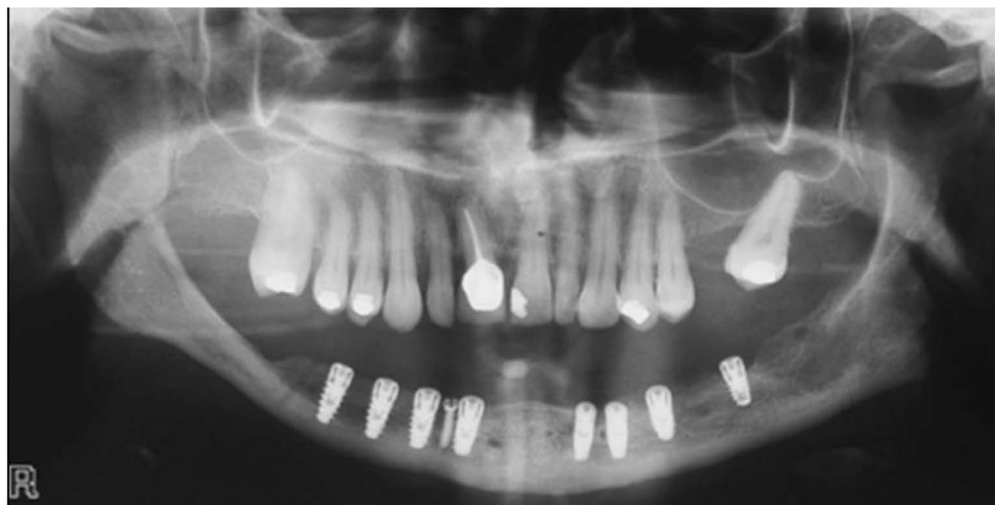

Figure 9. Later dental implants were inserted.

3.3. Patient 3

A 41-year-old woman had previous partial mandibular resection surgery due to an ameloblastoma (**Figure 10**).

In the first operation, an OSMED tissue expander cylinder 2.1 ml was used. In the second operation, done 8 weeks later, the tissue expander was removed and the bone was augmented by iliac bone graft prior to dental implant insertion (**Figure 11**). In this case, due to the tension free closure of the soft tissue overlying the bone graft, postoperative complications were reduced and good results obtained.

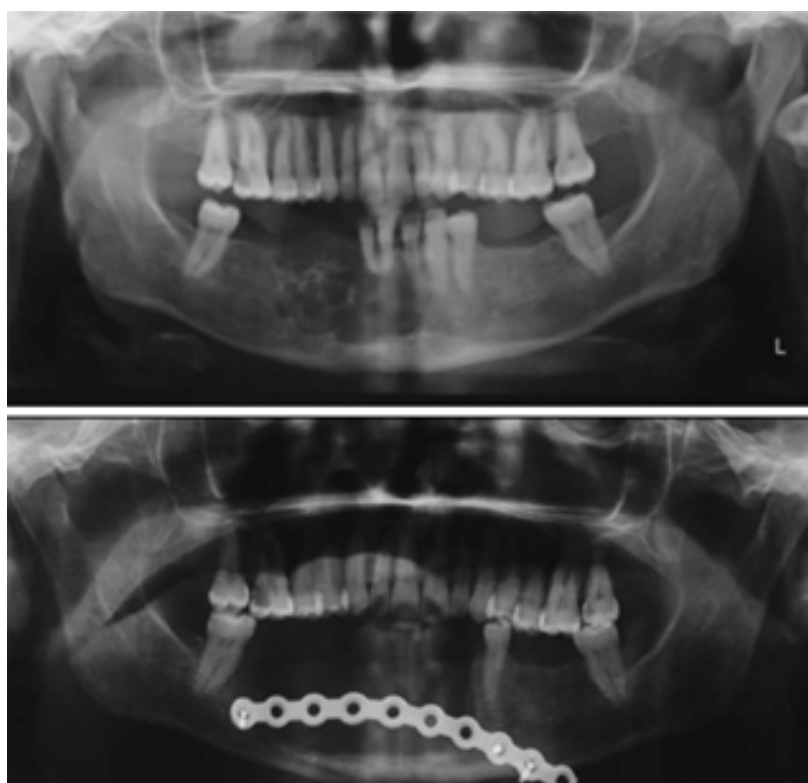


Figure 10. Ameloblastoma of the lower jaw. Resected.

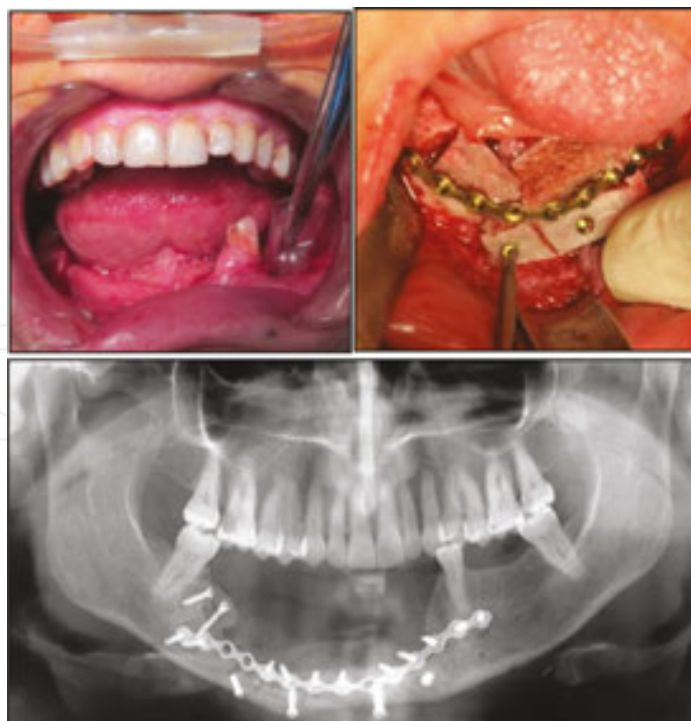

Figure 11. Left, Sub-periosteal tunnel preparation for tissue expander implantation Right, Bone augmentation was performed 8 weeks later Bottom, Panoramic view of the patient after bone augmentation.

4. Discussion

Soft tissue expansion has been used successfully for the reconstruction of soft tissue defects [44–47]. In case of inadequate normal soft tissue, new tissue should be created with the same color, texture and function as the adjacent tissue, which was first described by Neumann [48] for auricular reconstruction. In the head and neck area, tissue expansion has been used successfully for scalp, nose and ears [29, 30, 49, 50]. Intraoral soft tissue expanders have also been used prior to the bone augmentation in the case of inadequate soft tissue for primary tension free wound closure [51–56]. In their study they used classic forms of tissue expanders which were inflatable expanders inflated by weekly injections of saline. However, because of their sudden and intermittent volume increase, tissue hypoxia due to decreased blood flow to the area was reported [57]. Two types of expansion regimens are used clinically for classic tissue expansion namely ‘conventional, prolonged expansion’ for 1–3 months and ‘intraoperative sustained limited expansion’ [58, 59]. Some studies suggest that ‘conventional, prolonged tissue expansion’ can also be performed for 1–2 weeks without complications [60, 61]. The most common complications of soft tissue expansion are infection, dehiscence, hematoma, necrosis and failure [46, 47, 62–64]. When infection occurs, the expanders are usually removed to control the infection. Although several methods have been reported to salvage tissue expanders [65–67], usually substitution of the infected tissue expander with a new one is required.

By making a small incision as far as possible from the intended site for tissue expander insertion, the risk of dehiscence and failure is minimized [22, 29, 45]. Generally, in the same conditions, the smaller tissue expander is preferred over the larger one. Larger tissue expander usually require larger incisions with wider dissection and more undermining, which may increase the risk of dehiscence and also may cause scar expansion instead of normal tissue expansion [68]. As mentioned earlier, the expansion rate is important. Use of self-inflatable osmotic expander, has a gradual rate of expansion [43]. The early osmotic implants were made of a semi-permeable envelopes containing hypertonic liquid. Their expansion rates were rapid and were completed within the first 24–48 h following insertion and they were associated with more complications such as tissue ischemia and failure. Subsequent tissue expanders were made of dehydrated hydrogel in a silicone envelope with a more gradual expansion rate and lower complications [43, 69]. The OSMED self-inflating tissue expanders are made of a specially developed hydrogel that use the osmotic principle to gain volume. The hydrogel is made of co-polymers based on methyl methacrylate and N-vinyl pyrrolidone. Pre-operatively they are in their pre-expanded state and therefore are small, hard and easy to handle. After implantation, they start to absorb body fluid and grow consistently to a predefined shape and size. Their final volume depends on the product type and is between 3 and 12 fold their initial volume. The increase volume of the implant leads to an increase of soft tissue. Their expansion speed also differs by the product type. In some the tissue expander is delivered in a silicone shell, with an exact number and size of holes to assure gradual and consistent swelling of the device.

In this study, we used OSMED self-inflating tissue expander cylinder which is delivered in a silicone shell. The tissue expanders were placed sub-periosteally. It is reported that sub-periosteal implantation causes significant resorption of the underlying bone by impairing the micro-circulation of the underlying bone [33, 70–72], which was not observed in our patients. Periosteal-releasing incisions may reduce the blood supply to soft tissue flaps and increase the risk of dehiscence. The periosteal expansion facilitates a tension-free wound closure without the need to use any periosteal-releasing incisions [16]. Another strategy for minimizing the risk of intraoral dehiscence and infection [29] is keeping the incision small and away from the tissue expander, which may explain the low incidence of complications in our study and other reports [43]. It has been reported that slow and continuous expansion results in safe and effective generation of soft tissue and decreased incidence of intraoral dehiscence [38, 73]. In our study, the rate of expansion was slow enough not to cause any perforation of the soft tissue [74]. After expansion, the quality and quantity of expanded soft tissue was good enough to permit easy primary tension-free wound closure after major bone augmentation. The slow expansion will lead to slow and proper formation of new tissues over the time period [73].

5. Conclusion

In conclusion, our cases demonstrate that the use of tissue expander prior to bone augmentation can reduce the complications associated with non-OTE and lead to more predictable results.

Author details

Farzin Sarkarat¹, Farshid Kavandi^{2*}, Rouzbeh Kahali¹ and
Mohammad Hosein Kalantar Motamedi³

*Address all correspondence to: farshid_kavandi@yahoo.com

1 Department of Oral and Maxillofacial Surgery, CMF Research Center, Buali Hospital, Islamic Azad University of Medical Sciences, Tehran, Iran

2 Department of Oral and Maxillofacial Surgery, Shahid Beheshti University of Medical Sciences, Tehran, Iran

3 Trauma Research Center, Baqiyatallah University of Medical Science and Islamic Azad University of Medical Sciences, Tehran, Iran

References

- [1] Sebastian P, Thomas S, Varghese BT, Lype EM, Balagopal PG, Mathew PC. The submental island flap for reconstruction of intraoral defects in oral cancer patients. *Oral Oncol* 2008;44(11):1014–1018. Epub 2008 Jul 11.
- [2] Wang HL, Boyapati L. “PASS” principles for predictable bone regeneration. *Implant Dent* 2006;15:8–17.
- [3] Futran ND, Alsarraf R. Microvascular free-flap reconstruction in the head and neck. *J Am Med Assoc* 2000;284:1761–1763.
- [4] Eckardt A, Meyer A, Laas U, Hausamen JE. Free flap reconstruction of head and neck defects—a clinical review of twenty years. *Br J Oral Maxillofac Surg* 2007;45:11–15.
- [5] Urban IA, Jovanovic SA, Lozada JL. Vertical ridge augmentation using guided bone regeneration (GBR) in three clinical scenarios prior to implant placement: a retrospective study of 35 patients 12 to 72 months after loading. *Int J Oral Maxillofac Implants* 2009;24:502–510.
- [6] Felice P, Marchetti C, Iezzi G, Piattelli A, Worthington H, Pellegrino G, Esposito M. Vertical ridge augmentation of the atrophic posterior mandible with interpositional bloc grafts: bone from the iliac crest vs. bovine anorganic bone. Clinical and histological results up to one year after loading from a randomized-controlled clinical trial. *Clin Oral Implants Res* 2009;20:1386–1393.
- [7] Canullo L, Malagnino VA. Vertical ridge augmentation around implants by e-PTFE titanium reinforced membrane and bovine bone matrix: a 24- to 54-month study of 10 consecutive cases. *Int J Oral Maxillofac Implants* 2008;23:858–866.
- [8] Merli M, Migani M, Esposito M. Vertical ridge augmentation with autogenous bone grafts: resorbable barriers supported by osteosynthesis plates versus titanium reinforced barriers. A preliminary report of a blinded, randomized controlled clinical trial. *Int J Oral Maxillofac Implants* 2007;22:373–382.
- [9] Barone A, Covani U. Maxillary alveolar ridge reconstruction with nonvascularized autogenous block bone: clinical results. *J Oral Maxillofac Surg* 2007;65:2039–2046.
- [10] Cordaro L, Amade DS, Cordaro M. Clinical results of alveolar ridge augmentation with mandibular block bone grafts in partially edentulous patients prior to implant placement. *Clin Oral Implants Res* 2002;13:103–11.
- [11] Lundgren S, Sjostrom M, Nystrom E, Sennerby L. Strategies in reconstruction of the atrophic maxilla with autogenous bone grafts and endosseous implants. *Periodontology* 2000 2008;47:143–161.

- [12] von Arx T, Kurt B. Implant placement and simultaneous ridge augmentation using autogenous bone and a micro titanium mesh: a prospective clinical study with 20 implants. *Clin Oral Implants Res* 1999;10:24–33.
- [13] Esposito M, Grusovin MG, Maghaireh H, Coulthard P, Worthington HV. Interventions for replacing missing teeth: management of soft tissues for dental implants. *Cochrane Database Syst Rev* 2007;CD006697.
- [14] Jivraj S, Chee W. Treatment planning of implants in the esthetics zone. *Br Dent J* 2006;201:77–89.
- [15] Rothamel D, Schwarz F, Herten M, Ferrari D, Mischkowski RA, Sager M, Becker J. Vertical ridge augmentation using xenogenous bone blocks: a histomorphometric study in dogs. *Int J Oral Maxillofac Implants* 2009;24:243–250.
- [16] Abrahamsson P, Isaksson S, Gordh M, Andersson G. Onlay bone grafting of the mandible after periosteal expansion with an osmotic tissue expander: an experimental study in rabbits. *Clin Oral Implants Res* 2010;21(12):1404–10.
- [17] Nakayama Y, Soeda S, Kasai Y. The importance of arterial inflow in the distal side of a flap: an experimental investigation. *Plast Reconstr Surg* 1982;69:61–67.
- [18] McLean TN, Smith BA, Morrison EC, Nasjleti CE, Caffesse RG. Vascular changes following mucoperiosteal flap surgery: a fluorescein angiography study in dogs. *J Periodontol* 1995;66:205–210.
- [19] Morris SF, Pang CY, Zhong A, Boyd B, Forrest CR. Assessment of ischemia-induced reperfusion injury in the pig latissimus dorsi myocutaneous flap model. *Plast Reconstr Surg* 1993;92:1162–1172.
- [20] Carroll WR, Esclamado RM. Ischemia/reperfusion injury in microvascular surgery. *Head Neck* 2000;22:700–713.
- [21] Radovan C. Breast reconstruction after mastectomy using the temporary expander. *Plast Reconstr Surg* 1982;69:195–208.
- [22] Radovan C. Tissue expansion in soft-tissue reconstruction. *Plast Reconstr Surg* 1984;74:482–92.
- [23] Ionomou TG, Michelow BJ, Zuker RM. Tissue expansion in the pediatric patient. *Ann Plast Surg* 1993;31:134–40.
- [24] Menard RM, Moore MH, David DJ. Tissue expansion in the reconstruction of Tessier craniofacial clefts: a series of 17 patients. *Plast Reconstr Surg* 1999;103(3):779–86.
- [25] Zaal LH, van der Horst CM. Results of the early use of tissue expansion for giant congenital melanocytic naevi on the scalp and face. *J Plast Reconstr Aesthet Surg* 2009;62(2):216–20.

- [26] Mahoney EJ, Dolan RW, Choi EE, et al. Surgical reconstruction of lentigomaligna defects. *Arch Facial Plast Surg* 2005;7(5):342–6.
- [27] Hurvitz KA, Rosen H, Meara JG. Pediatric cervicofacial tissue expansion. *Int J Pediatr Otorhinolaryngol* 2005;69(11):1509–13.
- [28] van Rappard JH, Molenaar J, van Doorn K, Sonneveld GJ, Borghouts JM. Surface-area increase in tissue expansion. *Plast Reconstr Surg* 1988;82:833–9.
- [29] Wieslander JB. Tissue expansion in the head and neck. A 6-year review. *Scand J Plast Reconstr Surg Hand Surg* 1991;25:47–56.
- [30] Antonyshyn O, Gruss JS, Zuker R, Mackinnon SE. Tissue expansion in head and neck reconstruction. *Plast Reconstr Surg* 1988;82:58–68.
- [31] Bennett RG, Hirt M. A history of tissue expansion. Concepts, controversies, and complications. *J Dermatol Surg Oncol* 1993;19:1066–1073.
- [32] Bascom DA, Wax KA. Tissue expansion in the head and neck: current state of the art. *Curr Opin Otolaryngol Head Neck Surg* 2002;10:273–277.
- [33] Rucker M, Binger T, Deltcheva K, Menger MD. Reduction of midfacial periosteal perfusion failure by subperiosteal versus supraperiosteal dissection. *J Oral Maxillofac Surg* 2005;63:87–92.
- [34] Chanavaz M. Anatomy and histophysiology of the periosteum: quantification of the periosteal blood supply to the adjacent bone with ⁸⁵Sr and gamma spectrometry. *J Oral Implantol* 1995;21:214–219.
- [35] Argenta LC. Tissue expansion. In: Aston SJ, Beasley RW, editors. *Thorne CHM Plastic Surgery*. 5th edn. New York: Lippincott-Raven; 1997. p. 91.
- [36] Cunha MS, Nakamoto HA, Herson MR, et al. Tissue expander complications in plastic surgery. A 10-year experience. *Rev Hosp Clin Fac Med Sao Paulo* 2002;57:93–97.
- [37] Austad ED, Rose GL. A self-inflating tissue expander. *Plast Reconstr Surg* 1982;70:588–94.
- [38] Wiese KG. Osmotically induced tissue expansion with hydrogels: a new dimension in tissue expansion? A preliminary report. *J Craniomaxillofac Surg* 1993;21:309–13.
- [39] Downes R, Lavin M, Collin R. Hydrophylic expanders for the congenital anophthalmic socket. *Adv Ophthalmic Plast Reconstr Surg* 1992;9:57–61.
- [40] Wiese KG, Vogel M, Guthoff R, et al. Treatment of congenital anophthalmos with self-inflating polymer expanders: a new method. *J Craniomaxillofac Surg* 1999;27:72–6.
- [41] Gundlach KK, Guthoff RF, Hingst VH, et al. Expansion of the socket and orbit for congenital clinical anophthalmia. *Plast Reconstr Surg* 2005;116:1214–22.

- [42] Berge SJ, Wiese KG, von Lindern JJ, Niederhagen B, Appel T, Reich RH. Tissue expansion using osmotically active hydrogel systems for direct closure of the donor defect of the radial forearm flap. *Plast Reconstr Surg* 2001;108:1–5 (discussion 6–7).
- [43] Ronert MA, Hofheinz H, Manassa E, Asgarouladi H, Olbrisch RR. The beginning of a new era in tissue expansion: self-filling osmotic tissue expander—four-year clinical experience. *Plast Reconstr Surg* 2004;114:1025–1031.
- [44] Cullen KW, Powell B. Tissue expanders in surgery. *Br J Clin Pract* 1989;43:75–77.
- [45] Houpt P, Dijkstra R. Tissue expansion in reconstructive surgery. *Neth J Surg* 1988;40:13–16.
- [46] Manders EK, Schenden MJ, Furrey JA, Hetzler PT, Davis TS, Graham WP, III. Soft-tissue expansion: concepts and complications. *Plast Reconstr Surg* 1984;74:493–507.
- [47] Neale HW, Kurtzman LC, Goh KB, Billmire DA, Yakuboff KP, Warden G. Tissue expanders in the lower face and anterior neck in pediatric burn patients: limitations and pitfalls. *Plast Reconstr Surg* 1993;91:624–631.
- [48] Neumann CG. The expansion of an area of skin by progressive distention of a subcutaneous balloon; use of the method for securing skin for subtotal reconstruction of the ear. *Plast Reconstr Surg* 1957;19:124–130.
- [49] Argenta LC. Controlled tissue expansion in reconstructive surgery. *Br J Plast Surg* 1984;37:520–529.
- [50] Argenta LC, VanderKolk CA. Tissue expansion in craniofacial surgery. *Clin Plast Surg* 1987;14:143–153.
- [51] Zeiter DJ, Ries WL, Weir TL, Mishkin DJ, Sanders JJ. The use of a soft tissue expander in an alveolar bone ridge augmentation for implant placement. *Int J Periodontics Restor Dent* 1998;18:403–409.
- [52] Lew D, Amos EA, Unhold GP. An open procedure for placement of a tissue expander over the atrophic alveolar ridge. *J Oral Maxillofac Surg* 1988;46:161–166.
- [53] Lew D, Hinkle RM, Collins SF. Use of subperiosteal implants with distal filling ports in the correction of the atrophic alveolar ridge. *Int J Oral Maxillofac Surg* 1991;20:15–17.
- [54] Bahat O, Handelsman M. Controlled tissue expansion in reconstructive periodontal surgery. *Int J Periodontics Restor Dent* 1991;11:32–47.
- [55] Lew D, Amos EL, Shroyer JV, III. The use of a subperiosteal tissue expander in rib reconstruction of an atrophic mandible. *J Oral Maxillofac Surg* 1988;46:229–232.
- [56] Wittkamp AR. Short-term experience with the subperiosteal tissue expander in reconstruction of the mandibular alveolar ridge. *J Oral Maxillofac Surg* 1989;47:469–474.

- [57] Pietila JP. Tissue expansion and skin circulation. Simultaneous monitoring by laser Doppler flowmetry and transcutaneous oximetry. *Scand J Plast Reconstr Surg Hand Surg* 1990;24:135–140.
- [58] Machida BK, Liu-Shindo M, Sasaki GH, Rice DH, Chandrasoma P. Immediate versus chronic tissue expansion. *Ann Plast Surg* 1991;26:227–231.
- [59] Sasaki GH. Intra operative sustained limited expansion (ISLE) as an immediate reconstructive technique. *Clin Plast Surg* 1987;14:563–573.
- [60] Mustoe TA, Bartell TH, Garner WL. Physical, biomechanical, histologic, and biochemical effects of rapid versus conventional tissue expansion. *Plast Reconstr Surg* 1989;83:687–691.
- [61] Timmenga EJ, Schoorl R, Klopper PJ. Biomechanical and histomorphological changes in expanded rabbit skin. *Br J Plast Surg* 1990;43:101–106.
- [62] Cunha MS, Nakamoto HA, Herson MR, Faes JC, Gemperli R, Ferreira MC. Tissue expander complications in plastic surgery: a 10-year experience. *Rev Hosp Clin Fac Med Sao Paulo* 2002;57:93–97.
- [63] Bozkurt A, Groger A, O'Dey D, et al. Retrospective analysis of tissue expansion in reconstructive burn surgery: evaluation of complication rates. *Burns* 2008;34(8):1113–1118.
- [64] Tavares Filho JM, Belerique M, Franco D, Porchat CA, Franco T. Tissue expansion in burn sequelae repair. *Burns* 2007;33(2):246–251.
- [65] Yui NW, Khoo CTK. Salvage of infected expander prostheses in breast reconstruction. *Plast Reconstr Surg* 2003;111:1087–1092.
- [66] Chun JK, Schulman MR. The infected breast prosthesis after mastectomy reconstruction: successful salvage of nine implants in eight consecutive patients. *Plast Reconstr Surg* 2007;120:581–589.
- [67] Kendrick AS, Chase CW. Salvage of an infected breast tissue expander with an implant sizer and negative pressure wound management. *Plast Reconstr Surg* 2008;121:138e–139e.
- [68] Hallock GG. Safety of clinical overinflation of tissue expanders. *Plast Reconstr Surg* 1995;96:153–157.
- [69] Anwender T, Schneider M, Gloger W, et al. Investigation of the expansion properties of osmotic expanders with and without silicone shells in animals. *Plast Reconstr Surg* 2007;120:590–595.
- [70] Stuehmer C, Rucker M, Schumann P, Bormann KH, Harder Y, Sinikovic B, Gellrich NC. Osseous alterations at the interface of hydrogel expanders and underlying bone. *J Craniomaxillofac Surg* 2009;37:258–262.

- [71] Schaser KD, Zhang L, Haas NP, Mittlmeier T, Duda G, Bail HJ. Temporal profile of microvascular disturbances in rat tibialperiosteum following closed soft tissue trauma. *Langenbeck's Arch Surg* 2003;388:323–330.
- [72] Hemmer KM, Marsh JL, Picker S. Calvarial erosion after scalp expansion. *Ann Plast Surg* 1987;19:454–459.
- [73] Wiese KG, Heinemann DE, Ostermeier D, Peters JH. Biomaterial properties and biocompatibility in cell culture of a novel self inflating hydrogel tissue expander. *J Biomed Mater Res* 2001;54:179–188.
- [74] Kaner D, Friedmann A. Soft tissue expansion with self-filling osmotic tissue expanders before vertical ridge augmentation: a proof of principle study. *J Clin Periodontol* 2010.

