

We are IntechOpen, the world's leading publisher of Open Access books Built by scientists, for scientists

6,900

Open access books available

186,000

International authors and editors

200M

Downloads

Our authors are among the

154

Countries delivered to

TOP 1%

most cited scientists

12.2%

Contributors from top 500 universities



WEB OF SCIENCE™

Selection of our books indexed in the Book Citation Index
in Web of Science™ Core Collection (BKCI)

Interested in publishing with us?
Contact book.department@intechopen.com

Numbers displayed above are based on latest data collected.
For more information visit www.intechopen.com



Surgical Repair of Trigeminal Nerve Injuries

Ahmad Alshadwi and Mohammed Nadershah

Additional information is available at the end of the chapter

<http://dx.doi.org/10.5772/64059>

Abstract

This chapter reviews the relevant surgical anatomy, clinical indications, and timing for surgical repair of the inferior alveolar and lingual nerve injuries. It will also present state-of-the-art reconstructive surgery and examine the factors influencing success as well as the scientific literature for outcome studies after surgical repair.

Keywords: trigeminal nerve, injury, surgical repair, microneurosurgery, nerve graft

1. Introduction

The trigeminal nerve and its peripheral branches are susceptible to injury from a wide variety of surgical procedures, trauma, and iatrogenic causes in the practice of dentistry and medicine. These types of injuries may result in significant morbidity due to their impact on speech, mastication, and social interactions. Although these sensory disturbances often recover spontaneously, some may be permanent with varying outcomes ranging from mild hypoaesthesia to complete anesthesia. Some patients can also develop troublesome outcomes such as neuropathic responses, leading to chronic pain syndromes that may become quite debilitating.

The face and perioral region have one of the highest densities of peripheral nerve innervation in the body, which is why it is challenging for patients to tolerate neurologic disturbances in this region compared to other areas of the body. Pain, temperature, and proprioception are transmitted centrally through the lingual, mental, inferior alveolar, infraorbital, and supraorbital nerves. Different types of sensory nerve fibers transmit each sensation with different susceptibilities to injury and recovery. The goal of trigeminal nerve microsurgery is to create an environment in which these nerves that do not demonstrate spontaneous recovery are given the opportunity for regeneration to prevent the development of neuropathies.

1.1. Relevant surgical anatomy

The third division (mandibular branch) of the trigeminal nerve travels through the foramen ovale into the infratemporal fossa (**Figure 1**). The lingual nerve shortly branches off close to the skull base.

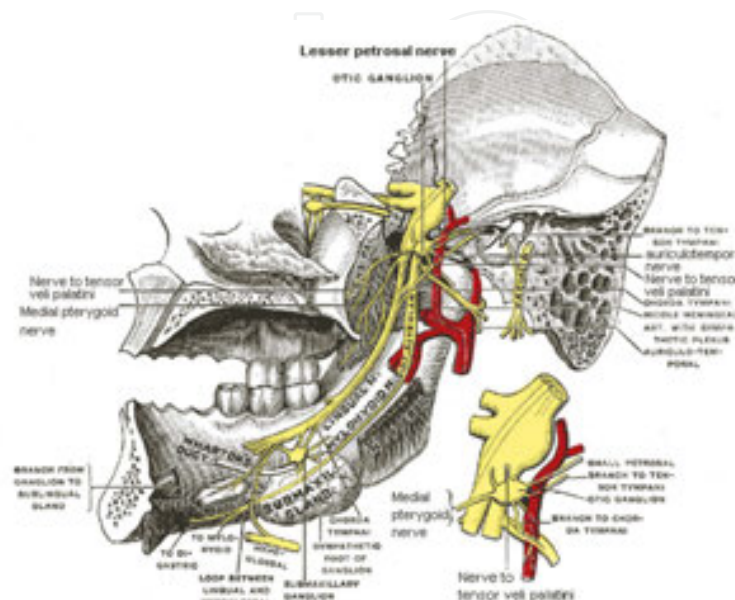


Figure 1. Anatomy of the mandibular division of the trigeminal nerve.

The lingual nerve lies anterior and medial to the inferior alveolar nerve and descends between the lateral and medial pterygoid muscles. At the lower end of the lateral pterygoid muscle, it receives fibers from the chorda tympani which carries special sensory fibers providing taste sensation (from the anterior two thirds of the tongue) and the presynaptic parasympathetic fibers to the submandibular ganglion, providing secretomotor innervation (to the sublingual and submandibular salivary glands). The nerve then follows the lateral surface of the medial pterygoid muscle and travels medial to the mandibular ramus for about 3 cm. In the third molar region, the lingual nerve may be intimately associated with the third molar and/or the alveolar bone, protected by periosteum or within the soft tissues of the retromolar region. While traversing the retromandibular region, the lingual nerve can potentially cross the internal oblique ridge with only a layer of oral mucosa covering and protecting the nerve. This is where the lingual nerve is most vulnerable to injury during removal of the third molar teeth.

The inferior alveolar nerve (IAN) winds around the lower border of the lateral pterygoid muscle and then turns sharply lateral to reach the inner aspect of the mandible and into the body of the mandible through the mandibular foramen; the foramen is identified by a bony elevation called the lingula on the medial aspect of the ramus. The IAN passes laterally within the mandibular canal and exits via the mental foramen. In the sagittal plane, the IAN begins approximately 10 mm below the sigmoid notch and reaches its lowest point at the second premolar/molar region. Just before exiting the mental foramen, the nerve loops anteriorly and then superior and posteriorly in the premolar area. The IAN is most susceptible to iatrogenic

injury at the third molar site and in the premolar area, given the nerve course in the mandibular canal.

Histologically, trigeminal nerve cell bodies are located within the trigeminal ganglion; trigeminal nerve ends synapse with sensory receptors in the anatomical area supplied by the trigeminal nerve to convey stimulation and pass it through the nucleus caudalis, medulla, and pons onto the cortex.

Generally, nerves are wrapped in a number of fascial structures beginning with the mesoneurium layer, which surrounds the whole nerve and contains blood vessels called vasa nervorum that provides the nutritional framework. Deeper than that is the epineurium that provides coverage for the perineurium layer, which separates fascicles into functional units; each fascicle is made up of joining axons and Schwann cells that are covered by endoneurium (**Figure 2**).

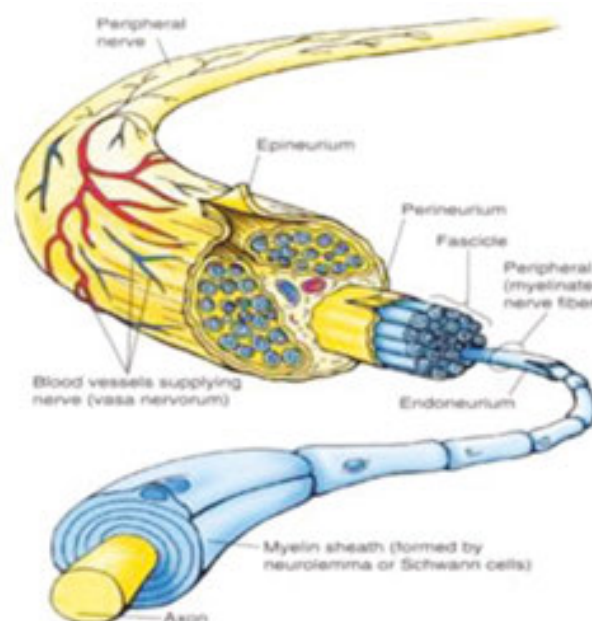


Figure 2. Microanatomy of a peripheral nerve.

The lingual nerve starts as oligofascicular proximally and then becomes polyfascicular after it is joined by the chorda tympani, whereas the IAN tends to be polyfascicular with decreasing number of fascicles as it travels distally [1].

1.2. Neurosensory testing and work-up

Documentation of sensory nerve injury is critical from legal perspectives and extremely important in determining the nature and type of injury. The first step is obtaining the patient's chief complaint, whether it is a loss of sensation, pain, or other abnormal sensation or functional impairment [2]. When noting the history, few key elements need to be documented namely, location and cause of injury, date of injury, development of the symptoms, etc. Return of sensation within the first 4 weeks indicates a neuropraxia that implies a great prognosis,

whereas a delay in return of function indicates a more serious injury, such as axonotmesis. Neurotmesis should be considered if loss of function/sensation continues for more than 3 months. Clinically, it is imperative to observe signs of traumatic injury, erythema, edema, or change in the state of local tissues (scar formation). Blanching, flushing, or changes in the overlying tissue temperature or sweating are indicative of hyperexcitability of the sympathetic nervous system. Tinel's sign (tingling over the distribution of the nerve) is another sign that clinicians should try to elicit as it may indicate neuroma development. If the pain follows an anatomical pattern, an incontinuity neuroma may be suspected and if there is pain without radiation, neurotmesis and neuroma formation may be suspected. Diagnostic nerve blocks are valuable tools in differentiating peripheral versus central pain. Radiographs and particularly

IntechOpen

Figure 3. Algorithms for neurosensory testing to evaluate peripheral trigeminal nerve injuries and their recovery. (A) Evaluation of the patient with decreased altered sensation. (B) Evaluation of the patient with unpleasant/painful altered sensation.

CT scans may indicate foreign bodies, such as screws, implants, or other alloplastic materials, which may be causing the problem.

The purpose of neurosensory testing is to determine and outline the sensory deficit, quantify the magnitude and character of the deficit, and record it for comparison in an objective manner over time. Usual tests include touch, directional touch, two-point discrimination, temperature change, and pinprick. Whether injured fibers are myelinated or non-myelinated is important; usually non-myelinated fibers recover quicker than myelinated nerves. Pain is the first sensation to return, whereas other sensations recover more slowly. Photographs or diagrams are helpful in documenting the extent of injury and its recovery [3]. More definitive and sophisticated tests (somatosensory-evoked potentials) can be used to record the return of function and monitor recovery after surgery (**Figure 3**) [4].

2. Indication and timing for surgical repair

Nerve injuries can be broadly classified into open and closed injuries. The patient who is undergoing repair of facial trauma or ablative oncologic surgery will often have the injured or intentionally resected nerve directly exposed and visible (open injury) during the procedure and this is the ideal time for repair of the nerve injury (immediate primary repair) if microsurgical expertise is available [5]. On the other hand, if conditions are unfavorable at that time, nerve reconstruction may be deferred. Delayed primary repair (within one week) or early secondary repair (after appearance of visible granulation tissue in the wound) has a favorable prognosis for sensory recovery approximating immediate primary repair [6, 7].

In recent years, however, the vascularized free flap has become the preferred method for reconstructing larger defects (>6 cm) of the mandible and all large soft-tissue defects unable to be restored by local rotational flaps [8]. Because free flaps often contain sensory nerves suitable as grafts to reconstruct important branches of the trigeminal nerve resected along with a tumor, they provide an excellent opportunity to restore important sensation to the tongue, lip, or face during the same operation. For instance, a microvascularized osseomyocutaneous scapulohumeral free flap containing the long thoracic nerve has been used to successfully reconstruct mandibular defects and restore the sensation of the IAN after resection of oral carcinomas [9]. A radial free forearm flap containing either the medial antebrachial nerve or the lateral forearm cutaneous nerve provides a well-matched donor nerve to reconstruct the IAN or the lingual nerve after ablative cancer surgery [10–12]. Many cancer reconstructive teams now include a microsurgeon, who can enhance the opportunity for restoration of optimum osseous continuity, soft-tissue coverage, and nerve function.

A nerve injury may be unsuspected or unobserved (closed nerve injury), particularly during elective dentoalveolar surgery or when patients sustain facial trauma that do not require open reduction [13]. Excising a benign tumor or cyst near the inferior alveolar or lingual nerve can cause injury that is not visualized at that time. Surgery for benign submandibular or sublingual salivary gland disease may likewise pose a risk on the lingual nerve and may not be observed

by the surgeon [14, 15]. Sensory dysfunction in the distribution of the injured branch of the trigeminal nerve postoperatively should prompt the surgeon to investigate the situation.

Although guidelines have been proposed for indications and timing of surgical repair of trigeminal injuries [16], the exact optimal time for surgical intervention in the treatment of closed trigeminal nerve injuries remains uncertain, as shown by a recent literature review [17]. Seddon [18, 19], based on his extensive experience with treatment of missile injuries to the extremities during and after World War II, proposed a classification of closed peripheral nerve injuries. This classification, which emphasizes clinical factors, is helpful to the clinician in making timely decisions regarding treatment. Another classification devised by Sunderland emphasizes nerve pathophysiology. These two classifications are summarized in **Table 1** [20].

Seddon	Neurapraxia	Axonotmesis	Neurotmesis
Sunderland	I	II, III, IV	V
Nerve sheath	Intact	Intact	Interrupted
Axons	Intact	Some interruption	All interrupted
Wallerian degeneration	None	Some distal axons	All distal axons
Conduction failure	Transitory	Prolonged	Permanent
Potential for spontaneous recovery	Complete	Partial	Little or none
Time to spontaneous recovery	Within 4 weeks	Begins at 5–12 weeks, may take months	None, if not begun by 12 weeks

Table 1. Comparison of Seddon’s and Sunderland’s classifications of peripheral nerve injuries as applied to the trigeminal nerve (Adapted with permission from Bagheri and Meyer: Oral Maxillofac Surg Clin N Am; 2013. [58]).

Because of the progressive effects of Wallerian degeneration on nerve tissue distal to the site of nerve injury, time is of essence when attempting to achieve successful restoration of satisfactory sensory function [21–23]. Seddon [19], from his clinical experience, believed that the surgeon must be aggressive in the surgical treatment of closed peripheral nerve injuries, stating “If a purely expectant policy is pursued, the most favorable time for operative intervention will always be missed.” Ideally, one should aim his repair while nerve regeneration is most active: According to Holmes and Young [24], Schwann cells’ proliferative power peaks 2–3 weeks post injury and regress in about 3 months after injury.

As most of the injuries to the branches of the trigeminal nerve in relation to routine oral surgery procedures are of closed nature that would not be readily apparent to the clinician: that being said, patients may benefit from a period of observation prior to any surgical intervention. Generally, 3 months is the optimal time to wait between injury and attempted repair [25–28].

Indications for trigeminal nerve microsurgery include:

1. Observed nerve transection.
2. No improvement in sensation for more than 3 months.

3. Development of pain due to nerve entrapment or neuroma formation.
4. Presence of foreign body.
5. Progressively worsening hypoesthesia or dysesthesia (An unpleasant abnormal sensation, whether spontaneous or evoked).
6. Hypoesthesia that is intolerable to the patient.

Contraindications for trigeminal microsurgery may include

1. Development of central neuropathic pain.
2. Clinical evidence of improving sensory function.
3. Level of hypoesthesia that is acceptable to the patient.
4. Severely medically compromised patient unable to tolerate general anesthesia for microsurgery.
5. Excessive time elapsed since the initial injury.

3. Principles of surgical repair

Surgical treatment of peripheral nerve injuries has benefited from increased knowledge of neuropathophysiology and technical advances in equipment and surgical nuances over the past 30 years. The principles of treatment of peripheral nerve injuries elsewhere in the body apply equally to the trigeminal nerve and its peripheral branches [6, 7, 29, 30].

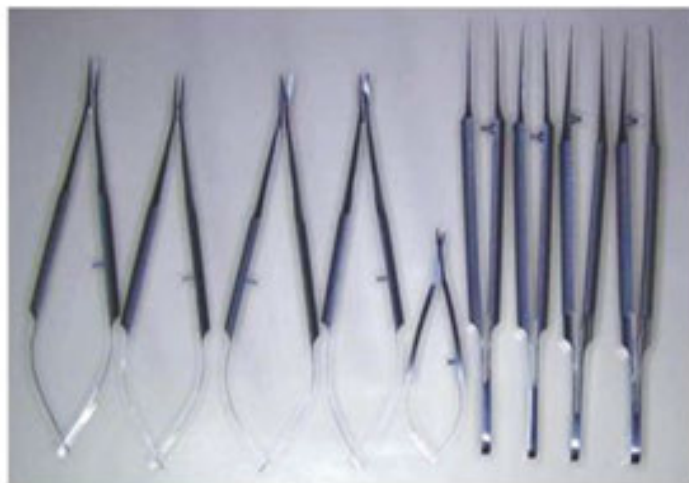

Figure 4. Basic set for microsurgery.

Microneurosurgical operations are performed with the patient under general with nasal endotracheal anesthesia in a sterile operating environment. The patient must remain perfectly

motionless while delicate maneuvers are performed on structures often less than 2 mm in diameter. This could be achieved with the use of muscle relaxant. Because most procedures are lengthy, the patient's bladder is catheterized and alternating compression pads are placed on the lower extremities when indicated. The surgical team usually consists of the surgeon, an assistant surgeon (preferably also trained in microsurgery), and a scrub nurse/surgical technician familiar with the instruments, objectives, and work habits of the surgeon. Specialized instruments including tissue forceps, scissors, small round burr mounted on high-torque high-speed handpiece and bone curettes, needle holders, and nerve hooks are sterilized and packaged in sets for each operation (**Figures 4 and 5**).



Figure 5. Rhotong curettes used to expose and dissect nerves from their bony canals.

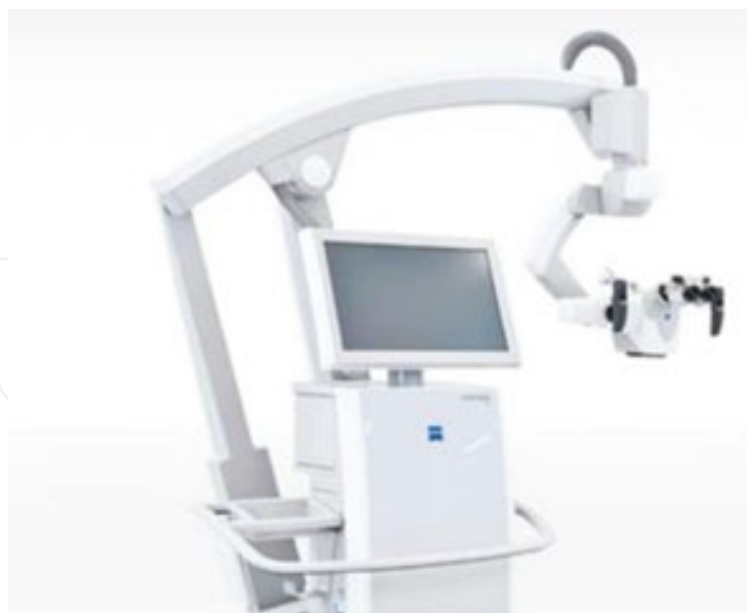

Figure 6. Pentero microscope from Carl Zeiss Meditec AG, Goeßwitzer Strasse, 07745 Jena, Germany.

Small, nonreactive material (7-0 to 9-0 monofilament) is used for suturing nerves. In repair of the peripheral branches of the trigeminal nerve, sutures are generally placed only within the

epineurium [31]. Wolford and Stevao [32] noted that the trigeminal nerve branches are polyfascicular in nature (non-grouped multiple fascicles of different sizes); hence, epineural repair offers better outcomes since perineural repair will likely yield more trauma due to the fact that dissecting each individual fascicle and suturing them together will lead to nerve atrophy and scarring. The operating microscope with hand controls and multiple ports for surgeon, assistant, and/or camera is essential for adequate magnification and visualization of delicate nerve structure (**Figure 6**).

O'Brien and Morrison [33] found no convincing evidence that a perineural repair is significantly better than an epineural repair if magnification is used, as magnification will allow more accurate alignment of the fascicles with the repair. The operating room table should be turned 90° relative to the anesthesiologist to allow for placement of the surgical microscope.

The surgeon and assistant are often seated and supportive rests for the wrists and forearms help to minimize hand tremors during surgical manipulations. Good hemostasis is required to aid in visualization and to minimize later formation of scar tissue in the operative site surrounding the repaired nerve. Hemostasis is achieved by control of the patient's blood pressure by the anesthesiology team, elevation of the operative site (patient head), placement of bone wax to staunch oozing from medullary bone, injection of epinephrine-containing local anesthetic solution, and the judicious use of bipolar cautery for electrocoagulation of small vessels within or adjacent to the nerve. Residual clotted blood in proximity to a nerve repair may increase the amount of connective tissue proliferation, leading to further scarring and compression-induced ischemia potentiating demyelination, hence the importance of maintaining a hemostatic surgical field. Miyamoto showed decreased axonal growth when repair tension exceeds 23 g [34]. Hausaman [35] emphasized that a tension-free co-adaptation is vital for functional return and recommended nerve grafting where nerve stumps cannot be repaired in a passive, tension-free fashion.

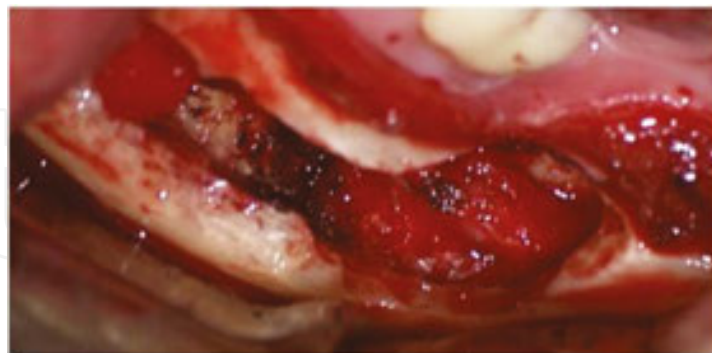


Figure 7. Lateral mandibular corticotomy to expose inferior alveolar nerve.

Generally, the mental and lingual nerves are exposed transorally, and the IAN may be approached either transorally or through a submandibular skin incision. The decision regarding which incision to use is largely determined by the degree of access and visualization afforded by a particular approach and, in some instances, by the surgeon's personal preference and experience. Exposure of the IAN can be accomplished after decorticating the lateral cortex

with skeletonization of the mental nerve branches. Regardless of which technique is used to access the mandibular bone, subsequent access to the nerve is achieved through lateral decortication (**Figure 7**).

The lingual nerve is approached transorally through either a paralingual or lingual gingival sulcus incision. The paralingual mucosal incision is made along the floor of the mouth parallel to the lingual plate, with dissection completed using blunt and sharp dissection to expose the nerve. Advantages of this approach include a smaller incision with direct visualization; however, transected nerve ends may retract from the field on exposure. The lingual gingival sulcus incision requires a lateral release along the external oblique ridge for complete flap mobilization and is extended along the lingual sulcus of the teeth to approximately the canine region. Once the flap is elevated in a subperiosteal plane and retracted, the nerve may be visualized from below through the overlying periosteum and bluntly dissected from the flap. This technique requires a larger incision than the paralingual incision; however, the proximal and distal nerve ends will not retract during surgical dissection (**Figure 8**).

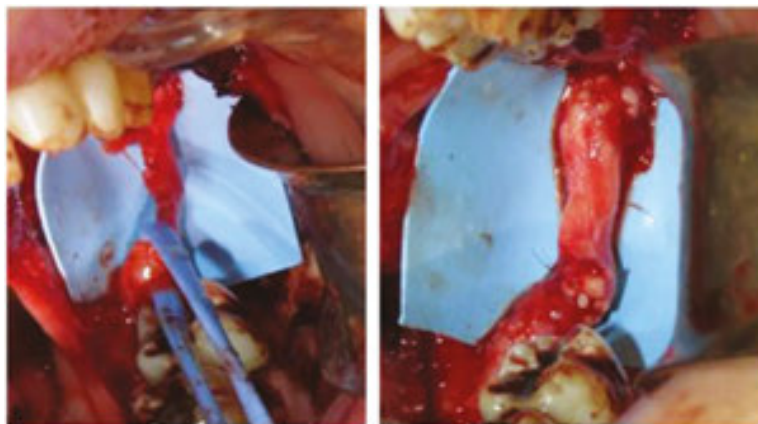


Figure 8. Lingual nerve repair with allograft Avance (AxoGen Inc, Alachua, FL, USA).

External neurolysis is the surgical procedure used to release the nerve from its tissue bed and remove any restrictions that can lead to conduction blockade or prevent recovery. Injury to soft tissues surrounding a nerve such as the lingual nerve can induce scar tissue and create a compressive neuropathic injury. The dissection of scar tissue from an intact nerve may potentiate the recovery of sensation. External neurolysis is usually performed under some magnification to grossly assess the nerve and to isolate any pathologic tissues. For patients with moderate sensory disturbances, external neurolysis may be the only surgical procedure indicated. Once the external neurolysis is completed, the nerve can be examined under magnification and clinical findings will dictate the need for any additional procedures such as removal of foreign bodies including endodontic filling material, tooth fragments, or dental implants.

Internal neurolysis may be indicated when there is evidence of nerve fibrosis or visible regions of nerve compression. The nerve may appear narrow or enlarged depending on the mechanism and type of injury. This procedure requires opening of the epineurium to examine the internal

structure of the nerve. Because the trigeminal nerve has a scarce amount of epineurium, any manipulation could potentially lead to further scar formation, hence the need for a delicate surgical technique. A longitudinal incision is made through the epineurium using a beaver blade to expose the internal structures in a procedure referred to as an epifascicular epineurotomy. With release of the epineural fibrosis, the nerve may expand, indicating a successful internal neurolysis procedure. If this is ineffective, a circumferential portion of the epineurium may be removed in a procedure called epifascicular epineurectomy. If no expansion and fibrosis is observed, the affected nonviable segment can be excised and the nerve prepared for primary neurorrhaphy. The epineurectomy procedure is rarely indicated because of the potential for further nerve injury through the surgical manipulation itself.

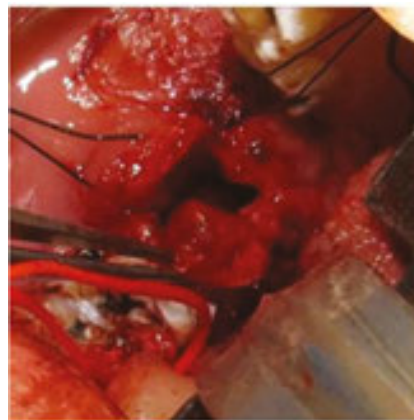

Figure 9. Exophytic neuroma of the lingual nerve.

Excision of neuromas is performed to prepare the nerve for co-adaptation by removing nonviable tissues in order to re-establish continuity. This procedure may be performed in cases of complete transection injuries or partial injuries in which there is an exophytic type of neuroma (**Figure 9**).

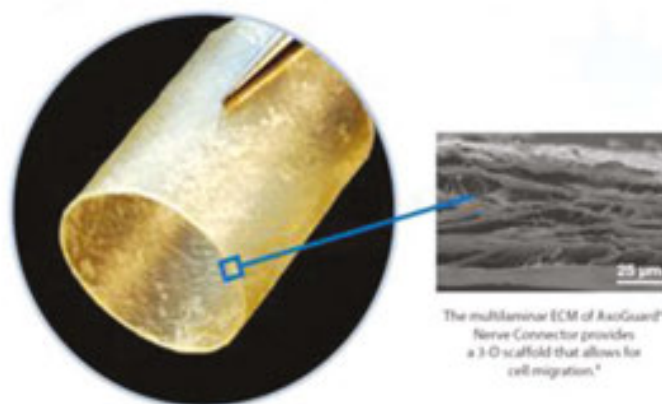


Figure 10. Axoguard Nerve Protector (AxoGen Inc, Alachua, FL, USA).

After excision of the neuroma-like tissue, the resulting stumps are examined under magnification to ascertain whether normal tissue is present as determined by the presence of herniated intrafascicular tissues. The goal is to allow the suturing of the two nerve ends together without tension in a process called primary neurorrhaphy. The two nerve stumps are approximated using 7-0 to 9-0 nonreactive epineural sutures. Three to four sutures are optimally placed to allow for nerve healing. It is the preference of the authors to wrap the nerve on completion with a resorbable membrane such as Axoguard Nerve Protector (AxoGen Inc, Alachua, FL, USA) to protect the surgical site and potentially minimize additional scarring in the region (Figure 10).

These materials may also provide a “seal” which ensures that growth factors released during nerve regeneration remain locally within the conduits themselves.

4. Factors affecting nerve repair success:

There are a lot of factors that determine the outcome of nerve repair. According to Wolford and Stevao [32], the factors affecting the success of the procedure are as follows:

1. Time between injury and repair.
2. Nature and extent of injury.
3. Vascularity.
4. Axons' orientation between the nerve and graft.
5. Distance between the injured nerve stumps.
6. Quality of the repair.
7. Tension of the repair.
8. Type and preparation of the graft.
9. Age and health of the patient.

Microneurosurgical repair outcome is greatly affected by number of elements, some of them pertain to the nerves themselves and others external to it. Type and degree of injury, blood supply to the surgical bed, and infections in addition to scarring are examples of external factors that affect the recovery of repaired nerves. Perhaps age and overall health of the patient are considered the most significant external factors, as better outcomes have been reported in younger healthier patients [36].

On the other hand, quality, technique, tension, and timing of the repair are the principle local factors that impact the repair outcome. Moreover, Wallerian degeneration is a unique phenomenon that will influence both the proximal and distal stumps of the injured nerve and may extend up to the first node of Ranvier [37]. Location of the injury along the nerve will affect the distance the axons have to travel, as the more proximally the injury is located, the more

regeneration is expected, however, the less access the surgeon will have. Finally, the type of nerve does have an impact on repair recovery as pure nerves (either motor or sensory), tend to recover more rapidly when compared to mix type (the trigeminal nerve is a mixed nerve).

5. Nerve grafting considerations

The gold standard for reconstructing a peripheral nerve gap when it is not possible to perform a tension-free primary neurorrhaphy has long been the autogenous nerve graft [38]. A nerve graft interposed between the proximal and distal nerve stumps eliminates tension across the repair and distal nerve regeneration approximates that occurring across a tension-free primary neurorrhaphy [39]. In the head and neck region, the great auricular nerve in the upper lateral neck has been the most frequently harvested donor for nerve gaps of less than 3 cm while the sural nerve in the lower extremity is more suitable for longer nerve gaps [40]. Each nerve harvest has its own morbidity, as patients will end up with a sensory deficit over the lateral aspect of the foot if the sural nerve is used, and to the ear plus lateral skull if the greater auricular nerve is harvested. The patient requires an informed discussion about the potential sensory loss as result of the harvest procedure, so they can determine which graft donor site they wish to choose. Miloro and Stoner [41] subjectively assessed outcomes following sural nerve harvest and found that most patients tolerated sural nerve harvest without significant donor site morbidity.

The donor nerve and the damaged nerve need to approximate one another in diameter, fascicular size, and numbers to ensure successful outcome. The average diameter of the inferior alveolar nerve is 2.4 mm and the lingual nerve is 3.2 mm [42, 43]. The greater auricular nerve is 1.5 mm in diameter and the sural nerve is 2.0 mm in diameter. There is also considerable difference between the size and number of fascicles of those nerves. Svane et al. [42] found that the inferior alveolar nerve has up to 18 fascicles at the third molar area, which decreases to about 12 fascicles at the mental foramen. The lingual nerve has been shown to have similar number of fascicles at the third molar site but wean down to about nine fascicles as it enters the tongue. As for the greater auricular and sural nerves, they have 9 and 12 fascicles, respectively [43], all of them are considered polyfascicular in nature; when we look at the cross-section, it is noted that the sural nerve is more flattened whereas the rest of them are more round in shape and 2–4 cm of length can be harvested when considering the greater auricular nerve as the donor site; on the other hand, the sural nerve may give up to 20–30 cm of nerve graft [44, 45].

When the lost soft tissue or bone included in a tumor resection or an avulsive injury is planned to be reconstructed with a vascularized free flap, nerves contained in such flaps, including the long thoracic nerve (in scapulohumeral flap) [9] or the medial antebrachial or lateral cutaneous nerve of the forearm (in a forearm flap) [12], provide easily accessible tissue for simultaneous trigeminal nerve reconstruction during the same operation. If the diameter of the donor nerve is less than that of the recipient, two or more cable grafts can be placed side by side to match the recipient nerve diameter and maximize neurotization of the distal nerve stump.

Reconstruction of the nerve gap with a processed allograft shows promise in laboratory research [46]. A product consisting of a human decellularized allograft, which has been made to be non-immunogenic and inert in the recipient's body but which provides a biological substrate for nerve regeneration (Avance; AxoGen Inc, Alachua, FL, USA) is available (**Figure 11**).

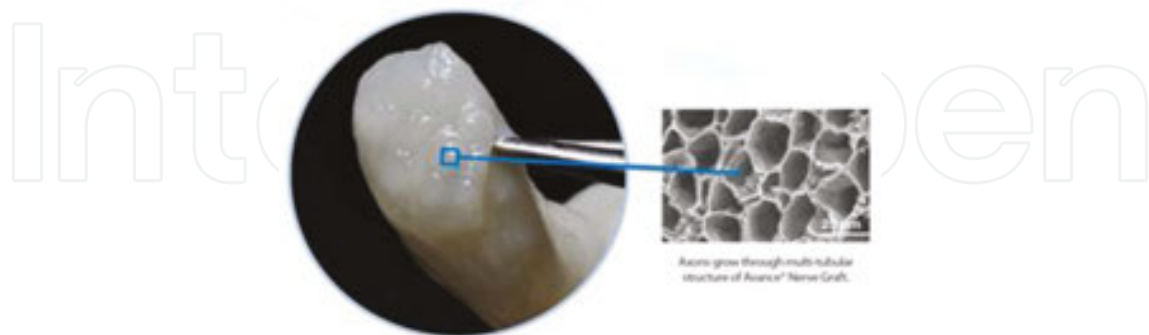


Figure 11. Allogenic nerve graft material Avance (AxoGen Inc, Alachua, FL, USA).

Successful inferior alveolar nerve reconstruction with a decellularized nerve allograft has been reported [47], and early results with repair of small gaps (<3 cm) are favorable in the authors' practice. This product is currently used to repair longer nerve gaps in the extremities. Although at present, this experience has not been reported for the reconstruction of large trigeminal nerve gaps, and the ultimate maximal length of a nerve gap that can be restored with the processed allograft has yet to be determined, it will undoubtedly play a greater role in nerve reconstruction in the maxillofacial region in the future.

Guided nerve regeneration with an autogenous vein graft conduit has been used to reconstruct short gaps in small digital nerves in the hand [48]. This technique is successful only in short nerve gaps (<3 cm) when used in peripheral trigeminal nerve repairs [49, 50]. An alloplastic nerve conduit (polyglycolic acid or polytetrafluoroethylene) has been used with limited success in trigeminal nerve injuries, but only in minimal nerve gaps [51, 52]. Such distances are commonly exceeded when reconstructing traumatic avulsive or oncologic surgical defects with nerve gaps of the trigeminal nerve; therefore, guided nerve regeneration has limited applicability.

6. Outcomes of surgical repair of trigeminal nerve injuries

Analyzing, interpreting, and comparing the results of microsurgical repair of trigeminal nerve injuries from multiple studies have frequently been a difficult task, because of lack of standardized methods for evaluating neurosensory function and a uniform grading system for surgical outcomes. In the past few years, studies conducted by experienced clinicians have established that microsurgical repair of trigeminal nerve injuries can result in improved sensory function for a large majority of selected patients. Pogrel reviewed his results, based on neurosensory testing, from microsurgical repair of 51 Trigeminal Nerve injuries (inferior

alveolar nerve = 17, lingual nerve = 34), and reported that 28 (54.9%) gained “some” or “good” improvement in sensory function. Nerve repair at more than 10 weeks after injury was less likely to be successful. No differences were observed in the results based on gender, with slightly better success in the inferior alveolar nerve group than in the lingual nerve group [53]. A long-term follow-up of repair of 20 lingual nerve injuries by Rutner et al. [54] using standardized neurosensory testing and patients’ subjective evaluations of their degree of recovery of sensory function found that 15 patients (85%) gained improvement in all neurosensory testing parameters, whereas 18 patients (90%) judged the repair to have achieved “some improvement”. Strauss et al. [55] reported microsurgical repair of 28 inferior alveolar nerve injuries evaluated by neurosensory testing produced “slight” (N = 12, 42.9%) or “significant” (N = 14, 50%) improvement, whereas only 2 repairs resulted in “no improvement” (7.1%).

Grade	Description
S0	No sensation
S1	Deep cutaneous pain in autonomous zone
S2	Some superficial pain and touch sensation
S2+	Pain and touch sensation with hyperesthesia
S3	Pain and touch sensation without hyperesthesia; static 2 point discrimination >15mm
S3+	Same as S3 with good stimulus, localization and static 2 point discrimination 7–15mm
S4	Normal sensation

Table 2. Medical Research Council Scale for grading sensory function of peripheral nerves as applied to the trigeminal nerve; Grades S3, S3+, and S4 are considered functional sensory recovery (Adapted with permission from Birch et al. *Surgical disorders of the peripheral nerves*. Philadelphia: Churchill Livingstone; 1998. p. 405–14.).

Subsequent studies have used neurosensory testing for preoperative and postoperative assessment of sensory function and have graded the outcome of surgical intervention for trigeminal nerve according to the Medical Research Council Scale (MRCS) for grading sensory nerve function (**Table 2**).

In a review of 60 surgically repaired trigeminal nerve injuries (inferior alveolar nerve = 4, lingual nerve = 56), 45 (75%) were found to have achieved functional sensory recovery (MRCS score of 3.0 or greater) in 1 year postoperatively [25]. The time from nerve injury to surgery did not statistically correlate with outcome, although all patients were operated on at less than one year after injury. Bagheri et al. [13, 56, 57] have reported their experience with microsurgical repair of a variety of trigeminal nerve injuries and causes. Among the total of 429 nerve repairs (inferior alveolar nerve = 186; lingual nerve = 222; mental nerve = 12; inferior orbital nerve = 7; labial branch nerve = 2), the success rate (achieving functional sensory recovery, MRSC grade of >3) varied from 81.7% for the inferior alveolar nerve to 90.5% for the lingual nerve [22, 23]. The success rate for inferior alveolar nerve repair increased to 87.3% when the nerve was reconstructed with an autogenous nerve graft in comparison with all other types of repair. In the most successful group of nerve repairs, the lingual nerve was repaired in the

overwhelming majority of cases by primary neurorrhaphy rather than an autogenous nerve graft [22]. This result probably reflects the much greater ease of creating sufficient mobilization of the lingual nerve to bring the proximal and distal nerve limbs together to close a nerve gap without tension than is the case with the IAN. Many of the patients were operated on more than one year following injury, allowing for an analysis of the effect of time on the outcome of nerve repair. At more than 9 months following lingual nerve repair or 12 months after IAN repair, there was a statistically significant decrease in successful outcome. Patient age was also a significant factor in outcome, with significant drop-off in success rate for inferior alveolar nerve repair after 51 years of age and a similar decline in favorable outcome for lingual nerve repair after age 45 years [58].

7. Summary

Patients who sustain large traumatic avulsive injuries or defects from ablative tumor surgery in the oral and maxillofacial region often have lost sensory function caused by injury or avulsion of one or more peripheral branches of the trigeminal nerve. Such injuries result in altered and/or painful sensation in the tissues previously supplied by these important sensory nerves. Normal orofacial functions, such as eating, drinking, oral hygiene, swallowing, and speaking, are dependent on adequate sensory input. Loss of this input creates significant orofacial dysfunction and jeopardizes the quality of life of afflicted patients. Nerve repair and reconstruction techniques have been revolutionized over time with the introduction of better instrumentation and improved knowledge of neurobiology. The successes of these techniques depend upon accurate assessment of the injury nature as well as early and meticulous repair so that the patient has the best chance for functional recovery. Whenever possible, repair or reconstruction of injured branches of the trigeminal nerve should be planned and performed in conjunction with reconstruction of other lost osseous or soft tissues in the oral and maxillofacial region. After surgery, an important aspect of global rehabilitation of such patients is a well-planned program of daily sensory re-education exercises to assist in achieving maximum potential sensory recovery and associated orofacial function and thus, an improved quality of life.

Author details

Ahmad Alshadwi^{1*} and Mohammed Nadershah²

*Address all correspondence to: aalshadwi@kfshrc.edu.sa

1 Department of Oral and Maxillofacial Surgery, King Faisal Specialist Hospital and Research Centre, Riyadh, Kingdom of Saudi Arabia

2 King Abdulaziz University, College of Dentistry, Jeddah, Kingdom of Saudi Arabia

References

- [1] Andrew BG, Zuniga T, Zuniga J. Nerve repair. In: Haggerty C, Laughlin R. (editors). *Atlas of Operative Oral and Maxillofacial Surgery*. Wiley Blackwell; Hoboken: New Jersey, USA, 2015. pp. 522–34.
- [2] Zuniga JR, Essick GK. A contemporary approach to the clinical evaluation of trigeminal nerve injuries. *Oral Maxillofac Clin North Am* 1992;4:353–67.
- [3] Meyer RA. Evaluation and management of neurologic complications in oral and maxillofacial surgery. In: Kaban LB, Pogrel MA, Perrott DH, editors. *Complications in Oral and Maxillofacial Surgery*. Philadelphia, PA: WB Saunders; 1997. p. 69.
- [4] Minahan RE, Mandir AS. Neurophysiologic intraoperative monitoring of trigeminal and facial nerves. *J Clin Neurophysiol* 2011 Dec;28(6):551–65.
- [5] Noma H, Kakizawa T, Yamane G, et al. Repair of the mandibular nerve by autogenous nerve grafting after partial resection of the mandible. *J Oral Maxillofac Surg* 1986;44:31–6.
- [6] Jabaley ME. Current concepts of nerve repair. *Clin Plast Surg* 1981;8:33–44.
- [7] Mackinnon SE. Surgical management of the peripheral nerve gap. *Clin Plast Surg* 1989;16:587–603.
- [8] Potter JK. Mandibular reconstruction. In: Bagheri SC, Bell RB, Khan HA, editors. *Current Therapy in Oral and Maxillofacial Surgery*. St Louis, MO: Elsevier/Saunders; 2012. pp. 483–96.
- [9] Schultes G, Gaggl A, Karcher H. Vascularized transplantation of the long thoracic nerve for sensory re-innervation of the lower lip. *Br J Oral Maxillofac Surg* 2000;38:138–41.
- [10] Woo BM, Kim DD. Radial forearm free flap. In: Bagheri SC, Bell RB, Khan HA, editors. *Current Therapy in Oral and Maxillofacial Surgery*. St Louis, MO: Elsevier/Saunders; 2012. pp. 572–9.
- [11] McCormick SU, Buchbinder D, McCormick SA, et al. Microanatomic analysis of the medial antebrachial nerve as potential donor nerve in maxillofacial grafting. *J Oral Maxillofac Surg* 1994;52:1022–5.
- [12] Shibahara T, Noma H, Takasaki Y, et al. Repair of the inferior alveolar nerve with a forearm cutaneous nerve graft after ablative surgery of the mandible. *J Oral Maxillofac Surg* 2000;58:714–7.
- [13] Bagheri SC, Meyer RA, Khan HA, et al. Microsurgical repair of peripheral trigeminal nerve injuries from maxillofacial trauma. *J Oral Maxillofac Surg* 2009;67:1791–9.
- [14] Catone GA, Merrill RG, Henny FA. Sublingual gland mucus-escape phenomenon—treatment by excision of sublingual gland. *J Oral Surg* 1969;27:774.

- [15] Chidzonga MM, Mahomva L. Ranula: experience with 83 cases in Zimbabwe. *J Oral Maxillofac Surg* 2007;65:79–82.
- [16] Meyer RA, Ruggiero SL. Guidelines for diagnosis and treatment of peripheral trigeminal nerve injuries. *Oral Maxillofac Surg Clin N Am* 2001;13:365–76.
- [17] Ziccardi V, Steinberg M. Timing of trigeminal nerve microsurgery: a review of the literature. *J Oral Maxillofac Surg* 2007;65:1341–5.
- [18] Seddon HJ. Three types of nerve injury. *Brain* 1943;66:237–88.
- [19] Seddon HJ. Nerve lesions complicating certain closed bone injuries. *J Am Med Assoc* 1947;135:691–3.
- [20] Sunderland S. A classification of peripheral nerve injuries producing loss of function. *Brain* 1951;74:491–516.
- [21] Waller AV. Experiments on the glossopharyngeal and hypoglossal nerves of the frog and observations produced thereby in the structure of their primitive fibres. *Phil Trans R Soc London* 1850;140:423.
- [22] Bagheri SC, Meyer RA, Khan HA, et al. Retrospective review of microsurgical repair of 222 lingual nerve injuries. *J Oral Maxillofac Surg* 2010;68:715–23.
- [23] Bagheri SC, Meyer RA, Cho SH, et al. Microsurgical repair of the inferior alveolar nerve: success rate and factors that adversely affect outcome. *J Oral Maxillofac Surg* 2012;70:1978–90.
- [24] Holmes W, Young JZ. Nerve regeneration after immediate and delayed suture. *J Anat* 1942;77:63–96.
- [25] Susarla SM, Kaban LB, Donoff RB, Dodson TB. Functional sensory recovery after trigeminal nerve repair. *J Oral Maxillofac Surg* 2007;65:60–5.
- [26] Robinson PP, Loesher AR, Yates JM, Smith KG. Current management of the inferior alveolar and lingual nerves as a result of removal of third molars. *Br J Oral Maxillofac Surg* 2004;42:285–92.
- [27] Alling CC. Dysaesthesia of the lingual and inferior alveolar nerves following third molar surgery. *J Oral Maxillofac Surg* 1986;44:454–7.
- [28] Hillerup S, Stoltze K. Lingual nerve injury II. Observations on sensory recovery after micro-neurosurgical reconstruction. *Int J Oral Maxillofac Surg* 2007;36:1139–45.
- [29] Dellon AL. Management of peripheral nerve injuries: basic principles of microneurosurgical repair. *Oral Maxillofac Surg Clin N Am* 1992;4:393–403.
- [30] Zuniga JR, Zenn MR. Principles of microsurgery. *Oral Maxillofac Clin N Am* 2001;13:331–42.

- [31] Ziccardi VB. Microsurgical techniques for repair of the inferior alveolar and lingual nerves. *Atlas Oral Maxillofac Surg Clin N Am* 2011;19:79–90.
- [32] Wolford LM, Stevao ELL. Considerations in nerve repair. *Bayl Univ Med Cent Proc* 16:152–6.
- [33] O'Brien B, Morrison WA. *Reconstructive microsurgery*. Edinburgh: Churchill Livingstone; 1987. pp. 137–64.
- [34] Miyamoto Y. Experimental study of results of nerve suture under tension vs grafting. *Plast Reconstr Surg* 1979;64:540–9.
- [35] Hausaman JE. *Plastic Surgery of the Head and Neck*. In: Volume 2, Stark RB, editors. Churchill Livingstone; London: UK, 1987. pp. 809–27.
- [36] McEwen I. Median and ulnar nerve injuries. *Aust N Z J Surg* 1962;32:28–47.
- [37] Grafstein B. The nerve cell body response to axotomy. *Exp Neurol* 1975;48:32–51.
- [38] Dodson TB, Kaban LB. Recommendations for management of trigeminal nerve defects based on a critical appraisal of the literature. *J Oral Maxillofac Surg* 1997;55:1380–6.
- [39] Mackinnon SE, Dellon AL. *Surgery of the peripheral nerve*. New York, NY: Thieme; 1988. p. 91.
- [40] Meyer RA. Nerve harvesting procedures. *Atlas Oral Maxillofac Surg Clin N Am* 2001;9:77–91.
- [41] Miloro M, Stoner JA. Subjective outcome following sural nerve harvest. *J Oral Maxillofac Surg* 2005;63:1150–4.
- [42] Svane TJ, Wolford LM, Milam SB, Bass RK. Fascicular characteristics of the human inferior dental nerve. *J Oral Maxillofac Surg* 1986;44:431–4.
- [43] Brammer JP, Epker BN. Anatomic-histologic survey of the sural nerve: implications for inferior alveolar nerve grafting. *J Oral Maxillofac Surg* 1988;46:111–7.
- [44] Abbey PA, LeBanc JP, Lupkiewicz S, Stewart CM. Fascicular characteristics of the human lingual nerve: implications for injury and repair. *J Oral Maxillofac Surg* 1987;45:M7.
- [45] Jones RHB. Repair of the trigeminal nerve: a review. *Aust Dent J* 2010;55:112–9.
- [46] Whitlock EL, Tuffaha SH, Luciano JP, et al. Processed allografts and type 1 collagen conduits for repair of peripheral nerve gaps. *Muscle Nerve* 2009;39:787–99.
- [47] Shanti RM, Viccardi VB. Use of decellularized nerve allograft for inferior alveolar nerve reconstruction. *J Oral Maxillofac Surg* 2011;69:550–3.
- [48] Chiu DT, Strauch B. A prospective clinical evaluation of autogenous vein grafts used as a nerve conduit for distal sensory nerve defects of 3 cm or less. *Plast Reconstr Surg* 1990;86:928–34.

- [49] Miloro M. Inferior alveolar nerve regeneration through an autogenous vein graft. *J Oral Maxillofac Surg* 1996;54(Suppl 3):65–6.
- [50] Pogrel MA, Maghen A. The use of autogenous vein grafts for inferior alveolar and lingual nerve reconstruction. *J Oral Maxillofac Surg* 2001;59:985–8.
- [51] Crawley WA, Dellon AL. Inferior alveolar nerve reconstruction with a polyglycolic acid bioabsorbable nerve conduit. *Plast Reconstr Surg* 1992;90:300–2.
- [52] Pogrel MA, McDonald AR, Kaban LB. Gore-Tex tubing as a conduit for inferior alveolar and lingual nerve repair: a preliminary report. *J Oral Maxillofac Surg* 1998;56:319–21.
- [53] Pogrel MA. The results of microneurosurgery of the inferior alveolar and lingual nerve. *J Oral Maxillofac* 2002;60:485–9.
- [54] Rutner TW, Ziccardi VB, Janal MN. Long-term outcome assessment for lingual nerve microsurgery. *J Oral Maxillofac Surg* 2005;63:1145–9.
- [55] Strauss ER, Ziccardi VB, Janal MN. Outcome assessment of inferior alveolar nerve microsurgery: a retrospective review. *J Oral Maxillofac* 2006;64:1767–79.
- [56] Bagheri SC, Meyer RA. Management of trigeminal nerve injuries. In: Bagheri SC, Bell RB, Khan HA, editors. *Current Therapy in Oral and Maxillofacial Surgery*. St Louis, MO: Elsevier/Saunders; 2012. pp. 224–37.
- [57] Bagheri SC, Meyer RA, Khan HA, et al. Microsurgical repair of the peripheral trigeminal nerve after mandibular sagittal split osteotomy. *J Oral Maxillofac Surg* 2010;68:2770–82.
- [58] Bagheri SC, Meyer RA. Microsurgical reconstruction of the trigeminal nerve. *Oral Maxillofac Surg Clin N Am* 2013;25:287–302.