

We are IntechOpen, the world's leading publisher of Open Access books Built by scientists, for scientists

6,900

Open access books available

186,000

International authors and editors

200M

Downloads

Our authors are among the

154

Countries delivered to

TOP 1%

most cited scientists

12.2%

Contributors from top 500 universities



WEB OF SCIENCE™

Selection of our books indexed in the Book Citation Index
in Web of Science™ Core Collection (BKCI)

Interested in publishing with us?
Contact book.department@intechopen.com

Numbers displayed above are based on latest data collected.
For more information visit www.intechopen.com



State-of-the-Art Immediate Implant Therapy

Peter R. Hunt and Laura M. Ceccacci

Additional information is available at the end of the chapter

<http://dx.doi.org/10.5772/63254>

Abstract

Implantology is the newest major branch of dentistry and one that is rapidly becoming more and more important. A subject that was ridiculed 40 years ago is now transforming dentistry. Implantology gives hope for the end-stage edentulous patient unable to wear dentures. It enables those facing loss of a tooth to avoid bridgework or removable partial dentures. It is often simpler, faster, and far more effective over the long term to replace a failing tooth with an implant with a restoration than to do a root canal, post-core, and crown. This chapter discusses immediate implant therapy, which greatly reduces surgical interventions and shortens total treatment time, while preserving the alveolar structures which are rapidly lost when a tooth is extracted.

Keywords: immediate implant therapy, socket regeneration with implants, single-stage implant surgery, immediate placement, immediate loading

1. Introduction

Traditionally, implants have been placed into healed ridges where the teeth had been removed from a previous procedure. For an edentulous patient there was no other option, but to remove the teeth quickly before placing implants, which became a standard. The traditional protocol was then to reflect a soft tissue flap, to prepare a channel in the bone, to place the implant with a cover screw, and then to cover the soft tissue flap back over the region for a period of three to six months. At that time, another soft tissue flap was raised and a connection made to bring the implant transgingivally so that it could be brought into function. This meant the patient was subject to three surgical interventions: the extraction, the implant placement, and the second-stage exposure. With healing cycles in place, therapy from extraction to second-stage exposure and final restoration could take a year or more to complete.

Although this protocol can ensure a stable and functioning implant, it has some unfortunate sequelae. Most obvious are the time, expense, and discomfort for the patient associated with the three surgical procedures. Only recently have we started to appreciate that there is another, more significant issue with this three-stage protocol. This is the significant loss of alveolar bone and the periodontal soft-tissue complex in the region of the extraction. This can be extremely difficult to correct with augmentation procedures. Aesthetic and functional deformities remain. Immediate implant therapy can reduce the number of surgical procedures and expedite therapy, while at the same time minimizing the loss of alveolar and gingival structures, thus reducing aesthetic and functional deformities.

2. Post-extraction course

2.1. Ridge collapse

When a tooth is removed, the hard and soft tissue complex surrounding the tooth undergoes a series of changes. The soft tissues immediately collapse down, having lost the support from the tooth (**Figure 1**).

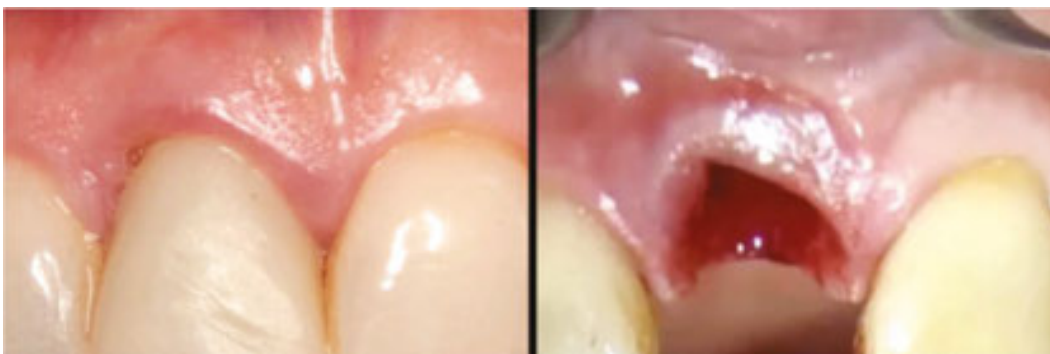

Figure 1. As soon as the right central incisor is removed, the soft-tissue complex starts to collapse.

Bleeding into the socket rapidly turns to a blood clot. Very quickly epithelium starts to migrate over the top of the blood clot. By this time blood vessels have invaded the blood clot and stem cells are proliferating, differentiating, and maturing. The region becomes progressively organized so that connective tissue and then bone start forming (**Figure 2**).

In time, there are major changes in the soft tissue covering the ridge. After the ridge epithelializes over, the new “Ridge” gingiva blends with the remnants of the original marginal attached gingiva. This lasts for a relatively short time because the region of attached gingiva starts to shrink, sometimes so much that only a very narrow band of attached gingiva remains on the alveolar crest (**Figure 3**).

As time passes, the bone in the crestal region shrinks, more so on the labial than on the lingual. The ridge height diminishes and the overall bone volume decreases. The tough cortical bone thins and the medullary bone starts to atrophy as there is less function with the teeth missing.

The more time that passes, then the more bone loss that is likely to occur [1–3]. All these factors suggest that it would be better to do everything possible to stop the shrinkage process starting when the tooth is removed. Immediate interceptive therapy is required.

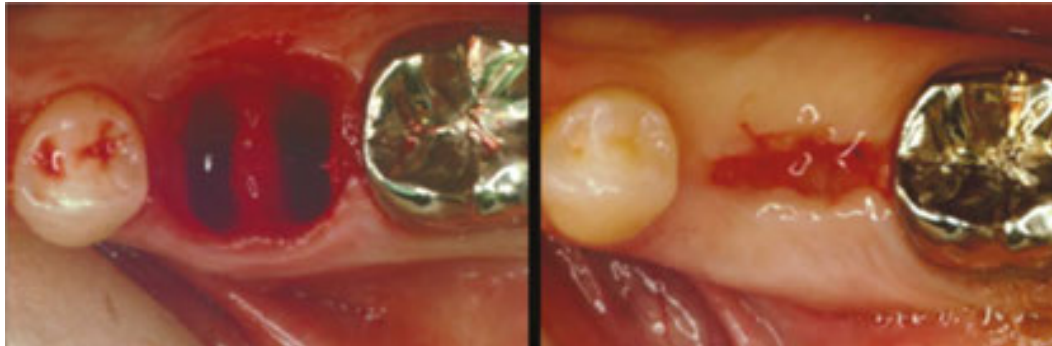


Figure 2. Left: The first molar has just been removed. Right: One month later.

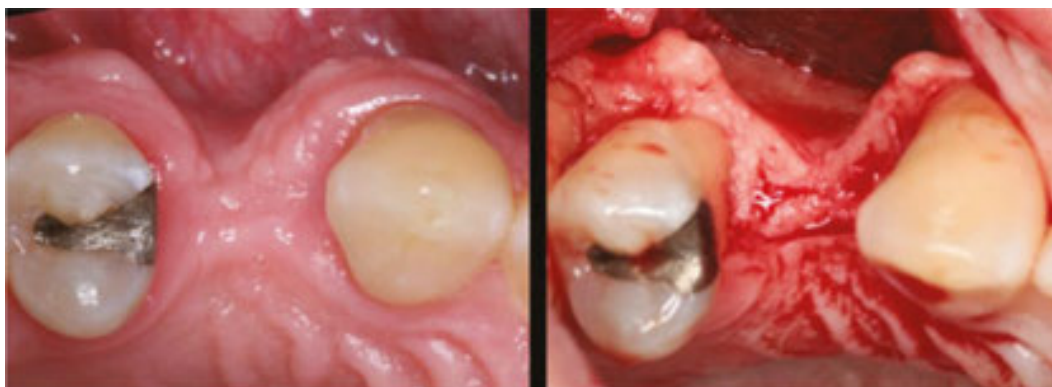

Figure 3. In this case, following the loss of the premolar, both the attached gingiva and the alveolar bone shrunk down extensively.

3. Requirements for immediate implant placement

3.1. Successful removal of the tooth

Immediate placement is precluded upon careful removal of teeth. The prime aim is to leave a socket with intact bone walls with sufficient residual bone to stabilize an implant. Unfortunately, this is one of the major uncertainties in the whole protocol, because some teeth can be extremely resistant to removal, others can fracture readily. If not careful, the bone housing for the tooth can easily be lost in the tooth removal process. For these reasons, it is quite standard to split multi-rooted teeth into their individual roots. Each root can then be removed individually. Removing labial bone to get at decayed or fractured off at the gum level teeth is generally quite harmful as this reduces the height of the residual socket. Instead, periostomes are better

used for loosening and elevating the roots. Ultrasonic periosteal tips are particularly useful to expedite root removal (**Figure 4**).

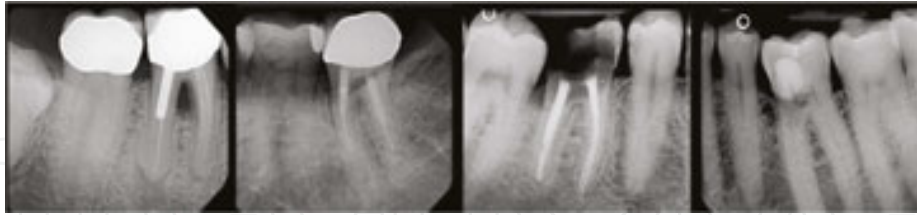


Figure 4. Teeth difficult to remove. Left: Large post in distal root with bulbous root end. Left Center: Long, thin deep roots. Right Center: Deep decay, poor tooth structure, large root canal fillings. Right: External resorption, very deep roots, proximity to neighboring tooth.

3.2. Removal of infection and granulation tissues in the region

Once the tooth has been removed from the socket, it is critical to remove three tissues from the socket: Remnants of the gingival complex, deeper granulomas, and periapical lesions.

3.2.1. Remnants of the gingival complex

Where the teeth have been periodontally involved it may take some time to work around the socket to remove any soft tissue remnants with curettes and excavators. In some sockets, there may be infected epithelial remnants which pass down quite deep. These need to be removed so that they are not taken down deeper into the region when an implant is placed. Both infections and epithelial down-growths are both associated with loss of osseointegration; removing them allows for successful implant therapy (**Figure 5**) [4].

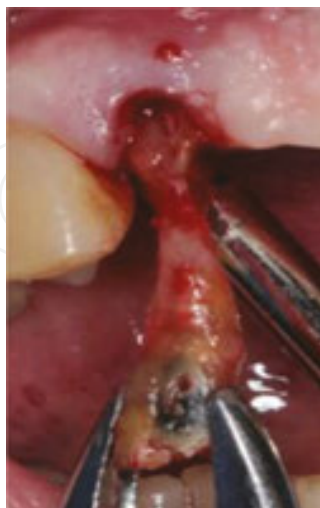

Figure 5. When this tooth was being removed, a considerable amount of epithelial remnants and connective tissue granulations came out with it. Granulations can often be more extensive than expected. They take time and considerable effort to remove.

3.2.2. Deeper granulomas

More difficult to remove are deeper granulomas residing between roots. These can be of periodontal or endodontic origin. It is necessary to work around and under the granuloma with spoon excavators. Once they have been separated then they can be lifted up and out of the socket. Ultrasonic debridement and/or de-granulation with rough-cut burs can speed the process (**Figure 6**).

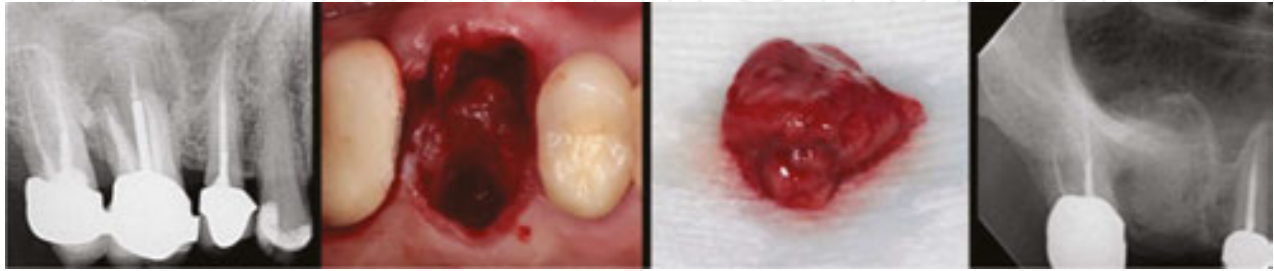


Figure 6. This molar has obvious trifurcation involvements and periapical infection. With the tooth removed, the granulations are apparent, considerably more than expected. When cleaned out, a large sinus perforation to the distal was apparent. There was no ability to stabilize an implant, so the procedure was changed to a “Socket Regeneration” procedure.

3.2.3. Periapical endodontic lesions

The most difficult region to remove residual infection from is the apical region. Sometimes an apical granuloma will come out with the root and this is always good to see. There are other times where it may be necessary to open up the apical region beneath the root space or to access the lesion from a lateral approach. No matter what, it is critical to do this de-granulation for an implant placed in the region to be successful (**Figure 7**).

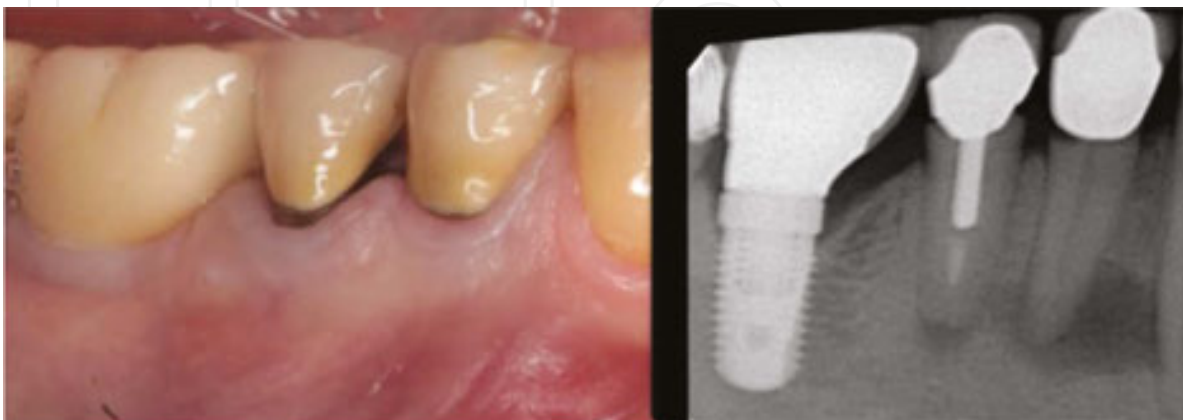


Figure 7. Both these premolars have apical infections and may break off at the gum level because of marginal decay. A procedure is needed to remove the teeth, debride the region and place implants. See **Figures 35** and **36** for treatment.

4. Ability to position and stabilize an implant in the remaining bone volume

Once the tooth has been removed and the region de-granulated, attention must turn to positioning and stabilizing an implant correctly. There are two different and sometimes incompatible considerations.

4.1. Implant positioning

These days it is the abutment which produces the desired emergence form as it exits the soft tissue collar. An implant platform is round but the form of a tooth as it emerges from the gingiva is highly variable. So the abutment that starts out round at the implant platform needs some vertical height, thickness of gingiva or “running room” to change to the desired form as it exits the gingiva. This implies two things: first, positioning the implant platform is critical, as it needs to serve as the base for the abutment; second, the angle of the implant, the diameter of the implant, and the length of the implant are less critical (**Figure 8**).

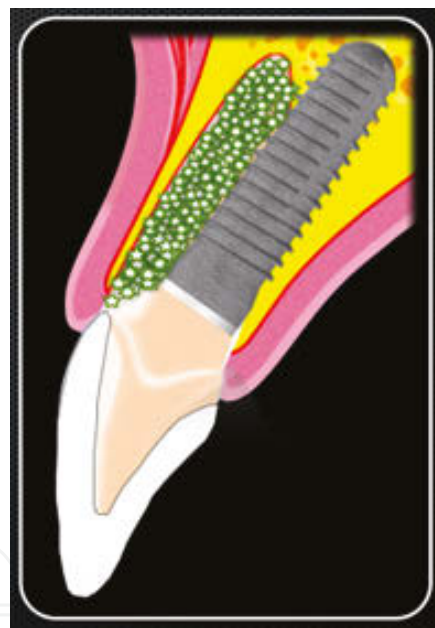

Figure 8. Modern implant environment principles.

Implant: oriented into palatal bone wall to gain stability.

Platform Placement: deeper to allow room for Emergence Profile Development

Augmentation: to fill out the residual socket, preserve labial bone wall, and prevent resorption

Abutment: to develop the desired “Tooth Form” and to support hard and soft tissue contours

Positioning an implant into a healed bony ridge is in many respects simpler than placing one into an extraction socket for several reasons.

4.1.1. The original socket may divert drills and take them off course

This is most common in multi-rooted sockets where the central core of bone can be very hard and it can be very difficult to establish a starting point for a pilot drill. The drill tends to be diverted down and into one of the root spaces (**Figure 9**).

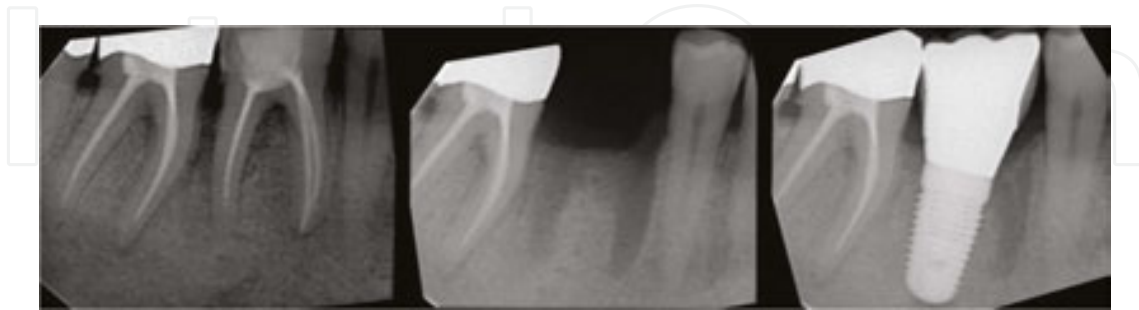

Figure 9. This vertically fractured molar was removed. Instead of the channel being established centrally in the furca region, it was diverted down the distal root space. A custom abutment was needed to manage the situation.

4.1.2. The original socket is not where implant support is available

A common example of this is in the maxillary anterior region where it is not a good idea to place an implant down the socket as this will mean that the implant gets placed too labial. This jeopardizes the thin labial bone wall of the socket. It is better to intentionally angle the implant into the palatal wall of the socket to gain the desired stability and position (**Figure 10**).

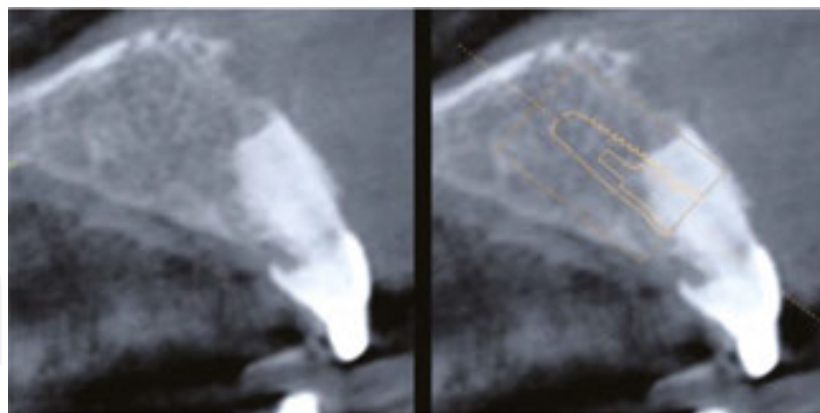


Figure 10. This central incisor needs replacing. The labial bone wall is very thin. The implant needs to be set into the palatal bone wall. The proposed position is outlined.

4.1.3. The original position of the tooth may not be the best position for an implant

The tooth may have an original malocclusion or have drifted, rotated, or changed position as part of a mesial drifting or bite collapse process. This can mean that it would be better to have the implant in a slightly different position (**Figure 11**).

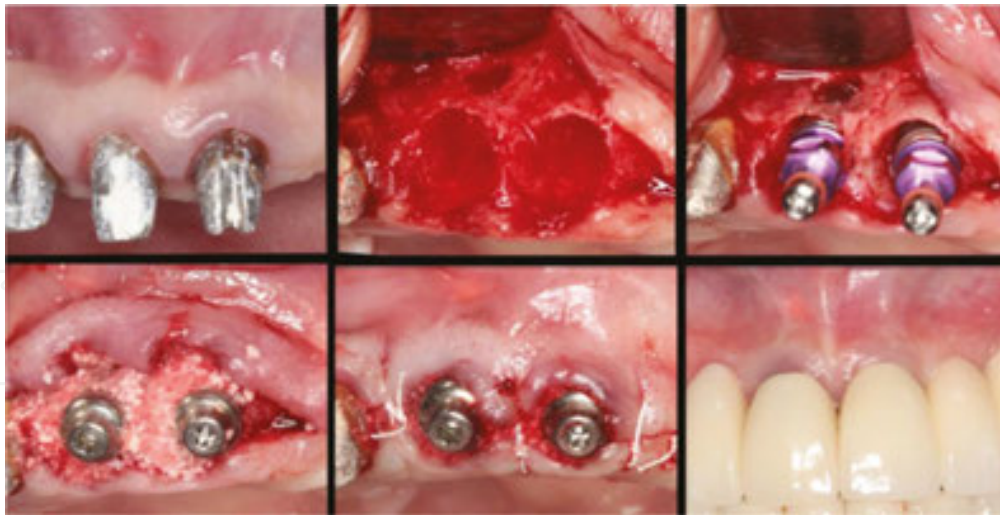


Figure 11. This case shows failing incisor teeth. These were extracted and immediately replaced with Camlog® implants and gingivaformers. Notice how the implants were moved laterally in the sockets to improve the midline of the final case.

4.2. Stabilizing regions

The ability to gain stability for a dental implant in extraction sockets very much depends on the form of the socket. The bone walls in a socket are generally quite firm and stable, so a small amount of bone can provide adequate stability for an implant. Of course, if immediate loading is required at the same time then a much higher level of stability is required [5, 6].

The region providing stabilization for an implant within a recent extraction socket can be quite limited and requires careful planning. Most times the socket will be larger than the implant. Often the only place where the implant engages the bone is in the apical region where the bone walls converge. However, one must be careful because all too often the socket is compromised in one way or another. For example, many sockets have little or no labial bone and this means that the implant needs to be positioned more centrally within the available bone complex. In socket management, it is always necessary to appreciate how the socket is liable to heal, both with or without an implant.

Sometimes, particularly in the molar regions, there is no obvious place for stabilizing an implant in the former socket. If bone is available beyond the residual socket, it may be possible to use as little as 2–3 mm to stabilize the implant. In the mandible, it is necessary to carefully check the location of the mandibular nerve as this may prevent this “Going beyond the socket” procedure. All that is needed is to make sure that the implant is stable. Obviously, it will not be possible to immediately load the implant with this limited amount of stabilization (**Figure 12**).

In the maxilla, it may be necessary to perform an intentional sinus lift to gain stability for the implant. The bone of the sinus floor, though it may be thin, is generally very stable. All that is necessary is to penetrate the floor in a safe way, such as with an ultrasonic device. The hole is

then expanded with a hand-held osteotome. The final diameter of the channel should be matched to the apical diameter of the tapered implant that will be placed.

The sinus floor membrane is lifted with the osteotome. Bone graft is then placed and taken up into the sinus with the osteotome. A tapered, screw-threaded implant is placed into the channel. As it is screwed to place, the implant will gain increasing stability as the wider part of the implant gains traction. The sinus-lifted portion will also provide enhanced long-term stability (**Figure 13**).

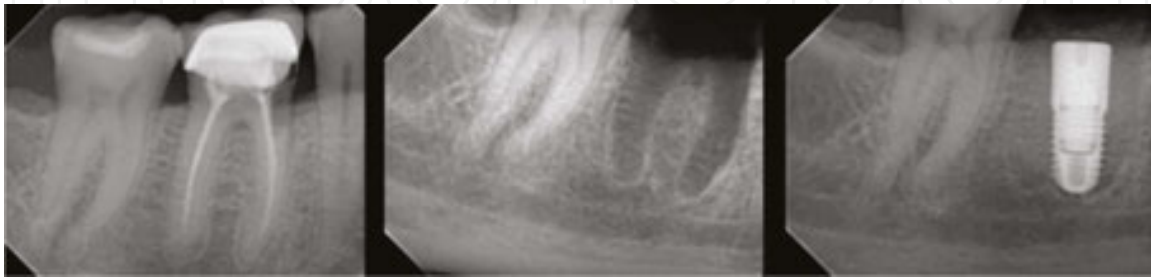

Figure 12. It would not have been sensible to take the channel deeper to gain stability because of the proximity of the nerve. Instead, the Pilot Drill was angled down the mesial root space, and then the channel was uprighted and expanded with progressively larger drills. The final implant placement was nicely centered and the implant was stable.

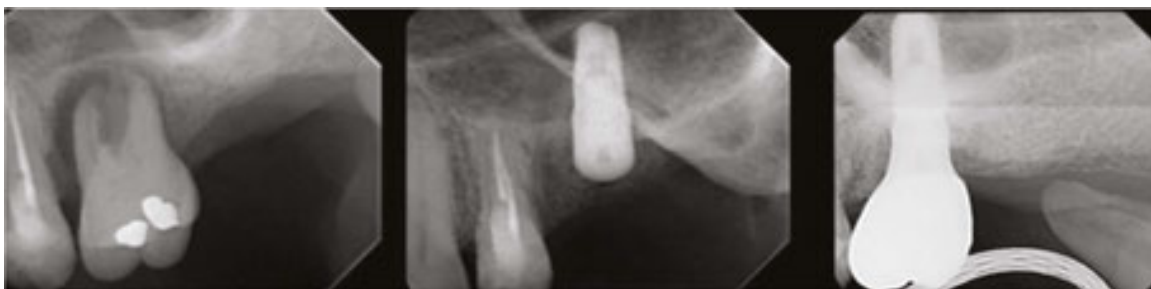

Figure 13. There was nothing much holding this molar in place. It was removed, the region debrided, and an intentional sinus lift performed to gain additional bone volume to stabilize an implant, so gaining additional support. Both the sinus region and the residual socket were grafted. Both regions healed to provide adequate support for the implant and restoration.

5. Provision of an osseous coagulum surrounding the implant

If an implant is adequately stabilized in a fresh socket, then much of the implant surface is liable to be exposed to the oral environment, allowing it to become contaminated; the result is that the implant will fail to osseointegrate. Instead of just leaving a blood clot around the implant, most operators feel more comfortable with filling the voids between the implant and the bony walls of the socket with a bone graft; this not only helps with implant osseointegration but also helps in preventing ridge collapse [7]. The term “Osseous Coagulum” implies supplying all the components which surround and protect the implant following placement.

These help stabilize the blood clot and allow a secure environment for it to develop stem cells, to re-organize, develop osteoblasts, and develop native bone ready to osseointegrate to the implant.

Certain types of bone graft, the slow-resorption materials, have been shown to resist or slow down the ridge resorption process which starts as soon as a tooth is removed [7–9]. At the same time, they encourage new bone to develop. The two aspects are synergistic. They help each other, so the term “osseous coagulum” implies a region which will in time become bone.

New bone formation occurs most predictably within the four walls of a socket. This is why everything possible is done to preserve the four walls of a socket during tooth removal and why the implant platform is placed down below the bone crest. If one bone wall is missing, then a membrane is always placed to provide the environment for its regeneration (**Figure 14**).

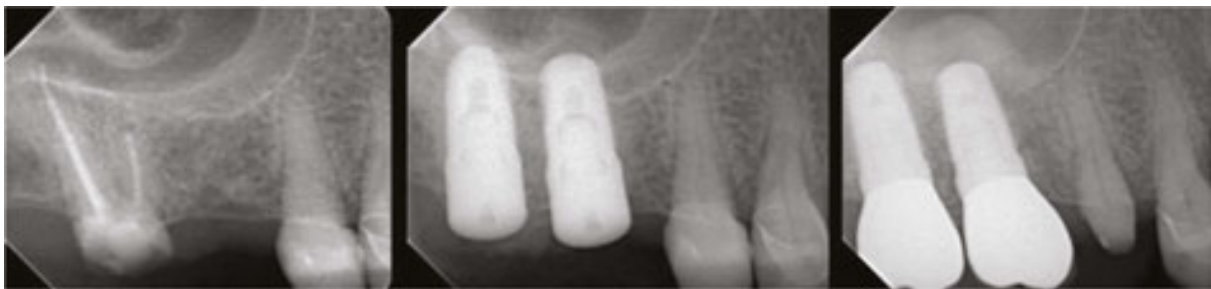

Figure 14. In this case an Osseous Coagulum Zone was needed in the region of the extracted roots of the second molar and also in the sinus lift region for the first molar implant. This was all managed in one surgical procedure when the second molar was extracted.

6. Wound closure

Closing the wound is the last part of the procedure. The aim is to protect the implant within the osseous coagulum, contain the graft materials, prevent early contamination and infection, stabilize the blood clot, and prevent bleeding. It is not just a matter of flap closure. One also has to consider the devices used to cover the implant including cover screws, extended height healing caps, and abutments of one form or another. Each of these components has a specific indication.

6.1. Component options

6.1.1. Cover screw

Cover screws are flat, low-profile devices often supplied with the implant. These are mostly used in traditional therapy where primary closure of the flaps over the region containing the new implant is desired (**Figure 15**).

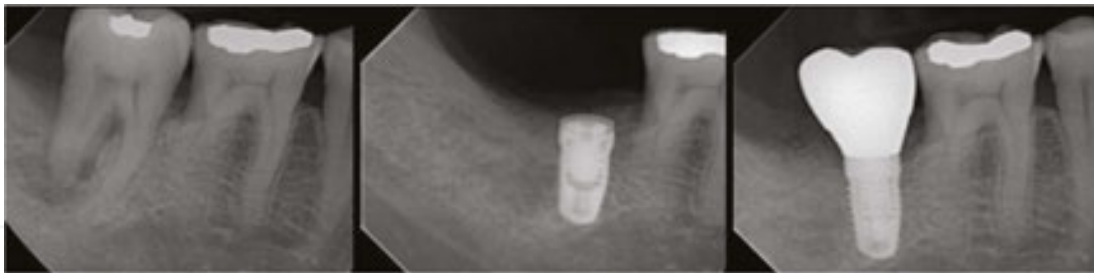


Figure 15. This case had a large periodontal defect with complete involvement of the distal root. The tooth was extracted, the region debrided and an implant with a cover screw placed at the same time. The deficient region in the distal root region was augmented with Bio-Oss Collagen® (Geistlich). There was primary closure over the implant. The region recovered and was restored with a custom abutment and final crown.

6.1.2. *Gingivaformer*

Gingivaformers come in various heights and configurations. Traditionally they have been placed at second-stage implant exposure surgery to form a trans-gingival passage into the mouth. These days they are often placed at the time of implant placement, with flaps being brought up around the outside of the gingivaformer (**Figure 16**).

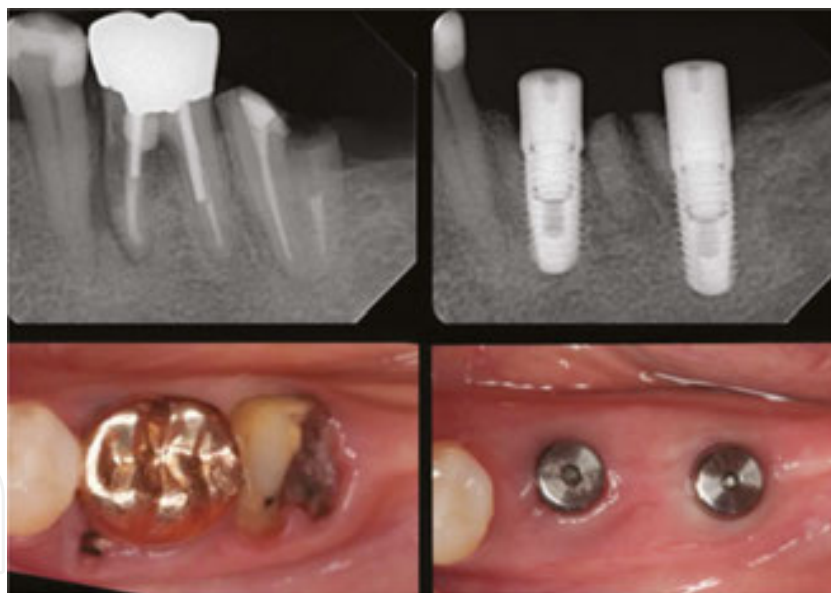


Figure 16. Left: Two failing molars. They were removed and immediately replaced with implants and hard- and soft-tissue augmentation. Right: Three months later, healing is evident. The case is now ready for restoration.

6.1.3. *Abutment*

Abutments provide an emergence and form which is more tooth-shaped. They also carry a restorative post, so these devices are used for immediate implant placement where immediate loading and a provisional restoration are required. Custom zirconia sleeves secured to a Ti-CAD base devices are generally more useful than off-the-shelf components because they allow

for custom form, good gingival reaction, and tooth-like color. Zirconia has better gingival adhesion than Titanium or PEEK plastic components. We use them for both temporary and final restorations (**Figure 17**).

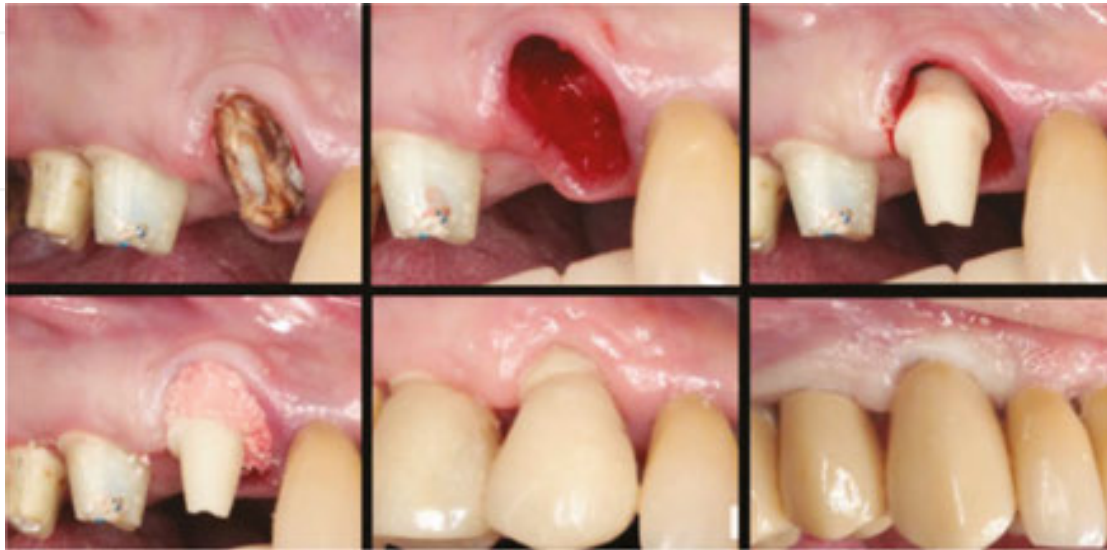

Figure 17. In this case, when the tooth was extracted, an implant was placed which supported a provisional abutment. Graft material was placed around the abutment to fill the channel defects. Despite the exposed graft material which was stabilized by cyanoacrylate (not shown), the wound healed-over fast and at one month appears very normal. Notice how the gingival margin healed well up on the abutment. The final implant-supported restoration improved the form and appearance of the original tooth.

6.2. Soft tissue closure

6.2.1. Primary closure

Traditionally, implant placement has been done by raising soft tissue flaps in the region adjacent to the implant site to allow access to prepare the bone channel and to place the implant(s). At the end of the procedure, the soft tissue flaps were closed back over the wound with what is called Primary Closure. With immediate placement of implants into extraction sockets, getting primary closure is more complex. To accomplish this, it is necessary to raise flaps and advance them to cover over the socket. The bigger the socket the more difficult it is to close over. If bone and soft tissue augmentation has been done, then more bulk has been added to the region, and this can increase the problems of getting closure. Finally, swelling and hematoma formation can make obtaining and maintaining primary closure still more difficult. The traditional solution to this problem is to make the flaps more mobile by raising them further and by severing the periosteum under the free mucosal part of the flap. However, this has the effect of moving attached gingiva from the sides of the socket to the top of the socket. There's no real problem with that in the short term, but in the long term it's essential to have attached gingiva attached to the alveolar bone outside and around an implant. It means

an additional surgical procedure is needed not only to place a trans-gingival component, but also to raise the attached gingiva in the region and to displace it out and around the gingiva-former.

However, unless large-scale augmentation is being used, or the patient has a predisposition to implant failure, then primary closure is not required. Partial closure is quite adequate in most situations.

6.2.2. *Partial closure*

“Partial closure” is where the flaps are brought up around a gingivaformer or abutment placed in the implant, instead of a cover screw. This has several advantages. The surgical procedure is less invasive and it makes for a “single-stage” procedure. This is where there is no need for a secondary implant exposure procedure. It means that the overall treatment time is reduced by several months. The soft tissue complex is also more mature and stable than would be normal in a traditional two-stage procedure. It is easy to provide augmentation under the flaps, with bone graft and thickness increasing membranes, thus increasing the gingival thickness and providing a “safety zone” to protect the rough surface of the implant from becoming contaminated at an early stage. Finally, it means that attached gingiva surrounds the gingivaformer or abutment and this provides better protection for the implant and a more “Natural” appearance as the implant restorative component emerges through the gingiva. We tend to add a collagen-based bone graft at the base of the gingivaformer to fill any channel defects that may be present between the implant and the inner walls of an extraction socket. This is heaped up to increase gingival thickness. This provides a “safety zone” to protect the rough surface of the implant from becoming contaminated and infected at the outset (**Figure 18**).

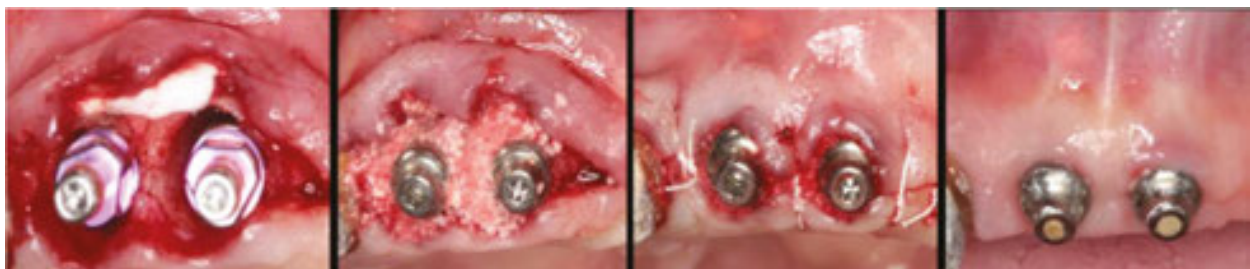

Figure 18. These front teeth were failing, so they were removed. Camlog® implants and gingivaformers were placed. The region was augmented with Mucograft® and Bio-Oss Collagen® (Geistlich) and the flaps were approximated. Healing proceeded nicely and a good final outcome was obtained.

6.2.3. *Membrane closure*

It is useful to think of ways which avoid extensive soft tissue mobilization and primary closure, one which leaves the attached gingiva where it is, or increases and thickens it. The trend is to use membranes of one form or another to cover the socket, the implant, the gingivaformer, and the bone graft within the osseous coagulum and the whole area.

Essentially, this is taking up the well-established principles of “socket regeneration” [7–9]. This is where extraction sockets are filled with bone graft of one form or another, and then covered over with various membranes. These range from Teflon-based plastic membrane, to collagen membranes to artificial membranes derived from polylactic acid or biodegradable co-polymers. Most of these seem to work quite satisfactorily, although as healing occurs, some shrinkage of the complex can be anticipated. The key is to get “wall-to-wall” regeneration within the socket. The membrane has several functions. First, it stabilizes the blood clot and bone graft mixture which enables it to consolidate, start healing, and become organized. With some membranes such as collagen membranes, the membrane material becomes partly or completely incorporated into the blood clot. The region soon becomes epithelialized. In others, such as the Teflon membranes, epithelialization starts to occur underneath the membrane. The individual processes do not matter too much as all the membranes serve to protect the healing wound and to reduce the potential for trauma, contamination, and infection. By about three weeks, the region is able to manage on its own because it is covered by epithelium with connective tissue immediately underneath. In short, it is not essential for complete primary closure of soft tissue flaps over a socket regeneration site. Instead, it is possible to achieve wound closure, implant osseointegration, bone regeneration, and good soft tissue healing by using artificial membrane; all the more reason to use these proven socket regeneration techniques to provide protection in a healing socket which contains a newly placed implant. Another benefit is with the implant there will be less shrinkage of the complex. A 4.0 mm height gingivaformer is generally placed into the implant instead of a cover screw and this helps “tent up” and stabilize the region. Bone graft generally fills up to and slightly over the top of the gingivaformer, and then the membrane covers the whole region.

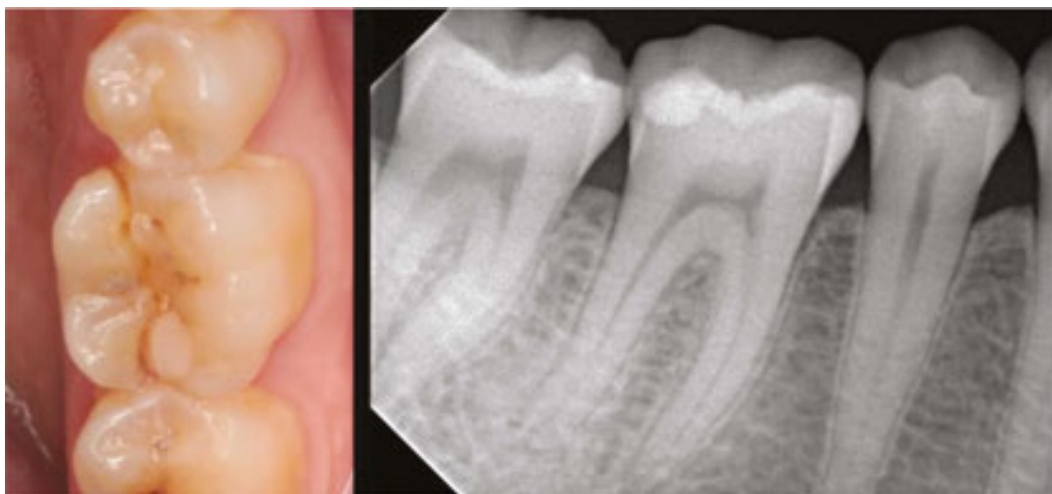


Figure 19. This mandibular first molar is vertically fractured and the crack extended sub-osseously.

As healing progresses there is some shrinkage. The top of the gingivaformer generally becomes exposed and at the appropriate time, it can easily be removed for impression taking. Emergence profile development and placement of a final abutment and restoration are then routine (Figures 19–21).

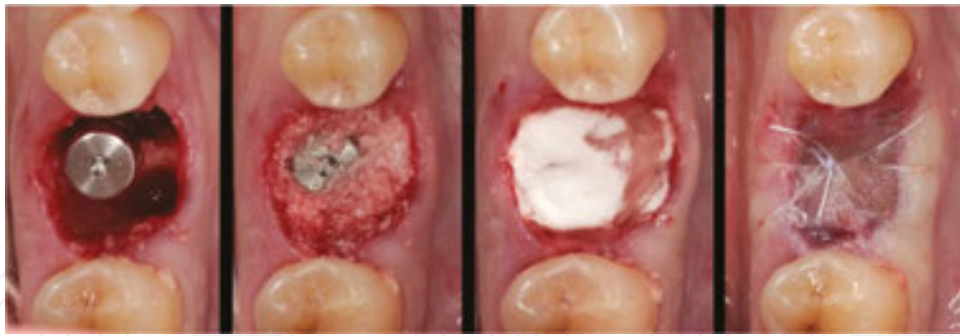


Figure 20. The tooth was removed and a Camlog® implant and gingivaformer placed. Bio-Oss Collagen® was placed down and around the implant. A Mucograft® membrane was placed over and the region sutured and sealed with Tissue Glue.

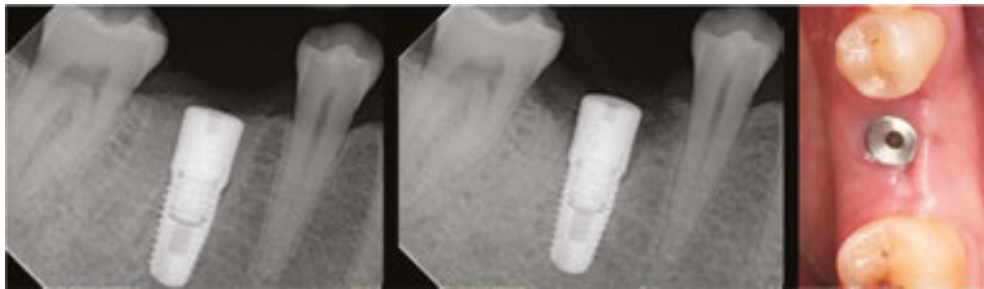


Figure 21. The radiograph on the left was taken immediately following the procedure. The one alongside was taken 3 months later as was the photograph. The case is now ready for a final restoration.

7. Regional considerations

7.1. Maxillary anteriors

Maxillary anterior teeth immediate replacement is very demanding. It can be very difficult to provide a final result where it is hard to know if a crown is implant-supported or tooth-supported. All too often, the give-away is that the implant-supported unit has recession of the interproximal papillae and labial gingival margin. This can be very difficult to reverse surgically. The obvious way to approach these situations is to be prepared for an immediate implant replacement and to make sure that the original hard and soft tissues in the region are maintained.

It's critical not to place the implant directly down the extraction socket as this will lead to the implant being set far too labial, leading to greater recession of the labial bone and soft tissue complex [9–14]. What is needed instead is to reinforce and regenerate the labial plate of bone. This is done by generating an osseous coagulum by placing a slow-resorbing bone graft between the labial bone and the implant. This allows adequate time for native bone to grow into the region. Instead of stabilizing the implant into the bone at the apex of the socket, the

implant needs to be stabilized into the palatal bone wall. This requires an abutment which can be angled towards the palatal which means the screw access channel will come out labially. To manage, this requires a separate abutment with an angle change and a separate crown. To facilitate the desired abutment form and angle change, it is necessary to set the implant platform quite deep within the bone complex. The case shown below illustrates all of these considerations (**Figures 22–28**).

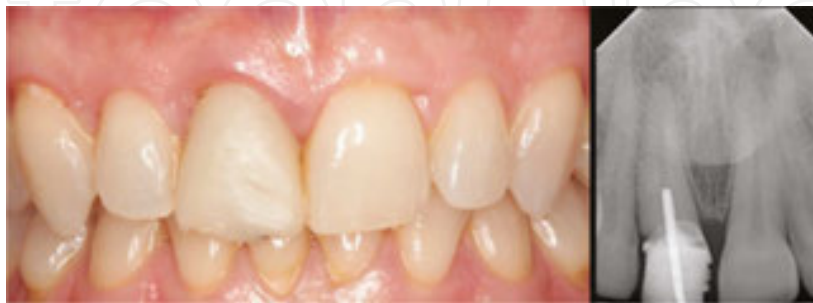

Figure 22. The patient had the misfortune to have a crown on a maxillary central incisor fracture off while she was under anesthesia for a minor surgical procedure.

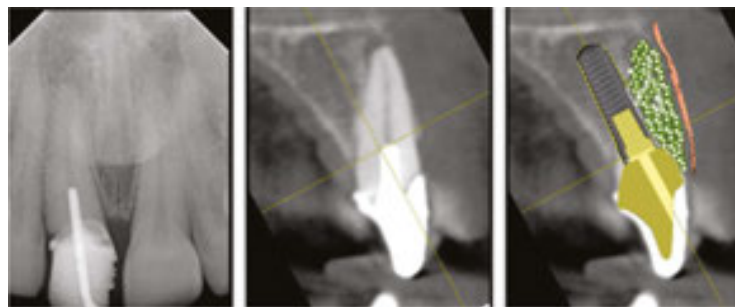


Figure 23. The cross-sectional CBCT cut showed that the tooth had little or no labial bone plate, but that there was a good volume of stable bone in the palatal wall of the socket. The principle of the procedure then is to anchor an implant into this palatal wall. The empty bone socket then needed to be filled with a bone graft and the outer wall of the socket needed to be protected with a membrane.

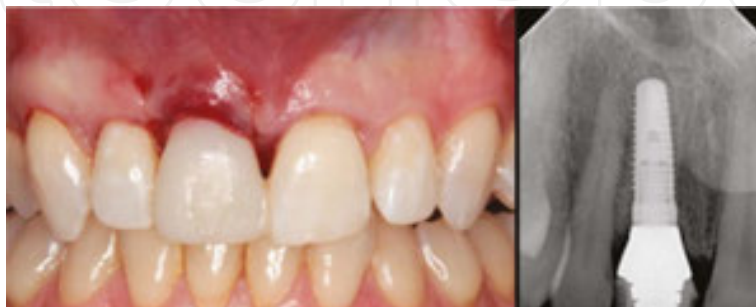

Figure 24. Here was the situation immediately following the procedure. An implant has been placed, all the augmentation materials are present and a temporary abutment with a provisional crown has been secured. It is screw-retained.

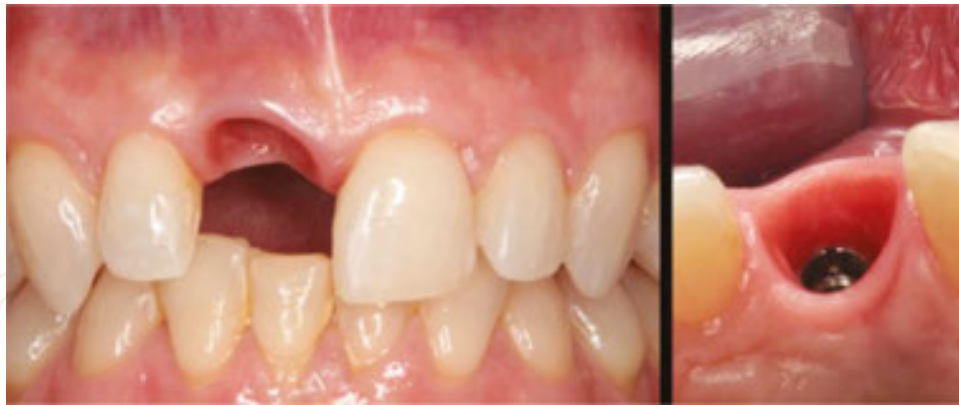

Figure 25. Four months later when the temporary abutment and crown are removed, the region looks very healthy. Notice the well-keratinized sulcus and freedom from inflammation.

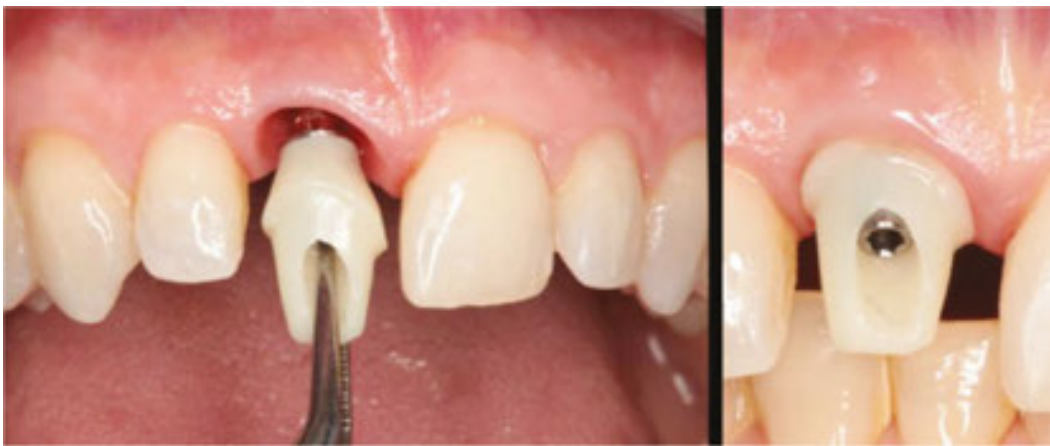

Figure 26. Now the final abutment is placed. This is a custom Zirconia sleeve secured onto a Titanium Base CAD-CAM component.

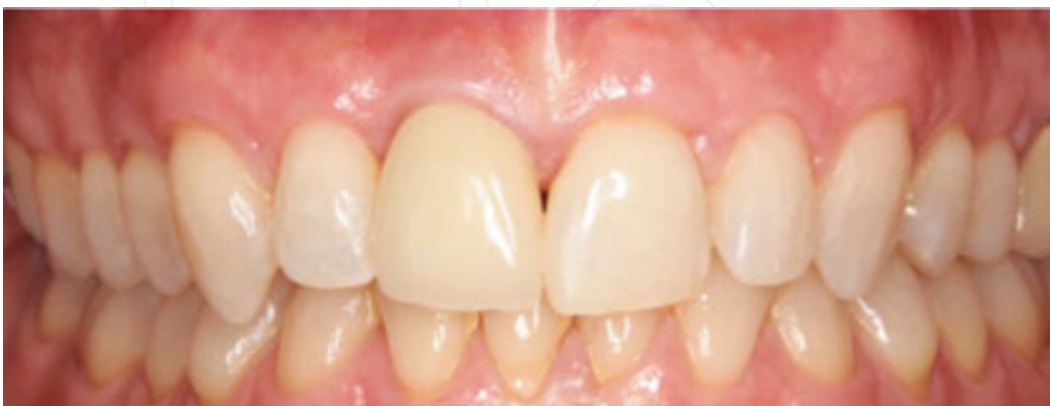

Figure 27. The final result.

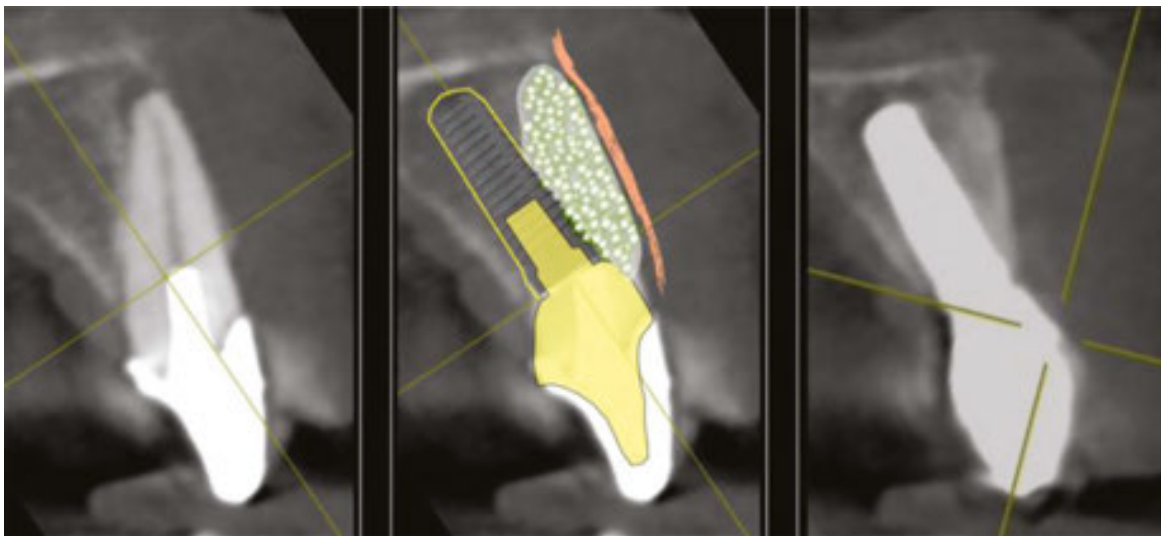


Figure 28. On the right is a cross-sectional CBCT slice taken 6 months following treatment showing that the labial region is stable and has filled in nicely.

7.2. Mandibular anteriors

The guidelines for mandibular anterior replacements are completely different from those of the maxillary anteriors. The situation can be much more variable and requires very careful analysis. The essential thing to appreciate is that one has to be very careful to make sure there is adequate bone volume within which to place an implant. The case which follows is a good illustration of some of the problems that can occur (**Figures 29–32**).

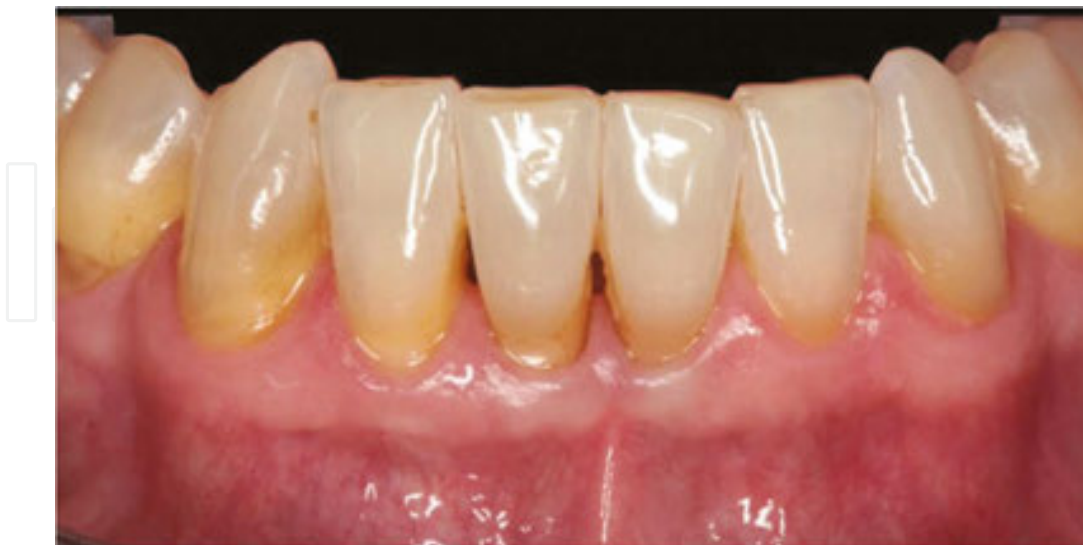

Figure 29. These lower anterior teeth seem almost perfect. On a routine examination the general dentist noticed there was a radiographic defect in the root canal chamber of the right central incisor. He referred the case to an endodontist for evaluation who diagnosed an external resorption of the tooth. He declined to treat the case and recommended an implant consult.

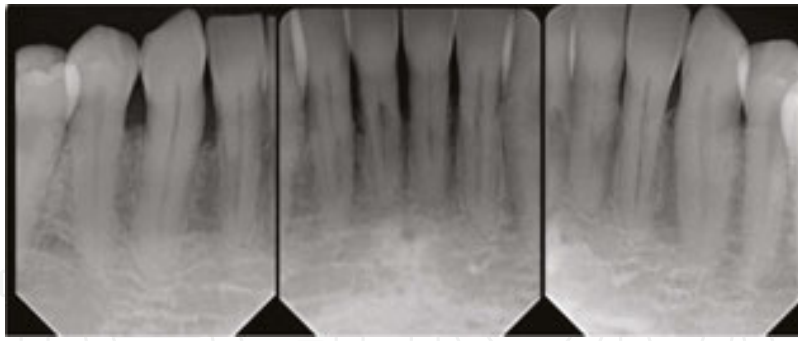


Figure 30. The patient came to see us. We took a CBCT and in the cross-sections it was obvious that the two central incisors had minimal supporting bone on the lingual and very little on the labial aspect.

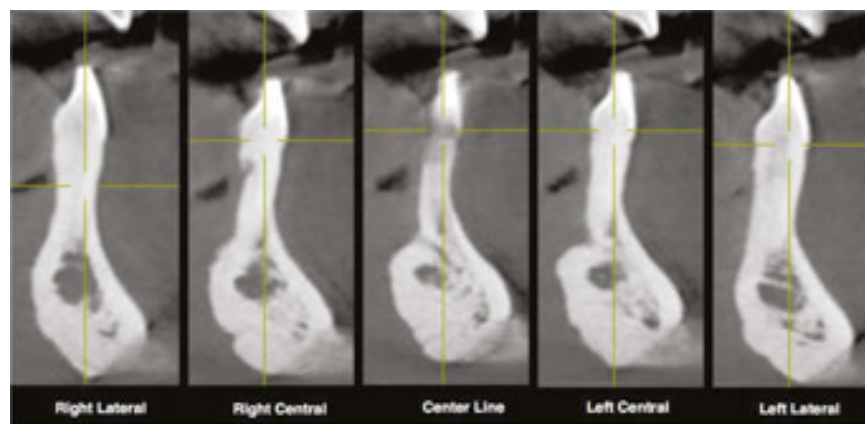


Figure 31. In addition in the midline, there was a very strange invagination of the bone structure. In short, this was not a suitable place for an implant.

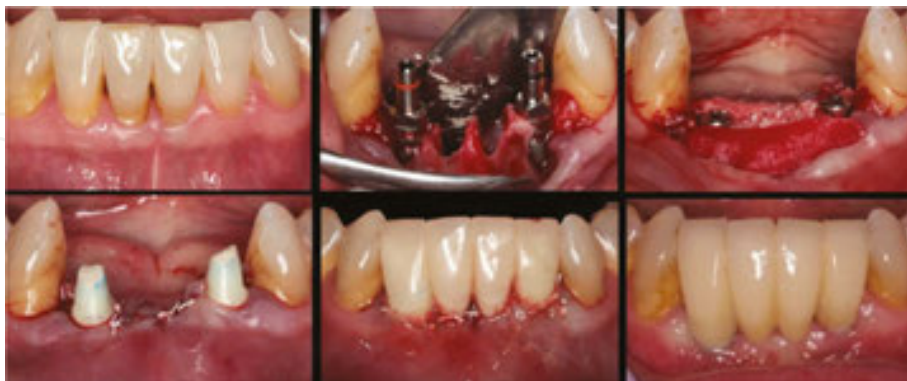

Figure 32. Two implants were placed in the lateral incisor regions, with extensive regional augmentation. An immediate provisional restoration was placed at the same time. After healing, for 6 months a final restoration was able to be constructed by the referring dentist, Dr. Peter Flaherty, Devon, PA.

One last point, the mandibular anterior region is the only region of the mouth where the bone width can decrease from the crest to the apical region. Although there may appear to be ample

bone at the crest it can be relatively easy to perforate out of the bone during the channel preparation and implant insertion. Usually the perforation is out to the labial.

7.3. Maxillary premolars

Maxillary premolars can be quite difficult to replace with implants. There can be two, sometimes even three roots of a premolar, particularly the first premolar, so the tooth can be difficult to remove in the first place. The labial roots are generally set very close to the outer plate of bone, so in this respect they are similar to the maxillary anterior teeth. It can be tempting to want to choose a palatal root space to place the implant into, but this may be set too palatally. It is better to prepare the initial channel down between the labial and the palatal roots. An ultrasonic tip can establish the ideal starting point for a pilot drill which allows the channel to be finalized using drills. Premolar roots are much wider palatal-to-buccal than they are mesial-to-distal, so it may not be possible to get great initial stability. What stability can be achieved is obtained in the apical one third of the channel. It can be tempting to use a larger diameter implant to get greater stability but this should be resisted because it can leave minimal interproximal space.

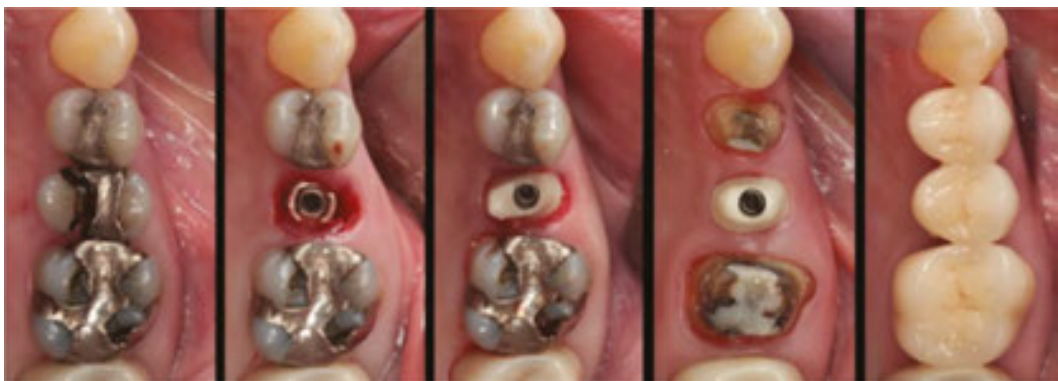

Figure 33. This case started with the sub-osseous fracture of the palatal cusp of a maxillary second premolar. The tooth was not restorable. It was extracted and immediately replaced with an implant to which a temporary Zirconia Sleeve abutment was then attached.

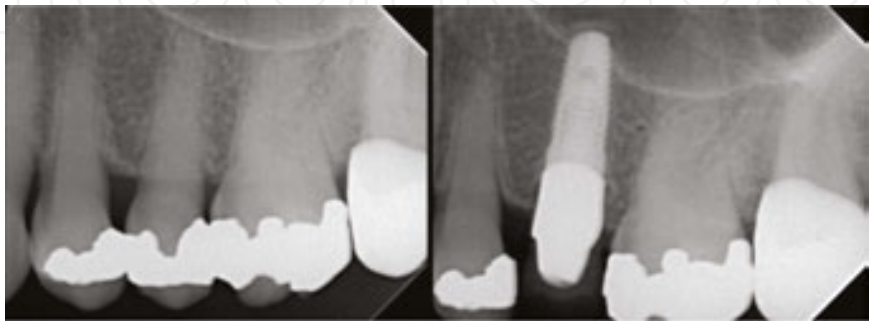

Figure 34. As is often the case with premolars, there was not enough initial stability of the implant to load it immediately. By taking the implant a little higher, into the sinus region, additional stability was gained.

One relatively common problem is for the implant to penetrate out of the bone apically. The reason for this is that the operator fails to appreciate that the bone housing tapers in medially as the alveolus progresses apically. This can be avoided if the drill path parallels that of the outer plate of bone. It is also necessary to sink the implant platform deeper than usual so that the abutment placed on the platform can flare out buccally and lingually to develop an elliptical, pre-molar form (**Figures 33–35**).

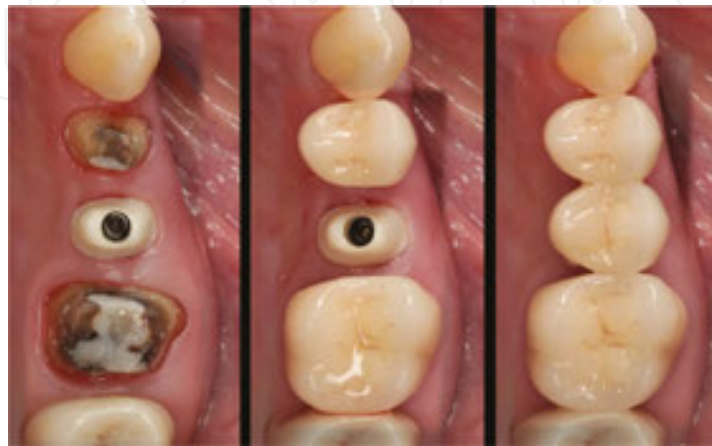


Figure 35. The deep position of the implant platform made it easy to develop the optimal emergence form for the abutment and for the final crown.

7.4. Mandibular premolars

The anatomy of the mandibular premolar region can be challenging. The labio-lingual bone dimension can be narrow even when it contains teeth. When the teeth are removed, the ridge shrinks more. The labial bone can be particularly thin and rapidly disappears after an extraction. The mandibular nerve can be very close which makes it impossible to gain extra stability for an implant by preparing the implant channel deeper (**Figures 36 and 37**).

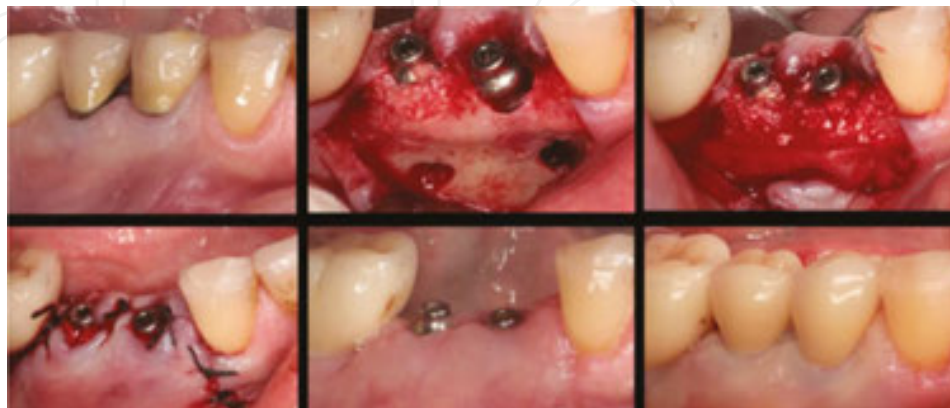


Figure 36. These two premolars were painful and had apical lesions. A labial flap allowed access to remove the teeth, to debride the region and to place implants and gingivaformers.

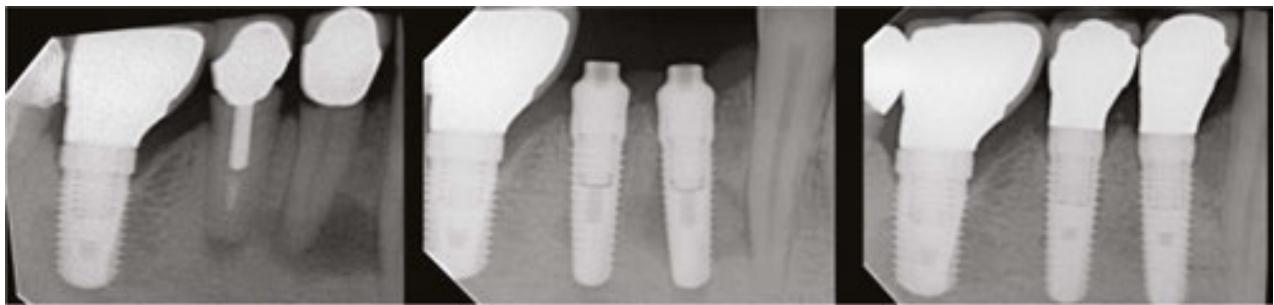

Figure 37. The radiographic series shows good healing. The molar implant was one with a 1.4 mm machined collar placed five years earlier.

7.5. Maxillary molars

The critical factor to appreciate with maxillary molars is that they have relatively little bone supporting them in the first place. What bone there is usually closely follows the form of the roots with the covering of bone around each root being quite thin. This bone covering can easily be taken away by recession, occlusal trauma, and furcation involvements. What is left can be inadequate to support an implant. It is critical to retain what bone there is in the region. An adequate volume of bone to support an implant is found in less than 5% of cases in our experience. This is why when replacing a maxillary molar with an implant it is necessary to consider providing a sinus lift. Once these principles are appreciated, then immediate molar replacement is both predictable and successful (**Figures 38–40**) [15].

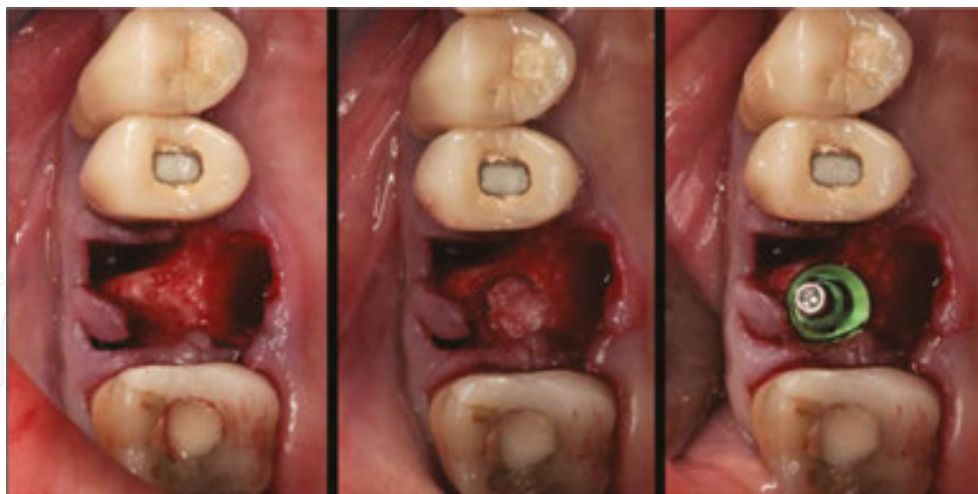


Figure 38. The first molar was failing and was removed. The labial and lingual walls were almost non-existent and the socket was expected to collapse. The central core bone in the trifurcation region was adequate to prepare a trephine channel, to raise the sinus floor, to augment the sinus region with bone graft and to place an implant.

Where the trifurcation region of bone is unable to stabilize an implant, such as when there is a large furcation involvement, it will be necessary to obtain apical stabilization by an intentional sinus lift procedure.

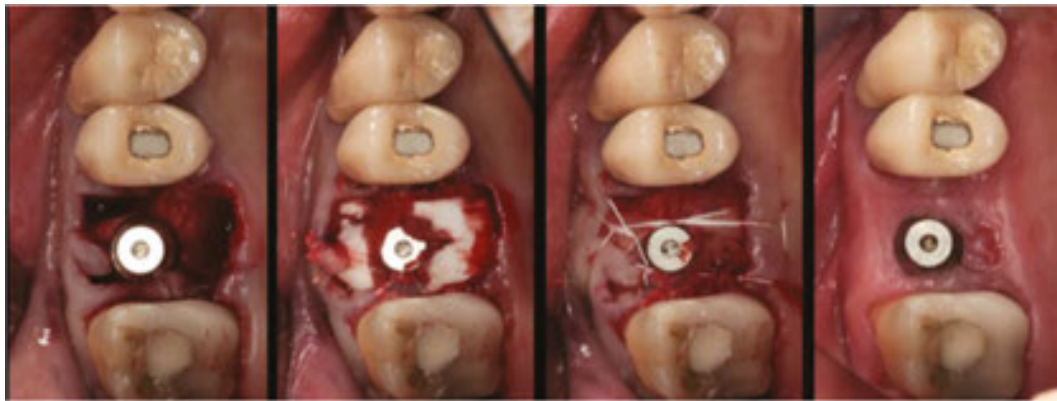


Figure 39. The former root spaces are then filled with bone graft, covered with a membrane and sutured. There was no advancement of the marginal gingival flaps.

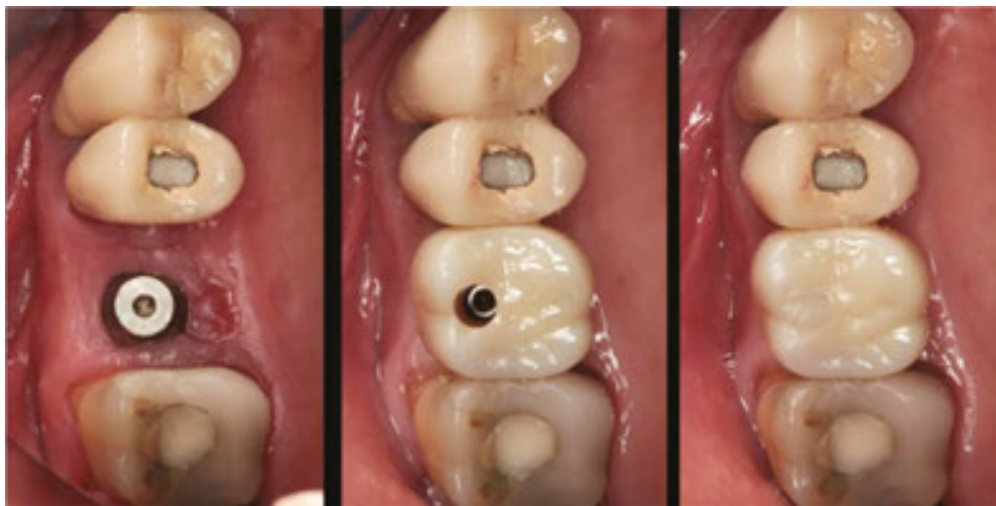

Figure 40. The region healed well and a restoration was placed.

Here is an example of such a case (**Figures 41–44**).

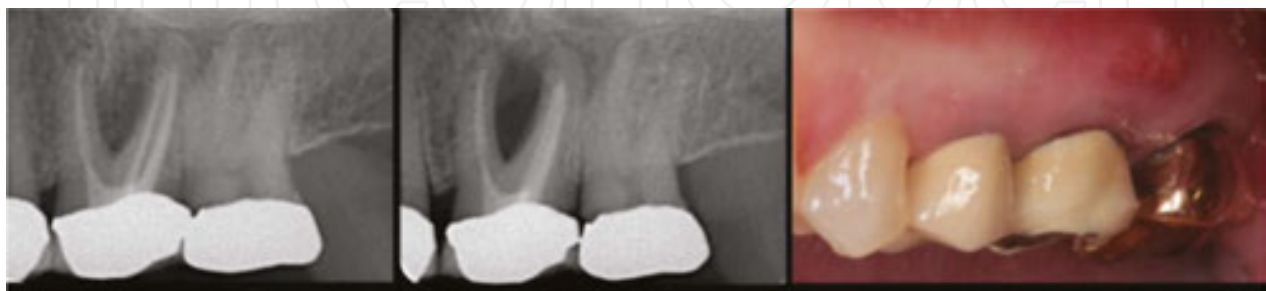

Figure 41. Left: On initial presentation the patient was advised to have the molar replaced by an implant. Center: Five months later, with no therapy, the furcation defect had increased greatly. Right: An abscess is now pointing out labially.

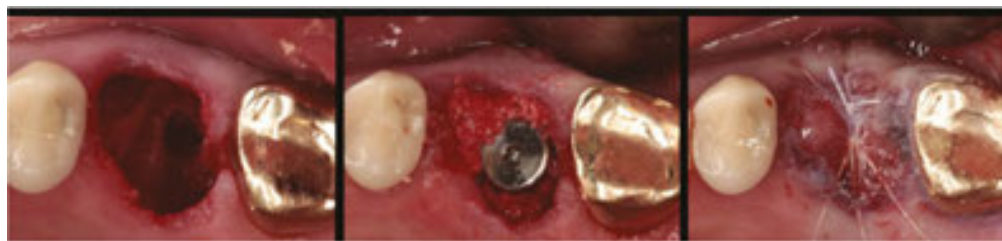

Figure 42. The tooth was sectioned and removed. A sinus floor perforation was obvious, so this was used as the starting point for the stabilization of the implant, even though it was a little distal. After a small sinus lift with bone graft, the implant was placed, surrounded by more bone graft, sutured and covered by a membrane.

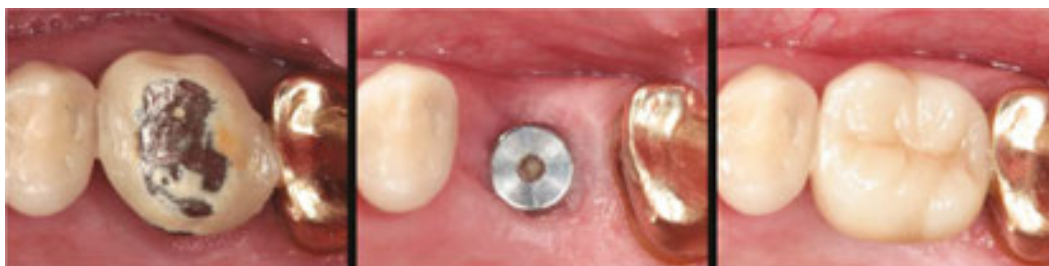

Figure 43. Here is the original, after healing and with the final restoration.

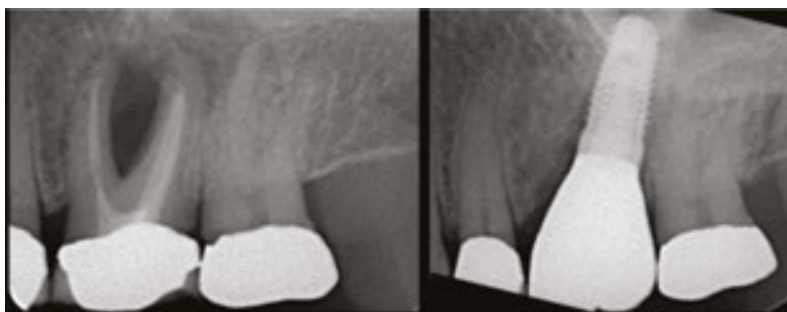

Figure 44. Before and after radiographs.

7.6. Mandibular molars

When mandibular molars are extracted, there tends to be a fairly rapid collapse of the labial plate with loss of ridge height and recession of the ridge to the lingual. Part of the reason for this is that the buccal roots of mandibular incisors often have very little bone coverage. In addition, traditional extractions with forceps can be fairly destructive on the labial bone plate. In short, it can be very difficult to rebuild a collapsed mandibular ridge. Prevention of ridge loss is better, simpler, easier, and faster. In the extraction procedure, everything possible should be done to preserve the labial and lingual plates.

Removing the roots can be difficult and time-consuming. Once this is done and granulation tissues have been removed, there should be a four-wall defect. Establishing the right position

for and stability of the implant can be difficult. Sometimes this is possible in a former root socket. It may be possible to use the inter-radicular septum. Often it is necessary to make the channel for the implant a little deeper than the socket of the tooth. However, it is critical to ensure that there is clearance above the mandibular nerve. If this is not available, then it will be necessary to perform a socket regeneration procedure. The case which follows is typical of a situation which could be managed immediately (**Figures 45–47**).

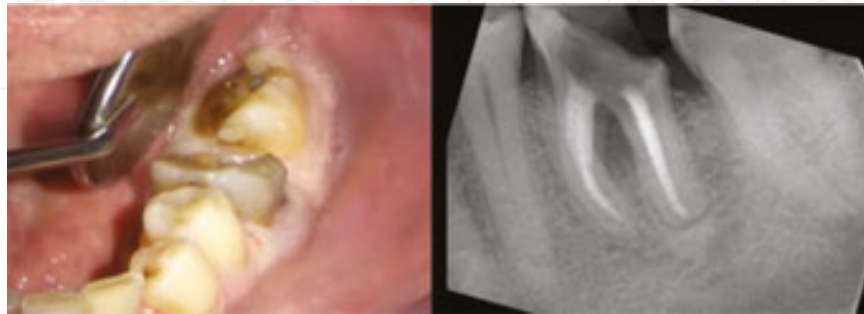

Figure 45. This mandibular molar had never been restored after the root canal therapy. Now the tooth is hopeless and there is considerable bone destruction in the region.

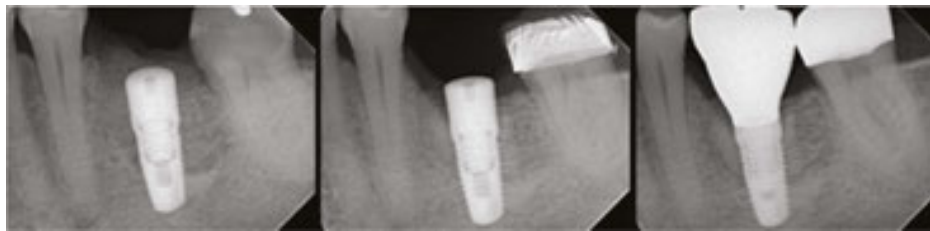

Figure 46. The tooth was removed, the region debrided, stabilization for the implant was generated apically, an oss-eous coagulum was developed with a bone graft and a membrane covered over the region while it healed. The final restoration was placed five months following the procedure.

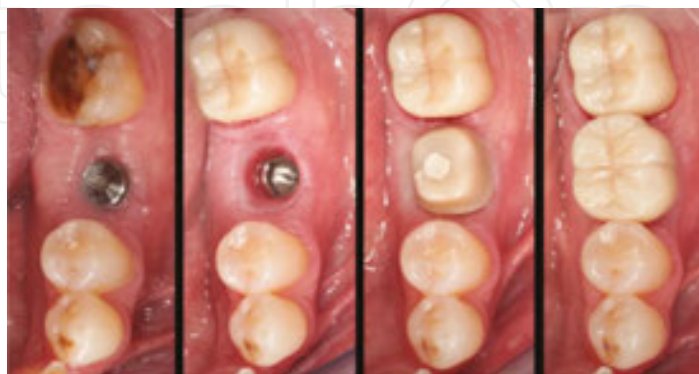

Figure 47. As is typical the gingivaformer is exposed by the time the case is ready to be restored. A custom zirconia emergence attached to a Camlog® Titanium Base CAD-CAM component is placed. This allows the final crown to appear very natural.

8. Larger scale immediate replacements

The success of immediate single tooth replacement has led us to take on larger scale cases with multiple missing teeth. These are always difficult situations because the hard and soft tissue defects that can arise from the loss of multiple adjacent teeth are more extensive and much more difficult to repair. The principles applied are much the same as for the individual tooth situation. The teeth are removed carefully with care being taken to preserve whatever bone is in the region. The region is thoroughly debrided, implant channels prepared, implants placed with adequate stability, an osseous coagulum with membrane coverage provided, and closure. The one real difference in these cases is that flap access to the region is required. The case shown below would generally not be treated using an immediate protocol. Traditional therapy would have been very complex because the teeth would have been removed, the ridge would shrink away almost completely, and re-building the region would have been exceedingly difficult, multi-staged, and lengthy. The patient, a graduate student in his late twenties, was about to leave the region and requested an accelerated protocol (**Figures 48–52**).

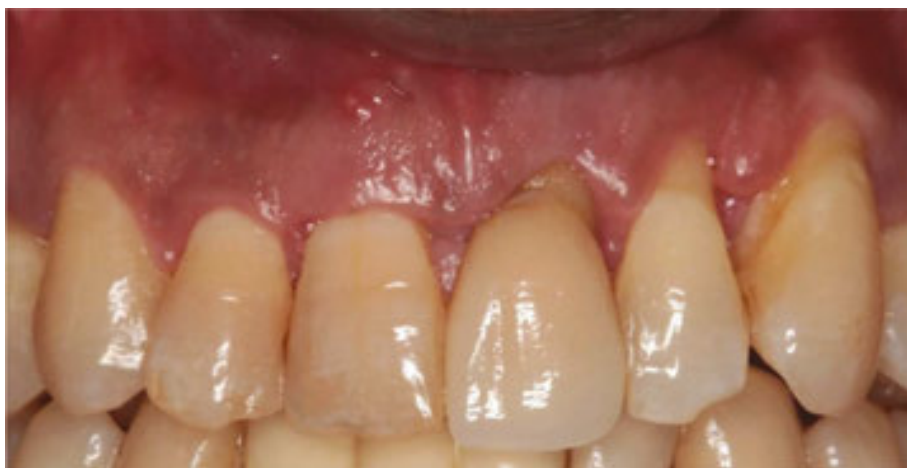

Figure 48. Clinical view of the dentition.

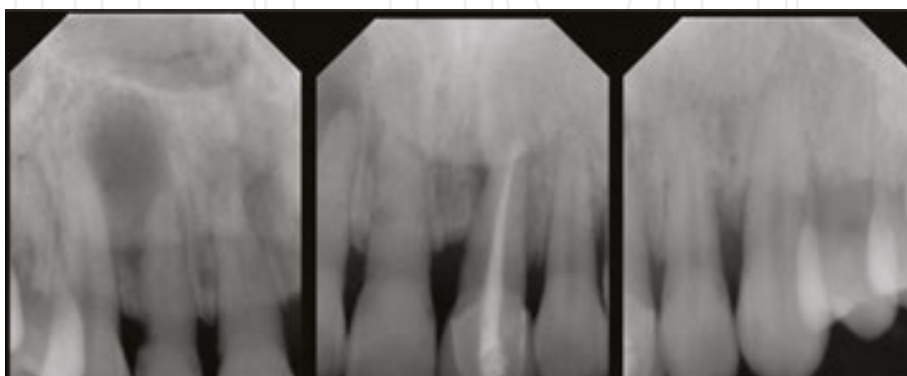


Figure 49. Periapical radiographs of the region.

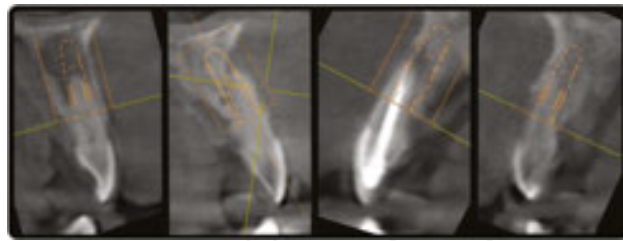


Figure 50. CBCT slices through the teeth show a variety of advanced lesions including almost complete loss of facial bone on three teeth.

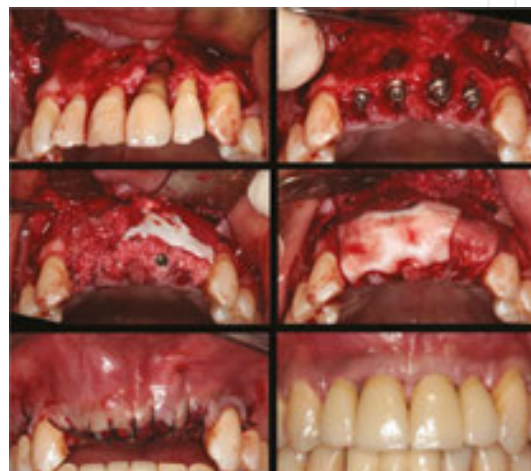

Figure 51. The region was open flapped for debridement. Camlog® implants were placed in all four sockets. An osseous coagulum was developed using BioOss Collagen particulate bone graft and covered with Bio-Gide® and Mucograft® collagen membranes (Geistlich). The region was closed without primary closure. Five months later the case was restored with individual abutments and restorations.

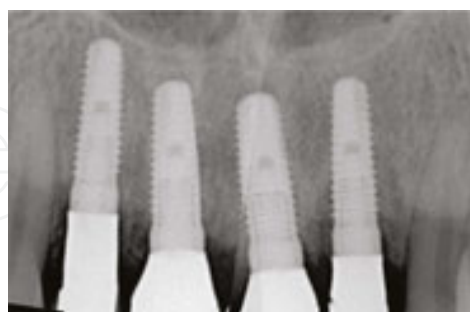

Figure 52. Post-therapy radiographs show that the region is continuing to recover.

Traditional therapy for this case would have been extremely complex, time consuming, and difficult. While this result cannot be considered ideal, it was relatively simple, fast, and effective. The basic principles of debridement, positioning, and stabilization of implants, developing an osseous coagulum and wound closure described above were used throughout therapy. All things being considered, the result in this case is very encouraging.

8.1. Failing individual teeth with aesthetic concerns

The case shown below also has many problems. They can all be handled individually, but what is really needed is to blend them all into a treatment plan that works towards a harmonious end result. It is a real challenge to make implant-supported restorations look natural alongside restorations supported on natural teeth but that was what was needed in this case (Figures 53–56).

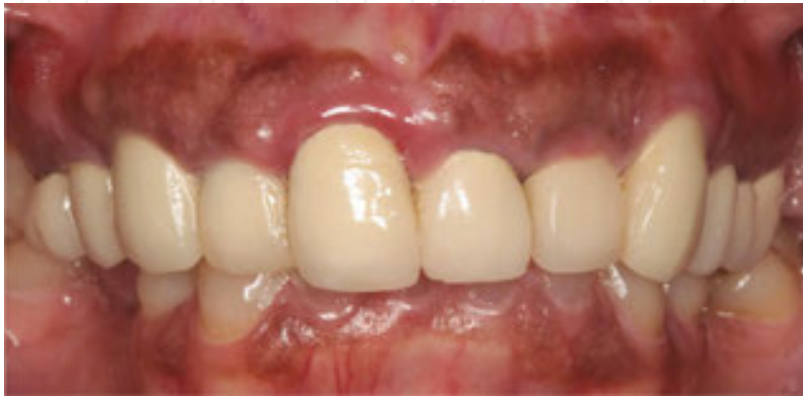

Figure 53. The patient was concerned about the puffy gums and the poor appearance of the teeth.

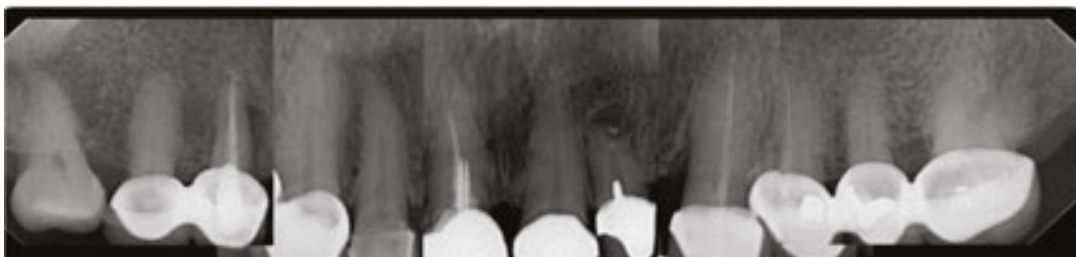

Figure 54. The radiographs show some failing teeth but the bone support is basically good.

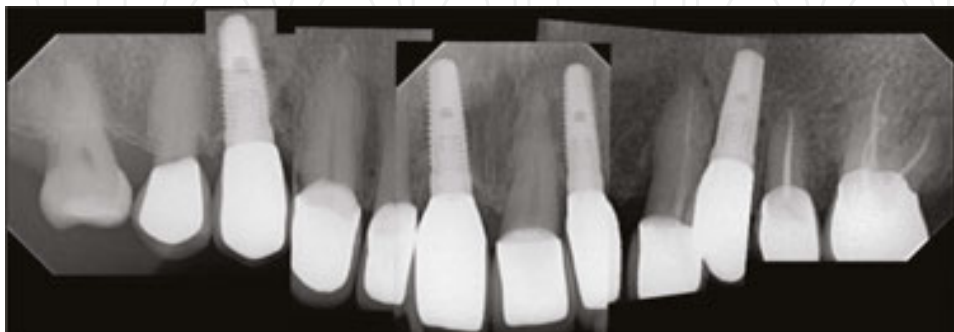


Figure 55. Four implants have replaced the failing teeth using an immediate replacement protocol. In the process the gingival lines have been re-aligned and the gingival health of the implants and natural teeth is now good. The aesthetics have been greatly improved.

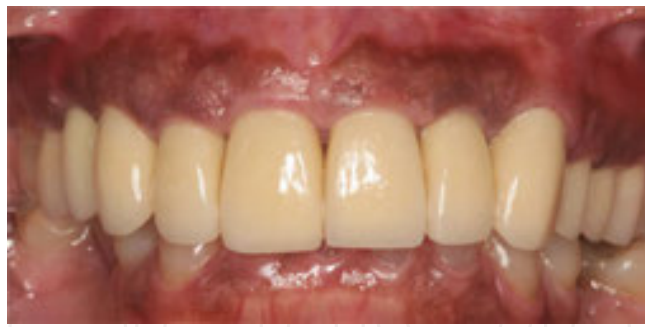

Figure 56. Therapy is completed, the appearance is now very natural.

9. Complications

Complications can occur with any procedure, but in immediate replacement these tend to be infrequent and relatively insignificant. The critical requirement is for careful monitoring of healing during the post-surgical process. If problems arise they should be managed as rapidly as possible.

9.1. Early loss of implant stability

This is an infrequent but very serious complication, usually occurring on immediately loaded implants with restorations. Loss of implant stability requires immediate action.

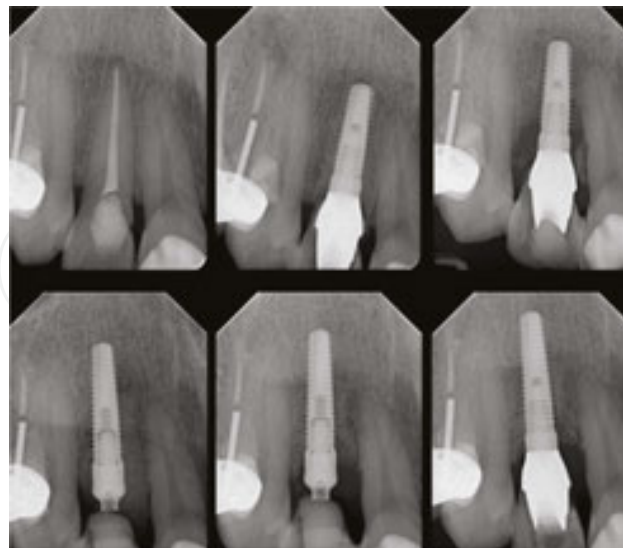


Figure 57. This lateral incisor was fractured at the gum level. It was removed and immediately replaced with an immediate load implant and provisional. Four weeks later he reported it was mobile. The referring dentist bonded it to the adjacent teeth. He was referred back to us 10 days later when it was more obvious that the region was quite compromised.

There are three options. First is to remove the abutment and to replace it with a gingivaformer. For this to work there must be no signs of inflammation or infection in the region, just slight mobility. The second alternative is to remove the implant, clean the region, and to replace it with another fresh, un-contaminated implant. Preferably this will gain additional stability with a larger size or length. However, it should be converted to a gingivaformer procedure to be sure of getting rid of the potential for breakdown. The third alternative is to remove the implant, to clean out the region, and do socket regeneration in the region. The case shown below was managed with the second option protocol (**Figure 57**).

The implant was removed and the region thoroughly cleaned out. A longer implant was then placed, with a gingivaformer positioned; the region was then augmented extensively with more bone graft before the region was closed. Three months later the healing was satisfactory, though there was some medial papillary recession.

9.2. Connection abscess (abutment screw loosening)

These occur because of loosening of the abutment retaining screw. Usually an abscess is a rather late occurrence. At an earlier stage there is inflammation of the marginal gingiva. If this is allowed to continue for too long, then the abscess may penetrate through the gingiva as seen in the case below. The way to check this is to rock the crown and to see if there is any mobility. The axis of the rotation will be at the connection. It is important to differentiate this from mobility of the implant which is where the axis of rotation would be more apical.

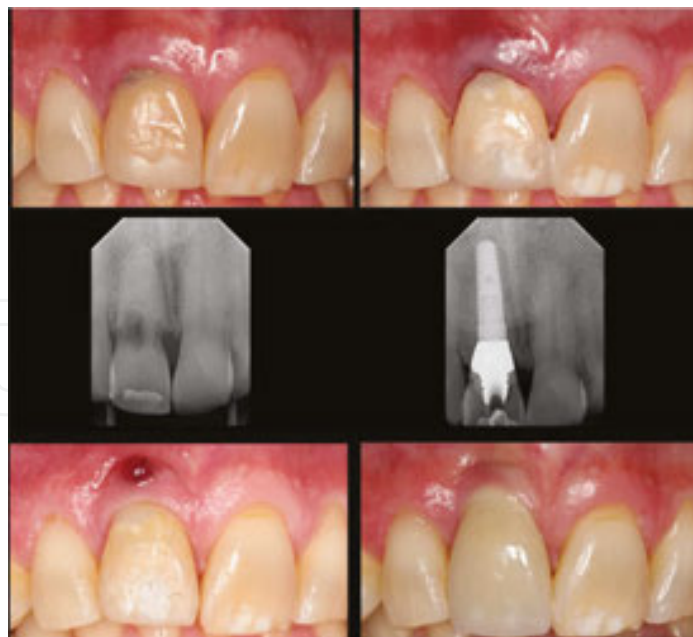

Figure 58. Top left: Situation with internal tooth resorption. Top Right: Following immediate replacement. Center left: Original radiograph. Center right: With implant and provisional. Bottom left: Four months later with connection abscess due to mobility of connection. Bottom right: Final case with healed situation but with increased marginal recession.

This sometimes occurs because at the time of implant placement, there is a hesitance about over-tightening the abutment retaining screw, as this may cause the implant to rotate. If this rotation does occur, it can be interpreted as the wrong choice of post-surgical restoration in that the implant was really not stable enough to immediately load.

There can be one other cause for this problem. It occurs when bone graft used for the augmentation gets trapped between the abutment and the implant platform when the abutment is placed. A radiograph should always be taken at the end of the procedure to check that this has not occurred. Although the connection may be tight at the outset, as the graft softens, the joint will loosen (**Figure 58**).

9.3. Marginal gingival recession

This is a rather complex subject. Stability of the marginal gingival complex depends on many factors which can be grouped into three main considerations: structure, replacement structure, and pathology.

Structure: We start working with the pre-existing condition. A normal gingival complex is supported over marginal bone; if that bone is lost for one reason or another then the gingival margin can more easily recede. Gingiva is usually differentiated into attached gingiva and free marginal gingiva. Everybody appreciates that attached gingiva should be attached to the tooth, but there is not so much appreciation for it also being attached to the marginal bone complex. Many of our surgical procedures raise up and move this marginal attached gingiva, sometimes to places where there is no bone for it to re-attach to, for example when a flap is mobilized to cover over a socket. When replacing a tooth with an implant, it is critical that it be surrounded by attached gingiva, which is attached to the bone and then comes up over the gingivaformer or abutment.

Replacement Structure: Some teeth when replaced by an implant will have considerable amounts of native bone remaining in the region. Although this will be affected by the change-over, in most cases the hope is that it remains, regenerates, and starts to support the implant. However, in some of our most critical situations, such as in the maxillary anterior region, the implant is set back palatally and at an angle to get stability in the palatal bone. The void between the implant and the labial wall of the socket has to be augmented with a bone graft. We usually over-augment to make sure that this consolidates without receding. Similarly, the gingival complex is usually augmented with a gingival allograft or more traditionally a connective tissue graft. Another factor to take into account is the material and form of the temporary abutment as this is often used to bulk out and support the augmented regions. These should be of materials which are bio-compatible with the soft and hard tissues in the region. We use custom formed Zirconia sleeves secured on a titanium base to accomplish this in our cases.

Pathology: Inflammation and infection can affect marginal soft and hard tissues. They can induce a wide-range of responses ranging from swelling to hyperplasia, from fibrosis to tissue breakdown, and for attached tissues to become detached (**Figure 59**).

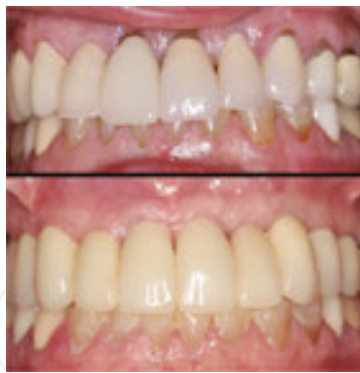

Figure 59. This patient had marginal recession and recurrent decay around the maxillary anterior teeth. Neither the patient nor the referring dentist was comfortable with another round of conventional restorative therapy. The teeth were all replaced with implants. Notice the change in gingival form and structure. Restorative dentistry by Dr. Chris Furlan, Havertown, PA, USA.

9.4. Peri-implantitis

Peri-implantitis is an inflammatory reaction in the tissues surrounding an implant, both gingiva and bone. One has to be careful to differentiate it from marginal gingivitis or inflammation of the gingival tissues about an implant. If there are changes in the marginal bone below the rough surface of the implant, then one should assume that osseointegration in that region has broken down and that the rough surface on the implant has become contaminated. If this is the case then it is doubtful if it can be “re-treated” or made so that re-osseointegration can develop. It may be possible to get short-term benefits, but it is often better to replace the implant (**Figure 60**).

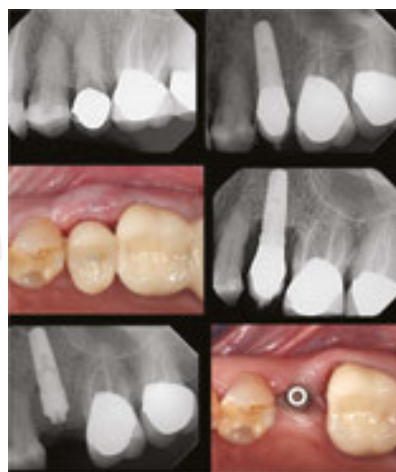

Figure 60. Top: Deep decay was under the margin of the crown on the second premolar, so the tooth was replaced with an immediately loaded provisional restoration. Center: Six weeks later, she returned with pain and gross inflammation of the marginal gingiva. A radiograph showed rapid breakdown around the collar of the implant. It was removed, and the region debrided. A fresh implant was placed with a bottleneck gingivaformer and closed after further augmentation. Bottom: Four weeks later, the inflammation in the soft tissue complex is resolving well and further healing can be expected.

9.5. Apico-implantitis

This is a problem where infection breaks down the apical bone surrounding an implant. Generally there can be two sources of the infection. The first is a residual apical infection left from a tooth in the region that was extracted previously. The second source can be from an apical infection on an adjacent tooth. Diagnosis may be difficult and access to the region for debridement can be more complex (**Figure 61**).

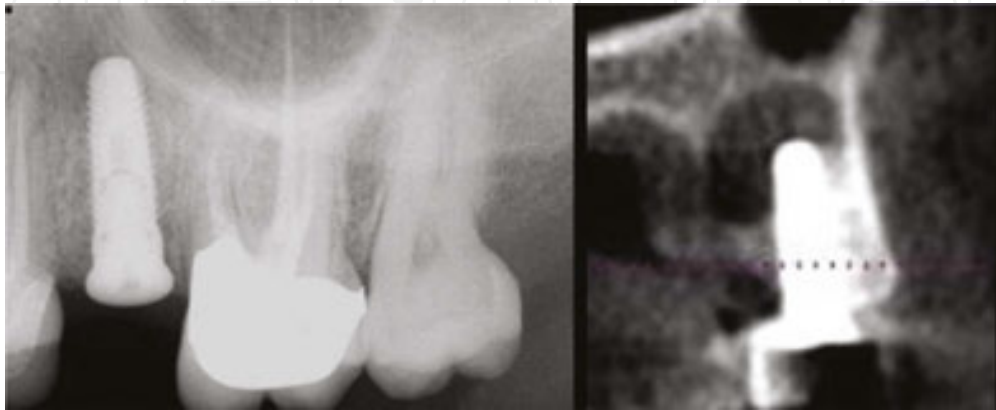


Figure 61. This implant was placed and appeared to integrate well, but a check radiograph at a later time showed apical pathology. The implant was removed, the region debrided and allowed to heal.

9.6. Sequestrum formation

Sequestra are portions of bone which lose vitality and then become a nidus of infection. Most of these occur in the mandible. Bone fragments may lose much of their surrounding support and blood supply during the extraction process or during implant placement. Most common are inter-radicular septa, followed by bone walls of adjacent teeth. Part of the issue can be that these regions may have been traumatized or even fractured during the extraction process. These can delay healing in the region, become a source of infection about an implant, and be painful. Once identified, it is best to remove the sequestrum and allow the region to heal. They can happen in any extraction socket, not just when implants are placed.

10. Summary and conclusions

Bone regeneration within four-wall sockets seems to be relatively easy to achieve. Socket regeneration is based upon using this principle. Immediate implantation is simply taking the concept one step further by stabilizing an implant in the middle of the regenerating socket. It is becoming increasingly obvious that immediate implantation procedures can be successful, that they can minimize the extent and number of surgical interventions, and return the patient to function within the shortest possible time. In addition, they help retain the supporting complex of a tooth being extracted and replaced by an implant. In comparison, traditional techniques seem increasingly outdated.

We have come to believe that it is easier to retain than regain an alveolar supporting complex. For immediate implantation procedures to be successful, it is necessary to pay attention to some basic principles:

1. The tooth needs to be removed with minimal damage to the socket walls.
2. The socket needs to be debrided of soft tissue granulations and infected tissues.
3. Correct positioning and adequate stabilization of the implant must be established.
4. An osseous coagulum needs to surround the implant and fill the socket. Using a slow-resorbing bone graft material can help prevent ridge resorption.
5. A gingivaformer or abutment placed in the implant can provide a “tenting” effect, which assists augmentation and helps prevent early contamination of the rough surface of the implant.
6. The socket does not need to be covered with gingiva, it can be covered and protected by membranes as in socket regeneration procedures.
7. If high initial stability of the implant is achieved, then immediate provisionalization can be considered.

Author details

Peter R. Hunt* and Laura M. Ceccacci

*Address all correspondence to: peter.hunt@drpeterhunt.com

Private Practice of Implantology and Rehabilitation Dentistry, Philadelphia, USA

References

- [1] Schropp L, Wenzel A, Kostopoulos L, Karring T. Bone healing and soft tissue contour changes following single-tooth extraction: a clinical and radiographic 12-month prospective study. *Int J Perio Restor Dent*. 2003;23(4):313-323.
- [2] Hämmerle CH, Araújo MG, Simion M. Osteology Consensus Group 2011. Evidence-based knowledge on the biology and treatment of extraction sockets. *Clin Oral Implants Res*. 2012;23 Suppl 5:80-82.
- [3] Fuentes R, Flores T, Navarro P, Salamanca C, Beltrán V, Borie E. Assessment of buccal bone thickness of aesthetic maxillary region: a cone-beam computed tomography study. *J Periodontal Implant Sci*. 2015;45(5):162-188. DOI: 10.5051/jpis.2015.45.5.162. Epub 2015 October 26.

- [4] Meltzer AM. Immediate implant placement and restoration in infected sites. *Int J Periodont Restor Dent*. 2012;32(5):e169-173.
- [5] Sanz-Sánchez I, Sanz-Martín I, Figuero E, Sanz M. Clinical efficacy of immediate implant loading protocols compared to conventional loading depending on the type of the restoration: a systematic review. *Clin. Oral Impl. Res*. 2015; 26:964–982. DOI: 10.1111/clr.12428
- [6] Javed F, Romanos GE. The role of primary stability for successful immediate loading of dental implants. A literature review. *J Dent*. 2010;38(8):612-620.
- [7] Barone A, Aldini NN, Fini M, Giardino R, Calvo Guirado JL, Covani U. Xenograft versus extraction alone for ridge preservation after tooth removal: a clinical and histomorphometric study. *J Periodontol*. 2008;79(8):1370-1377.
- [8] Cardaropoli D, Tamagnone L, Roffredo A, Gaveglia L, Cardaropoli G. Socket preservation using bovine bone mineral and collagen membrane: a randomized controlled clinical trial with histologic analysis. *Int J Periodont Restor Dent*. 2012;32(4):421-430.
- [9] Viña-Almunia J, Candel-Martí ME, Cervera-Ballester J, et al. Buccal bone crest dynamics after immediate implant placement and ridge preservation techniques: review of morphometric studies in animals. *Impl Dent*. 2013;22(2):155-160.
- [10] den Hartog L, Slater JJ, Vissink A, Meijer HJ, Raghoobar GM. Treatment outcome of immediate, early and conventional single tooth implants in the aesthetic zone: a systematic review to survival, bone level, soft-tissue, aesthetics and patient satisfaction. *J Clin Periodontol*. 2008;35(12):1073-1086.
- [11] Ferrus J, Cecchinato D, Pjetursson EB, Lang NP, Sanz M, Lindhe J. Factors influencing ridge alterations following immediate implant placement into extraction sockets. *Clin Oral Impl Res*. 2010;21(1):22-29. DOI: 10.1111/j.1600-0501.2009.01825.x. Epub 2009 November 13.
- [12] Knoernschild KL. Early survival of single-tooth implants in the esthetic zone may be predictable despite timing of implant placement or loading. *J Evid Based Dent Pract*. 2010;10(1):52-55.
- [13] Cosyn J, Eghbali A, De Bruyn H, Collays K, Cleymaet R, De Rouck T. Immediate single-tooth implants in the anterior maxilla: 3-year results of a case series on hard and soft tissue response and aesthetics. *J Clin Periodontol*. 2011;38(8):746-753. DOI: 10.1111/j.1600-051X.2011.01748.x.
- [14] Block MS, Mercante DE, Lirette D, Mohamed W, Ryser M, Castellon P. Prospective evaluation of immediate and delayed provisional single tooth restorations. *J Oral Maxillofac Surg*. 2009;67(11 Suppl):89-107. DOI: 10.1016/j.joms.2009.07.009.
- [15] Block MS. Placement of implants into fresh molar sites: Results of 35 cases. *J Oral Maxillofac Surg*. 2011;69(1):170-174.

