

# We are IntechOpen, the world's leading publisher of Open Access books Built by scientists, for scientists

6,900

Open access books available

186,000

International authors and editors

200M

Downloads

Our authors are among the

154

Countries delivered to

TOP 1%

most cited scientists

12.2%

Contributors from top 500 universities



WEB OF SCIENCE™

Selection of our books indexed in the Book Citation Index  
in Web of Science™ Core Collection (BKCI)

Interested in publishing with us?  
Contact [book.department@intechopen.com](mailto:book.department@intechopen.com)

Numbers displayed above are based on latest data collected.  
For more information visit [www.intechopen.com](http://www.intechopen.com)



---

## **Concepts in Management of Advanced Craniomaxillofacial Injuries**

---

Sylvio Luiz Costa de Moraes,  
Alexandre Maurity de Paula Afonso,  
Bruno Gomes Duarte,  
Maiolino Thomaz Fonseca Oliveira,  
Darceny Zanetta-Barbosa, Gabriel Pires Pastore,  
Luciano Mauro Del Santo and  
Daniel Falbo Martins de Souza

Additional information is available at the end of the chapter

<http://dx.doi.org/10.5772/63738>

---

### **Abstract**

The authors present a sequencing assessment of patients who were victims of traumatic deformities of the craniomaxillofacial complex. To that end, the authors highlight the eight steps worthy of particular attention, namely (1) clinical history and photographic documentation; (2) clinical assessment; (3) assessment through image and diagnostic exams; (4) planning of the treatment; (5) bases for the three-dimensional reconstruction of the face; (6) reconstruction sequence of multiple facial fractures; (7) support measures; and (8) complications. The proposed assessment sequence allows the oral and maxillofacial surgeon or craniomaxillofacial surgeon to assess the degree of impairment of traumatic deformity, which contributes in a significant way to the decision-making process of the treatment.

**Keywords:** craniomaxillofacial, trauma, treatment, facial injuries, reconstructive surgical procedures

## 1. Introduction

The treatment of craniofacial or maxillofacial trauma, from here on referred to as craniomaxillofacial trauma (CMF Trauma), is a challenging endeavor, as it involves the individual's so-called command and control center, including their face and skull. It is life-threatening and may lead to facial motor and sensory sequelae such as alterations of functions related to sight, speech, swallowing, and breathing, as well as facial aesthetics [1] and possible sequelae related to the central nervous system (CNS) and other parts of the body. CMF Trauma patients need to be initially assessed according to the Advanced Trauma Life Support (ATLS) protocol: (A) airways; (B) breathing; (C) circulation; (D) disability; and (E) exposure.

The main goal of the initial systematic assessment of CMF Trauma patients is to identify patients whose serious injuries are life-threatening and to set treatment priorities so that it is possible to manage them in an efficient and aggressive manner [2].

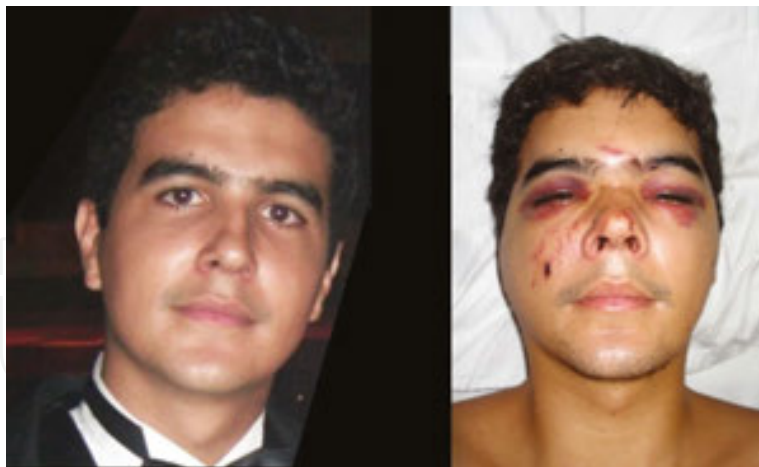Therefore, patients who have gone through ATLS and are now stable can and should be specifically assessed from the craniomaxillofacial point of view. The stratification of trauma is then carried out, which requires a routine, which contains a number of issues. The proposed assessment sequence allows for the Oral & Maxillofacial Surgeon or Craniomaxillofacial Surgeon, from here on referred to as Maxillofacial Surgeon, to reach important conclusions about the degree of impairment of traumatic deformity, which contributes in a significant way to the decision-making process of the treatment. To that end, the authors highlight the following eight points.

## 2. Eight highlight points

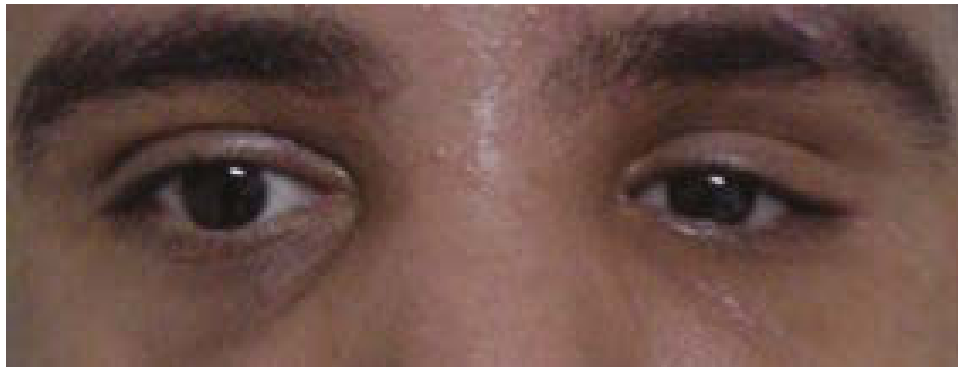### 2.1. Clinical history and photographic documentation

At this stage, the clinical history of the patient is established. It is then possible to determine the history of the current injury (history and understanding of the dynamics of the trauma), previous injury history, medical history, family history, social history, and physical examination. Photographic documentation is an important tool for recording the facial features and alterations prior to the proposed treatment (**Figure 1**).

It is also valuable information from a legal standpoint. Extraoral photographic shots should include front and side views of the patient, always aiming at a good positioning of the head whenever possible. Intraoral views should reveal pre-surgery dental occlusion and the presence of puncture or penetration wounds. Fractures involving the orbital content may be associated with the incarceration of the extrinsic muscles of the eyeball or even nerve damage, causing ophthalmoplegia, dystopia, diplopia, and sometimes enophthalmos because of the increase in the orbit perimeter (**Figure 2**).



**Figure 1.** (A) and (B)—Photographic analysis.



**Figure 2.** Left eye—enophthalmos and hypophthalmos.

The photographic recording of those alterations is extremely relevant for the comparison of pre- and post-surgery parameters [3]. The combination of the anamnesis, physical and radiographic examinations, and photographic analysis allows for the initial dimensioning of the trauma.

## **2.2. Clinical assessment**

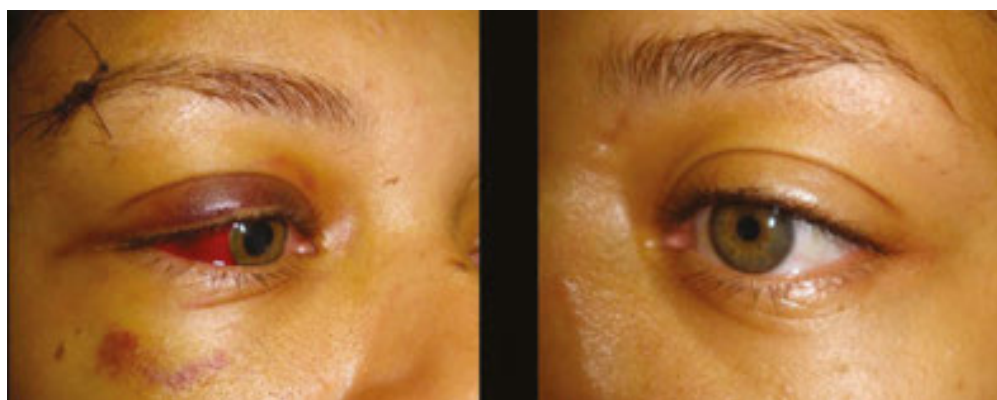When ATLS has been concluded, attention is directed to the following parameters:

### *2.2.1. Visual acuity*

The evaluation of the pupils and the eyeball is carried out in accordance with the Glasgow Coma Scale (GCS) during the neurological examination of the patient [4]. When the patient is stable, the examination of the face, carried out by the maxillofacial surgeon, should focus on the optic pathways in search of alterations, which might point to possible direct or indirect lesions of the CNS. The examination also allows for an initial assessment of the integrity of the eyeball. Such measures are important as part of the basic neurological and ophthalmological

examinations and could contribute to the identification of possible lesions that have a risk of leading to visual loss or amaurosis. In CMF trauma, the initial ocular evaluation carried out by the maxillofacial surgeon is essential for patients with fractures on the midface [4–7].

It is worth keeping in mind that the specialized ocular evaluation for patients who have open or closed lesions of the eyeball is to be carried out by an expert ophthalmologist. Early diagnosis of the cause of amaurosis is essential for the treatment of patients [5, 7], and its assessment includes the following: detailed clinical history, physical examinations, and imaging [7]. All CMF trauma patients need to be examined, as apparently mild lesions or ones which have not been noticed, may lead to complications which could lead to amaurosis, even in the absence of facial fractures [5]. The initial assessment of the optic pathways and cranial nerves (CN) of the superior orbital fissure (SOF) consists of the following: (a) assessment of pupil diameter; (b) response to light—through photomotor and consensual reflex; and (c) assessment of ocular movements. The assessment of eyeball tension by means of gentle touching [5] could help in the examination of the eyeball structure, as a decrease in tension could point to rupture of the eyeball.



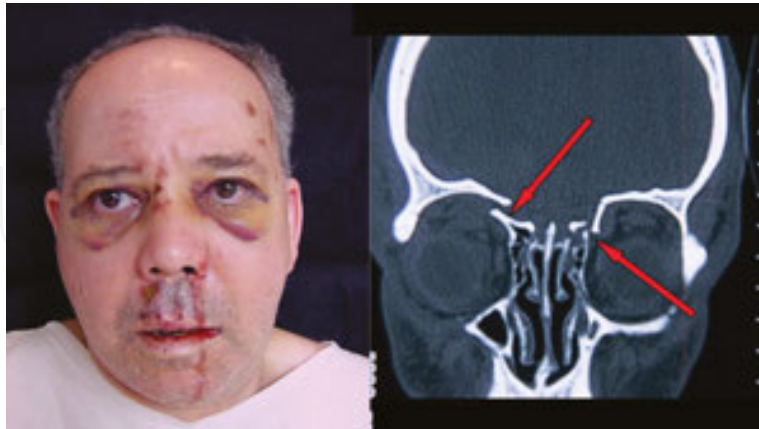**Figure 3.** Right eye pupil dilated and alterations related to visual acuity after CMF trauma.

According to the literature [5, 8], the presence of relative afferent pupil defect (RAPD) is considered to be a sensitive clinical sign of visual deficiency. The second CN is assessed by means of visual acuity tests, pupil reactivity, fundoscopy, perception of color, and visual field [5, 7]. The assessment of the optic pathways depends on the clinical conditions of the patient [7, 8]. It is carried out on patients who are awake and cooperative and difficult in patients who are unconscious [5, 6], but every effort should be made to evaluate the visual function in the initial examination [7, 8]. Studies show that amaurosis may occur as a result of optical ischemia which occurs 90–120 min after the trauma. Some authors state a longer time interval, however, the best results in treatment are observed in early approaches [6] (**Figure 3**).

### 2.2.2. Cerebrospinal rhinorrhea

Patients with trauma in the central region of the face or those who present signs of disjunction in the frontal-ethmoid-maxillary region, and, therefore, an impairment of the cribriform plate

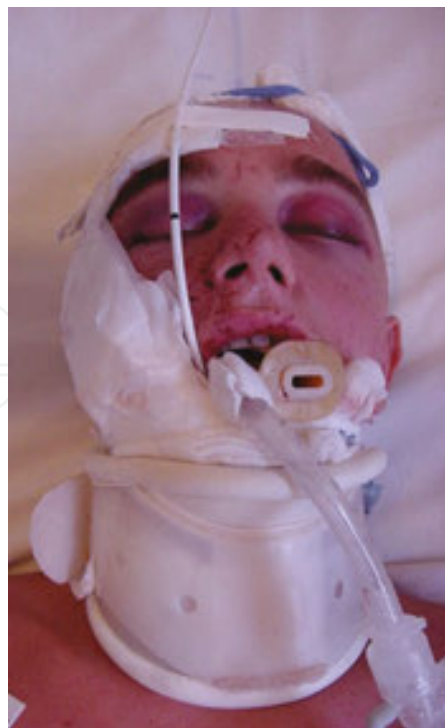should be assessed with the hypothesis of cerebrospinal fluid leak, known as cerebrospinal rhinorrhea borne in mind (**Figure 4**).



**Figure 4.** Patients with baso-ethmoid-orbital fracture and cerebrospinal rhinorrhea.

### 2.2.3. *Cervical spinal cord trauma*

This situation is evaluated during the “A” phase of ATLS, in which patients normally wear a cervical collar. Possible manipulations that are deemed unavoidable should be carried out with fixation devices that prevent head and spinal cord movement (**Figure 5**).

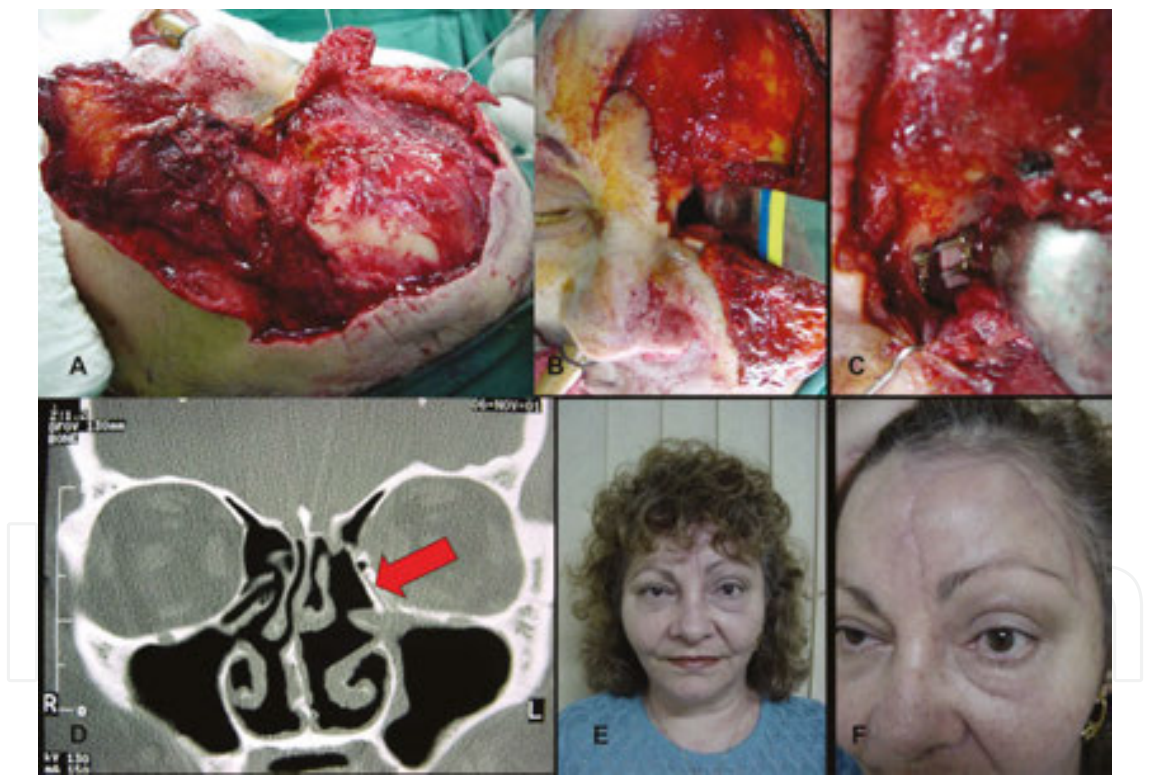

**Figure 5.** Fixation devices that prevent head and spinal cord movement.



2.2.4. Myocutaneous injuries

Assessment of previous tetanus immunization should be done. Patients who have been immunized and have received a booster shot within the last 10 years and who have wounds with no risk of tetanus **do not** require prophylaxis. The wounds, which present tetanus risk, include those which are highly contaminated by dirt or fertilizer, slough, and deep puncture wounds. Patients with wounds that are a tetanus risk and who have not received a booster shot within the last 5 years should be treated with 0.5 mL of tetanus toxoid. If patients have not received a booster shot within the last 10 years, it is possible to choose to give them 250 IU of homologous tetanus immunoglobulin, and a booster shot, followed by the complete immunization cycle [9]. However, it is important to emphasize that generally the health systems of each country recommends immunization according to their own criteria. The wounds should be treated as quickly as possible so as to ensure the covering of hard and soft tissue avoid infection and healing by secondary intention, which has considerable potential for forming scars that result in aesthetic and functional damage. If necessary, it is possible to use regional flaps for the covering defects [9] (**Figure 6**).



**Figure 6.** (A)–(F) – Patient with severe soft tissue injury and medial orbital wall fracture. Immediate reconstruction of the skeletal and soft tissues.

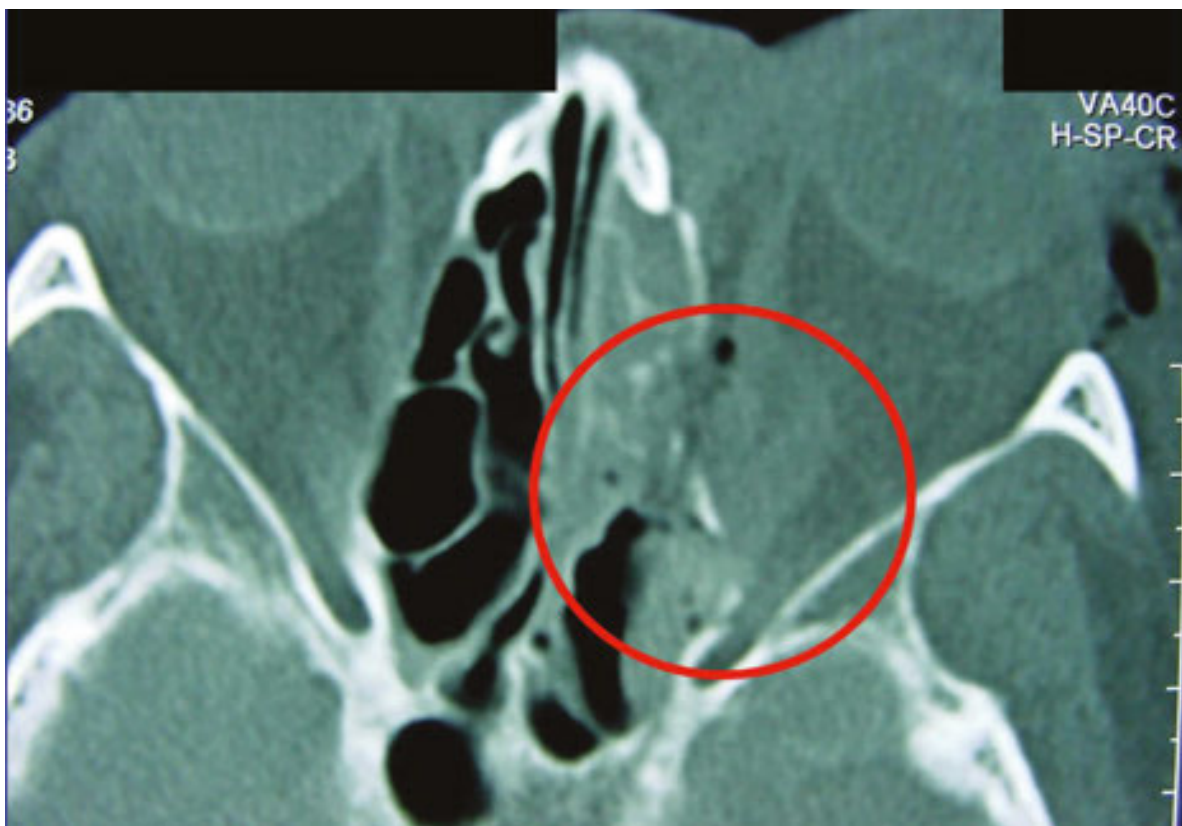
2.2.5. Other trauma

The maxillofacial surgeon should keep in mind that the dynamics of trauma, which is directly related to the kinetic energy, could lead to other associated fractures and concomitant other

musculoskeletal and visceral injuries which should be sought. Thus, combining the initial dimensioning of the injury and the initial clinical evaluation, the surgeon must quantify the “degree of apparent impairment” of the trauma.

### 2.3. Imaging and diagnostic assessment

Imaging obtained through helical computed tomography scanning (CT scans) is important in the assessment of CMF Trauma; as the facial skeleton amounts to one of the most complex anatomical relationships and three-dimensional combinations of bone anatomy. It may still be pointed out that in polytrauma patients the sensitivity of contrast of the various densities on the CT can identify a wide variety of foreign bodies which may be present, depending on the nature of the trauma (such as fragments of wood, plastic, glass, and other materials). CT is considered to be a primary diagnostic tool, especially in the field of traumatology. It is important that the surgical and radiology teams collaborate on the needs of the surgical team and the technical possibilities of every piece of equipment that the radiology team may offer, which should be exploited via the installed software at hand to optimize the standards of patient evaluation (**Figure 7**).



**Figure 7.** CT scan axial section showing fracture of the medial wall and orbital apex.

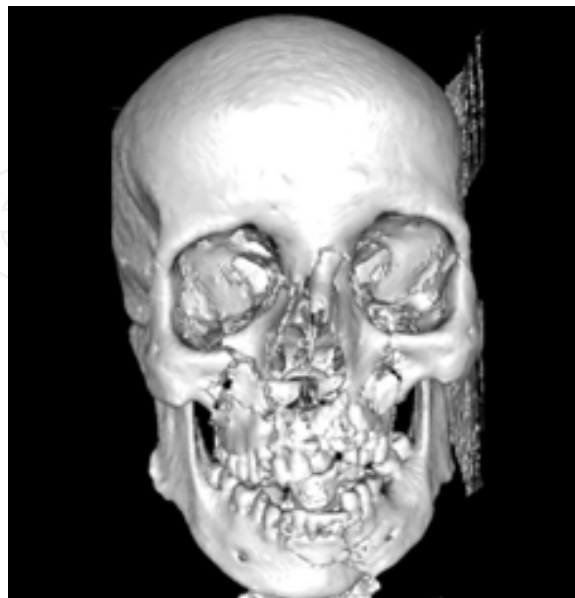The main advantages of CT, which the authors call the “Decalogue of Helical Computed Tomography,” include the following:



1. Being non-invasive;
2. Minimum discomfort for the patient;
3. Low exposure to radiation;
4. Greater speed in the execution;
5. Maximized details;
6. Allows for multidisciplinary evaluations;
7. Allows for the reconstruction of images;
8. Allows for the establishment of investigation protocols;
9. Guides viable surgical approaches; and
10. Facilitates the analysis of results.

#### *2.3.1. Technical possibilities of CT scan*

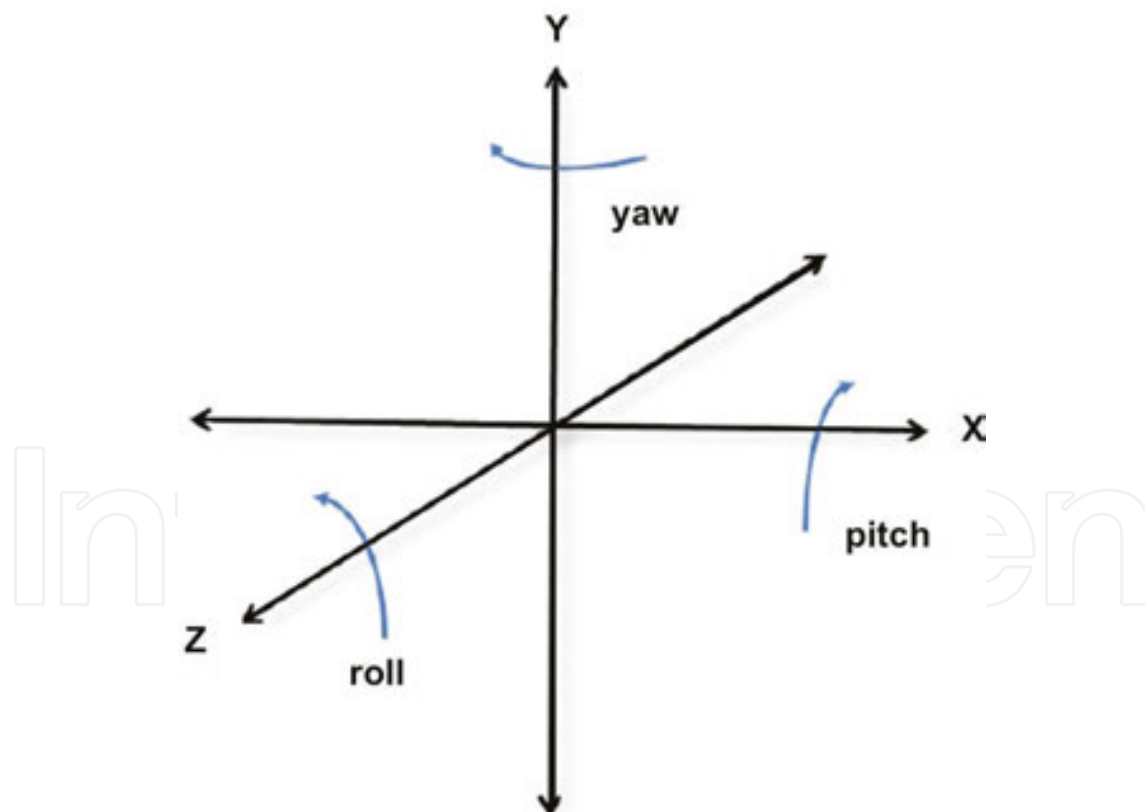
CT scan acquisition of images is possible with the patient lying down or the patient sitting up. In patients that are trauma victims, the “lying down” position is frequently used. CT scan allows for the acquisition of images of the head (skull, maxilla, and mandible) in a few seconds, with the patient lying down (supine position). Hospital tomography scans are of the helical or spiral type, and are fourth generation devices and have a significant reduction of the image-acquisition time, which has enabled the complete study of the head in less than one minute. Spiral-CT allows for high-quality multidisciplinary and three-dimensional (3D) reconstructions (**Figure 8**).



**Figure 8.** CT scan 3D reconstruction in a patient with panfacial fracture.

Zimmerman et al. [10] stated that spiral-CT is the diagnostic method of choice for assessment of severe brain trauma in pediatric patients. As a routine, the authors recommend to delimit in scout view the *axial sections* between the vertex of the skull and the submandibular region, and the *coronal sections* between the nasal and occipital points. With those limits and the programming of thin slices (equal to or smaller than 1 mm) and extension of the Digital Imaging and Communications in Medicine (DICOM), it is possible to evaluate with relative precision the totality of the craniofacial skeleton. It is important to note that in patients with cervical spinal cord trauma the study of the cervical spine during the screening must be included. It is possible to evaluate bone thickness, to obtain linear, angular, and volumetric measurements. The acquisition of images enables skeleton reconstructions with the use of virtual surgical planning applications, through which it is possible to plan the spatial position of the mandibulomaxillary relation to the skull with precision, evaluating three dimensions (Figure 9).

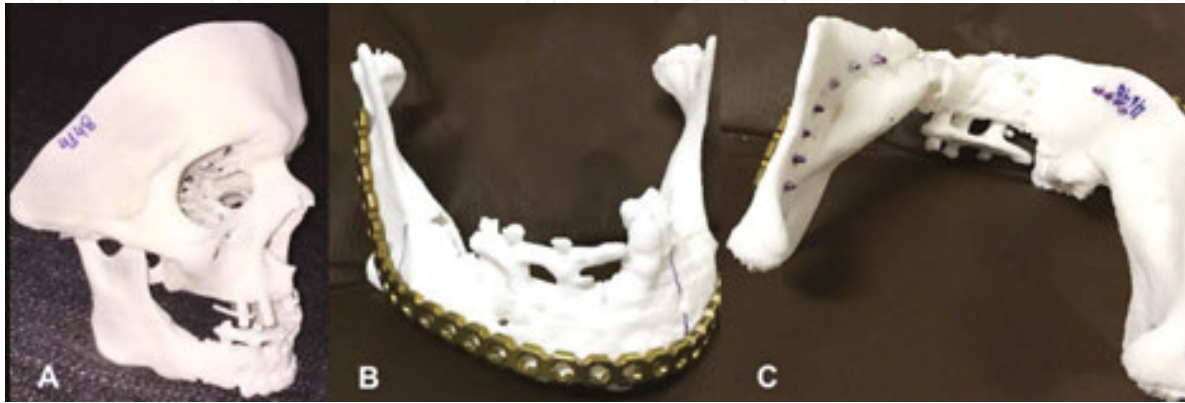
1. Yaw axis or “Y” axis;
2. Lateral axis, pitch axis or “X” axis; and
3. Roll axis, longitudinal axis or “Z” axis.



**Figure 9.** The three axes: yaw axis or “Y” axis, pitch axis or “X” axis, and roll axis or “Z” axis.

It is also possible to plan the surgical sequence and the kinds of fixation materials, the anatomical contours and the size of screws to be used. Therefore, it is possible to quantify and

to qualify the skeleton fixation material to be used in the surgery. If the surgeon does not have the software to make a complete virtual surgical plan, the quality of the obtained image allows for the printing of biomodels with 3D printers. It is then possible to plan the surgical procedure by repositioning fractured segments, bending the plates, and choosing the size of the screws that are to be used for skeleton fixation (**Figure 10**).



**Figure 10.** Biomodel obtained by 3D printer for surgical planning.

From those images, it is possible to carry-out a high-quality two-dimensional multiplanar evaluation of the craniomaxillofacial region, with the *axial*, *coronal*, and *sagittal* sections. The 3D reconstruction of the images illustrates the trauma from the point of view of general assessment. It is, therefore, important for the 3D evaluation. It should be pointed out that 3D reconstruction by itself is not yet the ideal reconstruction for pre-surgery assessment of the orbital cavities, as the low thickness of the medial or ethmoidal walls of the orbit and of the orbital floors do not enable the viewing of good-resolution, irregularity-free images. However, it is of particular importance for the treatment of sequelae of trauma and congenital deformities, for the planning and guidance of osteotomies. The 3D reconstruction helps the maxillofacial surgeon more than it does the radiologist. However, one should keep in mind that in order to obtain a good-quality 3D reconstruction the slices must be of low thickness, so as to avoid the so-called stacking artifacts.

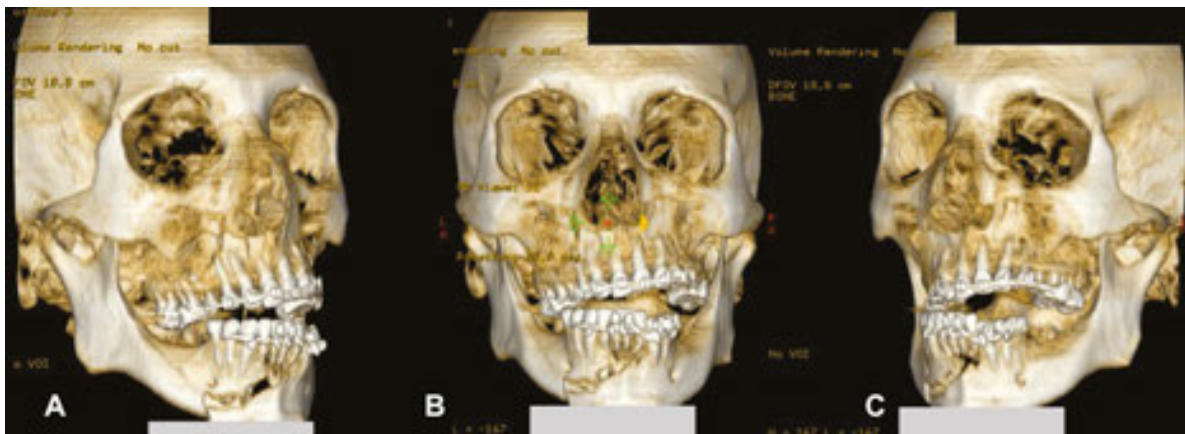
CT scan images that can be combined in a two-dimensional or in a 3D way make the diagnosis easier and provide more effective guidance for treatment. The use of CT scan must be preceded by the mental incorporation of the sectional anatomy of the craniomaxillofacial skeleton, enabling the clear and precise identification of the structures that are involved in the object of the evaluation. It is a diagnostic instrument that offers advantages which make its use more than just an imaging resource.

The presence of metallic components in the teeth or bones may present problems for the acquisition of images. The use of titanium plates and screws causes interference less frequently. Considering the highlighted points, the evaluation of the patient with traumatic deformity by

imagery allows the maxillofacial surgeon to quantify the “*degree of anatomical impairment*” of the trauma and to establish the diagnosis for the planning of treatment.

## 2.4. Planning of the treatment

For the treatment of complex facial trauma, it is important that the maxillofacial surgeon and team have core knowledge of craniofacial anatomy, of its pathophysiology, principles of individualized treatment of each fracture, the biomechanical basis of the craniomaxillofacial skeleton, and the facial reconstruction sequence. In the past, when imaging resources were limited to conventional two-dimensional radiographs and the absence of functionally stable internal fixation (SIF), complex traumas were often treated in a conservative manner with limited surgical approaches and frontal skeleton wire suspensions and intermaxillary fixation (IMF) with steel wires. The diagnosis and consequent treatment of those fractures sometimes were not satisfactory. Important complications, including **dental malocclusion, alterations in ocular motility and visual acuity** (dystopia, ophthalmoplegia, and diplopia), were relatively common, and numerous **aesthetic deformities** such as **severe asymmetry, enophthalmos and hypophthalmos, elongations or facial retrusions** persisted [11–13] (Figure 11).



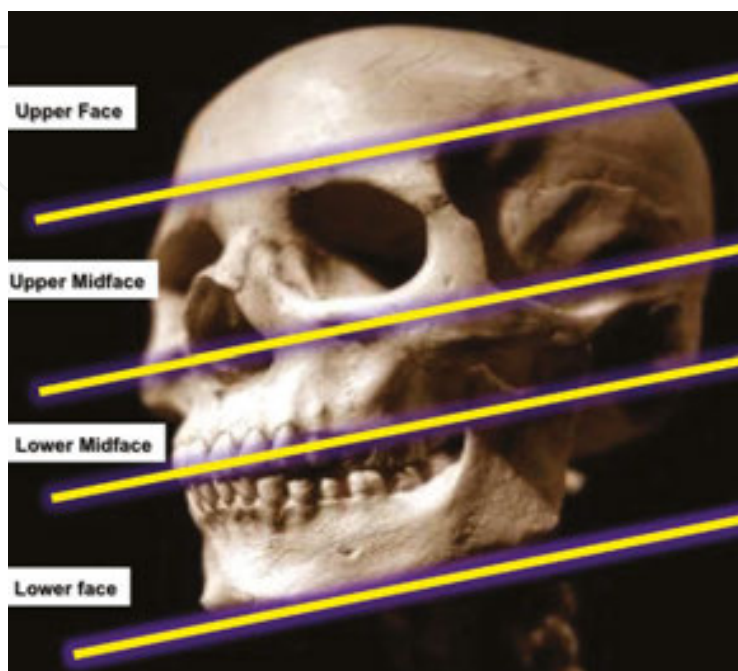
**Figure 11.** (A)–(C)—CT scan 3D reconstruction showing complex fracture and retrusion of the maxilla.

The gold standard for treatment is early diagnosis by means of CT, with a three-dimensional and volumetric evaluation of the entire facial skeleton, which makes it possible to plan adequate surgical exposure and the use of SIF.

It is important to know the “*degree of anatomical impairment*” to classify complex trauma. Follmar et al. [14] divides the face into four segments (**Figure 12**):

- a. **Frontal Region** (frontal bone, frontal sinus, supraorbital ridges, and orbital roof)—Physiognomically constitutes the **Upper Face**;
- b. **Upper Midface**—composed of the orbital floors, lateral and medial orbit walls, naso-orbital-ethmoid region (NOE), nasal bones, nasal septum, and the zygomaticomaxillary complexes or malar eminences;

- c. **Lower Midface**—composed of teeth-supporting portions of the jaw and hard palate; for containing those structures, it is also called the “occlusal Unit” by some authors [15]; and
- d. **Mandible or Lower Face**—the movable third of the facial skeleton.



**Figure 12.** The face in four segments.

According to Follmar’s classification [14], it can be said that the so-called Panfacial fractures are those that affect at least three of the four axial segments of the facial skeleton. To clarify the frontier between the Upper Midface and the Lower Midface, it is represented by the imaginary line of the LeFort I fracture line [14, 16]. The surgical treatment for facial reconstruction is challenging because it is complex. The treatment plan is related to the existing fractures and also to the access routes for the fixation of the fractures, choosing of the best areas for the use of bone fixation (plates, mesh, and screws). It is important to highlight the fact that craniomaxillofacial trauma is complex, panfacial with loss of soft and/or hard tissue that may lead to difficulty in the application of osteosynthesis material in the areas that are ideal for support of physical load. Besides, high-energy trauma, which sometimes presents with comminution, may also present increased difficulty for the placing with miniplates and screws, especially because of the impairment of bone vascularization [17].

It is important to point out that a complex craniomaxillofacial trauma patient should not be treated as if they have “some isolated fractures”; because traumatic brain injury (TBI), spinal cord injury of various levels, acute or in-progress impairment of airways, pulmonary contusion and eventual restriction of thoracic expansibility (fractured ribs, pneumothorax), or abdominal trauma and loss of intravascular volume may be associated with it may be missed in the first evaluation [16].



Treatment will involve:

1. Choosing of surgical approaches;
2. Initial selection of fixation systems;
3. Planning of the reconstruction sequence
  - 3.1. Reconstruction of the craniofacial unit and/or
  - 3.2. Reconstruction of the central segment and/or
  - 3.3. Reconstruction of the maxillomandibular unit.

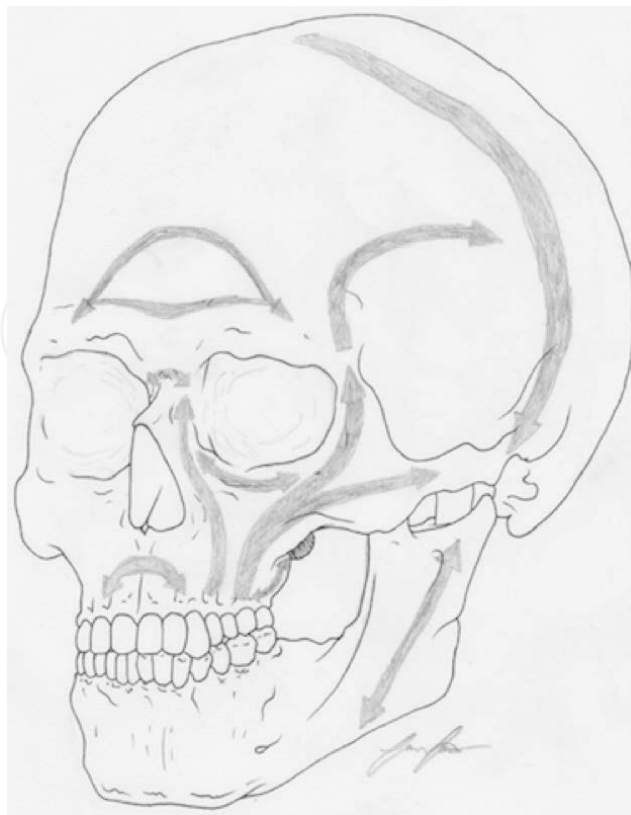
The first described surgical approaches for treatment of facial fractures were small, limited approaches, with direct access to the fracture areas. It is currently known that the correct 3D reconstruction of the face can only be accomplished by means of wide surgical exposition, which allows for the reduction and fixation of fractures [13, 18, 19], by reconstructing the jaw horizontally and vertically at the zygomatic and naso-orbital-ethmoid (NOE) area, the LeFort, palate, frontal region and the frontal sinus [15]. For those reasons, complex facial fractures must be treated by means of wide surgical access, via coronal approach for exposure of the frontal, frontozygomatic, frontoethmoidal, and fronto-orbital regions [20], with or without preauricular extension subciliary and subtarsal approaches which can sometimes be replaced by transconjunctival approaches; full maxillary surgical approach for exposure of the entire jaw, as well as approaches pertinent to jaw fractures, which can usually be intraoral, extraoral or both, depending on the topography of the fractures.

Other surgical approach should be considered, such as the use of pre-existing lacerations. Sometimes, the lacerations that are a consequence of trauma are closely associated with the fracture areas. The use of those lacerations as surgical approaches should be considered when they offer adequate exposure for the reduction and fixation of fractures. The advantage of those approaches is avoiding new surgical incisions. Surgical approaches should address the safety of noble structures and attention to cosmetic considerations in order to permit an esthetic scar [21]. Extraoral approach to the jaw should be made carefully, considering the branches of CN VII branches, responsible for the motility of facial muscles [21]. When the surgical approach has been made, the maxillofacial surgeon can expose the fractures, which will let the team know what the “degree of real impairment” is.

## **2.5. Basis for the three-dimensional reconstruction of the face**

### *2.5.1. Zones of greater resistance in the craniofacial skeleton*

The Midface human skeleton has evolved to resist the vertical forces of mastication. It protects the face and the base of the skull against various kinds of trauma. Those zones of greater resistance are known in the upper face, midface and lower face or mandible as vertical, horizontal, arch or sagittal buttresses, and platforms (**Figure 13**).



**Figure 13.** Zones of greater resistance in the craniofacial skeleton.

Facial reconstruction consists of 3D reconstruction in *vertical, horizontal, and sagittal buttresses* and the *platforms*.

The **vertical buttresses** include:

- (a) *Nasomaxillary or canines* which are located in the canine fossa and extend to the orbits;
- (b) *Zygomaticomaxillary* which include the zygomatic bones up to the orbital rims and zygomatic arches; and the
- (c) *Pterygomaxillary* which include the pterygoid processes of the sphenoid bone and the maxillary tuberosities. Those buttresses are not reconstructed because of the difficulty of access [13].

**Vertical buttresses in the Lower Face** include the following:

- (d) *Condyles of the mandible*;
- (e) *Angle of the mandible*; and
- (f) *Mandibular ramus* [15].

The condyles and ramus of the mandible establish the posterior vertical height of the face [13] and are important anatomical structures which should be considered at the time of facial reconstruction, so that there are no alterations in facial height.

The **horizontal buttresses** are as follows:

- A. *Frontal bar* which is a key area in the reconstruction of Joseph Gruss's Outer Facial Frame [15];
- B. *Arches*:
  - 1. *Interorbital* or *supranasal* which unites the nasomaxillary or canine buttresses, in the upper part;
  - 2. *Infranasal* which unites the nasomaxillary or canine buttresses, at the base;
  - 3. *Supraorbital* which unite the nasomaxillary or canine buttresses to the zygomatic buttress;
  - 4. *Infraorbital* which unite the nasomaxillary or canine buttresses and zygomatic buttresses in their medial portion; and
  - 5. The *malars* which unite the zygomatic and pterygoid buttresses.

**Horizontal buttresses in the Lower Face** include:

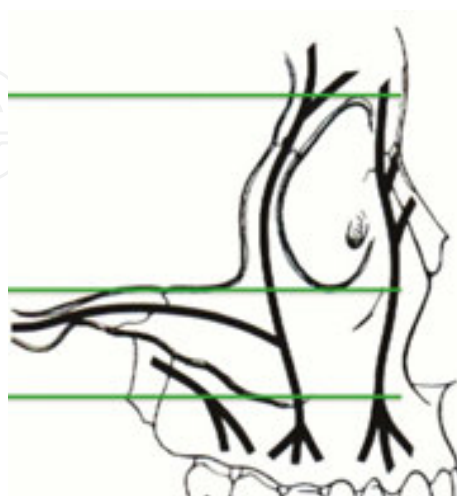
The mandible *body*;

The *parasymphysis*; and

The *symphysis*.

The **sagittal buttresses** are represented by the *zygomatic arch*, the *maxilla*, and the *mandibular body* [15].

The so-called **platforms** are references of the Upper Face and Midface which correspond to imaginary ramps from the auditory meatus which represent the facial projection from the *anterior cranial fossa*, the *orbital floors*, and the *floor of the nasal cavities* (**Figure 14**).



**Figure 14.** The craniofacial platforms as references of the upper face and midface.

The reconstruction of those vertical, horizontal, and sagittal buttresses and, consequently, the platforms is the basis for reestablishing the **projection, height, and width of the face** [13, 16]. They are essential triad for the three-dimensional reconstruction of the face. Nowadays, what is used, as a parameter for the three-dimensional reconstruction of the face is the intervention in the craniofacial and maxillomandibular units, which will be detailed further on, in the surgical approach sequence. The technique for reconstruction of the Midface has evolved from orthopedic and craniofacial reconstructive surgery with skeleton fixation and immediate bone grafting [22].

For the execution of the reconstruction of the craniomaxillofacial skeleton, one should take into account that in the upper midface and lower midface there is variable bone thickness and a factor in choosing the region that is more or less favorable to osteosynthesis; regions such as that of the body of the zygomatic bone, zygomaticomaxillary buttress, orbital rims, nasal bone, and the frontal bone are favorable to the placement of plates and screws for osteosynthesis, because they are regions of suitable bone thickness. On the other hand, regions of lower bone thickness such as the anterior wall of the maxillary sinus and orbital walls do not provide solid anchorage for the application of SIF, except for the lateral wall and roof, because they are respectively thicker.

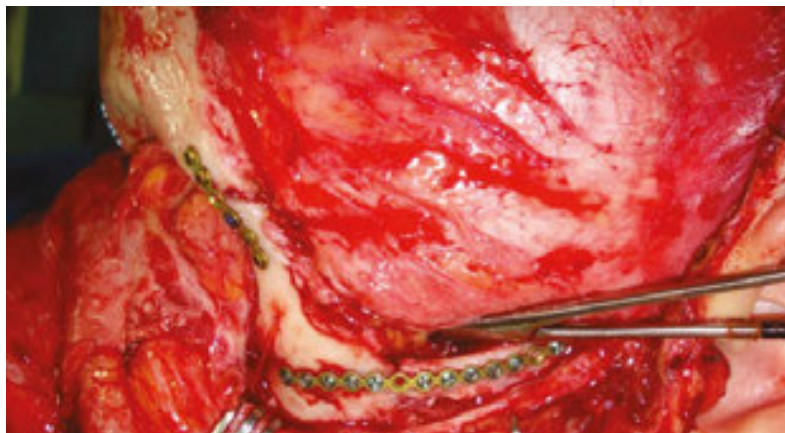The thickness of the frontal bone varies from 4 to 9 mm [22], so in some cases it is possible to use screws of that length without risk of damage to the Dura mater; it is important to pay attention to the frontal sinus, where the thickness is usually less. According to the AO Manual [15], the SIF material to be used for the reduction of Midface Fractures is neutralization plates (adaptation plates) or the Locking® System, in the regions of the above-mentioned buttresses. Regarding the SIF material to be used for the reduction of Lower Face fractures, it is possible to choose a number of systems for load sharing or load-bearing osteosynthesis.

## 2.6. Reconstruction sequence in multiple facial fractures

In the past, the starting point for the treatment of facial fractures used to be dental occlusion, with or without the use of surgical guides obtained by means of plaster models from complex, low-precision castings. In any case, occlusion is still an important reference for the reconstruction of facial buttresses during the procedure, not only because of the necessity of good occlusion but also because of the relation of the occlusal plane to the fixed facial skeleton; occlusion still occupies an important place in the treatment of facial fractures. However, guiding the reconstruction primarily by the occlusion leads to results which were faulty in some cases, regarding height, width, and facial projection. A good occlusion without the standards of correct skeleton positioning resulted in failures in reconstruction and residual facial deformities below the functional and aesthetic expectations of the treatment.

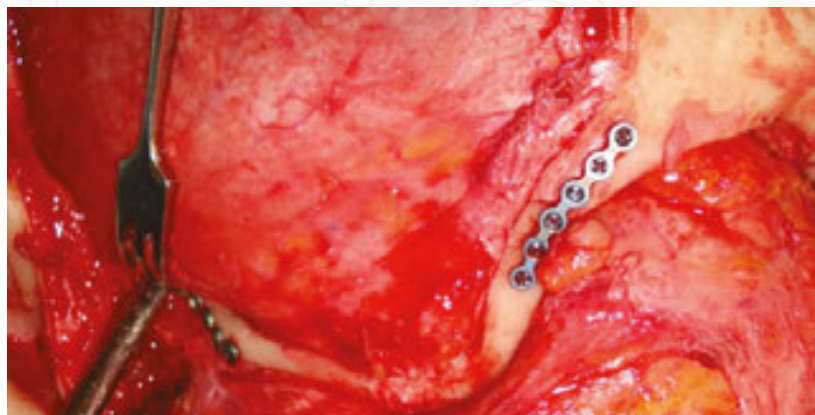
With this concept, 3D reconstruction has had significant progress in terms of results for patients who are victims of facial multiple trauma [23]. Several reconstruction sequences have been described [23–25] including the “top-down,” “bottom-up,” “inside-out,” and “outside-in” steps, with an emphasis on the zygomatic arches [11, 13, 26] ending up in the reconstruction of the naso-orbital-ethmoid (NOE) complex and establishing the upper midface and lower midface connection or on a “LeFort I imaginary line.” The reconstruction order is not more

important than the surgical planning. A prime factor for the good sequencing of the reconstruction is the identification of stable points of reference from which it is possible to initiate the sequence [16] of fixations that make up the facial skeleton. Simplifying and reconstructing the distribution buttresses of masticatory forces could be the secret to the treatment of extensive facial trauma patients. In order to accomplish the three-dimensional reconstruction of the face, most authors [27] recommend the management of the two primary facial units: the **craniofacial unit** and the **maxillomandibular unit**, from the so-called key areas to the three-dimensional reconstruction of the face; we can summarize these in the following manner: **Projection:** zygomatic arches and anteroposterior mandibulomaxillary position (**Figure 15**);



**Figure 15.** 3D facial reconstruction—projection—key area: zygomatic arches and anteroposterior mandibulomaxillary position.

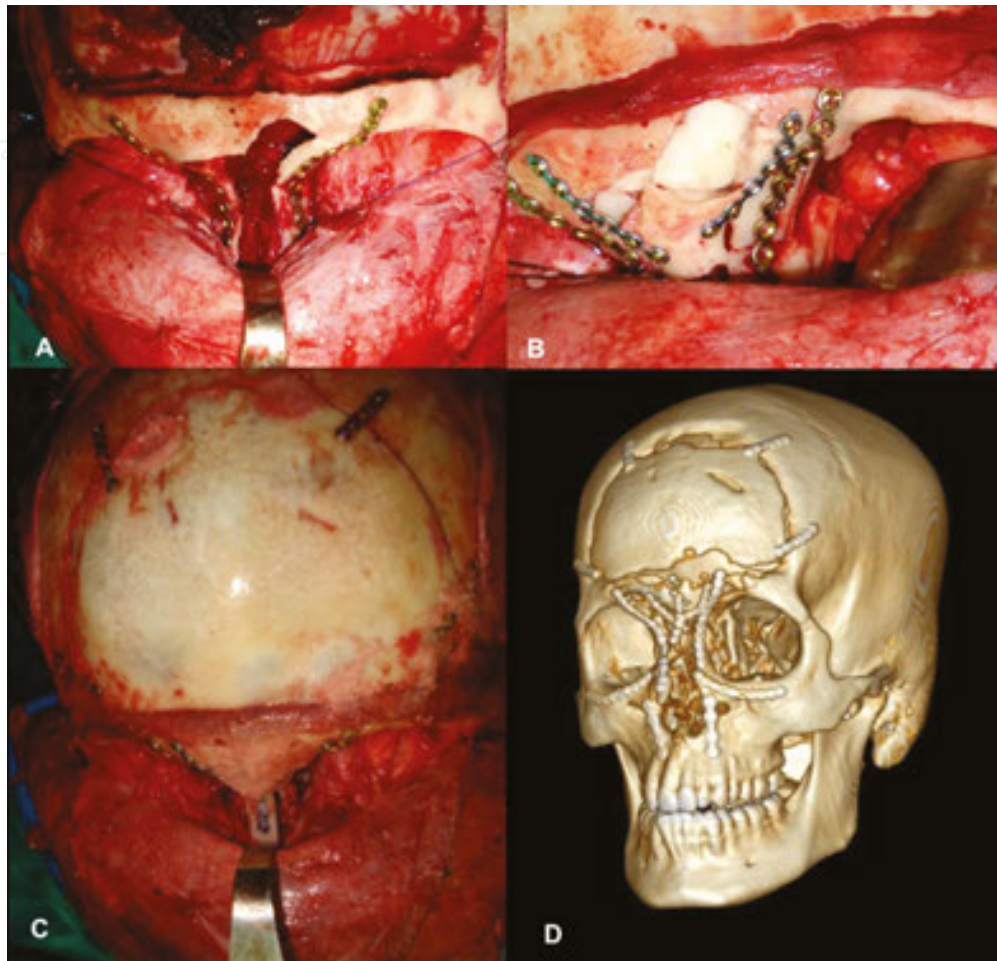
**Height:** Frontozygomatic suture and zygomaticomaxillary complexes, buttresses of the maxilla and mandible, especially the mandibular ramus and the condylar process (relation of connection between the Upper Midface and Lower Midface and Lower Face or Mandible (**Figure 16**).



**Figure 16.** 3D facial reconstruction—height—key area: frontozygomatic suture and zygomaticomaxillary complexes and buttresses of the maxilla and mandible.

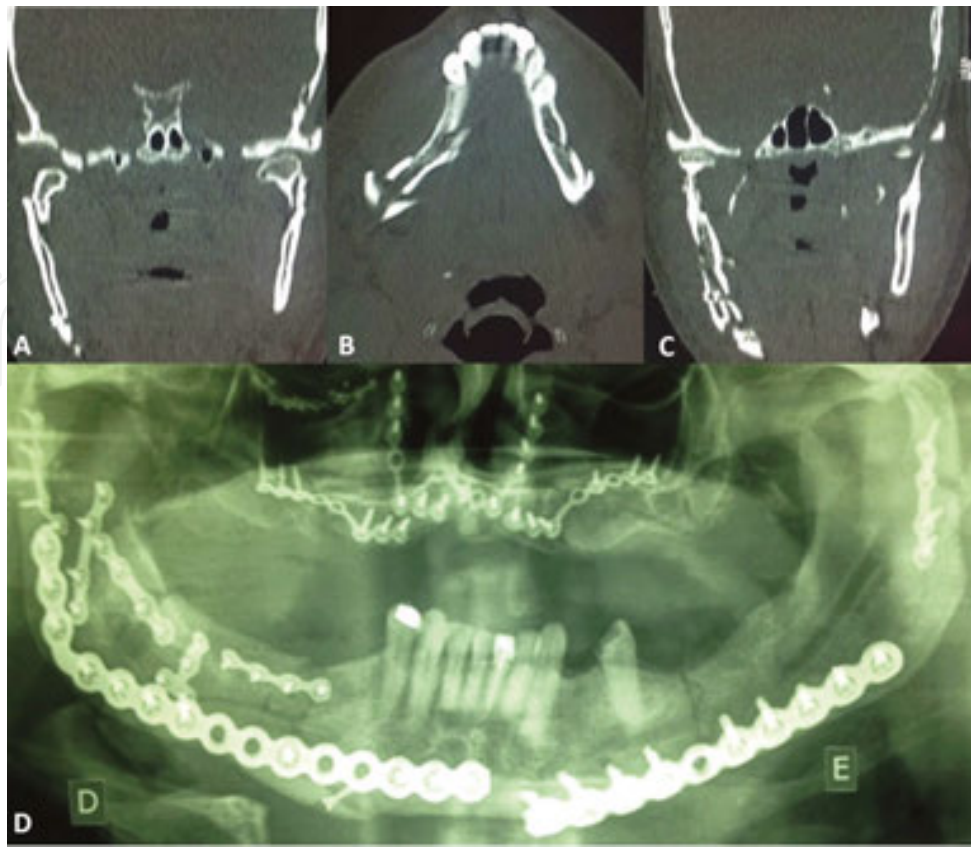


**Width:** Outer facial frame: frontal bar, internal orbits, zygomaticomaxillary complexes, (**Figure 17**) central segment of the face, and the correct arcuate contour of the jaw.



**Figure 17.** (A)–(D)—3D facial reconstruction—width—key area: outer facial frame—frontal bar, internal orbits, zygomaticomaxillary complexes, central segment of the face and the contour of the jaw. Patient with extensive frontal-nasal-baso-ethmoid-orbital fracture, subjected to three-dimensional reconstruction including the anterior cranial fossa and the “central midface.”.

As a rule of the entire facial skeleton, the treatment goes along a very simple concept of *exposing the fractures, identification of the anatomical references, and fixation of the buttresses*. Those fixations should begin with the simplification of the fracture lines, whenever possible, with Erich bars and/or plates and screws of lighter systems and monocortical screws. Interfragmentary screws can also be used, as they are simple, low profile materials. Screws for IMF are useful in the cases of fractures without much fragmentation of the alveolar processes because of the impossibility of ensuring adequate mandibulomaxillary “arcuate contour.” The execution sequence of the reconstruction may vary according to the extension of the fractures and, in general, should be initiated at the mandible through the intervention in the **maxillomandibular unit** made up of: (a) maxilla in the *lower midface*; (b) *buttresses of the mandible* (**Figure 18**); and (c) *dental occlusion* [13].



**Figure 18.** (A)–(D)—maxillomandibular unit—(a) maxilla in the lower midface; (b) buttresses of the mandible (complex fracture), and (c) final result.

The reconstruction of the mandible can be used for rehabilitation of the occlusion reestablishment of facial height and width, as well as of the posterior vertical height [11, 13, 14]. In fractures that reach the maxilla and the mandible, the hard palate region should be considered a guide for mandibular reconstruction; thus, the palate needs to be reconstructed so that it can be used as a reference for the latero-medial relation of the mandible.

However, it is important to pay close attention in the reductions of symphyseal fractures (especially when associated with bilateral condylar or subcondylar fractures) so that there is no enlargement of the mandibular arch, a fact which would lead to an erroneous reconstruction of the entire lower midface and upper midface, causing complete facial enlargement which would be difficult to correct later on. In that situation, the extraoral approach of the symphyseal fracture is justified for the perfect evaluation of the internal face of the mandible.

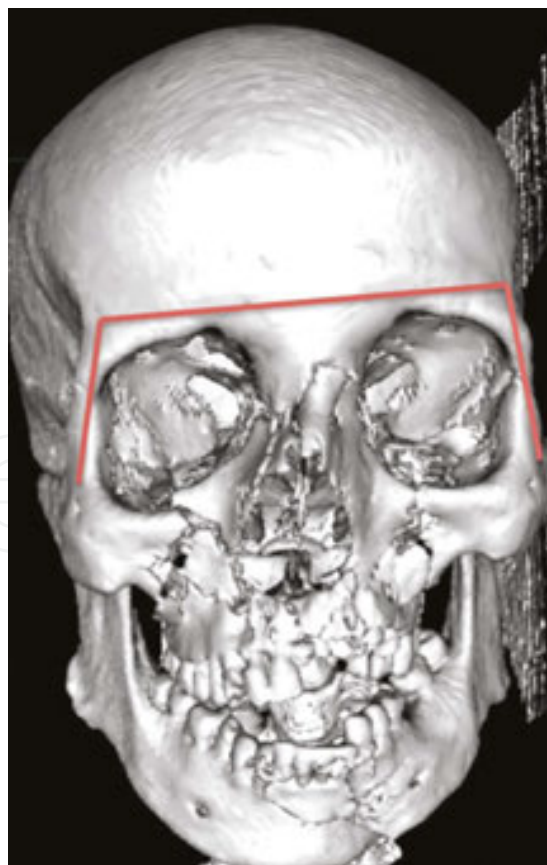
When there is a low subcondylar fracture without comminution and with good bone interface, it is possible to ensure the repairing of posterior facial height and then proceeds to the reduction of the other fractures in the mandibular arch [13].

From there, one carries out the reductions of the fractures of the mandibular arch (symphyseal and/or parasymphyseal and/or body and/or mandibular angle fractures), paying attention to the correct reduction and alignment of the internal cortex in order to avoid facial enlargement. To that end, digital compression in the region of the mandible angles contributes to an adequate

outline of the mandibular arch. When one uses a plate in the mandible that has sufficient strength and uses the fixation system of compression of the stumps promoted by the eccentric relation of the screws relative to plate (Dynamic Compression Plate – DCP®), the overbending maneuver which contributes to the correct alignment of the internal mandibular cortex is recommended.

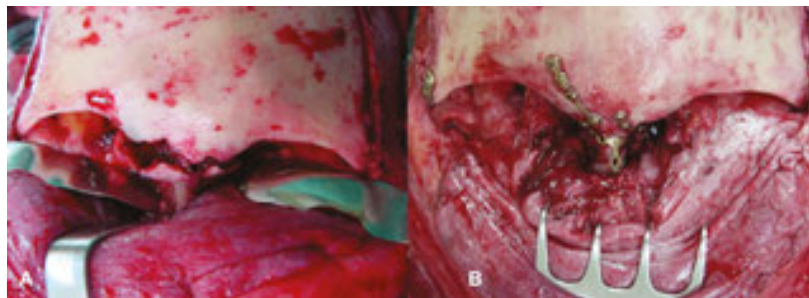
The chosen material for the fixation of the mandible should prioritize plates with intermediate segments for the fracture lines. One should avoid leaving instability orifices, which may represent areas of fragility of the fixation system. The choice of plates also includes the construction of a whole that promotes as much stability as possible without interfering with mandibular function and aesthetics. Plates of security to plate system, or Locking® System should be preferred, as they cause less compression of the cortical bone, lessening local osteolysis and lowering infections from failure in the fixation system.

The reconstruction of the **craniofacial unit** is made up of: (a) *Gruss's Outer Facial Frame* (**Figure 19**), which includes the frontal bar, zygomatic arches, and orbital rings [26], where the zygomatic arch is related to the reestablishment of width and facial projection; and (b) *Upper Midface*, known as "*Paul Manson's Upper Midface*" (**Figure 20**), where it is necessary to control facial width, taking into consideration the NOE region [28].



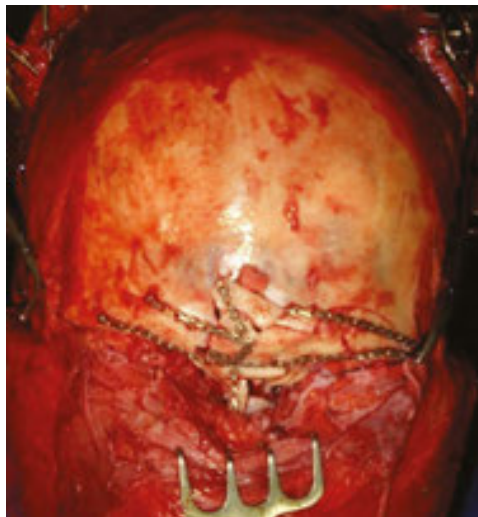
**Figure 19.** Frontal view, "Gruss' Outer Facial Frame."



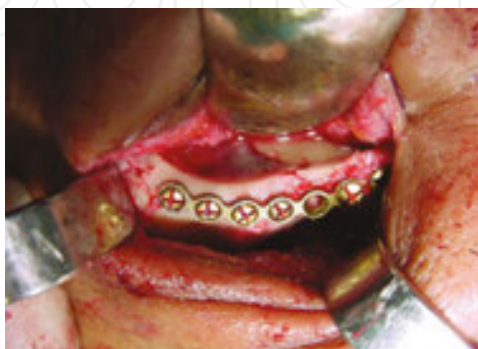

**Figure 20.** (A) and (B)—Reconstruction of “Paul Manson’s upper midface.”.

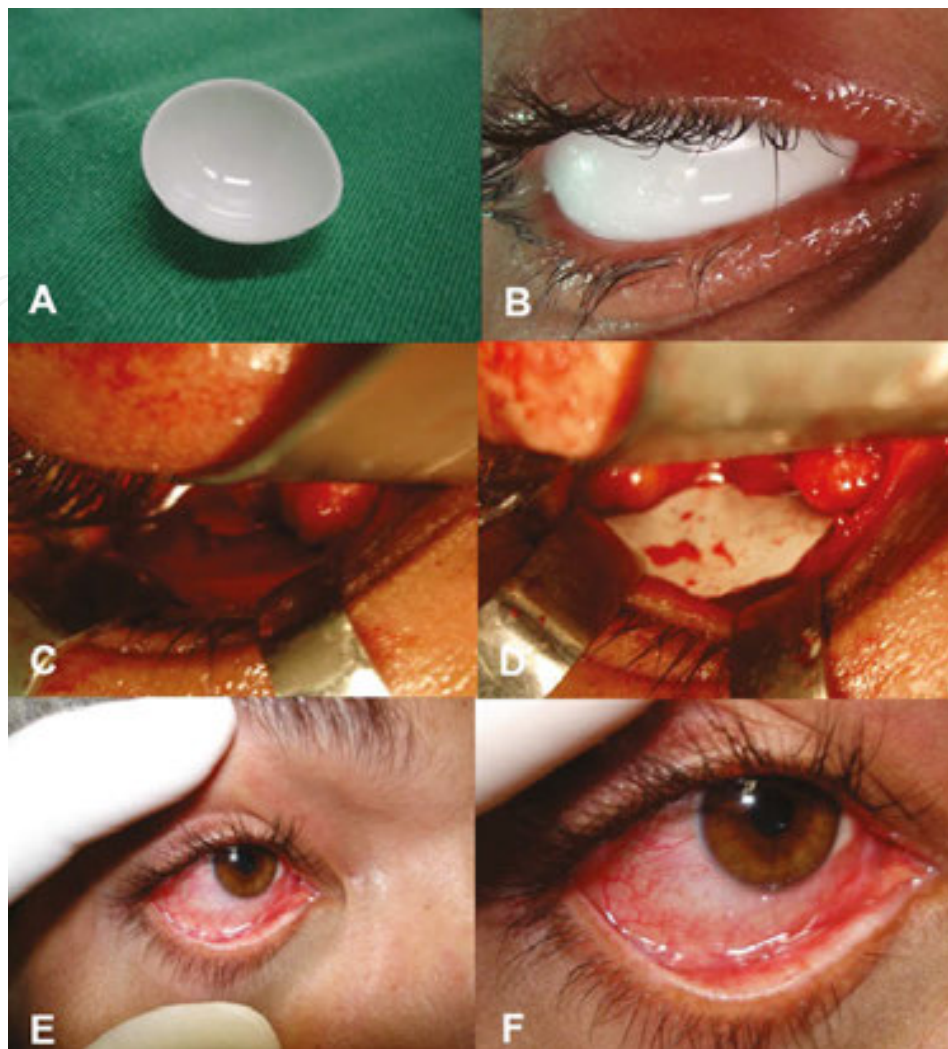
The coronal surgical approach (**Figure 21**) should be made on the supragaleal plane, that is, above the galea aponeurotica and of the subtarsal (**Figure 22**) or transconjunctival approaches (**Figure 23**), depending on the type and extension of the orbit fractures, or fragmentation of NOE fractures.



**Figure 21.** Coronal approach showing the reconstruction of the extensive frontal-nasal-ethmoid-orbital fracture.



**Figure 22.** Subtarsal approach.

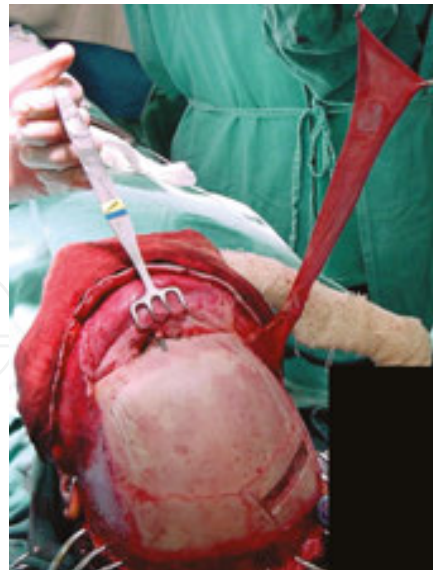

**Figure 23.** (A)–(F)—A patient with orbital fracture treated by transconjunctival approach. (A)–(B)—protective lenses; (C)–(D)—approach and use of polytetrafluoroethylene and (E)–(F)—follow-up of 07 days with excellent result.

One initiates the reconstruction of a unit, with the reconstruction of the outer facial frame and the reduction of the linear or fragmented fracture(s) of the anterior wall of the frontal sinus. For that stage, we can employ plates and screws of the 1.0 or 1.2 mm system, with or without bone grafts, titanium mesh, or other biomaterials depending on the degree of comminution and/or loss of substance at the fracture site. However, if there is a misaligned and/or fragmented fracture, a neurosurgical approach should be carried out.

If the fracture of the frontal sinus extends into the cribriform plate, associated with ACF fracture or not, the frontal sinus should be carefully curetted so that there is no remaining mucosa that is vascularized by small diploic valveless veins, the so-called Breschet veins [15]. Cranialization or obliteration should be carried out. In that case, the obliteration of the frontonasal ducts should be done and bone graft in the ACF should be used when necessary, associated with a pericranium flap (**Figure 24**) for repair of dura mater or use of other biomaterials for repair, such as polytetrafluoroethylene.





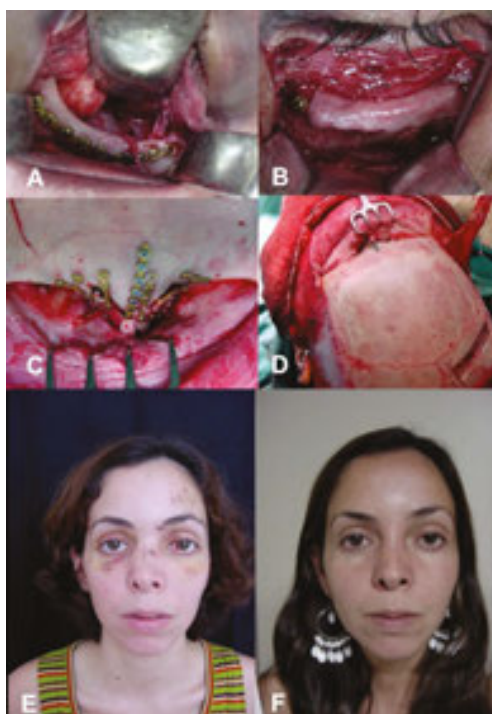**Figure 24.** Pericranium flap.

With the exposition of the frontozygomatic region and zygomatic arches, it is possible to reposition the zygomas by fixating them to the frontal bone and to the zygomatic arches. The initial positioning from the zygomas to the frontal bone can be done with a “pivot” steel thread that enables some rotation of the zygomaticomaxillary complex until the final reduction [16] with SIF. The SIF used in those areas is of the stable kind, with the necessary strength to support buttresses of distribution of force and muscle insertions. At this point, the lateral limits of the upper midface will be reestablished. At that stage, the maxillary fractures should be reconstituted and the maxillary buttresses repaired. IMF is again imperative and fixation materials need to be sufficient to support the masticatory load and compensate possible spaces without bone support. The fixation of those plates should be carried out with short monocortical screws so as to impair the upper airways as little as possible. The next step is the reconstruction of the infraorbital rims, when the zygoma and the maxilla are fixed upwards using delicate SIF, which will also provide the fixation of the central region of the face, the NOE region. SIF in the frontonasal region can also be used for the fixation of occasional nasal dorsum grafts. For that, it is possible to use systems of remarkable flexibility and low profile, avoiding touch sensitivity of the material that is employed. At this point, the reconstruction of the upper face and of the upper midface is finished, and the mandible is integrated to the lower midface with the use of IMF.

In order to “connect” the upper midface to the maxillomandibular unit one performs the reconstruction of the vertical buttresses, in the following manner: (a) nasomaxillary buttresses reconstruction that fixates the central segment of the face to the maxilla downwards, using SIF and (b) zygomaticomaxillary buttresses reconstruction which fixates the zygoma and the maxilla downwards, also using SIF. Completing the reconstruction of the vertical and horizontal buttresses, the next stage regards bone grafting or the employment of biomaterials for the reconstruction of the orbital walls, which usually do not withstand the use of screws, except

for the areas next to the orbital rims or in the region of the lateral wall and the ceiling, which are naturally thicker.

It is important to point out that in cases of fracture of the orbits, with extensive fragmentation of the walls and therefore an alteration in the “orbital continent,” it becomes necessary to reconstruct the orbital walls with bone grafts, malleable or preformed titanium plates, and other biomaterials to reestablish the contour of the internal orbit. In general, traumatic deformities of the orbital cavity may require contour correction or volumetric reconstruction, which will determine the kind of material that can be used in the reconstruction. However, that is a truly complex situation, as lesions of the periorbital area, occasional escapes of intraconal fat or post-traumatic lipolysis are factors that lead to the evolution of late enophthalmos.



**Figure 25.** (A)–(F)—NOE fracture treated by expanded approach. (A)–(B)—sub tarsal approach, (C)–(D)—coronal approach and (E)–(F)—pre and postoperative photos, 06 months follow-up.

When that kind of fracture reaches one of the orbits, it is possible to use the contralateral orbit as a parameter for the reconstruction and the projection of the eyeball as a guide to the reconstruction of the key area of the projection of the eyeball. Neuronavigation has been used as an adjuvant to treatment to obtain, among others, that parameter of the contralateral orbit and also adequate anteroposterior position of bone grafts and/or titanium mesh without damage to the optic nerve. Finalizing the reconstruction of the NOE region, with the reestablishment of the intercanthal segment [13, 24], one performs the reinsertions of the eyelid medial ligaments, in the posterosuperior region of the posterior lacrimal crests. After the grafting or inclusion of other biomaterials, one proceeds to the reinsertion, when necessary, of the lateral eyelid ligaments and to the bilateral facial resuspension before the synthesis of coronal access.

Adequate sequencing and, whenever possible, surgical approaches that are barely or not at all visible lead to results that are stable and aesthetically well accepted (**Figure 25**).

## 2.7. Support measures

Although some of the stages that are listed are not necessarily steps related to the surgical procedure to be carried out, they are important items which contribute in a significant way to the result of the definitive surgical treatment.

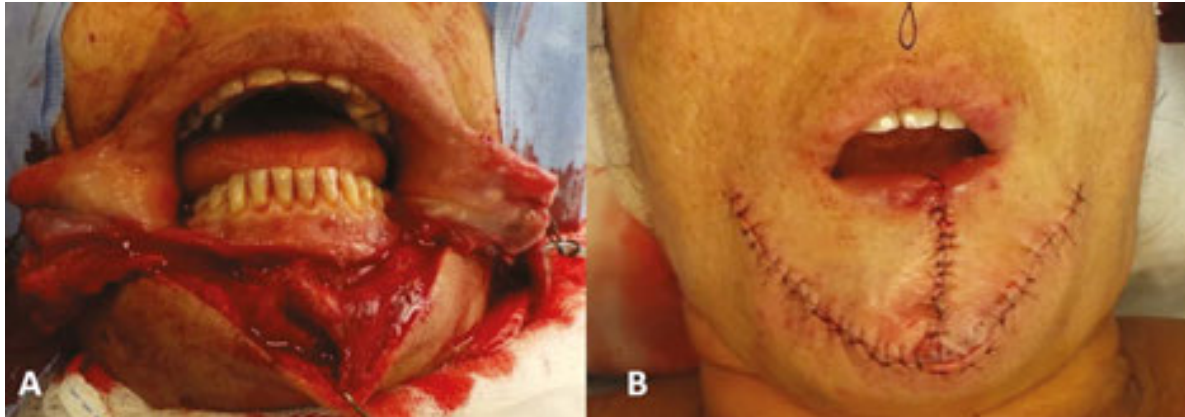
### 2.7.1. General support measures

1. Tetanus prophylaxis: human hyperimmune immunoglobulin;
2. Antibiotic prophylaxis;
3. Volume replacement;
4. Use of diuretics;
5. Steroids;
6. Analgesia;
7. Cryotherapy;
8. Headboard elevated to 30°;
9. Others medications routinely used by the patient;
10. Permeability of tracheal tube and/or tracheal cannulas;
11. Urinary catheter;
12. Venous puncture or venous dissection;
13. Hydro balance;
14. Vital signs; and
15. Oximetry.

### 2.7.2. Support measures for soft tissue

1. Preserve the integrity of soft tissue and noble structures;
2. Protection with dressings;
3. Protection of eyeballs;
4. Neurovascular structures;
5. Consider grafting and/or inclusions; and
6. Final reconstruction of soft tissue.

All alterations that have been identified in the clinical history, physical examination, and complementary examinations must be in the medical records and preferably photographed so that possible preexisting alterations are attributed to the treatment (**Figure 26**).



**Figure 26.** (A) and (B)—Immediate reconstruction, by Gilles flap, extensive lower lip injury caused by dog bite.

## 2.8. Complications

The authors divide complications to general and specific; they are subdivided as immediate and late; according to the moment they arise.

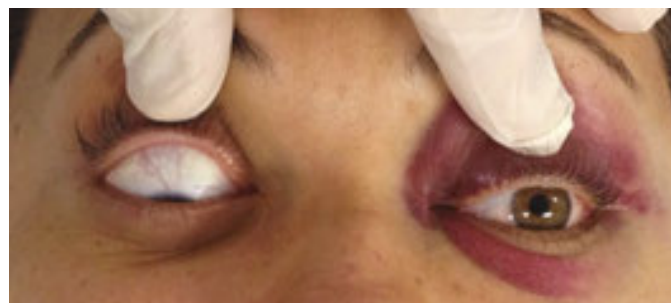### 2.8.1. General complications

#### A. Immediate:

1. Reconstruction failure;
2. Dental malocclusion;
3. Edema;
4. Bruises;
5. Hematoma;
6. Rhinorrhagia;
7. Cerebrospinal rhinorrhea: rare and normally associated with fractures of the cribriform plate or posterior wall of the frontal sinus associated with meningeal lesion;
8. Partial or complete neurogenic lesion: CN III, IV, and VI (ptosis, mydriasis and ophthalmoplegia), CN II (amaurosis);
9. Diplopia may have a neurogenic or mechanical origin (incarceration in fracture line) (**Figure 27**); and
10. Inadequate aesthetics.

**B. Late:**

1. Meningitis: most common intracranial complication;
2. Secondary mucocele: the average time interval between the trauma and diagnostic confirmation of the presence of secondary mucocele is about 7.5 years. (However, secondary mucocele has been reported from a period of two months up to 42 years after the trauma);
3. Frontal headache: most common complication after frontal sinus trauma;
4. Lesions of the lacrimal system which must be treated by a simple survey of the nasolacrimal duct or by dacryocystorhinostomy according to the severity of the lesion;
5. Infection;
6. Visibility of the implantable material: One must use titanium plates of low profile with adequate screws because they lead to a better aesthetic result and do not need to be removed; and
7. Eye dystopia and enophthalmos: inaccurate position because of inadequate correction of the orbital walls.



**Figure 27.** Mechanical incarceration extrinsic muscle of the left eyeball (superior rectus muscle) in fracture line (orbital roof fracture).

For a didactical dissertation, the authors divide the complications by anatomic topography of the affected facial thirds.

*2.8.2. Upper face fractures*

Among the immediate complications, we can mention infection, which rarely takes place thanks to great local vascularization; and CSF leak, which occurs to more than 10% of patients with frontobasal fractures. Treatment consists of lumbar drainage, rest, and antibiotic prophylaxis (third-generation cephalosporin) for the prevention of meningitis. If after one week there is no remission of symptoms, it will be necessary to study a possible surgical reapproach to repair the dura mater [29]. Intermediate complications are rarer and normally associated with an obstruction of the patency of the frontonasal duct. When that occurs, there may be the development of frontal mucocele, which should be surgically treated immediately [30].



### *2.8.3. Upper midface and lower midface fractures*

Hematoma and hemorrhage are the most common complications in the fractures of the midface. Among kinds of hemorrhage, those resulting from extensive blunt cut injuries are treated with local hemostasis and suture of the wounds. Rhinorrhagias are controlled with anterior nasal packing, associated with or without posterior nasal packing, for 48 h. In some situations of epistaxis refractory to the initial treatment, it is possible to use selective electrocauterization helped by nasofibroscopy or endovascular embolization. When hematoma is associated with orbit fractures, it can lead to serious complications. Retrobulbar hematoma is characterized by intense orbital pain, exophthalmia/proptosis, diplopia or reduction in visual acuity associated with mydriasis. In the presence of those signs and symptoms, tomography evaluation and emergency orbital decompression are mandatory [27]. Intermediate complications are normally associated with facial deformities caused by bad repositioning of the fractured bone segments or by failure in facial reconstructions.

Among late complications, we can mention:

enophthalmos, hypophthalmos, ophthalmoplegia, traumatic telecanthus, dacryocystitis, epiphora, lagophthalmos, diplopia, amaurosis, paresthesia, and nasal synechiae [30].

### *2.8.4. Lower face or mandible fractures*

Obstruction of the superior airways and hemorrhage is the most common immediate complications of the lower face. Obstruction of the airways may occur in patients with bilateral fracture of the parasymphysis, with glossoptosis; or patients who are victims of gunshot wounds that cause more damage to bone tissue and cervical soft tissue, with the formation of extensive swelling and bruising, evolving to acute respiratory failure [30].

Among late complications, we can mention infection, pseudarthrosis, nonunion, malunion, and ankylosis of the temporomandibular joint (TMJ) [27].

Infections are normally associated with the presence of foreign bodies in the interior of soft tissue, contamination of the osteosynthesis material, devitalized bone fragments, or non-vital teeth. Treatment is based on the removal of the focus of infection and antibiotic therapy.

Pseudarthroses, nonunions, and malunions are usually related to failure in the stabilization of the osteosynthesis material or to failure in the anatomic reduction of the fractured segments. The treatment requires surgical reapproach [27]. TMJ ankylosis is one of the complications of intracapsular fracture of the mandibular condyle, associated with failure in postoperative physiotherapy. The treatment is surgical resection of the ankylosed mass and articular reconstruction with the use of autogenous bone graft or prosthetic joints [27, 30].

## **3. Conclusion**

The management of CMF trauma should be understood as a continuing learning. Knowledge of anatomy and other basic sciences, the understanding of the pathophysiology of trauma, the

correct triage of the traumatized patient stratification sequence combined with good specialized training are factors that will determine the outcome and yield the best chance for a correct diagnosis and the more precise and safe treatment result. Finally, it should be kept in mind that “the best chance of the patient is the first.” For this reason, the well-conducted initial care, for all who participate in treatment, is an important step toward successful outcomes.

## Author details

Sylvio Luiz Costa de Moraes<sup>1,2,9,10\*</sup>, Alexandre Maurity de Paula Afonso<sup>1,3,10</sup>,  
Bruno Gomes Duarte<sup>4,10</sup>, Maiolino Thomaz Fonseca Oliveira<sup>5,10,12</sup>, Darceny Zanetta-Barbosa<sup>5,10</sup>,  
Gabriel Pires Pastore<sup>7,9,10,11</sup>, Luciano Mauro Del Santo<sup>6,7,10</sup> and  
Daniel Falbo Martins de Souza<sup>7,8,10</sup>

\*Address all correspondence to: [sdmoraes@yahoo.com.br](mailto:sdmoraes@yahoo.com.br)

1 Clinic for Cranio-Maxillofacial & Reconstructive Surgery, São Francisco Hospital & RECONFACE, Facial Reconstruction Center, Rio de Janeiro (RJ), Brazil

2 Antonio Pedro University Hospital (HUAP), Universidade Federal Fluminense, UFF, Niterói, Rio de Janeiro (RJ), Brazil

3 Oral and Maxillofacial Surgery in Hospital Federal de Bonsucesso, Rio de Janeiro (RJ), Brazil

4 Private Practice Oral and Maxillofacial Surgeon, Bauru (SP), Brazil

5 Universidade Federal de Uberlândia, UFU (MG), Brazil

6 Oral and Maxillofacial Surgery at Universidade Paulista, UNIP (SP), Brazil

7 Oral and Maxillofacial Surgery and Traumatology Service at Hospital Alemão Oswaldo Cruz (SP), Brazil

8 Oral and Maxillofacial Surgery and Traumatology Service at Conjunto Hospitalar do Mandaguí (SP), Brazil

9 AO Foundation, International Faculty, Switzerland / AOCMF Brazil

10 Brazilian College of Oral and Maxillofacial Surgery, Brazil

11 Oral and Maxillofacial Surgery at Universidade Paulista, UNIP (SP), Brazil

12 Hospital de Urgências Governador Otávio Lage, HUGOL (GO), Brazil

## References

- [1] Holmes S. Facial trauma: Who should provide care? *Br J Oral Maxillofac Surg.* 2009; 47: 179–181.
- [2] Krishnan DG. Systematic assessment of the patient with facial trauma. *Oral Maxillofacial Surg Clin N Am.* 2013; 25: 537–544.
- [3] Supit L, Prasetyono TO. A portable mirror stands for clinical facial photo documentation. *Arch Plast Surg.* 2015; 42: 356–360.
- [4] Moraes SLC, Afonso AMP, Oliveira AM, Oliveira AA, Santos RG. Cranio-Maxillofacial Trauma. In: Vinhães, JC, editor. *Clinical and Surgical Therapeutics.* p. 391–428. 2nd ed. Rio de Janeiro: Guanabara Koogan, 2003; 1813p.
- [5] Perry M, Dancey A, Mireskandari K, Oakley P, Davies S, Cameron M. Emergency care in facial trauma – A maxillofacial and ophthalmic perspective. *Injury.* 2005; 36: 875–896.
- [6] Perry M, Moutray T. Advanced Trauma Life Support (ATLS) and facial trauma: Can one size fit all? Part 4: “Can the patient see?” Timely diagnosis, dilemmas and pitfalls in the multiply injured, poorly responsive/unresponsive patient. *Int J Oral Maxillofac Surg.* 2008; 37: 505–514.
- [7] Ashar A, Kovacs A, Khan S, Hakim J. Blindness associated with midfacial fractures. *J Oral Maxillofac Surg.* 1998; 56: 1146–1150.
- [8] Hammer, B. *Orbital Fractures: Diagnosis, Operative Treatment, Secondary Corrections.* Seattle: 1st ed. Ed. Seattle: Hogrefe & Huber Publishers, 1995. 100p.
- [9] Herford AS, Ghali GE. Damage to soft tissue. In: Miloro M, Ghali GE, Larsen PE, Waite PW, editors. *Principles of Oral and Maxillofacial Surgery,* Peterson. p. 357–370. 1st ed. São Paulo: Editora Santos, 2008; 766p.
- [10] Zimmerman RA, Gusnard DA, Bilaniuk LT. Pediatric craniocervical spiral CT. *Neuroradiol.* 1992; 34: 112–116.
- [11] He D, Zhang Y, Ellis E. Panfacial fractures: analysis of 33 cases treated late. *J Oral Maxillofac Surg.* 2007; 65: 2459–2465.
- [12] Curtis W, Horswell BB. Fractures an approach to management. *J Oral Maxillofacial Surg Clin N Am.* 2013; 25: 649–660.
- [13] Louis PJ. Treatment of panfaciais fractures. In: Miloro M, Ghali GE, Larsen PE, Waite PW, editors. *Princípios de Cirurgia Buco Maxilo Facial de Peterson.* p. 547–559. 1st ed. São Paulo: Editora Santos, 2008; 766p.

- [14] Follmar KE, Baccarani A, Das RR, Erdmann D, Marcu JR, Mukundan S. A clinically applicable reporting system for the diagnosis of facial fractures. *Int J Oral Maxillofac Surg.* 2007; 36: 593–600.
- [15] Sugar A., Bentley R. Principles of stabilization: splinting, adaptation, compression, lag screw principle In: Ehrenfeld, M., Manson, PN, Prein, J. *Principles of Internal Fixation of the Cranio-facial Skeleton: Trauma and Orthognathic Surgery.* p. 95–101. New York: Ed. Georg Thieme Verlag, 2012; 395p.
- [16] Erdmann D, Marcus JR. Panfacial Fractures. In: Marcus JR, Erdmann D, Rodriguez ED, editors. *Essentials of Craniomaxillofacial Trauma.* p. 301–311. 2nd ed. St. Louis: Ed. Quality Medical Publishing, 2012; 333p.
- [17] Christensen J, Sawatari Y, Peleg M. High-energy traumatic maxillofacial injury. *J Craniofac Surg.* 2015; 26(5):1487–1491.
- [18] Tessier, P. Total osteotomy of the middle third of the face for facial stenosis or for sequelae of the Le Fort III fractures; *Plast Reconstr Surg.* 1971; 48: 533.
- [19] Moraes SLC, Oliveira AM, Afonso AMP, Oliveira AA, Santos RG. Three-dimensional reconstruction of the face in cranio-maxillofacial complex trauma. In: *Annals of the XVI Brazilian Conference on Oral and Maxillofacial Surgery and Traumatology*; 2001; Rio de Janeiro. São Paulo: Brazilian College of Oral and Maxillofacial Surgery. 2001; p. 44–45.
- [20] Manson PN, Clark N, Robertson B. Comprehensive management of pan-facial fractures. *J Craniomaxillofac Trauma.* 1995; 01: 43–56.
- [21] Ellis III E, Zide MF. *Surgical Approaches to the Facial Skeleton.* Baltimore: Ed. Williams & Wilkins. 1995; 223p.
- [22] Manganello-Souza LC, Tenorio-Cabezas N. Plates and miniplates system of skeleton fixation. In: Manganello-Souza LC, Cerqueira Luz JGC, editors. *Surgical treatment in Oral and Maxillofacial Trauma.* p. 303–310. 3a ed. São Paulo: Roca, 2006; 340p.
- [23] Jarrahy R, Vo V, Goenjian HA, Tabit CJ, Katchikian HV, Kumar A et al. Diagnostic accuracy of maxillofacial trauma two-dimensional and three-dimensional computed tomographic scans: comparison of oral surgeons, plastic surgeon, and neurologists. *Plast Reconstr Surg.* 2011; 127: 2432–2440.
- [24] Markowitz BL, Manson PN. Panfacial fractures: organization of treatment. *Clin Plast Surg.* 1989; 16: 105–114.
- [25] Manson PN, Clark N, Robertson B, Slezak S, Wheatly M, Vander Kolk C, et al. Subunit principles in midface fractures: the importance of sagittal buttresses, soft-tissue reductions, and sequencing treatment of segmental fractures. *Plast Reconstr Surg.* 1999; 103: 1287–1306.



- [26] Gruss JS, Bubak PJ, Egbert MA. Craniofacial fractures: an algorithm to optimize results. *Clin Plast Surg* 1992; 19: 195–206.
- [27] Manson PN. Panfacial fractures. In: Ehrenfeld, M, Manson, PN, Prein, J, editors. *Principles of Internal Fixation of the Cranio-Facial Skeleton: Trauma and Orthognathic Surgery*. p. 293–305. New York: Ed. Georg Thieme Verlag; 2012; 395p.
- [28] Frtitz MA, Koltai PJ, Sequencing and organization of the repair of panfacial fractures. *Op Tech Otolaryngol Head Neck Surg*. 2002; 13: 261–264.
- [29] Manson PN, Stanwix MG, Yaremchuk MJ, Nam AJ, Hui-Chou Hm Rodriguez ED. Frontobasal fractures: anatomical classification and clinical significance. *Plast Reconstr Surg*. 2009; 06: 2096–2106.
- [30] Zelken JA, Khalifian S, Mundinger GS, Ha JS, Manson PN, Rodriguez ED, et al. Defining predictable patterns of craniomaxillofacial injury in the elderly: analysis of 1047 patients. *J Oral Maxillofac Surg*. 2014; 02: 352–361.