

We are IntechOpen, the world's leading publisher of Open Access books Built by scientists, for scientists

6,900

Open access books available

186,000

International authors and editors

200M

Downloads

Our authors are among the

154

Countries delivered to

TOP 1%

most cited scientists

12.2%

Contributors from top 500 universities



WEB OF SCIENCE™

Selection of our books indexed in the Book Citation Index
in Web of Science™ Core Collection (BKCI)

Interested in publishing with us?
Contact book.department@intechopen.com

Numbers displayed above are based on latest data collected.
For more information visit www.intechopen.com



Management of the Oroantral Fistula

Guhan Dergin, Yusuf Emes, Cagri Delilbası and
Gokhan Gurler

Additional information is available at the end of the chapter

<http://dx.doi.org/10.5772/63403>

Abstract

Communication between the maxillary sinus and oral cavity is a common complication in oral surgery. It results mainly from maxillary premolar and molar extractions when the sinus floor is close to the tooth apex. It can also occur after an infection involving the maxillary teeth, invasion of the sinus cavity by a cyst or carcinoma, trauma, the Caldwell-Luc operation, or other dentoalveolar or implant procedures. Openings smaller than 2 mm may heal spontaneously, whereas larger openings require surgical treatment. An oroantral fistula (OAF) may develop as a complication of dental extractions, as a result of infection, or as sequelae of radiation therapy, trauma, and removal of maxillary cysts or tumors. Various techniques have been examined for the closure of oroantral communications. However, the most common question is how to provide better healing of the defect area and the donor site. In this chapter, etiology, clinical features, medical and surgical managements of OAFs, and advantages and disadvantages of different closure methods of closure techniques are discussed in this chapter.

Keywords: oroantral fistulas, maxillary sinus, flaps, oral surgery, oral cavity

1. Introduction

An abnormal connection between the oral and antral cavities is defined as an oroantral communication (OAC). OAC between the maxillary sinus and oral cavity is a common complication in oral surgery, resulting mainly from premolar and molar extractions when the sinus floor is close to the tooth apex and separated by a thin bony lamella [1–3]. In physiologic circumstances, maxillary sinus mucosa thickness ranges from 1 to 7 mm [4, 5] but in some cases, when the bony floor of the antrum is resorbed by periapical infections or cysts the risk of an

OAC increases. It can also occur after an invasion of the sinus cavity by cysts and tumors, maxillofacial surgical procedures such as indirect or direct sinus lifts, dentoalveolar-grafting operations or corrective surgery such as orthognathic surgeries. OACs can also occur due to trauma [1, 3]. Epithelialization of a communication between the oral cavity and the maxillary sinus forms a pathologic tract, which is called an oroantral fistula (OAF). Various techniques have been described for the closure of OAFs. However, the question is how to provide better healing of the defect area and the donor site. In this chapter, etiology, clinical features, and medical and surgical management methods of OAFs are discussed.

2. Etiology

The most common cause of the OACs is the extraction of the posterior teeth, which have their roots in close relationship to the maxillary sinus. Even though earlier studies have pointed to the second premolars as the highest risk of OAC during extraction [6], later studies have reported that the molar teeth have their roots in the closest proximity to the sinus floor [7–10]; Güven [11] has stated that in his study, second molar extraction followed by first molar had the highest risk. OACs as a result of tooth extraction are the most common in the third decade of life and encountered mostly in adults with few posterior teeth, in which the maxillary sinuses are enlarged. Due to their underdeveloped small maxillary sinuses, the risk of OAC during extraction is very low in children. General consensus is that the OACs must be closed within 24–48 h to prevent fistula and sinusitis [12, 13].

Infections, cyst-, and tumor-removal operations performed in the posterior maxilla and trauma can also lead to the formation of an OAC. OACs can be encountered following a sinus augmentation procedure due to infection of graft material or an improper incision during the operation. Nedir et al. [14] reported the formation of an OAC after the failure of a dental implant in the second molar region. The implant, which was placed 10 years after a sinus-lift procedure and the loss of osseointegration, led to the removal of the implant, causing an OAC. Maxillary osteonecrosis due to the use of bisphosphonates can cause sinusitis and OAF, and when indicated in these patients, the removal of the necrotic bone may cause an OAC [15].

3. Clinical findings and diagnosis

Air and fluids passing into the nose and mouth are the main clinical findings following the formation of an OAC. The clinician may see blood bubbles in the defect or the patient may sense the leakage of air when blowing while nostrils are closed. Usually, patients complain of an unpleasant salty discharge into the mouth from the opening, odor, and reflux of fluids and foods into the nose from the mouth or leakage of air, which sometimes makes it difficult to smoke. Patients may also experience resonance of their sound and speech problems if the defect is large. Suctioning of the socket may create a hollow sound that shows communication. Sinus membrane can be sometimes intact. Therefore, great attention should be paid during the exploration of the perforation with probing or suctioning methods that may lacerate the sinus membrane, which may sometimes be intact [16, 17].

The presence of one or more of these mentioned symptoms could be the indicator of an OAC or a fistula, while some patients may not show any of these findings if the passage is too small or closed by a large polyp. To validate clinical findings, the clinician needs to radiologically examine the site via a panoramic radiograph or a computed tomography (CT). Dental tomography gives clear data about the perforation and its size if the defect is closed by a polyposis or a granulation tissue [18].

4. Management of OACs/fistula

As almost all of posterior teeth have the risk of OAC, the clinician must evaluate the patient thoroughly prior to extraction. The relationship between the maxillary teeth apices and the maxillary sinus, cortical thickness of the sinus floor, apical granulomas, and cysts, which may have caused the sinus floor resorption, should be evaluated radiographically. After the extraction, it is safer if wound edges are well approximated and stabilized with sutures if the surgeon suspects a small perforation. Larger perforations may be closed with local flaps [1, 19, 20].

An accidental small perforation during a dentoalveolar surgical intervention, such as drilling in implant surgery, apicoectomy of maxillary teeth, and excision of cysts and tumors, can be repaired intraoperatively if the sinus is not infected. The surgeon should be careful not to close the defect with the excessive tension of the tissues, which may enhance the risk of postoperative wound dehiscence [21].

The main goal of the clinician in the management of OAC/fistula is the closure of the defect and prevention of oral bacteria and food debris penetrating the sinus. These oral contaminants may infect the sinus or induce inflammation, which may cause impaired ciliary function, problems of sinus areolation, congestion, and sinusitis. But before the closure of OAF, symptoms associated with inflammation in the sinus such as persisting pus discharge from OAF, malodor, nasal congestion and discharge, and postnasal drip should be eliminated medically with antibiotics, frequent antral irrigations, and decongestants. Patients should be carefully monitored and should be assessed often if the OAC or fistula has any acute sinusitis symptoms. Regardless of the chosen technique, two main points should be taken into account. First, sinus infection must be treated with adequate nasal drainage. This can be obtained by Caldwell-Luc procedure with nasal gastrostomy or endoscopic sinus surgery. Second is decreasing congestion by nasal decongestant and sterile saline water to obtain natural drainage and areolation from ostium. Avoid using long-term topical nasal decongestants that may cause rebound nasal congestion [16, 22].

5. Surgical management of OAFs

The preference of the technique to close an OAC depends on the size of the defect (which is sometimes difficult to estimate clinically), the health of the surrounding tissues, the health of

the maxillary sinus, and the time of diagnosis. Also, postoperative prosthetic planning (e.g., dental-implant planning) should be taken into consideration [19, 23].

Success of the closure of an OAC, or an OAF, is closely related to the health of the involved maxillary sinus. If the drainage of the antrum via mucociliary transportation is impaired and osteomeatal complex is obstructed, a combined approach to the OAC may be necessary [23]. Even though an open approach to the maxillary sinus was used for a long time (Caldwell-Luc operation), functional endoscopic sinus surgery in combination with an intraoral closure technique is currently the treatment of choice in these patients [10, 21, 24].

The closure of the OAFs rarely requires a bony reconstruction except in patients with cleft repair or implant rehabilitation. When intraoral donor sites are insufficient, extraoral sites such as calvarial or anterior iliac crest may be used. Various authors previously described a variety of techniques for the closure of OACs. Agarwal [24] et al. have proposed the suturing of platelet-rich fibrin rolls to the communication site even though they did not mention their indication criteria for this technique. Noel et al. [17] used a pedicle nasoseptal flap in a patient who had previously undergone radiotherapy. The patient they described had an opening of 10 mm, which was closed successfully. The use of allogeneic materials or xenograft or alloplastic materials and the placement of a third molar tooth or a dental implant into the defect have all been proposed for the treatment of OACs. But all these methods are rarely used in the literature and are replaced with soft-tissue management techniques [16].

Several surgical techniques for OAF closure have been introduced in the literature. Buccal and palatal flaps are commonly used methods, while the other local flaps are mostly variations of the two techniques. Distant flaps such as the buccal pedicle fat pad, tongue, and temporal muscle flaps are also used techniques to close OAF. The size and localization of the defect, the presence of acute or chronic infection in the sinus, and the absence of sufficient vestibular depth or keratinized tissue surrounding the defect are all determinately important factors for the preference of surgical technique to close the defect. Additionally, during planning of the flap design, the surgeon should take into account whether it is immediate or delayed, whether there is thick and healthy tissue surrounding the defect, and whether the patient is healthy or medically compromised [16].

5.1. Buccal approach

5.1.1. Buccal advancement flaps

Buccal advancement flaps are among the most commonly used techniques for the OAC closure. This is due to the simplicity of the technique. Even though the literature states that OACs can heal spontaneously when the defect size is smaller than 1–2 mm, this may not be true in every small defect. [8, 11, 25, 26]. Some studies have even reported the spontaneous healing of OACs up to 5 mm size [8]. When there is infection in the communication site and the communication remains open for an extended period of time, this may lead to the formation of an OAF. Due to these facts, most surgeons may prefer buccal advancement flaps as the first treatment of choice even in small communications where closure may be possible by simple suturing [27].

Rehrman's flap and Môczár flap are the two most commonly used buccal advancement flaps. These two flaps may also have disadvantages when compared to simple suturing, because the reflection of a mucoperiosteal flap may result in swelling, and also requires the dentist to have proper training to perform this operation. Another disadvantage of the buccal advancement flap is the risk of losing the depth of the vestibular sulcus, even though the Môczár flap results in less vestibular sulcus flattening according to Vowern [8].

There are flapless closure methods which are simply the placement of resorbable materials into the socket such as oxidized cellulose [28]. These materials maintain a closure by stabilizing the blood clot in the socket. It must be kept in mind that there are currently no generally accepted guidelines to choose the method of closure. This is the reason why these flapless techniques are very commonly used by general practitioners due to their simplicity, which do not require extensive surgical skill. Even though some studies show these simple methods are as effective in obtaining closure as the buccal advancement flap, these studies are not always considered reproducible in terms of the method of analysis of the complications [27, 28]. It is generally not possible to know the exact size of the opening in the sinus floor without reflecting the flap. Therefore, dentists must be careful when deciding to use the flapless techniques and must keep in mind that the defect may be larger than they think it is. A plain radiograph (periapical film or orthopantomograph) can give an idea about the defect size. When an OAC occurs, success rate is very high when immediate closure is obtained. This rate drops significantly when the closure is performed secondarily [1, 29]. Infected tissues, apical cysts, and foreign bodies must be removed from the socket in case they may prevent healing [1, 11, 26].

To perform the buccal flap, two vertical diverging incisions are made at the mesial and distal ends of the socket. The incisions must extend beyond the defect and must lie on healthy bone. After elevation of the mucoperiosteal flap, the gingival edges of the socket are de-epithelialized by a sharp instrument. Then, the flap is positioned palatally and primary closure is obtained by multiple sutures. An apical periosteal release of the flap can sometimes be necessary. Following surgery, an antibiotic should be prescribed. Surgeons may sometimes prescribe postoperative nasal decongestants. When a fistula with sinus infection is present, the infection must be treated first. Some authors recommend daily irrigation of the perforated antrum by antibiotic solutions prior to surgery [30].

Falci et al. [30] have described a modification of this technique in a patient with OAF. They have sutured together the mucosal margins of the fistula prior to the reflection of the buccal flap. Then, the buccal flap was pulled over this sutured site and tucked under the palatal flap, which was elevated simultaneously with the buccal flap.

The main disadvantage of this simple and safe technique is the weak perfusion of the flap, which may lead to failure in the closure of large defects. Yalçın et al. [12] recommend this technique be used for smaller defects. As mentioned earlier, this technique may lead to a flattening of the vestibular sulcus, and in edentulous patients, a secondary vestibuloplasty may be required. In edentulous patients, a palatal flap technique can be preferred especially if the alveolar ridge is severely atrophied. In their study of 23 cases, Yaçın et al. have performed the buccal flap in 10 patients, and a loss of vestibular depth was observed only in 2 patients at the end of 6 months.

Buccal advancement flaps can be safely preferred in dentate patients with no alveolar resorption and a bony defect of less than 5 mm size in the sinus floor for the immediate closure of the OAC. Buccal flaps can be used in edentulous patient also if the fistula is on the buccal side of the alveolar crest [12]. Despite an initial successful closure, both the patient and the surgeon must be aware that there is always a risk of a recurring OAF formation [21]. Neuschl et al. [31] have reported a very rare complication, in which the duct of the parotid gland was iatrogenically sutured into the maxillary sinus during the closure of an OAC using a buccal flap.

5.1.1.1. Technique

After the fistula tract is excised, the trapezoidal buccal mucoperiosteal flap is reflected and the lateral wall of the maxilla exposed. Horizontal releasing incisions are made at the most apical part of the flap, which helps to move and extend the flap to the defect without tension. After flap release, it can be advanced upon the defect and sutured to palatal tissue (**Figure 1a–c**).

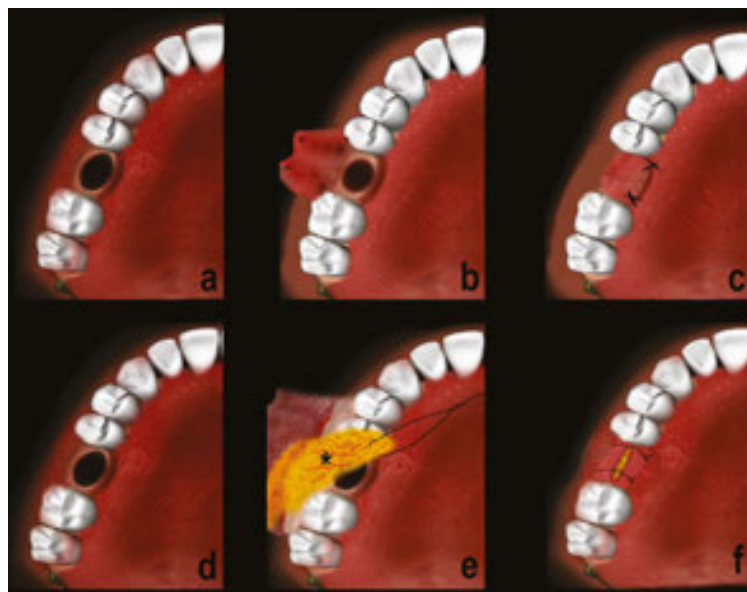


Figure 1. Illustration of buccal flaps: (a–c) Buccal advancement flap technique, (d–e) buccal fat-pad flap.

5.1.2. Buccal fat-pad flap

Another common buccal approach to OACs is the use of the buccal fat pad (BFP). The use of the BFP for the treatment of OAFs was first simply an alternative to the closure of small- and medium-sized defects; however, nowadays it is also used for large bony defects. The technique was first described by Egyedi in the late 1970s [32], and its use became more common following a study by Tideman et al. [33], which showed that the BFP epithelialized within 3–4 weeks. The technique is used not only in the treatment of OAFs but also in the reconstruction of medium-sized maxillary defects (as in tumor excisions) [34–36]. The buccal fat-pad flap has 10 ml of fat tissue. The fat pad is approachable through the oral cavity, and the buccal and temporal branches of the maxillary artery, facial artery, and superficial temporal artery perfuse

it sufficiently, which make it a good choice as a material to close medium-sized defects of the maxilla [37].

The incision is similar to the buccal flap technique. In order to expose the BFP, the periosteum is incised behind the zygomatic buttress. The fat pad is manipulated by pressing extraorally below the zygomatic arc. Then, the fat pad is sutured to the palatal tissues, covering the fistula.

The success of the technique has been reported by many authors. Mohan et al. used the technique in 11 patients for various pathologies including pleomorphic adenoma excision, and observed partial loss of the graft only in one patient and hematoma in another patient [38]. Martin-Granizo et al. [39] have reported the successful application of the technique in their patients, even in those who have had partial necrosis of the flap. Nezafati et al. [40] performed a study comparing the buccal flap and buccal fat-pad flap techniques, and concluded that both were similarly successful. Infection of fat tissue is the main problem of this technique.

5.1.2.1. Technique

A circular incision with a 3-mm margin is made around the defect (**Figure 2**), the epithelial tract with any inflammatory tissue was completely excised, and two vertical incisions extended into the vestibule are made.

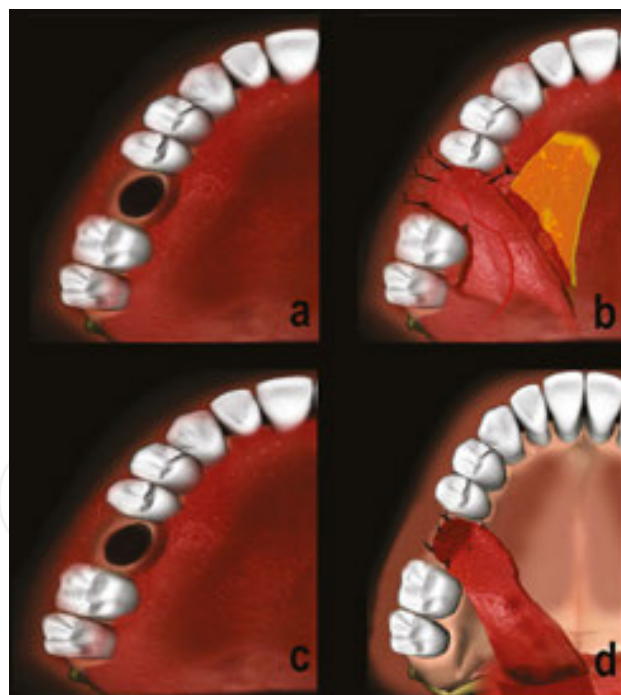


Figure 2. (a—c) Illustration of full-thickness rotational flap, (b—d) tongue flap technique for closure of large oroantral defects.

The trapezoidal buccal mucoperiosteal flap is reflected and the lateral wall of the maxilla is exposed. Buccal fat is exposed with a vertical incision through the periosteum posterior to the zygomatic buttress. Applying external pressure below the zygomatic arch helps herniation of

the BFP. Following gentle extraction, the BFP is released with meticulous dissection via scissors. After gaining sufficient length, the flap is advanced to the oral defect from behind the molar teeth and was fixed on the fistula by absorbable polydioxanone sutures over the fat pad, which was gently advanced over the bone defect (**Figure 3**), and secured with sutures (**Figure 4**). Finally, the mucoperiosteal flap is replaced in its original position with sutures inserted between the BFP and the buccal flap. The fat is left exposed in the mouth without any coverage (**Figure 1d–f**).

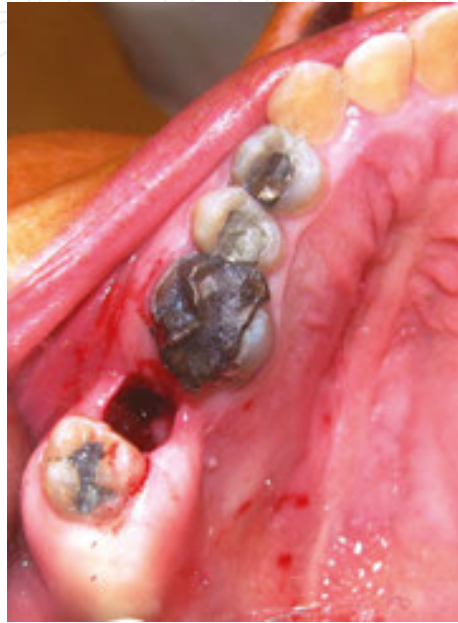

Figure 3. Excised fistula wall at the right maxillary molar region.

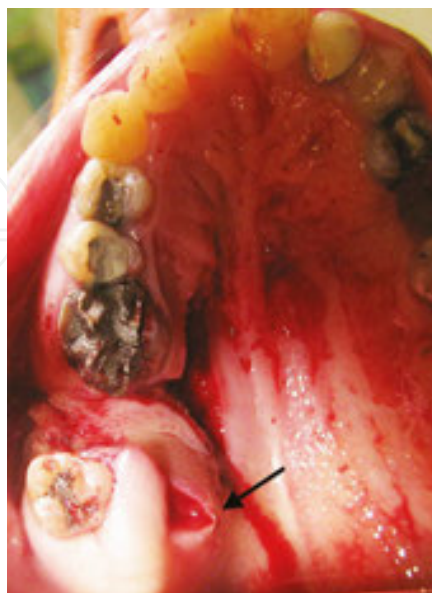

Figure 4. Dog-ear formation at full-thickness rotational flap at rotating point (marked with arrow).

5.1.3. Palatal flaps

The palatal flap has different forms that can be classified as straight-advancement, rotation-advancement, hinged, pedicle island, anteriorly based, submucosal connective tissue pedicle, and submucosal island flaps [1, 10].

5.1.4. Full-thickness palatal flap

Full-thickness rotational palatal flaps have the advantages of keratinized tissue, preservation of vestibular depth, and sufficient blood supply for better healing. However, the thick keratinized tissue limits rotation if the OAF is located at the maxillary tuberosity [1, 41]. With full-thickness palatal rotational flaps, at the pivot point, kinking or “dog-ear” formation can occur during flap rotation, which may compromise the vascular supply, predispose the patient to venous congestion, and impair the adaptation of the distal part of the flap. Kruger suggested that a V-shaped section be excised in the area of the greatest bend in the flap to prevent folding and wrinkling [3]. With full-thickness palatal rotational flaps, the technique exposes the bony structure of the hard palate and sometimes is required for re-epithelialization, causing severe complaints such as pain, burning, and edema of the hard palate.¹³ There is also a risk of necrosis of the exposed bone at the donor site, especially in systemically compromised patients. Erdogan et al. [42] reported unexpected palatal bone necrosis in diabetics after the use of full-thickness palatal rotational flaps. Using a palatal stent is recommended after palatal rotational flap operations to reduce the edema and to stabilize the flap in its new position [43].

5.1.4.1. Technique

In the full-thickness mucoperiosteal palatal rotational flap technique, the flap design is arranged according to the greater palatine artery. About 1-cm length of additional flap is created to achieve tension-free closure of the fistula on the buccal bony base. Bone defect and

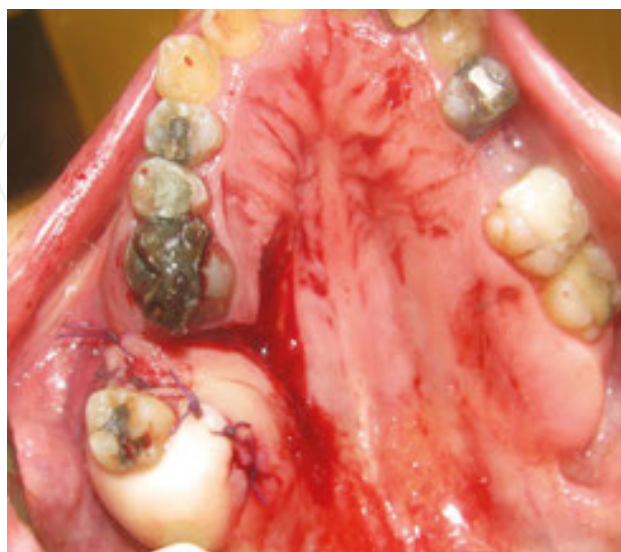

Figure 5. Dog ear was removed and adapted to defect and closed with full-thickness rotational flap.

angle of rotation are the key points in determining the width of the flap. Kinking formation at the rotation point of the flap should be evaluated; if dog-ear formation exists, it should be excised to obtain a better adaptation (**Figures 2 a–c and 3–6**).

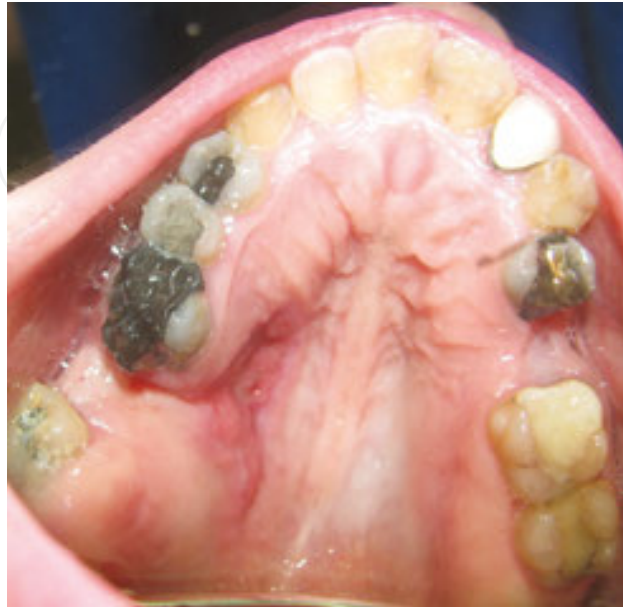

Figure 6. Healing of the fistula. After closing with FTPF (full-thickness palatal flap).

5.1.5. *Modified submucosal connective tissue flap*

Dergin et al. [44] reported a modified submucosal connective tissue flap for OAF repair. With a modified connective tissue flap, there is no folding or dog-ear formation because of its elasticity and it allows for better manipulation and adaptation in the closure of an OAF in the second and third molar region. In modified connective tissue flap techniques, all of the donor sites were closed with mucosal flaps that covered the underlying bone. In the modified connective tissue flap, no palatal acrylic plate is required postoperatively.

Ito and Hara [45] modified the pedicle palatal flap by developing a submucosal connective tissue pedicle flap, and reported that dividing the flap into an upper mucosal layer and underlying connective tissue layer overcomes the problem of bone exposure at the donor site. Healing at the donor site occurs within 1 month. The technique owes its success to the good blood supply and mobility without tension [46]. The only disadvantages of this technique are the difficulty of the dissection, possibility of injuring the blood supply, and the need for an experienced surgeon [45, 46].

The connective tissue-based pedicle palatal flap technique described by Dergin et al. [44] differs from the technique of Ito and Hara [45] in the design of the mucosal flaps and the preparation of the submucosal tunnel. Preparing a long, narrow mucosal flap carries a risk of necrosis and infection of the overlying mucosal flap at the donor site.

5.1.5.1. Technique

In the modified palatal connective tissue flap technique (**Figure 7a**), an H-type window-like incision was made in the palatal mucosa 4 mm from the gingival margins of the molar and premolar teeth, with the medial incision 2–3 mm from the midline. The fistula wall is excised circumferentially and the granulation tissue is curetted (**Figure 8**).

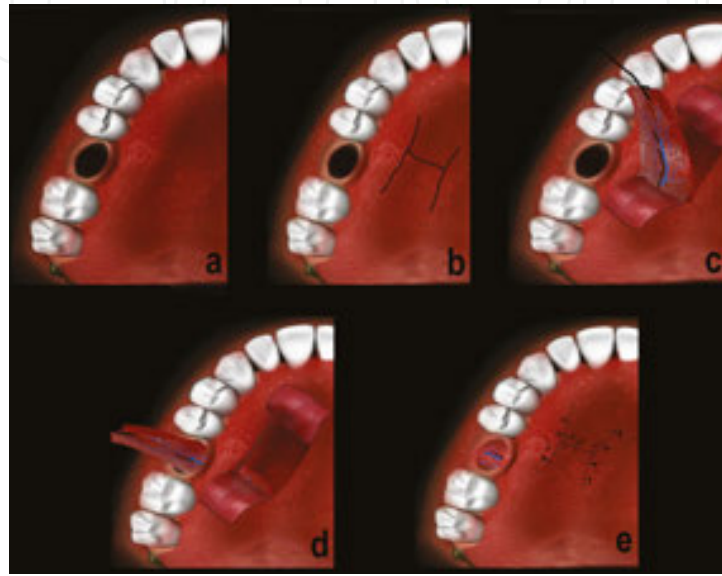


Figure 7. Illustration of the modified connective tissue technique a: excised fistulas wall, b: H incision, c: arterial palatal connective tissue window-like flaps and dissection of arterial connective flap, d: palatal tunnel maneuver, e: suturing.

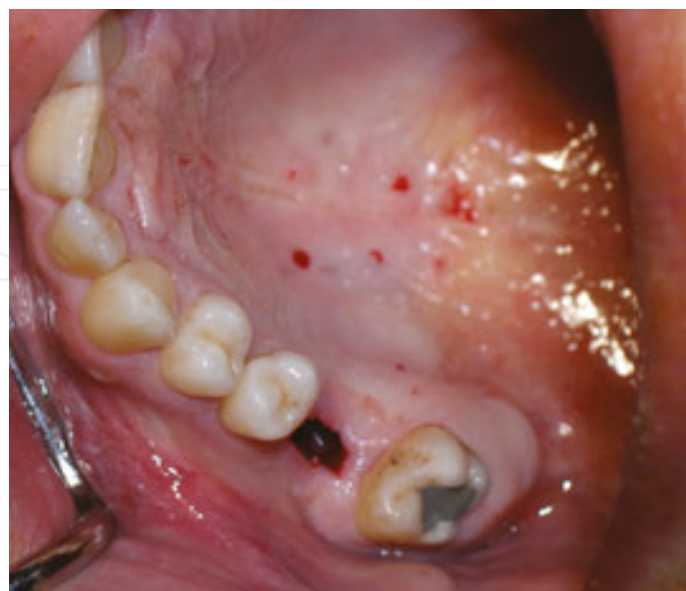

Figure 8. Oroantral fistula with excised fistula wall.

After excising the fistula, the mucosa of the two minor flaps of the H-type window-like incision (**Figures 7b** and **10**) was elevated and separated from the underlying connective tissue without jeopardizing the continuity of the mucosal flap (**Figure 9**).

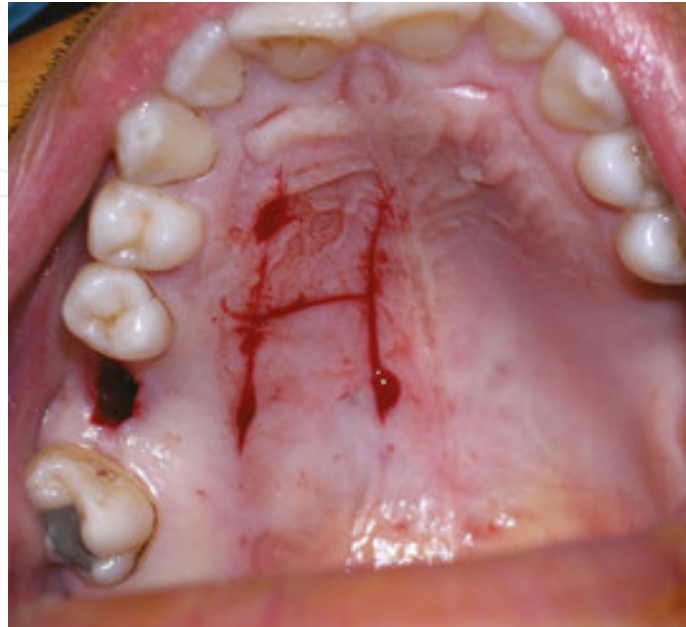

Figure 9. Intraoperative view of H-type incision.

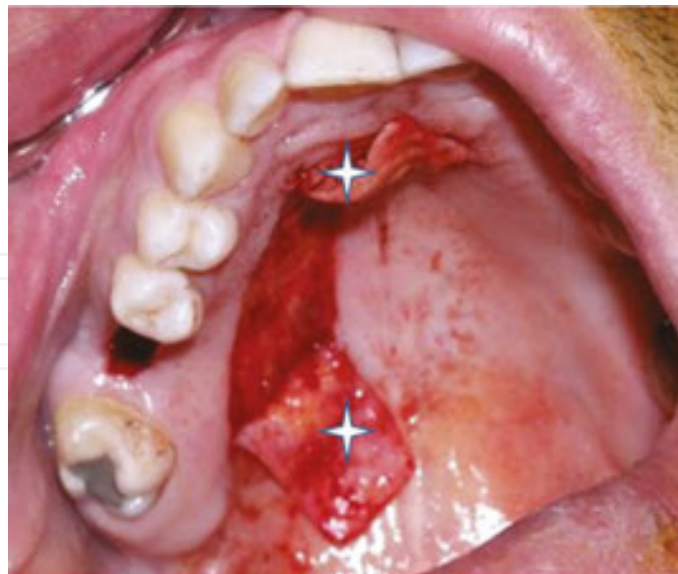


Figure 10. Elevated window-like mucosal H flap (marked with stars).

The underlying arterialized connective tissue was first dissected in the premolar-canine region, where the incisive and greater palatine arteries anastomose (**Figures 7c** and **11**).

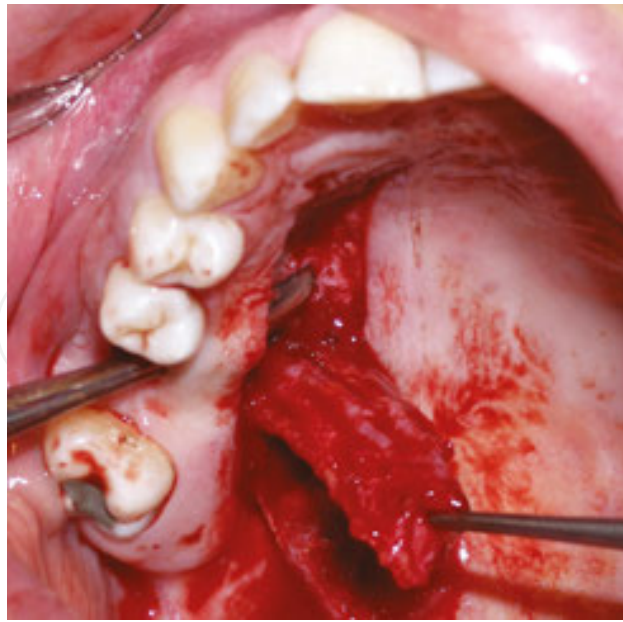


Figure 11. Intraoperative view of the elevated palatal connective tissue flap.

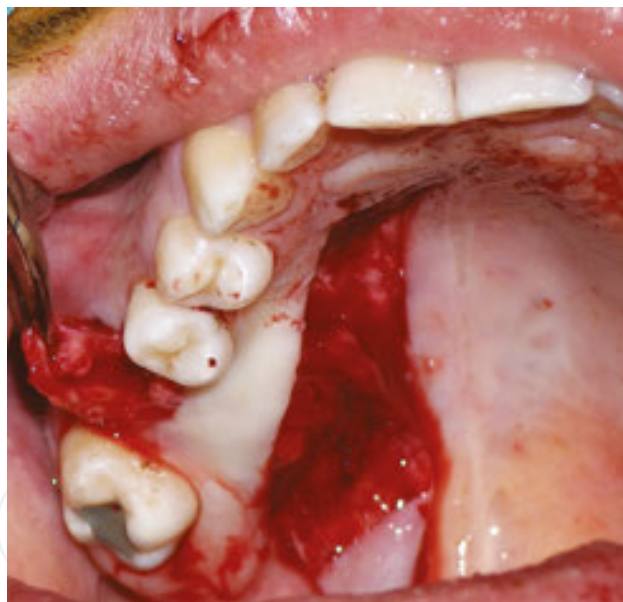

Figure 12. Orientation of the flap passing through the palatal tunnel to the underlying fistula during the operation.

The connective tissue was elevated with periosteum, as in palatal rotational flaps. The rotated flap was passed through a full-thickness tissue tunnel that was previously prepared on the palatal side of the OAF (**Figures 7d** and **12**).

The flap was inserted under the buccal mucosa and sutured with 4/0 polyglycan without any tension. The H-type minor flaps were sutured with 4/0 polyglycan and left for primary healing (**Figures 7e**, **13**, and **14**).

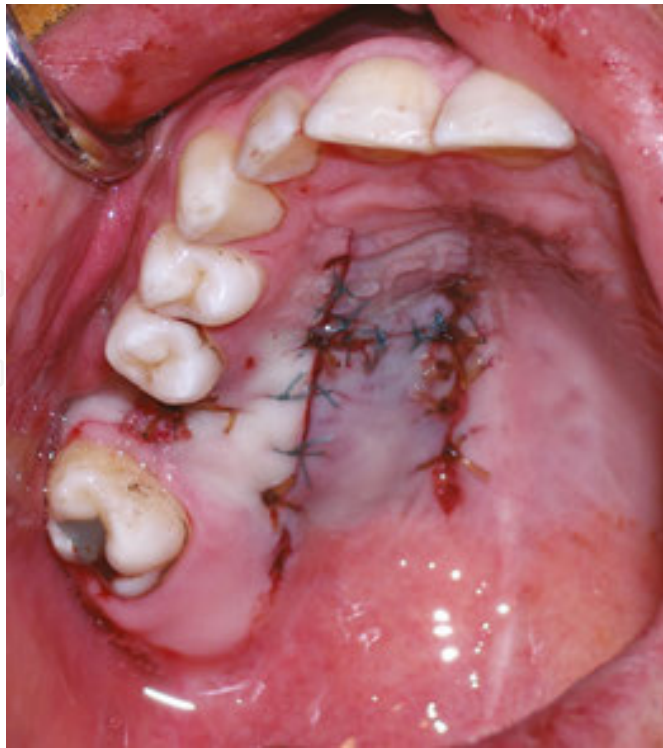


Figure 13. After the minor mucosal flaps were sutured, no area was left for secondary healing.

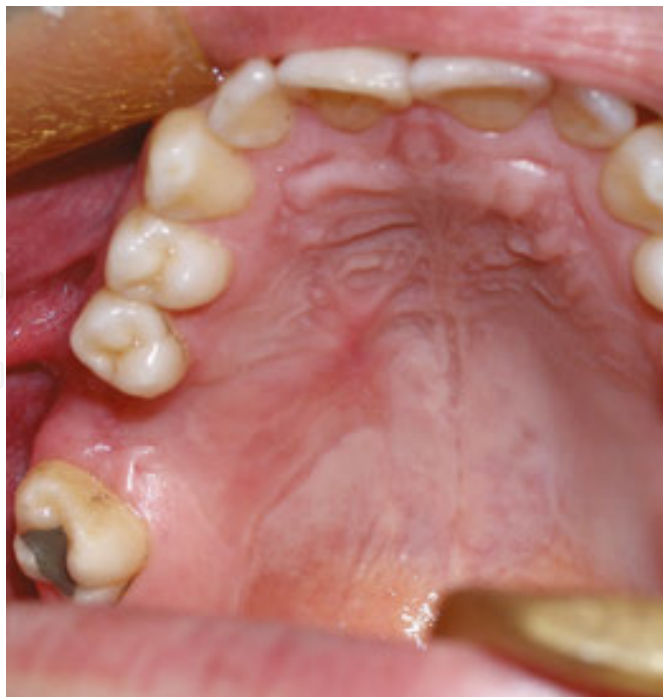

Figure 14. Healing of the fistula. After closing with MPCF (modified palatal connective tissue flap).

5.1.6. Distant flaps

Local flaps are the treatment of choice in most cases of OACs. However, sometimes these flaps may fail, and pedicle flaps from distant sites may be utilized in order to treat especially large defects. These flaps are usually selected from the anatomical sites in close proximity to the defect. Lateral tongue flap has been described as a method for the closure of OAF [47]. Lateral tongue flaps are used for the treatment of defects in the lateral palate and lateral alveolar process, and on the postoperative 14th day, the pedicle is severed [48] (**Figure 2c and d**).

The use of the temporalis flap has been described previously for intraoral reconstruction [49–51] and can be used for the reconstruction of large defects of the maxilla, especially following ablative tumor surgery. It is a well-vascularized flap with enough volume for the closure of large defects. The large bulk of this flap can also provide a soft-tissue bed if further bony reconstruction is planned for the defect site in the future. Distant flaps are preferred rarely, compared to local flaps [52].

6. Conclusion

OACs can be successfully treated if diagnosed at the time of occurrence or at an early stage. The size of the defect is an important factor in deciding which technique to use. Small openings can heal spontaneously, but the health of the sinus is an important factor which may lead to an incomplete healing and the formation of an OAF.

The clinician must make the correct diagnosis and decide the correct indication for treatment.

Local buccal and palatal flaps are the most proper for the closure of OACs resulting from dental procedures. However, large defects following tumor resection or trauma may require the use of more refined techniques for successful healing.

Author details

Guhan Dergin^{1*}, Yusuf Emes², Cagri Delilbasi³ and Gokhan Gurler³

*Address all correspondence to: guhandergin@yahoo.com

1 Dentistry Faculty, Department of Oral and Maxillofacial Surgery, Marmara University, Istanbul, Turkey

2 Dentistry Faculty, Department of Oral and Maxillofacial Surgery, Istanbul University, Istanbul, Turkey

3 Dentistry Faculty, Department of Oral and Maxillofacial Surgery, Medipol University, Istanbul, Turkey

References

- [1] Anavi Y, Gal G, Sifen R, Calderon S, Tikva Petah *et al.* Palatal rotation-advancement flap for delayed repair of oroantral fistula: a retrospective evaluation of 63 cases. *Oral Surg Oral Med Oral Pathol Oral Radiol Endod.* 2003 Nov;96(5):527–34.
- [2] Lee JJ, Kok SH, Chang HH, Yang PJ, Hahn LJ. Repair of oroantral communications in the third molar region by random palatal flap. *Int J Oral Maxillofac Surg.* 2002 Dec; 31(6):677–80.
- [3] Kruger GO, editor. *Textbook of oral and maxillofacial surgery* (6th ed). St Louis: CV Mosby; 1984: p. 291.
- [4] Hanazawa Y, Itoh K, Mabashi T, Sato K. Closure of oroantral communications using a pedicled buccal fat pad graft. *J Oral Maxillofac Surg.* 1995 Jul;53(7):771–5.
- [5] Skoglund LA, Pedersen SS, Holst E. Surgical management of 85 perforations to the maxillary sinus. *Int J Oral Surg.* 1983 Feb;12(1):1–5.
- [6] Mustian WF. The floor of maxillary sinus and its dental, oral and nasal relations. *J Am Dent Assoc.* 1933;20:2175–87.
- [7] Killey HC, Kay LW. An analysis of 250 cases of oroantral fistula treated by the buccal flap operation. *Oral Surg.* 1967 Dec;24(6):726–39.
- [8] Von Wowern N. Closure of oroantral fistula with buccal flap. Rehrmann versus Moczar. *Int J Oral Surg.* 1982 Jun;11(2):156–65.
- [9] Ehrl PA. Oroantral communication. Epicritical study of 175 patients, with special concern to secondary operative closure. *Int J Oral Surg.* 1980 Oct;9(5):351–8.
- [10] Punwutikorn J, Waikakul A, V Pairuchvej V. Clinically significant oroantral communications-a study of incidence and site. *Int J Oral Maxillofac Surg.* 1994 Feb;23(1):19–21.
- [11] Güven O. A clinical study on oroantral fistulae. *J Craniomaxillofac Surg.* 1998 Aug; 26(4):267–71.
- [12] Yalçın S, Oncü B, Emes Y, Atalay B, Aktaş I. Surgical treatment of oroantral fistulas: a clinical study of 23 cases. *J Oral Maxillofac Surg.* 2011 Feb;69(2):333–9.
- [13] Visscher SH, van Minnen B, Bos RR. Closure of oroantral communications: a review of the literature. *J Oral Maxillofac Surg.* 2010 Jun;68(6):1384–91.
- [14] Nedir R, N. Nurdin N, El Hage M, Abi Najm S, Bischof M. Oroantral fistula: a complication of late implant failure. *Clin Oral Implant Res.* 2015; 26(Suppl. 12):408.
- [15] Voss PJ, Vargas Soto G, Schmelzeisen R, Izumi K, Stricker A, Bittermann G, Poxleitner P. Sinusitis and oroantral fistula in patients with bisphosphonate-associated necrosis of the maxilla. *Head Face Med.* 2016 Jan; 6;12(1):3.

- [16] Kuriyama T, Lewis MAO, Williams DW. Infections of the oral and maxillofacial region. In: Andersson L, Kahnberg K, Pogrel MA, editors. Oral and maxillofacial surgery. West Sussex: Blackwell; 2010: pp. 1197–1208.
- [17] Noel J, Teo N, Divi V, Nayak JV. Use of pedicled nasoseptal flap for pathologic oroantral 23 fistula closure. *J Oral Maxillofac Surg*. 2016 Apr;74(4) 704.e1-6.
- [18] Borgonovo AE, Berardinelli FV, Favale M, Maiorana C. Surgical options in oroantral fistula treatment. *Open Dent J*. 2012;6:94–8.
- [19] Awang MN. Closure of oroantral fistula. *Int J Oral Maxillofac Surg*. 1988 Apr;17(2):110–5.
- [20] El Hakim IE, El Fakharany AM. The use of the pedicled buccal fat pad (BFP) and palatal rotating flaps in closure of oroantral communication and palatal defects. *J Laryngol Otol*. 1999 Sep;113(9):834–8.
- [21] Adams T, Taub D, Rosen M. Repair of oroantral communications by use of a combined surgical approach: functional endoscopic surgery and buccal advancement flap/buccal fat pad graft. *J Oral Maxillofac Surg*. 2015 Aug;73(8):1452–6
- [22] Abuabara A, Cortez ALV, Passeri LA, et al. Evaluation of different treatments for oroantral/oronasal communications. *Int J Oral Maxillofac Surg*. 2006 Feb;35(2):155–8.
- [23] Slack R, Bates G. Functional endoscopic sinus surgery. *Am Fam Physician*. 1998 Sep 1;58(3):707–18.
- [24] Agarwal B, Pandey S, Roychoudhury A. New technique for closure of an oroantral fistula using platelet-rich fibrin . *Br J Oral Maxillofac Surg*. 2016 Feb;54(2):e31–2.
- [25] Lazow SK. Surgical management of the oroantral fistula: flap procedures. *Oper Tech Otolaryngol Head Neck Surg*. 1999 Jun;10(2):148.
- [26] Miloro M, Ghali GE, Larsen P, Waite P. Peterson's principles of oral and maxillofacial surgery, 3rd edition. St. Louis: CV Mosby; 1998: pp. 477–85.
- [27] De Biasi M, Maglione M, Angerame D. The effectiveness of surgical management of oroantral communications: a systematic review of the literature. *Eur J Oral Implantol*. 2014 Winter;7(4):347–57.
- [28] Gacic B, Todorovic L, Kokovic V, Danilovic V, Stojcev-Stajcic L, Drazic R, Markovic A. The closure of oroantral communications with resorbable PLGA-coated beta-TCP root analogs, hemostatic gauze, or buccal flaps: a prospective study. *Oral Surg Oral Med Oral Pathol Oral Radiol Endod*. 2009 Dec;108(6):844–50.
- [29] Del Junco R, Rappaport I, Allison GR. Persistent oral antral fistulas. *Arch Otolaryngol Head Neck Surg*. 1988 Nov;114(11):1315–6.
- [30] Falci SG, Dos Santos CR. Modification of the vestibular mucoperiosteal flap technique for closure of oroantral fistula. *J Craniofac Surg*. 2015 Oct;26(7):e659.

- [31] Neuschl M, Kluba S, Krimmel M, Reinert S. Iatrogenic transposition of the parotid duct into the maxillary sinus after tooth extraction and closure of an oroantral fistula. A case report. *J Craniomaxillofac Surg*. 2010 Oct;38(7):538–40.
- [32] Egyedi P. Utilization of the buccal fat pad for closure of oroantral communication. *J Maxillofac Surg*. 1977 Nov;5(4):241–4.
- [33] Tideman H, Bosanquet A, Scott J use of the buccal fat pad as pedicled graft. *J Oral Maxillofac Surg*. 1986 Jun;44(6):435–40.
- [34] Rapidis AD, Alexandridis CA, Eleftheriadis E, Angelopoulos AP. The use of the buccal fat pad for reconstruction of oral defects: review of the literature and report of 15 cases. *Oral Maxillofac Surg*. 2000 Feb;58(2):158–63.
- [35] Hao SP. Reconstruction of oral defects with the pedicled buccal fat pad ap. *Otolaryngo Head Neck Surg*. 2000 Jun;122(6):863–7.
- [36] Dean A, Alamillos F, Garcia-Lopez A, Sanchez J, Penalba M. The buccal fat pad in oral reconstruction. *Head Neck*. 2001 May;23(5):383–8.
- [37] Loh FC1, Loh HS. Use of the buccal fat pad for correction of intraoral defects: report of cases. *J Oral Maxillofac Surg*. 1991 Apr;49(4):413–6.
- [38] Mohan S, Kankariya H, Harjani B. The use of the buccal fat pad for reconstruction of oral defects: review of the literature and report of cases. *J Maxillofac Oral Surg*. 2012 Jun;11(2):128–31.
- [39] Martín-Granizo R, Naval L, Costas A, Goizueta C, Rodriguez F, Monje F, Muñoz M, Diaz F. Use of buccal fat pad to repair intraoral defects: review of 30 cases. *Br J Oral Maxillofac Surg*. 1997 Apr;35(2):81–4.
- [40] Nezafati S, Vafaii A, Ghojzadeh M. Comparison of pedicled buccal fat pad flap with buccal flap for closure of oro-antral communication. *Int J Oral Maxillofac Surg*. 2012 May;41(5):624–8.
- [41] James RB. Surgical closure of large oroantral fistulas using a palatal island flap. *J Oral Surg*. 1980 Aug;38(8):591–5.
- [42] Erdogan O, Esen E, Ustun Y. Bony palatal necrosis in a diabetic patient secondary to palatal rotational flap. *J Diab Complications*. 2005 Nov–Dec;196:364–7.
- [43] Ward BB. The palatal flap. *Oral Maxillofac Surg Clin N Am*. 2003 Nov;15(4):467–73.
- [44] Dergin G, Gurler G, Gursoy B. Modified connective tissue flap: a new approach to closure of an oroantral fistula. *Br J Oral Maxillofac Surg*. 2007 Apr;45(3):251–2.
- [45] Ito T, Hara H. A new technique for closure of the oroantral fistula. *J Oral Surg*. 1980 Jul;38(7):509–12.
- [46] Yamazaki Y, Yamaoka M, Hirayama M, *et al*. The submucosal island flap in the closure of oroantral fistula. *Br J Oral Maxillofac Surg*. 1985 Aug;23(4):259–63.

- [47] Sielgel EB, Bechtold W, Sherman PM, Stoopack JC. Pedicle tongue flap for closure of an oroantral defect after partial maxillectomy. *J Oral Surg.* 1977;35:746–9.
- [48] Buchbinder D, St-Hilaire H. Tongue flaps in maxillofacial surgery. *Oral Maxillofac Surg Clin North Am.* 2003 Nov;15(4):475–86.
- [49] Alonso del Hoyo J, Fernandez Sanroman J, Gil-Diez JL, Diaz Gonzalez FJ. The temporalis muscle flap: an evaluation and review of 38 cases. *J Oral Maxillofac Surg.* 1994;52:143–7.
- [50] Demas PN, Sotereanos GC. Transmaxillary temporalis transfer for reconstruction of a large palatal defect: report of a case. *J Oral Maxillofac Surg.* 1989;47:197–202.
- [51] Koranda FC, McMahon MF, Jernstrom VR. The temporalis muscle flap for intraoral reconstruction. *Arch Otolaryngol Head Neck Surg.* 1987;113:740–3.
- [52] Campbell HH. Reconstruction of the left maxilla. *Plast Reconstr Surg.* 1948;3:66–72.

