

# We are IntechOpen, the world's leading publisher of Open Access books Built by scientists, for scientists

6,900

Open access books available

185,000

International authors and editors

200M

Downloads

Our authors are among the

154

Countries delivered to

TOP 1%

most cited scientists

12.2%

Contributors from top 500 universities



WEB OF SCIENCE™

Selection of our books indexed in the Book Citation Index  
in Web of Science™ Core Collection (BKCI)

Interested in publishing with us?  
Contact [book.department@intechopen.com](mailto:book.department@intechopen.com)

Numbers displayed above are based on latest data collected.  
For more information visit [www.intechopen.com](http://www.intechopen.com)



---

# Gastrointestinal Foreign Bodies

---

Obinna Obinwa, David Cooper,  
James M. O’Riordan and Paul Neary

Additional information is available at the end of the chapter

<http://dx.doi.org/10.5772/63464>

---

## Abstract

Retained foreign bodies within the gastrointestinal tract (GIT) are common emergency presentations. The majority will pass spontaneously or be removed endoscopically, but a few selected cases may require emergency surgery for removal. This chapter reviews the management of foreign bodies within the GIT including both instances of foreign body ingestions and foreign body insertions. The scope of this chapter is not limited to evidence-based data on selection of cases for conservative management but also includes data on endoscopic and surgical management.

**Keywords:** complications, decision support techniques, diagnosis, emergency management, endoscopy, foreign bodies, gastrointestinal tract, humans, surgery

---

## 1. Introduction

Gastrointestinal tract (GIT) foreign body ingestions or insertions are common clinical scenarios, with an estimated 1500–2750 patients dying annually from ingested foreign bodies in the United States each year [1–3]. The problem is encountered in all age groups, and the choice of an appropriate technique for removal may, at times, pose a dilemma for the clinician. Although recent reports suggest that most cases of foreign body ingestion do not result in mortality or significant clinical sequelae [4], evidence-based criteria for management should be employed so as to reduce the risk of potential adverse events. Importantly, cases selected for surgical removal should be appropriately investigated and managed.

---

## 2. Epidemiology

Foreign body ingestion is more prevalent amongst the paediatric age group than in the adult population. The peak incidence is between 6 months and 6 years [4]. The ingestion of foreign bodies is rarely seen in adults; is accidental and is commonly observed in the form of food (meat and bone) ingestion [5]. High-risk groups among an adult patient population include those with psychiatric disorders, prisoners and intoxicated patients [4]. Intentionally ingested objects typically include common household items (e.g., pens, plastic spoons, toothbrushes or pencils), whereas accidentally ingested items are often food impactions or bones.

Foreign body insertion, on the other hand, especially involving the lower GIT, is more prevalent in an adult demographic [6]. The true incidence is not known, as many patients do not seek medical attention or management is underreported for obvious reasons [7]. These cases are not limited to a particular demographic, and rectal foreign bodies have been reported in patients of all ages, genders and ethnicities [5, 8]. The mean age at presentation is 44 years but ranges from 20 to over 90 years, with a decidedly higher proportion of male patients (17–37:1) [7]. The most common reason for insertion is anal eroticism, with other reasons, in decreasing order of frequency, being concealment (as in prisoners), attention-seeking behaviour, assault and “therapeutic” (i.e., attempts to alleviate constipation) [9]. Some literature reports a bimodal age distribution, with the second peak occurring in males in their sixties, often for breaking up faecal impactions or prostatic massage [10].

## 3. Surgical pathophysiology

A rational approach to management of gastrointestinal intestinal foreign bodies requires an understanding of the natural course of these ingested or inserted objects. This knowledge is essential to be able to define groups of patients who would require early intervention. Approximately 63–76% of intentionally ingested foreign bodies are removed endoscopically, and the need for surgical intervention ranges from 12 to 16% [4].

Historically, 80% or more of ingested foreign bodies pass spontaneously without the need for intervention [11]. Complications such as impaction, perforation or obstruction occur at areas of physiological narrowing or angulations [12]. Areas of narrowing in the GIT include the upper oesophageal sphincter, aortic arch, left main stem bronchus, lower oesophageal sphincter, pylorus, ileocecal valve and anus; the duodenal sweep is an example of GI angulation [12]. Once foreign bodies have passed through the oesophagus, which is the least expansile aspect of the GIT, most objects pass within 4–6 days or in rare cases in up to 4 weeks [12]. Any anatomical variation in the GIT can alter these series of physiological narrowing and angulations. Therefore, patients with congenital malformations or those who have undergone previous GI surgery are more susceptible to retained foreign bodies [4].

The risk of retention and subsequent complications also varies according to the nature of the foreign body. For example, sharp or pointed objects, fish/animal bones, foil from blister packs, as well as magnets, are associated with an increased risk of perforation [4]. Magnets are especially dangerous as they may attract other simultaneously ingested foreign bodies [13]. Due to their magnetic forces, the objects may adhere to one another across two separate parts of the GI tract leading to severe and potentially fatal complications including volvulus and obstruction, pressure necrosis, fistula formation and perforation [14].

Impaction and progressive erosion of the foreign body through the intestinal wall lead to perforation, and, in most cases, this site of perforation is covered by fibrin, omentum or adjacent loops of bowel [12]. The passage of large amounts of intraluminal air into the peritoneal cavity rarely occurs as a result [12]. Retained gastric, intestinal and rectal foreign objects can cause severe injury through this mechanism. The main site of obstruction for rectal foreign bodies is the mid-rectum as objects are unable to renegotiate the anterior angulation of the rectum. All such retained foreign bodies should, therefore, be treated as potentially hazardous [8].

#### 4. Classifications

A clinical classification of gastrointestinal foreign objects into oesophageal, gastric, intestinal or colorectal foreign bodies is based on the location of the object within the GIT. Objects may also be classified as ingested foreign objects or foreign body insertions using the mechanism of entry as criteria for classification. Further sub-classifications of ingested foreign objects into groups of blunt objects, sharp pointed objects, long objects, food bolus impaction and objects containing poisons are useful in defining the management approach [12].

Foreign body insertions into the rectum may be voluntary or involuntary. The intent may be sexual or non-sexual. Using this two-tier classification system, rectal foreign bodies are classified as voluntary sexual, voluntary non-sexual, involuntary sexual and involuntary non-sexual. The most common category of inserted objects is that of voluntary sexual insertions and includes plastic/glass bottles, vegetables, wooden or rubber objects and sex toys [15]. Cases of insertion of involuntary sexual foreign bodies are almost exclusively limited to the domain of rape and sexual assault [15]. Involuntary non-sexual insertions (e.g., thermometers and enema tips) are found in the elderly, children or the mentally ill, and are often accidental [15]. The term “body packing” represents a form of voluntary non-sexual insertion and refers to smuggling of drugs by concealment in the GIT [12]. For example, illegal drugs (most often cocaine or heroin) are packed within latex condoms or balloons and are swallowed or inserted into the rectum in several parcels [12, 16]. These parcels pose a significant health risk as intoxication secondary to rupture can be potentially fatal. Alternatively, the American Association for the Surgery of Trauma Rectum Injury Scale may be used to assess injury from rectal foreign bodies [7].

## 5. Clinical presentations and assessment

Patients with gastrointestinal foreign bodies (either inserted or ingested) are often asymptomatic. Alternatively, they may present with a broad range of symptoms, which, vary based on the location, physical characteristics and the content of the object [5]. Most rectal foreign objects are introduced through the anus; however, sometimes, a foreign body is swallowed, fails to pass fully through the GIT, and is held up in the mid-rectum [10]. Patients with foreign bodies introduced through the anus are often embarrassed about their condition and may be reluctant to seek medical care [17]. In most cases, the patients present to the emergency room after failed efforts to remove the object at home [8]. The time interval from insertion to hospital presentation varies, and may be up to 2 weeks [9].

The medical history is highly critical in the management of foreign body ingestion or insertion [5]. The planning of diagnostic workup and the extent and urgency of a possible intervention are primarily decided according to the information provided by the patient regarding the type of object inserted, together with clinical complaints and findings [5]. However, the main difficulty encountered is that of patients' reluctance to divulge the nature of insertion/ingestion. For example, patients with rectal foreign bodies are often embarrassed about their condition and may seek to conceal some relevant facts leading to extensive workups and further delays [18]. A high index of suspicion is required to accurately diagnose their condition. At the same time, the practitioner should try to establish the mechanism of insertion. In one case report, the rectal injury was caused not by the foreign object itself, but by another object used as an introducer [19].

It is pivotal to maintain professionalism and courtesy while simultaneously obtaining an accurate, detailed history. For communicative adults, history of ingestion including timing, type of ingested foreign body and onset of symptoms are often reliable [20]. One must also consider whether such case of involuntary insertion constitutes an assault, for the management of the latter requires other medicolegal considerations. For example, it is essential to keep medical photographs of retrieved rectal foreign bodies for clinical records in cases of assault and child abuse [6]. The clinician should also be prepared to provide emotional support for the patient, and have a chaperone in the room when performing the physical examination [7].

Even in good historians, physical examination is mandatory to rule out potentially hazardous complications such as small-bowel obstruction or perforation. Signs of GI perforation may include tachycardia, subcutaneous crepitus and peritonitis. A medical consultation is required if systemic toxicity is due to ingestion of foreign objects [4]. A respiratory examination is necessary to assess for the presence of wheezing or crepitations suggestive of tracheal compression or aspiration, respectively. Specific other presentations are based on the anatomical region where the foreign body is located.

### 5.1. Oesophageal foreign bodies

Patients with oesophageal foreign bodies, particularly impacted food boluses, can specify the onset of symptoms and if symptomatic may attempt to localise their discomfort exactly.

However, the area of discomfort does not always accurately correlate with the site of impaction [4]. The typical complaints in symptomatic patients include a vague report of the sensation of something stuck in the centre of the chest or sudden onset of the difficulty of swallowing during eating. If they report the same sensation in the epigastric region, it may indicate that the foreign body has passed the lower oesophageal sphincter. When the foreign body has passed the oesophagus, the majority of patients remain asymptomatic but a sensation of foreign body, with dysphagia, can persist for several hours and thus can mimic a persisting foreign body impaction [12].

Dysphagia is another commonly reported symptom, and in the presence of drooling, especially in paediatric cases, may indicate an oesophageal obstruction. Patients with oesophageal foreign bodies may also present with respiratory symptoms such as a cough, stridor or dyspnea. These symptoms may occur as a result of a direct tracheal compression by the foreign body or indirectly due to aspiration of secretions. Non-specific symptoms, such as abdominal pain or distension, nausea and vomiting, haematemesis or melaena, may be present. If the pericardium and myocardium are involved, the patient may present with acute onset chest pain secondary to mediastinitis or may complain of dyspnoea or severe odynophagia. Such cases are associated with significant morbidity and are recognized causes of mortality [21].

## **5.2. Gastric and intestinal foreign bodies**

Once foreign bodies have passed through the oesophagus, they are usually asymptomatic, unless obstruction or perforation occurs. Symptoms suggestive of obstruction include abdominal pain, distension, vomiting and constipation. The presence of severe abdominal pain that is intensified by movement, fever and/or rigors makes a diagnosis of gastric or small-bowel perforation more likely. The clinician may also be able to predict the level of obstruction based on clinical history alone. For example, in small-bowel obstruction, the pain tends to be colicky in nature, as opposed to large-bowel obstruction that is usually associated with a more constant pain. For more proximal obstructions, vomiting tends to present before constipation, whereas the opposite is more consistent with distal GIT obstructions. Non-bilious vomiting indicates that the obstruction is above the level of the ampulla of Vater. Bilious vomiting occurs when the blockage is below this level, and faecal vomiting is more indicative of distal bowel obstruction. In the presence of obstruction or perforation, the typical findings on physical examination include abdominal distension and tenderness; additional peritoneal signs of rigidity or rebound tenderness make the diagnosis of perforation more likely.

## **5.3. Colorectal foreign bodies**

Because of the wide variety of objects and the variation in trauma caused to local tissues of the rectum and distal colon, a systematic approach to the diagnosis and management of rectal foreign bodies is essential [15]. Common complaints include rectal or abdominal pain, constipation or obstipation, bright red blood per rectum or incontinence. Complications such as bowel obstruction may also occur [6]. Sudden, excruciating pain during defecation should arouse suspicion of a penetrating foreign body that is usually lodged at or just above the anorectal junction [7]. The presence of a chocolate malodorous rectal mucoid discharge



signifies necrosis, perforation and/or sepsis [6]. Other manifestations depend on the size and shape of the foreign body, its duration in situ and the presence of infection or perforation.

Physical examination should include a careful abdominal examination to assess for signs of peritonitis or the ability to palpate an object trans-abdominally [15]. Abdominal examination is usually followed by a digital rectal examination. However, some authors advise that an abdominal X-ray should be performed before the rectal examination to prevent inadvertent, accidental injury to the surgeon from sharp objects [15]. A digital rectal examination estimates the distance of the foreign body from the anal verge, as well as assesses sphincter integrity. Sphincter injury is rare in cases of voluntary insertion. However, muscular spasm induced by the foreign body may result in increased sphincter tone. The sphincter may have obvious damage with visible injury to both the internal and external components and should be carefully examined [15]. Most foreign bodies are usually palpable on the digital rectal examination as they are most commonly lodged in the mid rectum.

## 6. Further investigations/workup

Radiological assessment is the key to further evaluation following a thorough history and clinical examination. For anorectal foreign bodies above the sacral curve and rectosigmoid junction, further evaluation with rigid or flexible proctosigmoidoscopy should be performed if the rectal object is not palpable. Laboratory tests are of limited value and should be limited to a basic pre-operative work, allowing for timely surgical management if appropriate [7, 15]. Patients with peritonitis or perforation should be kept nil by mouth and resuscitated with intravenous fluids and antibiotics [15]. A nasogastric tube should be considered, and Foley's catheter should also be passed [15]. Anti-thromboembolic prophylaxis should be commenced early and continued until discharge, particularly in elderly patients.

Plain radiographs are the first line radiological investigation as they are inexpensive and associated with reduced radiation exposure. Most true foreign bodies are radio-opaque but smaller thinner objects are not always detected [12]. Metal objects tend to be easily identified, whereas small bone or glass or wooden objects are less readily detected. Serial radiographic studies can be used to determine the passage of the foreign body and the complications resulting from it [5]. Biplanar imaging may be necessary if the history suggests foreign body ingestion but there is nothing detected on initial plain radiograph [12]. Complications such as aspiration, free mediastinal/peritoneal air or subcutaneous emphysema may also be detected on chest X-ray in a limited number of cases [12]. X-ray is not sufficient and not required in patients with non-bony food bolus impaction and without clinical signs of perforation [12].

The use of barium swallow as part of the workup for a patient with ingested foreign body is not advised [12]. It is associated with an increased risk of aspiration and may obscure visualization if subsequent endoscopy is indicated. If an upper GI foreign body is not detected on plain films, then an oral contrast medium (e.g., gastrograffin) may be considered, assuming oesophageal obstruction has been ruled out [12]. Computed tomography (CT) of the abdomen and pelvis is especially useful when radiolucent materials cannot be detected

with plain X-rays [5]. It may also be considered if the rectal foreign body has been in place for more than 24 h [8]. This modality has largely supplanted the previous contrast studies. The risk of potential complications increases if the foreign body has been in place for more than 24 h. With CT, the shape, size, location and depth of the impacted foreign body and the surrounding tissue can be visualized, which is important in determining treatment. Of note, free intraperitoneal air is a poor radiological sign [12]. The region of perforation can be identified on CT scan as a thickened intestinal segment, localized pneumoperitoneum, regional fatty infiltration or associated obstruction [12, 22].

## 7. Further management

### 7.1. Ingested foreign objects

Conservative outpatient management, on the one hand, is appropriate for asymptomatic patients with blunt objects in the stomach that are smaller than 2–2.5 cm in diameter and 5–6 cm in length [12]. As a rule, objects greater than 2.5 cm in diameter will rarely pass through the pylorus or ileocecal valve and objects longer than 6 cm will also rarely pass through the duodenal sweep [12]. Patients who are to be managed conservatively should be educated about the symptoms of potential complications and instructed to represent if they occur [12]. Of particular importance are those related to perforation or obstruction. They should also be instructed to check their bowel motions to monitor for spontaneous passage of the foreign body [12]. If the foreign body fails to pass beyond the stomach within 4 weeks, it is likely to require intervention [4, 12]. Conservative in-patient management, on the other hand, is recommended for “body-packers” with a failure rate of only 2–5% [12]. The management comprises clinical observation, whole bowel irrigation and radiographic follow-up for observing passage of the parcels [12].

Recently, the European Society of Gastrointestinal Endoscopy (ESGE) published guidelines for foreign body management [12]. According to their guidelines, the timing of endoscopic intervention is divided into three groups: emergency, urgent and non-urgent. Patients who are unable to manage their secretions on presentation, those who swallowed disk batteries and those with sharp objects in the oesophagus will require emergent endoscopic intervention (preferably within 2 h, but at latest within 6 h) [12]. Urgent (within 24 h) endoscopy is recommended for removal of oesophageal foreign objects that are not sharp-pointed, food impaction without complete obstruction, sharp pointed objects in the stomach or duodenum and objects longer than 6 cm in length and magnets within endoscopic reach [12]. As delay decreases the likelihood of successful removal of such objects and increases the risk of complication, endoscopic removal should not be delayed beyond 72 h even for the non-urgent cases [12]. Cases suitable for non-urgent management include coins in the oesophagus which may be observed for 12–24 h before endoscopic removal in an asymptomatic patient [4]. Cylindrical and disk batteries that are in the stomach of patients without signs of GI injury may be observed for as long as 48 h before proceeding with endoscopic removal [4]. Batteries



remaining in the stomach longer than 48 h should be removed before 72 h as well as objects in the stomach with a diameter greater than 2.5 cm [4].

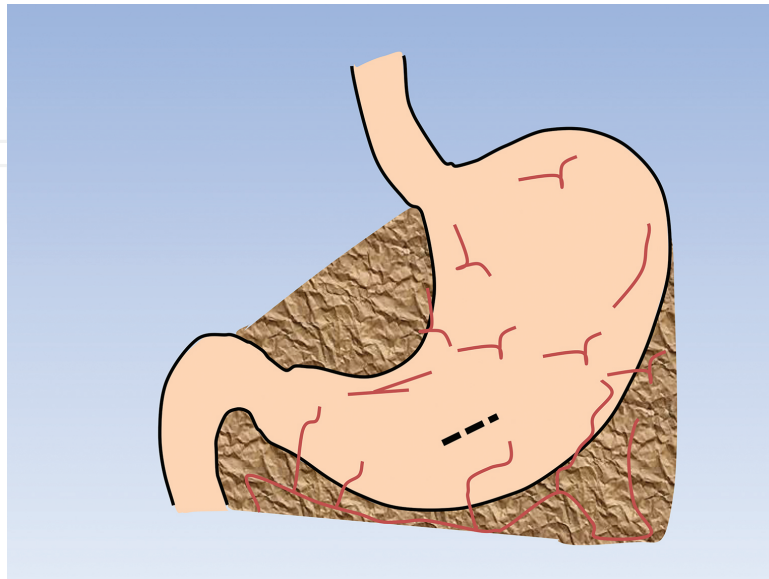
In practice, conscious sedation may be used for endoscopic removal in adults, but endotracheal intubation under general anaesthesia is often required for objects that are harder to remove. Standard-sized overtubes that extend past the upper oesophageal sphincter not only protect the airways but also facilitate passage of the endoscope during removal of multiple sharp, pointed objects or piecemeal extraction of an impacted food bolus [12]. Overtubes help to reduce further potential damage to the mucosa of the GIT while the foreign body is being withdrawn. The specific example of removal of food bolus may simply involve gently pushing the bolus into the stomach with success rates of over 90% and minimal complications [12]. However, extraction may also be performed using grasping forceps, retrieval graspers, polypectomy snare, basket and retrieval nets. Other blunt objects such as coins, buttons, toys, batteries and magnets can also be removed using a similar range of retrieval devices. Long objects including strings, cords, pen, pencils, toothbrushes, cutlery and screwdrivers are best removed using polypectomy snares or baskets. A transparent cap and latex rubber hood may be required additionally for removal of sharp pointed objects. If the foreign body cannot safely be retrieved endoscopically, in-patient treatment and close clinical observation are mandatory.

Bleeding can also be encountered as a complication of ingestion or endoscopic removal of sharp pointed objects. The principle of successful management is by meticulous resuscitation, accurate endoscopic diagnosis and timely application of appropriate therapy. The endoscopic and surgical management is similar to that of bleeding peptic ulcers. For example, ulcers with a clean base or non-protuberant pigmented dot in an ulcer bed, which are at low risk of re-bleeding, do not require endoscopic treatment [23]. For all others, including those who have active bleeding or non-bleeding visible vessels or have adherent blood clot, endoscopic treatment should be administered [23]. Injection with 1:10,000 adrenaline around the bleeding point and then into the bleeding vessel achieves haemostasis in up to 95% of cases [23]. Additional injection of sclerosants or absolute alcohol does not confer additional benefit. Fibrin glue and thrombin may be more effective, but they are not widely available. Heater probes, multipolar coagulation (BICAP), argon plasma coagulation or mechanical clips may also be used but consulting a gastroenterologist may be more appropriate at this stage. Repeat therapeutic endoscopy may be attempted if there is a suggestion of further active bleeding or in cases where the initial endoscopic treatment was sub-optimal. Operative intervention is mandatory if initial control of bleeding is not possible endoscopically and techniques are as described in standard surgical texts.

Besides for failure to control bleeding endoscopically, there are other indications for surgical intervention. Urgent cases include cases of ruptured narcotic packets or leakage, presentations with clinical evidence of peritonitis and intestinal obstruction. Non-urgent indications for surgery include scenarios in which endoscopic removal is challenging such as trichobezoars [24], or if the object has failed to progress along the GIT and is not accessible by endoscopy [25–27].

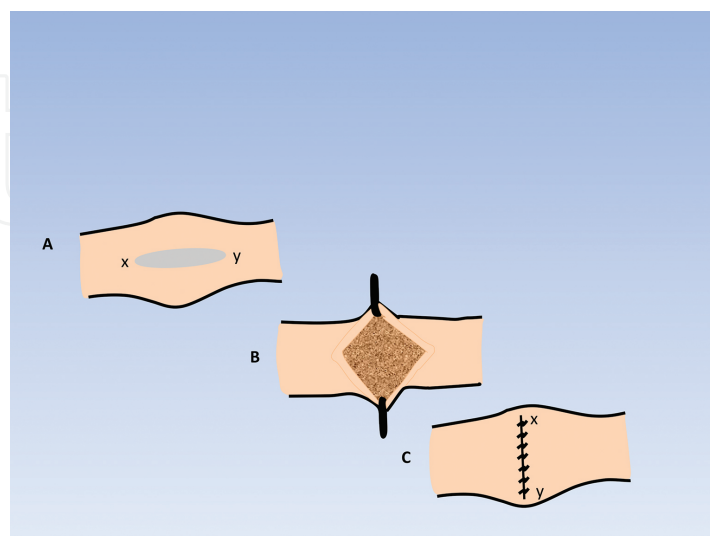
Access in all cases is through an upper midline incision. The abdominal wound is also protected to minimize the risk of wound infection. Subsequent surgical removal of gastric

foreign bodies will involve a transverse gastrotomy away from the pylorus and between the lesser and greater curve of the stomach (**Figure 1**).



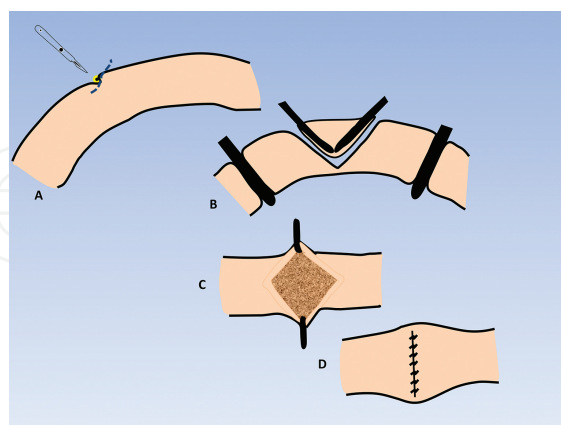
**Figure 1.** Transverse gastrotomy for removal of foreign bodies.

Objects impacted at the duodenal sweep can be removed through a duodenotomy if they cannot be milked back to the stomach. Similarly, impacted objects in the small bowel can be removed through enterotomies. Primary closure is indicated in cases without peritoneal contamination. For closure, it is important to avoid narrowing the lumen. Techniques similar to that of pyloroplasty involving transverse incisions with longitudinal closure using absorbable sutures should be considered (**Figure 2**).



**Figure 2.** Technique of pyloroplasty.

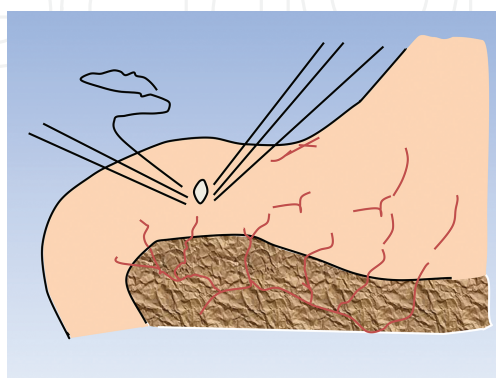
Perforated cases are often contained, so a primary closure or segmental resection of the affected small bowel may still be possible provided the tissues remain healthy (**Figure 3**).



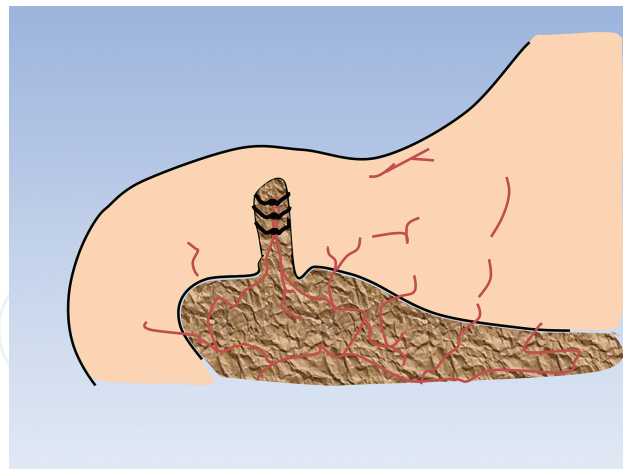
**Figure 3.** Segmental bowel resection and anastomosis.

Diversion may be reasonable in cases of delayed presentation, or where grossly faecal contamination has occurred, and the tissues are unhealthy. The stoma can be reversed at a later date (after 3 months usually). The use of intra-abdominal drains may be limited to the surgeon's preference. Postoperative care should follow the lines of enhanced recovery following upper gastrointestinal surgery.

Although sealed perforation involving degradable food matter can be treated non-surgically in the initial instance, such a policy requires careful interval assessment by an experienced surgeon with a low threshold for performing laparotomies if clinical improvement is not apparent both to confirm the diagnosis and oversee an unsealed perforation [28]. In most cases, however, the treatment of choice for patients with perforation of the duodenum is laparotomy, peritoneal lavage and simple closure of perforation, usually by omental patch repair [23]. The initial step of the repair involves placement of full-thickness bites at approximately 0.5 cm away from the edges of the perforation, and the defect is left untied (**Figure 4A**).



**Figure 4A.** Placement of sutures for omental patch repair.



**Figure 4B.** Final repair of a duodenal perforation with an omental patch.

A patch of omentum is then brought without tension and positioned over the perforation, and the sutures are successively tied to secure the omentum onto the defect itself (**Figure 4B**).

In cases of “giant” perforation, where the defect measures 2.5 cm or more, partial gastrectomy with closure of the duodenal stump should be considered [23]. Alternatively, in situations where the clinical situation or expertise dictates more expeditious surgery, the duodenal perforation should be closed as well as possible around a large Foley or T-tube catheter to create a controlled fistula [23]. Other methods described include a free omental and jejunal serosal “plug” [23].

## 7.2. Inserted foreign objects and anorectal objects

It is essential to remove all retained anorectal foreign bodies [8]. However, extraction of rectal foreign bodies may be challenging. The medical literature confirms the diversity of the problem, and equally some ingenious solutions [19, 29–40]. Techniques described range from simple digital extraction to complicated surgical removal. Several algorithms for management have also been proposed [6, 7, 29], with a tendency to progress from least to most invasive as required [7]. This approach will result in the best chance of success with the lowest risk to the patient [7].

Unless signs of peritonitis are present, or the patient is unstable, both of which necessitate emergency laparotomy, an initial attempt at bedside extraction is advised [15]. Bedside extraction is successful in 60–75% of cases [7]. A variety of tools can be used as adjunct retrieval devices including obstetric forceps, ring forceps, Kocher clamps, suction devices and various grasping forceps. The instruments used vary according to the characteristics of each case. For example, in cases where the rectal foreign body has created a seal with the rectal mucosa [15], a balloon catheter such as a Foley may be used to pull the foreign body distally along the GIT [41–44]. The Foley is inserted, deflated and passed proximally to the retained object, then inflated and subsequently pulled to drag the foreign body along the bowel. This technique is useful in cases in which the rectal lumen is obstructed by a smooth foreign body. The foreign

body results in a negative pressure differential on the proximal rectal lumen. By inserting the Foley above the area, the pressures will equalize and help facilitate the removal. Alternatively, obstetric vacuum extractors may be used to grasp the object, widen the anal canal and release the rectal seal [45–47]. It is pertinent to note that body packers should have potentially toxic packages removed with digital rectal examination only, tools and endoscopic devices should be avoided as they increase the risk of damage to the parcel and leakage/absorption of its' contents. Any systemic signs of perforation may warrant laparotomy with the subsequent supportive care of any overdose geared towards the drug ingested. The use of enemas and stimulants to propel the object distally is not recommended, as these may cause further damage to the rectal wall [7].

Surgeons have higher success rates at bedside transanal extraction than emergency physicians [48]. The exact reasons for this are unclear, but may represent a willingness to be more aggressive in attempts to remove the object and due to the ability to fix resultant damage in the theatre [7]. In general, predictors of failure of transanal extraction of retained rectal foreign bodies include objects longer than 10 cm, hard or sharp objects, those that have migrated into the sigmoid colon as well as those that have been retained for more than 2 days [6, 48].

When attempting to remove a rectal foreign body transanally, the most important factor in successful extraction is patient relaxation [15]. This can be achieved with a perineal nerve block, a spinal anaesthetic or either of these in combination with intravenous conscious sedation [15]. After the patient has been appropriately sedated and anaesthetized, attempts should be made to remove the object [15]. The high lithotomy position in Candy Care Stirrups in the operating theatre facilitates the removal of most objects and has the added benefit of allowing for downwards abdominal pressure to be applied to aid in the extraction of a foreign body [15]. The anal canal should be gently dilated to three fingers' breadth before transanal delivery [15]. A reverse Trendelenburg angulation may also be attempted. The technique of bimanual extraction helps move an object caudally and also prevents cephalad migration with difficult to grasp objects [7]. Blind insertion of instruments should be avoided as it can hinder the removal of the foreign body and induce rectal injuries or perforation [49].

Flexible sigmoidoscopy is required for objects that are located more proximally in the rectum or the distal sigmoid colon, which are often not amenable to removal by per digital rectal examination or with the tools mentioned earlier [29]. Endoscopy produces an additional means of non-operative extraction, thereby limiting operative intervention in some cases. Removal of sharp objects can pose an extra risk to both the patient and the surgeon, but direct visualization with rigid or a flexible endoscopy has helped to mitigate this problem [9, 15]. This excellent visualization of the mucosa with endoscopy also helps to evaluate for subtle and gross changes in the rectal mucosa [15]. Polypectomy snares may be used to "lasso" objects [18, 50] or objects may be grasped by grasping forceps using endoscopic methods. Removal under general anaesthesia is attempted when endoscopic removal under sedation is not successful. It is worth mentioning that all patients undergoing removal of foreign objects under general anaesthesia should also consent for laparoscopy or laparotomy should the first attempts fail [29].



Surgical removal (laparotomy or laparoscopy) is indicated in patients with systemic signs or radiological evidence of perforation. Additionally, surgery may also be performed as a last resort when anal dilatation, manual or forceps extraction have failed to remove the foreign body [29]. The surgical options for a failed transanal extraction vary from minimally invasive techniques to open surgery. Evidence for use of each technique is limited to case series and reports. For the laparoscopic-assisted techniques of removal, the object is milked inferiorly with direct intra-abdominal visualization using a laparoscope and grasper that aids in the eventual transanal extraction [51]. Similarly, a lower midline mini-laparotomy may be used to squeeze the rectum directly and allow transanal removal [52]. Ultimately, if these attempts remain unsuccessful, a colotomy with transabdominal removal can be performed [7]. This is also the technique usually required in an emergent setting where perforation has occurred [7]. If gross contamination or spillage is present, a Hartmann procedure may be the prudent option [7]. However, if tissue quality is good, a primary repair or short segment resection may be performed, and the repair is tested for a leak using protoscopy [8]. This approach is well supported in the trauma literature with experience of blunt and penetrating trauma [7]. Further, the evidence from trauma literature shows that severe faecal contamination, transfusion of more than three units of blood, and single-agent antibiotic prophylaxis are independent factors for abdominal complications following surgery for colorectal trauma [53].

Further notes on the management of rectal perforation are presented here. When patients present with a rectal perforation, they should, at first, be stabilized as with any trauma patient [15]. After stabilization, management depends on three factors: first, whether the patient is clinically stable or unstable, second, whether the perforation is in an intraperitoneal or extraperitoneal location, and last, whether there is significant fecal soilage or not [15]. Preoperative CT scan is required. A well-established order for the management of a rectal perforation secondary to a foreign body is diversion, debridement, distal washout and drainage [15]. Unstable patients, those with multiple comorbidities, those with significant tissue damage and those with delayed presentation more often require a diversion [15]. On the other hand, a primary repair and washout is suited for patients who present early, those with minimal tissue damage and those with little to no contamination [15]. Small extraperitoneal injuries can be managed with observation, avoidance of enteral feeding and antibiotics [15]. However, laparoscopic approach has been successfully applied in the treatment of colonic perforations, and operative outcomes are similar to open procedures in selected patients [15]. In cases of rectal perforation secondary to foreign body insertion, the operator must be aware of the possibility of secondary or occult organ injury. The small bowel, uterus, bladder and sigmoid colon should all be assessed preoperatively. It is also important that a full consent process outlining risk of a stoma is discussed before the patient is anaesthetized. Failure to do so may result in patient dissatisfaction with treatment and complaints.

If none of the above measures are successful, specifically in cases of large objects tightly wedged in the pelvis, the next logical step would be to carry out a symphysiotomy [8]. A symphysiotomy involves attempts at expanding the pelvic volume to facilitate the passage/removal of larger objects. Such a description may, however, be a historical anecdote rather than acceptable correct surgical practice.

## 8. Aftercare

If the ingested foreign bodies are not or cannot be removed, a case-by-case approach depending on the size and type of the foreign body is suggested [12]. A patient may be discharged if a successful and uncomplicated endoscopic removal of ingested foreign bodies has been achieved [12]. Other groups of patients including those with significant co-morbidities, delayed presentation, difficult extraction or haemodynamically unstable post-extraction may require further clinical observation. Post-extraction repeat endoscopy and plain radiographs should be considered before discharging any such patient [18, 48].

Psychological evaluation before discharge should be considered in the setting of intentional ingestion. This assessment may help reduce recurrent presentations. In cases of sexual assault, long-term psychological consequences may occur, and therefore, early involvement of mental health services and counselling is warranted [6]. Children in whom a non-accidental injury is suspected should be referred to a paediatrician for further evaluation, and legal authorities should always be informed in every case of suspected assault [6]. The aim is to offer support to victims of assault and abuse [18, 54]. Additionally, the patients should be examined for the use of alcohol and narcotic drugs.

Postoperative pain control, early ambulation and diet initiation upon return of bowel function should follow guidelines for any general surgical intervention [8]. For patients who underwent surgical extraction, the discharge should be considered when bowel physiology returns [8]. For anorectal foreign bodies, it is of paramount importance to inspect the distal colon endoscopically to rule out any unintentional injuries upon successful extraction [10, 18]. It is also important to document sphincter function post-extraction [7]. Although bleeding lacerations in the rectal mucosa are self-limiting, perforation resulting in sepsis and multisystem organ failure can occur [15]. If there is any clinical suspicion, a CT scan with rectal contrast or rectal enema with water-soluble contrast can detect this potentially life-threatening complication [7]. After diagnosis, stable patients may be managed with antibiotics [7]. Patients with signs of toxicity including fever, hypotension or severe pain should be managed by surgical exploration [7]. Depending on the level of perforation, options for surgical management are similar to those previously described above [7].

Significant trauma or damage to the anal sphincter can also result in mild to severe faecal incontinence. There are no good long-term studies, and few articles describe long-term follow-up [7]. One series included a telephone survey of 30 patients with a previous retained foreign body. None had any incontinence to solid, liquid or gas with a follow-up ranging from 8 to 96 months [55]. Although uncommon, complications from sphincter damage may include fistulas and stenosis [56]. Cases of sphincter dysfunction (including incontinence) are often initially managed conservatively; any injury is left open, and further assessment is undertaken in an elective setting [7]. A follow-up of at least 3 months is recommended before considering any sphincter repair [17]. If symptoms persist, a delayed sphincteroplasty may be performed with good results [57].

## 9. Summary

In keeping with the inquisitive nature of humans, there are a wide variety of foreign body presentations encountered in clinical practice across all age groups. Although there may be anecdotal or interesting clinical scenarios of ingested or inserted foreign bodies, one can never underestimate that there is a significant morbidity and unfortunately, mortality associated with these cases. The retrieval of upper gastrointestinal foreign bodies is a more described pathway in the literature. The removal of rectal foreign bodies often requires a wide variety of approaches, many of which are individualized. Surgery may be necessary in some patients.

## 10. Suggested additional reading

Birk M, et al. Removal of foreign bodies in the upper gastrointestinal tract in adults: European Society of Gastrointestinal Endoscopy (ESGE) Clinical Guideline. *Endoscopy*. 2016;48:1-8. <https://www.thieme-connect.com/products/ejournals/html/10.1055/s-0042-100456>.

## Key points

- Presentations due to gastrointestinal foreign body ingestion or insertions are common emergency clinical scenarios. The majority of these objects will pass spontaneously, and others will require endoscopic or surgical intervention for removal.
- Absolute indications for abdominal surgery include those patients with clinical peritonitis from perforation. Other indications for surgery include bowel obstruction and failure of conservative or endoscopic management.
- Surgical technique for removal of a gastric foreign body involves a transverse gastrotomy with incision away from pylorus and between the lesser and greater curvature of the stomach. Retained intestinal or colonic foreign bodies may also be removed through enterotomies or colostomies. Primary closure is indicated in the absence of peritoneal contamination, and it is important to avoid narrowing the gut lumen during closure.
- In the case of peritonitis due to gut perforation, a primary repair or short segment resection of enterotomy or colotomy may be appropriate after a thorough washout of the abdomen if the tissue quality is good. Diversion of the gut may be required in cases of delayed presentations, significant faecal contamination and signs of sepsis.
- Foreign body insertions represent a challenging and unique field of colorectal trauma. A careful history and examination is essential in the diagnosis. However, rectal examination may best be performed after an abdominal X-ray to prevent inadvertent, accidental injury to the surgeon from sharp objects.
- Bimanual extraction under anaesthesia is the technique of first choice when bedside extraction fails. Other options for removal under anaesthesia will include anal dilatation,

laparotomy or laparoscopy. A colotomy may be required for removal when the object cannot be milked down for transanal extraction. A Hartmann's procedure may be necessary in cases of significant faecal peritonitis.

- It is important to document sphincter function post-extraction of a rectal foreign body. Recto-sigmoidoscopy is advised to assess the rectal and distal colonic mucosa to determine the extent of any possible injury and exclude perforation.
- Cases of sphincter dysfunction after removal of a rectal foreign body are often initially managed conservatively, and the majority will resolve without any intervention. For those not settling, referral to a specialized colorectal surgery/incontinence unit is recommended and may require a delayed sphincteroplasty.

## Author details

Obinna Obinwa\*, David Cooper, James M. O'Riordan and Paul Neary

\*Address all correspondence to: obinnaobinwa@rcsi.ie

Department of Surgery, The Adelaide and Meath Hospital, Dublin Incorporating the National Children's Hospital, Dublin, Ireland

## References

- [1] Pfau PR. Removal and management of esophageal foreign bodies. *Techniques in Gastrointestinal Endoscopy*. 2014;16(1):32–9.
- [2] Lyons MF, 2nd and Tsuchida AM. Foreign bodies of the gastrointestinal tract. *The Medical Clinics of North America*. 1993;77(5):1101–14.
- [3] Clerf LH. Historical aspects of foreign bodies in the air and food passages. *Southern Medical Journal*. 1975;68(11):1449–54.
- [4] Ikenberry SO, Jue TL, Anderson MA, et al. Management of ingested foreign bodies and food impactions. *Gastrointestinal Endoscopy*. 2011;73(6):1085–91. DOI:10.1016/j.gie.2010.11.010.
- [5] Erbil B, Karaca MA, Aslaner MA, et al. Emergency admissions due to swallowed foreign bodies in adults. *World Journal of Gastroenterology*. 2013;19(38):6447–52. DOI: 10.3748/wjg.v19.i38.6447.
- [6] Ayantunde AA. Approach to the diagnosis and management of retained rectal foreign bodies: clinical update. *Techniques in Coloproctology*. 2013;17(1):13–20. DOI:10.1007/s10151-012-0899-1.

- [7] Cologne KG and Ault GT. Rectal foreign bodies: what is the current standard? *Clinics in Colon and Rectal Surgery*. 2012;25(4):214–8. DOI:10.1055/s-0032-1329392.
- [8] Kasotakis G, Roediger L and Mittal S. Rectal foreign bodies: a case report and review of the literature. *International Journal of Surgery Case Reports*. 2012;3(3):111–5. DOI: 10.1016/j.ijscr.2011.11.007.
- [9] Clarke DL, Buccimazza I, Anderson FA, et al. Colorectal foreign bodies. *Colorectal Disease: The Official Journal of the Association of Coloproctology of Great Britain and Ireland*. 2005;7(1):98–103. DOI:10.1111/j.1463-1318.2004.00699.x.
- [10] Akhtar MA and Arora PK. Case of unusual foreign body in the rectum. *Saudi Journal of Gastroenterology: Official Journal of the Saudi Gastroenterology Association*. 2009;15(2):131–2. DOI:10.4103/1319-3767.48973.
- [11] Carp L. Foreign bodies in the intestine. *Annals of Surgery*. 1927;85(4):575–91.
- [12] Birk M, Bauerfeind P, Deprez PH, et al. Removal of foreign bodies in the upper gastrointestinal tract in adults: European Society of Gastrointestinal Endoscopy (ESGE) Clinical Guideline. *Endoscopy*. 2016;48:1–8. DOI:10.1055/s-0042-100456.
- [13] Butterworth J and Feltis B. Toy magnet ingestion in children: revising the algorithm. *Journal of Pediatric Surgery*. 2007;42(12):e3–5.
- [14] Control CfD and Prevention. Gastrointestinal injuries from magnet ingestion in children—United States, 2003–2006. *Morbidity and Mortality Weekly Report*. 2006;55(48):1296–1300.
- [15] Coskun A, Erkan N, Yakan S, et al. Management of rectal foreign bodies. *World Journal of Emergency Surgery*. 2013;8(1):11. DOI:10.1186/1749-7922-8-11.
- [16] Lancashire MJ, Legg PK, Lowe M, et al. Surgical aspects of international drug smuggling. *British Medical Journal*. 1988;296(6628):1035–7.
- [17] Kurer MA, Davey C, Khan S, et al. Colorectal foreign bodies: a systematic review. *Colorectal Disease: The Official Journal of the Association of Coloproctology of Great Britain and Ireland*. 2010;12(9):851–61. DOI:10.1111/j.1463-1318.2009.02109.x.
- [18] Goldberg JE and Steele SR. Rectal foreign bodies. *The Surgical Clinics of North America*. 2010;90(1):173–84. DOI:10.1016/j.suc.2009.10.004.
- [19] Losanoff JE and Kjossev KT. Rectal “oven mitt”: the importance of considering a serious underlying injury. *The Journal of Emergency Medicine*. 1999;17(1):31–3.
- [20] Ambe P, Weber SA, Schauer M, et al. Swallowed foreign bodies in adults. *Deutsches Arzteblatt International*. 2012;109(50):869–75. DOI:10.3238/arztebl.2012.0869.
- [21] Ridder GJ, Maier W, Kinzer S, et al. Descending necrotizing mediastinitis: contemporary trends in etiology, diagnosis, management, and outcome. *Annals of Surgery*. 2010;251(3):528–34. DOI:10.1097/SLA.0b013e3181c1b0d1.



- [22] Goh BK, Chow PK, Quah HM, et al. Perforation of the gastrointestinal tract secondary to ingestion of foreign bodies. *World Journal of Surgery*. 2006;30(3):372–7. DOI:10.1007/s00268-005-0490-2.
- [23] Wayman J. Benign ulceration of the stomach and duodenum and the complications of previous ulcer surgery. In: Michael Griffin S, Raimes SA, Shenfine J, editors. *Oesophagogastric Surgery: Companion to Specialist Surgical Practice*. 5th ed. China: Elsevier; 2014. p. 317–35.
- [24] Iwamuro M, Tanaka S, Shiode J, et al. Clinical characteristics and treatment outcomes of nineteen Japanese patients with gastrointestinal bezoars. *Internal Medicine*. 2014;53(11):1099–105.
- [25] Webb WA. Management of foreign bodies of the upper gastrointestinal tract: update. *Gastrointestinal Endoscopy*. 1995;41(1):39–51.
- [26] Ginsberg GG. Management of ingested foreign objects and food bolus impactions. *Gastrointestinal Endoscopy*. 1995;41(1):33–8.
- [27] Smith MT and Wong RK. Foreign bodies. *Gastrointestinal Endoscopy Clinics of North America*. 2007;17(2):361–82, vii. DOI:10.1016/j.giec.2007.03.002.
- [28] Donovan AJ, Berne TV and Donovan JA. Perforated duodenal ulcer: an alternative therapeutic plan. *Archives of Surgery*. 1998;133(11):1166–71.
- [29] Koornstra JJ and Weersma RK. Management of rectal foreign bodies: description of a new technique and clinical practice guidelines. *World Journal of Gastroenterology*. 2008;14(27):4403–6.
- [30] Obinwa O, Robertson I and Stokes M. Removal of a sex toy under general anaesthesia using a bimanual-technique and Magill's forceps: a case report. *International Journal of Surgery Case Reports*. 2015;15:96–8. DOI:10.1016/j.ijscr.2015.08.014.
- [31] Couch CJ, Tan EG and Watt AG. Rectal foreign bodies. *The Medical Journal of Australia*. 1986;144(10):512–5.
- [32] Graves RW, Allison EJ, Jr., Bass RR, et al. Anal eroticism: two unusual rectal foreign bodies and their removal. *Southern Medical Journal*. 1983;76(5):677–8.
- [33] Siroospour D and Dragstedt LR, 2nd. A large foreign body removed through the intact anus: report of a case. *Diseases of the Colon and Rectum*. 1975;18(7):616–9.
- [34] Ahmed A and Cummings SA. Novel endoscopic approach for removal of a rectal foreign body. *Gastrointestinal Endoscopy*. 1999;50(6):872–4.
- [35] Glaser J, Hack T and Rubsam M. Unusual rectal foreign body: treatment using argon-beam coagulation. *Endoscopy*. 1997;29(3):230–1. DOI:10.1055/s-2007-1004178.
- [36] Wolf L and Geraci K. Colonoscopic removal of balloons from the bowel. *Gastrointestinal Endoscopy*. 1977;24(1):41.

- [37] Peet TN. Removal of impacted rectal foreign body with obstetric forceps. *British Medical Journal*. 1976;1(6008):500–1.
- [38] Aquino MM and Turner JW. A simple technique for removing an impacted aerosol-can cap from the rectum. *Diseases of the Colon and Rectum*. 1986;29(10):675.
- [39] Clark SK and Karanjia ND. A cork in a bottle—a simple technique for removal of a rectal foreign body. *Annals of the Royal College of Surgeons of England*. 2003;85(4):282.
- [40] Hughes JP, Marice HP and Gathright JB, Jr. Method of removing a hollow object from the rectum. *Diseases of the Colon and Rectum*. 1976;19(1):44–5.
- [41] Manimaran N, Shorafa M and Eccersley J. Blow as well as pull: an innovative technique for dealing with a rectal foreign body. *Colorectal Disease: The Official Journal of the Association of Coloproctology of Great Britain and Ireland*. 2009;11(3):325–6. DOI: 10.1111/j.1463-1318.2008.01653.x.
- [42] Safioleas M, Stamatakis M, Safioleas C, et al. The management of patients with retained foreign bodies in the rectum: from surgeon with respect. *Acta Chirurgica Belgica*. 2009;109(3):352–5.
- [43] Yaman M, Deitel M, Burul CJ, et al. Foreign bodies in the rectum. *Canadian Journal of Surgery. Journal Canadien de Chirurgie*. 1993;36(2):173–7.
- [44] Diwan VS. Removal of 100-watt electric bulb from rectum. *Annals of Emergency Medicine*. 1982;11(11):643–4.
- [45] Feigelson S, Maun D, Silverberg D, et al. Removal of a large spherical foreign object from the rectum using an obstetric vacuum device: a case report. *The American Surgeon*. 2007;73(3):304–6.
- [46] Johnson SO and Hartranft TH. Nonsurgical removal of a rectal foreign body using a vacuum extractor. Report of a case. *Diseases of the Colon and Rectum*. 1996;39(8):935–7.
- [47] Mackinnon RP. Removing rectal foreign bodies: is the ventouse gender specific? *The Medical Journal of Australia*. 1998;169(11–12):670–1.
- [48] Lake JP, Essani R, Petrone P, et al. Management of retained colorectal foreign bodies: predictors of operative intervention. *Diseases of the Colon and Rectum*. 2004;47(10):1694–8.
- [49] Lim KJ, Kim JS, Kim BG, et al. Removal of rectal foreign bodies using tenaculum forceps under endoscopic assistance. *Intestinal Research*. 2015;13(4):355–9. DOI:10.5217/ir.2015.13.4.355.
- [50] Singaporewalla RM, Tan DE and Tan TK. Use of endoscopic snare to extract a large rectosigmoid foreign body with review of literature. *Surgical Laparoscopy, Endoscopy & Percutaneous Techniques*. 2007;17(2):145–8. DOI:10.1097/SLE.0b013e318045bf1a.

- [51] Berghoff KR and Franklin ME, Jr. Laparoscopic-assisted rectal foreign body removal: report of a case. *Diseases of the Colon and Rectum*. 2005;48(10):1975–7. DOI:10.1007/s10350-005-0117-6.
- [52] Yildiz SY, Kendirci M, Akbulut S, et al. Colorectal emergencies associated with penetrating or retained foreign bodies. *World Journal of Emergency Surgery*. 2013;8(1): 25. DOI:10.1186/1749-7922-8-25.
- [53] Demetriades D, Murray JA, Chan L, et al. Penetrating colon injuries requiring resection: diversion or primary anastomosis? An AAST prospective multicenter study. *The Journal of Trauma*. 2001;50(5):765–75.
- [54] Huang WC, Jiang JK, Wang HS, et al. Retained rectal foreign bodies. *Journal of the Chinese Medical Association*. 2003;66(10):607–12.
- [55] Ooi BS, Ho YH, Eu KW, et al. Management of anorectal foreign bodies: a cause of obscure anal pain. *The Australian and New Zealand Journal of Surgery*. 1998;68(12): 852-5.
- [56] Rodriguez-Hermosa JI, Codina-Cazador A, Ruiz B, et al. Management of foreign bodies in the rectum. *Colorectal Disease: The Official Journal of the Association of Coloproctology of Great Britain and Ireland*. 2007;9(6):543–8. DOI:10.1111/j.1463-1318.2006.01184.x.
- [57] Crass RA, Tranbaugh RF, Kudsk KA, et al. Colorectal foreign bodies and perforation. *American Journal of Surgery*. 1981;142(1):85–8.