

# We are IntechOpen, the world's leading publisher of Open Access books Built by scientists, for scientists

6,900

Open access books available

185,000

International authors and editors

200M

Downloads

Our authors are among the

154

Countries delivered to

TOP 1%

most cited scientists

12.2%

Contributors from top 500 universities



WEB OF SCIENCE™

Selection of our books indexed in the Book Citation Index  
in Web of Science™ Core Collection (BKCI)

Interested in publishing with us?  
Contact [book.department@intechopen.com](mailto:book.department@intechopen.com)

Numbers displayed above are based on latest data collected.  
For more information visit [www.intechopen.com](http://www.intechopen.com)



---

# Minimally Invasive Surgery for Treatment of Patients with Advanced Cancer and Thoraco-lumbar Spine Metastases

---

Massimo Miscusi, Stefano Forcato and  
Antonino Raco

Additional information is available at the end of the chapter

<http://dx.doi.org/10.5772/63125>

---

## Abstract

Spinal metastases are common in patients with cancer. Spinal cord compression is the initial symptom of 5–10% of patients with diffuse cancer, and about 70% of lesions are found in the thoracic vertebrae. Patients with advanced cancer are generally excluded from major spine surgery, to reduce postoperative morbidity and mortality. Minimally invasive spine surgery (MISS) has recently been advocated as a useful approach for spinal metastases, especially in advanced cancer patients, seeking to decrease the morbidity of more traditional open spine surgery; furthermore, reducing the recovery time, MISS permits the post-operative chemotherapy and radiotherapy to begin sooner.

A series of 29 cancer patients, with a short life expectancy, presenting acute myelopathy due to vertebral thoracic metastases, underwent MISS, with simple laminotomy and percutaneous stabilization; results from such series were compared to those retrospectively obtained from an homogenous series of patients operated with traditional open surgery.

No significant differences between two groups were demonstrated in terms of surgical complications and neurological recovery. Nevertheless, patients operated with MISS appear to have an earlier recovery and better quality of life in the immediate post-operative period, which is a fundamental aim for patients who have a short life expectancy.

**Keywords:** minimally invasive spine surgery, cancer, thoracic metastases, myelopathy, quality of life

---

## 1. Introduction

Spinal cord involvement due to vertebral metastases is a frequent complication in cancer patients and metastatic lesions of spine can significantly condition their quality of life, potentially producing untreatable pain, vertebral fractures, or even neurological deficit due to spinal cord or radicular involvement [1, 2]. Spinal metastases are likely to increase their incidence because patients with cancer today can live longer, due to early detection, as well as to improvements in cancer treatment and care [3]. These lesions should be considered and treated both medically or surgically to prevent undesired sequelae, and to preserve or, whenever possible, improve the quality of their residual life [4, 5].

The spine is the third most common site for cancer cells to metastasize, following the lungs and the liver. Almost 70% of cancer patients are expected to have spinal metastasis. In case of symptomatic lesions, the majority (60–70%) are found in the thoracic region, while of the remainder, 20% are found in the lumbar region, and 10% are found in the cervical spine. More than 50% of patients with spinal metastasis have more than one level involved [6, 7].

Surgery of spinal metastases cannot be curative, but only palliative, aimed to preserve or, whenever possible, improve quality of life for patients with short- or mid-term life expectancy. In such cases, surgery is indicated for the stabilization of involved segments, for spinal cord or root decompression, and for tissue diagnosis.

In the optic of reducing post-operative morbidity and accelerate the post-operative recovery, minimally invasive spine surgery (MISS) may represent the best option to achieve equivalent or superior outcomes to those of traditional open spine surgery, and to reduce the impact of surgery on critical patients with poor general and neurological conditions with short- or mid-term life expectancy.

## 2. Patients with advanced cancer and thoraco-lumbar spine metastases

### 2.1. Management and surgical indication

The evaluation of clinical general and neurological conditions of patients with advanced cancer and spinal metastases is performed with the Karnofsky performance scale (KPS) and the American Spinal Injury Association (ASIA) scores. Total spine MRI and total body CT scan is mandatory in order to update the stadium of the disease and to planning the most correct treatment.

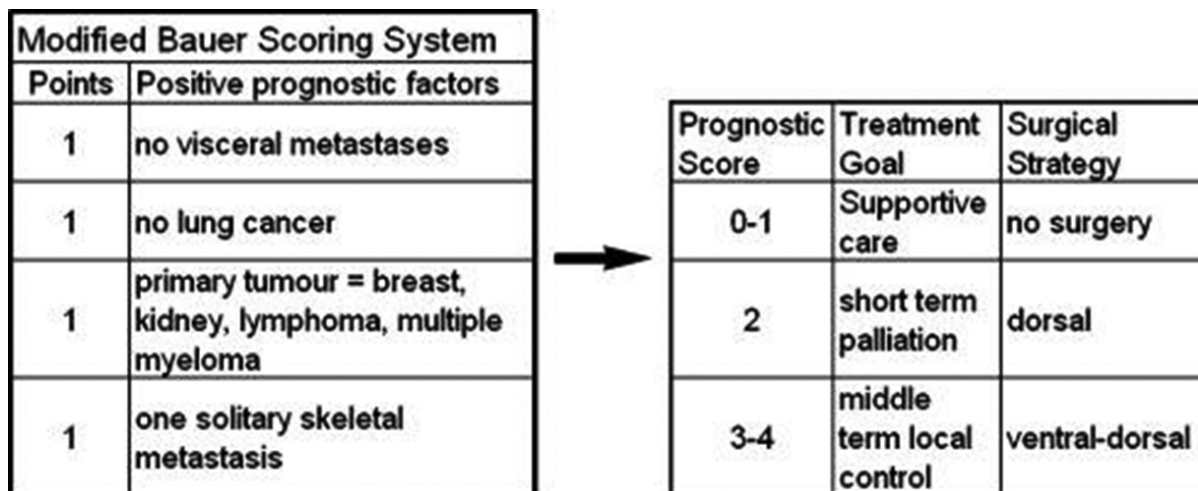
Approximately 90% of cancer patients with spinal metastases have bone and/or back pain, followed by radicular pain. Half of these patients have sensory and motor dysfunction, and more than half have bowel and bladder dysfunction. Five to 10% of cancer patients present with cord compression as their initial symptom; among these, 50% are non-ambulatory at diagnosis, and 15% are paraplegic [8].

The initial functional neurological score, evaluated with ASIA score, is the most important prognostic factor for the neurological recovery of patients undergoing surgery. Surgery, in the

majority of spinal metastasis cases, does not have a curative aim, but only palliative, to assure stability, pain control, and maintenance of neurologic integrity [3]. Surgery is also important to confirm the primary diagnosis, to debulk or remove the tumor mass for a more effective adjuvant therapy, and permit a patient’s mobilization.

The main indications for surgery in case of spinal metastases are the progressive neurologic deficit before, during, or after chemo- and radiotherapy, the intractable pain unresponsive to conservative treatment, the need for histological diagnosis, the treatment of radio-resistant tumor histology (e.g., RCC, melanoma), and to restore the spinal stability.

Numerous grading systems has been proposed, like the modified Bauer Scoring System (mBS), in order to give an indication to a conservative, palliative or more aggressive surgical treatment to a metastatic spine disease. The modified Bauer classification results equal or inferior then 3 points in case of patients with short- or mid-term life expectancy (**Figure 1**).



**Figure 1.** Modified Bauer Scoring System and the prognostic score.

To improve outcomes for patients with metastatic spine disease, many aggressive surgical strategies have been proposed. Nevertheless, an aggressive strategy is frequently associated with high morbidity and complication rates, and is not generally indicated in patients with poor general conditions and a limited life expectancy [9, 10].

These patients, in fact, often suffer from co-morbidities, malnourishment, diminished immunity, considerable pain, and they cannot face major surgery. Thus extensive surgical procedures or prolonged hospital stays are neither acceptable nor feasible in many of such patients.

Therefore, surgical risks must be weighed against life expectancy and quality of life, in order to justify standard surgical interventions.

## 2.2. The role of MISS

Recent advances in surgical techniques and percutaneous instrument placement have led to the development of minimally invasive approaches for the treatment of spinal metastases; these result in less post-operative pain, shorter overall hospital stays, less intra-operative blood loss, and an earlier start of adjuvant therapy [2, 11–14].

The reported advantages of these techniques include smaller incisions, which limit wound complications, and the avoidance of back muscles detachment and retraction that causes post-operative pain and profuse bleeding, thus, reducing the need of intra or post-operative blood transfusion. These advantages are crucial for maintaining and improving the quality of life of cancer patients with short- or mid-term life expectancy [15–17].

MISS technique has the aim to perform (1) percutaneous insertion of pedicle screws and rods; (2) small exposure and detachment of the para-spinal muscles, to avoid their denervation and devascularization; (3) a mini-open midline approach to decompress the spinal cord, reducing bleeding and post-operative pain.

Standard open techniques require the full exposure of the posterior elements of the involved segments, with complete exposure of facet joints, thus resulting in much more aggressive damage to the back muscles and soft tissues.

Our procedure is first based on the placement of purely percutaneous pedicle screws; using a double x-ray arch, a four-handed surgery was performed, in order to reduce the operation time and minimize the radiation exposure.

A mini-open median posterior approach to expose only spinous process and laminae of the involved segments is then performed. A laminotomy, without the removal of the spinous process, just in case it was not infiltrated, is performed; the posterior joints are not exposed and removed to reduce the muscle detachment and retraction (which produces an excessive bleeding).

The advantage of MISS techniques, in achieving an early better quality of life, seems to be related to their ability to reduce post-operative pain for both surgical-related and spinal metastasis-related components.

Criticism remains, regarding the reported difficulty of MISS to decompress enough spinal cord in case of spinal canal invasion; this persuasion is due to the erroneous conviction that the larger the surgical exposure, the better results achieved. On the contrary, in fact, MISS techniques permit an easy access to the spinal canal and complete spinal cord decompression and roots if needed.

## 2.3. Comparative study to traditional open surgery—materials and methods

Two series of cancer patients, with a mBS 1 or 2, presenting acute myelopathy due to vertebral thoracic metastases have been compared. The first group were composed of patients prospectively enrolled from May 2010 to December 2013 and treated with MISS procedures (MISS) (n=29); the second group was composed of retrospectively collected patients treated

with a traditional open surgery (OS) (n=25). Patients with complete neurological deficit (ASIA A) for more than 24 hours and a mBS >2 were excluded from present study.

For both groups (n = 48, 32 women and 16 men, with a mean age of 54.6 yrs), the primitive tumors were: lung cancer (n = 17, 35.4%), breast cancer (n = 15, 31.2%), myeloma (n = 4, 8.3%), clear cell renal carcinoma (n = 3, 6.2%), melanoma (n = 3, 6.2%), prostate cancer (n = 2, 4%), ovarian cancer (n = 1, 2%), and thyroid cancer (n = 1, 2%) (**Table 1**).

Group	OPEN	MISS	Total	p value
Demographic data				
Patients	19	29	48	
Sex ratio (M/F)	7:12	9:20	16:32	
Mean Age	51.74	57.60	54.65	
Clinical data				
Karnowsky	57.89%	55.36%	56.09%	0.94
Modified Bauer	2.6	2.3	2.4	0.135
Spinal metastases				
Single level	14 (73.6%)	18 (62.0%)	32 (66.6%)	
Two or more level	5 (26.3%)	11 (37.9%)	16 (33.3%)	
One column	10 (52.6%)	9 (31.0%)	19 (39.5%)	
Two or more column	9 (47.4%)	20 (68.9%)	29 (60.4%)	
Primary cancer				
Lung	8 (42%)	9 (31.0%)	17 (35.4%)	
Breast	6 (31.6%)	9 (31.0%)	15 (31.2%)	
Mieloma		4 (17.4%)	4 (8.3%)	
Kidney	2 (10.5%)	3 (10.3%)	3 (6.2%)	
Melanoma		3 (10.3%)	3 (6.2%)	
Prostate	2 (10.5%)		2 (4%)	
Ovary	1 (5.3%)		1 (2.0%)	
Thyroid		1 (3.4%)	1 (2.0%)	

**Table 1.** The clinical and oncological data of all the patients and divided by group.

Thirty two patients had one single level involved (66.6%), while 16 patients had a diseases extended to two or more segments (33.3%). In 19 patients (39.5%), the fracture involved a single column (OS: 52.6%, MISS: 31.0%), while two or three columns were substituted by cancer in 60.4% (**Table 1**).

The two groups were homogeneous, in terms of general and neurological conditions. All patients preoperatively presented an overall mean KPS of 56%, with 57.89 and 55.36% in the OS and MISS groups, respectively ( $p = 0.9$ ); the mean overall mBS was 2.4 (2.6 and 2.3 in the OS and MISS group, respectively,  $p = 0.18$ ) (**Table 1**). Pre- and post-operative ASIA scores for both groups are reported in **Table 2**.

Group		OPEN	MISS	Total	P value
ASIA					
Pre-op					
	A	3	3	6	
	B	2	4	6	
	C	6	9	15	
	D	8	13	21	
	E	0	0	0	
Post-op					
	Improved	12 (63%)	18 (62.0%)	30 (62.5%)	
	Stable	6 (31%)	9 (31.0%)	15 (31.2%)	
	Worse	1 (5%)	2 (6.7%)	3 (6.2%)	
P value				0.001	0.54
EORTC					
QLQ-C30					
QoL					
	Pre-op	16.00%	16.90%	16.60%	
	Post-op	25.80%	32.10%	28.90%	
P value				0.01	
Functional scales					
	Pre-op	59.10%	55.10%	57.10%	
	Post-op	72.60%	70.90%	71.70%	
P value				0.04	
Symptom scales					
	Pre-op	33.00%	34.10%	33.50%	
	Post-op	15.80%	15.10%	15.40%	
P value				0.009	
QLQ-BM22					
Functional scales b					
	Pre-op	75.15%	72.90%	74.00%	
	Post-op	79.80%	85.10%	82.45%	
P value				0.025	
Symptom scales b					



Group	OPEN	MISS	Total	P value
Pre-op	16.65%	18.10%	17.37%	
Post-op	8.20%	5.90%	7.05%	
P value			0.001	

**Table 2.** The pre-operative and post-operative neurological data (ASIA) and the quality of life data (EORTC QLQ-C30 and QLQ-BM22) of all the patients and divided by group.

The pre-operative neurological assessment showed a prevalence of ASIA D in both groups.

#### 2.4. Comparative study to traditional open surgery—results

Thirty patients (62.5%) showed an improvement of neurological status, while 15 patients were stable (31.2%), and only 3 patients (6.2%) worsened. No statistically significant differences in terms of neurological improvement were demonstrated between the two groups ( $p = 0.54$ ). The neurological conditions for only three patients (7.1%) (1 from the OS group, and 2 from the MISS group) worsened; these results were not due to surgical-related complications, but to bad general conditions.

Surgical and hospitalization data are given in **Table 3**.

Group	OPEN	MISS
Surgery data		
Operative time	3.2 h (2.5–4.5 h)	2.1 h (1.5–3 h)
Blood loss	900 ml (350–1500 ml)	140 ml (50–250 ml)
Hospitalization		
Blood supply	12 pts	0 pt
Complication	0 pt	1 pt
Post-op bed-rest	4 d (2–10 d)	2 d (1–3 d)
Discharge	9.25 d (5–14 d)	7.3 d (4–9 d)
Death	1 pt	0 pts
P value < 0.01		

**Table 3.** Surgical and hospitalization data divided by group.

There were no serious peri-operative complications, in the MISS group; only one patient developed a post-operative urinary infection. In the OS group, 1 patient died on the 14th post-operative day, due to metastatic hepatic failure. The mean operation length was 3.2 h and 2.1 h respectively in the OS group and in the MISS group ( $p < 0.01$ ).

The mean intra-operative blood loss was 900 mL in the OS group and 140 mL in the MISS group ( $p < 0.01$ ). Twelve patients in the OS group required post-operative RBC transfusions, while no one in the MISS group required additional blood supply. The mean post-operative



bed-rest time was 4 days with a mean length of hospitalization of 9.25 days in the OS group, while the mean post-operative bed-rest time was 2 days with a mean length of hospitalization of 7.3 days in the MISS group ( $p < 0.01$ ).

Pre-operative scoring for quality of life (QoL) was homogeneous in both groups, according to the EORTC QLQ-C30 and EORTC QLQ-BM22 scales (**Table 2**). At follow-up, the analysis of EORTC QLQ-C30 questionnaire showed a mean overall improvement of 12.3% in QoL score (OS: 9.8%, MISS: 15.2%,  $p = 0.01$ ), 14.6% in the functional scale score (OS: 13.5%, MISS: 15.8%,  $p = 0.04$ ), and 18.1% for the symptoms scale score (OS: 17.2%, MISS 19%,  $p = 0.009$ ). The evaluation of QLQ-BM22 scale showed a mean overall improvement at follow-up of 8.45% in the functional scale score (OS: 4.65%, MISS: 12.2%,  $p = 0.025$ ), and 10.32% in symptoms scale score (OS: 8.45%, MISS: 12.2%,  $p = 0.001$ ). The pre-operative VAS scores did not significantly differ between the groups ( $p > 0.015$ ) (**Table 4**).

Group	OPEN	MISS	Total
VAS			
Pre-op			
0–20	2	3	5
40	4	4	8
60	6	11	17
80	3	6	9
100	4	5	9
Post-op			
Improved	10 (53%)	21 (72%)	31 (65%)
Stable	7 (37%)	7 (24%)	14 (29%)
Worse	2 (10%)	1 (4%)	3 (6%)
P value			0.015
ANTALGIC			
Pre-op			
Ad lib.	2	3	5
NSAID	10	14	24
Morphine	7	12	19
Post-op			
Ad lib.	10	18	28
NSAID	4	8	12
Morphine	5	3	8
P value			0.01

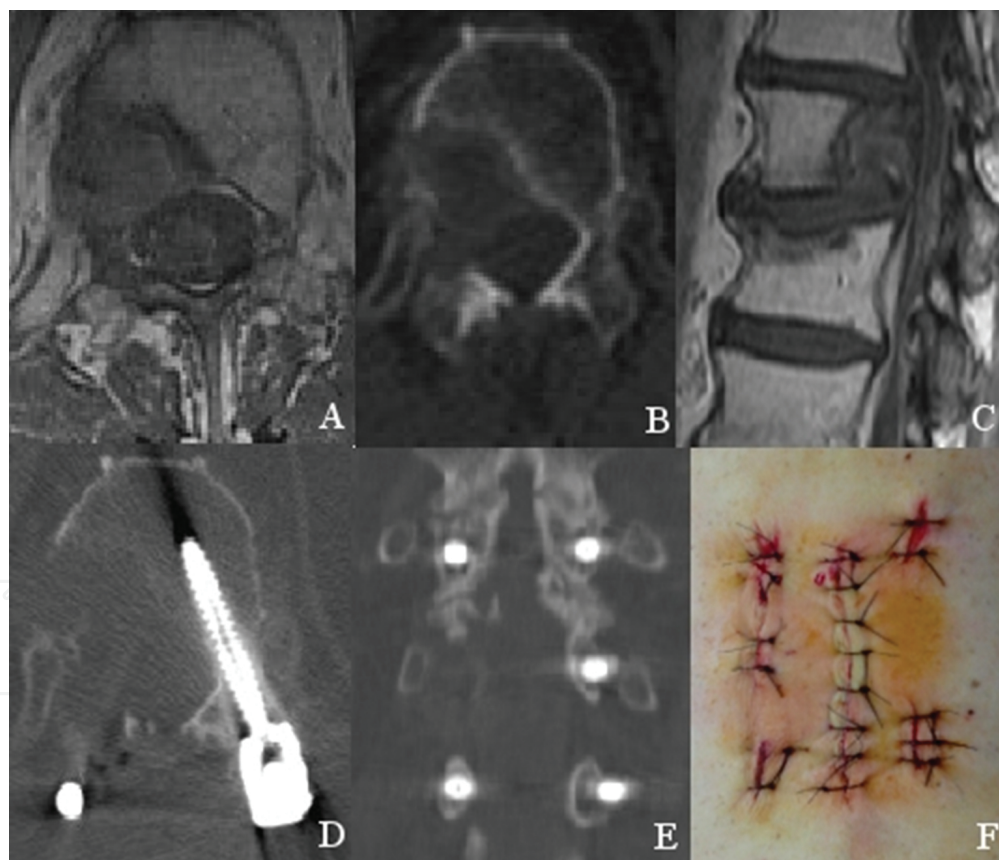
**Table 4.** The pre-operative and post-operative clinical data (VAS) and drug data (ANTALGIC) of all the patients and divided by group.

At follow-up, 31 patients (65%) showed an improvement of VAS score (OS: 53%, MISS: 72%), while 14 patients (29%) were stable (OS: 37%, MISS: 24%), and 3 patients (6%) worsened (OS: 10%, MISS: 4%) ( $p = 0.007$ ).

In the pre-operative period, five patients received ad libitum administration of antalgic drugs, and 28 patients received it at follow-up (OS: 10, MISS: 18). 24 patients were pre-operatively administered NSAIDs, while 12 patients received NSAIDs at follow-up (OS: 4, MISS: 8). Nineteen patients were pre-operatively administered morphine, while eight patients were administered morphine at follow-up (OS: 5, MISS: 3) ( $p = 0.01$ ).

## 2.5. Illustrative case 1

A 75-year-old with a two-year history of white cell renal carcinoma, already treated with chemo- and radio-therapy, presented with sudden leg weakness, hyper-reflexia, and urge-

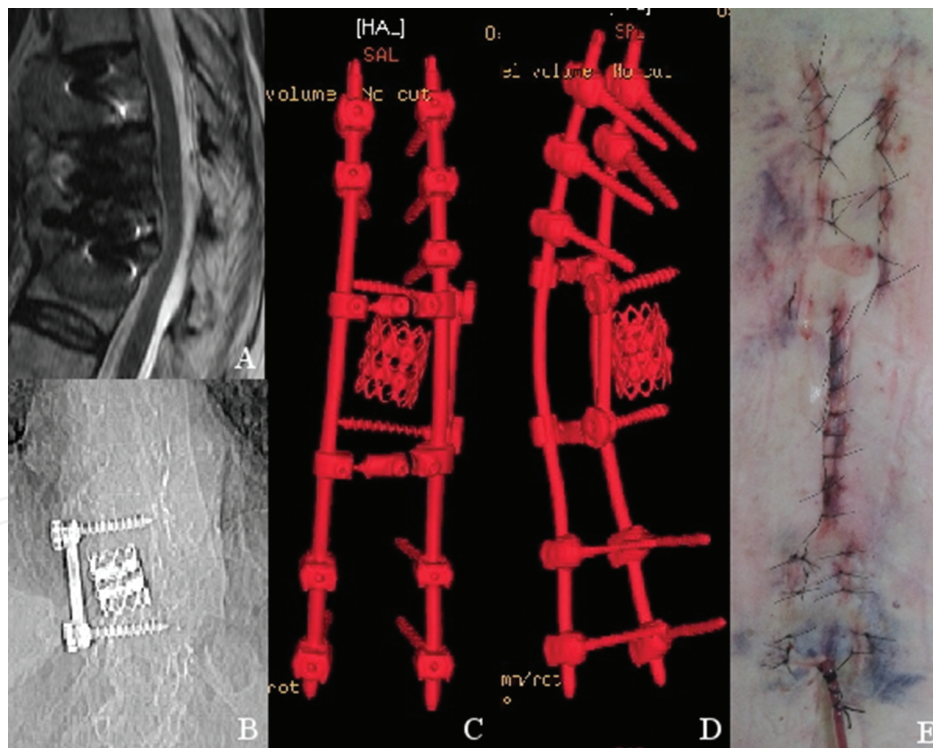


**Figure 2.** Clinical case #1. Pre-operative MRI axial, CT axial and MRI sagittal scan (A, B and C) showed an osteolytic lesion which substituted the T12 body and its right pedicle, with initial invasion of the spinal canal. In the D and E images it is shown the postoperative CT scan in the axial and coronal plane which documented the percutaneous short fixation with transpedicular screws at T11, L1, and at the left pedicle of T12, followed by a mini-open access, centered at the level of T12, with a decompressive right laminotomy. Skin incisions in the F image.

incontinence (ASIA C, KPS 60, mBS 2), after a one-month history of severe thoracic spinal pain (VAS 90/100), unresponsive to common analgesics. Imaging showed a lesion which substituted the T12 body and its right pedicle, with initial invasion of the spinal canal. He then underwent a pure percutaneous short fixation with transpedicular screws at T11, L1, and at the left pedicle of T12, followed by a mini-open access, centered at the level of T12, with a decompressive laminotomy.

The patient was mobilized in the first post-operative day, with an almost complete resolution of thoracic pain (VAS 20/100). Intraoperative blood loss was 200 cc, and RBC transfusion was not necessary. No opioids were administered in the post-operative period, and the patient was discharged on the fourth post-operative day. A post-operative CT scan showed the complete decompression of the spinal cord, with segmental fixation. At the follow-up, the patient presented a complete restoration of neurological deficit (ASIA E), and antalgic therapy with non-steroidal anti-inflammatory drugs (NSAID) was only administered ad libitum (Figure 2).

## 2.6. Illustrative case 2



**Figure 3.** Clinical case 2. Pre-operative MRI sagittal scan and coronal thoraco-lumbar X-ray (A and B images) showed diffuse spinal metastatic localizations with pathologic fractures of T9, T10 and T11, severe kyphosis and medullary compression in patient with a previous right partial T10 corpectomy with T9-T11 antero-lateral fixation. In the C and D images it is shown the postoperative CT scan 3D reconstruction which documented the percutaneous fixation with transpedicular screws at T7, T8, left pedicle of T9, L1 and L2, followed by a mini-open access, centered at the level of T10-T11, with a decompressive laminotomy and double cross-link. Skin incisions in the F image.

A 77-year-old woman, with a seven-year history of follicular thyroid cancer and previous lung and spine metastases that were treated with left inferior pulmonary lobectomy and right partial T10 corpectomy with T9-T11 antero-lateral fixation, respectively, came to our attention, having a new onset of severe thoraco-lumbar pain (VAS 90/100) with leg weakness (ASIA C). The free interval of disease was three years, after the conclusion of adjuvant chemo- and radio-therapy. Imaging showed diffuse spinal metastatic localizations with pathologic fractures of T9, T10 and T11; a severe kyphosis of the dorsal spine was evident. MRI results also showed spinal cord compression at T10-T11 levels, due to extradural metastatic tissue and progressive kyphosis (ASIA C, KPS 60, mBS 2).

The patient underwent a pure percutaneous fixation by transpedicular screws at T7, T8, L1 and L2, while at T9 only on the left pedicle was screwed; a mini-open access, centered at the level of T10-T11, was performed with decompressive laminotomy and positioning of two cross-links. The patient was mobilized in the first post-operative day. Intraoperative blood loss was only 350 cc. No opioids were administered in the post-operative period, and the patient was discharged on the eighth post-operative day. A CT scan, performed at the discharge, showed the complete decompression of the spinal cord and the final fixation. At follow up, the neurological conditions improved (ASIA D), and opioids were stopped, in order to start analgic therapy with NSAID (**Figure 3**).

## 2.7. Discussion

Results of our comparative study demonstrate that standard open techniques and the MISS techniques are equivalent, in terms of the ability to achieve an early neurological improvement in patients with acute myelopathy due to spinal cord compression. Nevertheless, MISS approach has a clear and significant advantage over standard open techniques, in terms of blood loss, operation length, and hospital stay; they also confirm its safety, with no patients presenting peri-operative surgical-related complications.

The study consisted of 48 patients with advanced cancer from different primary tumors, presenting a low Karnowsky score and acute myelopathy due to spinal-cord compression; All of them had low modified Bauer scores, which indicate only a short or middle term surgical palliation through posterior decompression and spinal segmental fixation [18]. Surgery was instrumented in all patients, to treat a preoperative instability or to prevent post-surgical instability. A gross total or complete resection of metastases was never attempted because clearly not indicated for any of the patients in the series.

According to the biological behavior of the lesion (i.e., osteolytic or osteoblastic), the number of segments involved, and the columns involved for each segment, the implant for fixation was as shortest as possible, and, in cases where the lesion was partially invading the vertebra, pedicle screws are also inserted in the fractured vertebrae.

We have been interested in comparing the quality of life at an early follow-up, since, in patients with advanced metastatic cancer, the late follow-up is generally conditioned by the progression of the primary disease, and this can produce a bias when evaluating the surgical results for neurological restoration alone or the quality of life. Considering an equivalent neurologi-



cal recovery, at 30 days follow-up, patients in the MISS group presented a better outcome in terms of quality of life: in our opinion this is the final aim of surgical treatment in case of patients with short- to mid-term life expectancy.

Interestingly some patients of our series aged over 60 years presented an early worsening of neurological symptoms, confirming that age is a key prognostic factor which must to be considered before choosing the surgical strategy in treating advanced cancer patients.

Finally, MISS seem to significantly reduce the post-operative pain. In fact, in our series, VAS reduced and the need for opioids was significantly lower in patients of the MISS group. The reduction in opioids administration improves the quality of life of such patients, avoiding severe constipation or alterations in consciousness.

In our experience, metastatic patients operated with MISS techniques, compared to those operated with traditional open surgery techniques, presented a significant improvement in term of blood loss, operation time, and bed rest length, which is associated to a more rapid functional recovery and discharge from hospital. The post-operative pain and the need of opioids administration were also significantly less pronounced, and these effects appear to translate to a better quality of life of such patients, which is a primary aim in case of patient with a short life expectancy.

## Author details

Massimo Miscusi<sup>1\*</sup>, Stefano Forcato<sup>2</sup> and Antonino Raco<sup>3</sup>

\*Address all correspondence to: massimo.miscusi@uniroma1.it

1 Department of Medico-Surgical Sciences and Biotechnologies, Sapienza University of Rome, Italy

2 Department NESMOS, Sapienza University of Rome, Italy

3 Department NESMOS, Sapienza University of Rome, Full Professor of Neurosurgery, Italy

## References

- [1] Ibrahim A, Crockard A, Antonietti P, Boriani S, Bünger C, Gasbarrini A, et al. Does spinal surgery improve the quality of life for those with extradural (spinal) osseous metastases? An international multicenter prospective observational study of 223 patients. Invited submission from the joint section meeting on disorders of the spine and peripheral nerves, March 2007. *J Neurosurg Spine*. 2008;8:271–278.

- [2] Ofluoglu O. Minimally invasive management of spinal metastases. *Orthop Clin North Am.* 2009;40:155–168.
- [3] Bhatt AD, Schuler JC, Boakye M, Woo SY. Current and emerging concepts in non-invasive and minimally invasive management of spine metastasis. *Cancer Treat Rev.* 2013;39:142–152. DOI: 10.1016/j.ctrv.2012.08.002.
- [4] Weber MH, Burch S, Buckley J, Schmidt MH, Fehlings MG, Vrionis FD, et al. Instability and impending instability of the thoracolumbar spine in patients with spinal metastases: a systematic review. *Int J Oncol.* 2011;38:5–12.
- [5] Winstead ER. After treatment: the needs of cancer survivors. *NCI Cancer Bull.* 2005;2:1–2.
- [6] Rose PS, Buchowski JM. Metastatic disease in the thoracic and lumbar spine: evaluation and management. *J Am Acad Orthop Surg.* 2011;19:37–48.
- [7] Zairi F, Marinho P, Allaoui M, Assaker R. New advances in the management of thoracolumbar spine metastasis. *Bull Cancer.* 2013;100:435–441. DOI: 10.1684/bdc.2013.1748.
- [8] Chow E, Nguyen J, Zhang L, Tseng LM, Hou MF, Fairchild A, et al. International field testing of the reliability and validity of the EORTC QLQ-BM22 module to assess health-related quality of life in patients with bone metastases. *Cancer.* 2012;118:1457–65.
- [9] Harel R, Angelov L. Spine metastases: current treatments and future directions. *Eur J Cancer.* 2010;46:2696–2707. DOI: 10.1016/j.ejca.2010.04.025.
- [10] Miscusi M, Domenicucci M, Polli FM, Forcato S, De Giorgio F, Raco A. Spondylectomy of T-2 according to the Tomita technique via an extended Fessler approach: a cadaveric study. *J Neurosurg Spine.* 2011;16:22–26. DOI: 10.3171/2011.9.SPINE10834.
- [11] Huang TJ, Hsu RW, Li YY, Cheng CC. Minimal access spinal surgery (MASS) in treating thoracic spine metastasis. *Spine.* 2006;31:1860–1863.
- [12] Logroscino CA, Proietti L, Tamburrelli FC. Minimally invasive spine stabilisation with long implants. *Eur Spine J.* 2009;18:75–81.
- [13] McLain RF, Lieberman IH. Endoscopic approaches to metastatic thoracic disease. *Spine.* 2000;25:1855–1858.
- [14] Rosenthal D, Marquardt G, Lorenz R, Nichtweiss M. Anterior decompression and stabilization using a microsurgical endoscopic technique for metastatic tumors of the thoracic spine. *J Neurosurg.* 1996;84:565–572.
- [15] Hsieh PC, Koski TR, Sciubba DM, Moller DJ, O'Shaughnessy BA, Li KW, et al. Maximizing the potential of minimally invasive spine surgery in complex spinal disorders. *Neurosurg Focus.* 2008;25:E19.

- [16] Kan P, Schmidt MH. Minimally invasive thoracoscopic approach for anterior decompression and stabilization of metastatic spine disease. *Neurosurg Focus*. 2008;25:E8.
- [17] Mobbs RJ, Sivabalan P, Li J. Technique, challenges and indications for percutaneous pedicle screw fixation. *J Clin Neurosci*. 2011;18:741–749. DOI: 10.1016/j.jocn.2010.09.019.
- [18] Leithner A, Radl R, Gruber G, Hohegger M, Leithner K, Welkerling H, et al. Predictive value of seven preoperative prognostic scoring systems for spinal metastases. *Eur Spine J*. 2008;17:1488–1495.