

# We are IntechOpen, the world's leading publisher of Open Access books Built by scientists, for scientists

6,900

Open access books available

186,000

International authors and editors

200M

Downloads

Our authors are among the

154

Countries delivered to

TOP 1%

most cited scientists

12.2%

Contributors from top 500 universities



WEB OF SCIENCE™

Selection of our books indexed in the Book Citation Index  
in Web of Science™ Core Collection (BKCI)

Interested in publishing with us?  
Contact [book.department@intechopen.com](mailto:book.department@intechopen.com)

Numbers displayed above are based on latest data collected.  
For more information visit [www.intechopen.com](http://www.intechopen.com)



---

## Facelift: Current Concepts, Techniques, and Principles

---

Fereydoun Pourdanesh,  
Mohammad Esmaeelinejad,  
Seyed Mehrshad Jafari and Zahra Nematollahi

Additional information is available at the end of the chapter

<http://dx.doi.org/10.5772/63150>

---

### Abstract

The effects of aging on skin, including thinning and loss of muscle tone, result in a flabby or drooping appearance of the face. The demands of an attractive appearance and smooth skin are wanted all around the world. There are a lot of factors which influence the choice of rejuvenation techniques, including anatomy of the facial skeleton, the severity of aging changes, social and economic status of the patient, and structure of the skin. Facelifting is a facial rejuvenation procedure in which by dissection of subcutaneous layers and different suturing techniques we are able to stretch the skin and make the patient look younger. This chapter presents the technique, current concepts, complications, and indications of facelift surgery.

**Keywords:** aging, lifting, rhytidectomy, rhytidoplasty

---

### 1. Introduction

**Facelifting**, also known as a **rhytidectomy**, technically means removal of wrinkles by surgery to give a more youthful appearance to the face. Although the history of this surgery goes back to more than one hundred years ago, in recent decades it has become more popular because demands of being youthful in middle and senile ages have increased among people. Due to contemporary improvements in medical care and increased common knowledge about the importance of healthcare, the life-span of people all around the world, especially in the first world countries, has been significantly increased. As a result, the common problems associated with senility have gained more attention.

One of the main concerns is facial rejuvenation of wrinkles.

**A wrinkle or rhytide** is a crease in the skin. Skin wrinkles typically appear as a result of aging processes such as glycation<sup>1</sup>. There are other factors such as age spots, sun ray effects, tissue sagging, and volume loss, which may also lead to an aged face. The major role of each factor depends on the skin type of the patient. Sagging or drooping is more prominent in patients with thick skin whereas patients with thin skin usually manifest aging with wrinkles and volume loss.

Asian people have thicker skins than Caucasians; therefore, their chief problem is tissue drooping and have less wrinkles in their face. Due to their relatively thick skin, the weight of their tissue is considerably more than other groups and performing facelift surgery is more difficult. Wrinkles begin to form in the early 30s. They usually start in anatomic regions with the thinnest skin such as the periorbital area. As the body gets older, skin and subcutaneous fat loses its volume and the collagen and elastic fibers lose their elasticity, which results in superficial wrinkles.

This chapter briefly explains different approaches of facelifting as well as indications, advantages, and disadvantages of various modifications of facelift surgery, complications, and post-operative care.

## 2. History of facelift surgery

In early 1900, Hollander introduced the basic facelift surgery which only involved removal of excessive tissue along the hairline. In 1920, surgeons undermined the subcutaneous layer, which became the preferred technique. This method improved skin laxity, but it was unable to address the underlying soft tissues ptosis. Surgeons found that increased skin redundancy is not the only factor involved in aging processes and there are other factors such as ptosis of the deep soft tissues, skeletal deformities, and changes in skin texture which play a significant role.

In 1974, Skoog developed a technique which elevated a subdermal flap in continuity with the subplatysmal plane in the neck in order to address the deeper tissues. The skin and platysma muscle were elevated together as a unit to develop a more youthful jawline for the patient. Although Skoog's technique did not gain acceptance, it was a turning point in facelift surgery.

In 1976, Mitz and Peyronie defined the superficial musculoaponeurotic system (SMAS) [1]. In the late 1980s and early 1990s, based on Skoog's technique, Hamra introduced the deep plane rhytidectomy followed by composite facelift in order to improve the periorbital and nasolabial regions [2]. Owsley made this technique even better by describing the malar fat pad dissection and suspension to improve the nasolabial crease [3]. Ramirez introduced the subperiosteal rhytidectomy technique to improve the cheek, forehead, jowls, lateral canthus, and eyebrows [4].

---

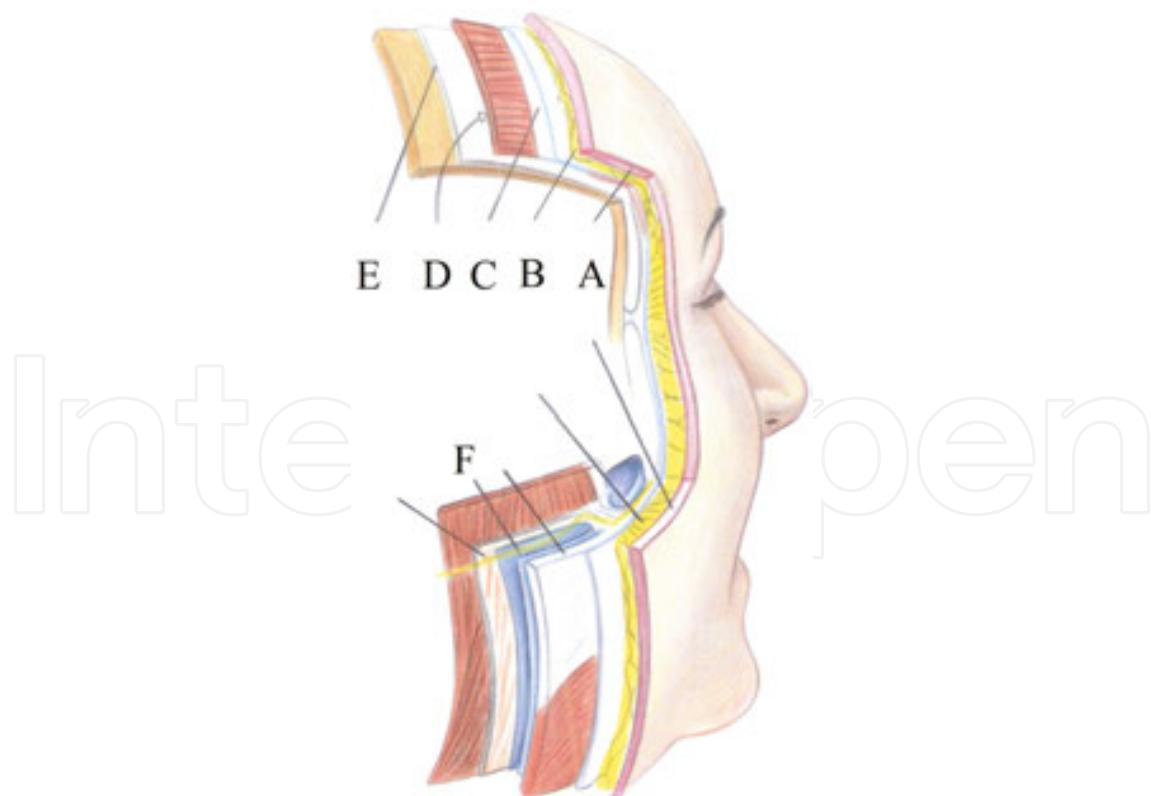
<sup>1</sup> Non-enzymatic glycosylation is the result of typically covalent bonding of a protein or lipid molecule with a sugar molecule, such as glucose, without the controlling action of an enzyme.

There have been a lot of comparisons between the risks and benefits of these methods. Less invasive methods which only included the superficial plane dissection showed decreased risk, reduced complications, lower morbidity, decreased convalescence, and more patient satisfaction.

More invasive methods, which included deeper plane dissections, showed more stable long-term results, better control of the midface and similar risks and complication rates as less invasive techniques. During the past decade, surgeons tend to reduce the complexity of facelift procedure and patients demanded less invasive and less complicated surgeries. Nowadays, due to younger age of facelift procedure, less invasive methods such as endoscopic technique, minimal incision facelift surgery and suspension sutures have gained popularity.

### 3. Facelift anatomy

Any surgeon who wants to perform a facelift procedure must know the anatomy of the face. The first layer in facelift anatomy is the skin. The dermal plexus of blood vessels is responsible for the skin and facelift flap blood supply. Usually, fat is left adherent to the dermal under surface of the flap to enhance its viability.



**Figure 1.** Anatomy of layers of the face. (A) Skin; (B) subcutaneous; (C) SMAS; (D) retaining ligaments; (E) deep fascia; (F) nerve.

The next layer is the subcutaneous layer. The fat in this layer is in close contact with deeper SMAS and superficial dermis. This layer can be safely undermined without damaging the anatomic structures. The subcutaneous layer has different thicknesses based on the location and patient. It becomes thickened over the malar region and is attached to it by ligaments running from the underlying periosteum through the malar pad and insert into the dermis. This area, also referred to as McGregor's patch, provides resistance when dissecting because of its fibrous nature.

The third layer is the SMAS layer. This layer separates the subcutaneous fat from the parotid-masseteric fascia and facial nerve branches. The SMAS layer is continuous with the galea in the scalp, the temporoparietal fascia in the temples, and the superior cervical fascia in the neck. SMAS is continuous with the platysma and separates two layers of fat in the face into superficial and deep layers. All of the facial muscle motor nerves are deep to this plane (**Figure 1**). When this layer is stretched or pulled, it moves the entire lateral face in the desired vector. In theory, this would allow the face to move more as a unit, thus making expression more efficient.

The fourth surgical plane is the sub-SMAS plane. It contains the facial nerve motor branches and the parotid duct. The parotidomasseteric fascia is the layer over the parotid gland and masseter muscle. By operating superior to this layer, the facial nerve branches are protected. Just as the SMAS is an extension of the superficial cervical fascia, parotidomasseteric fascia is also an extension of the superficial layer of the deep cervical fascia into the face and the deep temporal fascia above the zygomatic arch. By deeper and more anterior dissection beneath this layer, the chance of injury to the facial nerve branches increases.

There is a sub-SMAS loose areolar tissue plane extending from the anterior border of the parotid to the anterior border of the masseter. Blunt dissection in this plane gives the deep plane facelift (DPFL) dissection the ability to proceed safely even though it is almost intimate with the underlying facial nerve branches.

As the facial nerve branches move further anteriorly, they pass over the buccal fat pad and innervate the mimetic muscles. Facial nerve branches, parotid duct, buccal fat pad, and facial artery and vein are all part of the plane under the parotidomasseteric fascia. Dissection over the parotid gland must be done with great caution because although it is a safe plane, it may damage the facial nerve branches as they course out of the parotid gland and cross the masseter muscle.

Several other structures may be damaged in a routine facelift procedure. The greater auricular nerve and external jugular vein are in close contact with sternocleidomastoid muscle. The greater auricular nerve innervates the earlobe and cheek. These two are always superficial to the SMAS layer; hence, dissecting in the subcutaneous layer may preserve these structures.

#### **4. Patient selection and evaluation**

As any other cosmetic procedure, patient evaluation and selection are very important in the whole treatment plan. The surgeon should keep in mind that failing to plan is planning to fail.

During the asking of chief complaint and taking case history, evaluation of psychological aspect of the patient must be done carefully. Never treat a SIMON<sup>2</sup> patient.

At first, the surgeon and the patient must have complete understanding of the procedure and the risk and benefits. Second of all, the surgeon must know the chief complaint of the patient. Next, a thorough medical and habitual history must be taken from the patient. Some drugs such as isotretinoin and vitamin E have adverse effects on healing and must be noted in the patient's history. Vitamin E supplements and NSAIDs or aspirin should be avoided at least 2 weeks before the surgery. Smoking and alcohol consumption can further delay the healing period and increase the skin flap necrosis. The patient must be persuaded to quit smoking 2 months before surgery.

Areas such as the jowls, prominent bands in the platysma, and a collection of submental fat are the most improved areas in facelift procedure. Thorough examination of these regions gives valuable clues about the treatment plan.

The face is divided into thirds. The upper third consists of the forehead and upper and lower eyelids, which are not typically addressed in superficial plane rhytidectomy. The middle third includes ears and cheeks. The surgeon must assess the amount of skin laxity in this region. The initial position of the earlobe must be noted because there may be a displacement after closure. The lower third includes chin, jawline, and neck [5].

Dedo classified neck profiles into the following subtypes [6]:

- Class 1: No submental fat, good muscle tone, and a well-defined cervicomental angle.
- Class 2: Cervical skin laxity and an obtuse cervicomental angle.
- Class 3: Submental fat accumulation; may require submental lipectomy.
- Class 4: Platysmal muscle banding.
- Class 5: Retrognathia and/or microgenia.
- Class 6: Demonstrating a low hyoid.

Based on this classification, the surgeon chooses the best treatment modality possible. In some cases, facelift surgery alone is not enough for attaining proper results, so other resurfacing procedures must be discussed with the patient that might be needed in future. Good marking of the patient's face and neck in upright position before scheduling for anesthesia has an important role in facelift surgery.

#### **4.1. Indications for facelift surgery**

The appearance of wrinkles, folds, and creases on an individual's face is the primary basis for a surgeon to agree to the operation. Skin drooping of the cheeks and jowls are among the factors indicating a person as a prime candidate for the facelift procedure. Other factors include

---

<sup>2</sup> Single, immature, male, overly expectant, narcissistic is a patient with excessive concern of their surgery and usually exaggerates a minor physical defect.



predominant eye bags, folds in the eye area (crow's feet and laugh lines), and a permanent crease above the bridge of the nasal region and folds in the forehead. Ideally, the patient should be around the age of fifty or below. Above this age may not be ideal anymore, because the work may be more extensive than for younger individuals. This means that more surgeries may be needed.

Another indication for rhytidectomy is the state of skin in the surgical site. Sun exposure is one of the main reasons of wrinkles. The sun basically makes the skin look older and constant exposure of skin to sun exacerbates this matter. Facelift can rejuvenate patients. It is important to remember that normal looking appearance is one of the primary goals after this kind of surgery.

#### **4.2. Contraindications of facelift surgery**

Relative contraindications are poor medical health, patients who continuously consume blood-thinning medications, patients with unrealistic expectations, and heavy smokers. Fine wrinkles which can be managed by nonsurgical or conservative treatment very well are contraindications of facelift surgery. Secondary facelifts should also be done with caution because the scar from the primary procedure may disrupt the original tissue planes and increase the risk of facial nerve damage.

### **5. Facelift techniques**

#### **5.1. Subcutaneous facelift**

##### *5.1.1. Procedure*

Subcutaneous facelift or skin-only facelift was initially the major concept of the facelift procedure. Lexer presented skin-only facelift as a procedure in which the dissection is in a subcutaneous plane [7]. Subcutaneous dissection is needed in this technique so that muscular structure and SMAS remain intact. Facelift in this technique is consisted mainly of skin excision with primary closure. This method was the most popular modification of facelift for a long time. Although the role of subcutaneous facelift has diminished after deep layer (i.e., SMAS layer) was presented, the skin-only facelift is still suggested in selected patients.

This procedure is indicated in thin women with good facial skeleton as well as appropriate skin tone. Actually, this technique is suitable when the surgeon needs to only reduce the facial skin excess. Previous facelift surgery with SMAS plication is an indication for subcutaneous facelift procedure. The results of skin-only facelift are limited because of not addressing other senile facial structures. This technique is contraindicated in obese patients, especially with a non-ideal facial skeleton. Besides, this procedure is not appropriate in elderlies with severe aging changes and sagging of deep facial structures [8]. It is also important to consider that excessive subcutaneous dissection medially especially in smokers make the skin flap at the risk of ischemia [9].

### 5.1.2. *Advantages*

This procedure is very simple and suitable for beginners. The dissection plane is above the SMAS layer which contains the facial nerve, so it decreases the risk of nerve injury in this technique. This procedure is associated with good recovery and is an appropriate technique in secondary facelift and after that [10]. The complications of this method are not significantly higher than other DPFL [10, 11].

### 5.1.3. *Disadvantages*

The long-term results of skin-only facelifts are not very good. This is a major concern for surgeons. This issue results from two reasons. First, skin viscoelasticity property causes loosening of tightened skin after a while [12]. Second, intact subcutaneous tissues are susceptible to ptosis after a period of time because they are not manipulated in this technique.

## 5.2. SMAS plication facelift

### 5.2.1. *Procedure*

Introducing and describing SMAS by Mitz changed the concepts of facelift [1]. This technique was suggested as a new method to manipulate the subcutaneous tissues to solve the senile changes of the face including skin wrinkles and deep soft tissue sagging simultaneously. The fibro-fatty composition of SMAS layer gives it greater strength against gravity than skin. The concept of SMAS plication technique was manipulating a stronger layer which can bear more loads than skin.

The dissection plane in this technique is supra-SMAS. After dissecting in the subcutaneous plane, SMAS layer is exposed. The mobile segment of SMAS layer is fixed to the posterior relatively immobile layer (i.e., parotidomasseteric fascia) by mainly three sutures in a vertical direction. The excess of SMAS layer could be trimmed after suturing to prevent bulging. This technique is indicated in middle-aged patients with thin skins and moderate to severe laxity. Obese patients with thick skin types are not candidates for this technique.

### 5.2.2. *Advantages*

SMAS plication seems to be an easy procedure with little risk for facial nerve damage. Despite manipulation of SMAS layer, the dissection plane is above this layer and the facial nerve plane which let this method to be a relatively safe procedure. The surgery time is short and the recovery would be good in this technique. This technique may have a better esthetic result in midface area than DPFL [13]. On the other hand, the surgeon may be able to manipulate skin movements by SMAS plication procedure comparing to MACS lift and less invasive than sub-SMAS procedures [14, 15].



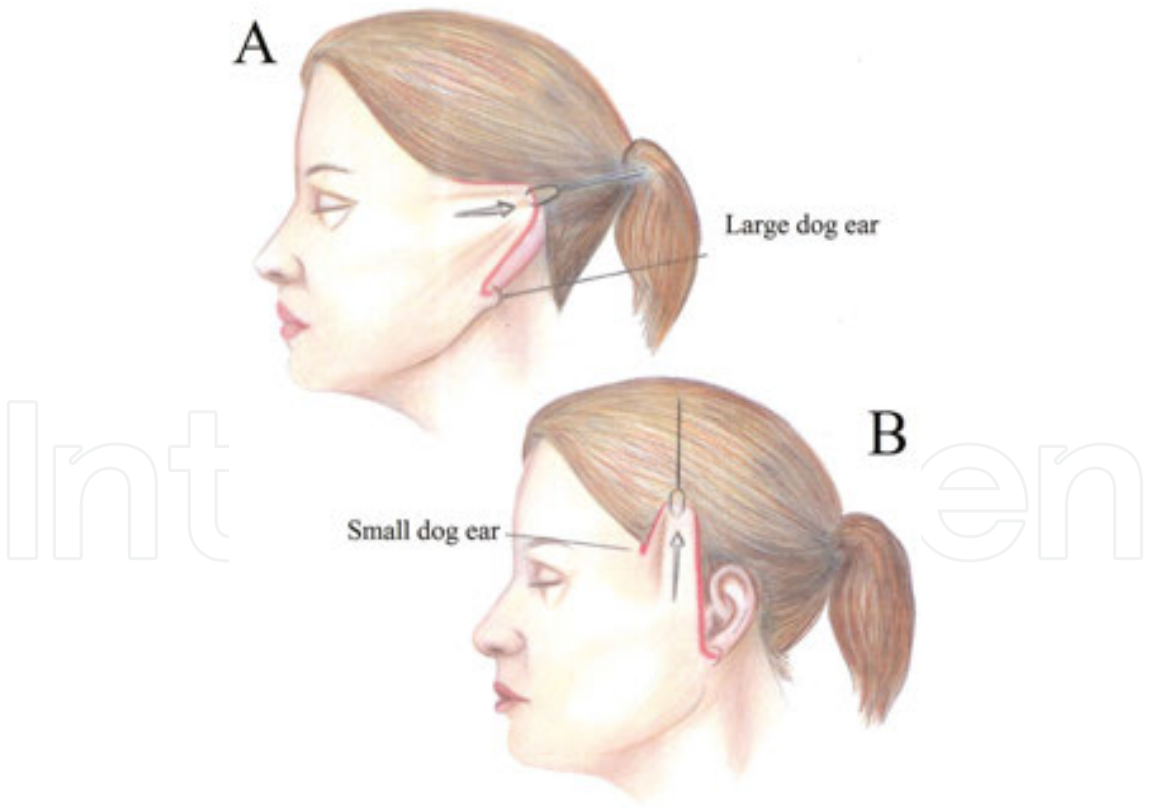
5.2.3. Disadvantages

Resolving neck aging is more difficult by this technique than DPFL. This issue is related to the inadequate release of platysma facial attachments [16]. SMAS plication is more invasive than some other lifting methods such as MACS lift [14]. The surgeon is not able to manipulate deeply positioned soft tissues under SMAS layer, which results in relatively short-term outcomes comparing to DPFLs.

5.3. Minimal access cranial suspension (MACS) lift

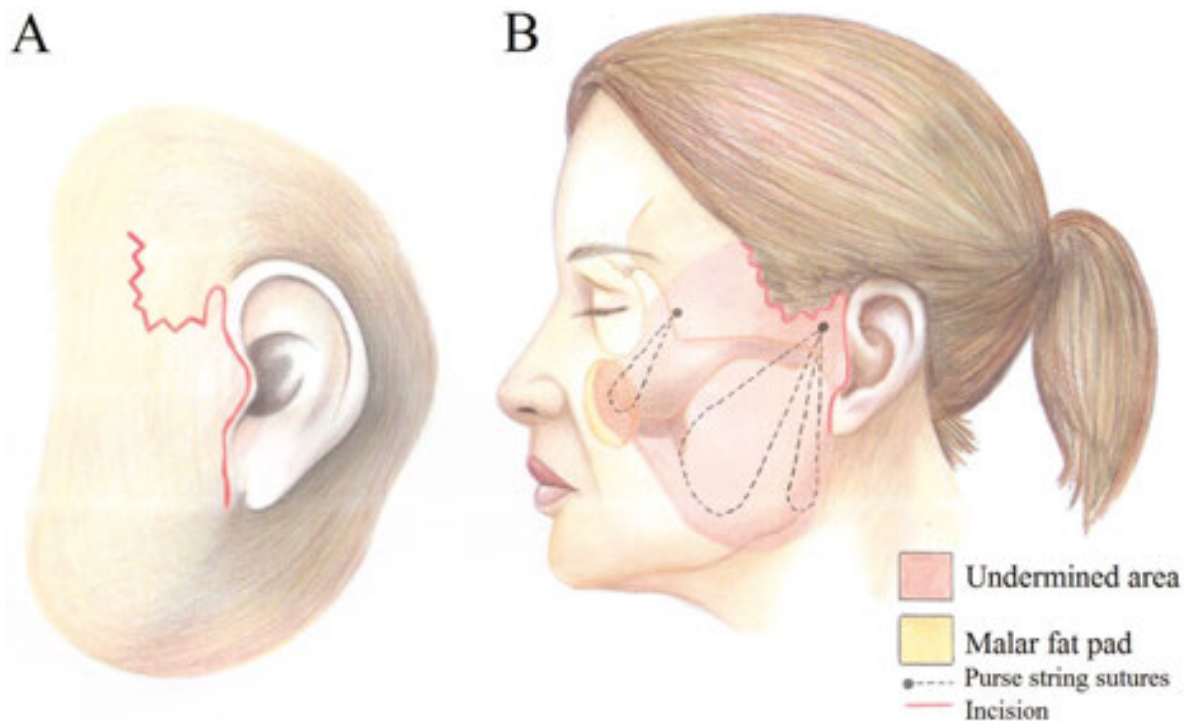
5.3.1. Procedure

The main concept of MACS lift was the difference in vector of traction. The skin is re-draped in an oblique direction in traditional face lifting. In MACS procedure, the horizontal vector of traction is avoided and skins simultaneously with under soft tissues are moved vertically [17] (Figure 2). MACS procedure is mainly divided into two types: simple and extended. The simple variation of MACS technique is used to correct the lower third of the face and aging appearance of the neck including jowling and the cervicomental angle by using two purse-string sutures. Extended MACS lift was presented to correct nasolabial groove and midface and lower eyelid senile changes [18]. The incision in the latter form of MACS technique is



**Figure 2.** (A) The wrong direction of facelifting forms a large dog ear under the ear lobe. (B) The correct direction of lifting in MACS technique omits the dog ear.

extended along the temporal hairline and a third purse-string suture is used to suspend the malar fat pad (**Figure 3**).



**Figure 3.** (A) Incision line in MACS technique. (B) Undermining area in MACS technique.

Submental liposuction is performed before starting MACS lift. The incision is made from lower limit of the lobule going through the pre-auricular crease upwards. The upper limits of the incisions in simple and extended variations are at the level of the lateral canthus and the level of the tail of the eyebrow, respectively. This procedure is performed in the pre-SMAS plane above the plane of facial nerve path. Dissection is performed two fingers below the angle of mandible. The purse-string sutures are used to fix the deep temporal fascia in the simple variation. In the extended variation, the third u-shaped purse-string suture is placed between the anterior part of the deep temporal fascia and the malar fat pad. The skin is excised after re-draping in a vertical direction.

### 5.3.2. Advantages

There are several advantages of MACS procedure suggested in the literature. Small skin incisions and limited subcutaneous dissection are the major advantages of this technique. The risk of facial nerve damage is low due to supra-SMAS dissection. The results are good and the recovery is rapid in this technique. The surgeon is able to re-drape the skin of the lower third of the face, correct the senile changes of the neck, and correct the cervicomental angle [19].

The MACS lift is a shorter procedure than SMAS imbrication with high patient satisfaction and low morbidity. The short incision in MACS lift is a major advantage in this technique,

especially in young patients. Avoiding the postauricular incision in this method makes this procedure acceptable in young patients who usually pull their hair up. The risk of hematoma is low in this technique. Besides, hematoma is easily evacuated and usually does not track into the neck. The dog ear formation under the ear lobe is prevented in this technique, owing to the vector of traction [20].

### 5.3.3. *Disadvantages*

The limitations of MACS lift procedure are mainly associated with the anatomy of the patient. The results of this technique are not very good in patients with a bulky neck and significant skin laxity [21]. The final neck contour is unsatisfactory in bulky neck patients due to limited skin excision and pure vertical vector of skin re-draping. The improvement would be less optimal in the latter group. There is a chance of skin flap irregularity regarding to the excessive bunching of the purse-string sutures. Avoiding the ligamentous lysis in this technique prevents the long-term results of MACS lift, especially if the sutures pull through. The cheese wiring effect is also more probable in this facelift modification.

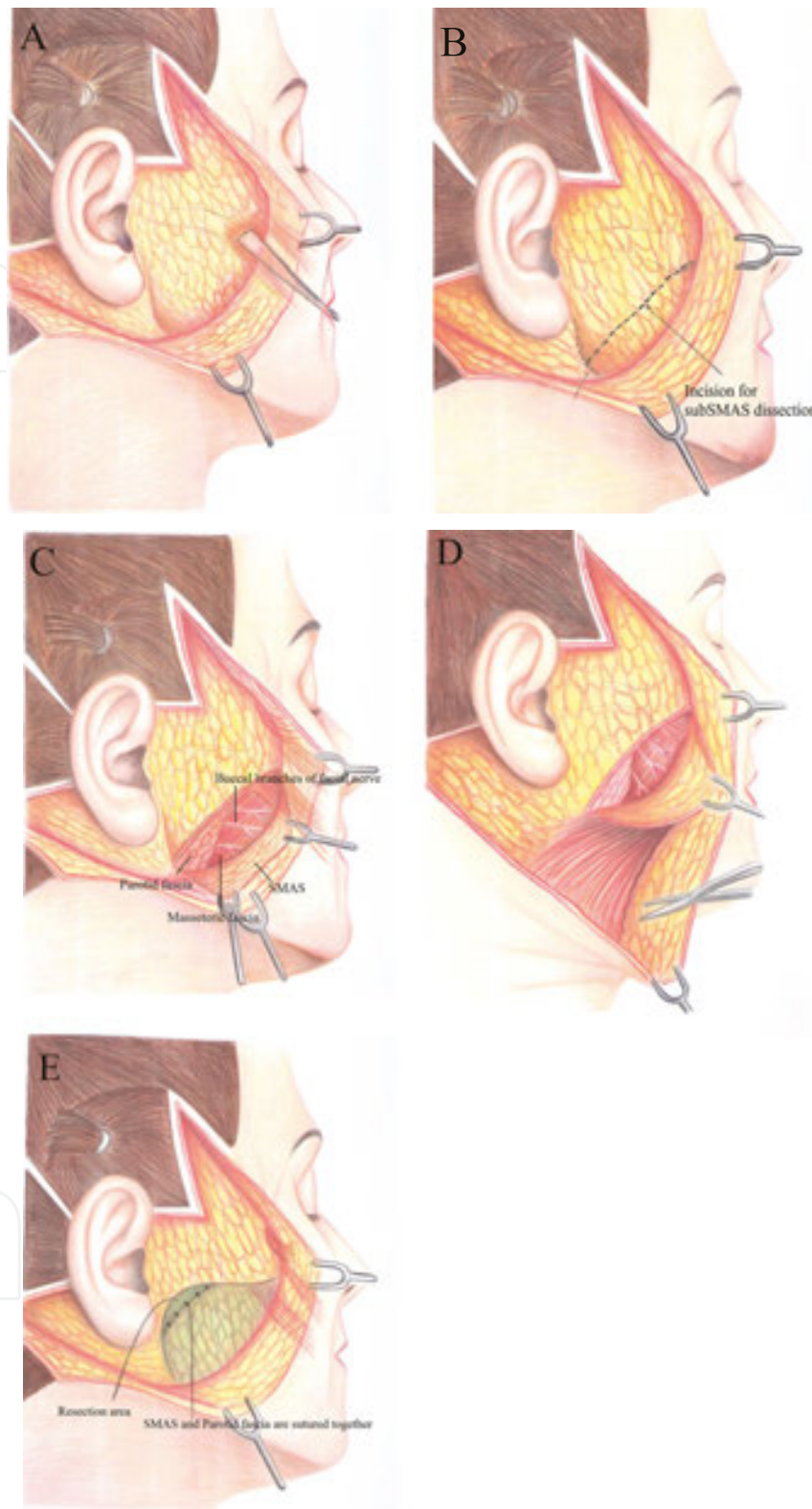
## 5.4. Deep plane facelift (DPFL)

### 5.4.1. *Procedure*

Deep plane rhytidectomy was suggested in place of traditional face lifting to correct aging changes of midface (i.e., malar fat pad) and nasolabial grooves. The deep plane modification was presented by Hamra for the first time [2]. The main concept of this technique was based on reversing gravity's effect by manipulating deep soft tissues to make more satisfying changes in older patients.

In the beginning of the procedure, subcutaneous dissection is performed 2 to 3 mm anterior to the tragus. SMAS layer is then incised after a few millimeters exposure. The dissection plane is the sub-SMAS plane. There are three main reference points during dissection of DPFL (**Figure 4**). Orbicularis oris is the first reference point which should not be considered as a part of the flap in deep plane dissection. Good esthetic results would be achieved by incorporating most of the soft tissue into the flap. The zygomatic major muscle is the second important reference point. Deep plane dissection is continued superiorly to the border of this muscle. The last reference point is the zygomatic minor muscle. Zygomatic cutaneous ligament as a major facial retaining ligament is lysed directly. It is necessary to release this ligament to mobilize the midface completely. The final flap consists of skin, subcutaneous tissue, and malar fat pad [22].

Patients with significant aging changes of midface and mentolabial fold are good candidates for this procedure. This method is not suggested for patients with irrational expectations and with poor medical health. This procedure is not suitable in secondary facelift unless the first one was not a sub-SMAS procedure. Although DPFL is indicated for smokers in some investigations [23], the surgeon should be aware of increased risk of wound-healing complications.



**Figure 4.** Deep plane rhytidectomy. (A) Subcutaneous dissection is performed 2–3 mm anterior to the tragus. (B) SMAS layer is then incised after a few millimeters exposure. (C) The dissection plane is the sub-SMAS plane. (D) Dissected SMAS layer is obvious. (E) The SMAS layer is sutured to the parotid fascia at the end.



#### 5.4.2. *Advantages*

This procedure is performed to gain good results in improvement of nasolabial folds. The results of this technique are relatively longer than other supra-SMAS techniques [24]. The surgeon is able to lyse the major facial retaining ligament (i.e., zygomatic cutaneous ligament) and assess the herniation of buccal fat pad directly. Dissecting in sub-SMAS layer and manipulating deep soft tissues of the face give rise to major changes and improvements of senile faces.

#### 5.4.3. *Disadvantages*

This facelift modification is associated with higher risk of facial nerve damage. Mono-plane dissection in this procedure does not give the surgeon the ability to move different layers including skin, subcutaneous, and SMAS layers in various directions.

### 5.5. Extended SMAS lift

#### 5.5.1. *Procedure*

Presenting sub-SMAS dissection by Lemmon was rapidly accepted by cosmetic surgeons [25]. Supporting the overlying skin by manipulating deeper soft tissues (i.e., SMAS layer) is the key concept of sub-SMAS modifications. Although SMAS plication seems to provide better results where the SMAS layer is thin, dissection of thick SMAS layer obtains more satisfactory outcomes.

This technique was presented by Stuzin et al. in 1995 [26]. The main procedure protocol in this method is dissecting and drawing skin and SMAS flaps separately. At first, the skin flap is dissected in the subcutaneous plane. The SMAS layer is incised, after which dissection is continued in sub-SMAS plane.

There are five critical landmarks during performing extended SMAS facelifting [27]:

The first point is 1 cm inferior to the zygomatic arch, which is the origin of the frontal branch of the facial nerve. The incision to start sub-SMAS dissection is from this point.

The second important landmark is the beginning point of releasing and dissecting the platysmal auricular ligament. This second landmark is 3 cm below the earlobe.

The third point is 5 cm below the mandibular angle, which is the inferior extent of sub-platysmal dissection.

Fourth landmark is the anterior border of the sub-platysmal dissection, which is identified by the facial vein where it crosses the inferior border of the mandible.

The last landmark is the zygomaticus major muscle, which is the anterior limit of sub-SMAS dissection in the cheek.

The vector of stretching the SMAS layer is different from the skin's [28]. The vector of retracting the SMAS layer is more vertical than the skin flap. The SMAS and platysma flaps can be rotated

in the postauricular area to improve the jaw and cervical contour. The SMAS flap is advanced superolaterally, perpendicular to the nasolabial fold in the malar fat pad area.

#### *5.5.2. Advantages*

The surgeon is more able to reverse the effects of the aging process by manipulating skin and SMAS flaps separately. The outcomes of this technique are long lasting due to releasing the facial ligaments and repositioning of the malar fat pad. As it was mentioned before, we are capable of replacing the malar fat pad by this technique. Maximum effects on lower face and neck can be achieved by creating a continuous SMAS-platysmal flap. The unnatural appearance of skin, which sometimes is seen in other facelift techniques, is prevented by reducing the tension of the skin flap due to separating the skin and SMAS flaps.

#### *5.5.3. Disadvantages*

The operation time of this technique is relatively longer than other modifications. This procedure is technically sensitive and needs a lot of experience to dissect the soft tissue of the face in two separate parts. The risk of facial nerve damage is relatively high in this method. Extensive dissection of the skin places it at a higher risk of necrosis. The compromised viability of the skin flap is a major concern in this technique. This procedure is not indicated in younger patients with mild aging changes and youthful lower face and neck. Less invasive procedures such as short scar facelift techniques are preferred in these patients.

### **5.6. Lateral SMASeotomy**

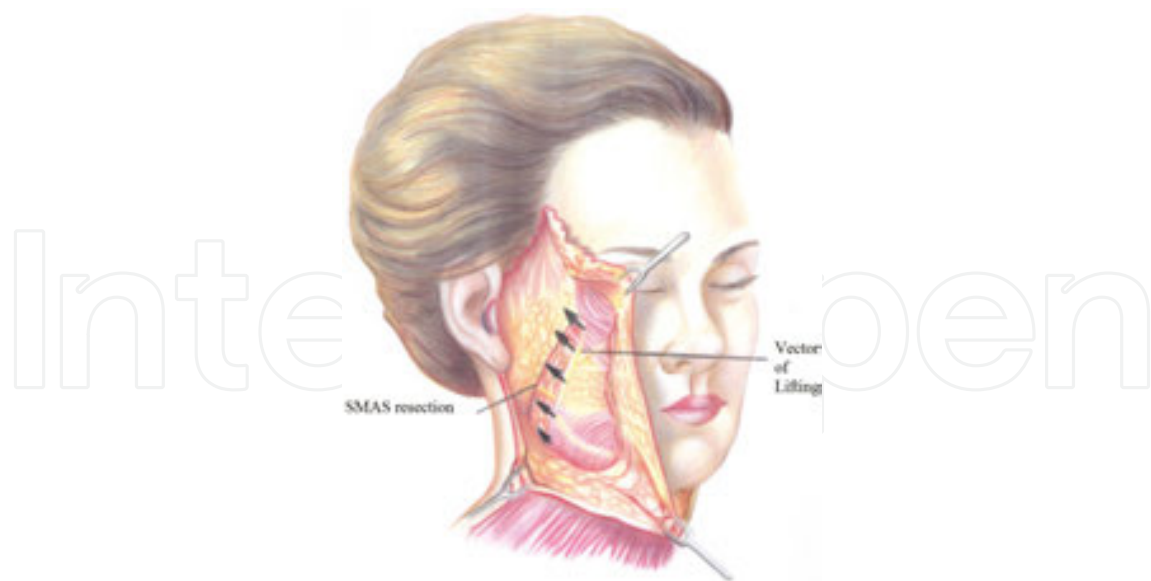
#### *5.6.1. Procedure*

Lateral SMASeotomy was first described by Baker [29]. Lateral SMASeotomy or limited SMAS procedure is a facelift modification in which the lateral portion of the SMAS located between the mobile and the fixed SMAS is removed.

Classical facelift procedure is begun at first until the SMAS layer is exposed. Superficial fascia covering the anterior border of parotid gland is excised and discarded. The anterior SMAS layer which is mobile is stretched in a superoposterior direction and fixed to the posterior fixed SMAS layer. The vector of tracing the SMAS layer is perpendicular to the nasolabial fold. Manipulating the SMAS layer is the key concept in determining the stability for satisfactory results (**Figure 5**).

This facelift method is indicated in patients younger than 50 with moderate skin laxity and moderate jowls. There should not be medial platysma bands present on normal animation although submental fat may be observed [30]. This technique can be performed in microgenia patients. This procedure is not indicated in the patients over 60 with severe skin laxity in the neck area.





**Figure 5.** Vector of elevation in SMASectomy technique.

#### 5.6.2. Advantages

The outcomes of this procedure continue much longer than SMAS plication technique due to the stronger fixation of SMAS layer. This technique is relatively easier than complicated procedures such as DPFL and composite facelift. It is a simple technique with minimal SMAS dissection and predictable postoperative results [31]. The postoperative pain may be more tolerable than MACS lift with similar short-term results [19].

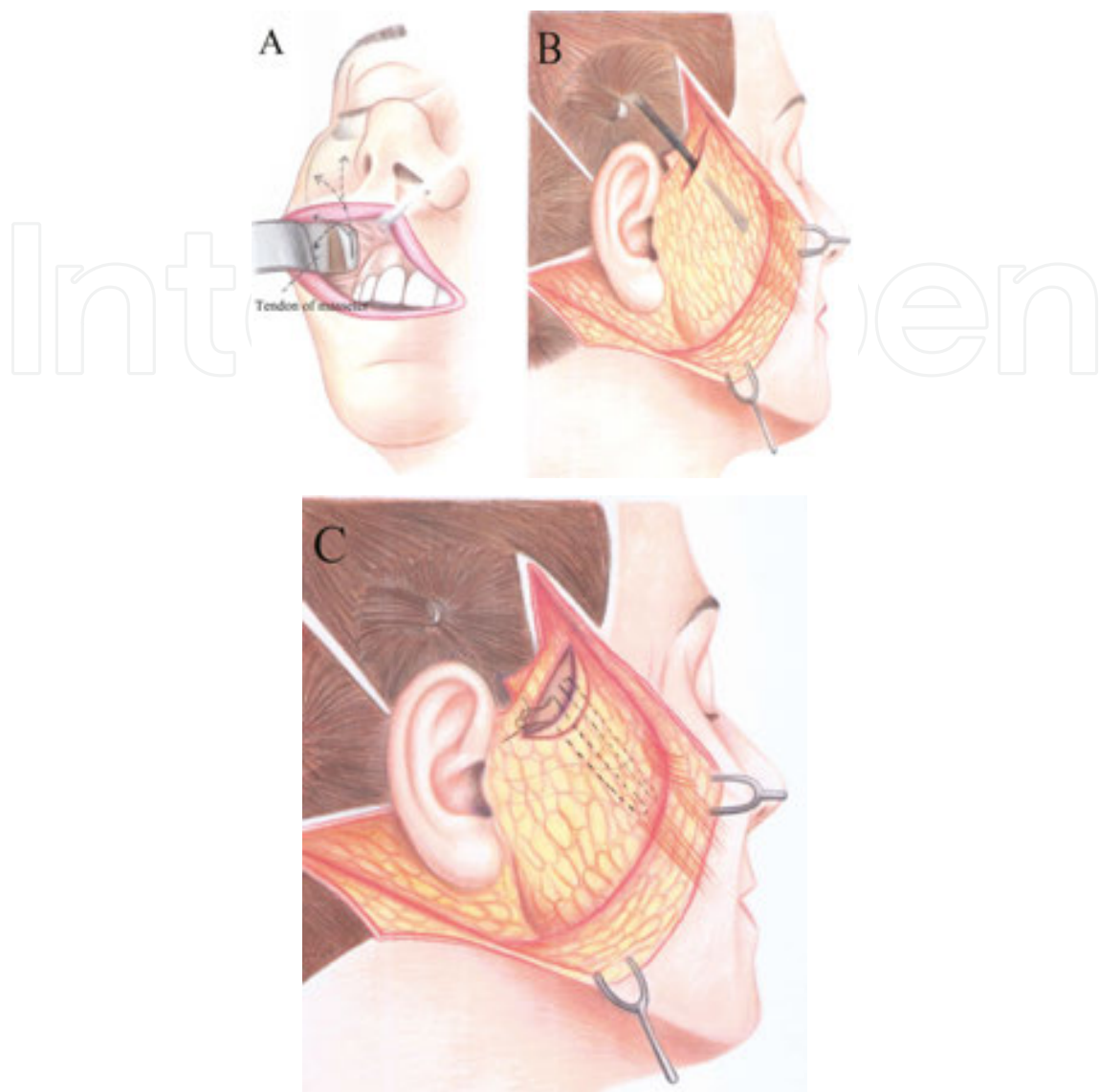
#### 5.6.3. Disadvantages

Manipulation of deep soft tissue is limited in this technique as in SMAS plication method. The intact facial ligaments after performing this surgery and limited advancement of deep facial tissues make the results less satisfactory [28]. The risk of facial nerve injury is relatively high in the current method. Preserving the integrity of SMAS layer after removing the indicated part is sensitive and needs experience [31]. The visible scar in this technique is a drawback compared to the short scar facelift modifications; the operation time is longer than MACS lift procedure [19].

### 5.7. Subperiosteal facelift

#### 5.7.1. Procedure

Tessier proposed the subperiosteal facelift technique for the first time [32]. It is possible to lift the soft tissues of the face vertically and reposition them at the level of their bony origin. This technique rapidly developed and was accepted as a suitable procedure for lifting the upper two thirds of the face.



**Figure 6.** (A) Intraoral dissection to provide direct exposure of subperiosteal dissection. (B) Temporal incision to dissect zygomatic area subperiosteally. (C) Suturing the midface soft tissue to the temporalis fascia.

There are three main landmarks in subperiosteal facelift [33]:

The first is the SOOF<sup>3</sup>. This landmark is located at the cross point of two imaginary lines which pass through the lateral of the eyebrows and inferior orbital rims.

The malar fat pad is the second important landmark in this procedure. The location of this point is at the cross of a vertical line passing through the lateral canthus and the horizontal line passing through the superior margin of the nasal alae.

The last point is Bichat's fat pad, which is located at the cross point of the vertical line passing through the lateral canthus and the horizontal line passing through the nasal base.

<sup>3</sup> Suborbicularis oculi fat.

Subperiosteal dissection is performed through the incision in the temporal area (**Figure 6**). The three mentioned points are lifted and sutured to the deep temporalis fascia. The SOOF, malar fat pad, and Bichat's fat pad are sutured and suspended to the deep temporalis fascia laterally, centrally, and medially, respectively. Nowadays, intra-oral subperiosteal dissection is more popular due to decreased operation time and reduced nerve damage risk [34].

This procedure is indicated in the patients with significant aging changes. Endoscopic subperiosteal facelift is an appropriate approach in patients with good skin tone. The other indication of this technique is in the patient who needs other simultaneous cosmetic procedures like skin resurfacing and implant or fat transfer. This method is suitable in raising the eyebrows, eyelid lateral corners, forehead, glabella, cheeks, and nasolabial fold.

#### 5.7.2. *Advantages*

This technique includes less incisions, use of endoscope, better fixation and allows for repositioning of the buccal and malar fat pads. Satisfactory results in correcting orbital festoons and brow ptosis are possible by this method. The risk of facial nerve damage is very low in this technique. Long lasting results of this method are expected due to manipulating deeper tissues and good fixation. The vascularity of the flap is maintained by minimal dissection and keeping whole layers together, which is an important advantage of this procedure in smokers. The face appears more natural comparing to SMAS lifting methods.

#### 5.7.3. *Disadvantages*

This facelift technique is not suitable to use as the second facelift surgery. This procedure is relatively contraindicated in patients with a history of facial bone fractures. Irregularities of the face make the subperiosteal dissection much harder.

Prolonged operation time and recovery period are the major drawbacks of this technique. This technique is not suitable for correcting the aging changes of the lower third of the face and neck.

## 6. Post-operative care after facelift surgery

Facelift surgery is one of the most dramatic procedures for rejuvenation. The success rate of the surgery relies on the surgeon and the patient as well. The surgeon cannot gain satisfactory results unless the patients follow the post-operative care properly.

### 6.1. Immediately after surgery

The patient should be in complete bed rest for the first 24 hours after surgery. The patients will be wrapped in dressings that will not be removed until 24 hours later. The patient's head must be elevated for at least the first week after surgery. They should not sleep on the side of their face but rather sleep supine with the back of the head on the pillow for about 2 weeks. The

surgeon should prescribe pain medications to prevent pain. The activities of the patient should be restricted the day of surgery and up to a week afterwards. The patient should place ice packs over the surgical site.

## **6.2. Bleeding**

Mild bleeding from the surgical site is not unusual. Head elevation and applying an ice compress with mild pressure about the face and neck usually decrease the bleeding. Elevation of the patients' blood pressure by bending, sneezing, lifting, coughing, straining, straining on the toilet, and other strenuous activities are the main causes of bleeding. The patient should refrain absolutely from activities that may increase blood pressure for 10 days after the surgery to avoid complications from bleeding.

## **6.3. Swelling**

Edema is a routine finding of any surgery. The amount of swelling is dependent on the looseness of the tissues and the amount of manipulation varies from person to person. Swelling around the eyes, cheeks, face, and down into the neck and chest are not uncommon. Swelling starts immediately following surgery and will reach its maximum 2 to 3 days post-operatively. Edema will decrease after the third day. The swelling will cause the skin of the face feel tight for a while. It may interfere with smiling before disappearing within a few weeks.

## **6.4. Pain**

Acetaminophen may be taken every 4 hours for mild pain. NSAIDs are not recommended for the first several days after surgery because of the increased risk of bleeding and/or bruising. Narcotics are indicated in severe pain. The patients should avoid alcoholic beverages since it enhances the effect of the narcotics. Pain and discomfort usually decreased after the first 2 to 3 days. Persistent pain may need attention.

## **6.5. Diet**

Clear liquids should be initially taken after general anesthesia or I.V. sedation. Over the next several days, a high calorie, high protein intake is very important. Supplements should be taken regularly. The patient should not be dehydrated by taking fluids regularly. Keeping well hydrated also prevents nausea and vomiting.

## **6.6. Wound care**

The patients should start cleaning the skin incisions the day after surgery with soap and water three times per day very gently and pat dried (do not wipe). The incisions should be dried and cleaned with a 50% solution of 3% hydrogen peroxide. The hydrogen peroxide should be mixed with an equal amount of warm tap water and a Q-tip should be used to clean the incisions. The incisions should be covered with antibiotic ointment after that. Incisions should not be allowed to become dry or crust over.

### 6.7. Discoloration

Discoloration of the skin following swelling occurs in some cases. Blood spreading beneath the tissues leads to development of discoloration. This is a normal occurrence in most patients which occurs 2 to 3 days post-operatively. Applying moist heat to the area could speed up the removal of the discoloration. Bruising is rare in younger patients, and sometimes yields as a slight yellow discoloration. In older patients, bruising can be quite significant and is represented as black and blue discoloration. Bruising of large degree may take approximately 2 weeks to resolve.

### 6.8. Antibiotics

The patient should be prescribed the antibiotics on-time to prevent postoperative infection.

### 6.9. Nausea and vomiting

In the event of nausea and/or vomiting following surgery, do not give anything by mouth to the patient for at least an hour including the prescribed medicine. Anti-emetic drugs are useful to prevent nausea.

## 7. Complications of the facelift procedure

Some of the complications of facelift surgery are hematoma (the most common complication), pre- and postauricular scar hypertrophy, facial telangiectasia, stitch abscess, neck hyperpigmentation, pre- and postauricular skin necrosis, nerve damage, temporal alopecia cutaneous sloughing or necrosis, seroma, wound dehiscence, hypertrophic scarring, contour irregularities, dimpling, and infection [35–42].

The most dangerous complications include hematoma (rates 1.0–15%), infection (0.05–0.18%), nerve injury (0.07–2.5%), skin sloughing (1.0–1.85%), and systemic vascular complications like venous thromboembolism (VTE 0.1%) [37, 41, 43, 44]. It has been reported that the complication rate in patients with a high body mass index (BMI) over 25 was 9.5%, compared to 4.7% in normal weight patients undergoing a facelift [43].

### 7.1. Hematoma

Hematoma formation remains the most common major complication after facelift surgery [45–47]. Common themes in patients who may experience hematoma following facelift include male sex, hypertension, preoperative medications that affect coagulation such as aspirin use, smoking, BMI, pre- and post-surgical blood pressure spikes, retching vomiting, post-surgical activity, and nausea [46, 47].

Hematomas in face can cause tissue ischemia, long-term edema, hyperpigmentation, and patient complaint. The incidence of hematoma reported 0.2–8.1% (needs a space between reported and 0.2) in articles [35]. Studies that document the occurrence of hematoma formation

following facelift surgery includes the use of drains in the surgical site which have some problems such as introducing infection into the wound, leakage, and being displaced [48, 49]. They create tracts at the site of removal, necessitate painful extraction, and risk injury to vessels on removal.

The incidence of hematoma following male rhytidectomy is lower than facelift in females although the incidence of hematoma in men remains higher than that in women in 30-year-old patients [49]. Meticulous perioperative blood pressure control significantly reduces the rate of postoperative hematoma formation [45]. Large hematomas can cause skin necrosis and need to be promptly evacuated.

## **7.2. Infection**

Infection is the second most common major complication occurring in 0.3% facelifts. Combined procedures and high BMI are risk factors for developing major infection. A post-facelift infection is most commonly caused by *Staphylococcus aureus* [37, 38].

## **7.3. Nerve injury**

Injury to the facial nerve during a face lift is a relatively rare but serious complication. Understanding of the anatomical course of the facial nerve and the relative danger zones can prevent this complication [50].

Two of the most feared complications of facelift surgery are motor and sensory nerve damage and flap necrosis [51]. Different injuries can result in frontal, buccal, zygomatic, marginal mandibular, and cervical nerve damage, including direct injury, neurapraxia, thermal injury from cautery, compression injury from sutures, edema, or hematoma. The greater auricular nerve is the most common sensory nerve that may be damaged during the facelift procedure.

## **7.4. Edema and ecchymosis**

Although some degree of postsurgical edema can be seen in all patients undergoing a facelift procedure, some of them show impressive swelling. Patients undergoing multiple procedures, including brow lift, midface implantinsertion, lip implants, and simultaneous laser resurfacing can swell to alarming proportions [52].

## **7.5. Skin slough**

Skin slough is a rare occurrence following face lift. The skin flaps are monitored closely during the postoperative course. Usually, vascular compromise is noted in the preauricular region and may appear as a distinct area of ecchymosis [41].

## **7.6. Scarring**

With a well-designed and well-executed facelift, noticeable scars are unusual, following a face lift procedure.



### 7.7. Alopecia

There is very little information associated with development of dermatological conditions after cosmetic surgical procedures, including hair transplantation and facelift surgery. Alopecia occurs following damage to the hair follicles from electrocautery, excess traction or tension on the skin flaps, and involuntary elevation or elimination of the temporal hair tuft [41].

### 7.8. Contour deformities

These temporary deformities are common immediately after rhytidectomy. The preauricular and submental regions are the usual regions of these deformities occurrence which are related to post-surgical edema or ecchymosis [41].

### 7.9. Flap necrosis

Flap necrosis following facial rhytidectomy is an irritating complication, both to the patient and to the surgeon [53]. Necrosis of the lipocutaneous flap may result in permanent scars and prolonged recovery. Causes vary from bandage compression, sleeping position of the patient, flap sutures under tension, inherent healing difficulties, and no detectable cause. Although smokers or patients with compromised health are more common to encounter this complication, flap necrosis may happen in the best conditions [52].

### 7.10. Systemic complications

Major complications included deep vein thrombosis (DVT), pulmonary embolism, blood transfusions, stroke, important anesthetic complications, and death [41].

## 8. New trends in non-surgical rejuvenation

Understanding the facial anatomy and its changes through aging has led to development of different facelift techniques that focus on being less invasive and less traumatic and also providing long-lasting results [54]. Numerous non-invasive face rejuvenation techniques have been investigated over the past decade to improve the results of the procedure and to avoid incisional surgery. Some of the treatment options are as follows: radiofrequency (RF) and ultrasound therapy that are useful in skin tightening/laxity. Also, there are numerous liposuction techniques/devices and injectable cytolytic drugs for submental fat reduction. Fractional lasers and RF devices, chemical peels, micro-needling, intense pulsed light (IPL), injectable fillers, pigment and vascular lasers, liquid nitrogen therapy are useful in superficial dyschromias and rhytides/crepe skin. Moreover, neuromodulators may enhance platysmal banding. Various types of fillers and volumizers including autologous fat, hyaluronic acid (HA), and injectable poly-L-lactic acid (PLLA) calcium or hydroxylapatite (CaHA) are used. A novel bimodal technique to restore volume loss facial structures for panfacial lipo-atrophy with PLLA has been introduced [55, 56].

A novel, minimally invasive, RF device employing a bipolar micro-needle electrode system is introduced, varying the pulse length allowed for fractional sparing of dermal tissue. In some studies, bipolar mode delivering energy directly within the dermis using five micro-needle electrode pairs is used with real-time feedback of tissue temperature for treatment control. Superficial cooling is achieved with a Peltier device [57].

The *thermaCool TC* (Thermage Inc.) is a RF device to induce tightening of the addressed skin problem via a uniform volumetric heating into the deep dermis tightening, resulting in a “nonsurgical facelift”. RF produces a uniform volumetric heating into the deep dermis. Gradual tightening is produced by this technique in most patients with no adverse effects [58, 59].

Laser, light, and RF energy sources have succeeded in treating the second category of skin aging; however, the surgical facelift is still the gold standard in treatment of laxity associated with intrinsic aging [60].

Laser resurfacing was presented in the 1980s with continuous wave carbon dioxide (CO<sub>2</sub>) lasers; however, because of many side effects, including scarring, short-pulse, high-peak power, and rapidly scanned, normal-mode erbium-doped yttrium aluminium garnet lasers and focused-beam CO<sub>2</sub> lasers were developed to remove skin in a precisely controlled manner [61]. Laser skin tightening is an FDA-approved method for the reduction of fine wrinkles and skin laxity. Laser skin tightening is a non-surgical, minimally invasive technique that uses an infrared light source to tighten skin through collagen heating under the skin's surface, causing the skin to contract [62]. Facial rejuvenation using polydioxanone (PDO) thread is a safe and effective procedure associated with only minor complications in cases of fine wrinkles, face sagging, and marked facial pores [63].

One important advance in facial rejuvenation is the use of fiber endoscopic video-assisted technique in aesthetic plastic surgery of the face. It substitutes the coronal incision with no skin resection and leads to a vertical reposition of the mobile soft tissue of the midface in indicated cases. It needs only a small incision of the scalp just behind the coronal incision and in the temporal area [64].

Pak et al. introduced a nonabsorbable polypropylene mesh as a newface lifting instrument, with the nasolabial fold as the main target area. Face lifting using a nonabsorbable mesh can improve nasolabial folds without serious adverse effects. So, this is a safe and effective technique in midface rejuvenation [65].

Incorporation of selective fat compartment volume restoration through SMAS manipulation allows for improved control in recontouring while addressing the problem of volume deflation in facial aging. Facial rejuvenation is described through merging two key important points based on lift-and-fill face lift: (1) lifting and tightening tissues in differential vectors according to original facial asymmetry and shape; and (2) precious facial contouring through selective fat compartment filling of malar locations (deep and high) and graft of nasolabial fold fat [66].

## 9. Summary

Cosmetic surgeries including facelift operation are becoming increasingly popular, and facial rejuvenation remains one of the most commonly requested aesthetic procedures. Many lifting procedures can be used in order to reduce sagging of skin and subcutaneous tissues and create a more youthful face. In the forehead and eyebrow region, the direct brow lift, temporal brow lift, transferable pharoplastic brow lift, coronal brow lift, and the endoscopic brow lift can be identified. The facelift is considered in the mid-face. Classic facelifts can be divided into the one layer, two layers, and the deep plane facelift (DPFL). The incidence of postoperative complications associated with lifting procedures is rare, but clinically important. Hematoma, skin necrosis of the wound edges, infection, nerve injuries are some of these complications. Today, the tendency toward minimally invasive procedures with smaller risk of complications and shorter recovery period are desired.

## Author details

Fereydoun Pourdanesh<sup>1</sup>, Mohammad Esmaeelinejad<sup>1\*</sup>, Seyed Mehrshad Jafari<sup>1</sup> and Zahra Nematollahi<sup>2</sup>

\*Address all correspondence to: esmaeelnejad@gmail.com

1 Department of Oral and Maxillofacial Surgery, School of Dentistry, Shahid Beheshti University of Medical Sciences, Tehran, Iran

2 Dental Research Center, Research Institute of Dental Sciences, Shahid Beheshti University of Medical Sciences, Tehran, Iran and Craniomaxillofacial Research Center, Azad University, Dental Branch, Tehran, Iran

## References

- [1] Mitz V, Peyronie M. The superficial musculo-aponeurotic system (SMAS) in the parotid and cheek area. *Plastic and reconstructive surgery* 1976; 58:80–88.
- [2] Hamra ST. The deep-plane rhytidectomy. *Plastic and reconstructive surgery* 1990; 86:53–61; discussion 62–53.
- [3] Owsley JQ, Jr., Zweifler M. Midface lift of the malar fat pad: technical advances. *Plastic and reconstructive surgery* 2002; 110:674–685; discussion 686–677.
- [4] Ramirez OM. The subperiosteal rhytidectomy: the third-generation face-lift. *Annals of plastic surgery* 1992; 28:218–232; discussion 233–214.

- [5] Connell BF. Contouring the neck in rhytidectomy by lipectomy and a muscle sling. *Plastic and reconstructive surgery* 1978; 61:376–383.
- [6] Dedo DD. “How I do it”—plastic surgery. Practical suggestions on facial plastic surgery. A preoperative classification of the neck for cervicofacial rhytidectomy. *The Laryngoscope* 1980; 90:1894–1896.
- [7] Mang W, Verlag ÄGS, Neumann H, Einhorn-Presse G. Rhytidectomy. *Facial plastic surgery* 2007; 23:635.
- [8] Marten E, Langevin CJ, Kaswan S, Zins JE. The safety of rhytidectomy in the elderly. *Plastic and reconstructive surgery* 2011; 127:2455–2463. DOI: 10.1097/PRS.0b013e3182131da9
- [9] Webster RC, Kazda G, Hamdan US, *et al.* Cigarette smoking and face lift: conservative versus wide undermining. *Plastic and reconstructive surgery* 1986; 77:596–604.
- [10] Ellenbogen R. A 15-year follow-up study of the non-SMAS skin-tightening facelift with midface defatting. Equal or better than deeper plane procedures in result, duration, safety, and patient satisfaction. *Clinics in plastic surgery* 1997; 24:247–267.
- [11] Rubin LR, Simpson RL. The new deep plane face lift dissections versus the old superficial techniques: a comparison of neurologic complications. *Plastic and reconstructive surgery* 1996; 97:1461–1465.
- [12] Gamble WB, Manson PN, Smith GE, Hamra ST. Comparison of skin-tissue tensions using the composite and the subcutaneous rhytidectomy techniques. *Annals of plastic surgery* 1995; 35:447–453; discussion 453–444.
- [13] Becker FF, Bassichis BA. Deep-plane face-lift vs superficial musculoaponeurotic system plication face-lift: a comparative study. *Archives of facial plastic surgery* 2004; 6:8–13. DOI: 10.1001/archfaci.6.1.8
- [14] Mohammadi S, Ahmadi A, Salem MM, *et al.* A comparison between two methods of face-lift surgery in nine cadavers: SMAS (superficial musculo-aponeurotic system) versus MACS (minimal access cranial suspension). *Aesthetic plastic surgery* 2015; 39:680–685. DOI: 10.1007/s00266-015-0543-3
- [15] Pitanguy I, Machado BH. Facial rejuvenation surgery: a retrospective study of 8788 cases. *Aesthetic surgery journal/The American society for aesthetic plastic surgery* 2012; 32:393–412. DOI: 10.1177/1090820x12438895
- [16] Jacono AA, Parikh SS, Kennedy WA. Anatomical comparison of platysmal tightening using superficial musculoaponeurotic system plication vs deep-plane rhytidectomy techniques. *Archives of facial plastic surgery* 2011; 13:395–397. DOI: 10.1001/archfacial.2011.69

- [17] Verpaele A, Tonnard P, Gaia S, *et al.* The third suture in MACS-lifting: making midface-lifting simple and safe. *Journal of plastic, reconstructive & aesthetic surgery* 2007; 60:1287–1295. DOI: 10.1016/j.bjps.2006.12.012
- [18] Verpaele A, Tonnard P. Lower third of the face: indications and limitations of the minimal access cranial suspension lift. *Clinics in plastic surgery* 2008; 35:645–659, vii. DOI: 10.1016/j.cps.2008.04.001
- [19] Prado A, Andrades P, Danilla S, *et al.* A clinical retrospective study comparing two short-scar face lifts: minimal access cranial suspension versus lateral SMASectomy. *Plastic and reconstructive surgery* 2006; 117:1413–1425; discussion 1426–1417. DOI: 10.1097/01.prs.0000207402.53411.1e
- [20] Tonnard PL, Verpaele A, Gaia S. Optimising results from minimal access cranial suspension lifting (MACS-lift). *Aesthetic plastic surgery* 2005; 29:213–220; discussion 221. DOI: 10.1007/s00266-005-0047-7
- [21] Mast BA. Advantages and limitations of the MACS lift for facial rejuvenation. *Annals of plastic surgery* 2014; 72:S139–143. DOI: 10.1097/sap.0000000000000092
- [22] Gordon NA, Adam SI, 3rd. Deep plane face lifting for midface rejuvenation. *Clinics in plastic surgery* 2015; 42:129–142. DOI: 10.1016/j.cps.2014.08.009
- [23] Parikh SS, Jacono AA. Deep-plane face-lift as an alternative in the smoking patient. *Archives of facial plastic surgery* 2011; 13:283–285. DOI: 10.1001/archfacial.2011.39
- [24] Marcus BC. Rhytidectomy: current concepts, controversies and the state of the art. *Current opinion in otolaryngology & head and neck surgery* 2012; 20:262–266. DOI: 10.1097/MOO.0b013e328355b175
- [25] Lemmon ML. Color atlas of SMAS rhytidectomy. First ed. Michigan: Thieme Medical Publisher; 1993
- [26] Stuzin JM, Baker TJ, Gordon HL, Baker TM. Extended SMAS dissection as an approach to midface rejuvenation. *Clinics in plastic surgery* 1995; 22:295–311.
- [27] Lindsey JT. Five-year retrospective review of the extended SMAS: critical landmarks and technical refinements. *Annals of plastic surgery* 2009; 62:492–496. DOI: 10.1097/SAP.0b013e31818ba77d
- [28] Ivy EJ, Lorenc ZP, Aston SJ. Is there a difference? A prospective study comparing lateral and standard SMAS face lifts with extended SMAS and composite rhytidectomies. *Plastic and reconstructive surgery* 1996; 98:1135–1143; discussion 1144–1137.
- [29] Baker DC. Lateral SMASectomy. *Plastic and reconstructive surgery* 1997; 100:509–513.
- [30] Baker DC. Lateral SMASectomy, plication and short scar facelifts: indications and techniques. *Clinics in plastic surgery* 2008; 35:533–550, vi. DOI: 10.1016/j.cps.2008.06.003



- [31] Kim BJ, Choi JH, Lee Y. Development of facial rejuvenation procedures: thirty years of clinical experience with face lifts. *Archives of plastic surgery* 2015; 42:521–531. DOI: 10.5999/aps.2015.42.5.521
- [32] Tessier P. Subperiosteal face-lift. *Annales de chirurgie plastique et esthetique* 1989; 34:193–197.
- [33] Patrocinio LG, Patrocinio TG, Patrocinio JA. Subperiosteal midface-lift. *Facial plastic surgery* 2013; 29:206–213. DOI: 10.1055/s-0033-1347000
- [34] Gentile RD. Subperiosteal deep plane rhytidectomy: the composite midface lift. *Facial plastic surgery* 2005; 21:286–295. DOI: 10.1055/s-2006-939507
- [35] Griffin JE, Jo C. Complications after superficial plane cervicofacial rhytidectomy: a retrospective analysis of 178 consecutive facelifts and review of the literature. *Journal of oral and maxillofacial surgery* 2007; 65:2227–2234.
- [36] De Cordier BC, de la Torre JI, Al-Hakeem MS *et al.* Rejuvenation of the midface by elevating the malar fat pad: review of technique, cases, and complications. *Plastic and reconstructive surgery* 2002; 110:1526–1536.
- [37] Gupta V, Winocour J, Shi H, *et al.* Preoperative risk factors and complication rates in facelift: analysis of 11,300 patients. *Aesthetic surgery journal* 2015; sjv162. 2016 Jan;36(1): 1–13.
- [38] Stuzin JM. MOC-PS (SM) CME article: face lifting. *Plastic and reconstructive surgery* 2008; 121:1–19.
- [39] Mustoe TA, Park E. Evidence-based medicine: face lift. *Plastic and reconstructive surgery* 2014; 133:1206–1213.
- [40] Matarasso A, Elkwood A, Rankin M, Elkowitz M. National plastic surgery survey: face lift techniques and complications. *Plastic and reconstructive surgery* 2000; 106:1185–1195.
- [41] Chaffoo RA. Complications in facelift surgery: avoidance and management. *Facial plastic surgery clinics of North America* 2013; 21:551–558.
- [42] Pitanguy I, Machado BH. Facial rejuvenation surgery: a retrospective study of 8788 cases. *Aesthetic surgery journal* 2012; 32:393–412.
- [43] Abboushi N, Yezhelyev M, Symbas J, Nahai F. Facelift complications and the risk of venous thromboembolism: a single center's experience. *Aesthetic surgery journal* 2012; 32:413–420.
- [44] Moyer JS, Baker SR. Complications of rhytidectomy. *Facial plastic surgery clinics of North America* 2005; 13:469–478.



- [45] Ramanadham SR, Mapula S, Costa C, *et al.* Evolution of hypertension management in face lifting in 1089 patients: optimizing safety and outcomes. *Plastic and reconstructive surgery* 2015; 135:1037–1043.
- [46] Maricevich MA, Adair MJ, Maricevich RL, *et al.* Facelift complications related to median and peak blood pressure evaluation. *Aesthetic plastic surgery* 2014; 38:641–647.
- [47] Niamtu J. Expanding hematoma in face-lift surgery: literature review, case presentations, and caveats. *Dermatologic surgery* 2005; 31:1134–1144.
- [48] Zoumalan R, Rizk SS. Hematoma rates in drainless deep-plane face-lift surgery with and without the use of fibrin glue. *Archives of facial plastic surgery* 2008; 10:103–107.
- [49] Baker DC, Stefani WA, Chiu ES. Reducing the incidence of hematoma requiring surgical evacuation following male rhytidectomy: a 30-year review of 985 cases. *Plastic and reconstructive surgery* 2005; 116:1973–1985.
- [50] Roostaeian J, Rohrich RJ, Stuzin JM. Anatomical considerations to prevent facial nerve injury. *Plastic and reconstructive surgery* 2015; 135:1318–1327.
- [51] Baker DC, Conley J. Avoiding facial nerve injuries in rhytidectomy anatomical variations and pitfalls. *Plastic and reconstructive surgery* 1979; 64:781–795.
- [52] Niamtu J. Complications in facelift surgery and their prevention. *Oral and maxillofacial surgery clinics of North America* 2009; 21:59–80.
- [53] Weissman O, Farber N, Remer E, *et al.* Post-facelift flap necrosis treatment using charged polystyrene microspheres. *The Canadian Journal of Plastic Surgery* 2013; 21:45.
- [54] Centurion P, Romero C, Olivencia C, *et al.* Short-scar facelift without temporal flap: a 10-year experience. *Aesthetic plastic surgery* 2014; 38:670–677.
- [55] Weinkle A, Sofen B, Emer J. Synergistic approaches to neck rejuvenation and lifting. *Journal of drugs in dermatology* 2015; 14:1215–1228.
- [56] Sadick NS, Manhas-Bhutani S, Krueger N. A novel approach to structural facial volume replacement. *Aesthetic plastic surgery* 2013; 37:266–276.
- [57] Hantash BM, Renton B, Berkowitz RL, *et al.* Pilot clinical study of a novel minimally invasive bipolar microneedle radiofrequency device. *Lasers in surgery and medicine* 2009; 41:87–95.
- [58] Ruiz-Esparza J, Gomez JB. The medical face lift: a noninvasive, nonsurgical approach to tissue tightening in facial skin using nonablative radiofrequency. *Dermatologic surgery* 2003; 29:325–332.
- [59] Narins D, Narins R. Non-surgical radiofrequency facelift. *Journal of drugs in dermatology* 2003; 2:495–500.

- [60] Alexiades-Armenakas M, Rosenberg D, Renton B, *et al.* Blinded, randomized, quantitative grading comparison of minimally invasive, fractional radiofrequency and surgical face-lift to treat skin laxity. *Archives of dermatology* 2010; 146:396–405.
- [61] Alexiades-Armenakas MR, Dover JS, Arndt KA. The spectrum of laser skin resurfacing: nonablative, fractional, and ablative laser resurfacing. *Journal of the American academy of dermatology* 2008; 58:719–737.
- [62] Alexiades-Armenakas M. Laser skin tightening: non-surgical alternative to the face-lift. *Journal of drugs dermatology* 2006; 5:295–296.
- [63] Suh DH, Jang HW, Lee SJ, *et al.* Outcomes of polydioxanone knotless thread lifting for facial rejuvenation. *Dermatologic surgery* 2015; 41:720–725.
- [64] Hönig JF, Knutti D, Hasse FM. Centro-lateral subperiosteal vertical midface lift. *GMS interdisciplinary plastic and reconstructive surgery DGPW* 2014; 3: 1–12.
- [65] Pak CS, Chang LS, Lee H, *et al.* A multicenter noncomparative clinical study on midface rejuvenation using a nonabsorbable polypropylene mesh: evaluation of efficacy and safety. *Archives of plastic surgery* 2015; 42:572–579.
- [66] Rohrich RJ, Ghavami A, Constantine FC, *et al.* Lift-and-fill face lift: integrating the fat compartments. *Plastic and reconstructive surgery* 2014; 133:756e–767e.

