

We are IntechOpen, the world's leading publisher of Open Access books Built by scientists, for scientists

6,900

Open access books available

185,000

International authors and editors

200M

Downloads

Our authors are among the

154

Countries delivered to

TOP 1%

most cited scientists

12.2%

Contributors from top 500 universities



WEB OF SCIENCE™

Selection of our books indexed in the Book Citation Index
in Web of Science™ Core Collection (BKCI)

Interested in publishing with us?
Contact book.department@intechopen.com

Numbers displayed above are based on latest data collected.
For more information visit www.intechopen.com



Meningiomas' Management: An Update of the Literature

Giulia Cossu, Mahmoud Messerer, Fabrice Parker,
Marc Levivier and Roy Thomas Daniel

Additional information is available at the end of the chapter

<http://dx.doi.org/10.5772/62929>

Abstract

Meningiomas are the most common primary intracranial tumors in the adult population [1]. They are generally considered benign lesions but after the 2007 WHO classification, the proportion of atypical meningiomas has steeply increased. Surgery is considered the mainstay of the treatment and a complete resection is considered curative in WHO grade I meningiomas. The role of adjuvant treatments like radiotherapy (stereotactic radiosurgery or conventional external beam irradiation) and chemotherapy in more aggressive cases is still discussed, above all in WHO grade II meningiomas. We would like to expose the most important advances in meningiomas' management in accordance with the recent literature evidences.

Keywords: meningioma, management, benign meningiomas, atypical meningioma, anaplastic meningioma, malignant meningioma, surgery, radiotherapy, chemotherapy

1. Introduction

Meningiomas are the most common primary intracranial tumors[1]. Their origin from the arachnoid layer was first hypothesized by John Cleland in 1864 [2] and then reasserted by Cushing and Weed in 1915 [3]. Meningiomas are classified according to their dural attachment and histological grading. The 2000 WHO histological classification has been modified in 2007, and the epidemiology of more aggressive subtypes has thus recently changed [4]. Meningiomas may be incidental and asymptomatic, or they may present clinically with focal neurological deficit in accordance with a mass effect on an eloquent area or with epileptic seizures.

Surgery represents the mainstay of the treatment, but the management of more aggressive meningioma is challenging. The role of adjuvant therapies should thus be discussed in cases of more aggressive histological types, subtotal resection and recurrent diseases.

2. Epidemiology

Meningiomas account for 20 and 38% of all primary intracranial tumors, respectively, in males and in females, with an incidence of about five cases per 100,000 persons [5]. In an autoptic series about 2–3% of the general population had an incidental asymptomatic meningioma [6]. The female sex and estrogenic conditions seem to be a risk factor for developing meningiomas, with a female to male ratio of about 3:1 [7].

Hormonal therapy and hormone-dependent conditions such as breast cancer [8], pregnancy [9], or obesity [10] were in fact associated with a higher incidence of meningiomas. Cranial irradiation is also a recognized risk factor for developing meningiomas, usually with tumors having a more complex cariotype and a more aggressive behavior [11]. Head traumas have been for long associated with a higher meningioma incidence, but the causal effect was never demonstrated.

Some genetic conditions may favor the arising of meningiomas, such as neurofibromatosis type 2 (NF2), an autosomal dominant disorder characterized by mutation of the tumor suppressor gene NF2 coding for merlin in chromosome 22q12.2. Also multiple endocrine neoplasia type 1 (MEN1) is associated to a higher incidence of meningioma.

Meningiomas may derive from the dura of the cranial vault, of the skull base and at sites of dura reflection like the falx, the tentorium, and the dura recovering venous sinuses. Meningiomas may also arise from the optic-nerve sheath and from the choroid plexus. About 10% of them arise in the spine. In rare cases, meningiomas outside the craniospinal axis have been reported [12]. The preferential localization of intracranial meningiomas is summarized in **Figure 1**.

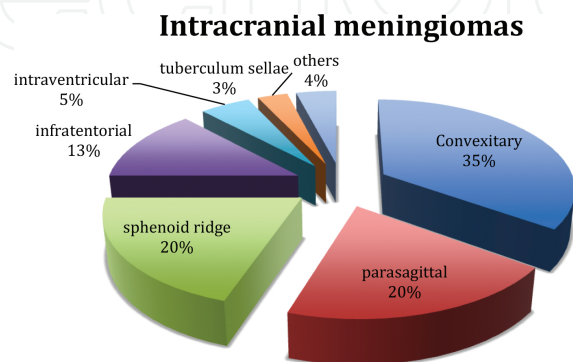


Figure 1. Graphic representation of the topographic distribution of intracranial meningiomas.

According to the 2007 World Health Organization (WHO) classification, meningiomas are divided in three categories: grade I or benign meningiomas, grade II or atypical meningiomas, and grade III or anaplastic meningiomas [11]. With this new grading system, which includes the brain invasion into the diagnostic criteria for aggressiveness, the percentage of atypical meningiomas grew to 20–35% of newly diagnosed meningiomas [13]. This classification is important because, together with the extension of resection, it may help in predicting the recurrence rate and thus the global prognosis [14, 15] (Figure 2).

Recurrence Rate at 5 y

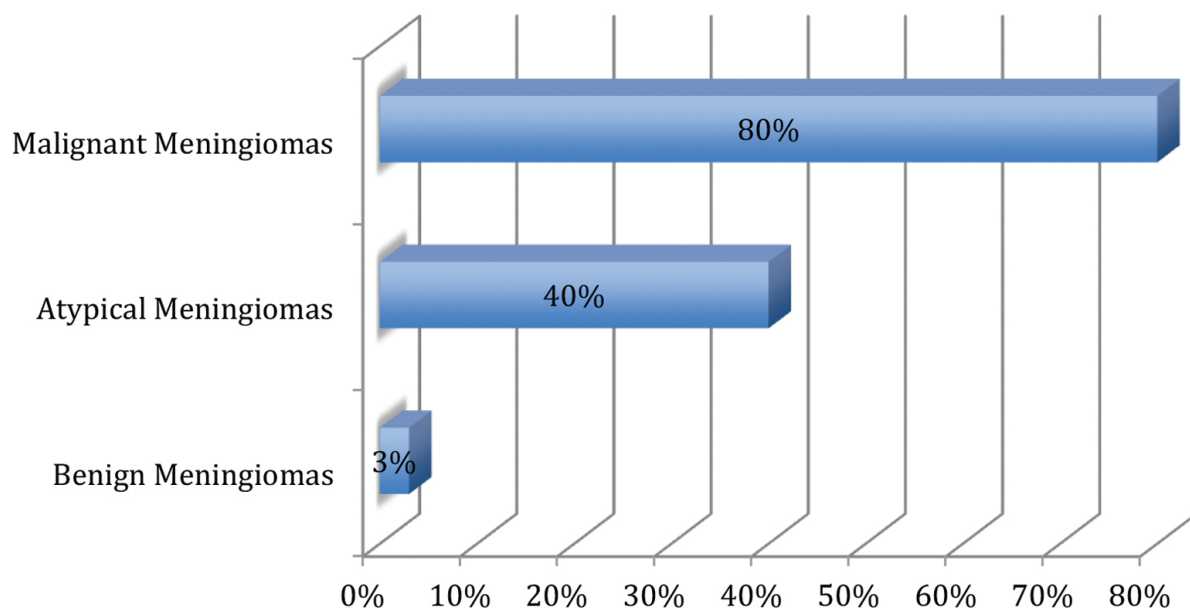


Figure 2. The recurrence rate at 5 years was stratified according to literature data: The recurrence after surgery is strictly related to the histologic grade of the lesion (WHO classification).

3. Clinical presentation

In many cases, meningiomas are asymptomatic and discovered in the context of investigations of unrelated symptoms [16]. When symptomatic they may determine epileptic seizures or focal neurological deficit according to the irritation or the compression of eloquent areas or vasculo-nervous structures. Hydrocephalus may be secondary to meningiomas obstructing the physiologic CSF flow. An increased intracranial pressure may be present in cases of voluminous lesions or with an associated peritumoral edema.

Focal neurological deficit is directly linked to the localization of the tumor, according to the compression of cranial nerves or specific hemispheric regions. Spinal tract compression is also typical for spinal meningiomas.

4. Radiology

Meningiomas present as well-defined extra-axial lesions with a typical peripheral CSF cleft. They present a homogeneous contrast enhancement on CT- and T1-weighted MRI with gadolinium administration. The tumor has a dural or bone implantation and a typical dural tail (contrast enhancement of the dura adjacent to meningioma implantation) (Figures 3 and 4). A reactive sclerosis of the underlying bone may be present in about half of skull-base meningiomas [17]. In rare cases, bone erosion is present (**Figure 5**). Calcifications or cystic portions may be present. Hyperintensity in T2-weighted MRI may denote a higher water content and thus an easily resectability during surgery.

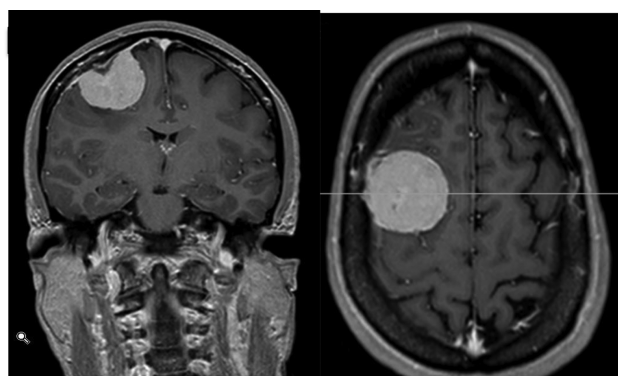


Figure 3. T1-weighted coronal (a) and axial (b) MRI with gadolinium administration showing a well-defined extra-axial lesion with an homogeneous enhancement and a contiguous dural enhancement (dural tail). A subtle CSF cleft is also visible between the lesion and the cerebral surface. These radiologic findings are typical for a convexitary meningioma.

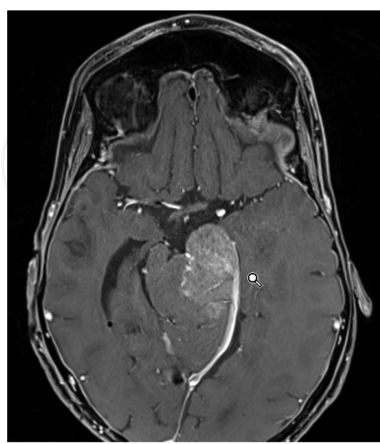


Figure 4. A tentorial meningiomas with less demarcated limits and probably infiltrating the adjacent brainstem. The dural tail is evident in this T1-weighted MRI post gadolinium administration. This 33-year-old patient was irradiated during infancy after the resection of an ependymoma of the IVth ventricle. This may help in explaining the atypical features of the lesion.

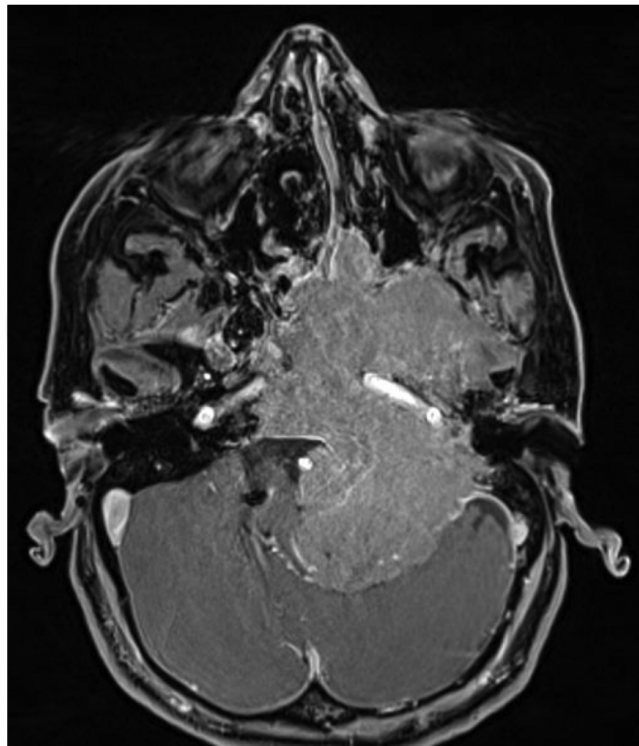


Figure 5. This skull base meningioma completely eroded the skull base and encased the internal carotid artery on the left side. Also the vertebral artery was surrounded by the tumor (not shown). The anatomy was completely modified by the lesion, and a preoperative study of the images was essential to plan the surgery.

Meningiomas may present an associated venous invasion and MRI venography may help in evaluating sinus thrombosis in the preoperative period.

An angiography may be performed in the preoperative period to assess the vascularization of the lesion and the relationship with important vascular structures. Meningiomas are in most of cases vascularized by the meningeal artery supplying the meninges at the tumor sites, and the angiographic blush is also called mother-in-law blush, because it comes early and leaves late. However, because of the risks linked to this invasive procedure, it is often performed in the context of the planning of a preoperative embolization.

5. Genetic and molecular profiles

More than a half of sporadic meningiomas of every histological grade have a mutation in NF2 gene on the chromosome 22q12, coding for merlin (moesin-ezrin-radixin-like protein), and it is considered an early event in tumorigenesis [18]. Merlin seems to interact with trans-membranous proteins to activate pathways promoting cell proliferation. Its expression may vary, however, according to meningioma's subtype [19]. The product of the DAL-1 gene, a member of the protein 4.1 family, has also been supposed to be implicated in meningioma tumorigenesis and progression. The prevalence of mutations of protein 4.1B was not different among WHO grades, and it may be an early event in meningioma tumorigenesis [20].

Aside 22q deletions, multiple genetic mutations are observed in meningioma progression, such as loss of heterozygosity in 1p, 3p, 6q, 9p, 10q, and 14q [21] and are associated with histological progression [22].

Recently, the analysis of microRNAs (miRNAs) profiles was identified as a potential tool to define the natural history of different meningiomas. A low expression of miR-29c-3p and miR-219-5p was associated with more aggressive phenotypes and with a higher risk of recurrence [23]. On the contrary, high expression of miR-145 seems to be associated with a more indolent biological behavior.

Complex karyotypes were found in 34% of benign meningiomas, 45% of atypical, and 70% of anaplastic meningiomas [24].

Proliferative markers such as MIB-1 and Ki67 have been associated with a more aggressive biological behavior in some studies [25, 26]. The relationship between genetic and molecular alterations and recurrence is a matter of debate: According to Sandberg et al. [26], the recurrence rate seems to be associated to proliferative markers and Ki-67 and cyclin B1 genes were overexpressed in recurrent meningiomas [27, 28], with a significant association between Ki-67 and tumor recurrence [29]. Contrasting results exist, however, on this argument, as Aguiar et al. [30] did not find any association between MIB-1 and the histological grade. Other markers have also been investigated, such as p53, TGF α , and β , PDGF [25, 31]. EGFRs are overexpressed in about 60% of meningiomas, while VEGF is also upregulated in meningioma cells but no association with the WHO histological grade was observed [32]. The invasiveness of meningioma cells has been linked to the expression of matrix-metalloproteinase-9 (MMP-9), and its expression may be a prognostic marker for recurrence [33].

In 1979, Donnell et al. [34] were the first to describe the role of estrogen receptors in meningiomas development. However, over the time, progesterone receptors showed to have a higher expression in meningioma cells and their level was correlated to a favorable clinical behavior [35]. Also the expression of E-cadherin was more elevated in benign meningiomas [36].

Furthermore, about 70–100% meningiomas express somatostatin receptors, predominantly the type 2a (hsst2a) [37].

6. Benign meningiomas or WHO grade I meningiomas

In most of cases, WHO grade I meningiomas are diagnosed. They present a benign clinical course, with rare mitoses and occasional pleomorphic nuclei. Various architectural patterns have been described, whose most frequent are meningothelial, fibroblastic, and transitional meningiomas. Meningothelial or syncytial meningiomas are characterized by a high cellular density with cells disposed in packed sheets. Fibroblastic meningiomas are similar to schwannomas, with elongated cells. Cellular whorls and psammoma bodies (mineralized whorls) are most common in the transitional type, which present intermediate features between the meningothelial and the fibroblastic subtype. Other rare variants are the psammomatous meningiomas, characterized by multiple psammoma bodies, the angiomatous meningiomas,

which are extremely vascularized with scarce foci of meningothelial cells and the secretory meningiomas, with lumina formed by cytokeratin-immunoreactive cells and containing PAS positive material.

Benign meningiomas are considered cured, if a complete resection is performed. Thus, a simple surveillance is indicated in cases where a gross total resection is possible (Simpson grade 1 or 2) with serial cerebral MRI, without any complementary treatment. A very small portion of benign meningiomas progresses to more aggressive variants (<2%) [38], but when considering only recurrent tumors, the prevalence becomes significantly higher (14%) [39]. The clinical behavior and the malignant potential of meningioma are still matter of debate. Many authors applied the model of clonal progression to meningiomas with a progressive appearance of more aggressive cellular subpopulations according with the presence of genetic imbalances and molecular modifications [40, 41].

Meningiomas show immunohistochemical positivity for epithelial membrane antigen (EMA) in 80% of cases. They also express other epithelial markers such as vimentin and cytokeratin. Antileu 7 and glial fibrillary acidic protein (GFAP) stains, characteristics for schwannomas and gliomas, respectively, are uniformly negative. Immunohistochemistry may thus help in the differential diagnosis in difficult cases.

An elevated labeling for Ki-67 may denote a more aggressive lesion [42, 43].

7. Atypical meningiomas or WHO grade II

According to the WHO classification of 2007, a growing subset of lesions (about one third) has the histopathological characteristics to be defined atypical, thus showing a more aggressive behavior [13].

The criteria to define atypical meningiomas are independent from meningioma subtype.

Atypical meningiomas are in fact described as lesions with one or more of these characteristics:

- 4–19 mitoses per 10 high power fields (hpf) and/or brain invasion and/or at least three of the following features:

- necrosis
- macronucleoli
- loss of ordered architecture
- hypercellularity
- small cells

Four subtypes of WHO grade II meningiomas have been described [11]: The chordoid meningioma is histologically similar to chordoma, with a mucin-rich stroma and clear vacuoles in epithelioid cells. This pattern is mixed with meningothelial or transitional tumor areas, and it is usually supratentorial. Castleman's disease has been reported in association with this

subtype [44]. The clear cell meningioma is composed by cells with glycogen-rich clear cytoplasm and extensive collagen deposition. This subtype typically occurs in the cauda equina region and in the posterior fossa. A high recurrence rate is characteristic. The atypical meningioma has atypical features and cannot be classified as chordoid or clear cell meningioma.

An association between the survival rate and the extent of resection for atypical meningiomas was confirmed by multiple studies [45, 46]. Even if a maximal resection is the first aim of the surgery, these lesions are often less well delimited and a safe resection is often incomplete because of bone infiltration and vascular invasion. Many studies are actually investigating the real role of adjuvant therapies. In fact both radiotherapy and eventually chemotherapy are not free of side effects and even if they are commonly adopted for malignant meningiomas, the balance benefits–risks is not yet assessed for atypical meningiomas.

8. Anaplastic or malignant meningiomas or WHO grade III

Anaplastic meningiomas may present directly as primary tumors or may derive from a malignant transformation of less aggressive lesions. Malignant meningiomas are characterized by the following [4]:

- 20 or more mitoses/10 hpf
- predominant rhabdoid or papillary morphology

Papillary meningiomas are rare and commonly found in children, characterized by a pseudo-papillary architecture. Rhabdoid meningiomas are formed by cells with eccentric nuclei and paranuclear inclusions.

Anaplastic meningiomas are associated with a high risk of recurrence and distant metastases. The most common sites of extraneural metastases are the liver, lungs, pleura, and lymph nodes.

Surgery aiming to obtain gross total or near total surgical resection represents the first choice, and it is combined with different types of external beam radiotherapy (fractionated or stereotactic radiosurgery) [47, 48]. Anaplastic meningiomas are malignant tumors with a survival limited to 1.5–3.5 years according to most of the series [49]. A better overall survival was observed in cases <60 years old and in patients receiving adjuvant radiotherapy [46]. The role of chemotherapeutic agents is still under investigation, and the debate is open in particular for somatostatin analogues [50, 51].

9. Management

9.1. Surgery

The mainstay of the treatment for symptomatic or enlarging meningiomas of every histological grade is the surgical excision. A complete surgical excision of the tumor and of the surrounding dural attachment is recommended and may be curative. Furthermore surgery allows a pathological diagnosis, may improve the symptoms, and relieve the mass effect. The extent of surgical resection was first classified by Simpson [52], and it is strongly associated to the recurrence rate (Table 1). The term “Simpson grade 0” was also coniated, to define a total resection of the tumor, of the infiltrated dura and of the hyperostotic bone, with a 2 cm of free margins [53]. A complete resection (Simpson I) may not always be performed because of the localization/size of the tumor and their relationship with neurovascular structures. Thus, the highest recurrence rate was described in patients with sphenoid wing meningiomas, followed by parasagittal meningiomas. En plaque meningiomas, with a flat extension in the subdural space, may also be difficult to resect completely. However, according to a recent study, patients with skull base meningiomas present at a younger age and lesions have often a more indolent behavior [54].

Simpson grade	Extent of resection	Recurrence rate at 5 years
0	Total removal of the tumor, dural attachment, and infiltrated bone with additional resection of a 2-cm dural margin	0%
1	Total removal of the tumor, dural attachment, and infiltrated bone	9%
2	Total removal of the tumor, dural attachment coagulated	19%
3	Total removal of the tumor, without resection nor coagulation of the dura/infiltrated bone	29%
4	Partial resection of the tumor	39%
5	Decompression (biopsy)	Ns
Modified according to Kinjo et al. [53].		

Table 1. Simpson grade classifying the extent of resection for meningiomas.

More aggressive meningiomas may present with associated brain invasion, venous sinuses invasion or less defined limits, thus rendering the complete resection more challenging. The minimization of postoperative neurological deficit is one of the main goals of neurosurgeons, thus respecting neurovascular structures and the extent of resection should be balanced with the risk of postoperative disability. In the most complex cases, thus, a subtotal resection may be performed and a residue is left in place, which will be followed or treated with adjuvant radiotherapy, as fractionated external beam or stereotactic radiotherapy.

The extent of resection being a key predictor of recurrence, a long-term follow-up is essential, especially in cases of subtotal resection.

9.2. Radiotherapy

Radiotherapy has been advocated as primary therapeutic option in cases, where the surgical excision was judged too risky because of the considerable postoperative neurological morbidities or as complementary treatment after surgery [55]. Several options of radiation therapies are available to treat meningiomas, such as photon-based stereotactic radiosurgery and hypofractionated radiation therapy. Positive results with radiation therapy have been observed in cases of incomplete resection [56, 57] or recurrence [58].

Furthermore interesting results have been found with cavernous sinus meningiomas [59] or parasagittal meningiomas [60] involving the posterior third of the superior sagittal sinus. Patients treated with a combined approach (subtotal resection followed by stereotactic radiosurgery) experienced a progression-free survival similar to the subgroup where GTR was achieved.

To summarize the most recent literature evidences, the adjuvant use of radiotherapy after the resection of grade III meningiomas is well established, while it is still matter of debate after gross total resection of grade II meningiomas. Aghi et al. [61] showed how immediate adjuvant radiation therapy may improve overall survival and reduce local recurrence with atypical meningiomas. However, no randomized controlled or prospective studies exist and the level of evidence is thus low. Some authors suggest in fact that a close follow-up is sufficient after GTR of atypical meningiomas, thus avoiding the risk of side effects of radiotherapy. Sun et al. [47] suggested that the analysis of histopathological features of aggressiveness, such as brain invasion and the MIB-1 index, to decide of a complementary treatment should be administered.

A dose of 60 Gy is generally considered beneficial for fractionated radiotherapy after subtotal resections and many centers administer hypofractionated radiotherapy, with doses of 1, 8, or 2 Gy per fraction, to diminish the risk of long-term neurotoxicity. After gross total resections, some authors suggest the possibility to lower the doses to 54 Gy (RTOG trial N°0539). The EORTC trial N°22042-26042 is actually investigating the benefit of 60 Gy after GTR, with an additional boost of 10 Gy after STR. The same doses seem to be advantageous with proton-beam therapy [62].

Further indications for radiation therapy are as follows: As adjuvant treatment after the incomplete resection of a meningioma or with recurrent tumors whose surgical removal of the residue will bring important potential neurological morbidities or with inoperable lesions.

The limitation of fractionated radiotherapy and stereotactic radiosurgery are linked to the tumor size and to the radiation neurotoxicity, with a risk of necrosis, cerebral edema and damage of critical neurovascular structures with consequent cranial nerve palsy [48]. Recent progresses in the field of conformational radiotherapy and stereotactic radiotherapy allow a better definition of the target, thus limiting the dose to the normal tissue and delivering a more focused dose on the resection bed/residual meningioma.

Other radiation-induced complications described in literature are the risk of secondary malignancy or of tumor progression [63, 64].

9.3. Chemotherapy

The development of new medical options for recurrent or aggressive meningiomas is strongly dependent from progresses made in the understanding of molecular pathways. The role of classic chemotherapeutic agents is disappointing [65]. Temozolomide showed no efficacy on refractory meningiomas according to Chamberlain et al. [66], and its efficacy seems to be linked to the functionality of the enzyme O6-methylguanine-DNA-methyltransferase [67]. Hydroxyurea showed preliminary favorable results in recurrent and radiation refractory meningiomas [68], but the study was conducted in a limited number of patients. The study of Chamberlain et al. [69] on the contrary showed a limited efficacy. Contrasting results exist on the efficacy of irinotecan on preclinical studies [70].

Multiple targeted therapies have been tried in preclinical and clinical trials. In the animal model, the use of mTOR inhibitors such as temsirolimus and everolimus showed a reduced growth rate in meningioma cells [71]. On the contrary, the application of EGFR inhibitors (gefitinib and erlotinib) did not show a significant benefit in patients with refractory meningiomas [72]. The most famous monoclonal antibody binding VEGFB, bevacizumab, was also investigated by Lou et al. [73] in a population of recurrent/progressive meningiomas, and a positive response was obtained in recurrent meningiomas. The benefit of this therapy was, however, not clear in the study of Nunes et al. [74]. Two ongoing trials will evaluate the efficacy of bevacizumab in a phase II trial (NCT01125046) and its association with everolimus in a cohort of recurrent/progressive meningiomas (NCT00972335). In preclinical studies sunitinib, a PDGFRB inhibitor may inhibit cellular migration in vitro [75]. Encouraging results from the use of sunitinib were also obtained in a cohort of patients with malignant meningiomas [50].

Hormonal therapies have been widely investigated as cytostatic therapies after the discovery of the association between meningioma incidence and hyperestrogenic and hyperprogestin conditions [18]. Mifepristone (RU-486) is an antagonist of progesterone receptors, and it is the most widely investigated agent in the oncologic field. Clinical studies on its efficacy show, however, contrasting results [7, 76, 77], and only minor evidences exist to recommend mifepristone with inoperable progressive meningiomas, after consideration of the histological grade of the tumor and progesterone receptor expression [78]. Positive preliminary results were obtained with diffuse meningiomatosis [79].

Immunohistochemical studies showed a high prevalence of somatostatin receptor (SSTR) expression in meningiomas, in particular of SSTR2A. The sandostatin LAR was tested in a prospective trial including recurrent meningiomas, with a partial radiological response in one third of patients [80]. However, pasireotide, an analogue with a wider affinity for multiple subtypes of SSTR, showed no benefit in recurrent meningiomas [51].

In conclusion, up to date chemotherapeutic agents and hormonal therapies shows a limited efficacy in the management of recurrent/progressive and more aggressive meningiomas and the field of investigation remains large. The nanotechnology, combined with the most recent

targeted therapies, may actually represent a revolution in the targeting, transport and delivering of chemotherapeutic agents [81], thus opening new ways for the treatment of these tumors.

10. Conclusions

Meningiomas were classically considered benign tumors. However, according to the new WHO classification, the proportion of more aggressive variants has steeply increased and thus the management has become more challenging. Surgery represents the mainstay of the treatment and a complete resection may be considered curative in WHO grade I meningiomas. However, neurosurgeons have often to deal with the risk of postoperative neurological morbidities and the role of adjuvant treatments, such as radiotherapy and chemotherapy, after subtotal resection or after the pathological confirmation of WHO grade II or III meningiomas, is actually being defined. A huge literature dealing with adjuvant radiotherapy and new cytostatic agents is developing, with the aim of obtaining an optimal long-term control. Up to now, treatments are empirically based and many hopes reside in new prospective and randomized controlled trials to better define the role of each therapeutic strategy and the best way to combine them.

Author details

Giulia Cossu^{1*}, Mahmoud Messerer^{1,2}, Fabrice Parker², Marc Levivier¹ and Roy Thomas Daniel¹

*Address all correspondence to: giulia.cossu@chuv.ch

1 Department of Clinical Neurosciences, Faculty of Medicine and Biology of Lausanne, Lausanne University Hospital, Lausanne, Switzerland

2 Department of Neurosurgery, Faculty of Medicine of Paris Sud, Kremlin-Bicêtre University Hospital, Le Kremlin-Bicêtre, France

References

- [1] Claus EB, Bondy ML, Schildkraut JM, Wiemels JL, Wrensch M, Black PM. Epidemiology of intracranial meningioma. *Neurosurgery*. 2005;57(6):1088–95; discussion 95.
- [2] Cushing H. The meningiomas (dural endotheliomas): their source, and favoured seats of origin. *Brain: a Journal of Neurology*. 1922;45:282.

- [3] Cushing HW, Weed LH. Calcareous and osseous deposits in the arachnoidea. Studies in the cerebro-spinal fluid and its pathway. *Bull Johns Hopkins Hosp* 1915; No. IX. 26:367.
- [4] Louis DN, Ohgaki H, Wiestler OD, Cavenee WK, Burger PC, Jouvet A, et al. The 2007 WHO classification of tumours of the central nervous system. *Acta Neuropathologica*. 2007;114(2):97–109.
- [5] Longstreth WT, Jr., Dennis LK, McGuire VM, Drangsholt MT, Koepsell TD. Epidemiology of intracranial meningioma. *Cancer*. 1993;72(3):639–48.
- [6] Nakasu S, Hirano A, Shimura T, Llena JF. Incidental meningiomas in autopsy study. *Surgical Neurology*. 1987;27(4):319–22.
- [7] Grunberg SM, Weiss MH, Spitz IM, Ahmadi J, Sadun A, Russell CA, et al. Treatment of unresectable meningiomas with the antiprogestosterone agent mifepristone. *Journal of Neurosurgery*. 1991;74(6):861–6.
- [8] Schoenberg BS, Christine BW, Whisnant JP. Nervous system neoplasms and primary malignancies of other sites. The unique association between meningiomas and breast cancer. *Neurology*. 1975;25(8):705–12.
- [9] Roelvink NC, Kamphorst W, van Alphen HA, Rao BR. Pregnancy-related primary brain and spinal tumors. *Archives of Neurology*. 1987;44(2):209–15.
- [10] Bellur SN, Chandra V, Anderson RJ. Association of meningiomas with obesity. *Annals of Neurology*. 1983;13(3):346–7.
- [11] Perry A, Louis DN, Scheithauer BW, Budka H, Von Deiming A. The 2007 WHO classification of tumours of the central nervous system. *Acta Neuropathologica*. 2007;114(2):97–109.
- [12] Falleni M, Roz E, Dessy E, Del Curto B, Braidotti P, Gianelli U, et al. Primary intrathoracic meningioma: histopathological, immunohistochemical and ultrastructural study of two cases. *Virchows Archiv: an International Journal of Pathology*. 2001;439(2):196–200.
- [13] Pearson BE, Markert JM, Fisher WS, Guthrie BL, Fiveash JB, Palmer CA, et al. Hitting a moving target: evolution of a treatment paradigm for atypical meningiomas amid changing diagnostic criteria. *Neurosurgical Focus*. 2008;24(5):E3.
- [14] Nakasu S, Fukami T, Jito J, Nozaki K. Recurrence and regrowth of benign meningiomas. *Brain Tumor Pathology*. 2009;26(2):69–72.
- [15] Yang SY, Park CK, Park SH, Kim DG, Chung YS, Jung HW. Atypical and anaplastic meningiomas: prognostic implications of clinicopathological features. *Journal of Neurology, Neurosurgery, and Psychiatry*. 2008;79(5):574–80.
- [16] Nakamura M, Roser F, Michel J, Jacobs C, Samii M. The natural history of incidental meningiomas. *Neurosurgery*. 2003;53(1):62–70; discussion 1.

- [17] Pieper DR, Al-Mefty O, Hanada Y, Buechner D. Hyperostosis associated with meningioma of the cranial base: secondary changes or tumor invasion. *Neurosurgery*. 1999;44(4):742–6; discussion 6–7.
- [18] Chen JA, Coutin-Churchman PE, Nuwer MR, Lazareff JA. Suboccipital craniotomy for Chiari I results in evoked potential conduction changes. *Surgical Neurology International*. 2012;3:165.
- [19] Stamenkovic I, Yu Q. Merlin, a “magic” linker between extracellular cues and intracellular signaling pathways that regulate cell motility, proliferation, and survival. *Current Protein & Peptide Science*. 2010;11(6):471–84.
- [20] Gutmann DH, Donahoe J, Perry A, Lemke N, Gorse K, Kittiniyom K, et al. Loss of DAL-1, a protein 4.1-related tumor suppressor, is an important early event in the pathogenesis of meningiomas. *Human Molecular Genetics*. 2000;9(10):1495–500.
- [21] Watson MA, Gutmann DH, Peterson K, Chicoine MR, Kleinschmidt-DeMasters BK, Brown HG, et al. Molecular characterization of human meningiomas by gene expression profiling using high-density oligonucleotide microarrays. *The American Journal of Pathology*. 2002;161(2):665–72.
- [22] Cai DX, Banerjee R, Scheithauer BW, Lohse CM, Kleinschmidt-Demasters BK, Perry A. Chromosome 1p and 14q FISH analysis in clinicopathologic subsets of meningioma: diagnostic and prognostic implications. *Journal of Neuropathology and Experimental Neurology*. 2001;60(6):628–36.
- [23] Zhi F, Zhou G, Wang S, Shi Y, Peng Y, Shao N, et al. A microRNA expression signature predicts meningioma recurrence. *International Journal of Cancer*. 2013;132(1):128–36.
- [24] Cerda-Nicolas M, Lopez-Gines C, Perez-Bacete M, Barcia-Salorio JL, Llombart-Bosch A. Histopathological and cytogenetic findings in benign, atypical and anaplastic human meningiomas: a study of 60 tumors. *Journal of Neuro-oncology*. 2000;47(2):99–108.
- [25] Amatya VJ, Takeshima Y, Sugiyama K, Kurisu K, Nishisaka T, Fukuhara T, et al. Immunohistochemical study of Ki-67 (MIB-1), p53 protein, p21WAF1, and p27KIP1 expression in benign, atypical, and anaplastic meningiomas. *Human Pathology*. 2001;32(9):970–5.
- [26] Sandberg DI, Edgar MA, Resch L, Rutka JT, Becker LE, Souweidane MM. MIB-1 staining index of pediatric meningiomas. *Neurosurgery*. 2001;48(3):590–5; discussion 5–7.
- [27] Bie L, Zhao G, Ju Y, Zhang B. Integrative genomic analysis identifies CCNB1 and CDC2 as candidate genes associated with meningioma recurrence. *Cancer Genetics*. 2011;204(10):536–40.
- [28] Perez-Magan E, Rodriguez de Lope A, Ribalta T, Ruano Y, Campos-Martin Y, Perez-Bautista G, et al. Differential expression profiling analyses identifies downregulation

of 1p, 6q, and 14q genes and overexpression of 6p histone cluster 1 genes as markers of recurrence in meningiomas. *Neuro-oncology*. 2010;12(12):1278–90.

- [29] Ho DM, Hsu CY, Ting LT, Chiang H. Histopathology and MIB-1 labeling index predicted recurrence of meningiomas: a proposal of diagnostic criteria for patients with atypical meningioma. *Cancer*. 2002;94(5):1538–47.
- [30] Aguiar PH, Tsanaclis AM, Tella OI, Jr., Plese JP. Proliferation rate of intracranial meningiomas as defined by the monoclonal antibody MIB-1: correlation with peritumoural oedema and other clinicoradiological and histological characteristics. *Neurosurgical Review*. 2003;26(3):221–8.
- [31] Nagashima G, Asai J, Suzuki R, Fujimoto T. Different distribution of c-myc and MIB-1 positive cells in malignant meningiomas with reference to TGFs, PDGF, and PgR expression. *Brain Tumor Pathology*. 2001;18(1):1–5.
- [32] Barresi V, Tuccari G. Increased ratio of vascular endothelial growth factor to semaphorin3A is a negative prognostic factor in human meningiomas. *Neuropathology*. 2010;30(5):537–46.
- [33] Barresi V, Vitarelli E, Tuccari G, Barresi G. MMP-9 expression in meningiomas: a prognostic marker for recurrence risk? *Journal of Neuro-oncology*. 2011;102(2):189–96.
- [34] Donnell MS, Meyer GA, Donegan WL. Estrogen-receptor protein in intracranial meningiomas. *Journal of Neurosurgery*. 1979;50(4):499–502.
- [35] Hsu DW, Efird JT, Hedley-Whyte ET. Progesterone and estrogen receptors in meningiomas: prognostic considerations. *Journal of Neurosurgery*. 1997;86(1):113–20.
- [36] Schwechheimer K, Zhou L, Birchmeier W. E-Cadherin in human brain tumours: loss of immunoreactivity in malignant meningiomas. *Virchows Archiv: an International Journal of Pathology*. 1998;432(2):163–7.
- [37] Schulz S, Pauli SU, Schulz S, Handel M, Dietzmann K, Firsching R, et al. Immunohistochemical determination of five somatostatin receptors in meningioma reveals frequent overexpression of somatostatin receptor subtype sst2A. *Clinical Cancer Research*. 2000;6(5):1865–74.
- [38] Lamszus K, Kluwe L, Matschke J, Meissner H, Laas R, Westphal M. Allelic losses at 1p, 9q, 10q, 14q, and 22q in the progression of aggressive meningiomas and undifferentiated meningeal sarcomas. *Cancer Genetics and Cytogenetics*. 1999;110(2):103–10.
- [39] Jaaskelainen J, Haltia M, Servo A. Atypical and anaplastic meningiomas: radiology, surgery, radiotherapy, and outcome. *Surgical Neurology*. 1986;25(3):233–42.
- [40] Al-Mefty O, Kadri PA, Pravdenkova S, Sawyer JR, Stangeby C, Husain M. Malignant progression in meningioma: documentation of a series and analysis of cytogenetic findings. *Journal of Neurosurgery*. 2004;101(2):210–8.
- [41] Nowell PC. Mechanisms of tumor progression. *Cancer Research*. 1986;46(5):2203–7.

- [42] Hsu DW, Efird JT, Hedley-Whyte ET. MIB-1 (Ki-67) index and transforming growth factor-alpha (TGF alpha) immunoreactivity are significant prognostic predictors for meningiomas. *Neuropathology and Applied Neurobiology*. 1998;24(6):441–52.
- [43] Cobb MA, Husain M, Andersen BJ, al-Mefty O. Significance of proliferating cell nuclear antigen in predicting recurrence of intracranial meningioma. *Journal of Neurosurgery*. 1996;84(1):85–90.
- [44] Kepes JJ, Chen WY, Connors MH, Vogel FS. “Chordoid” meningeal tumors in young individuals with peritumoral lymphoplasmacellular infiltrates causing systemic manifestations of the Castleman syndrome. A report of seven cases. *Cancer*. 1988;62(2):391–406.
- [45] Palma L, Celli P, Franco C, Cervoni L, Cantore G. Long-term prognosis for atypical and malignant meningiomas: a study of 71 surgical cases. *Journal of Neurosurgery*. 1997;86(5):793–800.
- [46] Durand A, Labrousse F, Jouvett A, Bauchet L, Kalamarides M, Menei P, et al. WHO grade II and III meningiomas: a study of prognostic factors. *Journal of Neuro-oncology*. 2009;95(3):367–75.
- [47] Sun SQ, Hawasli AH, Huang J, Chicoine MR, Kim AH. An evidence-based treatment algorithm for the management of WHO Grade II and III meningiomas. *Neurosurgical Focus*. 2015;38(3):E3.
- [48] Walcott BP, Nahed BV, Brastianos PK, Loeffler JS. Radiation Treatment for WHO Grade II and III Meningiomas. *Frontiers in Oncology*. 2013;3:227.
- [49] Champeaux C, Wilson E, Brandner S, Shieff C, Thorne L. World Health Organization grade III meningiomas. A retrospective study for outcome and prognostic factors assessment. *British Journal of Neurosurgery*. 2015:1–6.
- [50] Kaley TJ, Wen P, Schiff D, Ligon K, Haidar S, Karimi S, et al. Phase II trial of sunitinib for recurrent and progressive atypical and anaplastic meningioma. *Neuro-oncology*. 2015;17(1):116–21.
- [51] Norden AD, Ligon KL, Hammond SN, Muzikansky A, Reardon DA, Kaley TJ, et al. Phase II study of monthly pasireotide LAR (SOM230C) for recurrent or progressive meningioma. *Neurology*. 2015;84(3):280–6.
- [52] Simpson D. The recurrence of intracranial meningiomas after surgical treatment. *Journal of Neurology, Neurosurgery, and Psychiatry*. 1957;20(1):22–39.
- [53] Kinjo T, al-Mefty O, Kanaan I. Grade zero removal of supratentorial convexity meningiomas. *Neurosurgery*. 1993;33(3):394–9; discussion 9.
- [54] Mansouri A, Klironomos G, Taslimi S, Kilian A, Gentili F, Khan OH, et al. Surgically resected skull base meningiomas demonstrate a divergent postoperative recurrence

- pattern compared with non-skull base meningiomas. *Journal of Neurosurgery*. 2016;1–10.
- [55] Starke RM, Williams BJ, Jane JA, Jr., Sheehan JP. Gamma Knife surgery for patients with nonfunctioning pituitary macroadenomas: predictors of tumor control, neurological deficits, and hypopituitarism. *Journal of Neurosurgery*. 2012;117(1):129–35.
 - [56] Goldsmith BJ, Wara WM, Wilson CB, Larson DA. Postoperative irradiation for subtotally resected meningiomas. A retrospective analysis of 140 patients treated from 1967 to 1990. *Journal of Neurosurgery*. 1994;80(2):195–201.
 - [57] Barbaro NM, Gutin PH, Wilson CB, Sheline GE, Boldrey EB, Wara WM. Radiation therapy in the treatment of partially resected meningiomas. *Neurosurgery*. 1987;20(4):525–8.
 - [58] Kokubo M, Shibamoto Y, Takahashi JA, Sasai K, Oya N, Hashimoto N, et al. Efficacy of conventional radiotherapy for recurrent meningioma. *Journal of Neuro-oncology*. 2000;48(1):51–5.
 - [59] Wang YC, Chuang CC, Wei KC, Hsu YH, Hsu PW, Lee ST, et al. Skull base atypical meningioma: Long term surgical outcome and prognostic factors. *Clinical Neurology and Neurosurgery*. 2015;128:112–6.
 - [60] Kondziolka D, Flickinger JC, Perez B. Judicious resection and/or radiosurgery for parasagittal meningiomas: outcomes from a multicenter review. Gamma Knife Meningioma Study Group. *Neurosurgery*. 1998;43(3):405–13; discussion 13–4.
 - [61] Aghi MK, Carter BS, Cosgrove GR, Ojemann RG, Amin-Hanjani S, Martuza RL, et al. Long-term recurrence rates of atypical meningiomas after gross total resection with or without postoperative adjuvant radiation. *Neurosurgery*. 2009;64(1):56–60; discussion.
 - [62] Boskos C, Feuvret L, Noel G, Habrand JL, Pommier P, Alapetite C, et al. Combined proton and photon conformal radiotherapy for intracranial atypical and malignant meningioma. *International Journal of Radiation Oncology, Biology, Physics*. 2009;75(2):399–406.
 - [63] Kaido T, Hoshida T, Uranishi R, Akita N, Kotani A, Nishi N, et al. Radiosurgery-induced brain tumor. Case report. *Journal of Neurosurgery*. 2001;95(4):710–3.
 - [64] Sheehan J, Yen CP, Steiner L. Gamma knife surgery-induced meningioma. Report of two cases and review of the literature. *Journal of Neurosurgery*. 2006;105(2):325–9.
 - [65] Sherman WJ, Raizer JJ. Chemotherapy: What is its role in meningioma? *Expert Review of Neurotherapeutics*. 2012;12(10):1189–95; quiz 96.
 - [66] Chamberlain MC, Tsao-Wei DD, Groshen S. Temozolomide for treatment-resistant recurrent meningioma. *Neurology*. 2004;62(7):1210–2.

- [67] de Robles P, McIntyre J, Kalra S, Roldan G, Cairncross G, Forsyth P, et al. Methylation status of MGMT gene promoter in meningiomas. *Cancer Genetics and Cytogenetics*. 2008;187(1):25–7.
- [68] Schrell UM, Rittig MG, Anders M, Kiesewetter F, Marschalek R, Koch UH, et al. Hydroxyurea for treatment of unresectable and recurrent meningiomas. I. Inhibition of primary human meningioma cells in culture and in meningioma transplants by induction of the apoptotic pathway. *Journal of Neurosurgery*. 1997;86(5):845–52.
- [69] Chamberlain MC, Johnston SK. Hydroxyurea for recurrent surgery and radiation refractory meningioma: a retrospective case series. *Journal of Neuro-oncology*. 2011;104(3):765–71.
- [70] Gupta V, Su YS, Samuelson CG, Liebes LF, Chamberlain MC, Hofman FM, et al. Irinotecan: a potential new chemotherapeutic agent for atypical or malignant meningiomas. *Journal of Neurosurgery*. 2007;106(3):455–62.
- [71] Pachow D, Andrae N, Kliese N, Angenstein F, Stork O, Wilisch-Neumann A, et al. mTORC1 inhibitors suppress meningioma growth in mouse models. *Clinical Cancer Research*. 2013;19(5):1180–9.
- [72] Norden AD, Raizer JJ, Abrey LE, Lamborn KR, Lassman AB, Chang SM, et al. Phase II trials of erlotinib or gefitinib in patients with recurrent meningioma. *Journal of Neuro-oncology*. 2010;96(2):211–7.
- [73] Lou E, Sumrall AL, Turner S, Peters KB, Desjardins A, Vredenburg JJ, et al. Bevacizumab therapy for adults with recurrent/progressive meningioma: a retrospective series. *Journal of Neuro-oncology*. 2012;109(1):63–70.
- [74] Nunes FP, Merker VL, Jennings D, Caruso PA, di Tomaso E, Muzikansky A, et al. Bevacizumab treatment for meningiomas in NF2: a retrospective analysis of 15 patients. *Plos One*. 2013;8(3):e59941.
- [75] Pfister C, Pfrommer H, Tatagiba MS, Roser F. Vascular endothelial growth factor signals through platelet-derived growth factor receptor beta in meningiomas in vitro. *British Journal of Cancer*. 2012;107(10):1702–13.
- [76] Grunberg SM, Weiss MH, Russell CA, Spitz IM, Ahmadi J, Sadun A, et al. Long-term administration of mifepristone (RU486): clinical tolerance during extended treatment of meningioma. *Cancer Investigation*. 2006;24(8):727–33.
- [77] Lamberts SW, Tanghe HL, Avezaat CJ, Braakman R, Wijngaarde R, Koper JW, et al. Mifepristone (RU 486) treatment of meningiomas. *Journal of Neurology, Neurosurgery, and Psychiatry*. 1992;55(6):486–90.
- [78] Cossu G, Levivier M, Daniel RT, Messerer M. The Role of mifepristone in meningiomas management: a systematic review of the literature. *BioMed Research International*. 2015;2015:267831.

- [79] Touat M, Lombardi G, Farina P, Kalamarides M, Sanson M. Successful treatment of multiple intracranial meningiomas with the antiprogesterone receptor agent mifepristone (RU486). *Acta Neurochirurgica*. 2014;156(10):1831–5.
- [80] Chamberlain MC, Glantz MJ, Fadul CE. Recurrent meningioma: salvage therapy with long-acting somatostatin analogue. *Neurology*. 2007;69(10):969–73.
- [81] Caruso G, Elbabaa SK, Gonzalez-Lopez P, Barresi V, Passalacqua M, Caffo M. Innovative therapeutic strategies in the treatment of meningioma. *Anticancer Research*. 2015;35(12):6391–400.

