

We are IntechOpen, the world's leading publisher of Open Access books Built by scientists, for scientists

6,900

Open access books available

185,000

International authors and editors

200M

Downloads

Our authors are among the

154

Countries delivered to

TOP 1%

most cited scientists

12.2%

Contributors from top 500 universities



WEB OF SCIENCE™

Selection of our books indexed in the Book Citation Index
in Web of Science™ Core Collection (BKCI)

Interested in publishing with us?
Contact book.department@intechopen.com

Numbers displayed above are based on latest data collected.
For more information visit www.intechopen.com



Nonsurgical Rhinoplasty

Alexander Z. Rivkin

Additional information is available at the end of the chapter

<http://dx.doi.org/10.5772/62065>

Abstract

The goal of this chapter is to acquaint the experienced injector with the technique of Non-surgical Rhinoplasty (NSR). This is an advanced technique and I am assuming that readers will be thoroughly familiar with how to perform cosmetic injections. I am also assuming that readers are knowledgeable about the various fillers and injectables available today in the United States.

NSR provides the first noninvasive alternative to surgical rhinoplasty, accomplishing the cosmetic goals of contour improvement without the risks and downtime of surgery. NSR is not a replacement for rhinoplasty and is appropriate in a specific subgroup of rhinoplasty candidates, which will be characterized. The procedure is currently being performed in a variety of ways, as described in the literature review. This chapter will detail the optimal methods of carrying out NSR based on a 10-year, 2500-patient experience with the technique. Discussion will also include critical safety concerns, tips on how to get the best results possible, and complication management. Being prepared for complications is a particular concern with NSR because timely intervention is so critical in cases of ischemic events. Patient selection, knowledge of the anatomy, meticulous technique, and a focus on safety is the key to success with this procedure. Overall, NSR is safe, precise, effective, and versatile. My patients are thrilled with their results, and I have made it the foundation of a thriving practice.

Keywords: Rhinoplasty, injection, nonsurgical, Artefill, methyl methacrylate, Radiesse, calcium hydroxylapatite, Voluma, hyaluronic acid, Restylane, Juvederm, nose job, necrosis, vascular embolism, ischemia, plastic surgery

1. Introduction

Surgical rhinoplasty remains one of the most popular cosmetic procedures performed on the face. Statistics from the American Academy of Facial Plastic Surgery and the American Society of Aesthetic Plastic Surgery put the number of rhinoplasties performed in the United States in

2012 at around 190,000 [1,2]. This number is relatively unchanged from what it was in 1997, prior to the FDA approval of cosmetic botulinum toxin and hyaluronic acid fillers. As with any surgical procedure, patients undergoing rhinoplasty are subject to significant risks, recovery time and expense. Until recently, patients who wanted to avoid surgery have never had a viable alternative procedure that could accomplish the cosmetic goals of rhinoplasty noninvasively. With the advent of long-lasting injectable fillers, however, physicians and patients have embraced a nonsurgical surrogate.

I first performed primary Nonsurgical Rhinoplasty (NSR) using calcium hydroxyapatite injectable filler in 2003, prior to the publication or report of such a procedure being done in the United States. The novelty of the procedure caught the attention of the media, and I performed it on several prominent national news programs and shows. This sparked the interest of the public and doctors around the country began to offer NSR to their patients. Several small studies have documented the safety and efficacy of the procedure since then [3,4,5]. Due to the simplicity and efficacy of NSR, it has steadily grown in popularity over the last decade. Since 2003, I have had the privilege to perform over 2500 of these procedures in my clinic, using a variety of injectable fillers, with great success.

2. History

The idea of injecting substances under the nasal skin to improve cosmesis is not new. Corning and Gersuny first described injecting liquid paraffin into the nose to correct saddle nose deformity at the beginning of the nineteenth century. The practice was quickly embraced but just as quickly abandoned because of the severe long-term adverse effects of paraffin [6]. In 1919, Bruning tried to correct postoperative cosmetic nasal imperfections with fat injection [7]. The technique was ultimately not very well accepted because the fat grafts showed poor survival duration [8]. In 1986, Webster presented a 20-year retrospective study of microdroplet silicone injection into the nasal bridge to correct postsurgical nasal defects [9]. The study reported mostly positive results, but many physicians, aware of horrific reports of complications from the 1960s and 1970s, have remained wary of silicone injections.

The first modern study of NSR was published by Han *et al.* in 2006 [10]. It was an 11-patient pilot study, looking at the safety and efficacy of dorsal augmentation NSR using hyaluronic acid (Restylane, Medicis, Scottsdale, Ariz.) mixed with autologous fibroblasts. Hyaluronic acid (HA) is a glycosaminoglycan that is a major component of connective, dermal, and neural tissue in most mammals. Cross-linked HA has been widely used as an injectable filler since it was FDA approved in 2003. Because of its biocompatibility, no allergy testing is required. The HA in Restylane is produced by bacterial fermentation. The authors injected an average of 0.8 cc into the nasal dorsum of their patients, overcorrecting by 20%. Of the 6 patients that Han *et.al* were able to get follow-up data on, there were no adverse events and the augmentation effect was still persisting at 12 months. Later that year, Beer published a case report where he successfully corrected a dorsal cosmetic defect with Restylane [11].

Also that year, *Laryngoscope* published a report by Nyte where he successfully injected calcium hydroxyapatite (CaHA, Radiesse, Merz, San Mateo, CA) to correct collapse of the internal nasal valve in 23 patients [12]. Radiesse is a suspension of 30% of CaHA microspheres, 25–45µm in size, in a mix of glycerin, carboxymethyl-cellulose, and water. It is fully biocompatible because CaHA is identical to the mineral portion of human bone and teeth [13]. Radiesse was first approved as a radiologic marker and for use in vocal fold augmentation. FDA approval for cosmetic use came in 2006. Nyte's technique of injecting through the inside of the nose seemed to show some cosmetic correction along with the functional improvement. This is, however, the only study that advocated intranasal injection.

Several papers emerged in the next year, including two small studies of Radiesse for cosmetic improvement of the nose. In the paper by Stupak *et al.*, the authors reported on a 13-patient prospective single-arm trial with blinded evaluators of before and after pictures [5]. They injected post-rhinoplasty patients seeking minor contour improvement. Areas injected included dorsum, supratip, nasal sidewall, and ala. Mean amount injected was 0.18cc. They did not inject the nasal tip due to concern that Radiesse would diffuse after injection and the tip would lose definition. There were no adverse events and patient satisfaction and evaluator ratings were good, but follow-up was only 2 months. Dayan *et al.* described their experience with Radiesse NSR in 8 patients over the span of 2 years [14]. The volume they used ranged from 0.3cc to 1.6cc and the corrections were mostly to the dorsum, radix, and supratip. Duration of effect was estimated to be around 1 year. They encountered no complications. At the end of their paper they made a point of mentioning that Dayan had performed revision rhinoplasty on a patient who had received Radiesse 14 months earlier without complication.

The other paper that year was by De LaCerde *et al.* from Brazil [15]. They presented a 2-patient experience with NSR using small amounts of porcine collagen on one patient (0.35 cc) and hyaluronic acid (Voluma, Allergan, Irvine, Calif.) on the other (0.20 cc); follow-up was 4 months and 1 year, respectively. Areas injected included the nasofrontal angle, nasolabial angle, the dorsum, and the tip.

In 2009, Humphrey and Dayan published a paper describing their preferences and techniques of NSR in 22 patients with HA and an unspecified number with CaHA [16]. They advocated using CaHA over HA because the latter absorbed water unpredictably. They considered injecting significant amounts of HA into virgin noses dangerous due to the risk of vascular compromise from the hydrophilic swelling of the product. They recommended injecting filler subdermally and avoiding the tip and supratip area. The only complications that they observed from the technique came after injecting HA into the tip area of two post-rhinoplasty patients, one by Dayan and one by an outside injector. These were both cases of ischemia. Dayan's patient was a mild case of Raynaud's-like phenomenon on the nasal tip and had no sequelae due to treatment with Hyaluronidase. The outside injector's case was a more serious case of ischemia that resolved with Nitropaste and Hyaluronidase. Although necrosis was avoided, they report that the patient developed aesthetically displeasing skin changes 1 year afterward. Notably, they again write that Dayan has had no trouble performing rhinoplasty on post-CaHA NSR patients. This is interesting because it contradicted numerous anecdotal accounts

by other rhinoplasty surgeons at meetings and on the Internet that injectable fillers were causing catastrophic scarring and damage to the nasal tissues [17].

In 2010, we published our 4-year experience with CaHA NSR, comprising 385 patients [18]. We injected virgin noses as well as patients who had undergone rhinoplasty surgery in the past. We used volumes ranging from 0.3 cc to 0.5 cc of CaHA. We showed the procedure to be extremely safe. Two serious complications were encountered in patients who had undergone multiple revision rhinoplasties. They consisted of ischemia that progressed to small areas of tissue necrosis at the tip and ala despite treatment with Nitropaste and oral steroids. The rate of minor complications like cellulitis, prolonged swelling, or prolonged bruising was very low. Interestingly, a history of previous rhinoplasty surgery did not increase the risk of minor complications. The only exception was that post-rhinoplasty patients did have an increased incidence of prolonged erythema. We documented successful injection of all areas of the nose, including the tip, ala, dorsum, sidewall, and radix. We were surprised that the cosmetic effect of CaHA did not, on average, last as long as we expected. A significant number of patients showed evidence of resorption of the material as early as six months after injection.

In 2012, Kim and Ahn published a paper on a standardized NSR technique for Asian patients using mostly CaHA (except for tip injection, where they used HA) [19]. They reported their experience with 87 patients. Unlike most authors, they used 2% Xylocaine for anesthesia, injecting the infratrochlear and external nasal nerves as well as placing boluses at the nasal tip and the columnella-labial angle. Their technique consists of three steps. First, the columnella and columnella-labial angle is augmented with an injection from the tip down to the nasal spine. Second, the dorsum is augmented with a single injection, advancing the needle from the tip to the radix and injecting upon withdrawal, as in the first step. The third step involves shaping the tip with small, superficial bolus injections of HA. Four minor complications are reported, none of them ischemic. They end the paper with a series of sensible guidelines to avoid complications and achieve optimal cosmetic results.

In 2013, Kurkjian and Rohrich published their recommendations on technique for NSR [20]. The extent of their experience with the technique is not stated. They advocate low-pressure injection with HA fillers only, using the smallest possible needles. According to them, Sculptra and Radiesse should be avoided due to their irreversibility and the danger of long-term palpability under relatively thin nasal skin. For patients desiring permanent nonsurgical correction, permanent fillers should be avoided and fat should be used instead. They recommend using Restylane in all areas of the nose because it is relatively less hydrophilic. The exception is the tip, where Juvederm is also recommended, taking advantage of postinjection hydrophilic swelling for patients who want to increase tip fullness. In their experience, HA has much higher longevity in the nose, lasting up to 2–3 years in some areas (I have not seen evidence of this kind of duration in my HA NSR patients). They consider filler injection to be useful in the correction of post-rhinoplasty contour irregularities.

This year I published a prospective, blinded study on the safety and efficacy of injecting methyl methacrylate (Artefill, Suneva, Santa Barbara, CA) to correct nasal contour deficiencies [21]. Artefill is a third-generation methyl methacrylate filler in a collagen carrier that was FDA approved in 2006 for nasolabial fold correction. The filler is 20% methyl methacrylate and 80%

bovine collagen. Allergy testing for the carrier is commonly done 2 weeks prior to injection. The particles are smooth and 30–50 microns in size. I have been using Artefill off-label for NSR since 2006 with no complications in about 750 patients. In my experience, 3–5 injection sessions are necessary because the body quickly absorbs the collagen carrier and the methyl methacrylate stimulates fibroblast proliferation to a variable degree. For the study, I injected the product over 3 sessions, spaced 1 month apart. Results were evaluated by me, an independent, blinded MD evaluator, and the patient. With 1 year follow-up on 19 patients, we all observed excellent cosmetic effect and no complications of any kind. An example of the results we obtained is illustrated in Fig. 3.

3. Technique

NSR corrects mild or moderate cosmetic nasal irregularities. I perform this procedure to achieve the following cosmetic goals:

1. Raise and better define an underdeveloped nasal dorsum. This is most popular among my Asian patients.
2. Raise and better define a ptotic tip, as in Fig. 1.
3. Camouflage a dorsal bump. The dorsum is leveled by injecting filler above and below the bump, as in Fig. 2.
4. Correct asymmetry of the tip or dorsum by subtly augmenting the weaker side.
5. Correct post-rhinoplasty contour defects. Most commonly, these present as saddle nose deformity or other type of dorsal cartilage collapse, polly beak deformity, dorsal asymmetry due to asymmetric scarring, asymmetry of the tip due to postsurgical scarring or cartilage over-resection and alar foreshortening.

Injectors around the world have used a variety of materials to achieve the aesthetic recontouring of NSR. Currently, hyaluronic acid (HA) is the most popular filler material due to its reversibility (via injection of Hyaluronidase). There are a number of reports and editorials on technique in the literature. Most of these have been summarized above.

I consider HA, in its most common formulations of Juvederm and Restylane, to be the best material for the beginner or the occasional injector of the nose. The ability to dissolve HA is a critical safety feature for injectors who are not yet experts in the technique. Juvederm and Restylane are effective for basic NSR goals, such as augmenting the bridge and camouflaging minor dorsal bumps. These fillers struggle to perform, however, in the more advanced applications of this technique. Juvederm and Restylane are relatively soft materials. They can only provide moderate augmentation of the dorsum, they cannot lift a drooping tip very much and they are poor at sculpting defining points of the tip and the sidewall of the nose. In my experience, these HA fillers last an average of 6–8 months.

Perlane is a formulation of HA that is an improvement over Juvederm and Restylane for NSR. Its increased density permits the advanced injector to sculpt more effectively. It has less of a

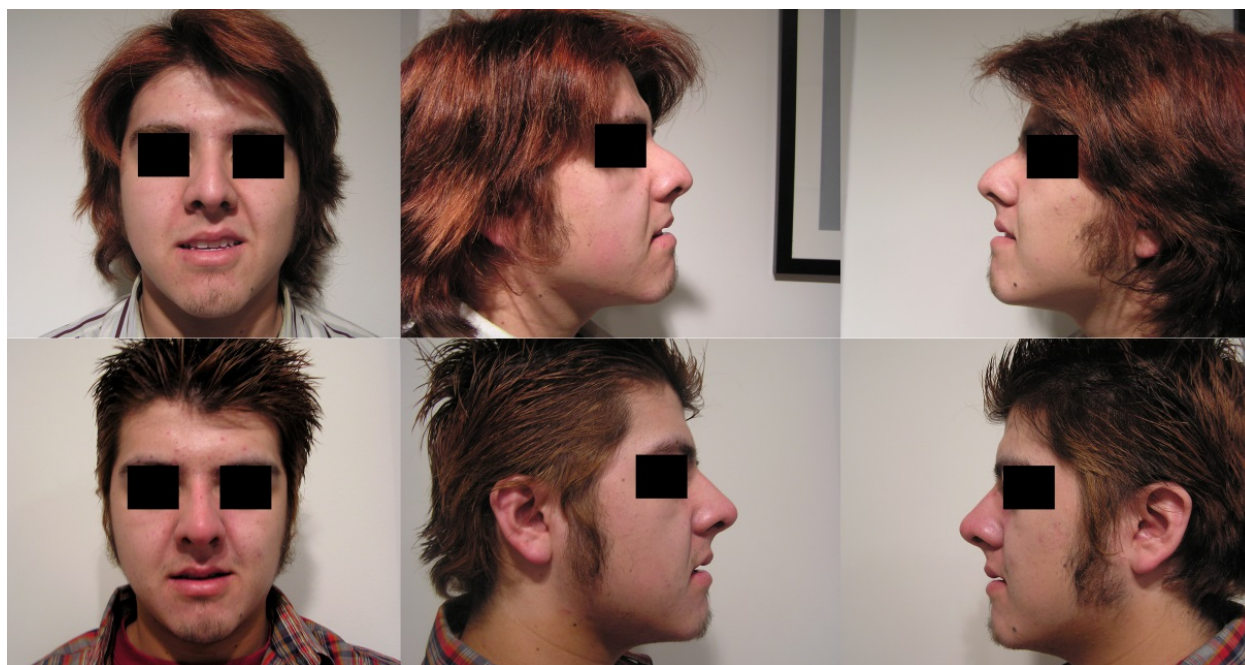

Figure 1. CaHA NSR to lift a ptotic nasal tip and augment the nasal radix. The “Before” pictures are on top, “After” on the bottom. The net result is a straighter nose on profile that appears smaller because it blends better into the rest of the face.

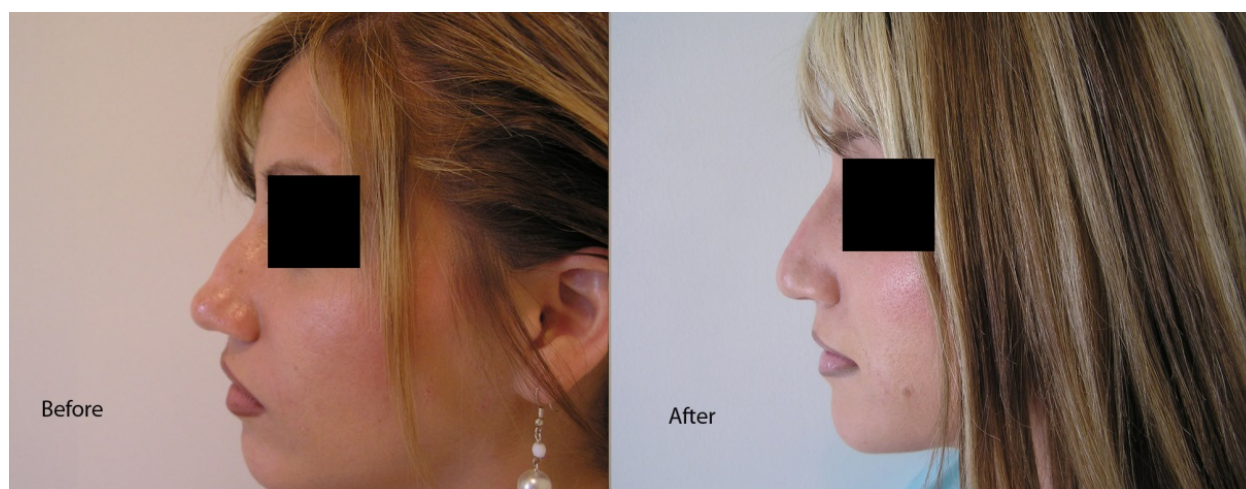

Figure 2. HA NSR to camouflage a dorsal hump. The patient wanted to use a minimum of product to make her profile straighter. She believed a slight curve would make her nose look more natural.

tendency to spread, so better definition can be achieved. Perlane also lasts somewhat longer in the nose than Juvederm and Perlane – about 8 months in my experience. Prior to the FDA approval of Voluma, I used Perlane for patients who wanted the added safety of a reversible filler.

I have used calcium hydroxyapatite (CaHA – Radiesse, MERZ Aesthetics Inc., San Mateo, CA) in most of my NSR procedures. Radiesse received FDA approval in 2006 for correcting

moderate to severe wrinkles and HIV-related facial volume changes. Prior to that it was approved for vocal cord augmentation and I was using it off-label in the nose. As a non-HA filler, CaHA is not reversible. Hypersensitivity reactions to CaHA are extremely uncommon and reports of other adverse events do not differ significantly from reports for HA fillers. Side effects noted of CaHA include:

- Nodules (generally associated with lip augmentation or injection in areas with little subdermal space, e.g., infraorbital area) (Smith, 2007) (Tzikas, 2008)
- Granulomas (Lee MJ, 2008)
- Skin necrosis (Dayan SH and Arkins JP, 2011)
- Redness, erythema, and swelling (Siclován, 2009)

The advantages of CaHA are its relative persistence of effect (average of 9–10 months in my experience, but quite variable between 6 and 12 months) and its high density. This last quality allowed me to effectively sculpt noses to my patients' satisfaction. It is possible to significantly elevate a droopy tip without excessive rounding. In fact, CaHA makes it possible to precisely create aesthetically pleasing tip defining points in patients with rounded and poorly defined tips. CaHA also makes it possible to significantly raise and add real definition to an underdeveloped dorsum – a quality that my Asian patients particularly appreciate.

With the FDA approval of Voluma in October of 2013, injectors gained a valuable new tool that seems to confer longer duration of effect than any other filler. Voluma is more cross-linked than other HA fillers and has a higher percentage of low molecular weight hyaluronic acid, making it exceptionally smooth, viscous, and cohesive. Increased cross-linking makes the filler more resistant to enzymatic degradation. Under study conditions, duration of effect was up to 2 years [22], but anecdotal reports from the investigators indicate the filler to be even longer lasting than that. Because of the duration of effect and its reversibility, I have been using Voluma for the majority of my NSR cases over the last 5 months. It performs well for the most part, but I find that in patients that need extensive elevation of their tip or dorsum, Radiesse is still the only filler thick enough to provide the desired lift. In these patients, my NSR combines Voluma and Radiesse.

I perform this procedure with the patient sitting up straight in the chair, as in Fig. 5. After taking standardized photographs, I use a compounded triple anesthetic cream for 15–20 min prior to the procedure (the materials I use are pictured in Fig. 4). My assistant will remove the cream and the patient will ice the area to be injected. During the injection, my assistant taps the patient's contralateral shoulder to distract their attention from the injection. I have found that alcohol works fine to clean the area and prevent infections. I prefer a thin-walled 29 gage half-inch needle when using any of the fillers – Voluma, Radiesse, or Artefill. If that is not available, I use a thin-walled 28 gage one-inch needle. I perform injections for the most part as shallow linear threads, placing small amounts of filler as I withdraw the needle. I will place filler into the area of the radix, dorsum, sidewall, tip, columnella, and ala as needed to correct each individual irregularity. I will then massage and mold the filler to blend into the desired contour. The patient goes home with instructions to avoid alcohol and strenuous exercise that



Figure 3. Artefill NSR to refine and straighten the dorsum and tip from both the profile and straight on views. This patient wanted to have a thinner appearing nose from the frontal view and a straighter and more refined looking dorsum and tip from the profile.

day, as well as heavy sunglasses for two weeks. I agree with Kim and Ahn's observation that the volume effect of most fillers decreases by about 25% within the first month or two [19]. For this reason, my procedure includes a complementary follow-up visit 3 weeks after the initial injection, where I can touch-up the results.

In my experience, there are several types of patients that seek NSR. Most commonly, it is the younger patient who cannot afford the time or resources required for postsurgical recovery. They hear about the procedure through friends and the Internet. They mostly present with mild or moderate cosmetic irregularities. Having studied the before and after pictures and read about the procedure, they understand that it is not a technique that can physically reduce the size of the nose, so I rarely see patients with severely large noses.

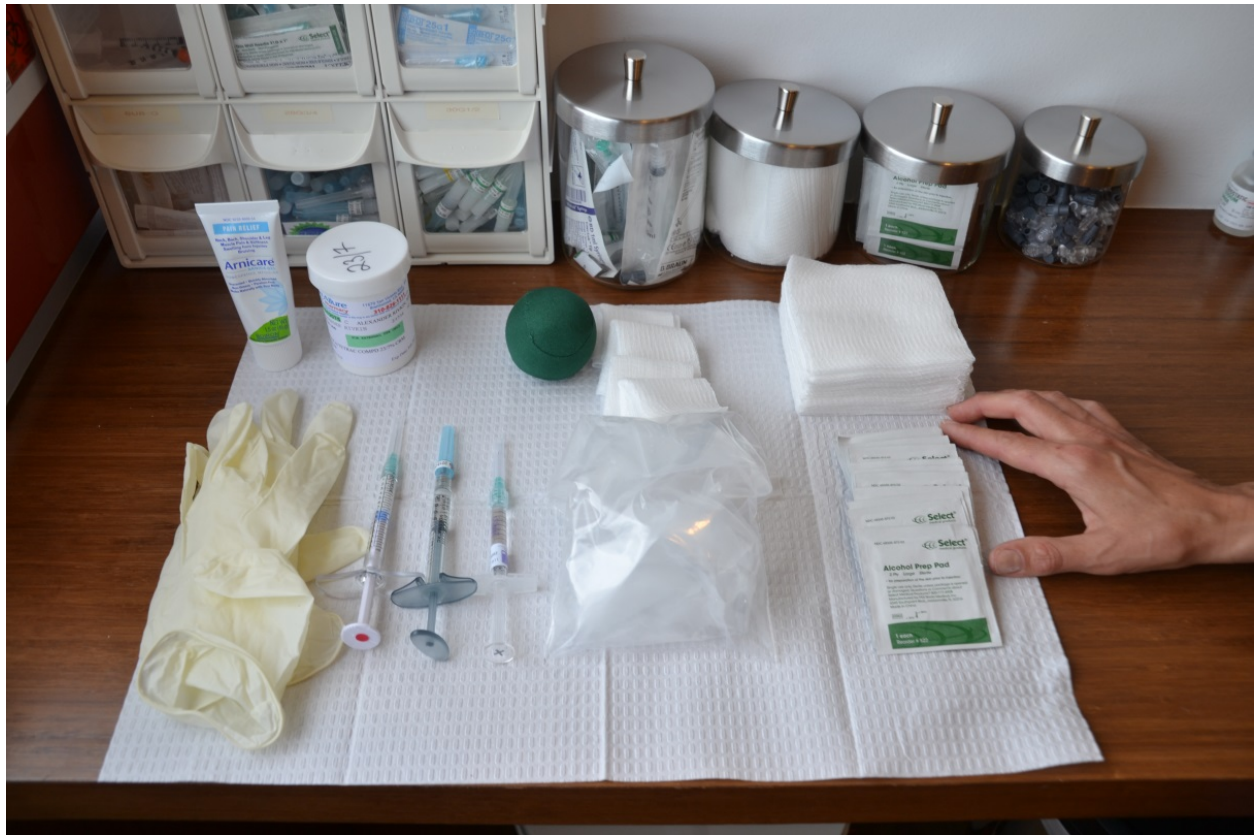

Figure 4. Equipment necessary for NSR. Radiesse, Voluma, and Perlane are all displayed with the first two as presplit half syringes (using a Luer-Lock connector and a 1cc syringe). I try to use the smallest possible needle gage – 27 or 28 G thin-walled needles are my preference. The photograph displays the four main methods of pain control in my injectables practice. Topical numbing cream is a compounded 23% Lidocaine, 7% Tetracaine mixture. Ice and a stress ball are important, but most important is my assistant's hand, which distracts the patient by tapping on the shoulder opposite to where I am standing.

About a third of my NSR patients are Asian, as in Fig. 6. These patients commonly desire an increase in the height and definition of their dorsum and radix, as well as improvement in the definition and projection of their nasal tip. These patients are usually young and cannot afford surgery. They are also often wary of unnatural surgical results, describing people with visible or overly large dorsal grafts that they have seen in the Asian community. Like many patients who opt for this procedure, they want to see the cosmetic change they desire, but only if their nose retains a natural appearance and no one can tell that they have had an aesthetic procedure.

Both of these kinds of patients usually choose the temporary procedure using a CaHA filler like Radiesse or an HA filler like Perlane or Voluma. They are aware that I commonly use Artefill for long-lasting to permanent results but want to try out the effect before they commit. Once the effect fades, some of these patients decide to continue with the temporary filler but many switch over to Artefill.

Another common category of patients presenting for this procedure are the ones who have desired cosmetic improvement in their nose for a long time, but have been afraid of surgical

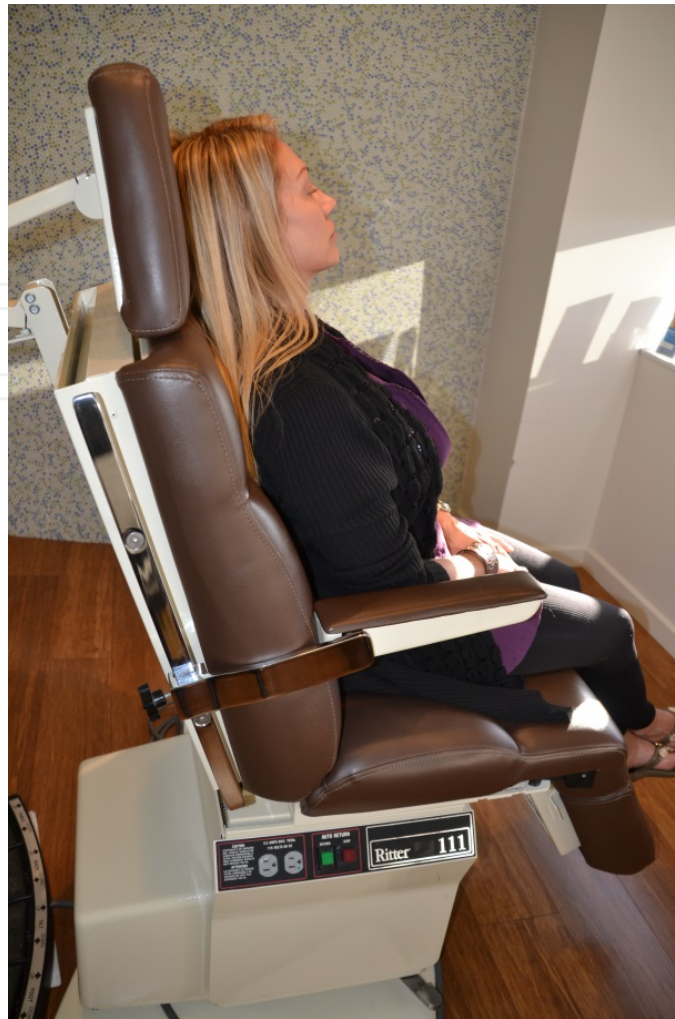

Figure 5. Correct patient position for NSR. She is relaxed and sitting comfortably with her head resting on the back of the chair. Movement is minimized. There is no tissue redistribution, as there would be if the patient was lying flat, so cosmetic results are optimally accurate.

and anesthesia risks. These patients present with a variety of aesthetic complaints. Most are appropriate for the NSR technique, but some require reduction and have to be turned away.

An important subset of the above patient group is those who consider their aesthetic complaint to be too minor to undergo surgical correction. They are bothered by their small bump or mild asymmetry but feel that surgery exacts too high of a price (both financial and temporal). These patients are mostly ideal candidates for NSR. A small amount of contour correction to restore symmetry or camouflage a small bump makes them very happy.

About a quarter of my patients have already had one or more surgical rhinoplasties. These patients present with a variety of aesthetic complaints, but all of them are disappointed in the aesthetic result of their surgery (or surgeries) and desire an effective alternative. Some opt for temporary fillers, but many choose methyl methacrylate so that they can “get it over with.” Figure 7 illustrates one of those patients. Anyone who performs NSR must be aware that these patients present with technically challenging problems. Postsurgical scarring stiffens the skin

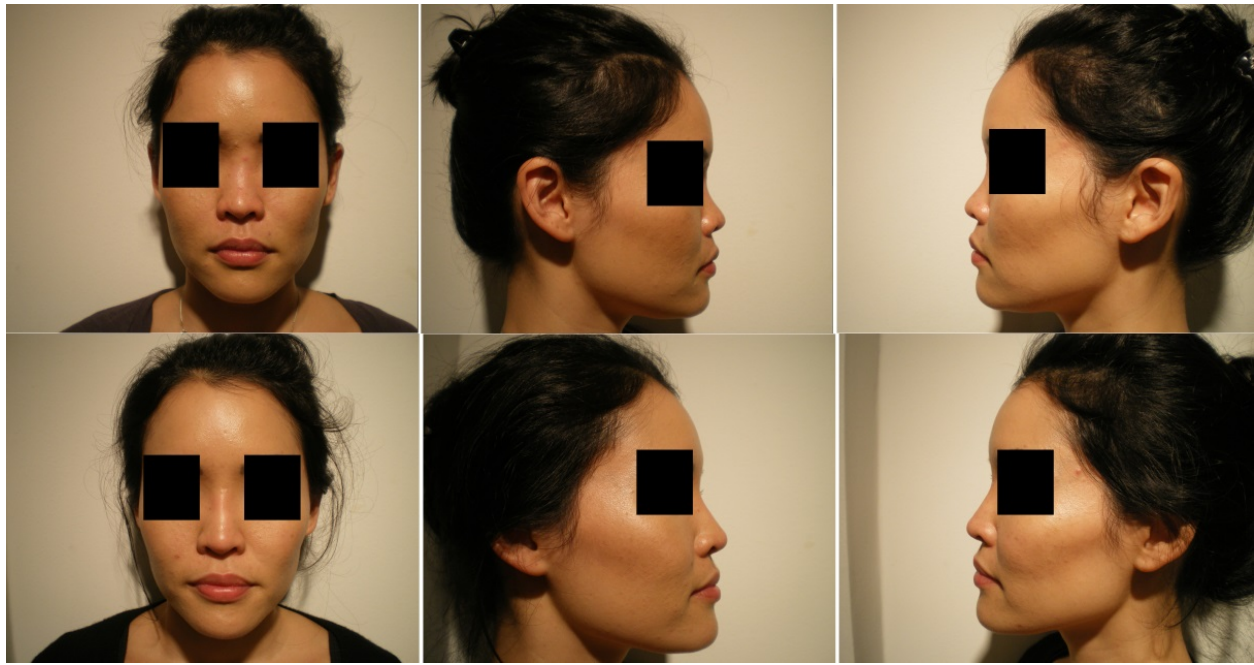

Figure 6. CaHA NSR to augment and better define a nasal bridge and tip in an Asian patient.

and limits the lift that can be achieved with filler injection. Injectors need to take care not to over-promise these patients. Their results are going to be, for the most part, relatively subtle. Most importantly, postsurgical skin has a more tenuous blood supply, especially around the tip and ala. The risk of ischemia and necrosis are significantly increased in these patients. Only the most experienced injectors should be treating them, since the complications of necrosis can be catastrophic.

Complications of NSR are relatively rare. This is not surprising, since the overall major complication rate for filler injections has been estimated to be less than one hundredth of one percent [4]. As described above, published studies are meager and mostly small, but they report few serious adverse events. Bruising, transient erythema, and short-term swelling represents most of the issues documented. The exceptions are the disturbing case reports that detail blindness and major necrosis of nasal tissue [5,6,7]. Since the doctors treating the complications and not those who injected the patients write most of these reports, conclusions about needle type, injection technique, and even material used are often difficult. Of the reports published by the actual injectors, we know that sudden pain, blanching, duskiness, and ecchymosis in the area being injected are all danger signals for ischemia and necrosis. Compromise of the blood supply to the skin in cases of filler injection can be caused by either intravascular embolism or small vessel compression by the filler.

Ophthalmalgia and visual loss within minutes are signs of retinal artery embolism. Other signs of ophthalmic vasculature embolism include immediate diaphoresis, nausea, headache, ophthalmoplegia, and ptosis [4].

In my experience, these complications can best be avoided by understanding the anatomy, always practicing safe injection technique, and having well-prepared protocols ready to launch

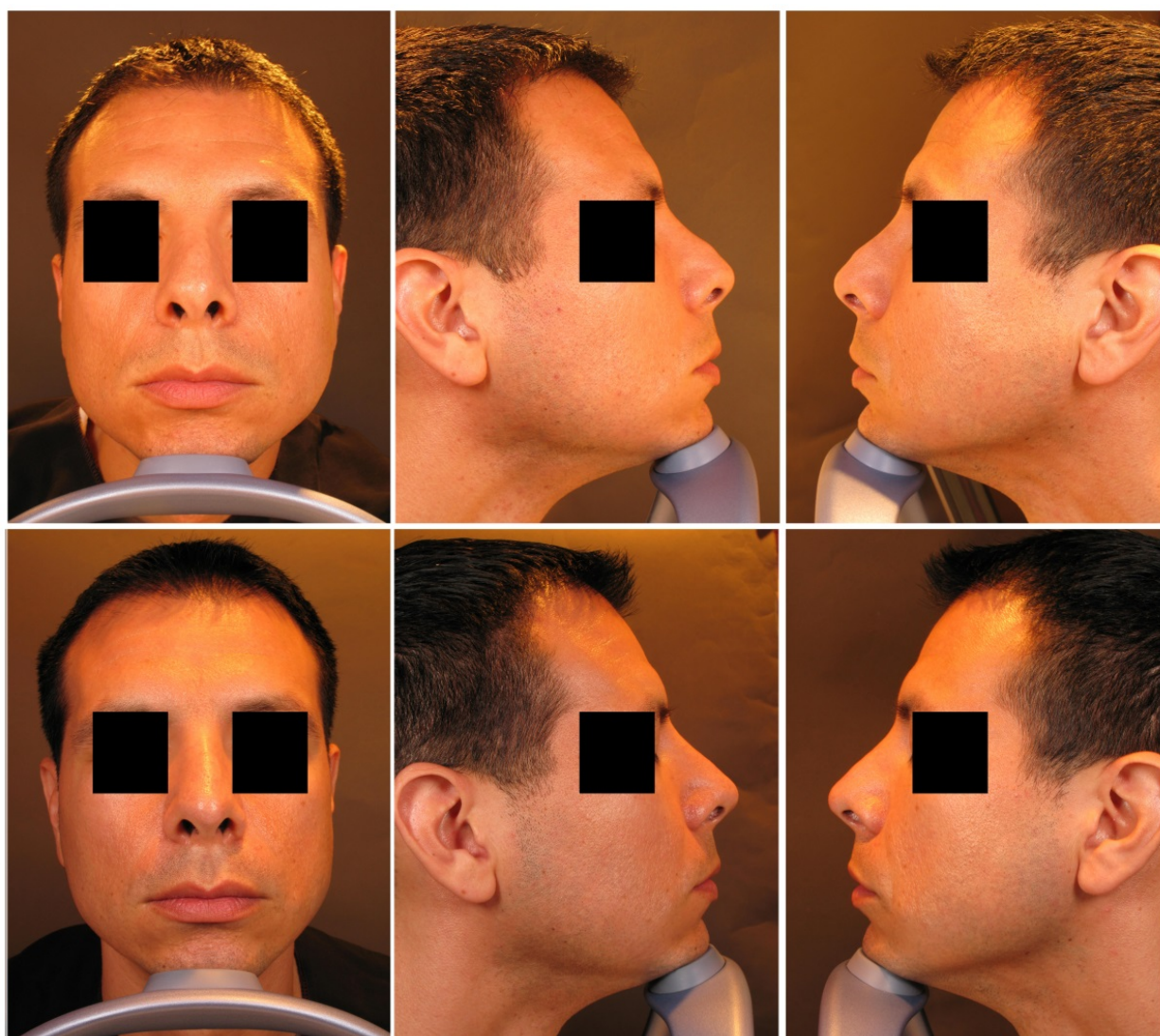

Figure 7. Artefill NSR to correct postsurgical contour irregularities and asymmetry of the dorsum and to lift the nasal tip. Lower series are 1 year after the last of three sessions of Artefill injections.

at any sign of danger. Our traditional understanding of the vascular anatomy of the external nose is illustrated in Fig 8.

A good injector is especially careful when injecting the radix and nasal sidewall, to avoid the dorsal nasal and angular branches, respectively. Based on Fig. 8, keeping one's injection points in the midline seems to ensure safety. This is surely true to some degree, but a recent paper by Saban *et al.* proposes that the external nasal vasculature is more interconnected than we think [23]. Using cadaver dissection and ultrasonography study of live subjects, the authors conclude that anastomoses between the internal and external carotid vascular systems are plentiful in the external nose. This plexus of vessels is located in the SMAS layer. Safe injection technique should therefore focus on keeping the needle deep instead of trying to avoid specific vessels.

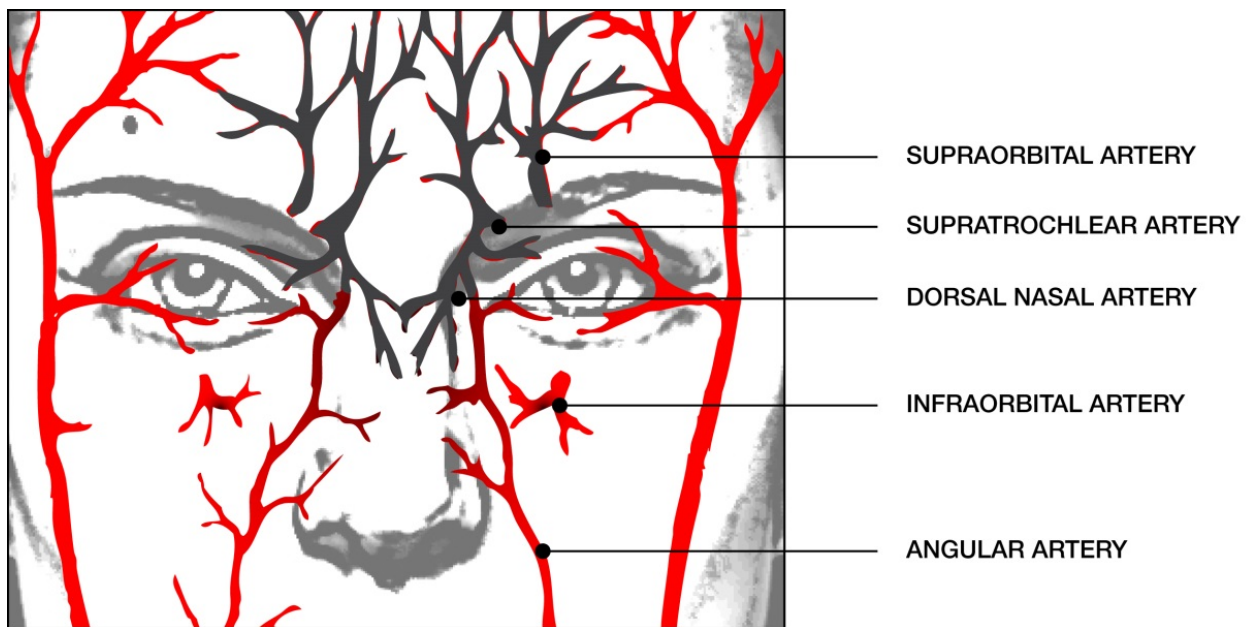


Figure 8. External arterial anatomy of the nose. Vessels originating from the External Carotid are in red, whereas those in black come from the Internal Carotid via the Ophthalmic Artery.

Some clinicians have recommended aspiration prior to injection of filler in order to avoid vascular embolism. In my experience, this is a cumbersome practice with questionable benefits. Most fillers are thick gels. Building up enough negative pressure for aspiration of blood takes a lot of hand force and would only work for Voluma due to its smooth viscoelastic properties. Even in experienced hands, by the time one aspirates and then injects, the needle is no longer in the same place, rendering the test useless.

Rather than aspirating, I think that following accepted best practice standards for injecting filler is a more reliable way of preventing complications [8,9]:

1. Needles should be as small as possible so that filler flow rate is low.
2. Fillers should always be injected slowly and under low pressure, especially in the nasal area. The blindness complications in the literature occurred because a filler embolus was injected with enough force to overcome systolic blood pressure and travel up into the ophthalmic vasculature. Gentle injection technique should prevent this complication.
3. The needle should be advanced through the skin slowly and filler should only be flowing when the needle is moving out of the skin. This way, even if the tip of the needle is inside the lumen of a vessel at some point, only a tiny amount of filler will enter the vessel, as the needle will be out in the next moment.
4. Small volumes of filler should be introduced with each injection.
5. We always ice prior to injection. Ice decreases pain and shrinks blood vessels, making them less likely to be punctured.

Some authors advocate blunt tipped cannulas for all filler injection as a way to reduce complications and discomfort [10,11]. I think this is not a good idea in the nose. The weakness of cannulas is precision. It is much easier to know the exact location of a needle tip than the tip of a cannula that bends easily as it is advanced through the tissue. The aesthetics of the nose are particularly sensitive to the smallest contour asymmetries. One millimeter of fullness difference between two sides of the tip is clearly noticeable. One-millimeter deviation from the midline, when augmenting a dorsum, makes the nose appear off-center.

The literature contains reports of severe complications from every type of filler available, and I have successfully used a variety of materials in the nose. I do not believe that there is a material contraindicated for nasal injection. It is the skill and knowledge of the injector that is paramount to the success of the procedure.

While not really a complication, vaso-vagal episodes can be disturbing to the novice injector. Diaphoresis, sudden pallor, a sensation of nausea are all warning signs of an impending episode. It is more likely to happen if the patient has not eaten much prior to their appointment. In the setting of cosmetic injections, patients become vaso-vagal primarily because they are holding their breath in anticipation of pain. The frequency of these episodes dropped dramatically once we began to routinely remind our patients to breathe. Distraction shoulder tapping also helps them tolerate the injections without excessive anxiety. If the patient does become vaso-vagal, our routine is to immediately place them in reverse Trendelenberg position, increasing blood flow to the brain. We place an ice bag behind their neck and give them something sweet to drink like orange juice or Coke. We monitor their pulse and blood pressure manually. Most patients will recover fully within a few minutes. We have not yet had to use smelling salts.

Complication management starts with the preventative measures outlined above. If, however, the clinician suspects that an ischemic event is unfolding, there are immediate steps that he or she should be ready to take. First, injection should stop immediately. The area should be massaged vigorously in an effort to restore blood flow and Hyaluronidase should be injected into the area. A dose of 50–80 units should be sufficient. Even if a non-hyaluronic acid filler has been used, Hyaluronidase is useful because it dissolves some native hyaluronic acid and decreases interstitial pressure, easing blood flow. Topical 2% Nitroglycerin paste (Nitro-bid. Savage Labs, Melville NY) should be in the room and readily available to anyone performing this procedure. It is a great vasodilator that acts very quickly. In situations of potential ischemia, a small amount should be applied to the area in question and it should stay on for at least 15 min. The patient should take aspirin 325 mg immediately. If the skin becomes pink again and remains so after a period of observation of 15 min or so, I would feel comfortable sending the patient home on aspirin every 4 h for a day, warm compresses, and periodic massage of the area. If the skin becomes dusky, I would reapply the Nitropaste for another 30 min and consider reinjecting the area with Hyaluronidase. I would observe the patient in the office for the next hour or so, applying warm compresses and massaging the area. At this point, the patient should begin oral steroid therapy and oral antibiotics. I would give them a Medrol dose pack and make sure that they take the first dose right away. At this point, the patient should be seen in the office on a daily basis to monitor the progression of tissue damage. If

damage continues to unfold, the injector should consider hyperbaric oxygen therapy and referral to a plastic surgeon. My in-room safety kit, a.k.a. injectables “crash cart” is illustrated in Fig. 9.

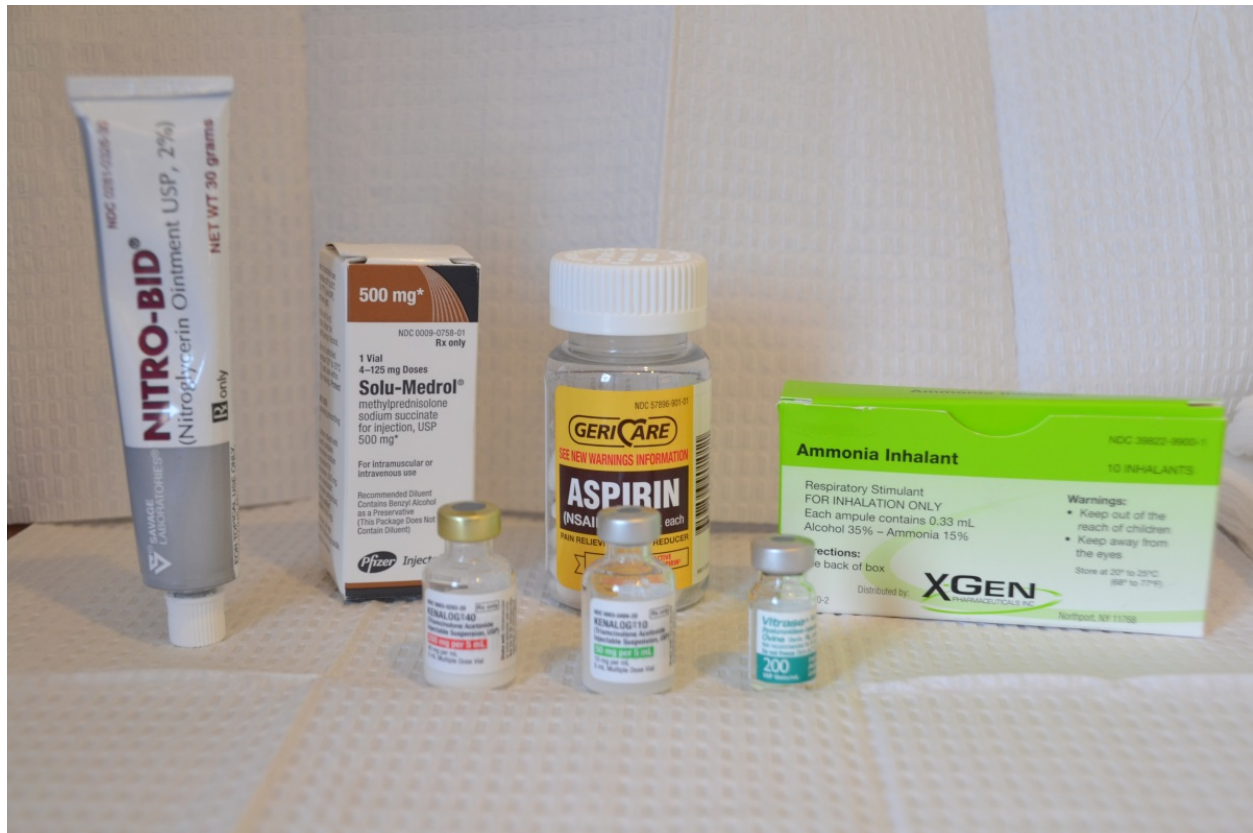

Figure 9. My in-room safety kit. Pictured are Hyaluronidase, Nitopaste, Aspirin, Kenalog, Solu-medrol, and smelling salts. These are the medications important to have on hand in every room.

When performed safely and correctly by an experienced and well-trained injector, NSR is a procedure that yields excellent patient satisfaction. It is not a replacement to rhinoplasty for all patients and I continue to refer those that are not candidates (mostly patients who need significant reduction) to my surgical colleagues. This procedure does, however, provide a valuable alternative to traditional surgery. It increases the pool of people wanting cosmetic correction of the nose, bringing in a significant population of patients who would never do surgery. In fact, recalling the statistics from AAFPRS and ASAPS, over the last 10 years that this procedure has become popular, it has not cut into the number of patients receiving surgical rhinoplasty [1,2]. For the patients who are candidates, it saves them expense, risk, and downtime. Finally, the precision of filler injection means that this procedure is in some cases superior to surgery in accomplishing patients' cosmetic goals. I have built a large practice upon this procedure and continue to receive many referrals from happy patients.

Acknowledgements

The author would like to thank Mimi Lam for her assistance with the layout and proofreading of this chapter.

Author details

Alexander Z. Rivkin

Address all correspondence to: arivkin@westsideaesthetics.com

Department of Dermatology, Division of Medicine, David Geffen, UCLA School of Medicine, Westside Aesthetics, Los Angeles, CA, USA

Conflict of interest: The author is on advisory boards and educational faculty for Allergan, Galderma, Merz, Solta Pharmaceuticals.

References

- [1] <http://www.aafprs.org/wp-content/themes/aafprs/pdf/AAFPRS-2012-REPORT.pdf>
- [2] <http://www.plasticsurgery.org/Documents/news-resources/statistics/2012-Plastic-Surgery-Statistics/full-plastic-surgery-statistics-report.pdf>
- [3] Jacovella PF. Aesthetic nasal corrections with hydroxylapatite facial filler. *Plast Reconstr Surg*. 2008 May;121(5):338e-339e.
- [4] Rokhsar C, Ciocon DH. Nonsurgical rhinoplasty: an evaluation of injectable calcium hydroxylapatite filler for nasal contouring. *Dermatol Surg*. 2008 Jul;34(7):944-6
- [5] Stupak HD, Moulthrop TH, Wheatley P, Tauman AV, Johnson CM Jr. Calcium hydroxylapatite gel (Radiesse) injection for the correction of postrhinoplasty contour deficiencies and asymmetries. *Arch Facial Plast Surg*. 2007 Mar-Apr;9(2):130-6.
- [6] Glicenstein J. The first “fillers,” vaseline and paraffin From miracle to disaster. *Ann Chir Plast Esthet* 2007;52:157–61.
- [7] Bruning P. Contribution a l’etude des greffes adipeuses. *Bull Acad R Med Belg*. 1919;28:440.
- [8] Peer LA. Loss of weight and volume in human fat grafts. *Plast Reconstr Surg*. 1950;5:217.

- [9] Webster RC, Hamdan US, Gaunt JM, Fuleihan NS, Smith RC. Rhinoplastic revisions with injectable silicone. *Arch Otolaryngol Head Neck Surg.* 1986;112: 269-276.
- [10] Han SK, Shin SH, Kang HJ, Kim WK. Augmentation rhinoplasty using injectable tissue-engineered soft tissue: a pilot study. *Ann Plast Surg.* 2006 Mar;56(3):251-5.
- [11] Beer KR. Nasal reconstruction using 20 mg/ml cross-linked hyaluronic acid. *J Drugs Dermatol.* 2006 May;5(5):465-6.
- [12] Nyte CP. Spreader graft injection with calcium hydroxylapatite: a nonsurgical technique for internal nasal valve collapse. *Laryngoscope.* 2006 Jul;116(7):1291-2.
- [13] Graivier MH, Bass LS, Busso M, Jasin ME, Narins RS, Tzikas TL. Calcium hydroxylapatite (Radiesse) for correction of the mid- and lower face: consensus recommendations. *Plast Reconstr Surg.* 2007 Nov;120(6 Suppl):55S-66S.
- [14] Dayan SH, Greene RM, Chambers AA. Long-lasting injectable implant* for correcting cosmetic nasal deformities. *Ear Nose Throat J.* 2007 Jan;86(1):25-6.
- [15] de Lacerda DA, Zancanaro P. Filler rhinoplasty. *Dermatol Surg.* 2007 Dec;33 Suppl 2:S207-12.
- [16] Humphrey CD, Arkins JP, Dayan SH. Soft tissue fillers in the nose. *Aesthet Surg J.* 2009 Nov-Dec;29(6):477-84.
- [17] <http://deantoriumi.com/issue1-1.asp>
- [18] Rivkin A, Soliemanzadeh P. Nonsurgical Injection Rhinoplasty With Calcium Hydroxylapatite in a Carrier Gel (Radiesse): A 4-Year, Retrospective, Clinical Review. *Cosmetic Dermatology.* 2009 Dec;Vol. 22 No. 12: 619-624.
- [19] Kim P, Ahn JT. Structured nonsurgical Asian rhinoplasty. *Aesthetic Plast Surg.* 2012 Jun;36(3):698-703.
- [20] Kurkjian TJ, Ahmad J, Rohrich RJ. Soft-tissue fillers in rhinoplasty. *Plast Reconstr Surg.* 2014 Feb;133(2):121e-6e.
- [21] Rivkin A. A prospective study of non-surgical primary rhinoplasty using a polymethylmethacrylate injectable implant. *Dermatol Surg.* 2014 Mar;40(3):305-13
- [22] Jones D, Murphy DK. Volumizing hyaluronic Acid filler for midface volume deficit: 2-year results from a pivotal single-blind randomized controlled study. *Dermatol Surg.* 2013 Nov;39(11):1602-12.
- [23] Saban Y, Andretto Amodeo C, Bouaziz D, Polselli R. Nasal arterial vasculature: medical and surgical applications. *Arch Facial Plast Surg.* 2012 Nov;14(6):429-36.

