

We are IntechOpen, the world's leading publisher of Open Access books Built by scientists, for scientists

6,900

Open access books available

186,000

International authors and editors

200M

Downloads

Our authors are among the

154

Countries delivered to

TOP 1%

most cited scientists

12.2%

Contributors from top 500 universities



WEB OF SCIENCE™

Selection of our books indexed in the Book Citation Index
in Web of Science™ Core Collection (BKCI)

Interested in publishing with us?
Contact book.department@intechopen.com

Numbers displayed above are based on latest data collected.
For more information visit www.intechopen.com



Transcutaneous and Transmucosal Serdev Sutures® for Nasal Tip Refinement, Alar Base Narrowing, and Other Corrections

Nikolay P. Serdev

Additional information is available at the end of the chapter

<http://dx.doi.org/10.5772/62074>

Abstract

The author describes his experience with the transcutaneous Serdev Suture® techniques in different aesthetic disproportions of the external nose and in secondary cases. Author's needles are specifically designed for these techniques. Rhinoplasty is part of the beautification process. The cosmetic surgeon should be guided by correct nose proportions, angles, and volumes. Proportional nose is one that fits in 1/3 of the face length. Proper volumes are: thin dorsum, thin tip, narrow alar base. The tip of the nose prominence gives volume to the central face and its position should be in harmony with the beauty triangle (projected cheekbones and chin). The tip should be in the line of the cheekbone prominences. The nasal dorsum should be straight or slightly concave. The best angles are: 90° angle at the tip, 110° nasolabial angle, 30° angle of nostrils to columella, 30° dorsum to profile line. The aim of Serdev Suture® techniques in beautification rhinoplasty is to improve the above-mentioned aesthetic proportions, volumes, and angles of the nose, adapted to the face as a whole. Serdev Sutures® in rhinoplasty include: tip rotation, refinement of the tip, lower and medial thirds, alar base narrowing and nasal dorsum lifting of concavities and irregularities.

Keywords: Rhinoplasty, Serdev Sutures®, nasal tip rotation, nasal tip refinement, alar base narrowing, nasal dorsum lifting, atraumatic rhinoplasty, mini-invasive, no bandages, no downtime

1. Introduction

Serdev Suture® techniques are over 20 for face (including rhinoplasty) and body liftings and/or volumizing. In rhinoplasty cases, the author used Serdev Sutures® as separate procedures or as part of complex rhinoplasties [1-17]. Their main indications are tip rotation and

refinement, alar base narrowing, dorsum asymmetries and deformities, and secondary cases, where trauma is not advisable.

Earlier rhinoplasty techniques were based on closed or open operative procedures with combinations of incisions, approaches, and tip altering maneuvers, cartilage separation and their treatments, which are followed by some not very rare complications, such as tip deformation, destabilization of the nasal framework, and nasal tip support. Later, radical cartilage resections have been replaced by reshaping and reorienting of the nasal tip components. Intraoperative suture techniques of the nasal tip in open surgery became popular with McCollough and English double-dome unit procedure to increase tip projection and refinement using a horizontal mattress suture through all 4 crura just beneath the domes; with Goldman tip procedure for the wide or bulbous lobule, with Daniel domal creation suture, a horizontally placed mattress suture, which shaped each dome separately. Numerous suturing techniques appear in the literature regarding open technique rhinoplasty. All subcutaneous suture techniques listed above are used in open surgery [18-29].

Serdev Sutures® techniques represent scarless transcutaneous or transmucosal **closed approach** techniques. They could be: 1) transcutaneous methods to refine the tip or narrow the alar base; 2) transmucosal medial crura mattress sutures for tip refinement, columella sliding, and columella stabilization; 3) refinement sutures of projected lateral crura; and 4) sutures of fibrotic tissue or greater cartilages to lift depressions on the dorsum – primary or secondary. Thus, narrowing of the tip and alar base, and cartilaginous lower and medial third of the nose, etc., could be obtained. Author's needles (Figure 1) and Polycon semielastic surgical sutures guarantee the atraumatic nature of the procedure and better healing process.

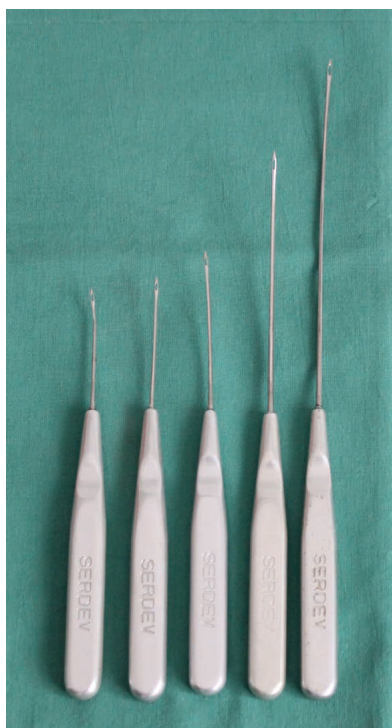

Figure 1. Curved semiblunt and semielastic Serdev® needles, with different lengths (50, 60, 80, 100, and 140 mm) and an eye at the tip.

One of the important qualities of Serdev® needles is that they create a round skin perforation point and allow for easy prevention of dermis fixation during the second needle pass that completes the circle of the suture. This is an advantage over cutting needles, which create a linear skin perforation that may result in capturing dermis, and must be avoided. The result when using other needles is dimpling, which is impossible to remove.

Stable results also depend on the suture material. Thin, monofilament threads can cut through the fine nasal cartilages, especially if the latter are mobile. Polycon, braided, semielastic USP 3-0 sutures, used by the author, protect the sutured cartilages and ensure the longevity of the result.

2. Anatomy

The alar cartilages define the nasal tip. Their three crura (medial, middle, and lateral) and their junctions are of main aesthetic importance. The medial crus forms the columella and its support. Wide distance between the medial crura makes the tip look bifid or wide, depending on thin or thick soft tissue and skin. The middle crus has a lobular and a domal segment. The normal divergence angle between lobular segments should be close to 30°. Both divergence and domal angle can form a wide tip. The length of the lobular segment is also responsible for the tip shape.

2.1. Indications for nasal tip, medial and lower third refinement via Serdev Sutures®

Indications are specific wide tip deformities: bifid tip with a dimple between the two tips, bulbous tip with flat domal segment and broad convex lateral crura; boxy tip with rectangular shape; ball tip with alar cartilages, which are too large and convex; bulky tip with thick skin, too heavy in comparison to the rest of the nose.

3. Tip rotation and dorsal alienation

3.1. Transcutaneous suture for lifting of all 4 crura or only medial crura of greater alar cartilages with fixation to the periosteum of the nasal bones

Two lines of the suture are important: 1) a pass under the nasal bone periosteum, which represents the immobile fixation, and 2) a subdermal pass in the columella, holding the mobile medial crura or all 4 crura of the greater alar cartilages – their suture rotation will shorten the nose. Two connecting subdermal passes fulfill the circle of the suture. The suture dives without engaging skin in each skin perforation point (Figure 2).

3.2. Surgical technique

The needle and suture are introduced through the following planes: The pass A-B is subperiosteal (50 mm Serdev® needle is used). A1-A and B1-B are subdermal connecting passes (60

mm Serdev® needle is used). The tip fixation pass A1-B1 is subdermal and fixes the greater alar cartilages. The knot could be placed in any point and should over-rotate the tip with about 2 mm (Figures 2 and 3). Skilled surgeons can change the A1-B1 pass, using only one perforation point in the middle of the columella just below the dome (point C) and make sure to pass subdermally and fix the greater alar cartilages.

Video: <http://www.youtube.com/watch?v=nRh8NDSgDck>

The same tip rotation is possible if only the medial crura of the greater alar cartilages are fixed just below the dome. This technique requires contamination prevention. The passes should not perforate into the nostrils.

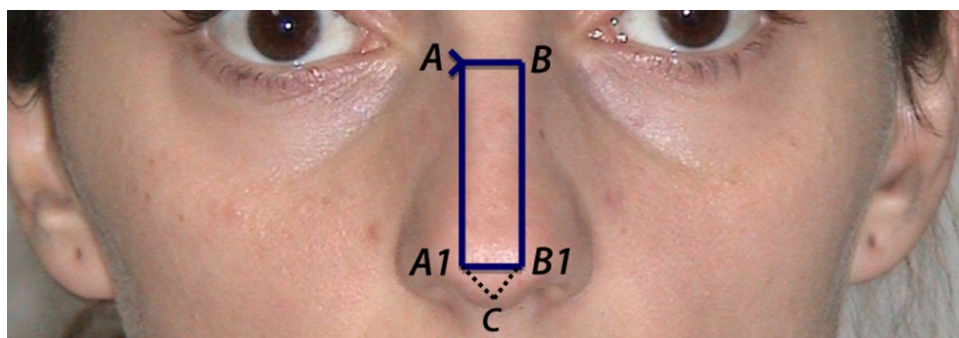


Figure 2. Tip rotation by transcutaneous suture: Pass A1-B1 should be subdermal to hold and rotate the greater alar cartilages and fix them to the subperiosteal A-B pass of the suture.

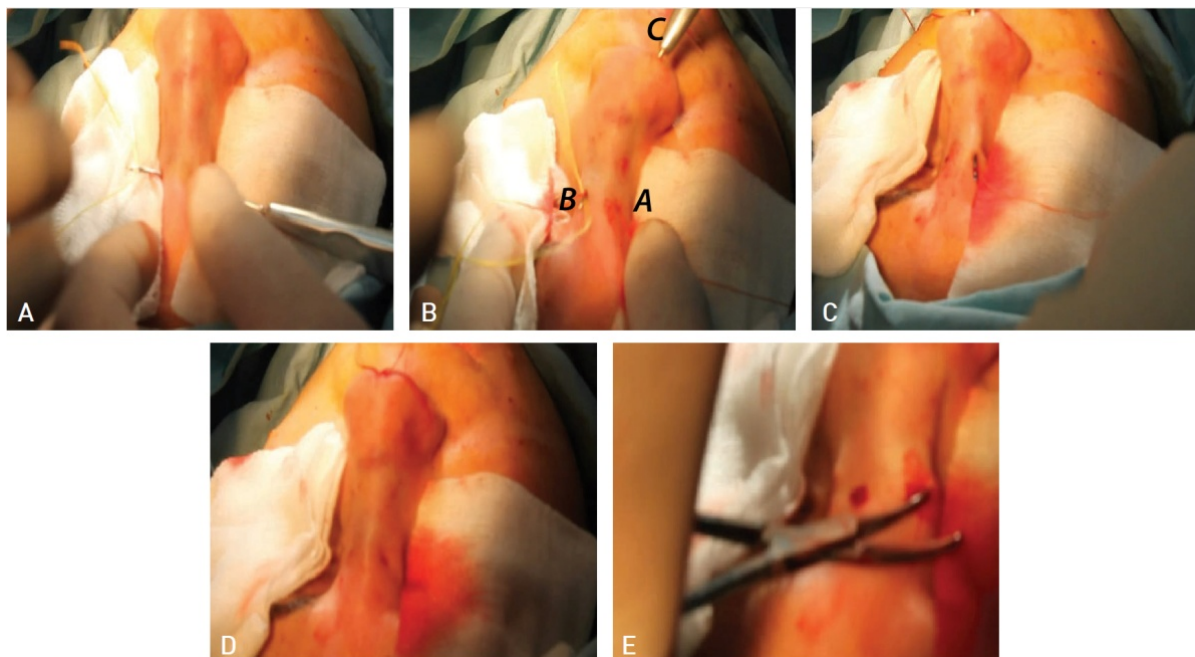


Figure 3. Nasal tip rotation by suspension of the greater alar cartilages to the nasal bone, A. Needle perforation through the nasal bone periosteum. The needle is loaded and the suture will be introduced in line B-A subperiosteally.

B. Using one skin perforation point in the middle of the columella, just below the dome, the first connecting needle pass is done to lift the left greater alar cartilage dome with fixation to the nasal bone periosteum. The needle reaches the left-side skin perforation point B at the level of the subperiosteal pass. The needle is loaded and the suture will be introduced in line B-C subdermally **C.** Using the same skin perforation point in the middle of the columella, just below the dome, the second connecting needle pass is done to lift the right greater alar cartilage dome with fixation to the nasal bone periosteum. The needle reaches the right side skin perforation point A at the level of the subperiosteal pass. The needle is loaded and the suture will be introduced in line A-C subdermally **D.** Suture is tied to slightly overcorrect the position of the nasal tip. **E.** Removal of skin dimples with a mosquito clamp – <http://www.youtube.com/watch?v=nRh8NDSgDck>

Nasal tip rotation by suture is mostly useful in Asians and Afro-Americans, having softer septum and unstable columella. In Caucasians with a hard septum the tip could not be lifted by suture and we perform another technique of the author – the T-excision and columella sliding, which could be supported by suture if necessary. The tip rotation suture is very helpful to align the dorsum, especially in irregular dorsum and secondary rhinoplasties.

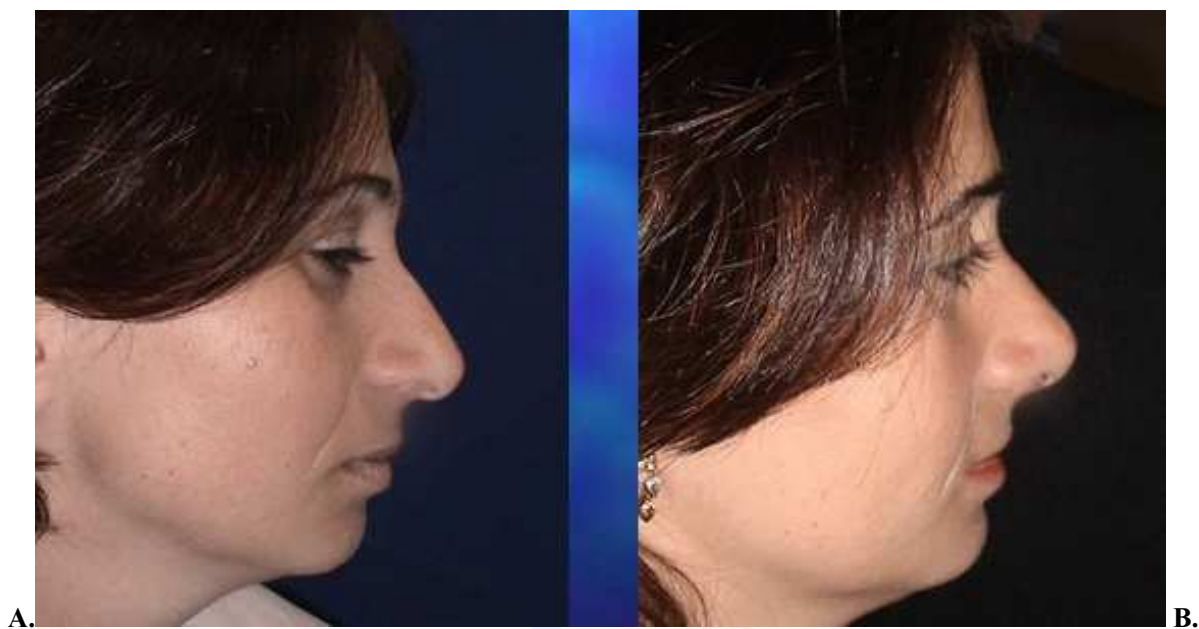

Figure 4. Nasal tip rotation via Serdev Suture® in a Caucasian patient. **A.** Before. **B.** After. Suture lift is possible if the long nose has a soft septum of normal length, and the elongation is represented by elongated mucosa.

4. Tip refinement

4.1. Tip refinement using transcutaneous transdomal suture of all 4 crura

A 50 mm curved semielastic Serdev® needle and semielastic Polycon sutures USP 3-0 are preferred for these specific delicate cartilages. They have prolonged absorption (2 years, i.e., after final fibrosis is obtained and foreign materials are no more necessary). Rigid and thin threads can perform like scalpels and cut through cartilages.

Nonabsorbable sutures are potential foreign bodies for late complications (infection, foreign body reaction, and extrusion). Early absorbable suture material disappears sooner than needed.

Author's transcutaneous sutures do not engage skin. The direct contact between cartilage surfaces in suture techniques stimulates fibrotic formation, which guarantees the stability of the result.

There is a selection of variation in each technique, modifications or combinations of techniques. For tip refinement, the author mostly uses the transdomal technique of suturing all 4 crura.

This method is very effective for narrowing the tip. It could be also used to additionally increase the tip projection. Skin perforation points are usually positioned the level of the tip point on either side, to insert a horizontal mattress suture through all 4 crura subdomally. It is a double dome suture (Figure 5) to narrow the tip by bringing the domes together.

4.1.1. Surgical technique

The transdomal suture uses 2 skin punctures and consists of 2 needle passes, without engaging skin. Each needle pass uses a different but parallel path through the cartilages. The transcutaneous suture is diving, buried below the skin. It attaches only cartilages, without including dermis in the suture. Skin and its perforations can be moved up and down the cartilages to obtain a distance of 2–3 mm between the parallel passes. Both needle passes have to be placed in the domal area without perforating the nostril in order to prevent contamination and compromising the result. The suture could be placed 3–4 mm posterior to the dome, to preserve the separation between the domes in front. The knots should be tied under elastic tension.

4.1.2. Clinical cases

The transcutaneous transdomal suture could be applied as a separate technique or as a part of primary or secondary rhinoplasty. It is simpler and safer than subcutaneous sutures in open rhinoplasty and their sequellae. It closes the divergence and dome angles atraumatically, thus saving time during operation, and shortens recovery.

4.2. Tip refinement using transmucosal domal suture of medial crura

This method is usually combined with the author's closed rhinoplasty techniques, such as T-excision and columella sliding. The suture should be placed as high as possible to fix the domal medial crura. There is no need for this suture to be buried below the nasal mucosa, which is involved on each side in the transmucosal mattress suture. Using absorbable sutures, the fibrosis stabilizes the effect after the first 3–4 weeks. If suture is not absorbable, it has to be removed after 3 weeks.

Medial crural fixation suture is used to fix the medial crura and to close the divergence angle between lobular segments of medial crura. This suture can refine the tip in cases of an open divergence angle of medial crura and normal domal angle. If the domal angle is more open, then the medial crura fixation suture can be an additional correction. The suture gathers the

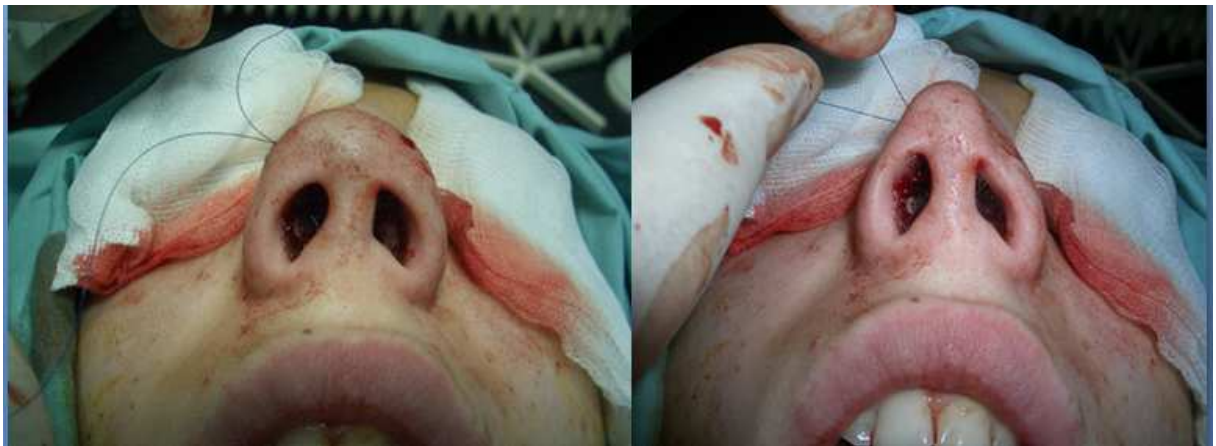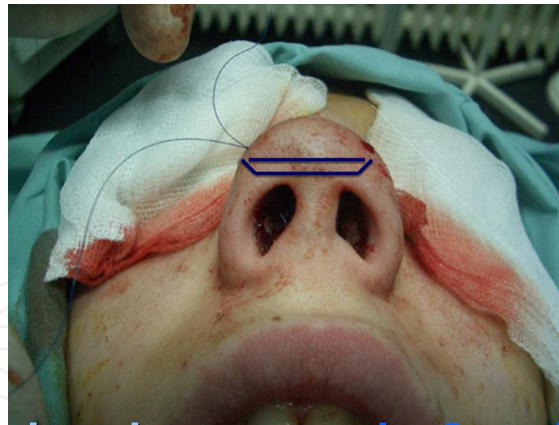


Figure 5. Transcutaneous transdomal suture of all 4 crura. The suture is made through the domal part of the lower alar cartilages. The tip deviation on the photo is due to the traction during knotting of the suture. The distance between the passes should be 2–3 mm. The suture should be placed in the domal tissue only. Be careful not to enter through the nostril as this will cause suture contamination. Dermis should not be engaged in order to prevent from dimples. Dimpling will be removed using a mosquito instrument.

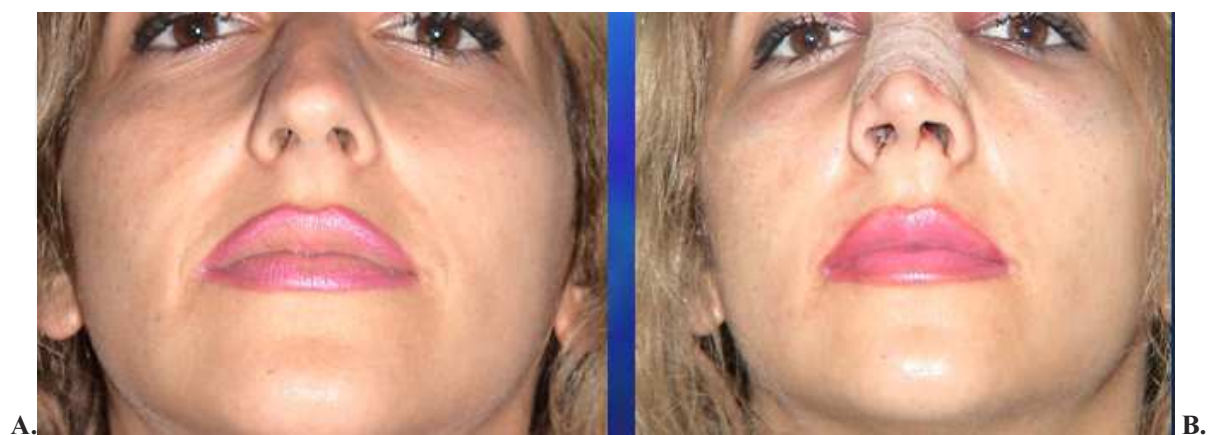

Figure 6. A. Before. Aquiline nose with a wide dome. B. After. Day 1 after rhinoplasty: T-excision, hump resection, digital fracture, columella sliding, and tip refinement using transcutaneous suture.

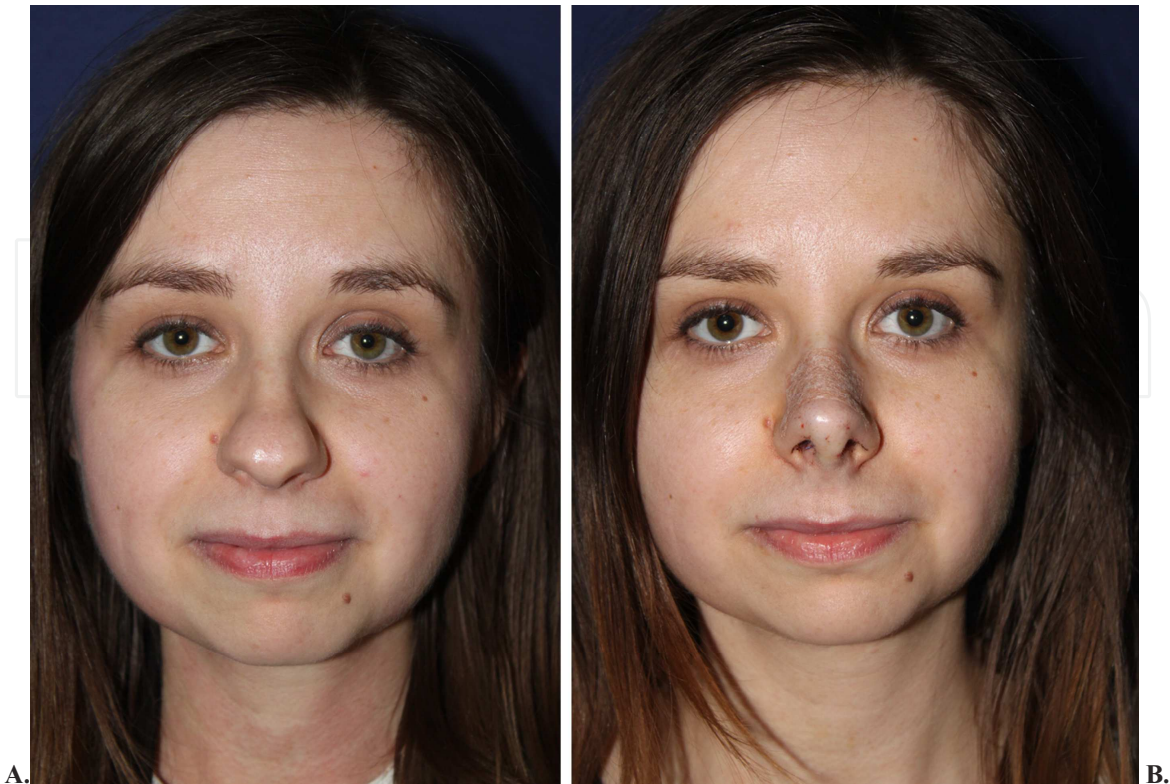

Figure 7. **A.** Before. Aquiline nose with a bulbous tip and hanging columella. Wide volume at the tip, disrupting the beauty triangle and the proportions of the face. **B.** Day 1 after T-excision, humpectomy, digital fracture, columella sliding, and two transcutaneous transdomal sutures for nasal tip and nasal lower third refinement, and transmucosal domal suture to stabilize dome refinement (See Section 6.2.2.). A case with no bruising, due to the atraumatic nature of the techniques. Narrow tip and dorsum, as well as better proportions of the face are present.

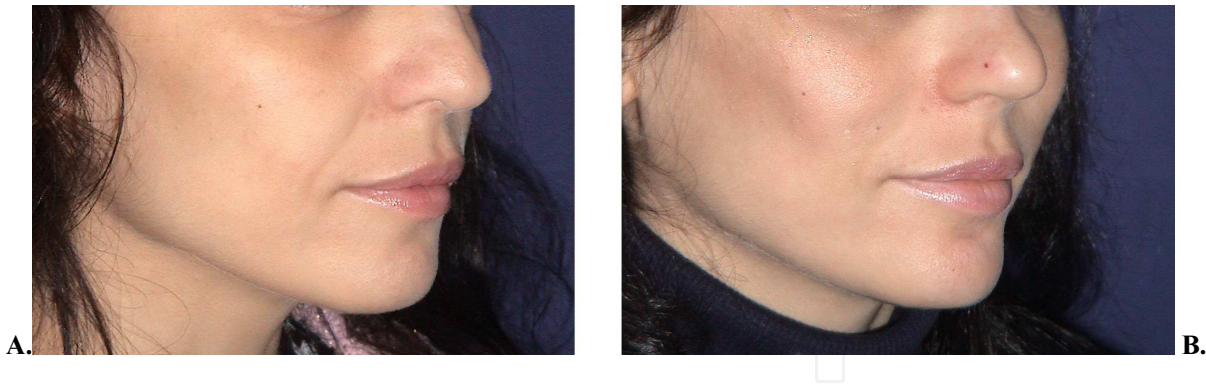

Figure 8. **A.** Before. Long nose. **B.** After. Day 1 after T-excision for tip rotation and transcutaneous transdomal suture for tip refinement. Simultaneous cheekbone lifting and chin enhancement using Serdev Sutures®. A small crust is present at the perforation point. Swelling is present. The patient – TV reporter has used makeup on her way to work.

open medial crura and gives additional projection to the domes. A horizontal mattress suture is placed through mucosa and both medial crura (Figure 9). The domal symmetry can be adjusted with the position of the needle perforating both medial crura. If there is asymmetry of both tips, the needle pass through cartilages should be parallel to the asymmetric defining points of the tip to keep symmetry in the tip area (Figure 1, Chapter 5).

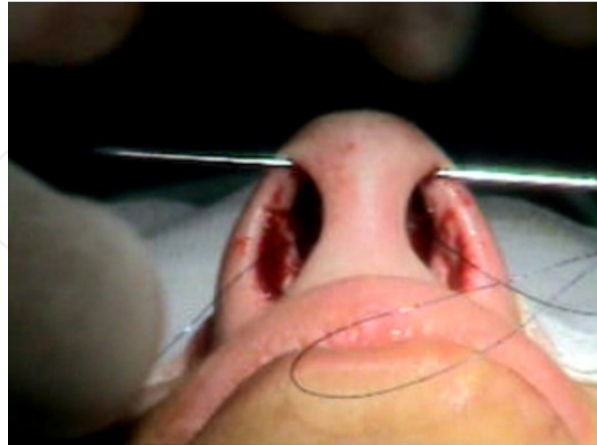


Figure 9. Transmucosal domal suture of medial crura for tip refinement, parallel to the tip defining points.

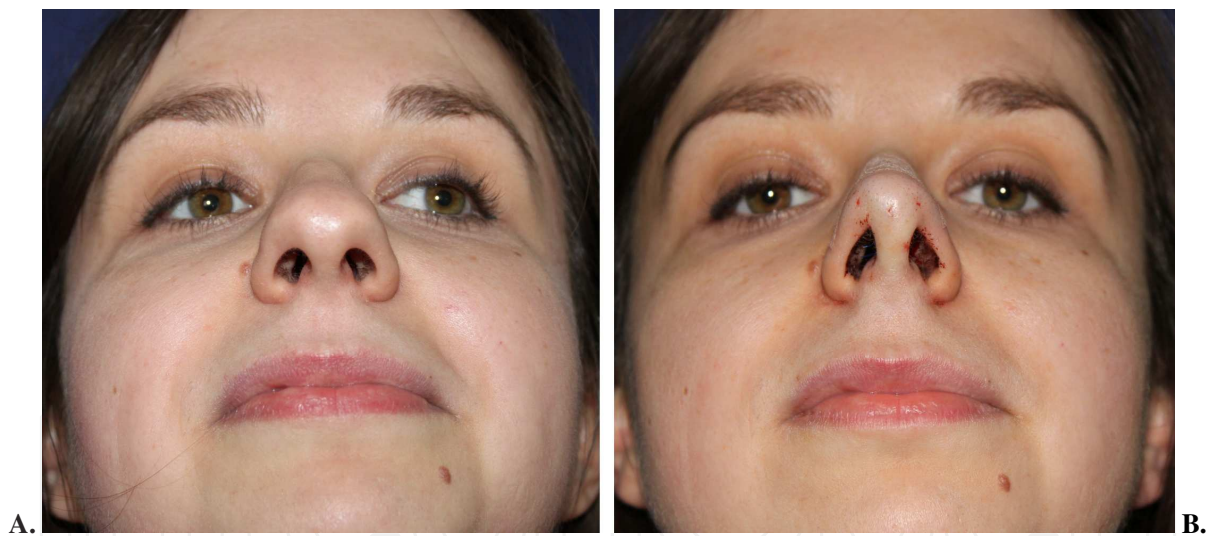

Figure 10. A. Before. A case of aquiline nose with a bulbous tip. **B.** Transcutaneous transdomal and transmucosal domal suture for tip refinement. Day 1 after simultaneous T-excision, humpectomy, digital fracture, columella sliding, two transcutaneous transdomal sutures for nasal tip and nasal lower third refinement, and transmucosal domal suture to stabilize dome refinement.

If both sides of the tip are not equal in projection, a domal equalization of symmetry may need an additional nonhorizontal transdomal or medial crura suture.

Both suture types give good refining definition and at the same time a projection effect. In cases of bulbous tip, transdermal suture of all 4 crura is preferable. Both sutures can be used separately, combined, or as a part of a complex rhinoplasty.

5. Refinement of the dorsum

5.1. Refinement of nasal lower third using lateral crura transcutaneous suspension suture

If prominent lateral crura widen the lower third of the nose, then spanning sutures are used by the author to reduce their convexity and narrow the area cephalic to the tip. The transcutaneous suture should be placed at the highest convexity area, in order to suppress it. Fixation of the suture to a higher point of the dorsal septum is used in selected cases to additionally rotate the tip.

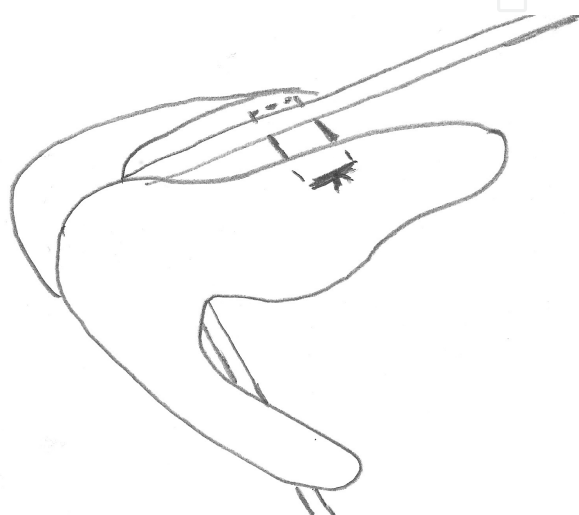


Figure 11. Transcutaneous suspension suture of the lateral crura of the greater alar cartilages for nasal lower third refinement.

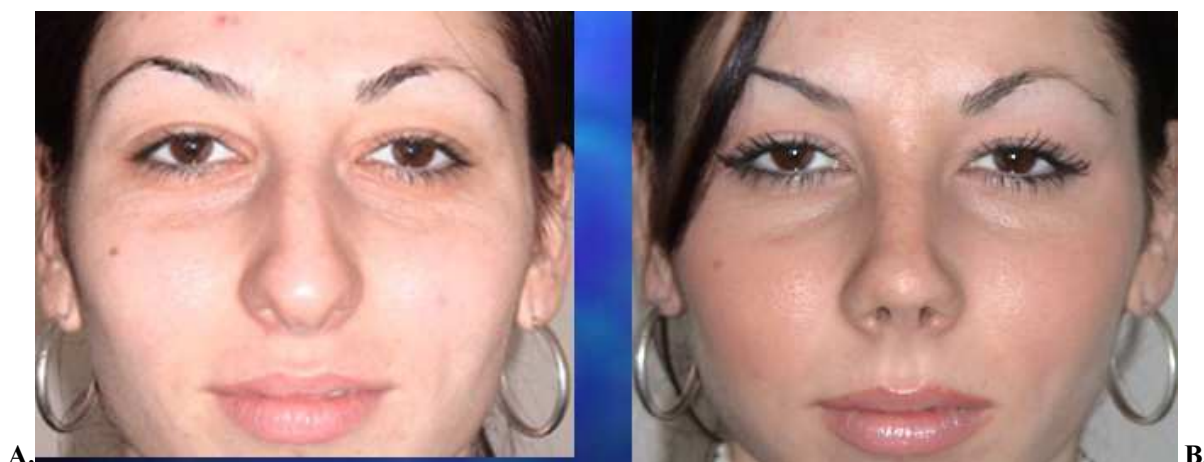

Figure 12. **A.** Before. Slightly deviated aquiline long nose. No septal deviation is present, only nasal bone irregularity. Bulbous tip with hanging columella. **B.** After. Simultaneous T-excision, hump resection, digital fracture to straighten the nasal pyramid, columella sliding, transcutaneous transdomal suture for tip refinement, and transcutaneous suspension suture of the lateral crura of the greater alar cartilages for lower nasal third refinement.

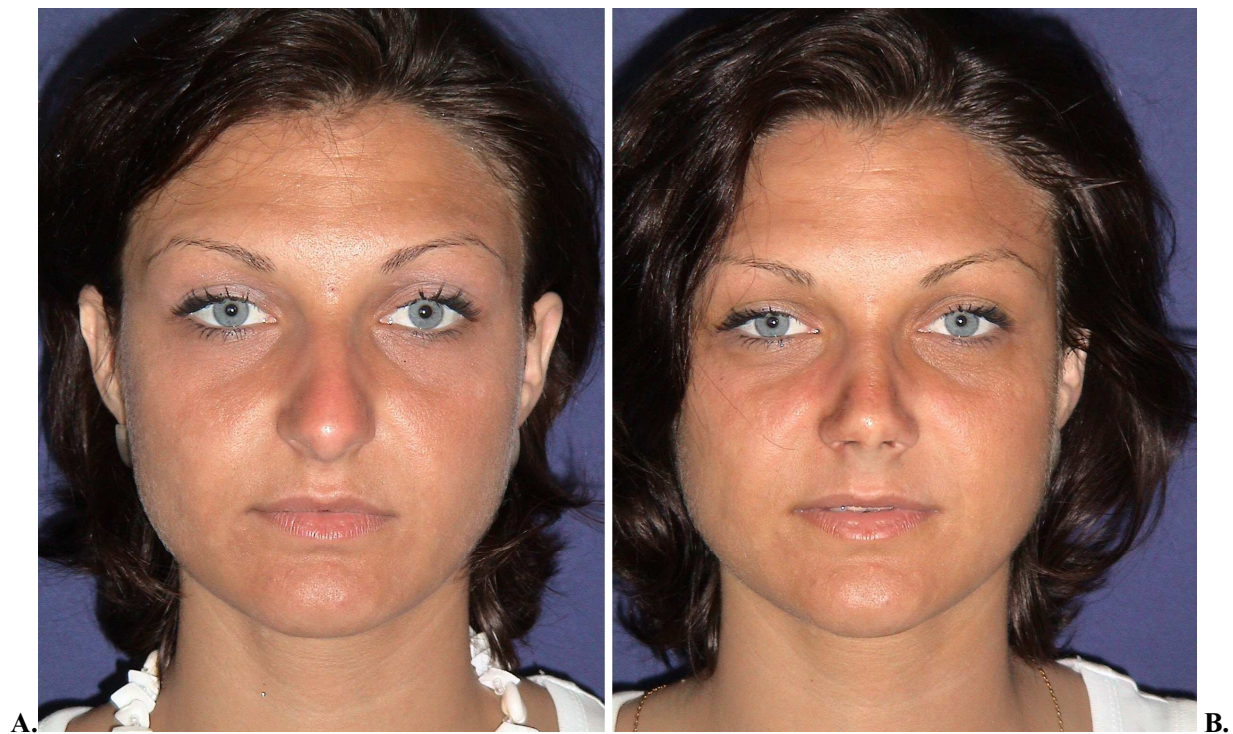

Figure 13. A. Before. B. After simultaneous T-excision for nasal tip rotation, columella sliding for tip projection, transcutaneous transdomal suture for tip refinement and transcutaneous suspension suture of the lateral crura of the greater alar cartilages for lower nasal third refinement.

5.2. Refinement of nasal medial third using transcutaneous suture of upper lateral cartilages

This suture (author's) is useful in primary cases with wide upper lateral cartilages or mostly in secondary cases with open cartilage and bony roof after rhinoplasty.

In secondary cases, digital fracture of the nasal bones and sutures of upper lateral cartilages are used by the author to optimally close the open roof, project and narrow the dorsum at the nasal medial third. One or more transcutaneous sutures could be placed along the cartilage part of the nose at the medial third, lower third, and the tip of the nose for whole dorsum refinement (Figure 14). Fixation of the suture to the dorsal septum is used in selected cases for stabilization, if necessary.

This maneuver is easy, catching the dorsal septum with the semiblunt, semielastic, curved Serdev® needles. They create a round skin perforation point and allow for easy prevention of dermis fixation during the second needle pass. This is an advantage over cutting needles, which create a linear skin perforation that in most cases leads to fixation of the dermis – the result is dimpling, which is impossible to remove.

Stable results also depend on the suture material. Thin, monofilament threads can cut through the fine cartilages. Polycon sutures, braided, semielastic, USP 3-0 protect the sutured cartilages and ensure longevity of the result.

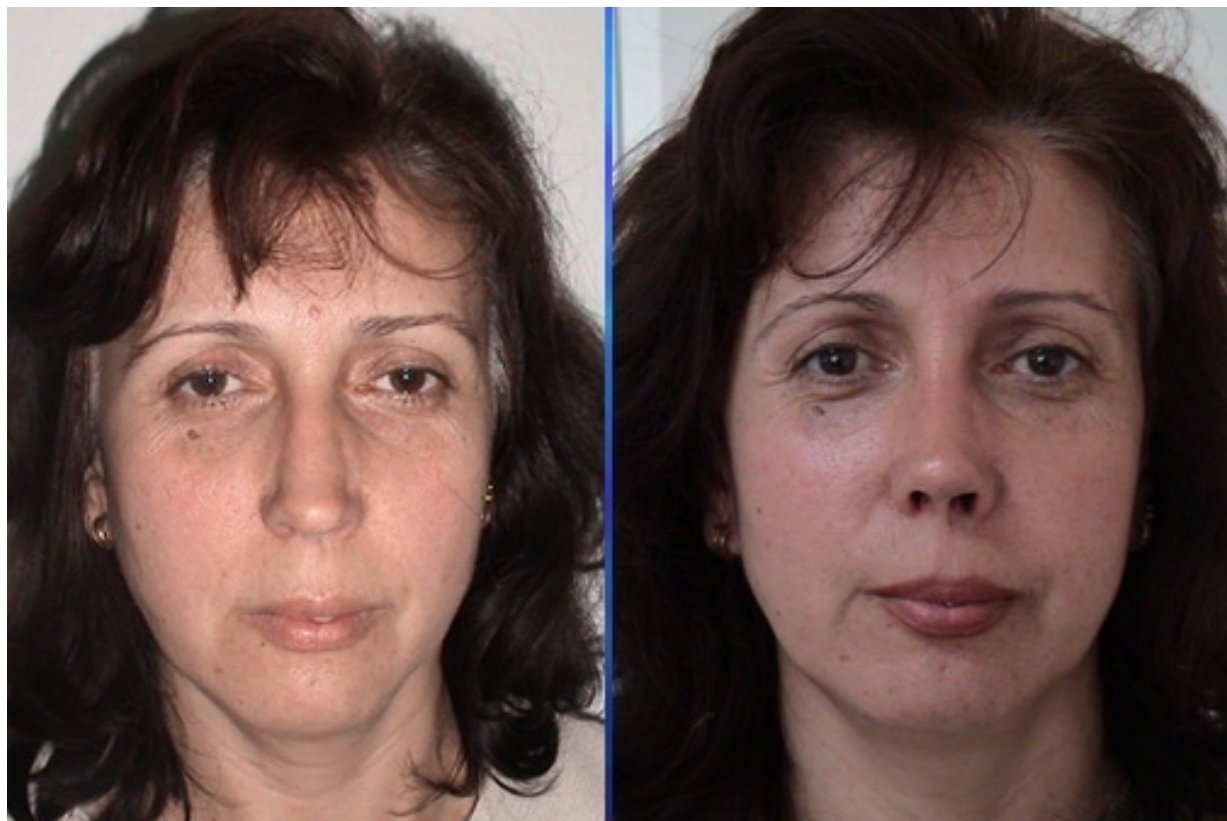

Figure 14. A case with serial sutures along the dorsum to achieve refinement.



Figure 15. Before, 3 days, and 2 months after T-excision, humpectomy, digital fracture for alignment, and sutures for tip and lower nasal third refinement.

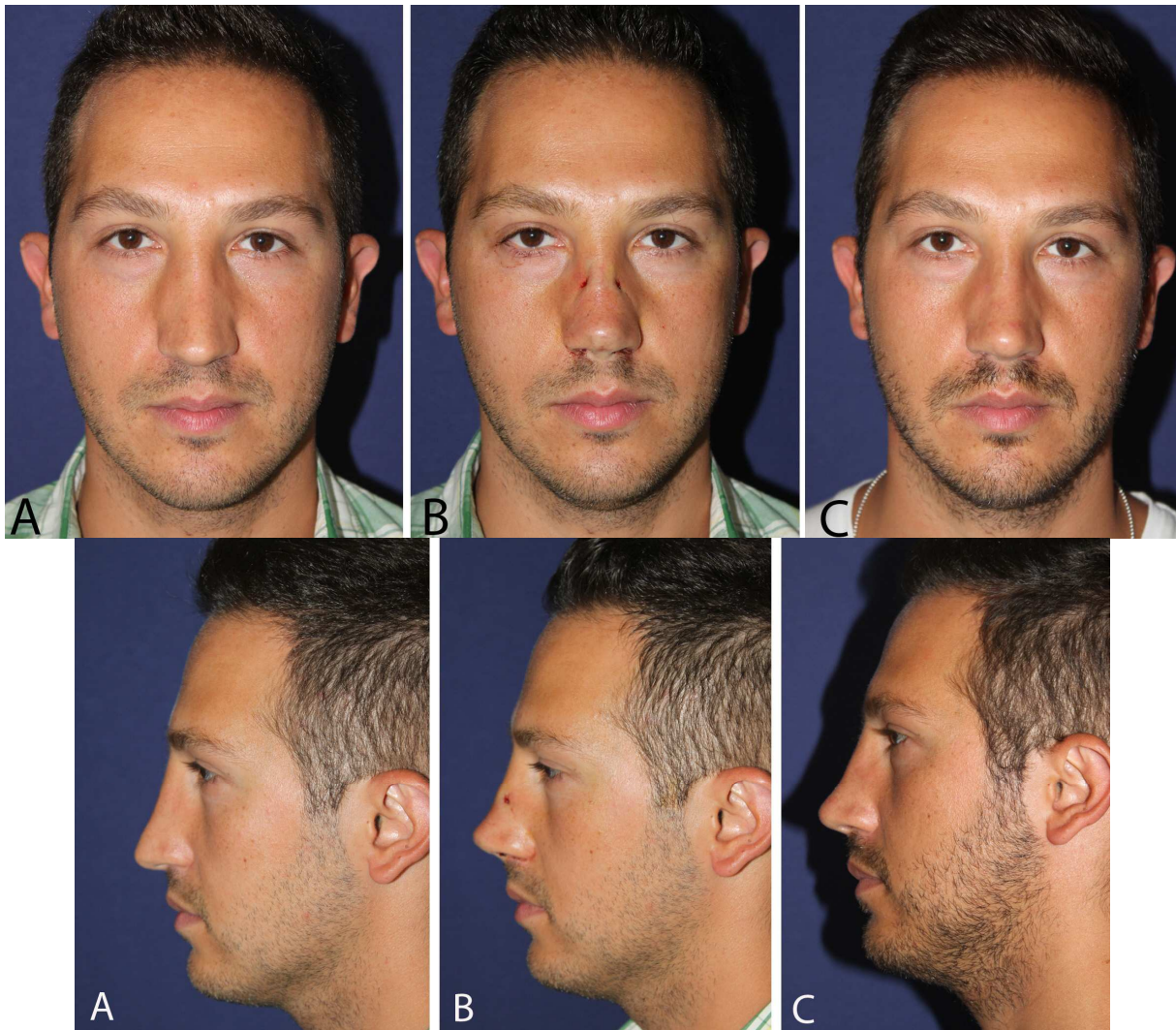

Figure 16. Secondary case. A third rhinoplasty procedure could offer a lot of complications. **A.** Before. Flat nose, very wide step form base of the nasal bones after lateral osteotomy. **B.** Immediate result after T-excision for nasal tip rotation, columella sliding for tip projection, and transcutaneous suture of the upper lateral cartilages for narrowing, re-forming and lifting/projection of the nasal dorsum. Better angles of the nose and proportions of the face. **C.** 3 months later. The nose is proportional, with much better and nearly normal “nonoperated appearance” after atraumatic mini-invasive surgery.

6. Alar base narrowing

The aesthetic angle of the nostrils between the columella and lateral alae should be 30°. Wide alar base with ethnic unstable columella in Asian, Afro-American, and Latino-American patients could need additional columella stabilization suture and transdomal suture for tip refinement.

Alar base narrowing has the additional effect of tip projection.

Deviations and deformities in cases of wide alar base could be different, depending on ethnoses, protruding medial crura, deviated nasal spine, etc. (Figure 17A, B, C). Resection and excision techniques are well known and applicable. In numerous cases the author meets patients who reject excisions and scars, and prefer his suture techniques.

The suture technique represents 2 parallel passes (1–2 mm distance between them), using 2 skin punctures at both nasolabial angles narrowing both nostrils (Figure 17A), or unilateral in cases of one medial crus protruding end (Figure. 17B), or narrowing only the divergent medial crura or combination of sutures (Figure 17 C, D). Suture lines should pass subdermally, exactly caudal to the nostrils and nasal spine. (**NB:** Do not perforate into the nostrils, in order to avoid contamination.)

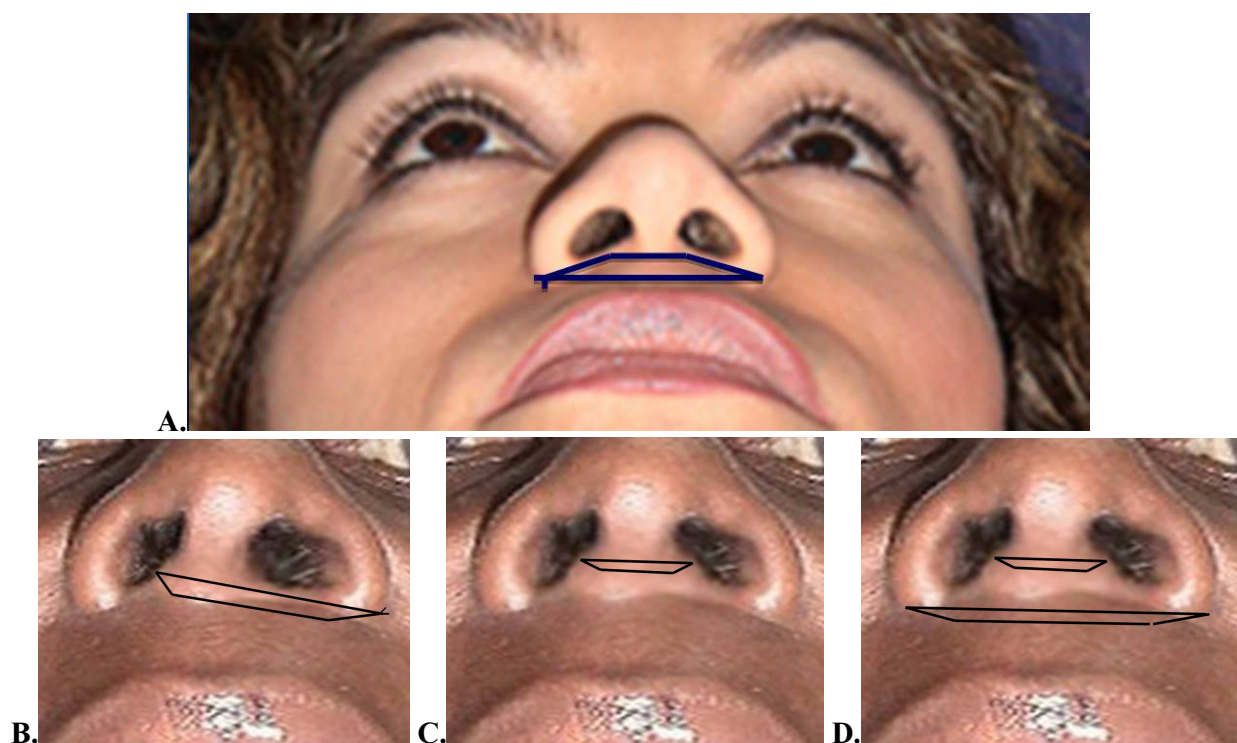


Figure 17. A. If the wide alar base is symmetrical, the suture represents 2 parallel passes (1–2 mm distance between them), using 2 skin punctures at both nasolabial angles. The suture lines should pass subdermally, exactly caudal to the nostrils and nasal spine. B. If the alar base is asymmetrical due to protruding end of one medial crus, the suture can be unilateral, or a combination of A and B. C. If the columella is wide due to divergent footplates of the medial crura of greater alar cartilages, the suture can fix only them. D. If a combination of deviations and deformities are present, different sutures can be used simultaneously.

If the wide alar base is symmetrical, the suture represents 2 parallel passes (1–2 mm distance between them), using 2 skin punctures at both nasolabial angles. Suture lines should pass subdermally, exactly caudal to nostrils and nasal spine (Figure 17A).

There are cases of wide alar base with asymmetrical columella due to one-side divergent medial crus footplate. Then the suture can be unilateral (Figure 17B) or a combination (Figure 17A and B). If the columella is wide due to very divergent footplates of medial crura, the suture

can fix only the divergent end of columella, or any combination of the sutures above, including tip refinement.

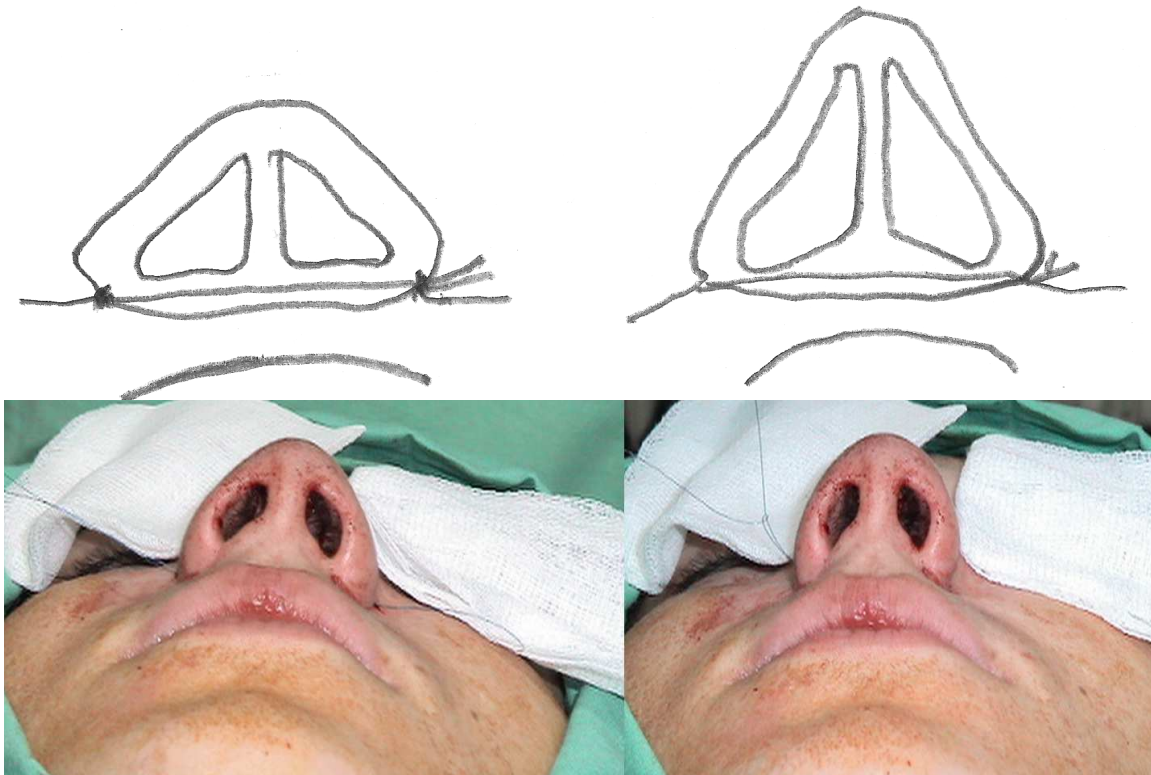


Figure 18. The suture for alar base refinement should obtain the 30° angle of the nostrils at the tip. If not possible, additional tip refinement should be performed.

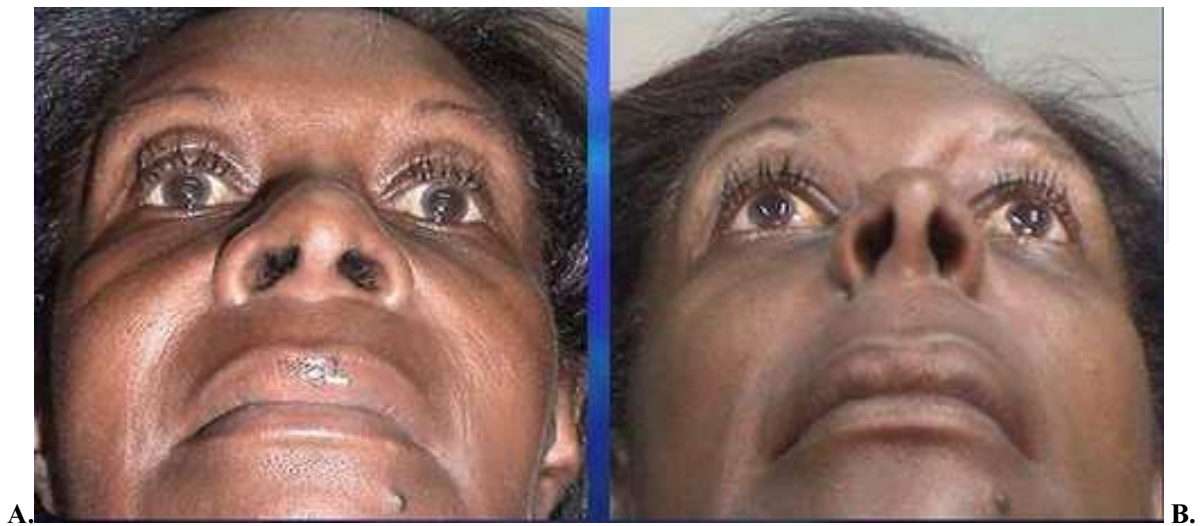

Figure 19. A Before and B. After alar base narrowing in Afro-American patient. Good tip projection and alar angle at the tip.

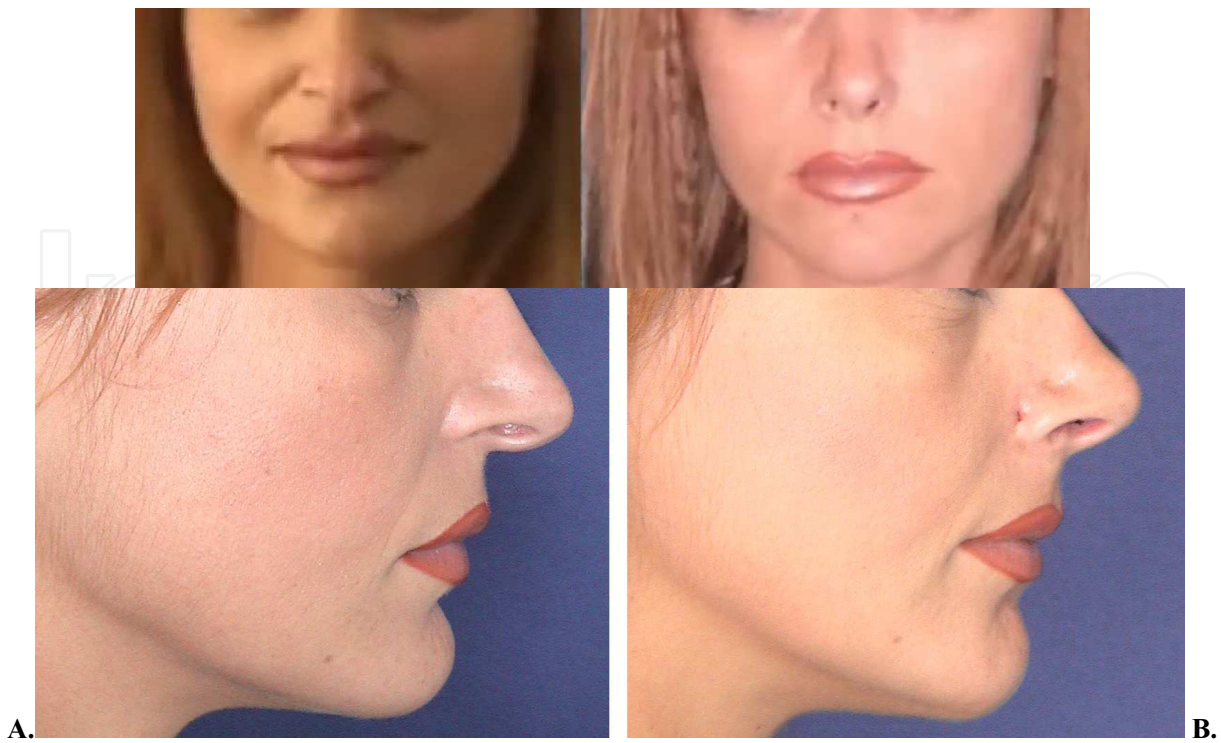

Figure 20. **A.** Before. Long nose with asymmetric nostrils. **B.** After T-excision for tip rotation and unilateral narrowing of the alar base. Photo is taken immediately after the operation.

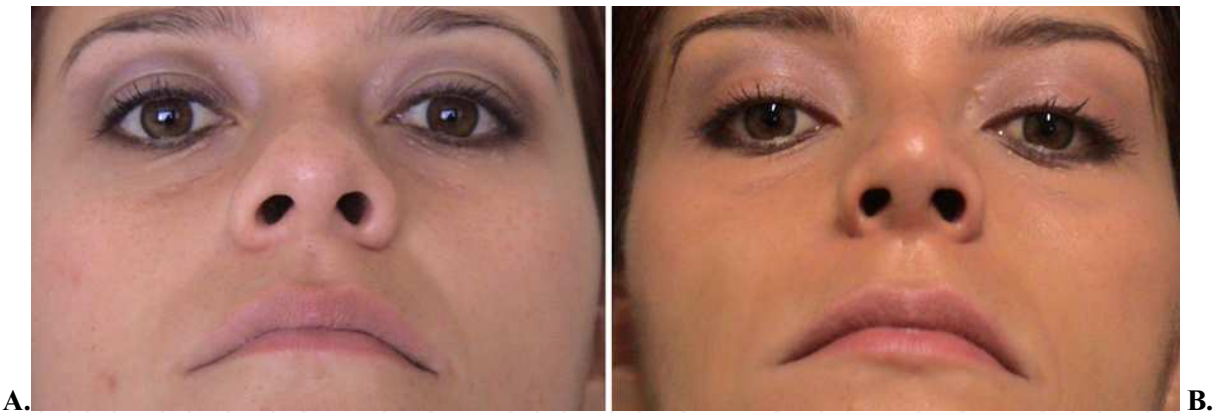

Figure 21. A case of tip refinement and alar base narrowing by sutures in Latino-American patient. Additional brow lift suture has been performed simultaneously.

Serdev Suture® techniques in rhinoplasty have multiple modifications, they are time-saving, prevent trauma, with immediate results, and no downtime. The post-op period is short. There is no bruising; immediate or prompt return to work and social life. No bandages or tampons are necessary.

Alar base narrowing is a very important type of Caucasian-type beautification in Afro-Americans and Asians. It provides refinement in Caucasian faces.

7. Sutures for dorsum prominence

7.1. In primary and secondary depressions and concavities

The author's transcutaneous sutures are placed just above the nasal bones and cartilages to fix fibrotic tissue, in order to project the soft tissue and skin. The dorsal part of cartilages could be sutured as well. A fixation of cartilages to the septum in primary and secondary open roof cases can be used for this purpose as well. In addition, these sutures narrow the nasal dorsum.

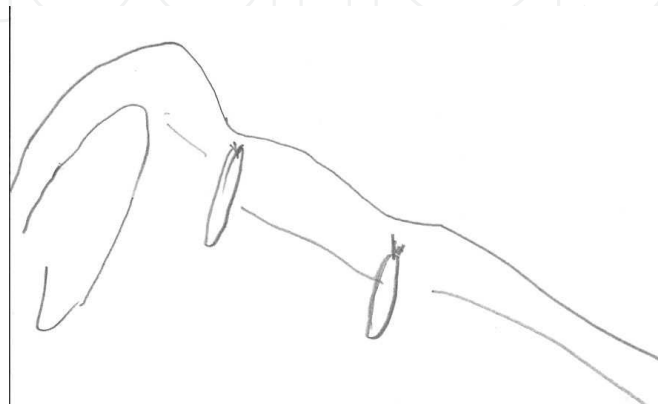


Figure 22. Serdev Sutures® for lifting of nasal dorsum in cases of concavities, and primary and secondary defects.

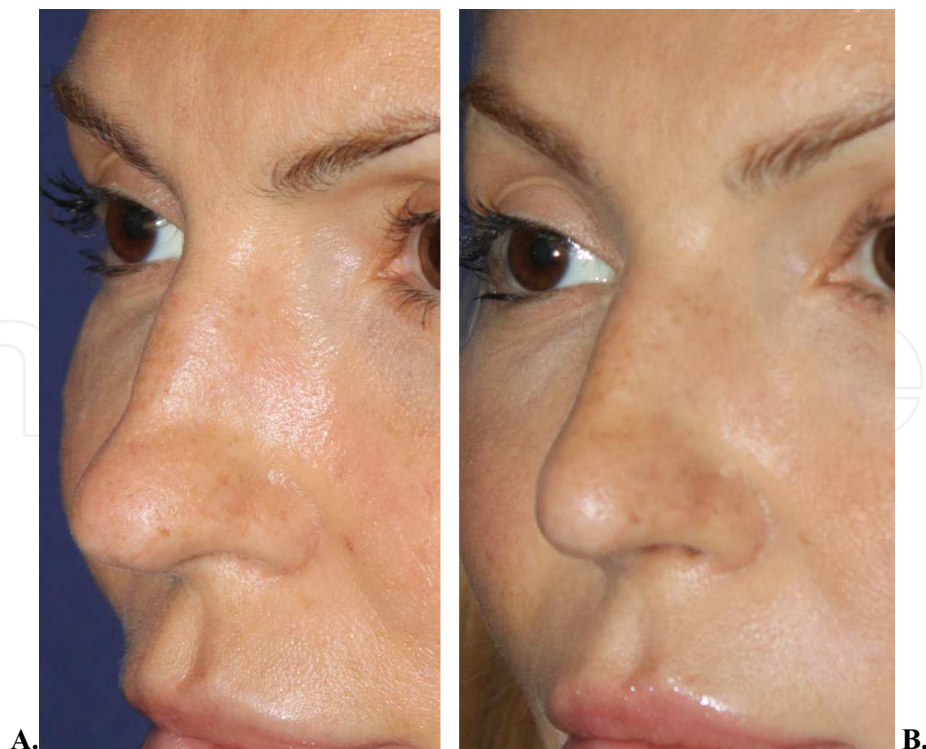

Figure 23. Serdev Suture® for dorsum alignment in supratip depression.

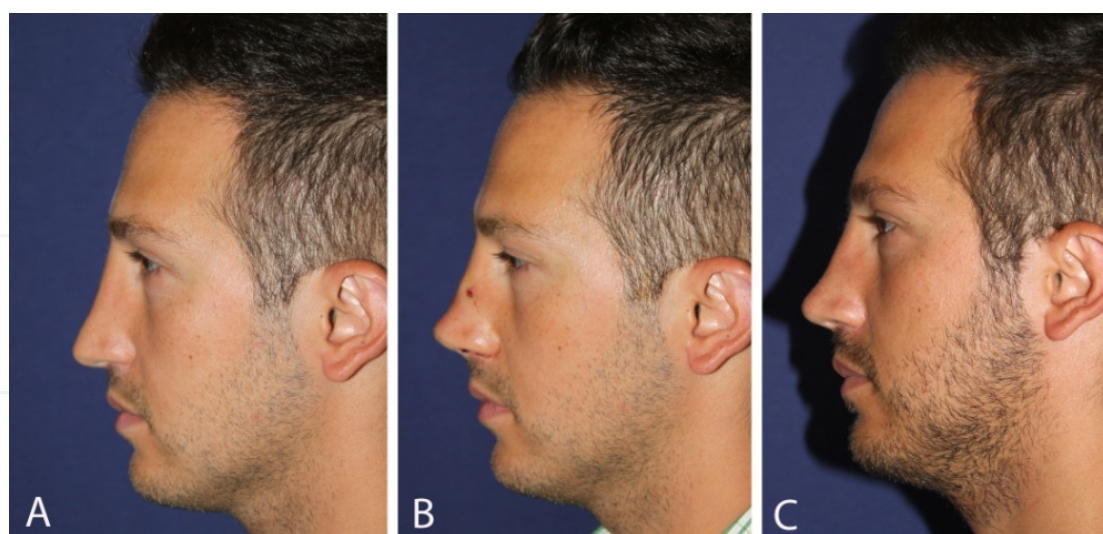

Figure 24. Serdev Suture® for lifting of the dorsum in a secondary open roof case with flat nasal appearance and T-excision for correction of the long nose and achieving of appropriate aesthetic proportions, volumes, and angles.

8. Conclusion

Serdev Sutures® in rhinoplasty, as mini-invasive and atraumatic procedures, used separately or as part of complex rhinoplasty, show advantages over other rhinoplasty techniques. Author's techniques are time-saving, atraumatic operations with great results and complication rate lower than 0.003% [1-3]. Transcutaneous suture techniques have advantages over medical rhinoplasty using temporary fillers as well, because the time of procedure is the same or shorter, but the result is permanent.

Author details

Nikolay P. Serdev*

Address all correspondence to: serdev@gmail.com

New Bulgarian University, Sofia, Medical Centre "Aesthetic Surgery and Aesthetic Medicine," Sofia, Bulgaria

References

- [1] Serdev NP. Suture Suspensions for Lifting or Volume Augmentation in Face and Body (English version), 2nd Annual Meeting of the National Bulgarian Society for

Aesthetic Surgery and Aesthetic Medicine, Sofia, March 18, 1994, *Int J Aesth Cosm* 2001; 1(1):2561-2568

- [2] Serdev NP. Principles of Face Beautification, Third World Congress of the International Society of Aesthetic Surgery, Tokyo April 8-10, 2000, 9W58
- [3] Serdev NP. Course: Beautification rhinoplasty, t-zone excision, columella sliding, suture methods, Updates in IV sedation and analgesia. 2005; Feb 23. Available from: <http://ijcs.org/courses/2005/90/index.php>
- [4] Serdev NP. Serdev sutures for: Nasal tip refinement, nasal tip rotation, Nasal alar base narrowing. *Int J Cosm Surg* 2007; 7(1):328- 386
- [5] Serdev NP. Serdev techniques in beautification rhinoplasty: T-zone excision, columella sliding, Serdev sutures. *Int J Cosm Surg* 2008; 8(1):388-469
- [6] Serdev NP. Nasal tip refinement, rotation, projection, alar base narrowing In: Serdev NP, Ed. *Serdev Sutures® Face and Body Lifts and/or Volumising*. Marllor editions, Italy, 2013: 75-81
- [7] Serdev NP. Serdev Sutures® in middle face 4. Beautification rhinoplasty – tip rotation and refinement, alar base narrowing. In: Serdev NP, Ed. *Miniinvasive Face and Body Lifts – Closed Suture Lifts or Barded Thread Lifts*. Intech, Rijeka, 2013. Available from <http://www.intechopen.com/books/miniinvasive-face-and-body-lifts-closed-suture-lifts-or-barbed-thread-lifts/serdev-sutures-in-middle-face>.
- [8] Serdev NP. Chin enhancement by scarless Serdev suture and Serdev rhinoplasty without tampons and bandages. Shop the world for beauty secrets E5 (Video) YouTube 2009; 12.05. Available from <http://www.youtube.com/watch?v=2wj5q3RCvuQ>.
- [9] Serdev NP. Secondary rhinoplasty - Tip rotation by Serdev suture after hump removal (video) YouTube 2011; 12.04. Available from <http://www.youtube.com/watch?v=nRh8NDSgDck>
- [10] Serdev NP. Rhinoplasty bloodless beautification in minutes, no bruising, no tampons, no plaster 19.02.2014 <http://www.youtube.com/watch?v=pRSGBqe8r6E>
- [11] Serdev NP. Rhinoplasty Dr Serdev author methods 1.07.2009 <http://www.youtube.com/watch?v=Ci53JRQIJFc>
- [12] Serdev NP. Nasal tip rotation by Serdev suture in secondary rhinoplasty 31.05.2012 <http://www.youtube.com/watch?v=IClFcRur-gs>
- [13] Serdev NP. Beautification rhinoplasty, T-excision, columella sliding, 6.04.2009 <http://www.youtube.com/watch?v=xe6lA-3fY6c>
- [14] Serdev NP. Beautification rhinoplasty in a long nose t excision columella sliding 26.10.2013 r. <http://www.youtube.com/watch?v=v1wMYoOayKc>

- [15] Serdev NP. Simultaneous brow lift by Serdev suture with chin dimple and secondary rhinoplasty 7.04.2009. <http://www.youtube.com/watch?v=jWQocHglFWs>
- [16] Serdev NP. Rhinoplasty. Tip refinement by Serdev suture. No scars, 27.01.2010 r. <http://www.youtube.com/watch?v=o2Ypkxqes7w>
- [17] Serdev NP. Live on TV Rhinoplasty, Brow Suture Lift, Chin Enhancement 10.01.2013 r. <http://www.youtube.com/watch?v=H73PTB2xyKU>
- [18] Behmand RA, Ghavami A, Guyuron B. Nasal tip sutures, part I: the evolution. *Plast Reconstr Surg* 2003;112(4):1125-1129, discussion 1146-1149.
- [19] Tebbetts JB. Shaping and positioning the nasal tip without structural disruption: a new, systematic approach. *Plast Reconstr Surg* 1994;94(1):61-77.
- [20] Mocella S, Bianchi N. Double interdomal suture in nasal tip sculpturing. *Facial Plast Surg* 1997;13(3):179-196
- [21] . Suture contouring of the nasal tip. *Arch Facial Plast Surg* 2000;2(1): 34-42.
- [22] Leach JL, Athre RS. Four suture tip rhinoplasty: a powerful tool for controlling tip dynamics. *Otolaryngol Head Neck Surg* 2006;135(2):227-231.
- [23] Tardy ME, Cheng E. Transdomal suture refinement of the nasal tip. *Facial Plast Surg* 1987;4(4):317-326.
- [24] Papal ID. Interlocked transdomal suture technique for the wide interdomal space in rhinoplasty. *Arch Facial Plast Surg* 2005;7(6):414-417.
- [25] Daniel RK. Rhinoplasty: a simplified, three-stitch, open tip suture technique, part I: primary rhinoplasty. *Plast Reconstr Surg* 1999;103(5):1491-1502.
- [26] McCollough EG, English JL. A new twist in nasal tip surgery: an alternative to the Goldman tip for the wide or bulbous lobule. *Arch Otolaryngol* 1985;111 (8):524-529.
- [27] Daniel RK. Rhinoplasty: creating an aesthetic tip: a preliminary report. *Plast Reconstr Surg* 1987;80(6):775-783.
- [28] Kridel RW, Konior FJ, Shumrick KA, Wright WK. Advances in nasal tip surgery: the lateral crural steal. *Arch Otolaryngol Head Neck Surg* 1989;115(10):1206-1212.
- [29] Pastorek NJ, Becker DG. Treating the caudal septal deflection. *Arch Facial Plast Surg* 2000;2(3):217-220.
- [30] Gruber RP, Friedman GD. Suture algorithm for the broad or bulbous nasal tip. *Plast Reconstr Surg* 2002;110(7):1752-1764, discussion 1765-1768.