

We are IntechOpen, the world's leading publisher of Open Access books Built by scientists, for scientists

6,900

Open access books available

186,000

International authors and editors

200M

Downloads

Our authors are among the

154

Countries delivered to

TOP 1%

most cited scientists

12.2%

Contributors from top 500 universities



WEB OF SCIENCE™

Selection of our books indexed in the Book Citation Index
in Web of Science™ Core Collection (BKCI)

Interested in publishing with us?
Contact book.department@intechopen.com

Numbers displayed above are based on latest data collected.
For more information visit www.intechopen.com



Depressor Septi Nasi Muscle Resection or Nerve Block

Daniel G. Moina and Gabriel M. Moina

Additional information is available at the end of the chapter

<http://dx.doi.org/10.5772/62073>

Abstract

In our daily practice, we usually perform the rhinoplasty without considering the dynamic functions. The depressor septi nasi muscle (DSNM) is very important in nose dynamics. Its hyperactivity in some rhinoplasty patients while they smiling or speaking causes a deformity that includes drooping of the nasal tip, elevation and shortening of the upper lip, and increased maxillary gingival show. The dissection of the depressor septi muscle during rhinoplasty can improve the tip-upper lip relationship in appropriately selected patients.

To manage this functional part of rhinoplasty, we aimed to clarify the anatomic study, surgical indications, rationale for the operative technique, and clinical cases are presented.

Keywords: Depressor septi nasi muscle, Nasalis muscle, Nose muscle, Nasal tip drooping, Nose tip Fall, Smile test, Open rhinoplasty, Close rhinoplasty, nasolabial complex, DSNM hyperactivity, Nasal length, Facial muscles, Teeth exposure, Suspended upper lip, Gingival show, Gummy smile, Botulinum toxin, BTN-A, Nerve block

1. Introduction

1.1. Anatomy of depressor septi nasi muscle

The anatomy of the depressor septi nasi has been well studied by Rod Rohrich [1,2]. Is a small, paired muscle located on either side of the nasal septum, has four proximal attachments, footplates of the medial crura, caudal septum, dermocarilaginous ligament and anterior nasal spine, The muscle is divided by the nasal septum into bilateral and symmetric portions. On each of these portions we may observe a division in its fascicles:

- Medial: in medial position, parallel to the nasal septum.
 - Intermedial: between medial and lateral.
 - Lateral: this one more peripheral to the nasal septum.
-

They were interdigitated with the orbicularis oris. Like the other muscles of the nose is innervated by branches of the facial nerve and supplied by the facial artery.

Three variation of the depressor septi muscle were delineated (Fig.1-2):

Type I: Inserted fully into the orbicularis oris. 62 %.

Type II: Inserted into the periosteum and incompletely into the orbicularis oris. 22%.

Type III: Showed no or rudimentary depressor septi muscle. 16 %.

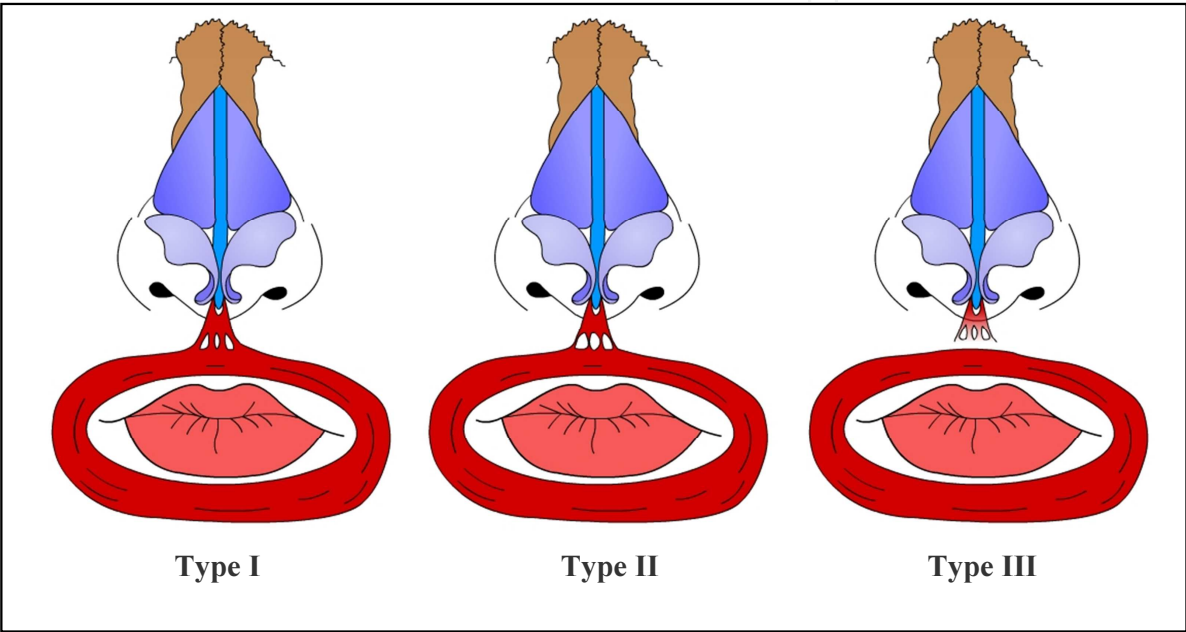


Figure 1. Anatomical variation of the depressor septi muscle.

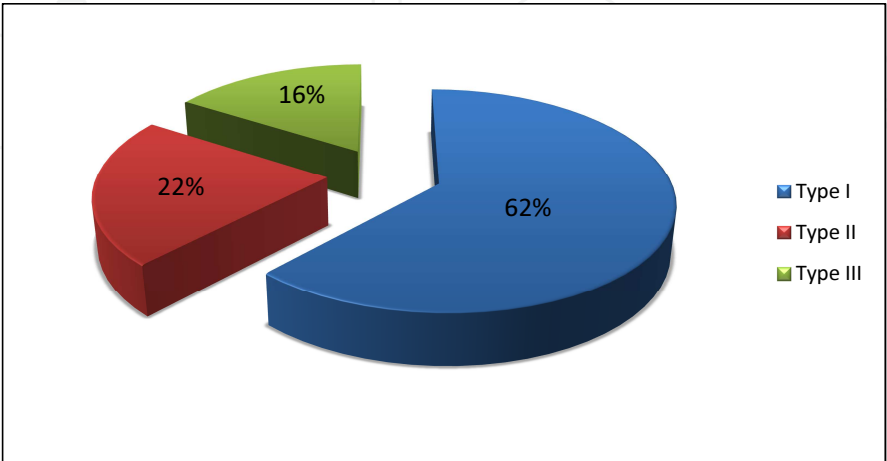


Figure 2. Percentages of anatomical variation of the depressor septi muscle.

In some patients (type I and II), animation (particularly smiling) produces a deformity characterized by:

1. A descending nasal tip.
2. A shortened upper lip.
3. An increased maxillary gingival show.
4. A transverse crease in the mid-philtral area.

In 1992 Cachay velazquez described these modifications as rhino-gingivolabial syndrome of the smile (drooping of the nasal tip, elevation and shortening of the upper lip, and increased maxillary gingival show) [3].

It's important to note that not only produces aesthetic alterations, also produces functional changes, alters the air turbulence.

The aim of treating the muscle with a minimally invasive surgery (permanent) or botulinum toxin (temporary) is decrease the effect of smiling on all four parameters.

Smile test (Wright 1976): Before the operation, during the smile analysis, front and lateral facial photographs of patients in repose and full smile were studied and at follow-up visits (Fig.3) [4,5,6].

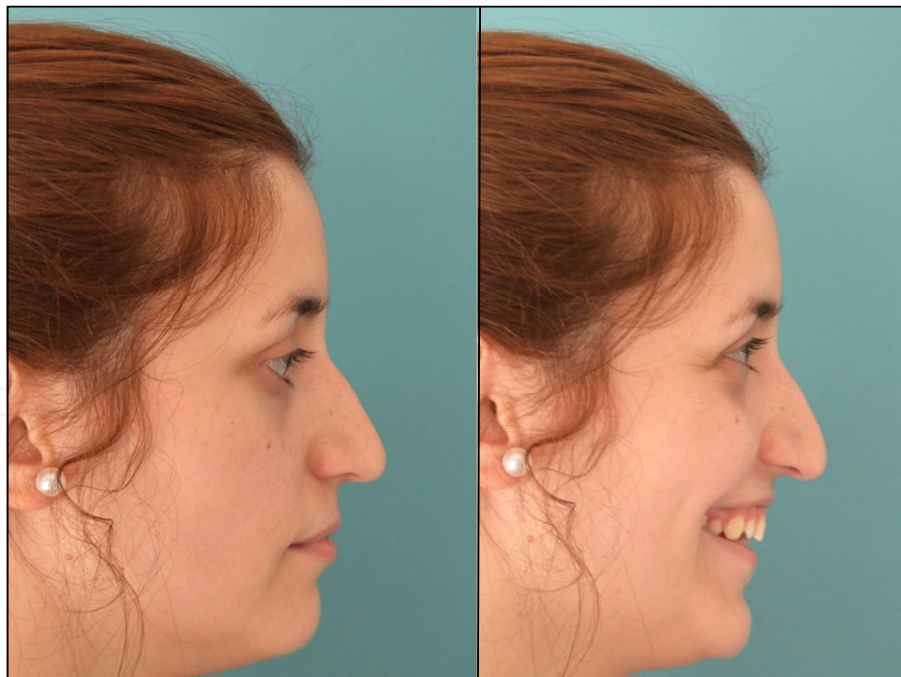

Figure 3. Smile Test, plunging of the nasal tip when smiling.

After the photographs the nasal length (NL) from the radix to the tip, tip projection (TP) from the alar-cheek junction to the tip, upper lip height (UL) and the presence or absence of a transverse upper labial crease (TC) were determined (Fig.4).

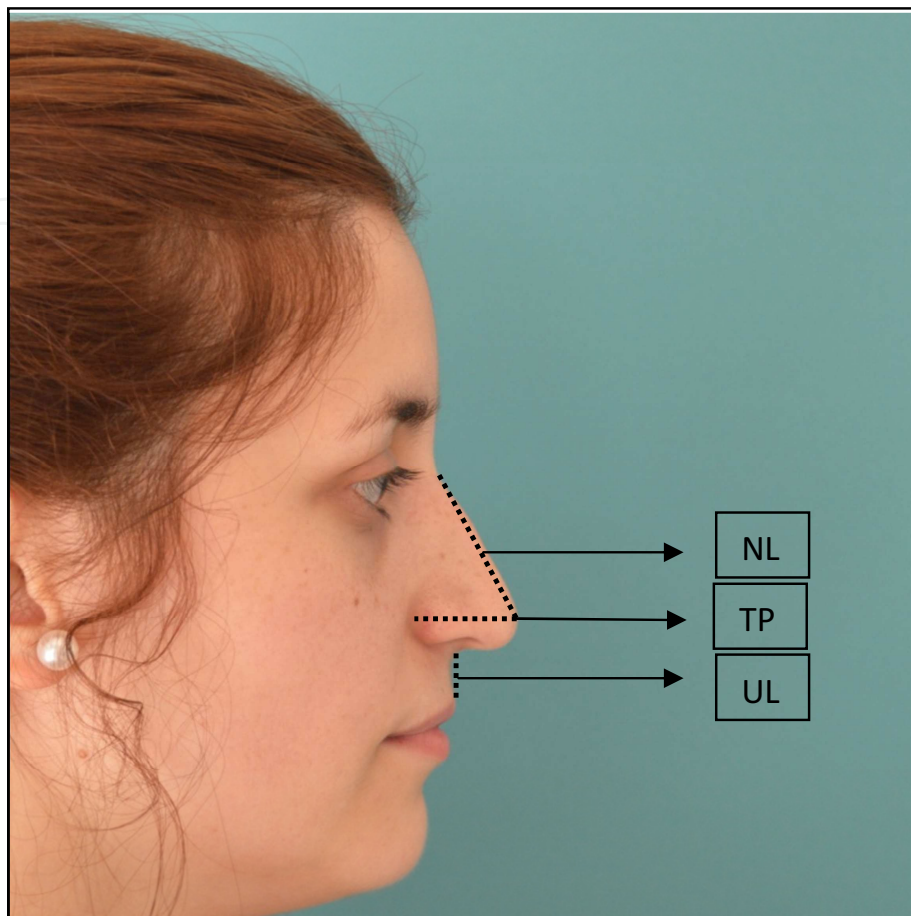


Figure 4. There main parameters used to evaluate the DSNM, NL (nasal length), TP (tip projection) and UL (upper lip height).

2. Surgical treatment of the depressor septi nasi muscle

The main and most important objective of the treatment is to remove the distal tension of the nasal tip, releasing and elevating it (Fig.5).

There are two surgical techniques for depressor septi nasi muscle treatment, transnasal and transoral technique. It's important to note that the two different techniques were not significantly different in decreasing the effects of smiling on nasal length, tip projection, upper lip height, or transverse crease.

Note: Release of this muscle also cause slight ptosis of the upper lip which may not be beneficial in patients with long upper lip.

The authors of this chapter use the transoral technique if the patient have a tethering of the frenulum and use the transnasal technique if you don't (Fig.6) [7].

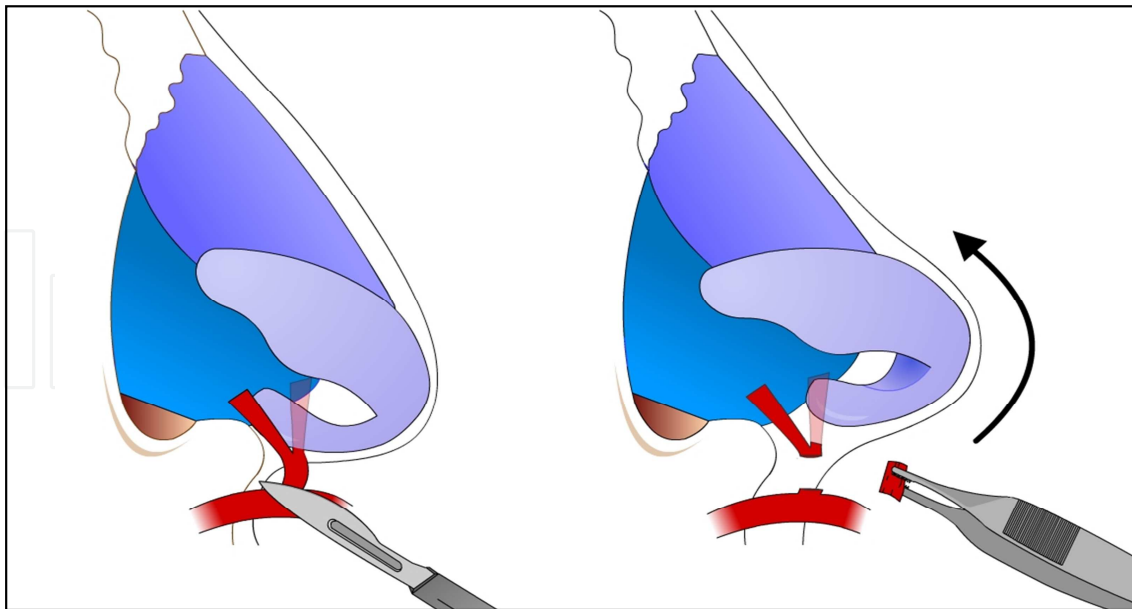


Figure 5. After resection of the muscle, the nasal tip is released.

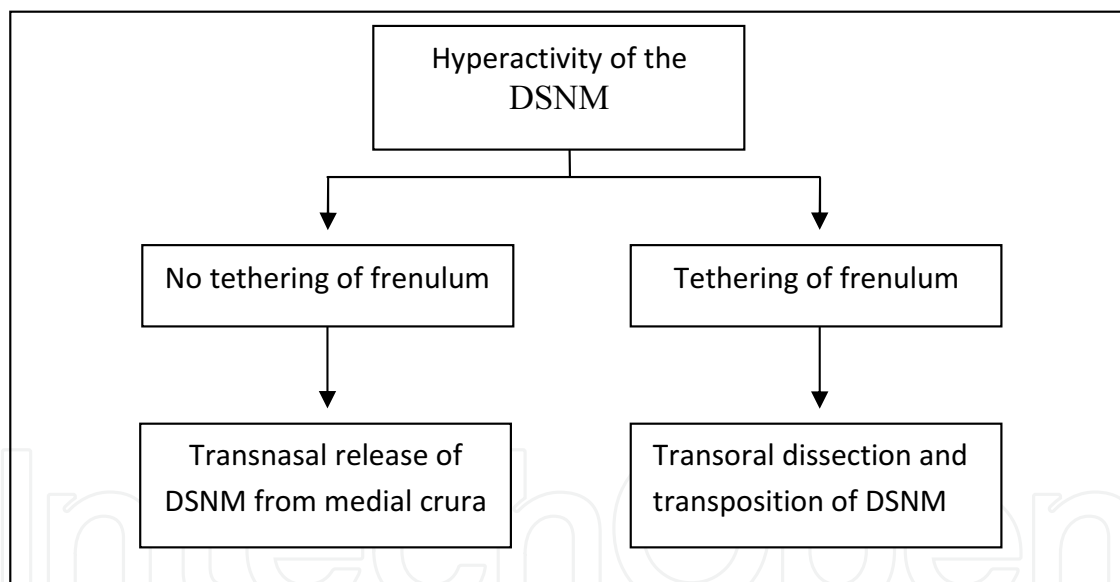


Figure 6. Algorithm for treatment of the DSNM.

- Transoral Technique (Fig.7):

We infiltrate the mucosa, frenulum and the soft tissue with 2% lidocaine with epinephrine 1:50,000, this way we produce analgesia and vasoconstriction, later on with a scalpel blade # 15 make a horizontal upper labial sulcus incision of no more than 10 mm, the depressor septi nasi muscle is released near its origin with the orbicularis oris or periosteum, transposed, and sutured to the contralateral transposed depressor septi nasi muscle (Nylon 4.0). The horizontal incision is closed vertically (vicryl 4.0).

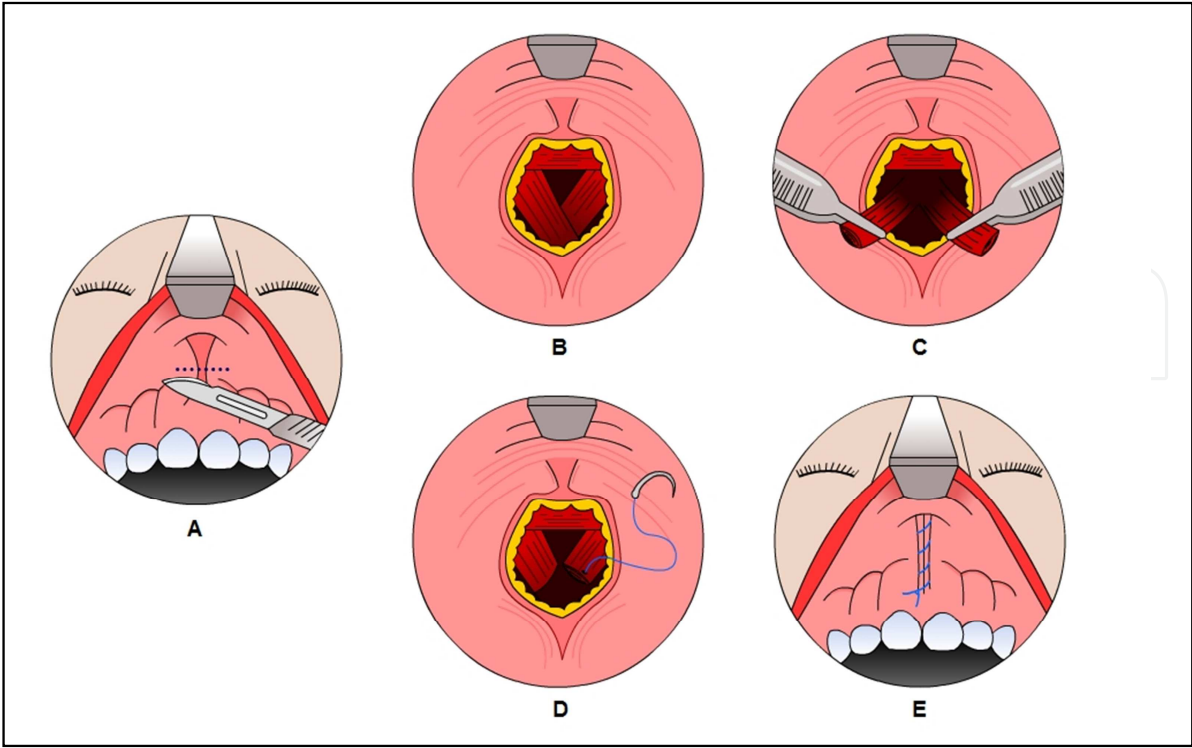


Figure 7. An artistic illustration of the transoral technique. a) Horizontal upper labial sulcus incision; b, c, d) Transposed and sutured to the contralateral transposed depressor septi nasi muscle; e) Close the horizontal incision vertically.

2.1. Transnasal technique

We infiltrate the membranous septum with 2% lidocaine with epinephrine 1:50,000, with a scalpel blade # 15 we make an incision of no more than 5 mm along the vestibular floor, the depressor septi nasi muscle is dissected and elevated with a dissecting Metzenbaum scissors from its position behind the columella, between the medial crura. Mahe and Camblin have noted that transaction of the depressor septi muscle may fail to produce lasting results because of reattachment of the muscle, that's why we prefer resect a 5-mm segment (Fig.8-9):

3. Nerve block of the depressor septi nasi muscle

For patients who don't want a surgical treatment, we purpose the blocking of the depressor septi nasi with BNT-A for similar but temporary results, about 4 to 6 months. (Fig.10):

3.1. Trancutaneous technique

After patient selection, we mark the injection points at the base of the columella, two points at the medial crural footplate and one point between the two medial crura.

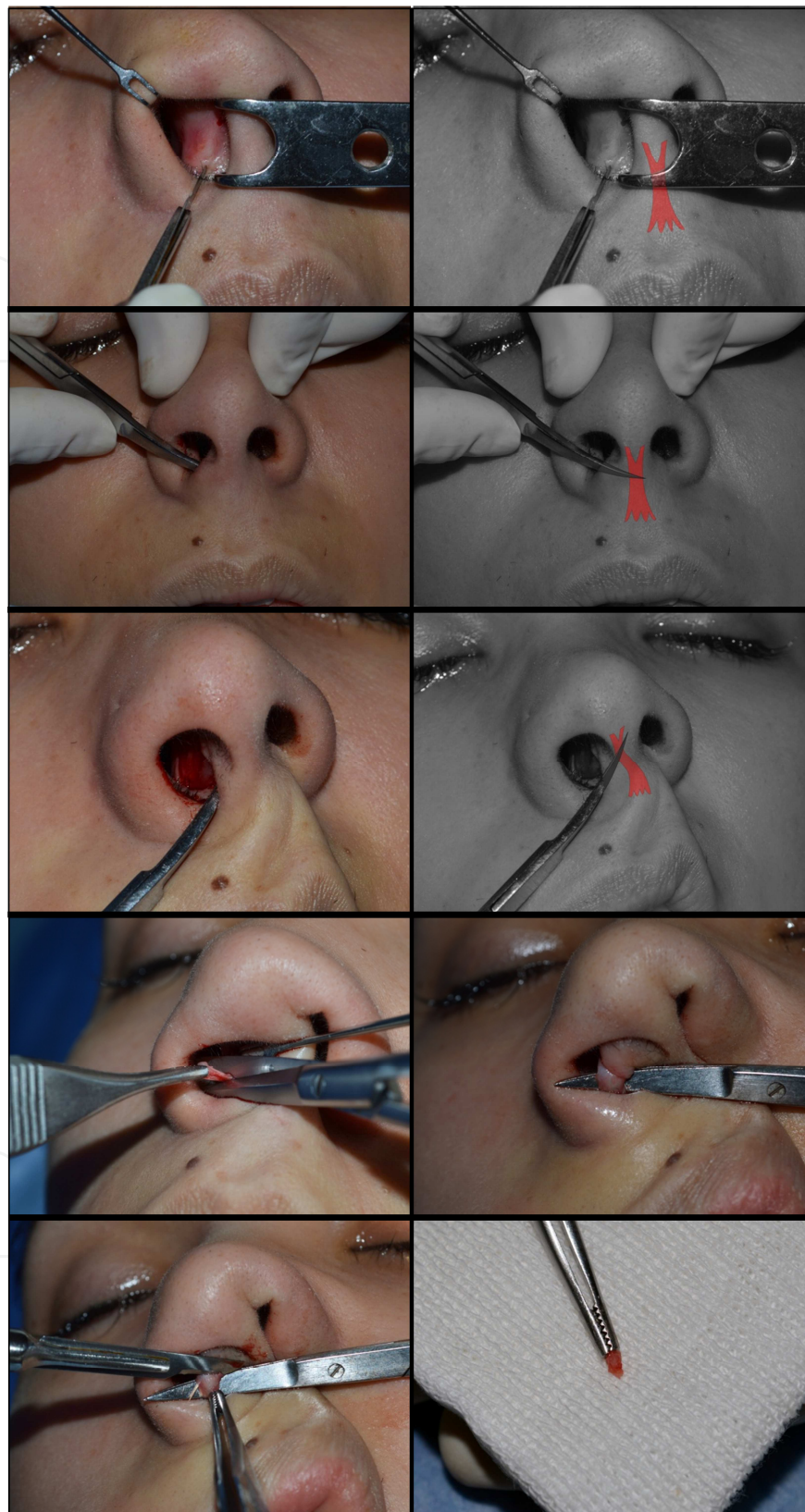


Figure 8. Transnasal technique.

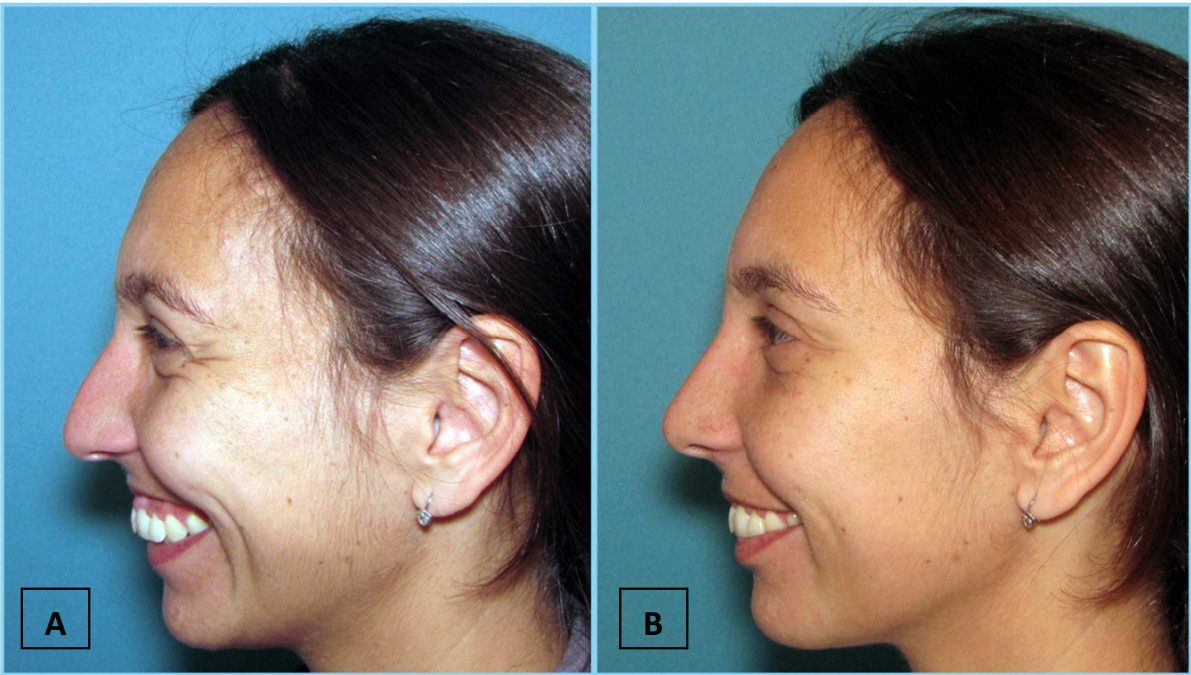

Figure 9. A) Preoperative patient with gingival smile, lowering of the nasal tip, upper lip shortening, and transverse crease in the mid-philtral area. B) Same patient in the post period.

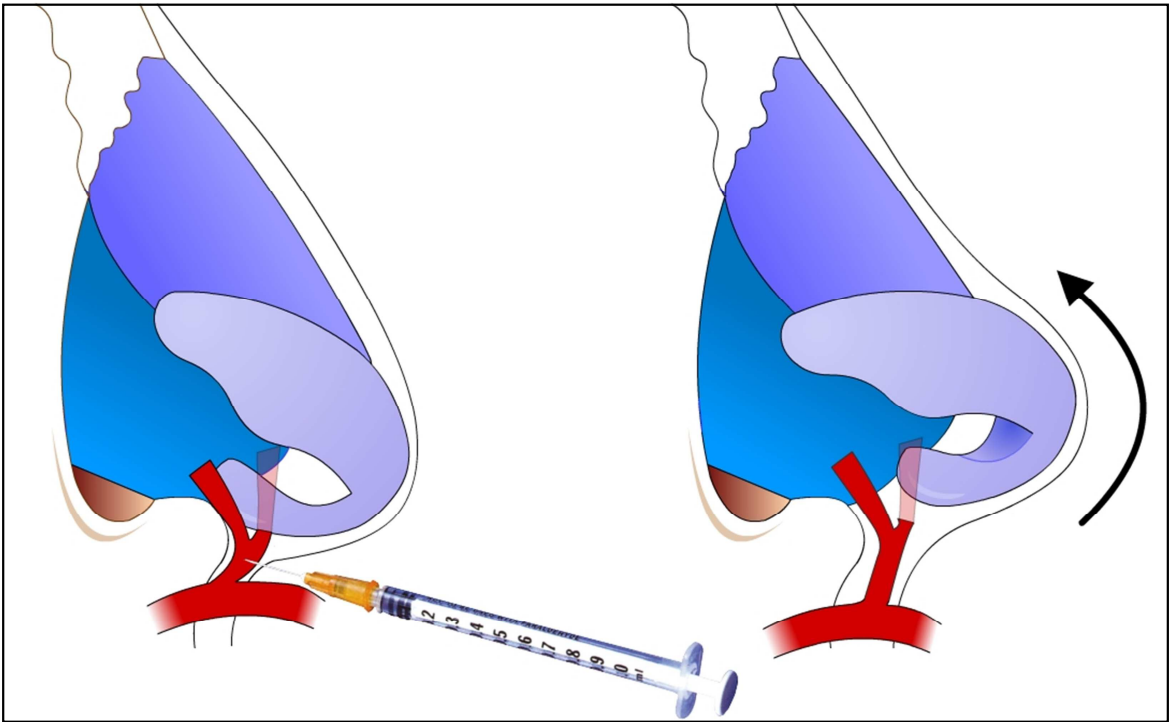


Figure 10. Nasal-labial angle blocking the m. depressor septi nasi with BNT-A: through the skin.

With a 1ml syringe and a 30G needle injecting 1 U of BNT-A at each point (Fig.11). After 1 week the results we get are relax the DSNM, enhancement of the nasolabial angle in static and

dynamic positions, improvement the transverse crease in the mid-philtral area and prevent the dropping of the nasal tip during smile [8].

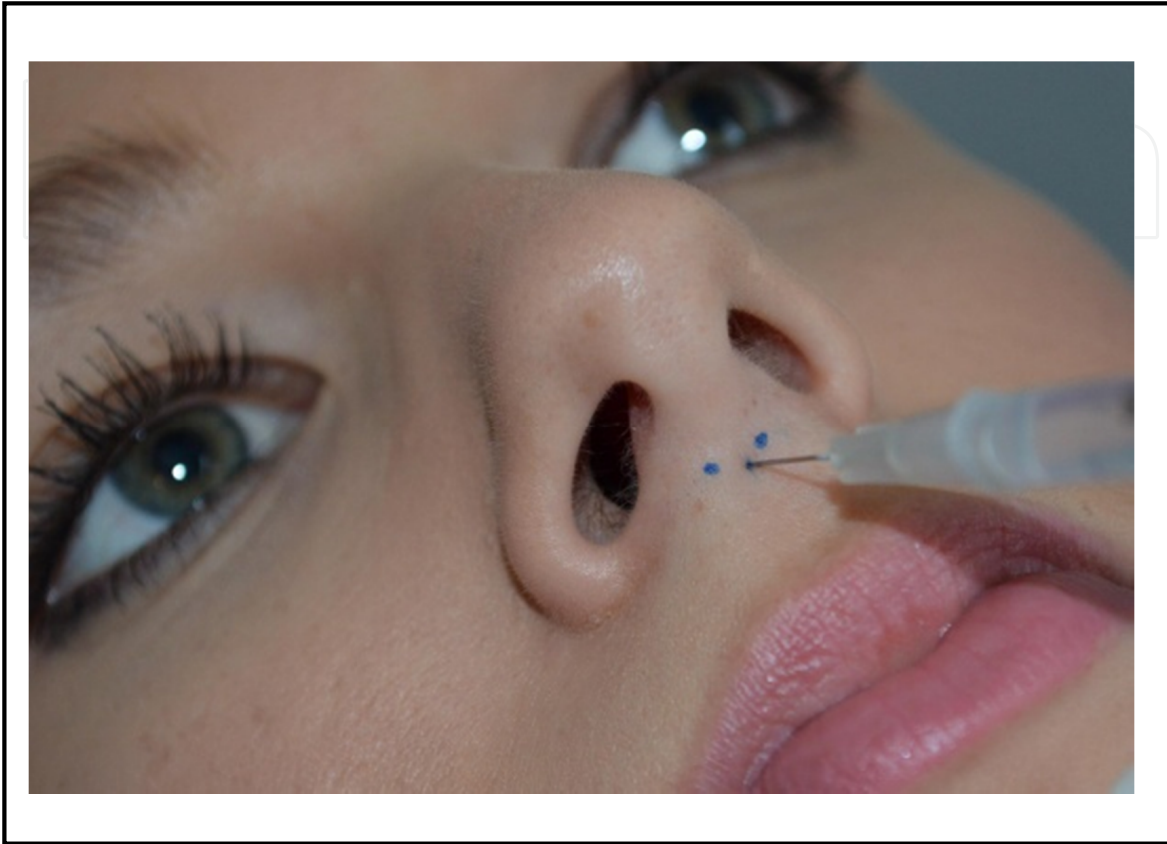

Figure 11. Nerve block of the DSNM technique.

4. Conclusion

An active depressor septi nasi muscle is responsible for descending the nasal tip, shortened upper lip, increased maxillary gingival show and transverse crease in the mid-philtral area. Those deformities can fixed with treatment minimally invasive with a permanent or temporary results

The authors of this chapter prefer the surgical treatment to get permanent results.

Acknowledgements

We would like to extend our grateful thanks to all those who helped make this chapter. Special thanks go to the following people:

To Jose Juri, M.D: Our master in Plastic and Reconstructive Surgery.

To Hector Moina, M.D for his willingness to review the chapter and his unfailing support.

To Gustavo Mouriño, M.D for his unconditional support.

To Alejandro Lucchelli, M.D for his high quality photography.

To Myrian Arenas, surgical scrub nurse, for her dedication.

Author details

Daniel G. Moina and Gabriel M. Moina*

*Address all correspondence to: dgmoina@hotmail.com

Centro de Rinología y Cirugía plástica Dr Moina, Buenos Aires, Argentina

Conflict of interest

The authors have no conflicts of interest to disclose in relation this chapter.

References

- [1] Rod J. Rohrich, Bang Hunyh, Arshad Muzaffar, William Adams and Jack Robinson. Importance of the depressor septi nasi muscle in rhinoplasty: Anatomic study and clinical application. *Plast Reconstr Surg*. 2000, January.
- [2] J. Sainz Arregui, M. Elejalde, J. Regalado, F. Ezquerro and M. Berrazueta. Dynamic rhinoplasty for the plungings nasal tip: Functional unity of the inferior third of the nose.
- [3] Cachay-Velásquez H. Rhinoplasty and facial expression. *Ann Plast Surg*. 1992;28:427–433.
- [4] Abdoljalil Kalantar-Hormozi, Arash Beiraghi-Toosi. Smile analysis in rhinoplasty: A Randomized study for comparing resection and transposition of the depressor septi Nasi muscle. *Plast. Reconstr. Surg*. 133: 261, 2014.
- [5] Rohrich RJ, Huynh B, Muzaffar AR, Adams WP Jr, Robinson JB Jr (2000) Importance of the depressor septi nasi muscle in rhinoplasty: anatomic study and clinical application. *Plast Reconstr. Surg* 105:384–388
- [6] Ebrahimi A, Nejadsarvari N, Motamedi MH, Rezaee M, Koushki ES (2012) Anatomic variations found on dissection of depressor septi nasi muscles in cadavers. *Arch Facial Plast Surg* 14:31–33.

- [7] Jamil Ahmad, Rod Rohrich. Discussion: Smile Analysis in Rhinoplasty: A Randomized Study for Comparing Resection and Transposition of the Depressor Septi Nasi Muscle. Volume 133, Number 2. Discussion.
- [8] Mauricio de Maio, Berthold Rzany: Botulinum Toxin in aesthetic medicine: Springer, 2007.

IntechOpen

IntechOpen

