

# We are IntechOpen, the world's leading publisher of Open Access books Built by scientists, for scientists

6,900

Open access books available

186,000

International authors and editors

200M

Downloads

Our authors are among the

154

Countries delivered to

TOP 1%

most cited scientists

12.2%

Contributors from top 500 universities



WEB OF SCIENCE™

Selection of our books indexed in the Book Citation Index  
in Web of Science™ Core Collection (BKCI)

Interested in publishing with us?  
Contact [book.department@intechopen.com](mailto:book.department@intechopen.com)

Numbers displayed above are based on latest data collected.  
For more information visit [www.intechopen.com](http://www.intechopen.com)



---

# **Surgical Approaches for Total Knee Arthroplasty**

---

Stefan Cristea, Vlad Predescu, Șerban Dragosloveanu, Ștefan Cuculici and Nicholas Mărandici

Additional information is available at the end of the chapter

<http://dx.doi.org/10.5772/62001>

---

## **Abstract**

Total knee arthroplasty surgery is a current practice in orthopedic surgery. The success of this intervention consists in part in the realignment of the lower extremity's anatomical axis, adequate implant orientation and design, good implant fixation, proper soft tissue balancing, and stability. A good exposure also allows optimal placement of the components. Our preferred approach is the median parapatellar approach in most cases. However, the orthopedic surgeon may face anatomical variants associated with knee types that may complicate the classic approach. We are reviewing multiple surgical approaches also used by us in our clinic in total knee arthroplasty, as well as additional techniques in these surgical approaches. The MIS approach can be used in many cases to reduce pain and speed the healing process. All of the total knee arthroplasty approaches are detailed with anatomical illustrations along with advantages and disadvantages of each. The ultimate goal is to restore knee function as quickly as possible and to preserve the anatomical integrity of the joint.

**Keywords:** Total knee arthroplasty, approaches, MIS approaches, orthopedic surgery

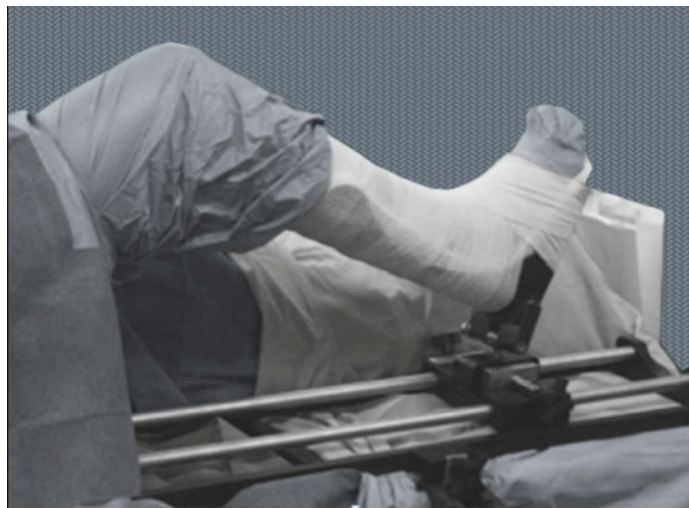---

## **1. Introduction**

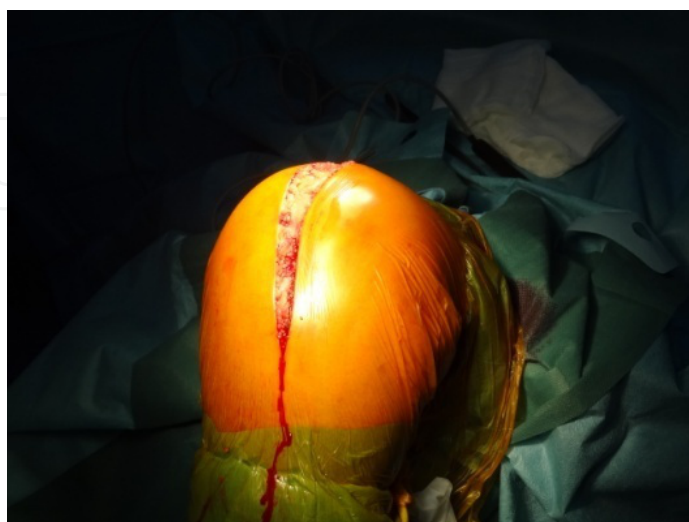
Total knee arthroplasty surgery is indicated in primary or secondary knee osteoarthritis. The success of this intervention consists in part in the realignment of the lower extremity's anatomical axis, adequate implant orientation and design, good implant fixation, proper soft tissue balancing, and stability. A good exposure also allows optimal placement of the components.

## 2. Patient preparation

The patient is placed supine on the operating table. After suitable skin preparation, drapes are applied in order to leave the leg free. A pneumatic tourniquet is applied as high as possible as to minimize compression of the thigh muscles, which would otherwise restrict knee mobility. A special table support (Figure 1) allows the knee to be flexed and extended several times during the operation; another option is to add a roll support on an ordinary table (Figure 2). Included in the preoperative preparation of the leg is the administration of a short-acting, non-depolarizing muscle relaxant that should provide sufficient muscle paralysis before and during the surgery.



**Figure 1.** Special table support for TKA.

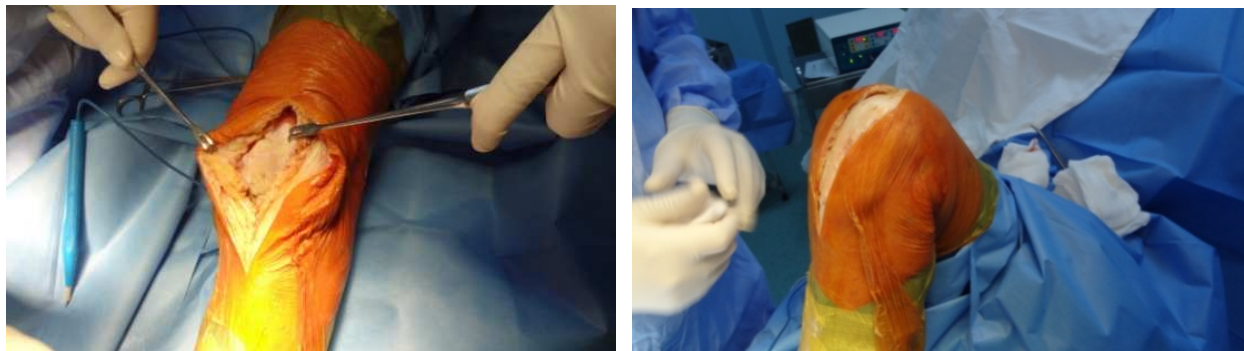


**Figure 2.** Position on the table.

The minimum duration needed for muscle relaxation is around 30–40 minutes. The anesthesiologist must adjust the medication dose depending on patient's habitus and weight to acquire this interval. This will ease patellar eversion if desired and minimize tension in the quadriceps distal to the level of the tourniquet. Muscle relaxant is required to be injected before the inflation of the tourniquet. As an alternative, epidural or spinal anesthesia will produce adequate muscle relaxation.

Apply a tourniquet proximally on the thigh and inflate it with the knee hyperflexed so as most part of the thigh muscles remains below the tourniquet's level. This will minimize restriction of the quadriceps and facilitate the eversion of the patella.

As soon as the patient is prepped on the operating table and the sterile drapes are applied, the landmarks for the surgical incision will be determined with the knee in extension (Figure 3).

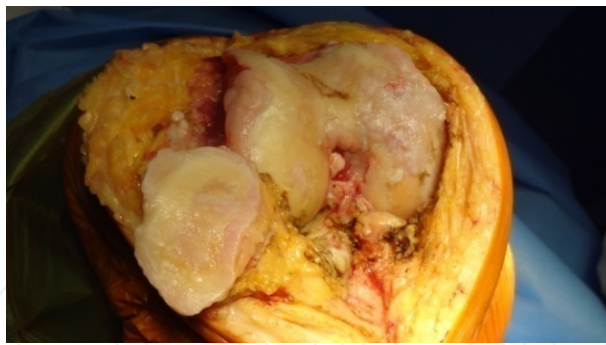


**Figure 3.** Position on the table.

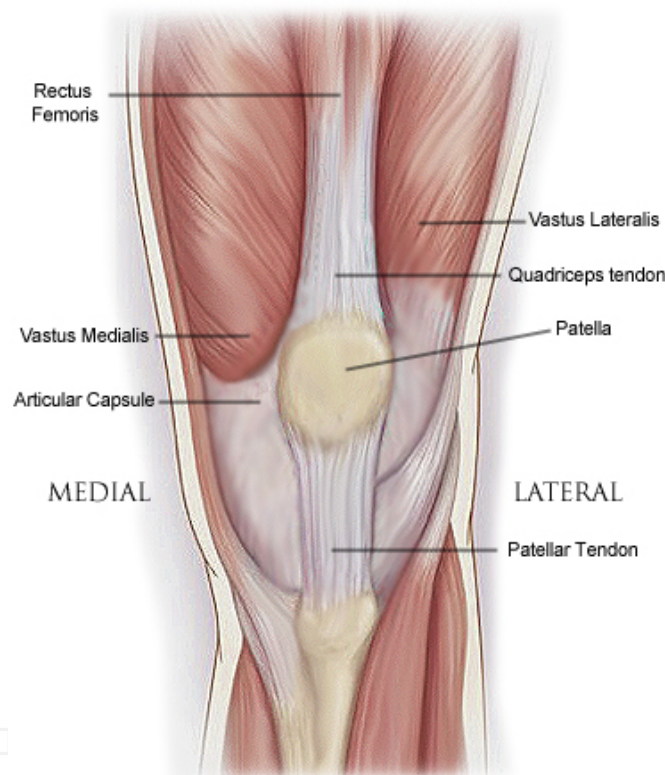
Surgical wound healing is of utmost importance in the success of knee arthroplasty. Oftentimes, a wound healing issue may appear and lead to devastating complications; therefore, this should be avoided and treated aggressively from the beginning. There are high risk patients who tend to develop this: steroid users, obese individuals, rheumatoid arthritis patients, smokers, diabetics, methotrexate users, as well as patients suffering from hypovolemia, reduced transcutaneous oxygen levels, and scars from previous surgery.

Frequently, some patients have had previous operations, undergoing osteotomies or arthroplasties, so previous incisions may be used or incorporated to decrease the risk of skin slough. If this is not possible, the new incision must have a safe corridor of at least 5 cm from the old one. Another possibility is to incise perpendicular to the old scars, or at least at a 60° angle. If there are different longitudinal skin incisions, the most lateral should be used in order to avoid a large lateral skin flap. If the skin is too damaged, a plastic surgeon's advice should be sought, considering the option of soft tissue expanders or sham incisions.

Any approach includes removal of osteophytes from the margins of the intercondylar notch and from the tibia which may aid in identification of landmarks (Figures 4 and 5).



**Figure 4.** Knee large exposure.

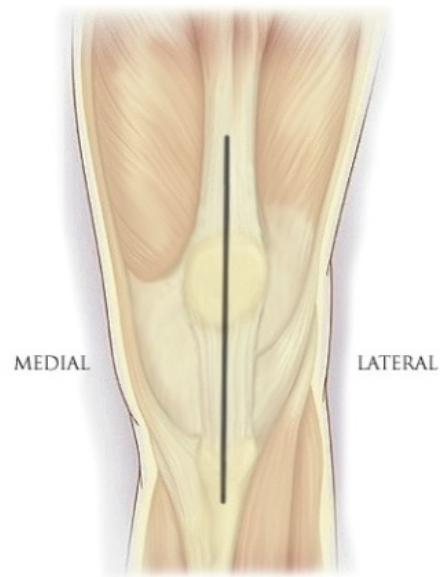


**Figure 5.** Anatomical landmarks.

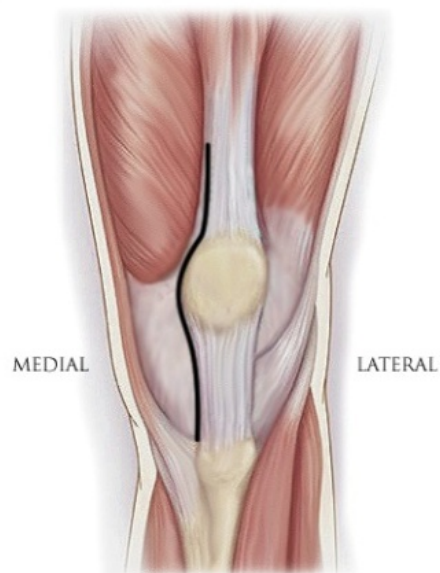
### 3. Anteromedial parapatellar approach

Use a standard anterior midline incision (Figure 6) extending from a point 5 cm proximal to the apex on the patella to the tibial tubercle. Dissect subcutaneous tissues. Enter the capsule through a medial parapatellar approach approximately 1 cm from the medial border of the patella (Figure 7). Incise the quadriceps mechanism longitudinally to allow adequate patellar

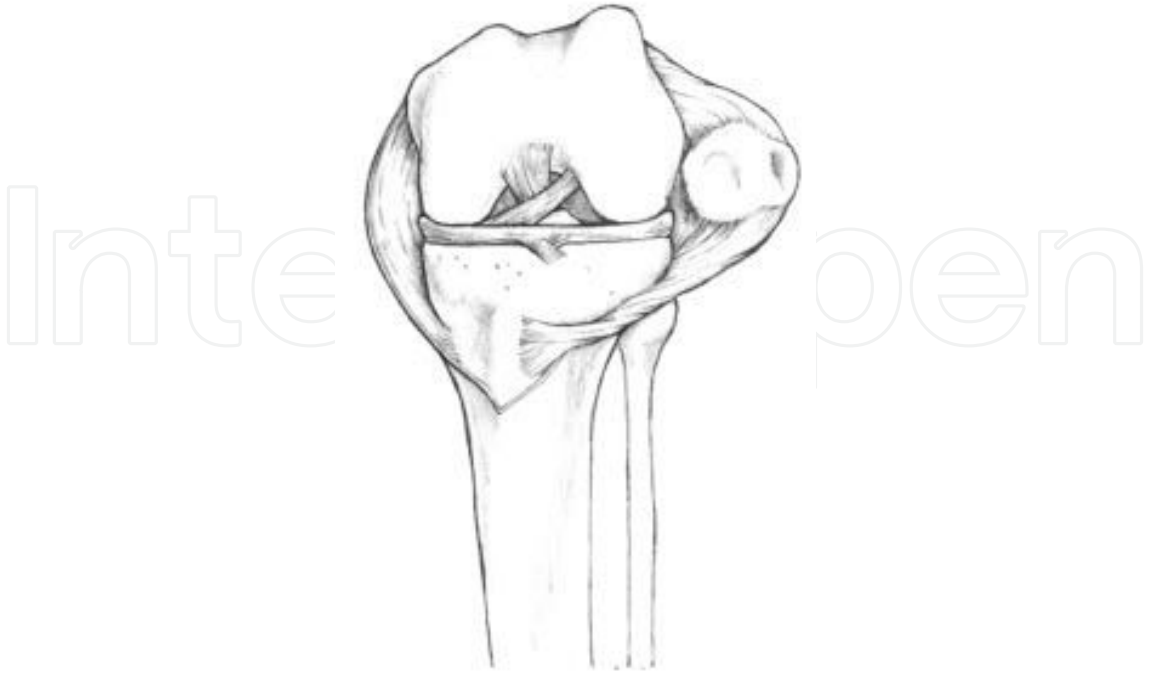
eversion [1] and sufficient knee flexion (Figure 8). Another variant is the Insall [2] anterior approach, in which the longitudinal fibers of the quadriceps tendon are carefully separated from the medial half of the patella preserving a substantial layer of tissue. Evert the patella laterally with the knee maintained in extension. Keeping the patella everted laterally, flex the knee to expose the knee joint. Wound closure with suture of the extensor mechanism facilitates the rapid recovery.



**Figure 6.** Standard anterior midline incision.



**Figure 7.** Medial parapatellar approach.



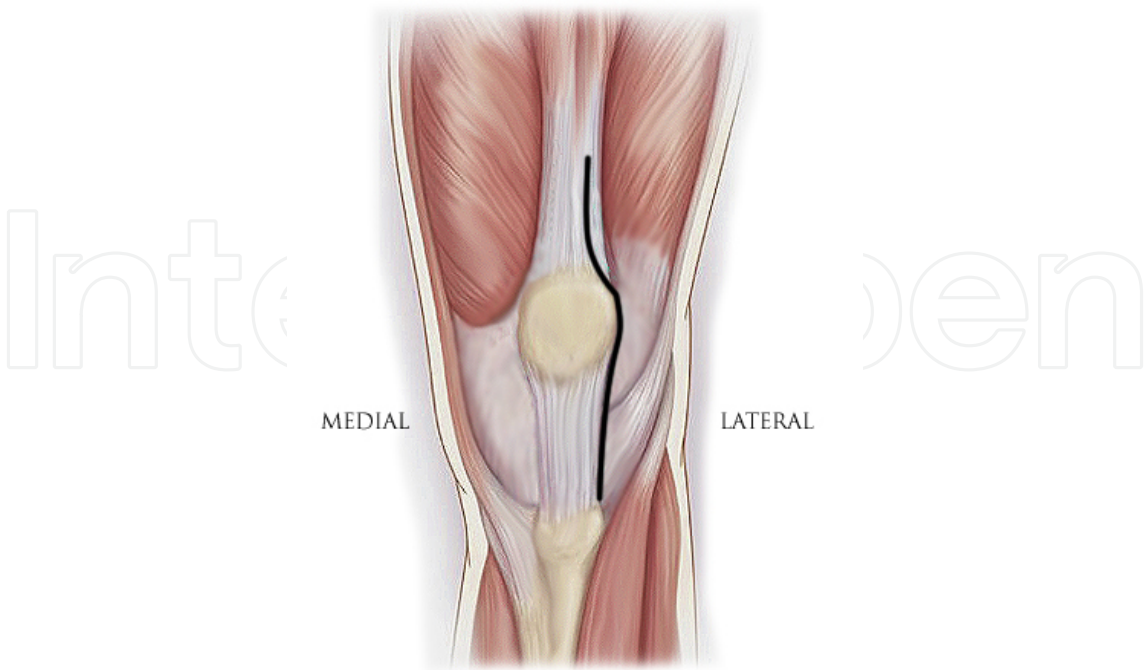
**Figure 8.** Patellar eversion and sufficient knee flexion.

Advantages	Precautions
- Very good exposure of the knee	- Risk of injuring the infrapatellar branch of saphenous nerve
- Very easy dislocation and eversion of the patella laterally	- Accidental avulsion of the patellar tendon from the tibial tubercle
	- Injuring the superior lateral geniculate artery

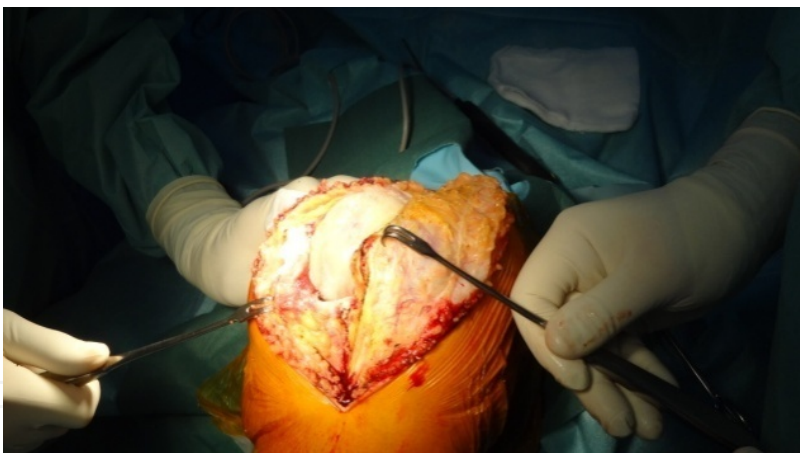**Table 1.** Anteromedial parapatellar approach

**4. Anterolateral parapatellar approach**

Use a standard anterior midline incision of the skin (Figure 6) extending from a point 5 cm proximal to the apex on the patella until the tibial tubercle. Dissect the subcutaneous tissue and deepen the incision along its length through the subcutaneous fat and then the prepattellar bursa. Following the lateral side of the patella, perform a lateral parapatellar arthrotomy (Figure 9) extending from just superior to the patella, along the lateral side of the quadriceps tendon to the tibial tuberosity distally. Evert the patella medially with the knee still in extension. Keeping the patella everted medially, flex the knee to expose the knee joint (Figures 4 and 10).



**Figure 9.** Lateral parapatellar approach.



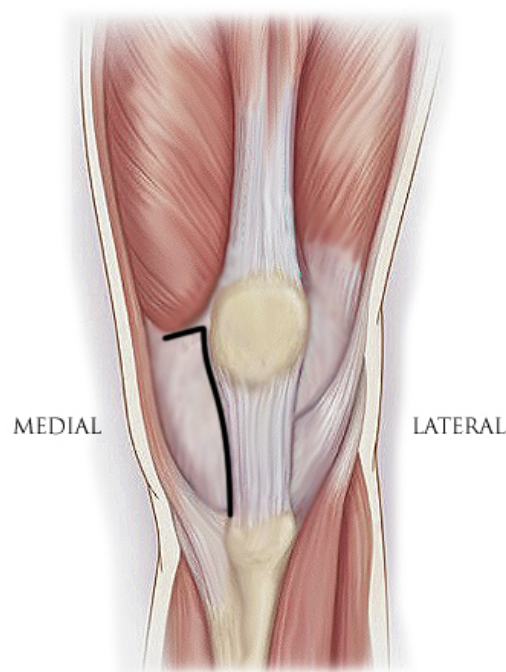
**Figure 10.** Evert the patella medially.

Advantages	Disadvantages
- Technically useful in valgus deformity cases	- Very rare
- Preserves the patellar blood supply	- Difficulty in everting the patella medially
- Prevents lateral patellar subluxation	- May require tibial tubercle osteotomy

**Table 2.** Lateral parapatellar approach

## 5. Subvastus approach [3]

Use a midline incision. Dissect the subcutaneous tissue but avoid incising the fascia covering the vastus medialis obliquus muscle. Identify the inferior border of the vastus medialis muscle and incise its overlying fascia medial to the patellar border. This should allow introducing the surgeon's finger or a retractor under the muscle's inferior border and pull the vastus medialis superiorly, separating it from the underlying synovial knee joint lining.



**Figure 11.** Subvastus approach

With the help of an electrocautery, the capsular incision is made under the vastus muscle's inferior border, starting posterolaterally, continuing laterally parallel to the border, and when the medial border of the patella is reached, the incision takes an L-shape, turning directly inferiorly at a 90° angle, parallel to the medial border of the patella (Figure 11). A small miofascial tissue cuff should be left attached to the medial border of the patella for closure. Tearing, splitting, or further damages to the muscle can be caused by incising along the inferior border of the vastus to the patellar superior pole and then inserting the retractors.

The arthrotomy consists in incising the underlying synovium incision that is performed across the joint line, in line with the patellar's tendon medial border.

Insert a bent Hohmann or a Z-retractor in the lateral flare in order to keep the patella and the extensor mechanism retracted with the quadriceps tendon and vastus medialis lying over the distal femur. The patella is either everted or subluxed. For additional exposure, the retropatellar bursa and fat pad can be excised or spared, depending on the surgeon's preference.

The knee is now flexed and extended in various degrees so as to vary the tension on the extensor mechanism and improve visualization.

Advantages	Disadvantages
- Claims of less intraoperative blood loss and more rapid rehabilitation	- Patella can be difficult to evert but it can be instead subluxated laterally
- Elevates the vastus medialis muscle instead of cutting into it	- Difficult to apply in muscular patients
- Preserving the quadriceps tendon intact	
- Preserving blood supply to the patella	

Table 3. Subvastus approach

6. Midvastus approach [4]

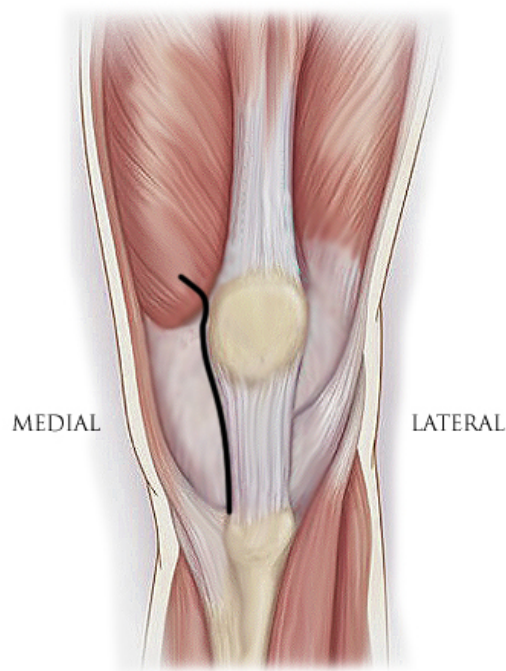
Similar to the subvastus approach, the dissection is carried out through the muscle of vastus medialis to facilitate exposure.

Use a longitudinal midline skin incision. Next, using electrocautery, the capsule should be incised parallel to the medial border of the patella and extended proximally and distally. The surgeon must leave a band of about 1 cm of capsule and peritenon that will later facilitate capsular closure.

The superficial fascia covering the quadriceps should be incised approximately 5 cm starting distally and extending proximally, so as to decrease the extensor mechanism’s tension and permit mobilization of the quadriceps. In this manner, the quadriceps will be able to be translated laterally easier, facilitating the exposure of the knee joint.

The following step consists in dissecting through the muscular fibers of the vastus medialis itself, running oblique over a length of approximately 4–6 cm from proximal and lateral down to the medial border of the patella. From here, the dissection is continued proximally along the medial patellar border and ends around the tibial tuberosity (Figure 12). The knee is slightly flexed and the surgeon should decide whether to excise or preserve the retropatellar bursa and fat pad. The patella can be everted or subluxed. If the surgeon’s choice is to evert the patella, then a release of the patella-femoral ligament should be made. Using a hook with two prongs, the patella is everted and dislocated laterally, or subluxed, exposing the articular surfaces.

Once the patella is everted, a bent Hohmann or a Z-retractor is introduced along the lateral gutter of the tibial metaphysis to maintain the dislocation of the patella and the extensor mechanism. For further flexing and exposing of the knee joint, the subperiosteal tissue should be dissected along the tibial insertion of the patellar tendon.



**Figure 12.** Midvastus approach.

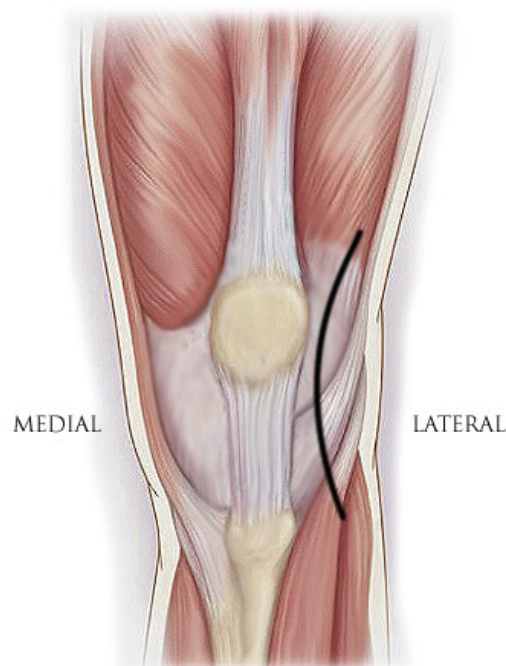
Advantages	Disadvantages
- Better exposure than the subvastus	- Cutting and disrupting the vastus medialis muscular substance
- Allows rapid restoration of extensor mechanism	
- Advantage over the standard incision is that the vastus medialis insertion into the medial border of the quadriceps tendon is preserved	- Patella can be difficult to evert and can be instead subluxated laterally

**Table 4.** Midvastus approach

**7. Lateral approach (Keblish)**

Begin the incision laterally around the knee, following the femur line and curve the incision around the knee, keeping it parallel to the patella and then in line with the tibia (Figure 13). Deepen the incision down to the fascia. Divide the deep fascia between the biceps femoris and the iliotibial band, revealing the lateral collateral ligament. Perform an anterior arthrotomy parallel to the lateral side of the patella.

This approach was first described [5] in order to perform a release of lateral contracture structures in valgus knee. If a patellar maltracking is anticipated and further lateral release may be necessary, then this approach can be a start option in surgery. The approach needs experience and is more demanding. Anatomy is reversed, and the surgeon is not commonly used to work with the patella subluxed medially. The advantage is the direct approach to the concave side of the deformity, preserving patellar vascularization. Medial dissection is avoided, and the medial soft tissue, which is lax, is no longer jeopardized during surgery. Patellar eversion is difficult in the original version of this approach. Tibial tubercle osteotomy may be necessary to overcome the patellar stiffness. After the lateral parapatellar approach itself, there are several tricks very important to avoid avulsion of the tibial tubercle. One is performing a lateral vastus snip about 2–3 cm long, and another is performing a minimal release of the patellar tendon from the tibial tuberosity. If it is not possible to slide the patella, then proceed with patellar osteotomy for patellar replacement. This can be done from the beginning, and then the bony surface can be protected with a metallic cap in order to avoid bony damage. At closure, the surgeon may confront with a problem, the remaining space between capsular incision sides. In order to avoid this, it is important to keep the Hoffa fat pad and damage it as little as possible. The Hoffa fat pad must be kept attached laterally, keeping the vascular pedicle and sutured between borders of capsular incision (Hoffa plasty). Generally, this approach is recommended in knees with more than 15° of valgus, with contracture of the lateral structures [6]. We could not find it especially useful even in valgus deformities with 30°.



**Figure 13.** Lateral approach.

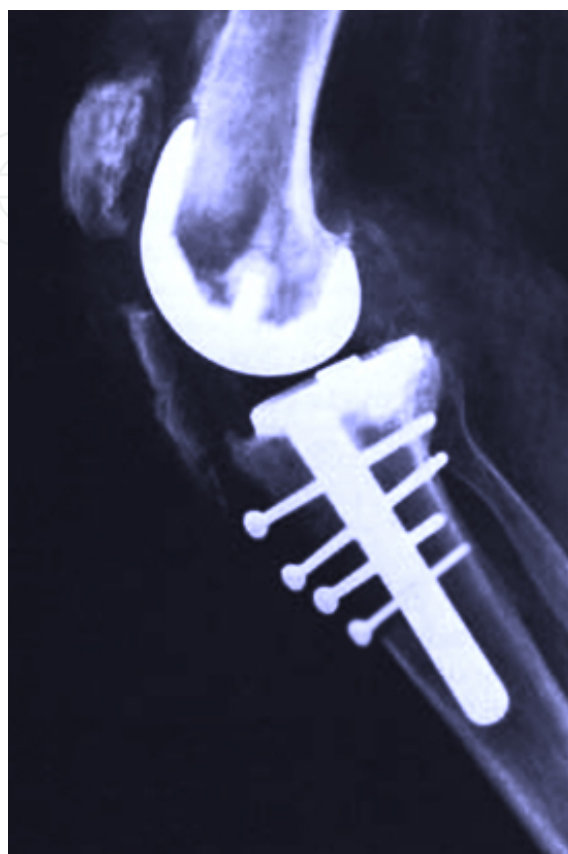Advantages	Disadvantages
- Technically useful in valgus deformity cases	- Being rare becomes uncomfortable. Technically is more demanding and needs an experienced surgeon
- Preserves the patellar blood supply	- Difficulty in everting the patella medially
- Prevents lateral patellar subluxation	- May require tibial tubercle osteotomy

Table 5. Lateral approach

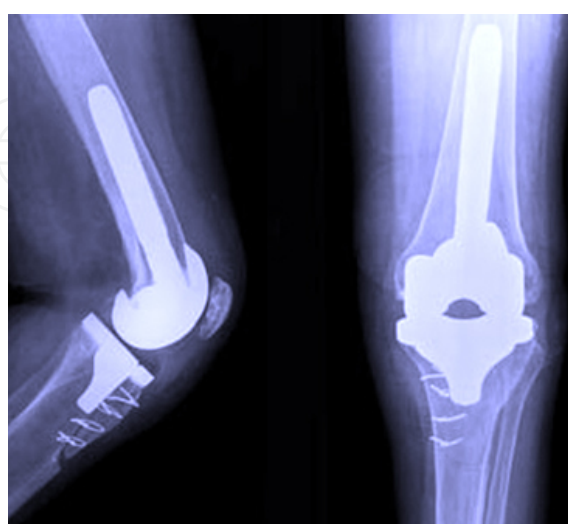
## 8. Tibial tubercle osteotomy technique (TTO)

This technique was introduced in 1983 [7]. The main indication is a stiff knee with shortening of the extensor mechanism and patella baja, but it must be left as one last alternative or avoided. Especially in revisions, it must be taken into consideration. This technique prevents the rupture of the patellar tendon but also allows lengthening of up to 2.5 cm of the extensor mechanism, enough to obtain good flexion in a stiff knee and avoid patella baja. Whiteside modified this technique and popularized it [8]. It is utilized with almost the same frequency as quad snip technique, especially in cases of high fibrosis stiff knees, knee arthroplasty revisions where median parapatellar approach rarely offers sufficient exposure. The tibial tubercle osteotomy should be as long as possible, 6–8 cm long and 1.5 times the width of tibial tubercle. Drilling holes can be useful to prepare the osteotomy, which is made with an osteotome or an oscillating saw. The proximal transverse cut is made oblique and upward in the methaphyseal area to create a ledge in order to prevent proximal migration. The distal transverse osteotomy is made at a 45° angle from the longitudinal cut. It is important to preserve lateral soft tissue attachments in order to prevent proximal displacement; a large tibial tubercle osteotomy will consolidate at least in few points to avoid nonunion (Figure 14). The tibial tubercle that has been osteotomized on the lateral side is everted to enlarge the exposure. At the end of the procedure, rigid fixation and good pattelar alignment are required to allow knee flexion in early postoperative interval and reduce further complications. Generally, two methods of fixation of the osteotomy fragment have been described: cerclage wire fixation and screw fixation. The fixation with cerclages is obtained with 3 or 4 loops of wire passed through drill holes in the tubercle and medial tibial cortex (Figure 15). The inclusion of the tibial prosthetic component into cerclage will increase the stability but it can create a bimetal reaction. The advantage of this type of fixation is that the wires are easier to place and provide a good fixation, but to avoid migration, a step cut on the proximal side of the segment needs to be made. On the other side, the proximal methaphiseal inclusion into cerclage could damage the popliteal artery. The complications might be as follows: anterior pain in the knee, migration of the tubercle, or soft tissue aggression caused by the tips of the wires. The fixation, with 2–4 bicortical screws, can provide a more reliable fixation (Figure 16), although it is more difficult to place the screws around a tibial revision stem for example. The subcutaneous prominence of the screw head can lead to knee pain, requiring screws removal. Other complication can be the tibial shaft fractures or the fracture of the tibial osteotomy fragment (Figure 14). Bleeding

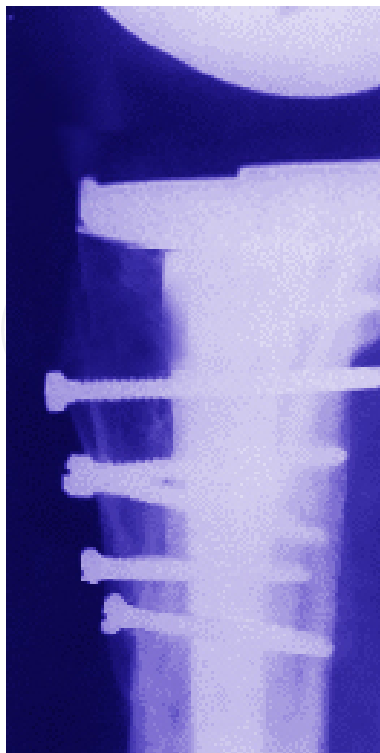
and skin healing problems may lead to infection in both cases. Passive range of motion of the knee must be intraoperatively tested till 90° and the fixation of must be rigid.



**Figure 14.** Migrated tibial tubercle



**Figure 15.** Tibial tubercle fixation with cerclages



**Figure 16.** Tibial tubercle fixation with screws

## 9. Rectus snip technique

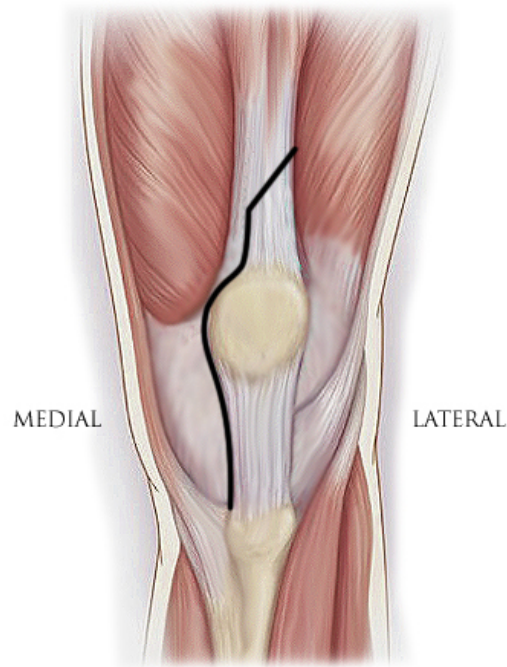
This is the main technique used in revision knee arthroplasty or in stiff knees. If the exposure is used in stiff knee, it is important that the stiffness is derived from proximal causes; otherwise, tibial tubercle osteotomy is a better solution.

The technique is easy and straightforward to perform, and good joint exposure is obtained in most of the revision cases or ankylosed knee, but it must be avoided.

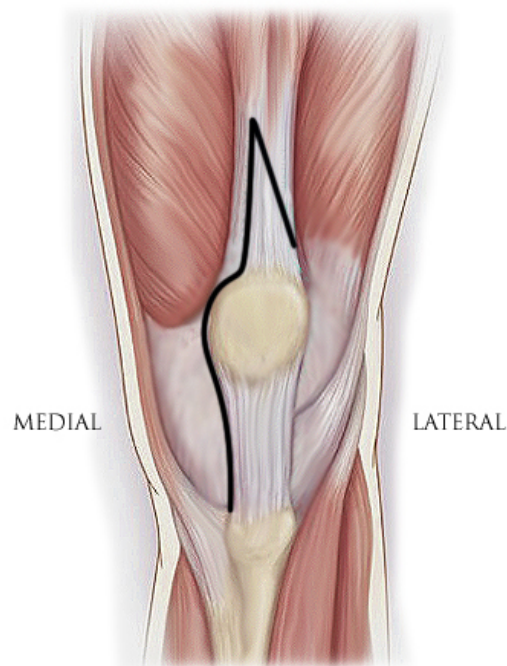
The technique consists in cutting the rectus tendon at or near the musculotendinous junction in a 45° direction proximally and laterally, parallel with vastus lateralis' muscular fibers (Figure 17). As a general rule, the tendon must be divided completely and at the end of the procedure, all the muscular fibers should be reattached.

It is very important to remove all fibrotic tissue from the lateral gutter. Afterward, the knee must be flexed easily, and the patella must slide laterally. If this is not possible, a subperiosteal minimal lateral release can be performed around the medial patellar side. After this, if the patella cannot be everted, then the exposure must be extensive and the approach should continue with a rectus snip. John Insall<sup>7</sup> was the first to perform this technique in order to protect the extensor mechanism. The recovery period is a little bit longer, but no modification of postoperative rehabilitation protocol is necessary. Scott modified this technique [9] by dividing the quadriceps tendon not only obliquely but also downward and distally. This

technique is known as V-Y quadricepsplasty (Figure 18). The main advantage of this exposure is that if the knee is very stiff and the joint cannot be exposed, this exposure can be converted in a full quadriceps turndown.



**Figure 17.** Rectus snip



**Figure 18.** V-Y plasty.

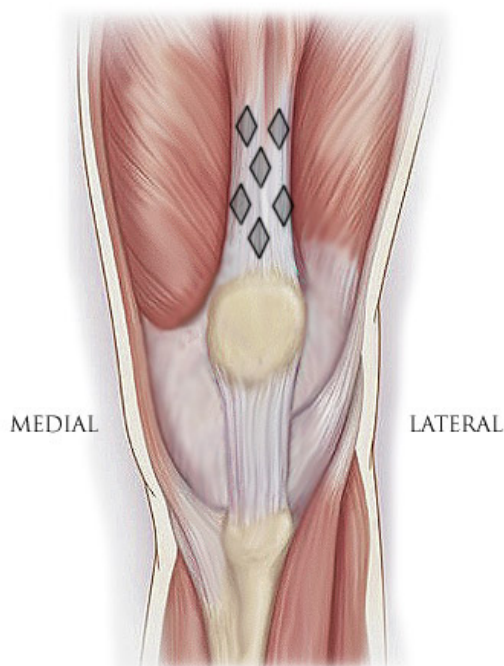
## 10. Quadriceps turndown

This technique is rarely used. The main indication is severe ankylosed knee, where scarring is so impressive that bending of the knee is impossible. The decision of turndown should be taken after removing all the fibrotic tissue and osteophytes. If scarring of the extensor mechanism is major, then a turndown with lengthening is an option. Actually, there are 2 options for accessing the joint for such knees: one is quadriceps turndown and the other is tibial tubercle osteotomy. The decision is made according to the localization of the soft tissue contracture. If it is distal to the patellar pole, then a tibial osteotomy has to be done. If the contracture is more proximal and in the lateral gutter, then a quadriceps turndown is the solution. This was described by Coonse and Adams and modified by Insall in the patellar turndown approach.

The technique consists in a medial parapatellar approach, and then from the proximal pole of the incision, in a 45° angle, a second incision is made distally and laterally through vastus lateralis and the iliotibial tract. The base of the capsular incision must be broad and the vascularization of the patella through inferolateral genicular artery must be preserved. At the end of the procedure, the extensor mechanism can be lengthened by suturing in V-Y fashion (Figure 18).

Another possibility is the Japanese lamplike quadricepsplasty (Figure 19).

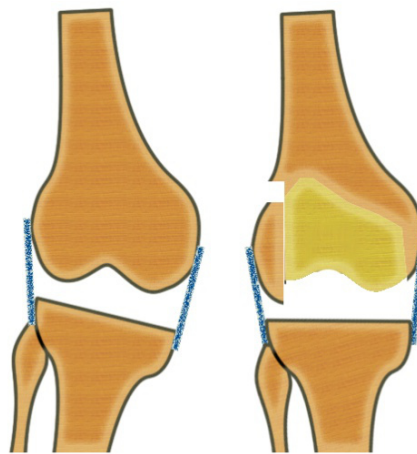
It is recommended to keep the knee in 30° of flexion when performing the lengthening. The recovery period is much longer; the knee must be kept in a brace with limiting knee flexion for the first 4–6 weeks. Sometimes an extension lag is present.



**Figure 19.** Japanese lamplike quadricepsplasty

## 11. Medial or lateral epicondylar osteotomy technique [10]

Medial epicondylar osteotomy is similar to the tibial tubercle osteotomy. Instead of releasing the medial soft tissue from the tibia, all the medial soft tissue is released from the femur, together with bony fragments. The technique is rarely used, for example, in cases where there is an important medial soft tissue contracture in flexion and extension. The procedure detaches the epicondyle with a bone fragment approximated 1 cm thick. After the final implant is cemented, the fragment is reattached with screws or sutures in order to have good medial stability. The secret is to keep the soft tissue's integrity between the medial collateral ligament, capsule, and adductor tendons. Sometimes the soft tissue is strong enough to stabilize the bone fragment even if this is not fixated to the femur (Figure 20). This kind of technique is also possible on the lateral side in difficult valgus knees where the lateral femoral epicondyle can be osteotomized and reattached in a new position. These techniques are demanding and can generally be avoided by using more conservative approaches. In our practice, they did not prove their utility.



**Figure 20.** Lateral epicondylar osteotomy technique

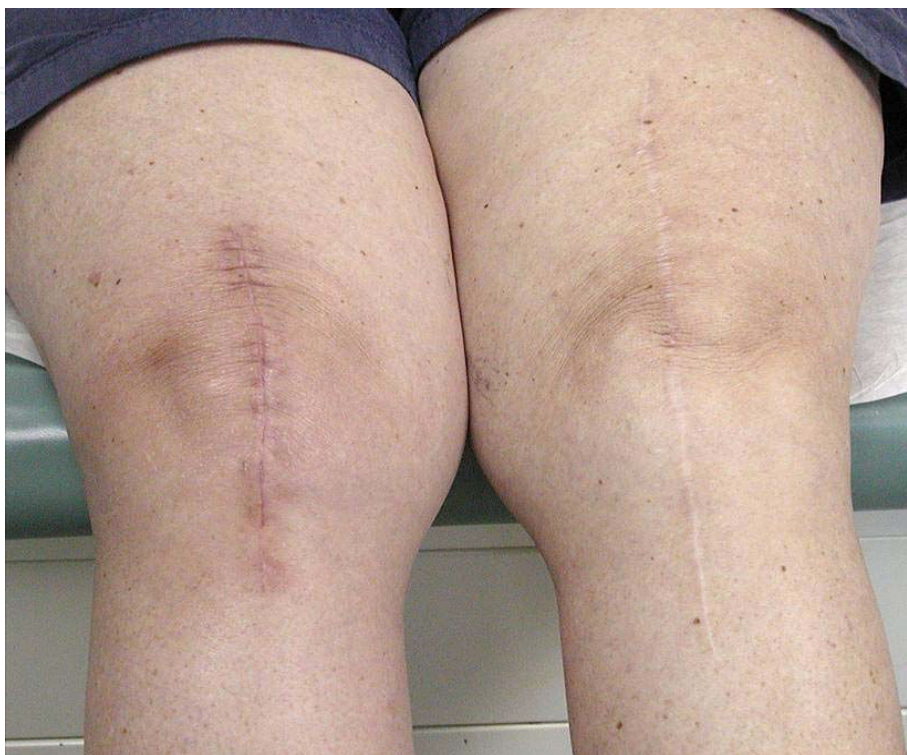Recovery after the knee arthroplasty is very important for a good surgical outcome, generally taking 4 weeks. To reduce the recovery period and the additional cost, many surgeons have developed new surgical techniques: minimal invasive approaches (MIS), new minimized specific instruments, navigation, and personalized surgical instruments (PSI).

After a long trial period of all these new trends, the classic approach remains the gold standard.

## 12. Minimal invasive surgery approaches (MIS approaches)

The needs to reduce surgery complications, hospital stay, and the need to accelerate functional postoperative recovery have lead surgeons to use smaller incisions that disrupt less tissue.

Additionally, blood loss is significantly lower than that in the classic incision cases; some patients may experience less postoperative pain, some may be able to resume their daily activities sooner, and some prefer the aesthetic aspect of the shorter scar (Figure 21).



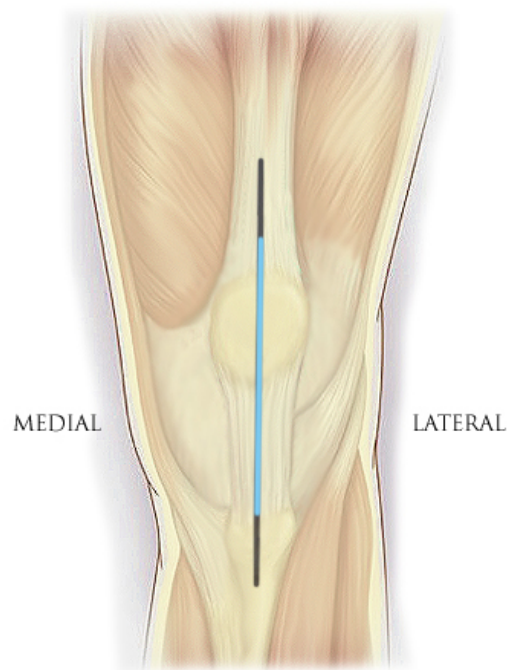
**Figure 21.** MIS incision versus classical in TKA.

The need for faster recovery time in total knee arthroplasty with less tissue disruption helped develop the mini-incision TKA technique in which the same surgical concepts are utilized, the same alignment goals are followed, but the original instruments have been minimized. A surgeon performing this technique should first have a good background in using the standard TKA procedure and should be familiar with the classical prosthesis components.

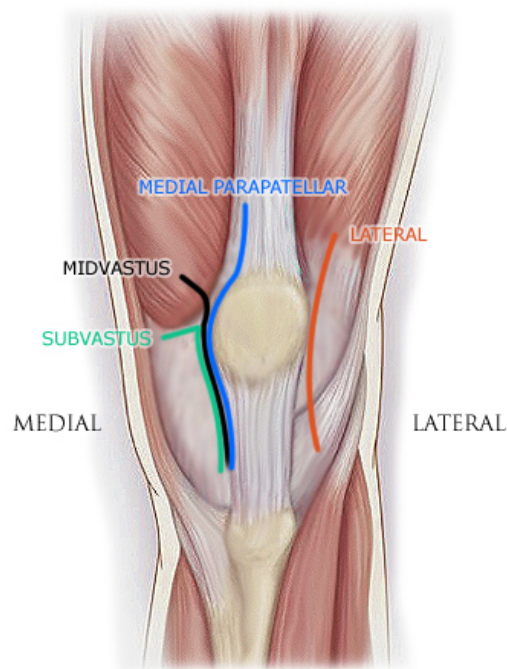
The mini-incision TKA is not indicated for all patients. Candidates for mini-incision arthroplasty must have preoperative flexion greater than 90° and must not be obese.

Extreme varus or valgus cases are contraindicated and also patients suffering from rheumatoid arthritis, for structural tissue reasons.

The incision may be made with the leg in extension or flexion depending on surgeon preference. First, the skin incision is made, being substantially smaller than the classical one (Figures 21 and 22). Then the surgeon can choose a mid-vastus approach, a subvastus approach, a mini-medial parapatellar arthrotomy (no quad), or a lateral approach (permits eversion of the patella) (Figure 23). Also, depending on the surgeon's preference, the patella can be either everted (if there is no tension on the patellar tendon) or subluxed (preferable in most cases).



**Figure 22.** MIS skin incision vs classical.



**Figure 23.** Different MIS incisions.

The length of the incision is dependent on the size of the femoral component needed. Although the goal of a mini-incision technique is to complete the surgery with an approximately 10 to

14 cm incision, extension of the incision is recommended if anatomical landmarks are not fully identified or patellar eversion is challenging, risking tibial tubercle avulsion. Maintaining extensor mechanism insertion is key in the mini-incision technique.

The first step in this procedure is the skin incision that is started at almost 2 cm proximal to the patellar superior pole and continued on the medial border of the patella. The subcutaneous tissue is carefully divided down to the retinaculum, facilitating access to the vastus medialis obliquus muscle. Following this step, the surgeon can choose his preferred type of arthrotomy. The incision's length should normally be about 50% above and 50% below the knee joint line. If it cannot be equally distributed, it is preferable that the longer portion be below the joint line. Electrocautery should be used during all steps of this exposure, minimizing bleeding after deflation of the tourniquet. Below are more detailed descriptions of each of the arthrotomies used in MIS TKA.

### **13. MIS approaches – Mini-medial parapatellar arthrotomy [11, 12]**

Minimally invasive total knee arthroplasty can be performed with a limited medial parapatellar arthrotomy. Begin by making a 10 to 14 cm midline skin incision from the superior aspect of the tibial tubercle to the superior border of the patella (Figure 22). Following subcutaneous dissection, develop medial and lateral flaps and dissect proximally and distally to expose the extensor mechanism. This permits mobilization of the skin and subcutaneous tissue as needed during the procedure. In addition, with the knee in flexion, the incision will stretch 2–4 cm due to the elasticity of the skin, allowing broader exposure.

The goal of minimally invasive surgery is to limit the surgical dissection without compromising the procedure. The medial parapatellar arthrotomy is used to expose the joint, but the proximal division of the quadriceps tendon should be limited to a length that permits only lateral subluxation. Candidates for mini-incision arthroplasty must have preoperative flexion greater than 90° and must not be obese.

The skin is first incised longitudinally around 10 cm starting from the superior patellar pole to the tibial tubercle. Medial and lateral flaps are now created, and with the flexion of the knee, even more exposure is obtained exposing the extensor mechanism. The dissection of the quadriceps tendon is carefully executed just to permit lateral subluxation of the patella without eversion. Incise the quadriceps tendon for a length of 2–4 cm initially. If it is difficult to displace, the patella laterally or if the patellar tendon is at risk of tearing, extend the arthrotomy proximally along the quadriceps tendon until adequate exposure is achieved.

### **14. MIS approaches – Midvastus arthrotomy**

The MIS-midvastus approach involves dividing 1–3 cm of the vastus medialis obliquus's (VMO) muscle fibers in full thickness starting from the superomedial patellar corner proxi-

mally (Figure 23). With the knee in flexion, the patella is subluxed laterally or everted. The incision may be extended if the surgeon needs more exposure of the joint.

## **15. MIS approaches – Subvastus arthrotomy**

The MIS-subvastus approach necessitates specially modified instruments. It consists in entering the knee joint through the inferior border of the vastus medialis, making sure not to disturb the quadriceps mechanism (Figure 23). The patella is difficult to evert and is instead subluxed laterally. This approach limits the visibility of the lateral tibial condyle, so it requires a trained and experienced surgeon familiar with its requirements.

## **16. MIS approaches – Lateral arthrotomy**

The MIS lateral approach has been recently described and used, having the advantages not to dislocate the knee joint, not to disturb the quadriceps mechanism, permitting the eversion of the patella but frequently requiring computer-assisted navigation. The approach consists in incising approximately 7–9 cm of the iliotibial band slightly below Gerdy's tubercle to the lateral epicondyle directly lateral to the patella (Figure 23). The distal femur is now exposed from the lateral side. A disadvantage of this lateral arthrotomy may be limited access to the tibia and to the posteromedial soft tissue attachments.

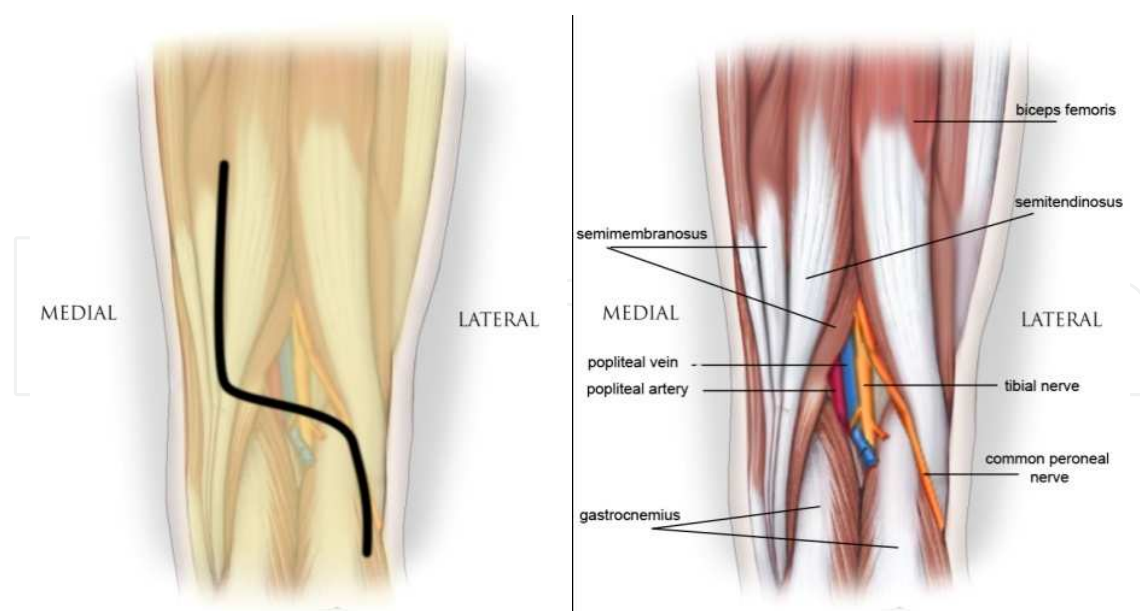
To reduce the recovery period and the additional cost, many surgeons have developed new surgical techniques: minimally invasive approaches, new minimized instruments, navigation, and personalized surgical instruments (PSI).

After a long period of testing of all these new trends, the classic anteromedial parapatellar approach is still the gold standard.

## **17. Posterior approach**

This approach can be useful only in neurovascular complications, but also for repairing the posterior cruciate ligament avulsion fractures or excision of a cyst in the popliteal area.

Make a curvilinear incision 10 to 15 cm long over the popliteal space with the proximal limb following the tendon of the semitendinosus muscle distally to the level of the joint (Figure 24). Curve it laterally across the posterior aspect of the joint for about 5 cm and distally over the lateral head of the gastrocnemius muscle. Identify the posterior cutaneous nerve of the calf (the medial sural cutaneous nerve) lying beneath the fascia and between the two heads of the gastrocnemius muscle being the indicator in the dissection [13]. Expose the popliteal artery and vein, which lie directly anterior and medial to the tibial nerve.



**Figure 24.** Posterior approach.

## Author details

Stefan Cristea\*, Vlad Predescu, Șerban Dragosloveanu, Ștefan Cuculici and Nicholas Mărăndici

\*Address all correspondence to: drstefancristea@yahoo.com

Emergency Hospital of Saint Pantelimon, Carol Davila University of Medicine and Pharmacy, Bucharest, Romania

## References

- [1] Fehring TK, Odum S, Griffin WL Patella inversion method for exposure in total knee arthroplasty. *J Arthroplasty*. 2002;17(1): 101–104
- [2] Insall JN. *Surgical Approaches in the Knee*. New York: Churcill-Livingstone 1984:41–54
- [3] Jackson JD, Pagnano MW. The mini-subvastus approach for total knee arthroplasty. *The Knee Joint*. 2012, pp 775–781
- [4] Vaughan LM. TKR through a mini incision. 17th Annual Vail Orthopaedic Symposium. State-of-the-art total hip and knee replacement controversies and solutions. January 19–24, 2003.

- [5] Keblish PA. The lateral approach to the valgus knee. Surgical technique and analysis of 53 cases with over two-year follow-up evaluation. *Clin Orthop Relat Res.* 1991 Oct; (271):52–62.
- [6] Barrack RE, Smith P, Munn B. Comparison of surgical approaches in total knee arthroplasty. *Clin Orthop* 1988; 356:16–21
- [7] Dalin MG. Osteotomy the tibial tubercle in total knee replacement *J Bone Joint Surg* 1983;65-A:704–706
- [8] Whiteside LA. Exposure in difficult total knee arthroplasty using tibial tubercle osteotomy. *Clin Orthop* 1995;321: 32–35
- [9] Scott RD, Siliski JM. The use of a modified V-Y quadricepsplasty during total knee replacement to gain exposure and improve knee flexion in the ankylosed knee. *Orthopedics* 1985;8: 45–48
- [10] Engh GA. Medial epicondylar osteotomy: a technique used with primary and revision arthroplasty to improve surgical exposure and correct varus deformity. *Instr Course Lect* 1999;48:153–156
- [11] Scuderi GR, Tria, AJ, Jr., Berger RA (eds.). *MIS Techniques in Orthopedics.* Springer Science, 2006.
- [12] Garvin KL, Scuderi G, Insall JN. Evolution of the quadriceps snip. *Clin Orthop* 1995;321:131–137.
- [13] LaPrade et al. The anatomy of the posterior aspect of the knee, an anatomic study. *JBJS* 2007. 89 758–764.

IntechOpen

