

We are IntechOpen, the world's leading publisher of Open Access books Built by scientists, for scientists

6,900

Open access books available

186,000

International authors and editors

200M

Downloads

Our authors are among the

154

Countries delivered to

TOP 1%

most cited scientists

12.2%

Contributors from top 500 universities



WEB OF SCIENCE™

Selection of our books indexed in the Book Citation Index
in Web of Science™ Core Collection (BKCI)

Interested in publishing with us?
Contact book.department@intechopen.com

Numbers displayed above are based on latest data collected.
For more information visit www.intechopen.com



Eye Removal — Current Indications and Technical Tips

César Hita-Antón, Lourdes Jordano-Luna and Rosario Díez-Villalba

Additional information is available at the end of the chapter

<http://dx.doi.org/10.5772/61030>

Abstract

The removal of the eyeball with or without other orbital tissues is always a complicated decision to take and nearly always involves the beginning of a new and intense doctor-patient relationship. The loss of the globe results in the loss of binocular vision and depth perception, thus the patient is limited when applying for certain jobs or handling delicate or dangerous materials. They may also be prohibited to drive in some countries or may have to do so with special care where permitted. The psychological impact on the patients' life may be even greater as it may be perceived as a severe facial disfiguration. Some patients may prefer to stay at home and their social life may be deeply affected. Since facial and eye appearance is essential for normal human relations and interaction, prosthetic eyes or orbits should imitate the eye, in most cases, or the whole orbit-eyelids-eye complex, which is less frequent.

Keywords: enucleation, evisceration, exenteration, orbital implant

1. Introduction

The need to remove an eye or other orbital contents is always difficult to digest for a patient. Many of them will experience the five stages of grief described by the Swiss psychiatrist Elisabeth Kübler-Ross in her 1969 book [1] *On Death and Dying*, inspired by her work with terminally ill patients. Older patients may think that these kinds of surgeries, especially exenteration, are not worth it. Younger patients are usually very worried about the cosmetic result rather than the difficulty of the surgery and the postoperative period. The ophthalmologist will need a good dose of empathy and psychology skills to explain to the patient that the planned surgery is the only and best option. The oculoplastic surgeon must be ready to hear that some patients will wish to ask for a second opinion. This may annoy the doctor in charge of the patient, but despite of this, it is advisable to help the patient look for a second opinion with other colleagues. When dealing with these kinds of patients, it is crucial to take your time

to explain with detail the surgical technique, the time the patient is expected to stay in the hospital, the need for frequent bandage changes in the hospital clinic, the possible complications of the socket, and a long recovery period before a prosthesis can be fitted in.

Evisceration, enucleation, and exenteration are the three main surgical options. Evisceration is the removal of the contents of the globe while leaving the sclera and extraocular muscles intact. Enucleation is the removal of the eye from the orbit while preserving all the other orbital structures, and exenteration is the removal of the globe as well as the soft tissues of the orbit (connective tissue, fat, and muscles).

There is evidence that Egyptians and Sumerians used artificial eyes to decorate their mummies and their statues, respectively; however, there is no evidence to suggest that they used them for medical purposes in living people. Clay models resembling eyes were used in the Roman Empire around 500 BC to cover phthisical eyes. It was not until the 16th century that enucleation surgeries were reported in the medical literature. In 1583, George Bartisch first described the extirpation of an eye. In 1817, Bear introduced evisceration in an eye with an expulsive hemorrhage when performing an iridectomy for an acute glaucoma [2].

It was in 1874 when Noyes reported the routine evisceration of the ocular contents when there was severe intraocular infection [3]. Later, in 1884, Mules reported for the first time the use of an orbital glass sphere implant in an eviscerated cavity, this becoming the bedrock of volume loss restoration and improving dramatically cosmetic results of this surgery [2,4]. In 1887, Frost inserted a crystal ball orbital implant inside Tenon's capsule after an enucleation procedure [5].

Since then, advances in surgical techniques, anesthesia, new implants, and wrapping materials and prosthetics over the past decade have greatly improved surgical outcomes and patient satisfaction. Today, most patients have good cosmetic results following the removal of and eye. However, even an exquisite surgical technique cannot prevent complications in the immediate and long-term follow-up of these sockets, making these patients challenging for the Oculoplastic Surgeon.

The decision to remove an eye must be individualized to each patient. Advantages and disadvantages exist among the different surgical techniques and implant materials.

2. Surgical indications

2.1. Enucleation

The most common indications are intraocular malignancy, blind painful eyes, penetrating trauma, very bad ocular cosmesis or phthisical eyes, and prevention of sympathetic ophthalmia (SO).

A significant decrease in the number of enucleations was observed between 1975 and 1995. This was primarily caused by a decrease in the number of glaucoma-related enucleations [6]. Evisceration, unlike enucleation, disrupts the integrity of the globe's barriers, which could trigger an autoimmune reaction (SO) in the contralateral eye. Although some authors believe

that SO continues to be an important disadvantage, evisceration has gained popularity in the past few decades because of superior functional and cosmetic results compared to enucleation. Levine et al. [7] concluded that the risk of SO following evisceration is extremely low.

Choroidal melanoma in adults and retinoblastoma in children are the most common intraocular malignancies. In some cases of malignancy diathermy, chemotherapy and radiation may be an alternative to more disfiguring surgeries.

2.2. Evisceration

1. Penetrating trauma: one of the most common indications of evisceration in cases when sclera is largely intact. Classically, it was thought that surgery should be performed within 14 days of injury. In cases with extensive disruption of the globe's tissues, the removal of all uveal tissue is difficult via an evisceration; therefore, enucleation may be a better option [6].
2. Blind eyes: removal of a blind eye is generally the last possibility. We attempt to control pain with a retrobulbar injection of alcohol or chlorpromazine. When the patient refers corneal discomfort, some eyes may benefit from conjunctival flaps [8]. Nowadays evisceration is widely preferred in Europe because of its advantages in blind eyes, such as better cosmetic results and shorter postoperative recovery time [9].
3. Endophthalmitis: many surgeons prefer evisceration for endophthalmitis because of the low risk of bacterial retroocular space invasion. Others suggest that enucleation should be performed when there is no certainty that the sclera may be involved [10]

2.3. Exenteration

Orbital content removal is reserved for the treatment of potentially life-threatening malignancies arising from the eye, eyelid, orbit, paranasal sinuses, and periocular skin. Secondary orbital spread from eyelid, intraocular, and conjunctival malignant tumors was the most frequent indication of exenteration, followed by primary orbital malignant tumors. Other indications have included sclerosing inflammatory pseudotumors and invasive fungal disease of the orbit [11-13].

3. Surgical techniques

3.1. Enucleation surgical technique

1. It is absolutely mandatory to ensure we will remove the correct eye. Sometimes it is obvious which eye should be enucleated, like in a severely traumatized eye, but in other cases, the eye can be morphologically perfect and doubts can arise. This can be the case of a choroidal melanoma. We strongly recommend to read the patients notes and ask the patient to identify the eye that should be removed. Once sure, the eye should be marked with pen with an arrow or letters on the side of the forehead of that eye. We also like to

dilate the eye with tropicamide [14]. This marks the side to operate on and allows the surgeon to check the tumor inside the globe in the operating room.

2. Once in the operating room, we ask the patient to identify calling out his name and surname and age. We ask again which eye is the one to be removed and to signal it for us with his hand before he lies on the operating table.
3. Although we are aware some surgeons prefer intravenous sedation and local anesthesia, it is of our preference and of our patients to undergo general anesthesia. Even in cases of general anesthesia, some surgeons also inject local anesthesia so as to obtain local vasoconstriction, which will aid the surgeon making the surgery “cleaner” and faster. Two percent lidocaine with 1:100,000 epinephrine can be used for superficial injection like in the subconjunctival space. Retrobulbar anesthesia is made with a combination of 2% lidocaine and 1:100,000 epinephrine mixed 1:1 with 75% bupivacaine.
4. Intravenous antibiotic is usually used 30 min prior to surgery in the presurgery preparation area.
5. We prep and drape in the standard fashion using povidone iodine for the skin and conjunctiva. We like to cover the other eye, but some may prefer to let the other eye uncovered and closed.
6. We use a lid speculum, taking care to protect the field from eyelashes. If eyelashes enter the field, these can be cut or stuck to the eyelid with an adhesive skin closure.
7. Using Westcott scissors or dissection scissors, perform a 360° limbal peritomy trying to leave on the limbus no more than 1 mm of conjunctiva. Remember to be as careful as possible. The conjunctiva, once closed at the end of the surgery, will be the first defensive layer of the anophthalmic socket (Figure 1).

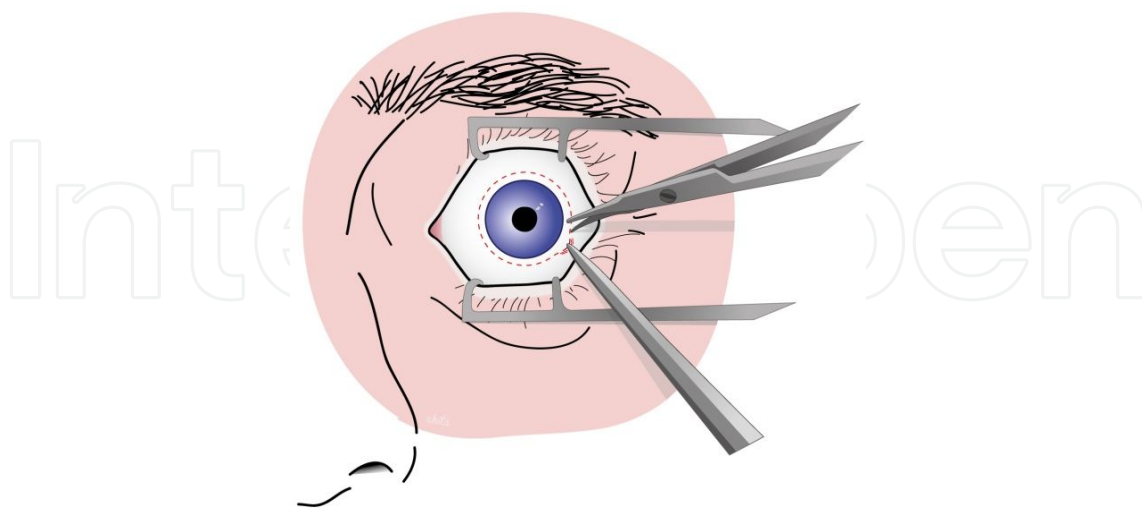


Figure 1. 360° limbal peritomy

8. Blunt dissect Tenon's capsule from the globe. Introduce your dissection scissors beneath the conjunctiva and Tenon in the limbus in any of the four quadrants limited by the four

rectus muscles and smoothly direct your dissection posteriorly and around the globe until you feel you are close to the optic nerve. Repeat this maneuver in the other three quadrants (Figure 2).

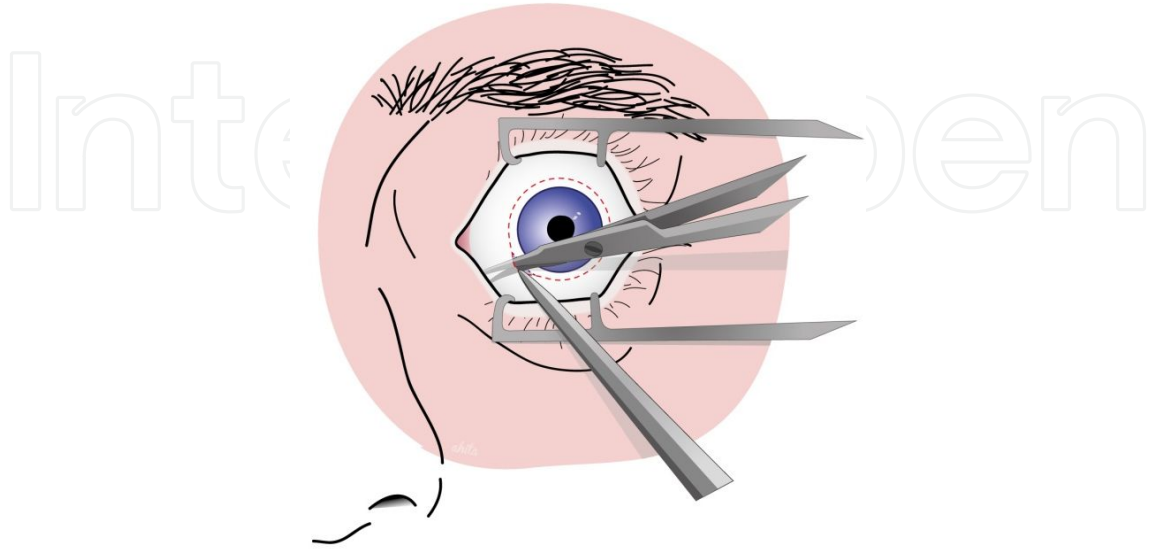


Figure 2. Blunt dissection of Tenon's capsule

9. Localize each rectus muscle with one or two muscle hooks. Ensure you isolate the insertion of the muscle. If this is not visible, some Tenon tissue may be present. Remove it with blunt forceps, pulling it away from the muscle insertion (Figure 3).

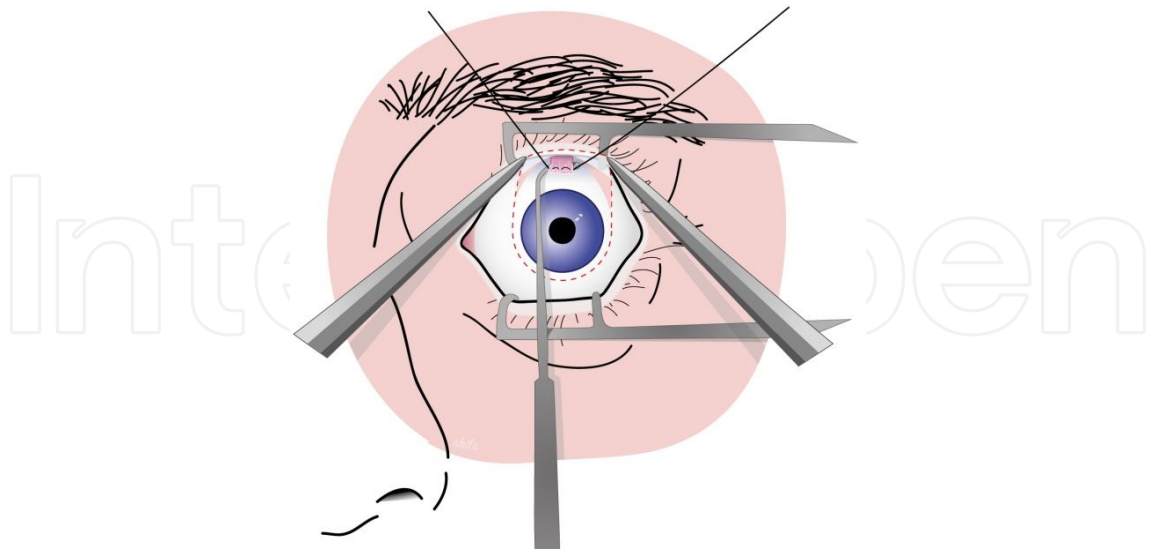


Figure 3. Muscle insertion isolation

10. Pass a 5/0 absorbable suture in a whiplock fashion on either side of the muscles insertion. Cauterize with a monopolar (Colorado needle) or bipolar cautery to avoid bleeding and

then cut the insertion of the muscle with a scissor leaving 1 or 2 mm of insertion on the globe (this stump will be useful in the future to pull the eye out of the orbit). Clamp the sutures for the four rectus muscles away from the surgical field with bulldog clamps or hemostats. The muscles will “spread” away from the globe (Figures 3-5).

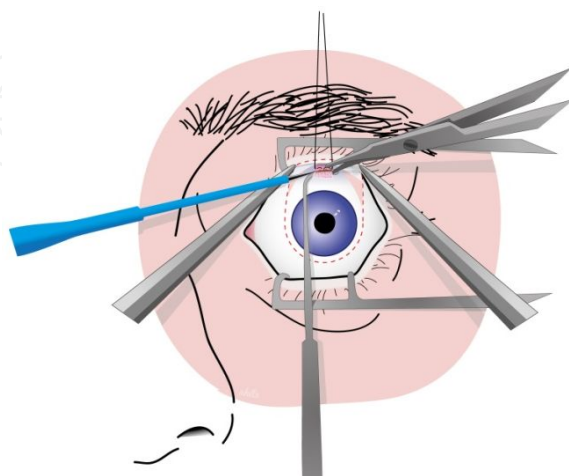


Figure 4. Muscle insertion is cut

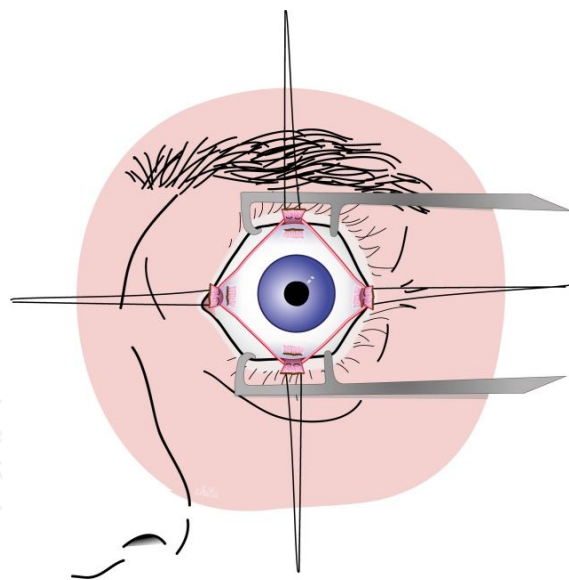


Figure 5. Four rectus muscles are isolated

11. Isolate the inferior oblique muscle in the inferotemporal quadrant with a muscle hook sweeping it from posterior to anterior toward where the inferior rectus was located. As with the rectus muscles, cauterize and cut. Some surgeons like to reinsert the inferior oblique muscle in the orbital implant. In our experience, it is not necessary to achieve a correct implant motility (Figure 6).

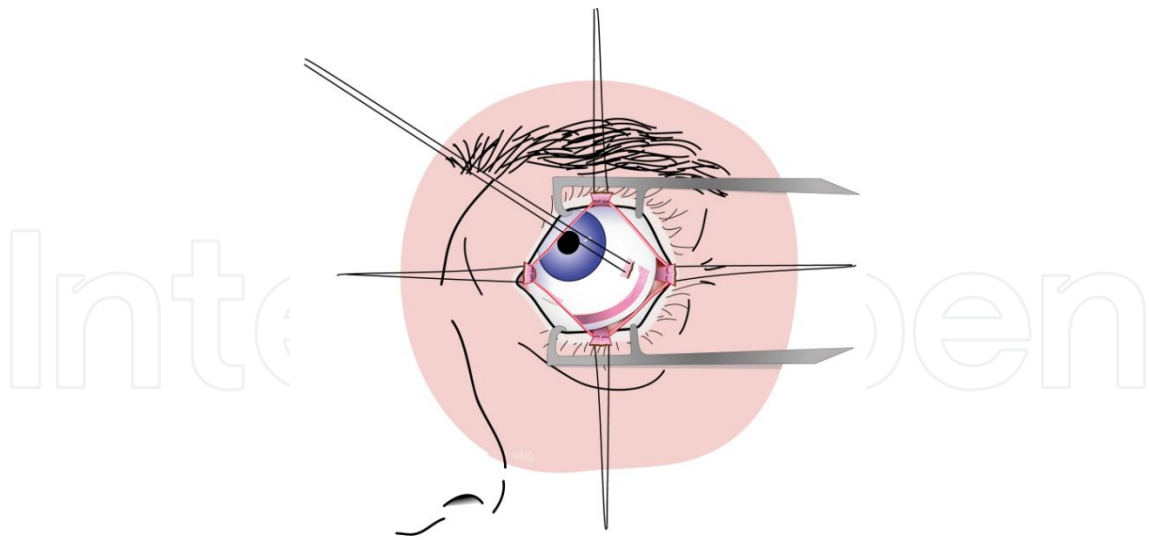


Figure 6. Inferior oblique exposure

12. Isolate the superior oblique muscle in the superonasal quadrant by sweeping the muscle hook from anterior to posterior toward the insertion of the superior rectus muscle. Cauterize, cut, and leave untagged.
13. Pass a 4/0 silk suture through the insertion of the two horizontal rectus muscles or the four of them. This will help to pull the globe during the removal.
14. Place a hemostat around the optic nerve. This will prevent the ophthalmic artery from bleeding. Place a large curved hemostat behind the globe; thus, you can safely cut the optic nerve with scissors without danger for the integrity of the globe. When you cut the nerve, you will find it harder than you would expect. To get as much optic nerve stump as possible, try to direct the scissors posteriorly while pulling the globe out of the orbit with your traction sutures (Figures 7 and 8).

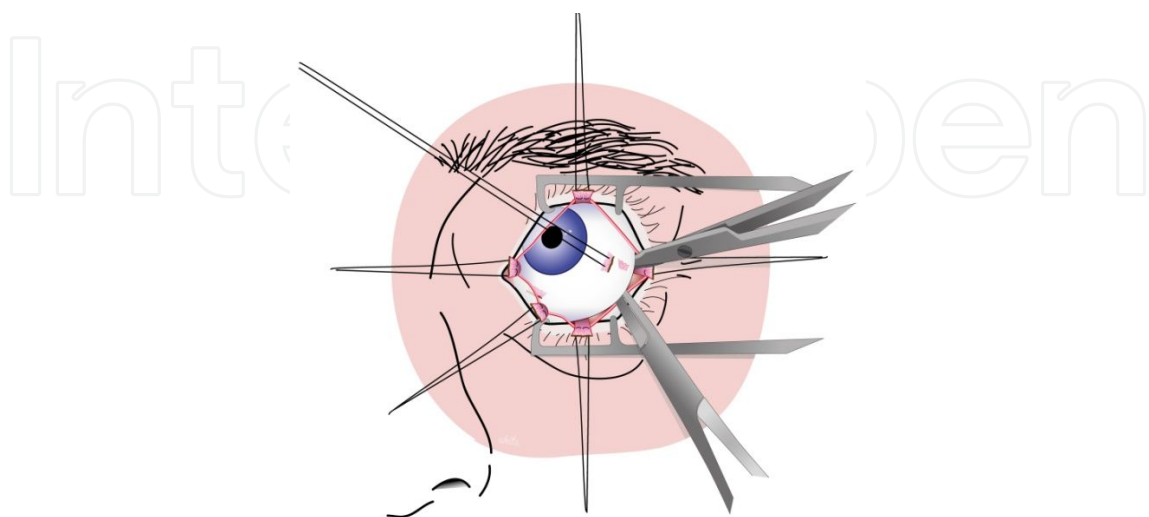


Figure 7. Hemostat placed on optic nerve which is cut with scissors

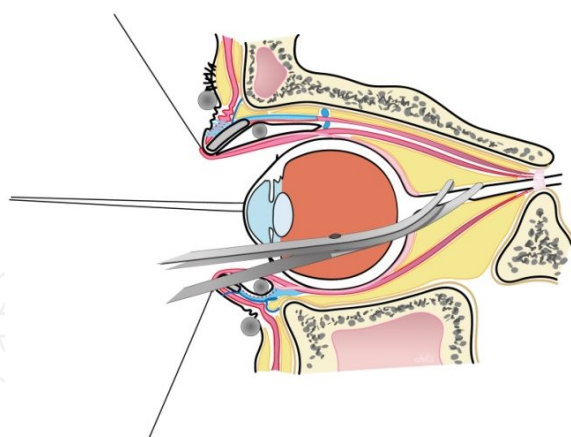


Figure 8. Sagittal view of the orbita showing the optic nerve being cut

15. Once the nerve is cut and you pull with your silk sutures, you may feel something is retaining the globe in the orbit. It is usually small segments of retained Tenon's capsule. Cut this Tenon's tissue with care as it may contain small vessels that may bleed. We recommend you cut this tissue as close to the globe as possible in order to avoid inadvertent injury to other tissues like muscles or orbital fat (Figure 9).

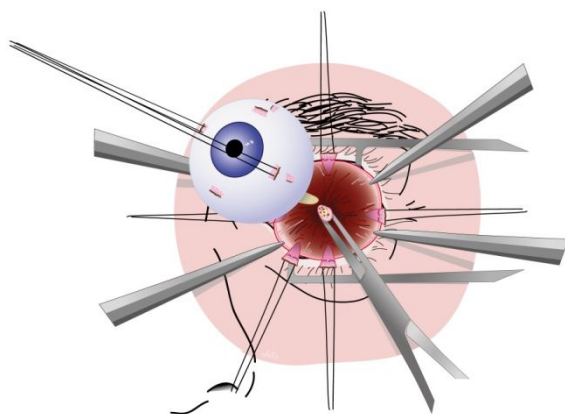


Figure 9. Globe removed from the orbit. Optic nerve stump compressed by hemostat

16. Place the globe in an auxiliary table and prepare it to send to the pathologist.
17. Release the hemostat around the stump of the optic nerve. Apply pressure in the socket and coagulate the optic nerve with the monopolar or bipolar cautery if there is generous bleeding. Avoid excessive cauterization in the socket as it may predispose to future complications of the cavity such as its contraction or implant displacement. Sometimes gentle pressure with gauze soaked in thrombin, saline, or hydrogen peroxide for a few minutes is enough to stop small hemorrhages.
18. Once the socket is ready, the next step is to introduce the orbital implant. The size of which should have been chosen depending of the axial length of the eye or the fellow eye if the removed eye was in phthisis.

19. Nonporous implants should be implanted, wrapped in a mesh or donor sclera; porous implants can be implanted, wrapped or unwrapped.
20. Prior to insertion of the implant, it is immersed in an antibiotic solution (500 mg of cefazolin in 500 ml of saline). Then a Vicryl mesh or sclera is placed around the implant. If you use a mesh, twist the excess mesh in the posterior pole of the implant, tie a knot with 4/0 polyglactin suture, and cut the remaining material. If you use donor sclera, suture it around the implant with 5/0 silk.
21. The implant is then introduced within Tenon's capsule in the orbit. Some surgeons use a Carter sphere introducer or similar plunger-like mechanisms. We use our hands. It is of crucial importance in order to avoid future problems to place the implant as posterior as possible. This is in the intraconal space, leaving part of the posterior pole of the implant uncovered by Tenon's capsule. Sometimes Tenon's tissue is dragged as you introduce the implant. We recommend that the surgical assistant retracts Tenon's anteriorly so as to avoid its displacement with nontoothed forceps while placing the implant.
22. Once correctly positioned in the orbit, we press the implant deep in the orbit with a finger to make sure it is correctly fitted. Make sure that Tenon's layer is not trapped under the implant and that it covers the implant needing no excessive traction with nontoothed forceps. If any doubt of good positioning or implant size should arise, removal of the implant is always a good option.
23. Secure the rectus muscles on the anterior surface of the implant or on the wrapping material. We like to suture first the horizontal rectus muscles. Avoid overlapping of the muscles. Some authors recommend a 5-to-10mm distance between them. We believe that placing them next to each other helps preventing implant extrusion. In the same way, suture both vertical rectus muscles adjacent to the horizontal muscles, creating a "muscle barrier." You may want to suture the inferior oblique muscle just inferior to the lateral rectus muscle (Figures 10 and 11).

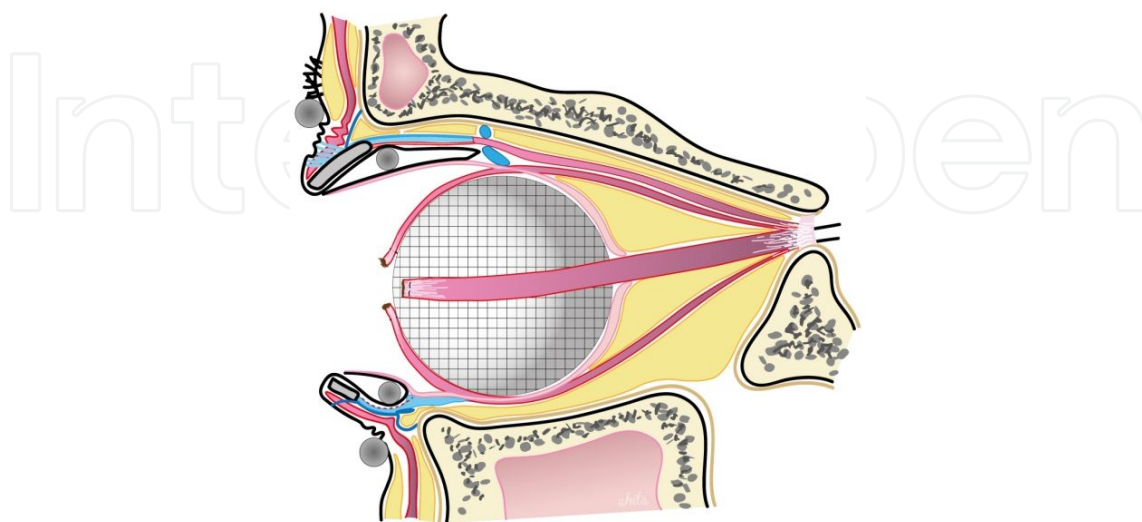


Figure 10. Sagittal view of the orbit showing four rectus muscles sutured to the implant

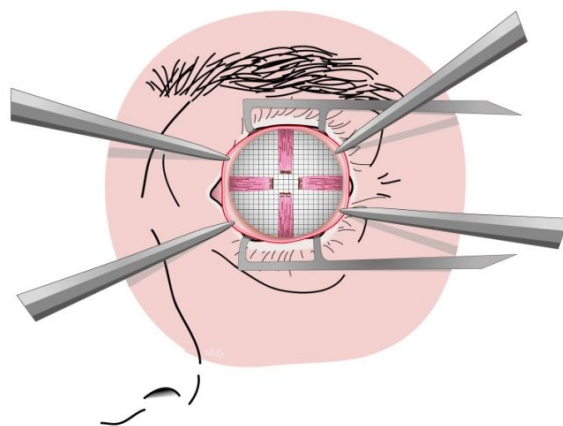


Figure 11. Frontal view of the orbit showing four rectus muscles sutured to the implant

24. Meticulous closure of Tenon's capsule is very important. We recommend interrupted buried 5/0 absorbable (polyglactyn) sutures, but some may prefer a running suture. It is extremely important to avoid tension when closing Tenon's layer (Figure 12).

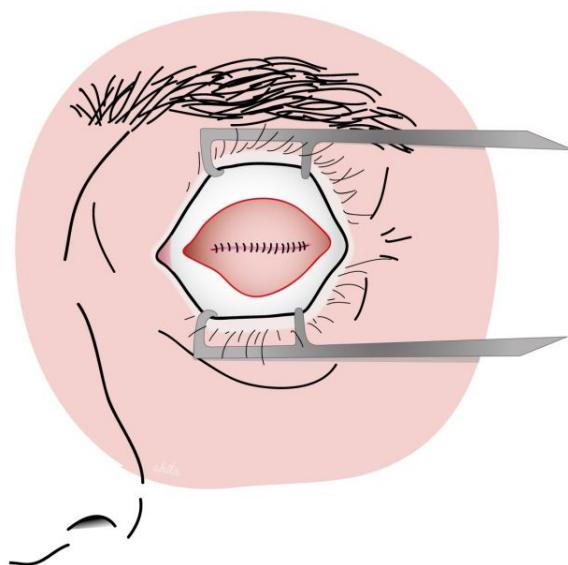


Figure 12. Tenon's capsule sutured beneath conjunctiva

25. A running 6/0 absorbable suture is used to close the conjunctiva, once again, avoiding not too close tissue under tension. Nerad [14] recommends local anesthetic injection into the retrobulbar space for postoperative pain relief (Figure 13). We prefer intravenous analgesia.
26. Abundant antibiotic and steroid ointment should be placed in the socket, and finally an acrylic conformer should be placed. Some surgeons perform a temporal tarsorrhaphy to maintain the conformer in place for 1 or 2 weeks.
27. Tight application of eye patches will finish our surgery.

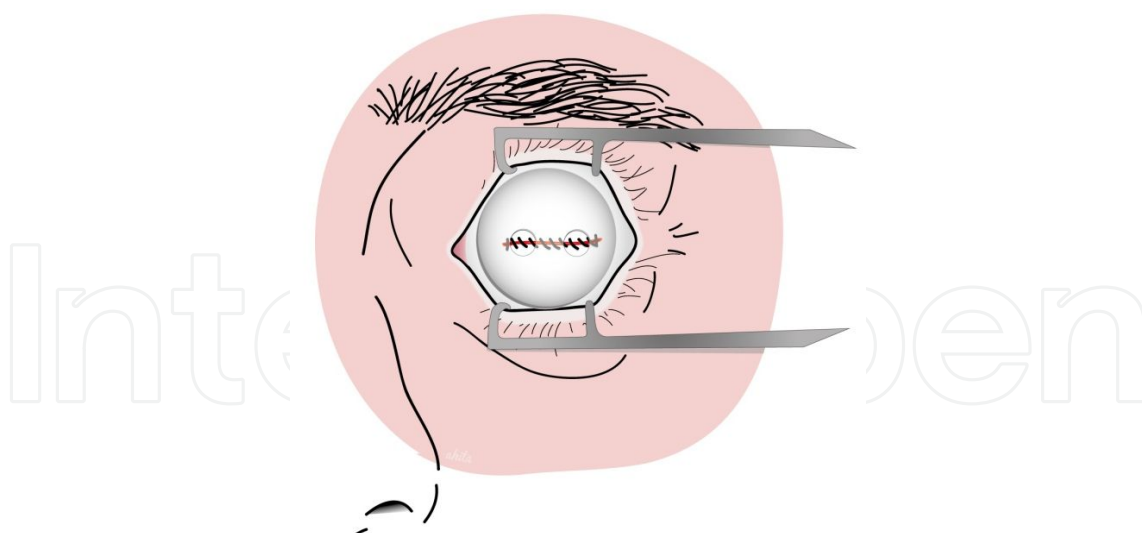


Figure 13. Conjunctiva sutured under an acrylic conformer

3.2. Evisceration surgical technique

1. See enucleation surgical technique (Figure 1).
2. Undermine the conjunctiva by approximately 5 mm, 360°.
3. Blunt dissect Tenon's capsule from the globe. Introduce your dissection scissors beneath the conjunctiva and Tenon's layer in the limbus in any of the four quadrants limited by the four rectus muscles and smoothly direct your dissection posteriorly and around the globe until you feel you are close to the optic nerve. Repeat this maneuver in the other three quadrants (Figure 2).
4. Localize each rectus muscle with one or two muscle hooks. Ensure you isolate the insertion of the muscle. If this is not visible, some Tenon tissue may be present, remove it with blunt forceps pulling it away from the muscles insertion (Figure 3).
5. Pass a 5/0 absorbable suture in a whiplock fashion on either side of the muscles insertion. Clamp the sutures for the four rectus muscles away from the surgical field with bulldog clamps or hemostats (Figure 14).
6. Incise full thickness of the cornea at the limbus with a blade (numbers 11 and 15; Phaco Keratome). Note that aqueous humor will exit the anterior chamber. Complete a 360° keratectomy with Westcott scissors and toothed forceps (Figure 14).
7. Once the cornea is removed, use an evisceration spoon to dissect the sclera from the choroid. If complete dissection is possible, remove the intraocular contents en bloc. It is common to find active bleeding from the central retinal artery and other perforant arteries that branch from long anterior ciliary arteries. We recommend to use suction and a monopolar or bipolar cautery to stop the bleeding. Should the intraocular contents break while dissecting the choroid from the sclera, we recommend to remove them with a suction device in order to minimize the exposure of the content of the eye to the socket, thus reducing the low risk of sympathetic ophthalmia (Figure 15).

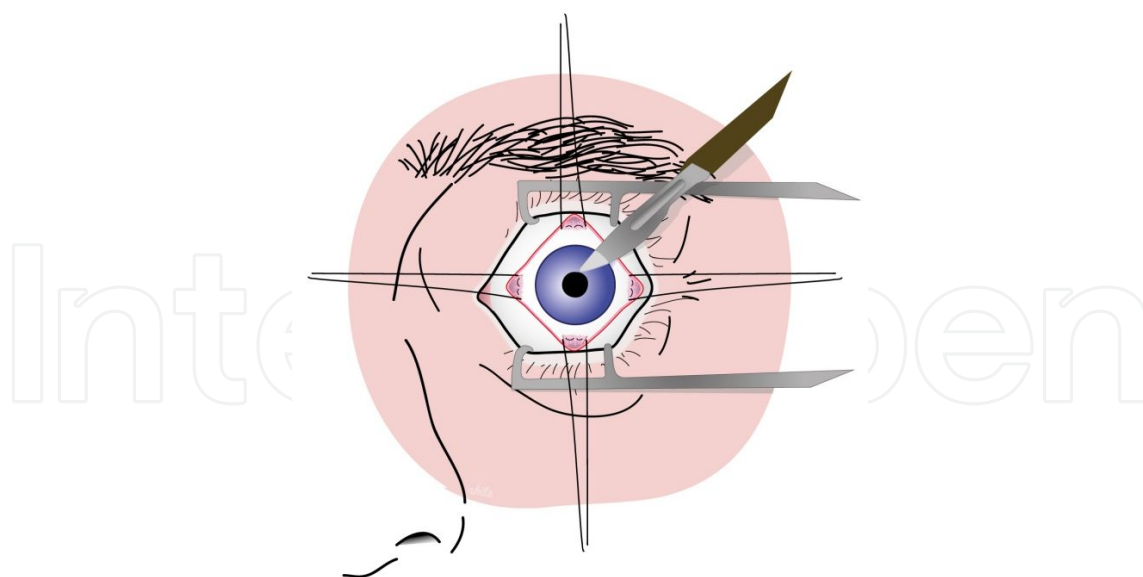


Figure 14. Keratectomy is started with number 15 or number 11 blades

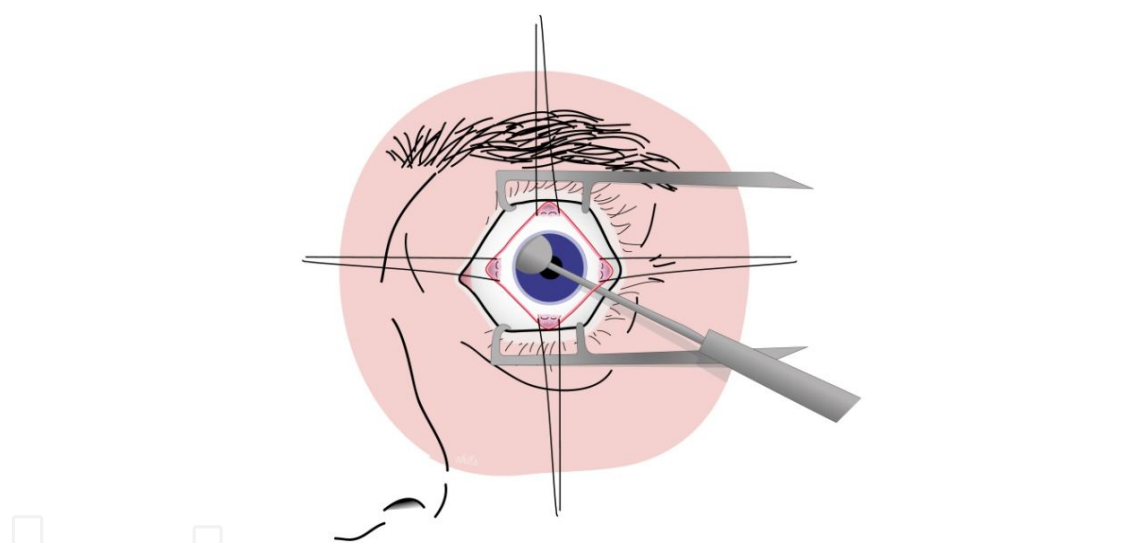


Figure 15. Choroid is dissected from sclera

8. Wipe the internal scleral surface with cotton-tipped applicators soaked in absolute alcohol and remove retained uveal tissue with gauze.
9. Upon this point of the surgery, there are different options to prepare the sclera to accommodate the orbital implant. Some authors prefer to make 10-15 mm radial scleral incisions in the four oblique quadrants, avoiding the insertions of the rectus muscles [13]. Others prefer a complete posterior sclerotomy, transecting the sclera from the superior nasal and inferior temporal limbus to the optic nerve. Sclera is then trimmed from the optic nerve in a circular fashion. We prefer the four-petal technique described by Sales-Sanz and Sanz-Lopez [15]: four sclerotomies are performed from the limbus, between the rectus muscle insertions, to the optic nerve with Stevens scissors. The optic nerve is cut at its insertion

point in the posterior sclera. The four sclerotomies reach one another to form four separate scleral petals, each containing one rectus muscle insertion. This last option allows in our experience an easier insertion of the orbital implant in the intraconal space and secondarily makes complete cover of the implant very simple (Figure 16).

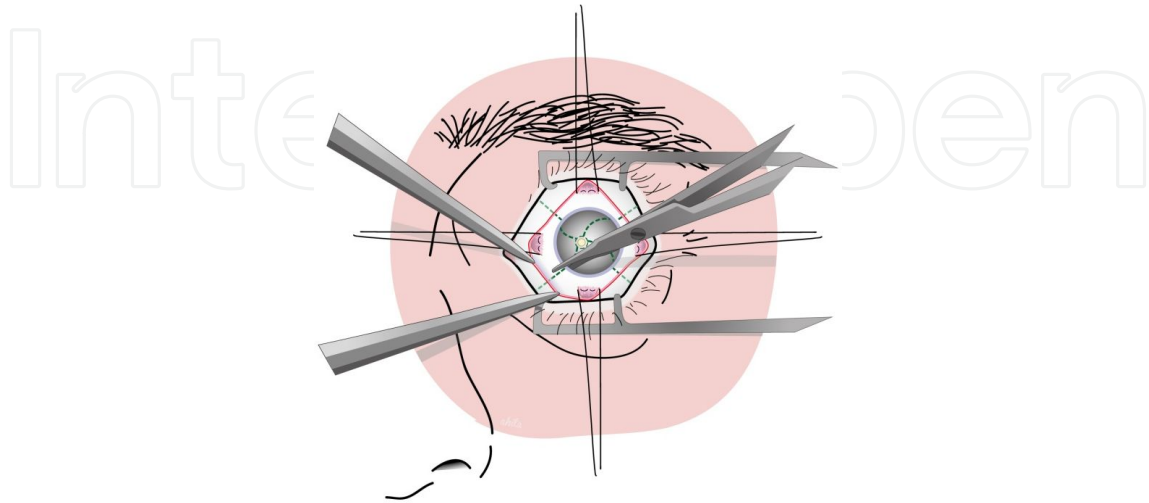


Figure 16. Four sclerotomies performed with scissors

10. 9. Gently pull the four petals out of the socket so the implant can be placed as deep as possible using a Carter sphere introducer or your fingers. The further the implant enters the orbit, the easier it will be to bring the four petals anterior to the implant. Because the petals are independent from each other and from the optic nerve, the sclera can cover any size of implant without tension. The vertical petals are sutured to each other in front of the implant using a continuous 5/0 absorbable suture. The horizontal petals are sutured in the same way over the vertical petals. Make sure that sutures are tied with no tension (Figures 17-20).

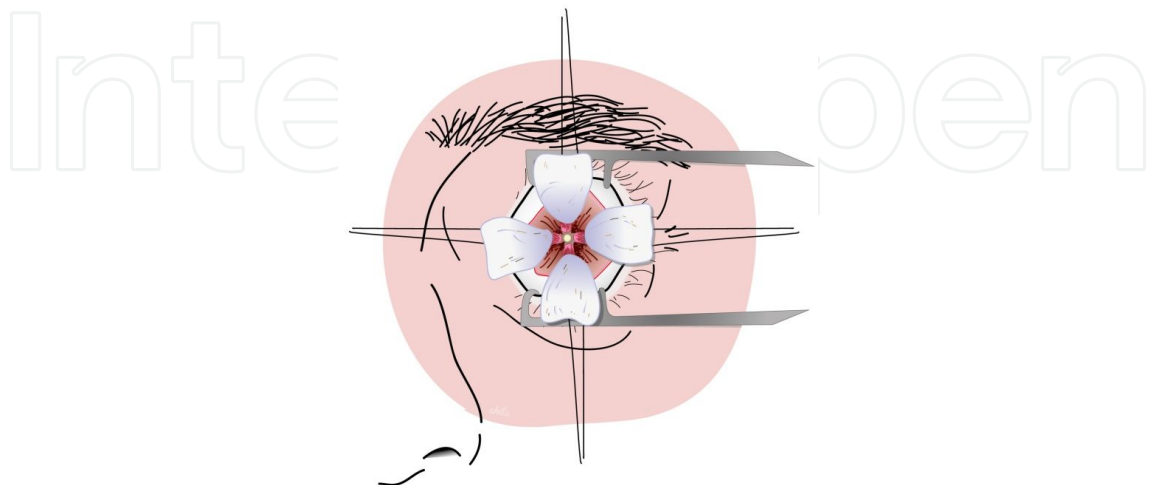


Figure 17. Four petals stretched wide appart

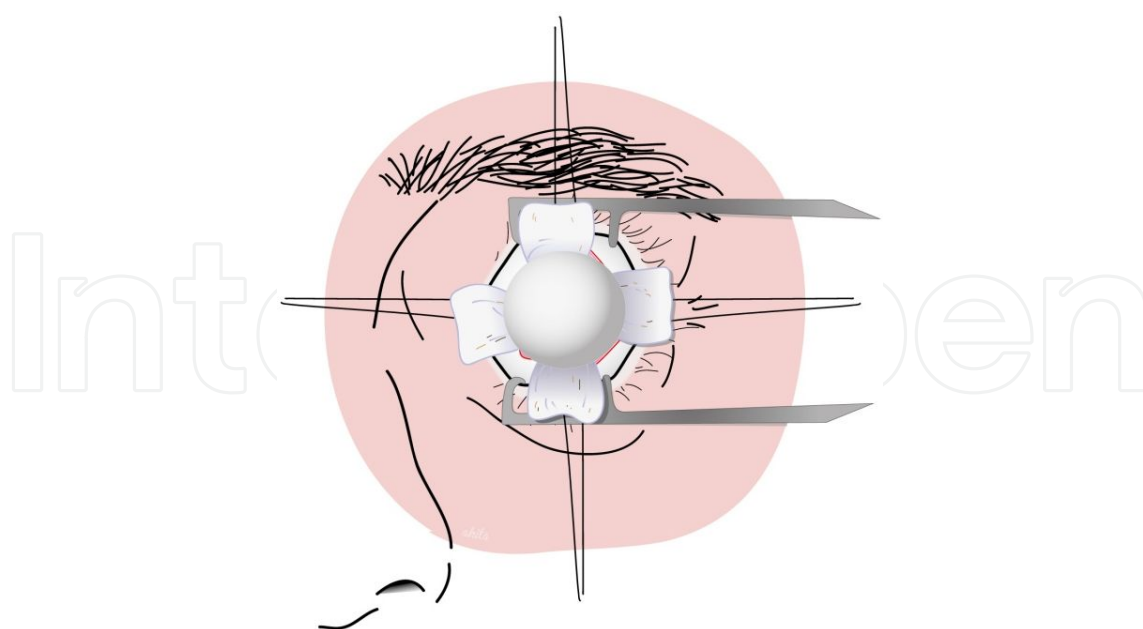


Figure 18. Implant placed between petals pressed deep inside the orbit

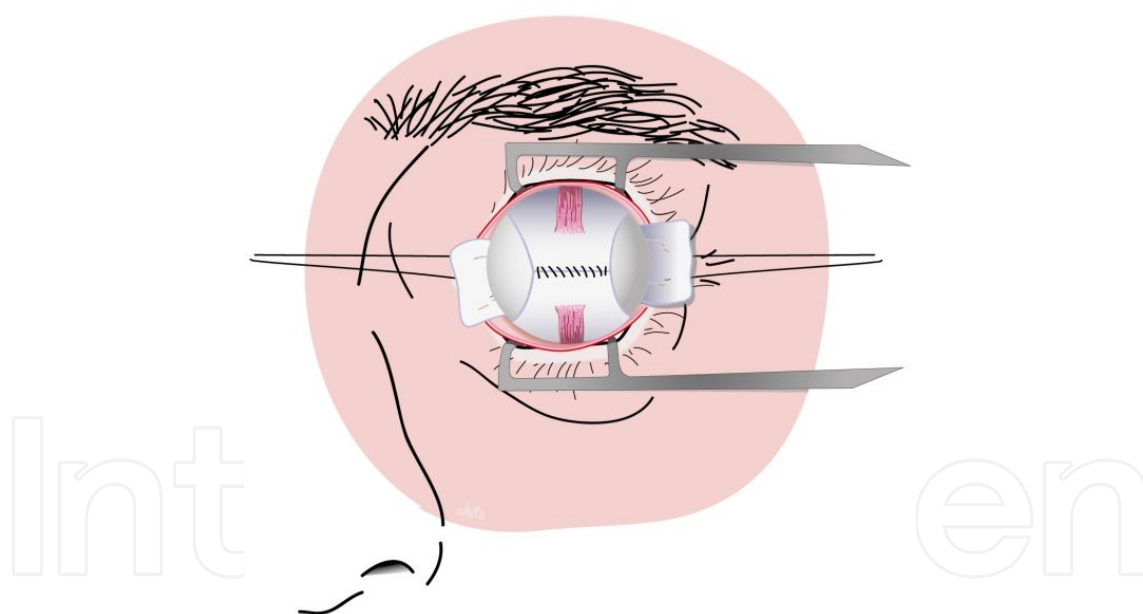


Figure 19. Implant wrapped with sclera from the upper and lower petals with muscles attached

11. Meticulous closure of Tenon's capsule is very important. We recommend interrupted buried 5/0 absorbable (polyglactyn) sutures; again, some may prefer running sutures. It is extremely important to avoid tension when closing Tenon's layer (Figure 12).
12. A running 6/0 absorbable suture is used to close the conjunctiva, once again avoiding to close tissue under tension (Figure 13).

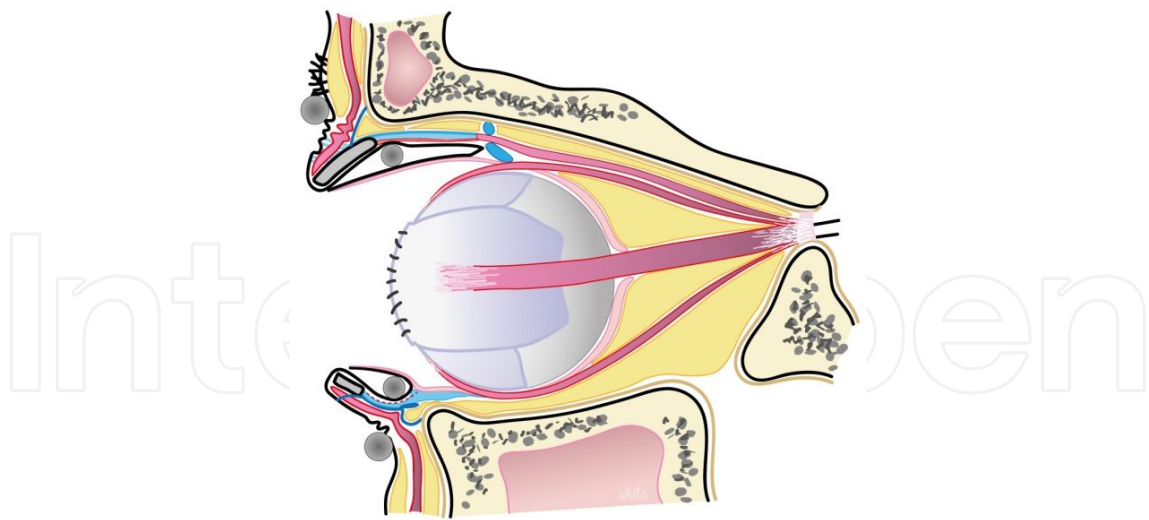


Figure 20. Sagittal view of orbit showing correct wrapping of implant with four petals of sclera

13. Abundant antibiotic and steroid ointment should be placed in the socket, and finally an acrylic conformer should be placed. Some surgeons perform a temporal tarsorrhaphy to maintain the conformer in place for 1 or 2 weeks.
14. Tight application of eye patches will finish our surgery.

3.3. Exenteration technique

Technically, orbital exenteration has several variations, each with its own indications.

3.4. Total exenteration

1. General anesthesia is advisable. Local anesthesia is useful to achieve good hemostasis in the eyelid and periorbital tissues. Retrobulbar or intraorbital anesthetics are forbidden when tumors or infections are present.
2. Intravenous antibiotic is usually used 30 min prior to surgery in the presurgery preparation area.
3. 4/0 silk sutures (two per eyelid) are placed on the eyelid border to provide traction. We recommend long bits with the needle as traction later on in the surgery may tear the tarsal and skin tissues.
4. With a scalpel blade (number 11 or 15) or with an electrocautery, incise the skin in an elliptical fashion trying to follow the inner surface of the orbital rim (Figure 21).
5. Dissect under the skin until you reach the periorbital with scissors or with the electrocautery. We strongly recommend to have a bayonet bipolar cautery forceps and a suction device before entering the subperiosteal space (Figure 22).

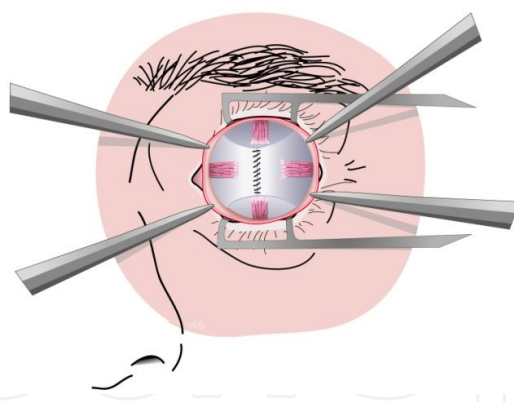


Figure 21. Frontal view of implant wrapped in scleral petals with attached rectus muscles

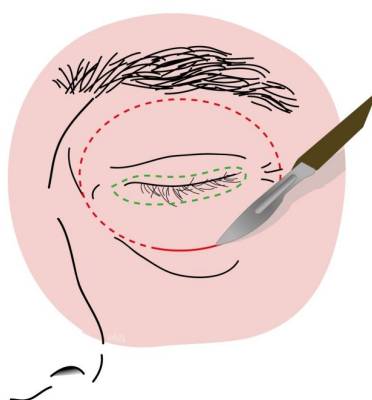


Figure 22. Skin incisión with number 11 or number 15 blades following the inner surface of the orbital rim

6. Once the periorbita is reached, incise it with a scalpel blade, a monopolar cautery, or a Freer periosteal elevator. Sometimes it is difficult to elevate the periorbital periostium as it is firmly stuck to the underlying bone, especially in the frontal bone and the frontal process of the maxillary bone (Figure 23).

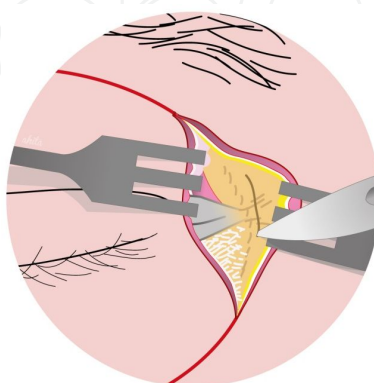


Figure 23. Detail of the periorbita being incised. Note ROOF being rejected temporally and lateral tarsal ligament being rejected nasally

7. Once elevated the periorbital periosteum, continue elevating the orbital periosteum. Care should be taken where the periosteum is more tightly adhered to the bone: anterior and posterior lacrimal crests, insertion of the inferior oblique muscle, trochlea, lateral orbital tubercle, and superior and inferior orbital fissures (Figure 24).

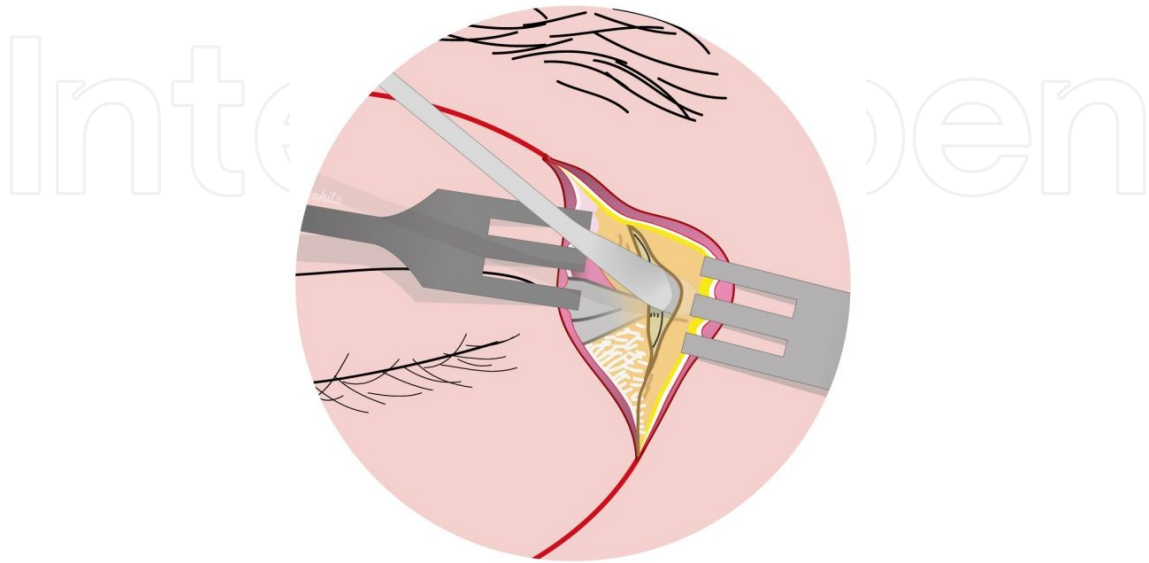


Figure 24. Freer periosteal elevator dissecting periorbita

8. Periosteum should elevate easily with the help of the Freer periosteal elevator and malleable retractors. At some point, periosteum can tear, do not panic, and carefully try to dissect it from the opposite point of the tear. The nasolacrimal duct will be exposed once the periosteum is elevated. If possible, obliterate it with fat or muscle to decrease the risk of fistula formation.
9. Continue posterior dissection of the periosteum. At this point, you should remember the orbital anatomy, a squared based pyramid. This means you will need to use your traction sutures on the eyelids and help yourself with one or two small malleable retractors to displace the orbital contents in order to increase the visibility of the orbital walls.
10. Important landmarks to take into account and to avoid damaging are as follows: in the medial wall—supratrochlear and anterior and posterior neurovascular bundles; in the roof—supraorbital neurovascular bundle; in the lateral wall—zygomaticofacial and zygomaticotemporal neurovascular bundles; and in the floor of the orbit—the infraorbital canal. When you come across these structures, bipolar cautery should be applied. Some authors prefer to clip them (Figures 25 and 26).
11. It is also important to remember that the medial wall and the floor of the orbit are easy to break because the bones at those points are thin, especially in the lacrimal fossa and in the ethmoid bone's lamina papyracea.
12. When dissection progresses in the inferolateral portion of the orbit, we will encounter the infraorbital fissure that is rich in vessels. It should be thoroughly electrocauterized.

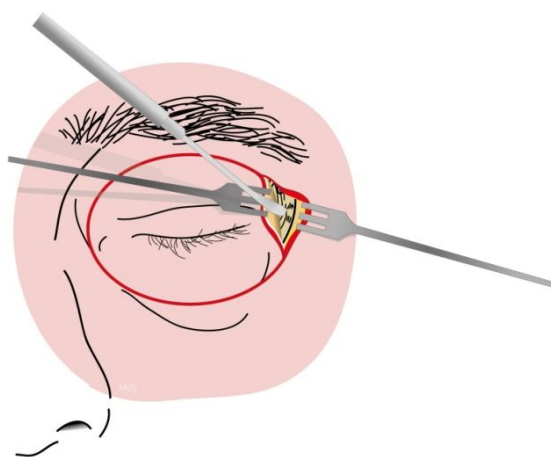


Figure 25. Dissection is carried on deep back towards the orbital apex

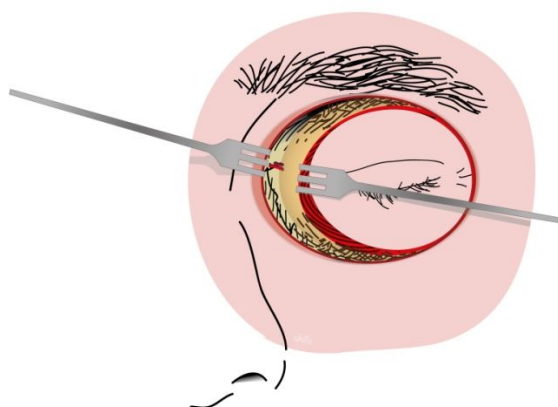


Figure 26. Avoid damaging important vessels such as the Anterior Ethmoidal Artery

13. Continue the dissection until the apex is reached. Carefully cauterize the superior orbital fissure and the posterior orbital tissues, including the optic nerve. We recommend to be patient and slowly cauterize and cut in small bits to avoid bleeding that may be difficult to control and may frighten the surgeon (Figure 27).

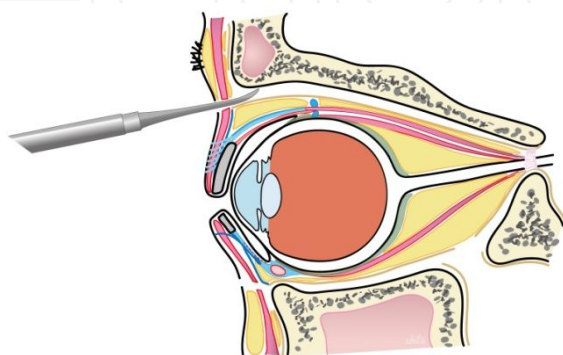


Figure 27. Sagittal view of Freer periosteal elevator dissecting the periorbita posteriorly

14. Pull the silk traction sutures and place the orbital content in an independent table where it will be prepared to be sent to the pathologist.
15. The orbit with the bare bones may be left to granulate, gauzes with antibiotic should be placed, and the orbit should be pressure patched. Some authors will consider covering the bone with a split-thickness skin graft [11,14,16] from the thigh or a tissue flap, generally from the temporalis muscle (Figures 28 and 29).

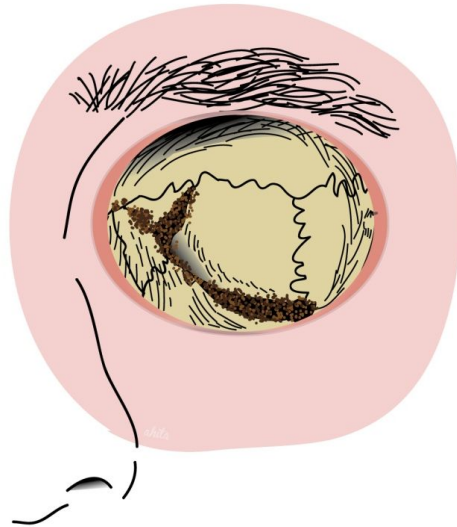


Figure 28. Frontal view of the exenterated orbit showing bone landmarks and hemostasis of the orbital apex

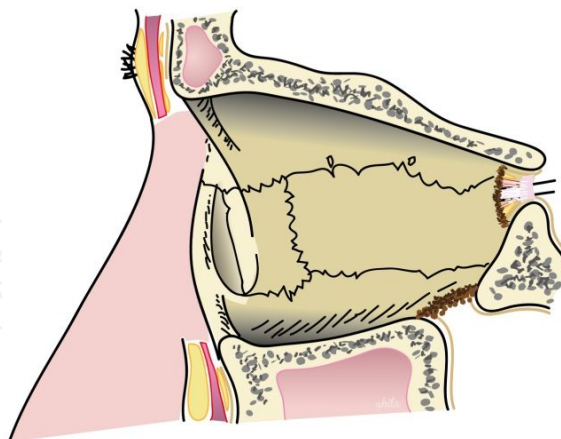


Figure 29. Medial view of the exenterated orbit showing bone landmarks and hemostasis of the orbital apex

3.5. Eyelid-sparing exenteration

We prefer this procedure when the disease does not affect the eyelid because the skin and orbicularis muscle can be used as “primers” to initiate the cavity’s granulation and epitheli-

alization. The difference with the previously described technique is that the skin incisions are placed 2 mm above the lash line and are joined at the medial and lateral canthus. Dissection is carried out in the preseptal plane or in the preorbicularis plane. We prefer the preseptal plane; it is easy to follow and allows a good blood supply to the future granulation tissues.

In conclusion, with this procedure, we partly cover the orbital bones, and we add a vascular supply to our skin flap, reducing the time the socket needs to granulate.

3.6. Subtotal exenteration

It may be performed when the disease involves anterior orbit or conjunctiva as in conjunctival melanoma or sebaceous cell carcinoma without evidence of deep orbital invasion. It spares orbital tissues from the deep orbit; thus, the socket should heal earlier, but orbital prosthesis fixation can be complicated since there is less space.

The technique is similar to that of total exenteration but subperiosteal dissection is not carried out as far posteriorly. Orbital tissues are cut, and thorough hemostasia is performed.

3.7. Extended exenteration with bone removal

Unfortunately, high-grade malignancies or osteolytic processes will require total exenteration and the removal of the bones of the orbit. Help from other surgeons such as neurosurgeons, otolaryngology, or maxillofacial surgeons is mandatory in these cases.

3.8. Reconstruction of the exenterated orbit

The decision to reconstruct the exenterated socket depends on what is planned for that orbit. When the patient desires an orbital prosthesis, spontaneous epithelialization, skin grafts, or thin local flaps are good options. Some surgeons argue that spontaneous granulation permits a better follow-up of the cavity in order to treat as soon as possible if disease recurs. Others prefer to fill the cavity with temporalis muscle flap but this increases the difficulty to adapt an orbital prosthesis for the ocularist.

3.9. Spontaneous granulation

It is the fastest way to finish the surgery, and it reduces surgical morbidity in other sites but requires very frequent postsurgical care, initially three times a week and later on every 1 or 2 weeks until complete epithelialization is observed. This can take up to 2 or 3 months more than when split thickness grafts are used. Usually, gauzes with antibiotic ointment are applied in the first month.

3.10. Skin grafting

Split thickness grafts, usually harvested from the thigh with an automated dermatome, are used, which is technically simple to perform and takes less time than a more complex flap reconstruction. In order to adapt the graft to the socket, slits can be performed with scalpel or a number 15 blade. The edges are sutured to the borders of the surgery with absorbable 6/0

sutures. Gauze soaked in antibiotic ointment is packed in the socket, and a pressure dressing is placed for 1 week. Once this is removed, the gauze will be changed every 2 or 3 days until the graft is correctly stuck to the bone beneath.

3.11. Soft tissue reconstruction

Some surgeons advocate primary reconstruction during exenteration surgery. Volume loss in the socket can be replaced with vascularized free flaps. They are useful to cover alloplastic implants or other kind of flaps used for bony reconstruction. One of their disadvantages is donor site morbidity. Another one is that aesthetics in the donor site and the socket may seem unnatural. Many local flaps have been used, including temporoparietal fascia, temporalis muscle, or frontalis muscle. As said previously, these flaps can potentially affect postoperative tumor surveillance, making imaging techniques, especially MRI, essential and increasing the cost for the National Health Service or the insurance company. On the other hand, orbital obliteration with a flap reconstruction may confer less pain, improve personal hygiene, and reduce the risk of sino-orbital fistula formation [17]. Spiegel et al [18] reported that orbital obliteration reduces the risk of intracranial infections and facilitates dosage calculation of radiotherapy by providing a more consistent and predictable tissue density.

3.12. Rehabilitation of the socket

Once exenterated, eviscerated, or enucleated, the socket is perceived by the patient and the family as a very significant facial deformity. Initially, the simplest way to mask the socket is with eye patches. However, once the cavity has healed, the patient can benefit from the experience of an ocularist.

Enucleated or eviscerated cavities will have a temporal prosthesis fitted in 4 or 6 weeks after surgery. Later on, a prosthesis will be made using a modified impression technique, so a custom-made prosthesis will be designed and adapted at the ocularist. It is very common that artificial eyes need to be adapted several times after the initial fitting before the patient feels comfortable with them. The patient will be followed at the ocularist once or twice a year to check if the prosthesis fits correctly in the socket, if it is affecting the lower eyelid (the weight of the prosthesis is a key factor) or if its surface needs polishing. The ophthalmologist will check the prosthesis position, the presence or absence of discharge, whether the fornices look normal, how the superior sulcus is, eyelid malpositions, eyelash malposition, relative enophthalmos, etc., when the patient visits the clinic.

Exenterated orbits are more difficult to deal with. Orbital prostheses are made by experienced anaplastologists or ocularists. The material used is completely different, usually silicone. Some patients may find glasses useful to mask the skin silicone interface. Sometimes, especially in shallow orbits, the prosthesis may tend to fall; therefore, magnetic coupling with osseointegrated screws can be fitted in, typically several months after epithelialization of the orbit is complete. Unfortunately, some patients might find that the lack of movement of these prostheses may make other people feel uncomfortable, and prefer to use just an eye patch.

4. Orbital implants

Evisceration and enucleation result in an empty cavity and aesthetic problems for the patients that we should try to avoid. We must be sure that the patient fully understands the information given about the surgery and expected results in order to obtain the informed consent. Once this is done, the surgeon will decide the type of orbital implant, which can be placed primarily or secondarily in another surgery. The implant can be made of synthetic material, autologous material, or eye-banked tissues. The ocularist has a very important role in the aesthetics of the patient. Artificial eyes have enormously improved the psychological impact and the physical image of the person who undergoes this mutilating surgery. It was back in 1885 when Mules suggested the idea of placing orbital implants in these orbits [4]. Later on, Frost used hollow glass spheres as orbital implants. The surgical procedure was slightly modified with time. It was not until 1972 when Soll [19] suggested placing the implant beneath Tenon's capsule. Helveston covered the implant with donor sclera. The volume loss in some sockets, the presence of contracted sockets, or the implant extrusion made Smith and Petrelli propose the use of dermis-fat grafts in some patients. The ideal implant should fulfill these requirements: it should replace enough orbital volume, it should permit the artificial eye to move as much as possible, it should make the eye prosthesis fit adequately in the socket, it should have a low complication rate, it should be cost-effective and simple to implant in the orbit, biocompatible, and it should not degrade [20].

Herein, we will review the available types of implants. Bio-inert and nonporous materials have given way to porous materials. The latter have multiple micropores that are interconnected, mimicking the human bone trabecular meshwork. Complications after orbital implantation will depend on several factors, including the surgical technique, the material and size of the implant, previous orbital treatments (e.g., radiotherapy), orbital disease, poorly fitted artificial eyes, or infections.

4.1. Implant selection

Both evisceration and enucleation can be performed without orbital implants, but nowadays, it is very rare not to use them because of the very poor esthetic results. The goal of placing an implant in the orbit is to compensate the loss of volume, to improve the prosthesis motility, and to offer a good symmetry with the contralateral eye. Some considerations on these facts are as follows:

4.2. Replacing volume loss

Volume loss appears to be the main determinant of anatomic changes after enucleation [21]. Human radiographic studies have confirmed that placing a spherical implant within Tenon's capsule counteracts the rotation of intraorbital contents after enucleation and associated back-tilt of the prosthesis. An adequate volume replacement permits a thinner prosthesis, relieving weight on the lower eyelid and minimizing associated ectropion formation and lid laxity [22]. Furthermore, an inferior displacement of the superior rectus-levator complex is associated to those changes [23]. Therefore, the implant must be big enough to replace the volume loss but

not too big, which may create excessive tension on Tenon's capsule that could favor the implant extrusion.

Proper implant size can be calculated either preoperatively (from the axial length of the eye to be operated on or the fellow eye) or intraoperatively (determining the volume of fluid displaced by the enucleated eye in a graduated cylinder). We recommend the first option. Kaltreider et al. [24] showed that the implant diameter should be the eye's axial length minus 2 mm or minus 1 mm if the length was calculated with A-scan. An implant that is too small will need a bigger prosthesis, potentially resulting in lower eyelid laxity and malposition of the artificial eye. Larger than needed implants will require smaller prosthesis but are associated to higher exposure rates and may difficult the adaptation of the artificial eye [25]. We follow the recommendations from Jordan and Klapper for adult patients. These are 20-22 mm spherical implants in enucleation surgery and 18-20 mm spherical implants in evisceration surgery [16].

4.3. Maintaining levator function

Another important issue to consider is the functionality of the levator muscle of the upper lid. The smaller diameter of implant, as compared to the globe alters the functional length and pivot point of the superior rectus-levator complex [26]. These factors may lead to a decreased levator function and ptosis. This situation can be improved either by surgery or by adding to the superior margin of the prosthesis additional material.

We should remember that with time, the orbital tissues of an anophthalmic orbit tend to contract towards the orbital apex, that is, nasally and inferiorly [27].

We can consider orbital implants in two main groups: integrated and nonintegrated implants.

4.4. Nonintegrated implants

They do not have a surface where rectus muscles can be anchored, nor they allow fibrovascular tissue to grow in them (this is why we call them nonintegrated). They include implants made of glass, rubber, iron, acrylic material, silicone, gold, silver, or polymethylmethacrylate [28]. Their only function is to replace the volume loss and to improve the cosmetic result. If the surgeon wants to increase the motility of the implant and, consequently, of the prosthesis, the rectus muscles should be repositioned and sutured to the anterior pole of the implant in order to move the artificial eye when the implant moves. Unfortunately, the movements achieved with this method are of smaller range than dose achieved when the implant is pegged. Some authors have suggested that when the rectus muscles are placed as described previously, that is, in the anterior pole of the implant, it may migrate when the muscles contract. Mourits et al. [29] consider that acrylic implants have a low extrusion rate and are easier to implant and explant (their surface is smoother, and there is no fibrovascular ingrowth to retain the implant) and are cheaper than porous implants. Nonintegrated implants have been widely used and have achieved good results in the end of the 19th century and all over the 20th century. Nowadays, they are still used in patients over 70 years old.

4.5. Integrated implants

4.5.1. Hydroxyapatite

Coralline hydroxyapatite is used frequently in enucleation surgery. It began to be used in orbital implants in the 1980s. It is a calcium phosphate salt present in the human bone. It is considered to be nontoxic, nonallergenic, and biocompatible. It allows fibrovascular tissue to grow in the implant, thanks to its 3-D architecture [30]. If the fibrovascular growth is poor, there is a risk of implant extrusion. There are two commercially available implants: Bio-Eye (Integrated Orbital Implants, Inc., San Diego, CA) and M-Sphere (IOP, Inc., Costa Mesa, CA). Bio-eye has been the first choice for many surgeons for years. In a survey performed in 2002 with the oculoplastic surgeon members of the American Society of Ophthalmic Plastic and Reconstructive Surgeons (ASOPRS), they inquired about their preferences in primary enucleations; 27.3% used hydroxyapatite while 42.7% used porous polyethylene [31]. Jamell et al. [32] suggested that the best way to evaluate fibrovascular growth into the implant is contrast-enhanced magnetic resonance with surface coil. They were able to show early fibrovascular growth in the implant being the central ingrowth of the fibrovascular tissue slower. This evaluation of the central vascularization of the implant is of great importance in order to know when to peg the implant. The greater vascularized the implant, the bigger the risk of blood when the implant is drilled, but at the same time, it is believed to reduce to the risk of infection, exposure, and migration [32,33]. Nevertheless, this technique has its drawbacks; it is time consuming and expensive. Therefore, sometimes you cannot detect complications of the vascularized implant on time. Due to this, Qi-hua et al. [34] used contrast-enhanced ultrasonography (CEUS) as an alternative to evaluate the implant's vascularization, claiming it is also effective and it is cheaper than the contrast-enhanced MRI. In order to increase the vascularization of the implant, some authors suggest to drill an additional number of holes in the implant where the scleral windows should be before inserting it in the cavity [35]. It is believed that increasing the fibrovascular ingrowth in the implant will decrease its risk of migration and extrusion. It should be emphasized that this type of implant is usually covered with donor sclera or other materials because its rough surface easily erodes the conjunctiva when the implant moves. This coating of the implant is useful to attach the extraocular muscles too. There is synthetic hydroxyapatite, which is half the price of coralline hydroxyapatite. It is easier to drill and to place the peg. There is also bovine hydroxyapatite from the cancellous bone of calf fibulae, fully deproteinized so as to be antigen-free.

When a peg is fit into the implant, this is done 6 or more months after the surgery because this is the time estimated for the vascularization to establish in the implant. This procedure is used in those patients who desire to increase the prosthesis motility.

Complications related to this type of implant are discharge, pyogenic granulomas, loss of the peg, reduced prosthesis motility, and an audible click, which can be annoying for the patient [36]. Calcified hydroxyapatite implants are capable of absorbing radiation. This is of special importance in children that have undergone enucleation surgery secondary to retinoblastoma, as it hinders local recurrences and decreases the effect of secondary orbital irradiation when needed [36-38]. Most patients are satisfied with the cosmetic outcome of the nonpegged implant and do not desire an additional procedure with increased risks for complications.

4.5.2. Porous Polyethylene (MEDPOR)

It is made of synthetic, high-density polyethylene powder. It is flexible and easily moldable in order to adapt it to different shapes [39]. In contrast with hydroxyapatite, it is cheaper, it does not need to be wrapped because the rectus muscles can be tied to it, and it is easier to place in the orbit. Instead of using sutures, some authors have tried to fix the muscles to MEDPOR implants with 2-octyl-cyanoacrylate tissue glue [40]. This proof-concept study concluded that this technique seemed safe and had good functional and anatomical results. Porous polyethylene allows fibrovascular ingrowth, but this does not happen as fast as it does in hydroxyapatite. A major drawback of porous polyethylene was that there was no integrating device for the ocular prosthesis available. Shore [41] described a titanium postcoupling system that was included in the implant 6-12 months after the primary surgery. Generally speaking, these implants offer excellent motility, good tolerance, and very few complications. Timoney et al. [42] reported two cases of foreign body inflammatory giant cell reaction in patients who underwent orbital fracture repairs with porous polyethylene implants.

4.5.3. Proplast

This is an alloplastic, biologically inert porous material. It allows fibrovascular ingrowth and attachment of extraocular muscles.

4.5.4. Aluminum oxide

It is a porous ceramic bio-inert material, structurally strong, and free of contaminants. It is cheaper than hydroxyapatite, and its surface is smoother. It is too biocompatible and generates a very mild inflammatory response. It can also be wrapped in Vicryl (polyglactin 910) mesh.

5. Wrapping material

Implant covering improves the volume of the orbit and motility of the prosthesis and provides an additional barrier for the implant. All of these are important factors for an optimal surgical result. It is usually done in nonintegrated implants like silicone but can be used in hydroxyapatite too in order to protect the Tenon's layer and the conjunctiva from the erosion of the rough implant surface.

5.1. Donor sclera

Once warmed up to room temperature, it is advisable to send cultures of the liquid in order to discard any possible microbiological contamination. Sclera is placed over the implant and sutured with 4-0 or 5-0 nonabsorbable running sutures. Due to its origin, there is a small possibility of infection transmission, including human immunodeficiency virus, hepatitis B or C virus, and Creutzfeldt-Jakob disease. These risks have made many surgeons abandon this wrapping material.

5.2. Autologous tissue

This type of tissue includes temporalis fascia, dermis, human donor pericardium, fascia lata, or posterior auricular muscle complex [43]. Their autologous origin prevents an immune host versus graft reaction. Nevertheless, they require an extra surgical procedure to harvest them and prepare them to cover the implant, which increases surgical time, and there is always the risk of donor site morbidity.

5.3. Synthetic tissue

Polyglactin 910 mesh (Vicryl mesh, Ethicon, Sommerville, NJ, USA) is used to wrap hydroxyapatite and bioceramic orbital implants. It offers a series of advantages: there is no risk of disease transmission, there is no need of a second surgical site, and it is easy to use. It has a porous structure that allows fibrovascular ingrowth [33]. Polytetrafluoroethylene and polyglycolic acid (Dexon mesh style no8, Davis & Geck, Manati, Puerto Rico) have also been used as implant cover materials.

Hydroxyapatite polyglactin mesh-wrapped implants [44] have been used in secondary implants with good results both in prosthesis motility and low exposition rate.

6. Considerations in children

The anophthalmic or microphthalmic socket in children has special features that we will discuss. One of the most important issues is that the orbit of the child should continue growing after the eye is removed. The surgeon must have that in mind in order to achieve good cosmetic and anatomical results. This will condition the implant selection.

The most frequent cause of enucleation in pediatric age is retinoblastoma. There has been a special concern whether to place an implant in these orbits due to the difficulties in the follow-up and the detection of tumor recurrence with an orbital implant in place. However, once it was observed that orbits in children with no orbital implants did not develop appropriately, the decision to implant was taken. Normal face and bony orbit growth depends on the orbital soft tissue contents. When the child is five and a half years old, his face is about 90% of the size of an adult's face [45]. Generally talking, the management of an anophthalmic socket in a child younger than 5 years old requires an implant that can increase in size, such as a dermis-fat graft or orbital tissue expander. A large fixed-sized orbital implant can be placed in children older than 5 years [46]. Orbital growth is completed by the time the child is 12-14 years old [47]. Dermis-fat grafts harvested from the thigh have shown to stimulate orbital growth in children [48], but their motility is poor. Thus, this is an ideal implant for children younger than 5 years old. The dermis-fat graft is also used to cover hydroxyapatite exposures and to reconstruct sockets. A low incidence of complications has been reported with hydroxyapatite implants in a large series of pediatric patients who had undergone enucleation surgery for different reasons after 60 months of follow-up and excellent cosmetic results. We should not forget that when treating an anophthalmic cavity in a child, we need to increase the conjunctival fornices,

increase the width of the palpebral fissure promoting at the same time the eyelid growth, and expand the orbital bones. These goals can be achieved with a good surgical implant and the use of progressively larger conformers.

Jordan and Klapper recommend choosing the implant depending on several factors. If a child younger than 5 years undergoes enucleation, they choose a 16-18 mm of diameter wrapped nonporous implant (e.g., silicone). They stress that you should introduce the biggest implant that does not create tension when closing the Tenon's and conjunctival layers. Another option may be dermis-fat grafts, knowing that they can reabsorb and lose some of its volume and taking into account that the artificial eye movements will be very limited. In children aged 5-15 years, they recommend hydroxyapatite or aluminum oxide [16]. On the other hand, Shah et al. used hydroxyapatite implants with low complication rates and good motility and high patient/family cosmetic satisfaction on long-term follow-up in 531 orbits of children with an average age of 3 years.

7. Postoperative complications

7.1. Anophthalmic socket complications

We can divide them depending on the surgery performed in the socket.

Patients underwent enucleation or evisceration.

7.1.1. *Dryness, discharge, or irritation*

Tear secretion may decrease with time [50]. Patients may be advised to use artificial tears or gel. Saline solution can be used to clean the ocular surface. Most anophthalmic sockets have some degree of discharge. Foreign body reaction, loss of prosthetic surface polishing, and therefore smooth surface, abrasion of conjunctival surface, and accumulation of debris between the prosthesis and the conjunctiva are factors that are believed to increase the production of debris and discharge [51]. It is advisable to minimize the handling of the prosthesis. If discharge is present, both the socket and the prosthesis should be evaluated. Scratches and loss of luster are relatively frequent, especially if the prosthesis is old. The ocularist usually helps with keeping the surface polished by smoothing the surface and removing proteins and debris every 6 or 12 months. Once surface problems or inadequate fit in the socket have been discarded, steroid or antibiotic steroid drops can be used once or twice daily. If the discharge is mucopurulent, especially if the eyelids are swollen and conjunctival hyperemia and chemosis is present, an infectious conjunctivitis should be considered. Treatment should include cultures and antibiotic (quinolone) drops.

Some patients may have a giant papillary conjunctivitis, which may require steroid and antihistamine drops. The artificial eye should be removed in the night and washed in soft contact lens daily cleaner and denture cleaning products.

7.1.2. Pain

Pain after eye removal is difficult to handle. If the prosthesis is correctly fit in the orbit, the conjunctiva should be checked for any signs of inflammation or infection. If the implant migrates anteriorly, it can compress the tissue and hurt. Pain may have its origin in the trochlea. This can be examined by pressing on this zone. If the pain resembles that experienced by the patient, triamcinolone injection in the trochlea can be effective [52]. Other causes of pain may be amputation neuroma, sinus inflammation, tumor, depression, or secondary gain [53].

7.1.3. Orbital cysts

They manifest as pain or pressure sensation or even only increased difficulty to fit the artificial eye. Cysts may grow if conjunctival epithelium is incarcerated after wound closure or when there is epithelial ingrowth in wound dehiscence [54]. Management options are complete surgical excision, marsupialization, absolute alcohol injection, or trichloroacetic acid (TCA) injection [55].

7.1.4. Lower eyelid malposition

When the eye is enucleated, the disruption of the fibrous framework of the orbit may result in the rotation of the orbital contents inferiorly and anteriorly. This will shallow the inferior fornix and tilt the prosthesis. The inferior portion of the prosthesis pushes on the inferior eyelid, while the superior portion moves posteriorly inside the orbit, deepening the superior sulcus. Both of these two features are part of the anophthalmic socket syndrome, which includes an upper eyelid ptosis, a deep superior sulcus, an enophthalmos, a lower eyelid malposition, and a fornix retraction. With time, the lower eyelid becomes more lax, especially when heavier prosthesis is fitted. This enhances the inferior migration of orbital tissues. The final result is a poorly fitting artificial eye, lower eyelid malposition, shortening of the inferior fornix, and deepening of the superior sulcus. In older patients, the laxity of the inferior eyelid increases, especially when wearing a prosthesis even if it is not heavy.

7.2. Eyelash misdirection and entropion

Several situations are responsible for eyelash misdirection. Fornix contracture is one of the most common due to the trauma of surgery of the eye removal or contracture as a result of chemical burn. Sometimes the contracture of the fornix is result of the contracture of the conjunctiva as a result of chronic inflammation. Lower eyelid laxity can also produce eyelash misdirection. In order to correct eyelash misdirection, there are a series of options depending on the underlying cause. When laxity of the eyelid is present, lateral canthoplasty can be a good option. A transverse tarsal incision with marginal rotation is a simple way to change the direction of the eyelashes. If there is a shallow fornix, a silicone band to reform the fornix is a suitable option, but if there is a moderate to severe contraction of the fornix, fornix deepening will require grafts that may be harvested from the hard palate, ear cartilage, or contralateral upper lid tarsus.

7.2.1. Ectropion

It is normally associated to lower eyelid laxity with aging in normal anophthalmic sockets. Heavy prosthesis or frequent removal of the artificial eye will result in premature ectropion, sometimes in very young patients. If the enucleation was due to orbital and eye trauma, skin scars can precipitate the apparition of ectropion. When ectropion is due to eyelid laxity, lateral tarsal strip is a good and a simple surgical option that offers good results. Heavy prosthesis should be changed for lighter ones. Anterior lamella contraction should be treated with skin or skin and muscle grafts and may benefit from lateral canthopexy procedures to tighten the eyelid.

7.2.2. Ptosis

Ptosis in an anophthalmic socket is sometimes difficult to manage. Too small or too big implants, migration of the implant, levator traumatic damage, trauma from a poorly fitted prosthesis, trauma from the original injury, or levator aponeurosis dehiscence from the tarsal plate can end in upper eyelid ptosis. If the implant is too small, it can be replaced for a bigger one or volume can be increased with a dermis-fat graft. When the implant migrates inferior and anteriorly, it can be repositioned superior and posteriorly with a subperiosteal implant. Once the other factors have been considered and corrected if possible, a levator aponeurosis advancement can be achieved through an anterior approach. The anterior approach will preserve the conjunctiva from potentially contract and helps to create a symmetric eyelid crease.

7.2.3. Deep superior sulcus and enophthalmos

Soft tissue and volume changes in the socket after enucleation or evisceration are responsible of upper lid ptosis and lower lid laxity but also deepening of the superior sulcus. Even when the initial surgical result may be satisfactory, with time, the implant may migrate inferior and anteriorly, deepening the superior sulcus and making the eye socket look sunken or enophthalmic. Conservative management may include alterations in the prosthesis or wearing glasses to camouflage the superior sulcus. Best results should be expected with surgery. Volume augmentation with orbital floor implant placement is the first step, followed by superior sulcus fat grafting and lower lid tightening. The last surgical procedure will be ptosis repair.

Orbital floor implants placed subperiosteally are indicated if the implant is of adequate size and in position. Different materials such as acrylic (polymethylmethacrylate), bone grafts, hydroxyapatite, autogenous fat, injectable hydroxyapatite, dermis-fat grafts, and others have been used. Polymethylmethacrylate is a well-tolerated material placed subperiosteally using a swinging eyelid technique. This implant displaces the orbital implant and surrounding connective tissue and fat anterior and superiorly, thus reducing the sunken superior sulcus. If there is a residual defect after this surgery or when the defect of the superior sulcus is mild or when the patients rejects the placement of a subperiosteal implant, the superior sulcus can be filled with a dermis-fat graft or with an autologous fat graft or a dermal filler such as hyaluronic acid [56]

7.2.4. *Implant exposure or extrusion*

They are the most frequent complications reported in the literature. They can happen with any kind of implant and at any time. There are many factors involved, including incorrect closure of the wound, infections, implant too large for the socket, bad prosthesis adaptation, or delayed fibrovascular ingrowth.

Exposures in the first 3 months after the surgery are probably due to poor wound healing or surgical closure or incorrect position of the orbital implant. Once again, we would like to highlight the importance of a correct tension-free closure of Tenon's layer. Exposures occurring 3 months to 1 year after surgery can be due to the factors previously reported and others like infection or inflammatory response. When exposures occur beyond the first 2 years, they are usually due to mechanical factors such as friction or pressure from the prosthesis [57].

If a nonporous implant exposition is acute and not too big, it can be solved with prompt medical or surgical treatment, but when the exposition is big (more than 3 mm) or long lasting (4 months or more), it usually leads to implant extrusion and, therefore, to its removal. On the other hand, exposed porous implants generally do not extrude because of their fibrovascular anchorage in the socket [58]. Although some porous implants can expose 10 years after surgery, most of the exposures take place within the first year after the surgery. As mentioned above, the use of materials that cover porous implants is an attempt to reduce implant exposition when the surface of the implant is rough enough to rub and tear the conjunctiva. However, Suter et al. [59] have suggested that this kind of material could produce the contrary effect as it would act as a barrier to fibrovascular ingrowth. Kamai et al. [60] used 20% autologous serum when there was conjunctival postoperative dehiscence and necrosis with good results. They recommend to put a drop at least 10 times a day. They observed that the healing occurred after 2 weeks of autologous serum use, preventing the exposure of the implant. Quaranta-Leoni et al. [61] found the presence of Gram-positive cocci infection in 59% of the patients in a group of 25 people when the porous orbital implants were exposed requiring explantation. A histopathological examination showed the presence of a chronic inflammatory infiltrate in 22 implants (88%) and significantly reduced fibrovascular ingrowth of the implant in all patients. They considered a good surgical option the implantation of a dermis-fat graft in the socket once explanted the implant in order to address the volume deficit following implant removal.

There are many surgical options to treat exposed implants: scleral patch grafts [62], mucous membrane grafts [63], temporalis fascia grafts [64], conjunctival pedicle grafts [65], and dermis-fat grafts [66]. Chu et al. [67] proposed a triple layer to treat exposed implants: donor sclera, muscle flaps, and oral mucosa.

7.2.5. *Socket contracture*

The patient will complain that the prosthesis keeps falling out of the socket. Acquired socket contraction is the consequence of shrinkage and shortening of some or all of the tissues of the anophthalmic orbit; thus, the fornices are not able to retain the prosthesis. In order to prevent it, it is mandatory to carry out a straightforward enucleation or evisceration surgery that is, taking care to keep trauma to the conjunctiva, connective tissue, and orbital at minimum levels.

Fornices should not be undermined, and cauterization should be minimized by using gauzes soaked in freezing water and using the bipolar cautery with low energy levels. The conformer should be fit in the socket once the surgery is finished and kept in place until a nondefinite artificial eye is fitted [68]. The more surgeries a socket undergoes, the bigger the risk of developing a socket contracture. In order to simplify its management, we can classify it into the following:

Mild socket contracture. When the posterior lamella shortens, the lashes rotate inward and entropion develops. There is a decrease of the inferior fornix causing a prolapse of the inferior pole of the prosthesis. A transverse tarsal incision with marginal rotation is the initial treatment of choice [69]. There is usually a lower eyelid horizontal laxity too. When there is enough conjunctiva, a lateral canthal tendon procedure associated to a fornix reformation procedure should be performed. The fornix is reformed using 3-0 or 4-0 polyglactin sutures anchored to the periorbital skin and tied over a bolster [70]. However, if there is a lower lid contraction, a posterior lamella lengthening procedure is the best option. Several autogenous spacer grafts have been used: fascia lata, oral mucosa [71], nasal cartilage, hard palate, upper eyelid tarsus, or auricular cartilage [72]. Auricular cartilage is easy to harvest, provides support for the artificial eye, lengthens the posterior lamella, and prevents forward tilt of the prosthesis [73]. Oral mucosa is an excellent option to increase the mucous surface but lacks supportive properties.

Moderate socket contracture. One or both of the fornices are contracted. Typically, the first to contract is the inferior fornix. When the superior fornix contracts, the artificial eye may be retained but the eyelid excursion may be very limited. The gold standard for the treatment of moderate socket contracture is mucous membrane grafting, usually obtained from oral (lip) or buccal (cheek) mucosa [74,75]. Grafts undergo shrinkage with time, so a graft harvested 40% bigger than the defect is recommended. The conjunctiva is undermined, and the graft is sutured with absorbable 7-0 interrupted sutures. A retinal band can be used to reform the inferior and upper fornices, anchoring it to the periorbital skin with bolsters. Then a conformer is placed. Amniotic membrane has also been used as a graft with good results.

If the patient has a socket volume deficiency associated to the socket contracture, the patient will improve with a dermis-fat graft [76], increasing the orbital volume and the conjunctival surface area.

Severe socket contracture. The conjunctival fornices are nearly or completely obliterated, and the prosthesis may fall constantly or give the patient a “staring” appearance. It is frequent to have discharge and irritation or even an active inflammation. The goal of the surgery is to make the patient comfortable and have a good cosmesis. The patient may need to undergo several surgeries with buccal mucosa grafts and flaps from temporalis muscle or radial forearm. When results are very poor, some patients may benefit from an exenteration procedure, which may improve the aesthetics and the comfort of the socket.

Patients underwent exenteration.

7.3. Exenterated orbit

7.3.1. Sino-orbital fistula

Its frequency has been reported to be as high as 68% [77] and as low as 28% [78]. It is more common when the orbit is left to granulate rather than when a skin graft is used. The majority affect the ethmoid sinus. Risk factors are surgical trauma to the ethmoid or lacrimal bones, sinus disease, radiotherapy, and immunocompromised. They can lead to ethmoidal sinusitis. Management ranges from conservative socket hygiene to surgical repair with flaps or grafts, but it is not unusual for the fistula to recur [79].

7.3.2. Chronic discharge

Once healed, if the socket has a sino-orbital fistula, pus from the ethmoid sinus can drain to the orbit when sinusitis is present. In these cases, systemic antibiotics like third-generation cephalosporin twice daily for 14 days may be enough. If medical treatment is not curative, the patient may be referred to the head and neck surgeon in order to program the patient for endoscopic sinus drainage surgery.

The skin coating the orbit will need to be cleaned with soap and water, just as any other part of the body. Sometimes patients are reticent to let anyone do this for them and it is relatively frequent to find dirty skin in the orbit.

7.3.3. Cerebrospinal fluid leak

A cerebrospinal fluid (CSF) leak may lead to meningitis, delayed cerebral abscess, seizures, CSF hypotension with position-dependent headache syndrome, occult hemorrhage, and even death [80]. The incidence reported by an Australian team was 0.6% [81]. However, it can be as high as 29% [82]. Interestingly, the intraoperative use of monopolar cautery in areas of thin orbital bone may contribute to the incidence of CSF leaks [83]. Once you detect clear liquid leaking from the bone in areas of high risk of encountering dura, prompt treatment usually ends in good results. It is very advisable to consult the neurosurgery team. A dural laceration can be sutured with 5-0 or 6-0 polyglactin or nylon to create a watertight seal. If the defect is large, an autologous graft (fat, temporalis muscle or fascia, and pericranium) and a tissue adhesive such as human fibrinogen and bovine thrombin or cyanoacrylate [84] can be used. In smaller defects, tissue adhesives may be enough to seal the leak. Additional materials used in the repair of CSF leaks at other sites include the use of gelfoam® in epidural blood patches. At the end, packing material can be placed in the socket to hold the plug of muscle or fascia against the defect and therefore protect from further leakage. After surgery, the patient must avoid blowing his or her nose and coughing as well as physical activity. Acetazolamide is used to reduce the production of CSF in order to treat CSF leaks. Some authors use systemic antibiotics when there is an intraoperative leak of CSF, but many believe they are unnecessary to prevent meningitis [85].

7.3.4. *Delayed healing*

The orbital defect left to heal spontaneously once exenterated will granulate slowly if allowed only to grow from the orbital rim, and it will heal faster when it heals from spared eyelids. Nevertheless, this will take at least 2-3 months more than when the defect is covered by a temporalis muscle transposition [86], dermis-fat graft (in subtotal exenteration), or split skin graft [87]. Healing by granulation has shorter operating room time and allows for better clinical monitoring of recurrence. However, it requires frequent visits to change the dressings [88], every week and sometimes every 2 or 3 days, and may delay other therapeutic procedures such as radiotherapy. Depending on how the granulation process is developing, dressings may need to be associated to hydrogel mesh or silver mesh. Orbital obliteration with temporalis muscle or a graft may induce less pain, improve personal hygiene, and reduce the risk of sino-orbital fistula, but it requires image techniques such as MRI, CT, or PET to detect local recurrences.

7.3.5. *Tumor recurrence*

Tumor recurrence following orbital exenteration can occur in 24-45% of cases [82,89]. Early detection of tumor recurrence in patients who have undergone orbital exenteration is very important. This task is relatively easy when the orbit was left to granulate, but it is difficult when the normal anatomical landmarks have been lost (like when exenteration is associated to ethmoidectomy), and there are flaps covering large cavities. Recurrent tumors may appear as soft tissue similar to the primary tumor, especially in the first 2 years of the surgery (65% of the cases) and in the margin of the flap [90]. Lee et al. recommend to follow this patients with frequent MRI, at least every 4 months after surgery for the 2 first years and every 6 months for 3 more years. On MRI, recurrences appear on the margin of the flap and are often T2 isointense, as opposed to the hyperintense appearance described in normal flaps. PET has also been used to help to differentiate recurrence from scarring or radiation-associated tissue changes.

8. Conclusions

The removal of the eye in any surgical variants (enucleation, evisceration, and exenteration) requires a careful and thorough planning process. A detailed patient explanation of the causes that have led to this type of surgery is mandatory as a breakdown of the consequences of the operation. These explanations should be extended to the family as the immediate aesthetic impact not only affects the patient. Once the most appropriate surgical technique has been chosen, it should be planned in detail beforehand, including potential needs for collaboration with other surgical specialties such as plastic surgery, maxillofacial surgery, neurosurgery, or otolaryngology. It is also important to have the support of anesthesiology for good intraoperative monitoring of the patient. The surgical procedure must be done with thoroughness and patience since the surgical time is long in many cases, and rigorous performance of the surgical steps is one factor that decreases the rate of complications. In cases where an implant is

required, this can be carried out in a primary or secondary way. The advantages and disadvantages of different types of implants and the use of wrapping material is widely discussed with the patient. It is important to emphasize the patient-recovering milestones and possible postoperative complications as well as the need for other secondary surgical techniques, e.g., eyelid surgery. Postoperative follow-up is crucial to detect and treat complications as early as possible. Finally, we would like to stress that collaboration with the ocularist is essential in order to get a good adaptation of the prosthesis and aesthetical patient satisfaction.

Author details

César Hita-Antón¹, Lourdes Jordano-Luna^{2,3} and Rosario Díez-Villalba^{2,3*}

*Address all correspondence to: mdiez.hugf@salud.madrid.org

1 Department of Ophthalmology, Hospital Universitario de Torrejón, Torrejón de Ardoz, Madrid, Spain

2 Department of Ophthalmology Hospital Universitario de Getafe, Getafe, Madrid, Spain

3 Universidad Europea de Madrid, Madrid, Spain

References

- [1] Kübler-Ross E. On Death and Dying. Macmillan New York; 1969.
- [2] Meltzer MA, Schaefer DP, Della Rocca RC. Evisceration. Smith's Ophthalmic Plastic and Reconstructive Surgery. Vol. 2. St. Louis: CV Mosby; 1987. pp. 1300-1307.
- [3] Noyes W. Treatise on Diseases of the Eye. New York: Wodd; 1881. p. 189.
- [4] Mulles PH. Evisceration of the globe, with artificial vitreous. Transactions of the Ophthalmological Societies of the United Kingdom 1885;5:200-206.
- [5] Frost WA. What is the best method of dealing with a lost eye? British Medical Journal 1887;1153.
- [6] Hansen AB, Petersen C, Heegaard S. Review of 1028 bulbar eviscerations and enucleations: changes in etiology and frequency overall 20 year period. Acta Ophthalmologica Scandinavica. 1999;77:331-335.
- [7] Levine MR, Pou CR, Lash RH. Evisceration: is sympathetic ophthalmia a concern in the new millennium? Ophthalmic Plastic and Reconstructive Surgery 1999;15:4.

- [8] Alino AM, Perry HD, Kanellopoulos AS, Donnenfeld ED, Rahn EK. Conjunctival flaps. *Ophthalmology* 1998;105:1120-3.
- [9] Massry GG, Holds JB. Evisceration with scleral modification. *Ophthalmic Plastic and Reconstructive Surgery* 2001;17:42-47.
- [10] Ozgur OR, Levent A, Dogan OK. Primary implant placement with evisceration in patients with endophthalmitis. *American Journal of Ophthalmology* 2007;143:902-904.
- [11] Nassab Rs, Thomas SS, Murray D. Orbital exenteration for advanced periorbital skin cancers. 20 years of experience. *Journal of Plastic, Reconstructive and Aesthetic Surgery* 2007;60:1103-1109.
- [12] Levin PS, Dutton JJ. A 20 years series orbital exenteration. *American Journal of Ophthalmology* 1991;112:496-501.
- [13] Collins GL, Nickoonahand N, Morgan MB. Changing demographics and pathology of non-melanoma skin cancer in the last 30 years. *Seminars in Cutaneous Medicine and Surgery* 2004;23(1):80-83.
- [14] Nerad JA. Enucleation, evisceration, and exenteration. The care of the eye socket. In: Nerad JA (Ed.), *Techniques in Ophthalmic Plastic Surgery*. Elsevier. pp. 463-486.
- [15] Sales-Sanz M, Sanz-Lopez A. Four-petal evisceration: a new technique. *Ophthalmic Plastic and Reconstructive Surgery* 2007;23(5):389-392.
- [16] Jordan DR, Klapper SR. Enucleation, evisceration, secondary orbital implantation. In: Black E, Nesi F, Calvano C, Gladstone G, Levine M (Eds). *Smith and Nesi's Ophthalmic Plastic and Reconstructive Surgery*. New York: Springer; 2011. pp. 1105-1130.
- [17] Yeatts R. The esthetics of orbital exenteration. *American Journal of Ophthalmology* 2005;139:152-153.
- [18] Spiegel J, Varvares M. Prevention of postexenteration complications by obliteration of the orbital cavity. *Skull Base* 2007;17:197-203.
- [19] Soll DB. Donor sclera in enucleation surgery. *Archives of Ophthalmology* 1974;92:494-495.
- [20] Chalasani R, Poole-Warren L, Conway RM, Ben-Nissan B. Porous orbital implants in enucleation: a systematic review. *Survey of Ophthalmology* 2007;52:145-155.
- [21] Smit TJ, Koorneef L, Zonneveld FW, Groet E, Otto AJ. Primary and secondary implants in the anophthalmic orbit. Preoperative and postoperative computed tomographic appearance. *Ophthalmology* 1991;98:106-110.
- [22] Sami D, Young S, Petersen S. Perspective on orbital enucleation implants. *Survey of Ophthalmology* 52:244-265, 2007.

- [23] Smit TJ, Koornneef L, Zonneveld FW, Groet E, Otto AJ. Computed tomography in the assessment of the postenucleation socket syndrome. *Ophthalmology* 1990;97:1347-1351.
- [24] Kaltreider SA, Jacobs JL, Hughes MO. A simple algorithm for selection of implant size for enucleation and evisceration. *Ophthalmic Plastic and Reconstructive Surgery* 2002;18:336-42.
- [25] Thaller VT. Enucleation volume measurement. *Ophthalmic Plastic and Reconstructive Surgery* 1997;13:18-20.
- [26] Tyers AG, Collin JR. Orbital implants and post enucleation socket syndrome. *Transactions of the Ophthalmological Societies of the United Kingdom* 1982;102:90-92.
- [27] Moshfeghi DM, Moshfeghi AA, Finger PT. Enucleation. *Survey of Ophthalmology* 2000;44:277-301.
- [28] Beard C. Remarks on historical and newer approaches to orbital implants. *Ophthalmic Plastic and Reconstructive Surgery* 1995;11:89-90.
- [29] Mourits DL, Hartong DT, Moll AC, Mourits MP. Management of porous orbital implants requiring explantation: a clinical and histopathology study. *Letters to the Editor. Ophthalmic Plastic and Reconstructive Surgery* 2014;30:528.
- [30] Ferrone PJ, Dutton JJ. Rate of vascularization of coralline hydroxyapatite ocular implants. *Ophthalmology* 1992;99:376-379.
- [31] Su GW, Yen MT. Current trends in managing the anophthalmic socket after primary enucleation and evisceration. *Ophthalmic Plastic and Reconstructive Surgery* 2004;20:274-280.
- [32] Jamell GA, Hollsten DA, Hawes MJ, et al. Magnetic resonance imaging versus bone scan for assessment of vascularization of the hydroxyapatite orbital implant. *Ophthalmic Plastic and Reconstructive Surgery* 1996;12:127-130.
- [33] Klapper SR, Jordan D, Punja K, et al. Hydroxyapatite implant wrapping materials: analysis of fibrovascular ingrowth in an animal model. *Ophthalmic Plastic and Reconstructive Surgery* 2000;16:278-85.
- [34] Qi-hua X, Chen Z, Jian-gang Z, Da-zhong Z, Yong-qiang Z. Comparison of contrast-enhanced ultrasonography and contrast-enhanced MRI for the assessment of vascularization of hydroxyapatite orbital implants. *Clinical Imaging* 2014;38:616-620.
- [35] Dutton JJ. Advances and controversies in ophthalmic plastic surgery: enucleation and evisceration. The 1998 American Academy of Ophthalmology Annual Meeting, New Orleans, LA, November 10, 1998.
- [36] Jordan DR, Chan S, Mawn L, Gilbert S, Dean T, Brownstein S, Hill VE. Complications associated with pegging hydroxyapatite orbital implants. *Ophthalmology* 1999;106:505-512.

- [37] Karcioglu ZA, Al-Ghamdi H, Al-Bateri A, Rostem A. Radiation absorption properties of orbital implants. *Orbit* 1998;17:161-167.
- [38] Arora V, Weeks K, Halperin EC, Dutton JJ. Influence of coralline hydroxyapatite used as an ocular implant on the dose distribution of external beam photon radiation therapy. *Ophthalmology* 1992;99:380-382.
- [39] Karesh JW, Dresner SC. High-density porous polyethylene (MEDPOR) as a successful anophthalmic socket implant. *Ophthalmology* 1994;101:1688-1695, discussion 1695-1696.
- [40] Warder D, Kratky V. Fixation of extraocular muscles to porous orbital implants using 2-octyl-cyanoacrylate glue. *Ophthalmic Plastic and Reconstructive Surgery* 2014; Oct 10. [Epub ahead of print].
- [41] Shore JW. Porous polyethylene orbital implants. The 18 American Academy of Ophthalmology Annual, New Orleans, LA, November 10, 1998.
- [42] Timoney PJ, Clark JD, Frederick PA, Krakauner M, Compton C, Horbinski C, Sokol J, Nunery WR. Foreign body granuloma following orbital reconstruction with porous polyethylene. *Ophthalmic Plastic and Reconstructive Surgery* 2014; Nov 12. [Epub ahead of print].
- [43] Naugle TC, Lee AM, Halk BG, Callahan MA. Wrapping hydroxyapatite orbital implants with posterior auricular muscle complex grafts. *American Journal of Ophthalmology* 199;128:495-501.
- [44] Quarante-Leoni FM, Sposanto S, Lorenzano D. Secondary orbital ball implants after enucleation evisceration: surgical management, morbidity, and long-term outcome. *Ophthalmic Plastic and Reconstructive Surgery* 2014 Jul 14. [Epub ahead of print].
- [45] Farkas LG, Posnick JC, Hreczko TM, Pron GE. Growth patterns in the orbital region: a morphometric study. *Cleft Palate-Craniofacial Journal* 1992;29:315-318.
- [46] Chen D, Heher K. Management of the anophthalmic socket in pediatric patients. *Current Opinion in Ophthalmology* 2004;15:449-453.
- [47] Furuta M. Measurement of orbital volume by computed tomography: especially on the growth of the orbit. *Japanese Journal of Ophthalmology* 200;104:724-728.
- [48] Katowitz JA. Orbital expansion with dermis-fat graft in the pediatric age group. Presented at the annual meeting of the American Academy of Ophthalmology, Anaheim, California, October 14, 1991.
- [49] Shah SU, Shields CL, Lally SE, Shields JA. Hydroxyapatite orbital implant in children following enucleation: analysis of 531 sockets. *Ophthalmic Plastic and Reconstructive Surgery* 2014; Jun 3. [Epub ahead of print].
- [50] Larned DC. Lacrimal mechanics in the enucleated state. *Ophthalmic Plastic and Reconstructive Surgery* 1992;8:202-207.

- [51] Vasquez RJ, Lindberg JV. The anophthalmic socket and prosthetic eye: a clinical and bacteriological study. *Ophthalmic Plastic and Reconstructive Surgery* 1989;5:277-280.
- [52] Jordan DR. Experience with 130 synthetic hydroxyapatite implants (FCI3). *Ophthalmic Plastic and Reconstructive Surgery* 2001;17 (3):184-190.
- [53] Jordan DR, Brownstein S, Dorey MW. Clinicopathologic analysis of 15 explanted hydroxyapatite implants. *Ophthalmic Plastic and Reconstructive Surgery* 2004;20(4): 285-290.
- [54] McCarthy RW, Beyer CK, Dallow, et al. Conjunctival cysts of the orbit following enucleation. *Ophthalmology* 1981;88:30-35.
- [55] Sanchez EM, Formento NA, Peres-Lopez M, Jimenez AA. Role of trichloroacetic acid in treating posterior conjunctival cystin anophthalmic socket. *Orbit* 2009;28:101-103.
- [56] Morley AMS, Taban M, Malhorta R, Goldberg R. Use of hyaluronic acid gel for upper eyelid filling and contouring. *Ophthalmic Plastic and Reconstructive Surgery* 2009;25:440-444.
- [57] Jordan DR, Klapper SR, Gilberg SM, Dutton JJ, Wong A, Mawn L. The bioceramic implant: evaluation of implant exposures in 419 implants. *Ophthalmic Plastic and Reconstructive Surgery* 2010;26;80-82.
- [58] Custer PL, Kennedy RH, Woog JJ, Kaltreider SA, Meyer DR. Orbital implants in enucleation surgery. A report by the American Academy of Ophthalmology. *Ophthalmology* 2003;110:2054-2061.
- [59] Suter AJ, Molteno AC, Bevin TH, Fulton JD, Herbison P. Long term follow up of bone derived hydroxyapatite orbital implants. *British Journal of Ophthalmology* 2002;86:1287-1292.
- [60] Kamai S, Kumar S, Goer R. Autologous serum for anterior tissue necrosis after porous orbital implant. *Middle East African Journal of Ophthalmology* 2014;21:193-195.
- [61] Quarante-Leoni FM, Moretti C, Sposanto S, Nardoni S, Lambiase A, Bonini S. Management of porous orbital implants requiring explantation: a clinical and histopathological study. *Ophthalmic Plastic and Reconstructive Surgery* 2014;30:132-136.
- [62] Inkster CF, Ng SG, Leatherbarrow B Primary banked scleral patch graft in the prevention of exposure of hydroxyapatite orbital implants. *Ophthalmology* 2002;109:389-392.
- [63] Lee-Wing MW. Amniotic membrane for repair of exposed hydroxyapatite orbital implant. *Ophthalmic Plastic and Reconstructive Surgery* 2003;19:401-402.
- [64] Sagoo MS, Olver JM. Autogenous temporalis fascia patch graft for porous polyethylene (MEDPOR) sphere orbital implant exposure. *British Journal of Ophthalmology* 2004;88:942-946.

- [65] Lu L, Shi W, Luo M, Sun Y, Fan X. Repair of exposed hydroxyapatite orbital implants by subconjunctival tissue flaps. *Journal of Craniofacial Surgery* 2011;22:1452-1456.
- [66] Lee BJ, Lewis CD, Perry JD. Exposed porous orbital implants treated with simultaneous secondary implant and dermis fat graft. *Ophthalmic Plastic and Reconstructive Surgery* 2010;26:273-276.
- [67] Chu HY, Liao YL, Tsai YJ, Chu YC, Wu SY, Ma L. Use of extraocular muscle flaps in the correction of orbital implant exposure. *PLoS One*. 2013 Sep 25;8(9):e72223. doi: 10.1371/journal.pone.0072223. eCollection 2013.
- [68] Tawfik HA, Raslan AO, Talib N. Surgical management of acquired socket contraction. *Current Opinion in Ophthalmology* 2009;20:406-11.
- [69] Kersten RC, Kleiner FP, Kulwin DR. Tarsotomy for the treatment of cicatricial entropion with trichiasis. *Archives of Ophthalmology* 1992;110:714-7.
- [70] Ma'luf RN. Correction of the inadequate lower fornix in the anophthalmic socket. *British Journal of Ophthalmology* 1999;83:881-2.
- [71] Molgat YM, Hurwitz JJ, Webb MC. Buccal mucous membrane fat graft in the management of the contracted socket. *Ophthalmic Plastic and Reconstructive Surgery* 1993;9:267-72.
- [72] Jackson IT, Dubin B, Harris J. Use of contoured and stabilized conchal cartilage grafts for lower eyelid support: a preliminary report. *Plastic and Reconstructive Surgery* 1989;83:636-40.
- [73] Smith RJ, Malet T. Auricular cartilage grafting to correct lower conjunctival fornix retraction and eyelid malposition in anophthalmic patients. *Ophthalmic Plastic and Reconstructive Surgery* 2008;24(1):13-8.
- [74] Klein M, Mennekin H, Bier J. Reconstruction of the contracted ocular socket with free full thickness mucous membrane graft. *International Journal of Oral and Maxillofacial Surgery* 2000;29:96-8.
- [75] Bowen EJ, Nunes E. The outcome of oral mucosal grafts to the orbit: a three and a half year study. *British Journal of Plastic Surgery* 2002;55:100-4.
- [76] Betharia SM, Patil ND. Dermis fat grafting in contracted sockets. *Indian Journal of Ophthalmology* 1988;36:110-2.
- [77] Mohr C, Esser J. Orbital exenteration: surgical and reconstructive strategies. *Graefe's Archive for Clinical and Experimental Ophthalmology* 1997;235:288-95.
- [78] Rahman I, Cook AE, Leatherbarrow B. Orbital exenteration: a 13 year Manchester experience. *British Journal of Ophthalmology* 2005;89:1335-40.
- [79] Limawararut V, Leibovitch I, Davis G, Rees G, Goldberg R, Selva D. Sino-orbital fistula: a complication of exenteration. *Ophthalmology* 2007;114(2):355-361.

- [80] Ebersold M. Five things oculoplastic surgeons should know about neurosurgery. *Ophthalmic Plastic and Reconstructive Surgery* 2000;16:247-9.
- [81] Limawararut V, Valenzuela AA, Sullivan TJ, McNab AA, Malhotra R, Davis G, Jones N, Selva D. Cerebrospinal fluid leaks in orbital and lacrimal surgery. *Survey in Ophthalmology*. 2008;53(3):274-284.
- [82] Kuo CH, Gao K, Clifford A, Shannon K, Clark J. Orbital exenterations: an 18-year experience from a single head and neck unit. *ANZ Journal of Surgery* 2011 May;81(5):326-30.
- [83] Wulc AE, Adams JL, Dryden RM. Cerebrospinal fluid leakage complicating orbital exenteration. *Archives of Ophthalmology* 1989;107:827-30.
- [84] Tse DT, Panje WR, Anderson RL. Cyanoacrylate adhesive used to stop CSF leaks during orbital surgery. *Archives of Ophthalmology* 1984;102:1337-9.
- [85] Yilmazlar S, Arslan E, Kocaeli H, et al. Cerebrospinal fluid leakage complicating skull base fractures: analysis of 81 cases. *Neurosurgical Review* 2006;29:64-71.
- [86] Reese AB, Jones IS. Exenteration of the orbit and repair by transplantation of the temporalis fascia. *American Journal of Ophthalmology* 1961;51:217-27.
- [87] Harting F, Koorneef L, Peeters HJ, Gillissen JP. Glued fixation of split-skin graft to the bony orbit following exenteration. *Plastic and Reconstructive Surgery* 1985;76:633-5.
- [88] Putterman A. Orbital exenteration with spontaneous granulation. *Archives of Ophthalmology* 1986;104:139-40.
- [89] Nemet AY, Martin P, Bengier R, et al. Orbital exenteration: a 15-year study of 38 cases. *Ophthalmic Plastic and Reconstructive Surgery* 2007;23:468-72.
- [90] Lee PS, Sedrak P, Guha-Thakurta N, Chang EI, Ginsberg LE, Esmaeli B, Debnam JM. Imaging findings of recurrent tumors after orbital exenteration and free flap reconstruction. *Ophthalmic Plastic and Reconstructive Surgery* 2014 Jul-Aug;30(4):315-21.