

We are IntechOpen, the world's leading publisher of Open Access books Built by scientists, for scientists

6,900

Open access books available

185,000

International authors and editors

200M

Downloads

Our authors are among the

154

Countries delivered to

TOP 1%

most cited scientists

12.2%

Contributors from top 500 universities



WEB OF SCIENCE™

Selection of our books indexed in the Book Citation Index
in Web of Science™ Core Collection (BKCI)

Interested in publishing with us?
Contact book.department@intechopen.com

Numbers displayed above are based on latest data collected.
For more information visit www.intechopen.com



Surgical Treatment in Diffuse Coronary Artery Disease

Kaan Kırallı and Yücel Özen

Additional information is available at the end of the chapter

<http://dx.doi.org/10.5772/61514>

Abstract

Diffuse coronary artery atherosclerosis can be defined as “consecutive or longitudinal” and “complete or partial” obstruction in coronary vessels. Most of the patients with diabetes, hyperlipidemia, chronic renal insufficiency, connective tissue disease, and multistented coronary arteries have diffuse atherosclerotic lesions in the coronary territory. Viable large myocardium without necrosis is the only coronary bypass indication in these patients, because it is very difficult to find any healthy area for anastomosis. This type of coronary occlusion frequently stimulates the formation of collateral vessels that protect against extensive myocardial ischemia. The choice of a surgical method also depends on the nature of the coronary artery, and multisegment plaques and healthy-area intervals simplify complete revascularization. On the other hand, a more aggressive treatment modality should be preferred when no soft site can be identified for arteriotomy or there is an extensively diseased area that is not amenable to grafting. The less invasive techniques are “don’t touch the plaque” techniques (jumping multi-bypass, sequential bypass, hybrid interventions). Sometimes an aggressive diffuse plaque formation needs to be treated with “touch the plaque” techniques (long-segment anastomosis, patch-plasty, endarterectomy \pm patch-plasty). In simple forms, a limited long-segment anastomosis of conduits eliminates the occlusion of the limited atherosclerotic plaque where the whole lesion is opened and cross-covered by the graft. In the accelerated form of coronary arteriosclerosis, the atherosclerotic plaque appears widespread and the full-length lumen of the coronary artery can get very narrow or occluded totally. The long-segment lesion is usually calcified and it inhibits any kind of stitching; however, the plaque can be separated easily from the arterial wall in order to create an appropriate lumen in the total occluded coronary artery. Because the aggressive endarterectomy increases the operation risk, the arteriotomy should be extended until the normal lumen with normal intima in the distal segment of the coronary artery. In general, severity and distribution of coronary arteriosclerosis tend to increase with time but the rate of increase is highly variable and difficult to predict. Although diffuse atherosclerosis is severe enough, it is uncommon to render any patient unsuitable for surgery.

Keywords: Diffuse atherosclerosis, endarterectomy, patch-plasty, sequential bypass, jumping bypass

1. Introduction

Coronary artery disease usually involves the proximal portion of the larger epicardial coronary arteries, but generally not their intramural branches. In most patients, atherosclerotic lesions in coronary territory are segmental and eccentric, and they affect particularly bifurcations and sharp curvatures, whereas the rest of long segments of coronary arteries are plaque-free. Diffuse coronary artery disease can be defined as the presence of multiple atherosclerotic stenoses or long-segment occlusions in coronary territory. Atheromatous materials spread toward distal and retain a long segment of coronary arteries which can obstruct coronary lumen “consecutive or longitudinal” and “complete or partial”.

In general, severity and distribution of coronary arteriosclerosis tend to increase with time but the rate of increase is highly variable and difficult to predict. Diffuse atherosclerosis severe enough to render the patient unsuitable for surgery is uncommon. On the other hand, progression of atherosclerosis in the native coronary arteries after coronary bypass surgery is not rare and accelerated atherosclerosis usually is the main contraindication for reoperation. The early and late results of endarterectomy are inferior to those of routine coronary bypass, but it offers a viable alternative not to leaving a territory ungrafted. Rate of aggressive progression of atherosclerosis cannot as yet be examined directly in multivariable risk factor analyses, but this progression can be slowed by intensive lipid-lowering therapy.

The nature of atherosclerotic coronary artery disease is a chronic inflammation and fibroproliferation of large- and medium-sized epicardial arteries consisting of the progressive deposition or degenerative accumulation of lipid-containing plaques on the innermost layer of the arterial wall. The basic mechanism of atherosclerosis is endothelial dysfunction which is characterized by the reduction of the endothelium-derived vasodilators, especially nitric oxide, and an increase in endothelium-derived contracting factors. The immune-inflammatory response involving macrophages, T-lymphocytes and intimal smooth muscle cells tries healing and repairing injured endothelium, stabilizing plaques, protecting rupture, and avoiding thrombosis. If the atherosclerotic stimuli persist over long time, the reparative response may accelerate and target to the progressive occlusion of the arterial lumen. Progressive diffuse coronary artery stenosis involves the following processes: local atheroma, lipid accumulation, biologic stimuli of vessel wall, chronic inflammation, cellular necrosis, plaque formation and complications, and calcification. Arterial wall injury is most often related to age, diabetes, smoking, dyslipidemia, hypertension, hyperuremia, and immunosuppressive therapy, which trigger and accelerate the inflammatory response aimed at restoring arterial wall integrity. During the progression of atherosclerosis, endothelial and smooth muscle cells die by apoptosis, and an atheromatous plaque covers the defects of the endothelium. A vulnerable plaque is a nonobstructive, silent coronary lesion, which suddenly becomes obstructive and symptomatic. Plaque rupture with/without thrombotic complications is the main reason for this acute coronary syndrome with/without complications. The lesions responsible for acute episodes are generally less calcified than plaques responsible for chronic stable angina, because calcification is the last part of the healing response to atherosclerosis and it appears to have no direct link to thrombosis. Because diffuse type of coronary disease is time-consuming, slowly

developing occlusions frequently stimulate the formation of collateral vessels that protect myocardium against extensive ischemia. Viable large myocardium without necrosis is the only indication for coronary revascularization in these patients (without mechanical complications of myocardial infarction), because it is very difficult to find any healthy area for anastomosis. Consequently, the relative severity and associated risk balance between focal stenosis and diffuse disease cannot be easily compared when making revascularization decisions [1]. The physiological anatomy of coronary arteries must be detailed for myocardial revascularization, but quantifying the anatomic severity of diffuse lesions is difficult. Lower coronary flow reserve associated with severe diffuse disease may neutralize or override any potential benefit from eliminating stenosis by stents. On the other hand, more diffusely expanded coronary atherosclerosis can cause higher mortality rate during coronary bypass artery grafting (CABG) than focal lesions because of association of more complicated vessels, which are not appropriate for suturing or distal perfusion after anastomosis. Patients with diffuse coronary artery disease can also face a twofold increased risk of in-hospital mortality or major morbidities, which is independent of reoperation [2].

2. Etiology

Most of the patients with diabetes, hyperlipidemia, chronic renal insufficiency, connective tissue disease, heart transplantation, and multi-stented coronary arteries have diffuse atherosclerotic lesions in the coronary territory. All of these diseases affect and accelerate coronary arteriosclerosis differently [3]. Restenosis after first CABG can also be a reason for the diffuse coronary atherosclerosis, but usually these patients have ungraftable diffuse diseased coronary vasculature and none of the specific revascularization methods can be used.

2.1. Diabetes mellitus

Compared with nondiabetic patients, diabetes mellitus increases the incidence of coronary artery disease two to four times as much and accelerates the nature of the atherosclerosis. The nature of coronary artery disease in diabetic patients is clinically challenging because it causes an extensive and diffuse multivessel involvement. Hyperglycemia is directly related to the atherosclerotic development, progression, and instability due to induced endothelial dysfunction (abnormal nitric oxide biology, increased endothelin and angiotensin II, reduced prostacyclin activity), abnormalities in lipid metabolism (high triglyceride and LDL-cholesterol, low HDL-cholesterol), systemic inflammation (increased oxidative stress, accumulation of advanced glycation and products), and disorders in the proteo-fibrinolytic system and platelet biology (thrombosis). Hyperglycemia can deplete the cellular NADPH pool and induce with high levels of fatty acids to oxidative stress on phospholipids and proteins. Insulin resistance is the main actor to the endothelial dysfunction in type II diabetes, and endothelial dysfunction is closely complicated with microangiopathy and atherosclerosis in diabetic patients. Endothelial dysfunction decreases the capacity of nitric oxide synthase enzyme and depleted nitric oxide, which effects endothelial cell-dependent vasodilatation. Overexpression of growth factors causes endothelial cells and vascular smooth muscle proliferation. All of these negative

changes accelerate atherosclerosis in all arterial territories, and the involvement of coronary arteries can be very extensive and diffuse with either serious jumping stenoses or long-segment narrowing with/without occlusion. The optimal strategy of coronary revascularization is controversial, but CABG has better long-term survival and freedom from re-interventions [4]. Diabetic patients have a higher restenosis rate after stent implantation and also progression of diffuse disease after stent implantation forms new lesions in diabetic patients than non-diabetic patients more often. Clinical outcomes in CABG patients are similar for diabetic and non-diabetic patients, while outcomes after stent could be worse for diabetic patients [5]. In diabetic patients with multivessel coronary artery disease, rates of death and myocardial infarction in 5 years are significantly lower in patients treated with CABG due to more complete revascularization, which bypasses several lesions and prevents coronary territory against progressive proximal coronary stenosis [6]. On the other hand, the operative risk in patients with diabetes might be a consequence of a preoperatively endothelial dysfunction and an inflammatory response to extracorporeal circulation characterized by an impaired release of interleukin-6 and increased turnover of E-selectin [7]. Simple distal anastomosis for each coronary artery cannot be enough to supply blood along the coronary territory, and most of the diabetic patients with diffuse multivessel coronary artery disease require specific surgical revascularization modalities, which can increase perioperative myocardial damage and operative mortality.

2.2. Hypercholesterolemia

Cholesterol is one of the most important risk factors for the development of premature coronary artery disease, which is characterized without any serious intravascular stenosis. Cholesterol levels and coronary artery disease show a strong and linear relationship, whereas cholesterol levels even in the normal range may inhibit endothelium-dependent vasodilatation in all arterial beds. The pathogenesis of atherosclerosis in the obese population can be related to metabolic syndrome associated with insulin intolerance and dyslipidemia, which cause endothelial dysfunction with decreasing nitric oxide production. Lowering of LDL-cholesterol rather than moderate weight loss is more effective to improve endothelial function, because the coronary vasculature is affected by the atherosclerosis process, and the most atherosclerotic lesions are associated with remarkable neovascularization of the vasa vasorum, which can cause intra-plaque rupture and bleeding. Hypercholesterolemia is one of the most important factors to stimulate this process and its role begins in the early atherosclerotic remodeling before plaque formation [8]. Hyperlipidemia-related coronary lesions are very predisposed to spread lengthways coronary territory and cause diffuse stenosis or occlusion, and calcification is usually associated with this type of atherosclerosis.

2.3. End-stage renal disease

A strong relationship subsists between chronic renal failure and coronary artery disease, and atherosclerosis can be accelerated in patients with end-stage renal disease due to multifactorial reasons [9]. Increased oxidative stress, hyperhomocysteinemia, hyperlipidemia, hyperglycemia and others are also important comorbidities. The main pathology is the impairment of

endothelium-dependent vasodilatation. Dialysis-dependent renal failure patients undergoing CABG can have a greater degree of distal and/or diffuse coronary artery disease burden compared with matched patients with silent renal failure. The diffuseness of coronary atherosclerosis in patients with end-stage renal disease can be severe and the intraluminal lesions are usually calcified. Extensive calcification of all arterial structures in the body can inhibit conventional CABG strategies, which increase surgical outcomes. Impaired distal run-off of the coronary arteries is another strong independent predictor of operative mortality. All kinds of complex anastomotic techniques can be used in these patients, and endarterectomy can be very easy to perform to get adequate distal run-off. Restenosis after CABG is not uncommon in this group of patients, especially if saphenous vein is used.

2.4. Connective tissue disease

Several connective tissue diseases (systemic lupus erythematosus, rheumatoid arthritis, systemic sclerosis, Takayasu disease) are characterized by vascular dysfunction and excessive fibrosis. The presence of coronary microvascular dysfunction is the common pathologic change in various chronic inflammatory diseases [10]. Cardiac manifestation of these chronic diseases can be estimated lower, because most of them are asymptomatic. Diffuse form of these pathologies has a distressed clinical course with severe organ involvement. First, an endothelial injury occurs early in the disease process leading to endothelial dysfunction. Myofibroblasts drawn into the arterial wall by cellular growth factors contribute to the thickening of the intimal layer, compromising regional blood flow by narrowing the arterial lumen. In the absence of epicardial coronary stenosis, the abnormal coronary flow is dependent on the structural remodeling of the small coronary arteries and arterioles. Aggressive surgical interventions are usually ineffective, but multi-anastomoses can be applicable. Because diffuse atherosclerosis shows strict adhesions between arterial wall layers, endarterectomy can never satisfy to load out the intra-arterial lumen for appropriate anastomosis.

2.5. Heart transplantation

The occurrence of coronary artery disease is common in posttransplant patients, and atherosclerotic process is different from normally occurring coronary artery disease. This type of atherosclerosis is specific for heart transplanted patients, and it affects the entire length of the coronary arteries, and diffuse intimal proliferation develops without damage to the internal elastic lamina in contrast to classic atherosclerosis. The intimal proliferation developed by smooth muscle cells and macrophages contains cholesterol crystals and lipid components, but calcification is rare. This lesion affects large epicardial coronary arteries as well as the penetrating intramyocardial branches, and occlusion of these small branches is the first reason for acute coronary syndrome. Coronary endothelial vasodilator dysfunction is a common and early indicator for graft atherosclerosis, which is caused by both immunological and classic risk factors. The immunological response is the first stimulus causing endothelial damage and this injury alters endothelial permeability, with consequent myointimal hyperplasia and extracellular matrix synthesis. Alloimmune injury starts when donor antigens expressed from the donor endothelial cells interact with recipient dendritic cells, and the activated macro-

phages secrete several factors, which stimulate the proliferation of smooth muscle cells and vascular remodeling [11]. Before microvasculature occlusions, stent or standard CABG can be preferred for the treatment of newly developed epicardial lesions, but endarterectomy may not be usually applicable in most diffuse cases, and retransplantation is the only option under these circumstances.

2.6. Multistented coronary arteries

The problem of restenosis after stenting represents a special case of arterial hyperplastic disease and the in-stent restenosis is made from myxomatous tissue, whereas accelerated intimal hyperplasia occludes the distal segment of the same coronary vessel after stenting. Availability of access to healthy coronary wall for revascularization is usually feasible in patients receiving a single stent implantation in one or each coronary artery. However, the distal vascular bed of multi-stented coronary artery is often influenced by the accelerated atherosclerosis and diffusely diseased where it is impossible to find any healthy area for distal anastomosis. Sometimes, open endarterectomy with removal of stent(s) can remain the last option for surgical revascularization.

3. Surgical treatment techniques

Diffuse atherosclerosis has been highly widespread among patients with coronary artery disease in the last two decades, because simple lesions are usually treated with stent interventions in the early phase of the coronary pathology. Diffuse coronary lesion and reduced coronary flow reserve can be silent due to several collaterals, but it might result in severe functional limitation, chronic low-level ischemia, and myocardial remodeling. Low-level ischemia can be a potential driver of both first coronary vasomotor and myocardial dysfunction, and then remodeling in heart failure with preserved ejection fraction. Diffuse atherosclerosis and microvascular dysfunction-associated coronary artery disease comorbid conditions may guide new, more effective, aggressive, and therapeutic interventions for global cardiovascular risk reduction due to complete revascularization. There is no difference in event-free survival between CABG or stent implantation in patients with high coronary flow reserve; however, CABG is significantly more effective than stent in patients with low coronary flow reserve [12]. Diffuseness of coronary artery disease is a serious risk factor for early and late adverse events after coronary revascularization, but the acceptable strategy should be complete revascularization. Standard bypass method (finding an appropriate lumen and performing anastomosis) is usually not possible in the diffusely diseased coronary arteries, and such a region, which may be found at most distal, cannot be expected to bring any benefit. For this reason, in such cases, it is required to apply a complex method other than standard bypass method. When the atherosclerotic stenosis is local, it is technically possible and easy to revascularize the distal segment directly, but in diffuse coronary artery disease or in the presence of diffuse stenotic regions, different techniques should be implemented for complete revascularization.

The treatment of the diffused-type coronary artery disease has always been an issue; however, this scenario is challenging for cardiac surgeons because diffuse atheromatous lesions frequently render epicardial coronary vessels unsuitable for conventional distal grafting. However, there are some strategies to perform a complete revascularization with increasing complexity and mortality risk sequentially in these patients. Second, to attenuate or prevent perioperative infarction and/or postischemic ventricular dysfunction caused by inadequate myocardial protection, there are many different administrative ways for cardioplegic solutions, but the optimal delivery method of cardioplegia also remains controversial. Off-pump bypass can be another option when coronary artery is totally occluded and retrograde flow supplies the myocardium.

The aggressive involvement type of atherosclerosis is the corner stone for coronary revascularization, and the first choice of the aggressive surgical techniques also depends on this nature (Table 1). A coronary artery with multisegment plaques and healthy-area intervals simplifies complete revascularization, and multiple revascularization of this coronary artery with different methods seems applicable by every cardiac team. On the other hand, a more aggressive treatment modality should be preferred when no soft site can be identified for arteriotomy or there is an extensively diseased area not amenable to grafting or no other methods except transplantation. The routine application for arteriotomy in patients with local stenosis is to perform the anastomotic incision proximal enough to get the larger-sized coronary target but distal enough from atherosclerotic lesion. Arteriotomy should be more complicated or extended to get appropriate coronary lumen and anastomotic area in patients with diffuse coronary lesions. The main goal of CABG is to finish complete revascularization using different surgical approaches during open-heart surgery. Using a single graft or multi-grafts or a hybrid procedure (stent + bypass) is a reliable option to revascularize all segments of each coronary artery: **don't touch the plaque techniques**. Sometimes an aggressive plaque formation needs to be touched using extended arteriotomy with/without endarterectomy and patch-plasty: **touch the plaque techniques**.

Don't Touch the Plaque Techniques

1. Jumping bypass technique

This technique is used for revascularization of the same coronary artery with more than one anastomosis (Figure 1). Most patients with diffuse coronary artery disease have multiple severe stenoses along coronary arteries or diseased coronary artery may have critically important side branches before the last stenosis that could not be bypassed. Jumping bypass is performed via single or multiple conduits on the same coronary artery and is the only solution to supply blood throughout the diseased coronary artery, especially for the left anterior descending (LAD) artery and the right coronary artery (RCA). The circumflex artery (Cx) may have multiple major branches and each one does not need to be revascularized consecutively with this technique; on the contrary, these branches should be revascularized separately with sequential grafting. The jumping bypass technique has several advantages to avoid unexpected adverse complications intraoperatively (Table 2). It is the simpler technique to perform complete revascularization in diffuse coronary disease patients. This technique can be applied via different approaches.

A. No-touch the plaque techniques
1. Jumping bypass (the same coronary artery)
a. with multiple grafts
b. with a single graft
c. with a composite graft
d. with a bifurcated graft
2. Sequential bypass (multiple coronary arteries)
a. with a single graft
b. with a composite graft
c. with a bifurcated graft
3. Hybrid revascularization (different coronary arteries)
B. Touch the plaque techniques
1. long-segment anastomosis
2. patch-plasty
3. endarterectomy ± patch-plasty
a. closed
b. open

Table 1. Aggressive bypass strategies for diffusely diseased coronary territory

1. To achieve complete revascularization of the same major coronary artery
2. To supply blood to the myocardium via grafting major side branches of the same coronary artery
3. To avoid more aggressive surgical procedures (“touch the plaque” techniques)
4. To shorten ischemic and cardiopulmonary bypass times
5. To salvage myocardium from perioperative myocardial infarction caused by graft failure

Table 2. Advantages of the jumping bypass technique

a. Jumping grafting with multiple conduits

This approach is the easiest approach, and it is usually used for the LAD revascularization, whereas the RCA is seldom preferred. This jumping bypass approach using more than one conduit is usually preferred in emergency situations to salvage myocardium perioperatively, but it can also be used in elective cases. Two arteriotomies are performed on the same coronary

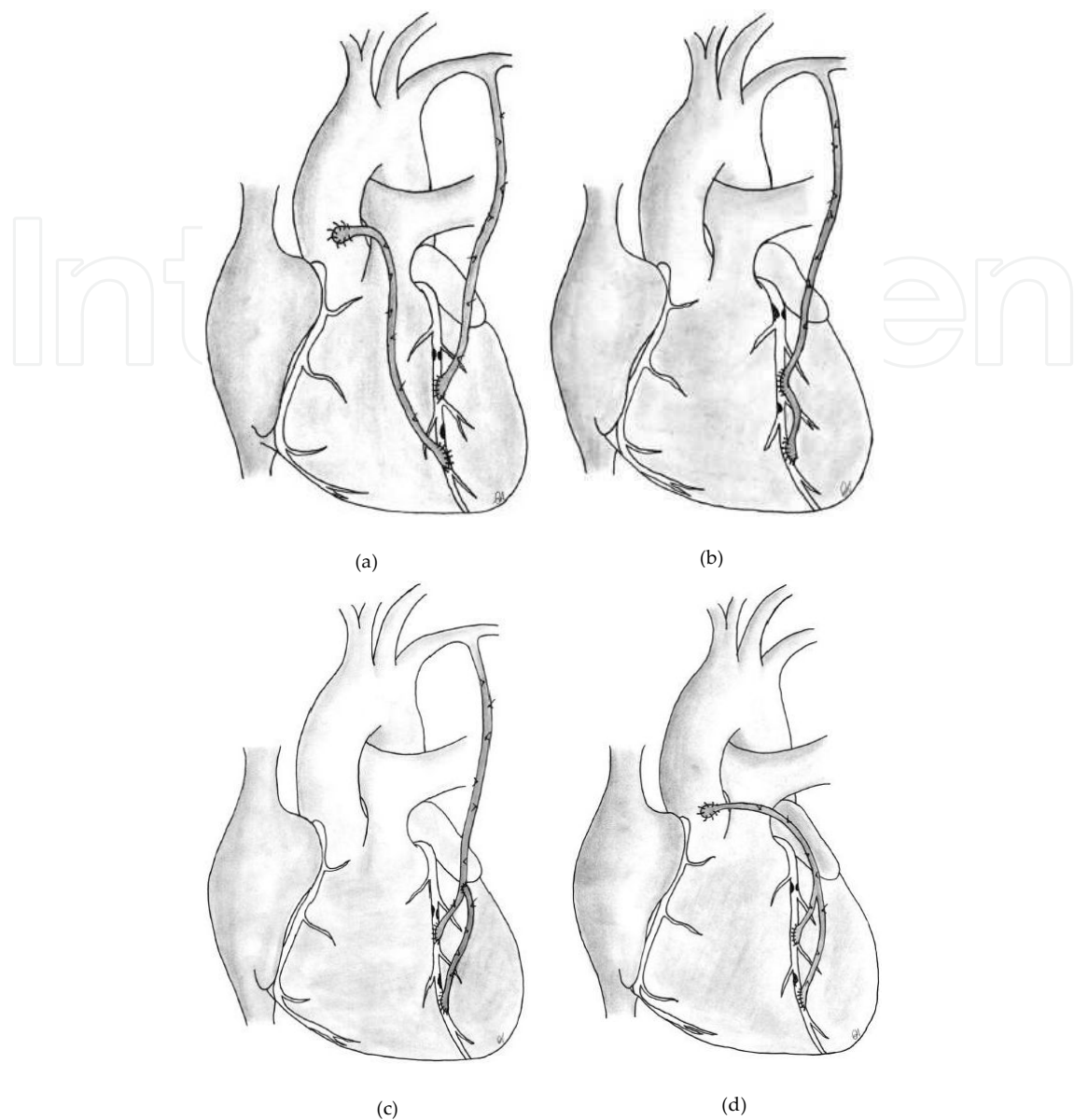


Figure 1. Jumping grafting is an alternative to multi-revascularization of the same coronary artery with multi-segment stenoses. **a)** Jumping grafting with multiple conduits. **b)** Jumping grafting with a single conduit. **c)** Jumping grafting with a composite conduit. **d)** Jumping grafting with a bifurcated conduit.

artery and both are grafted by different conduits (Figure 1a). Two conduits are anastomosed in an end-to-side fashion, and this approach achieves double suppliers with double sources. This approach is usually preferred for the LAD, and the left internal mammary artery (LIMA) is often anastomosed between the proximal and distal lesions, because the length of LIMA is usually not enough to reach to the distal segment. The distal segment of the coronary artery is revascularized using a second conduit, especially with a vein graft. In elective and planned surgery, the second graft could be an arterial conduit: the right internal thoracic artery (RIMA) or radial artery (RA). In the emergency salvage re-exploration after perioperative myocardial infarction, the saphenous vein graft (SVG) should be chosen for its precipitous harvesting. This

approach can be preventative against early graft failure, whereas the second independent conduit can continue to supply blood. This approach is also lifesaving when perioperative myocardial infarction is developed because of the graft failure, and the second graft is anastomosed at the distal part of the affected coronary artery. This alternative procedure is mostly used to salvage myocardium when the LIMA or the other conduit does not work due to any reason perioperatively.

b. Jumping grafting with a single conduit

This approach can be used for the LAD or RCA elective and planned revascularization, but it is not feasible for emergency surgery. This approach is similar to sequential bypass technique, but the only difference is to be a single target vessel requiring multiple anastomoses. If harvesting of a second conduit is not possible due to any reason and the target coronary artery has multiple stenosis, the harvested single graft can be anastomosed on the same coronary artery consecutively (Figure 1b). In situ or free conduits can be used for jumping grafting. The double arteriotomies are made in the direction of the long axis at the mid and distal soft segments of the target coronary artery, and a single proximal arteriotomy is made at the conduit. The two proximal incisions are aligned parallel and the proximal anastomosis is performed in a side-to-side fashion and created kissing anastomosis, which is the critical part of this approach, but “aligned perpendicular and created a diamond-shaped anastomosis” is never used for this anastomosis like the routine sequential bypass technique. The distal end of the graft is anastomosed to the distal arteriotomy on the target coronary artery as the standard end-to-side fashion. Using a larger graft for consecutive anastomoses on the same coronary artery can be performed with a lower technical risk than the LIMA because of its borderline diameter, and the best conduits for this approach are the RA and SVG. This approach is often complication free and consecutive grafting of the same target coronary artery permits efficient use of limited conduits, but it is preferred rarely.

c. Jumping grafting with a composite conduit

This approach can be used for the LAD revascularization. This approach is more time-consuming than the other approaches and needs more attention. A composite conduit can be built as T- or Y-graft with the in situ LIMA. This second graft is usually prepared from a free arterial graft (a short segment of the RA or RIMA), and both free ends of the second arterial conduit are anastomosed on the same coronary artery, whereas the LIMA is anastomosed at the middle part of the second conduit (T-graft) or the LIMA is anastomosed on the LAD, whereas both free ends of the second arterial conduit are anastomosed on the distal segment of the LAD and at the middle part of the LIMA (Y-graft) (Figure 1c). This application arranges uniform distal anastomoses using the same conduit with the same diameter and prevents stealing coronary blood by any larger conduit. In the absence of the second arterial graft, a short SVG can be also used as the composed part.

d. Jumping grafting with a bifurcated conduit

This approach can be used for the LAD or RCA revascularization. This approach is easy to apply, but it is very uncommon to find a bifurcated conduit in the body. The two branches of

the LIMA have a smaller diameter and are very vasospastic, which are not suitable for grafting. The only option is to harvest the SVG with its first major bifurcated branches (Figure 1d). The advantages are avoiding the second proximal anastomosis on the ascending aorta or on the other conduit, any handicap caused by anastomosis between both grafts, and technical difficulties and risks of kissing anastomosis.

2. Sequential bypass technique

This technique is used for revascularization of more than one target coronary arteries or major branches of the same coronary artery with the same conduit. The number of the sequential bypassed vessels depends on the availability of multi-conduits, which allow one or more sequential bypass at the same time. If harvesting adequate conduits is feasible, the true way is bypassing all diseased coronary artery separately as the “one graft-to-one target coronary artery” rule. The main purpose of this technique is the efficient usage of limited conduits to achieve complete revascularization (Table 3). The most distal anastomosis should be to the furthest target coronary artery with an acceptable diameter, and the conduit is anastomosed at several coronary arteries before its proximal anastomosis. The most possible drawback is more than one distal anastomoses with a single proximal source that can cause an aggravated risk of inadequate myocardial perfusion. It cannot be hazardous, if the equal coronary territory is bypassed with the same conduit sequentially. On the other hand, if the distal coronary artery has a small diameter, it would be hazardous, and this smaller distal anastomosis lies under the risk of total occlusion because of preferential graft flow to the larger proximal coronary arteries. All available conduits can be used for sequential grafting, especially the SVG. The RA is usually used for sequential anastomosis during full arterial revascularization [13]. The LIMA should not be used for sequential bypass grafting, if it supplies the LAD flow, but it can be used as a donor for composite T- or Y-grafting of other arterial conduits, especially with the RIMA, in order to achieve complete arterial revascularization. The distal anastomosis is performed with the standard end-to-side technique and all proximal anastomoses with the side-to-side technique. Both the target coronary artery and the conduit are incised longitudinally and aligned perpendicular to each other, and all proximal sequential anastomoses must be constructed in a diamond-shaped fashion to prevent any stenosis, kinking, distortion or tension on the anastomoses and conduit. Both the arteriotomy and the incision on the conduit should not exceed the diameter of the conduit. The distal anastomosis is completed first and the other anastomoses are performed towards the proximal consecutively.

1. To achieve complete revascularization of the different coronary arteries
2. To perform complete revascularization if conduits are inappropriate
3. To supply blood to the myocardium via grafting major side branches of the same or different coronary arteries
4 To avoid more aggressive surgical procedures (“touch the plaque” techniques)
5. To shorten ischemic and cardiopulmonary bypass times
6. To salvage myocardial revascularization intraoperatively when the conduits are shorter for proximal anastomosis on the ascending aorta.

Table 3. Advantages of the sequential bypass technique

a. Sequential grafting with a single conduit

This approach can be used for all coronary arteries and is the most used approach for complete revascularization. If harvesting of sufficient conduits is not possible due to any reason and there are a large number of target coronary arteries, the harvested single graft can be anastomosed on the different coronary arteries (RCA-Cx-Diagonal-LAD) or on the several branches of a single coronary artery (Cx 1-3) sequentially (Figure 2a). All free grafts are suitable for this sequential bypass approach. The best conduit for this approach is the SVG or RA. Proximal anastomosis is always performed on the ascending aorta without any concern on the long-term patency [14]. In situ arterial grafts should be used alone to the target coronary artery, especially both IMAs. First, the distal end of the graft is anastomosed to the distal target coronary artery in an end-to-side fashion. The other proximal coronary arteries are bypassed consecutively through the anterior surface of the heart. The small arteriotomies are made in the direction of the long axis of the target coronary artery and small incisions are made at the conduit. The two incisions are aligned perpendicularly creating a diamond-shaped anastomosis and the sequential anastomosis is performed in a side-to-side fashion, which is the critical part of this approach; however, “aligned parallel and created a kissing anastomosis” is never used for this anastomoses. This approach is often complication free, and sequential grafting of the different target coronary arteries permits efficient use of limited conduits.

b. Sequential grafting with a composite conduit

This approach can be performed in two different methods. The first method is usually used if the distal SVGs remain shorter for proximal anastomosis on the ascending aorta intraoperatively, especially for revascularization of the Cx-branches. A composite conduit can be built as Y-graft and the second short graft is usually anastomosed on the main conduit, and the most preferred conduits are the SVG and RA (Figure 2b-1). The main graft is anastomosed to the largest target coronary artery first, and the proximal anastomosis of the other shorter graft(s) is performed on this main graft before or after releasing the aortic cross-clamp. The second method is used for complete arterial revascularization of all coronary arteries, but this method is more time-consuming and needs more competency (Figure 2b-2). This composite conduit is prepared for T- or Y-graft and it can reach all surfaces of the heart. The most preferred conduits are the LIMA as a pedicle graft source and the RIMA as a composed part for grafting all target coronary arteries.

c. Sequential grafting with a bifurcated conduit

This approach can be used for revascularization of the distal RCA- or Cx-branches (Figure 2c). This approach is easy to apply, but it is very uncommon to find a bifurcated conduit in the body. The advantages are avoiding the second proximal anastomosis on the ascending aorta, any handicap caused by anastomosis between both grafts, and technical difficulties and risks of kissing anastomosis.

3. Hybrid revascularization

The standard hybrid coronary revascularization combines the benefits of the LIMA-to-LAD grafting and stent implantation to the other coronary territory. The hybrid revascularization

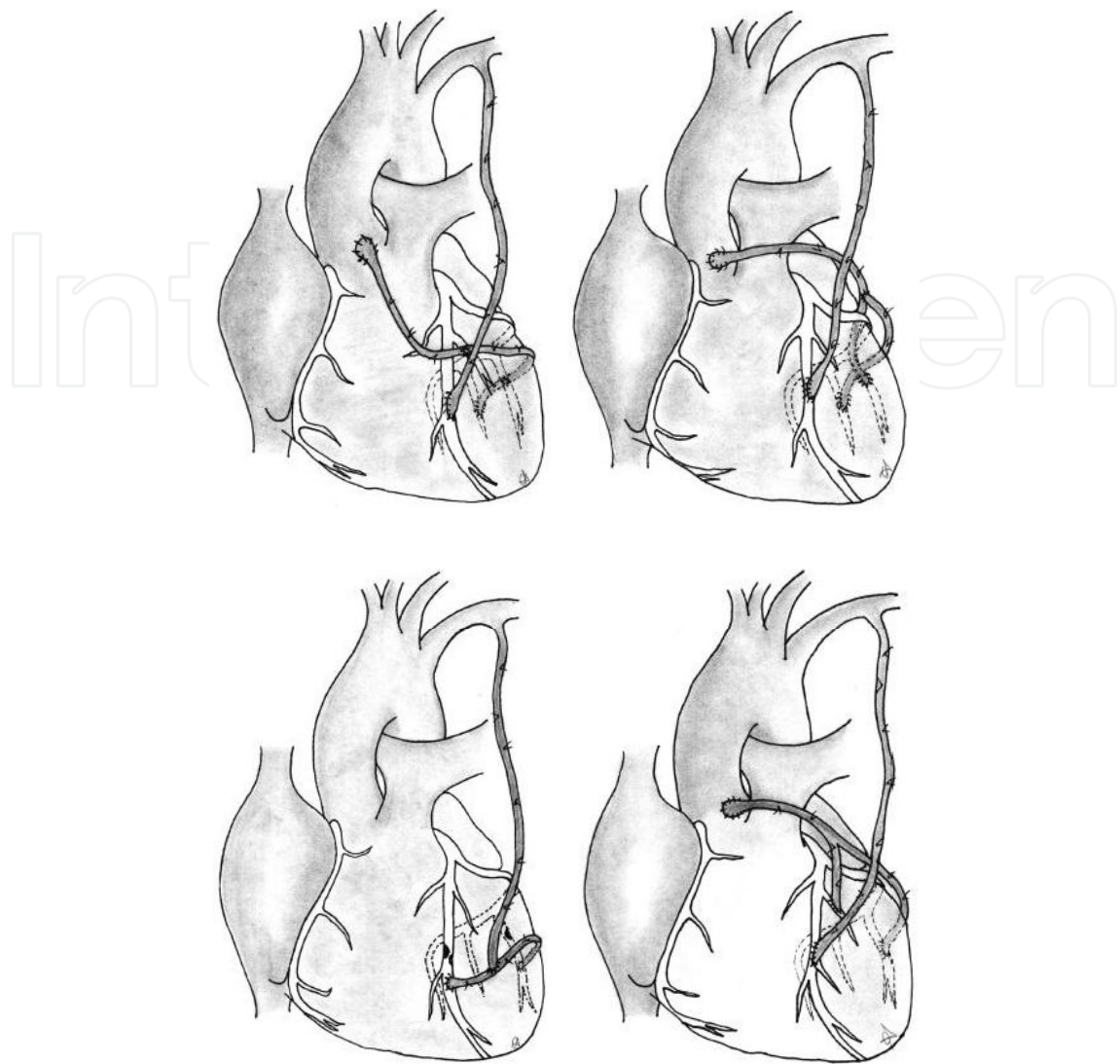


Figure 2. Sequential grafting is the best alternative for the multivessel revascularization in the absence of adequate conduits. **a)** Sequential grafting with a single conduit. **b)** Sequential grafting with a composite conduit: 1- classic approach with inadequate saphenous vein grafts; 2- T- or Y- graft for total arterial revascularization. **c)** Sequential grafting with a bifurcated conduit.

technique can be chosen with several indications in patients with diffuse coronary artery disease (Table 4). Patients with severe comorbidities or patients with multiple stenoses may be the best candidates for this procedure. If complete multivessel surgical revascularization increases operative adverse outcomes in high-risk patients, stent implantation in one or more coronary arteries, except the LAD, can be a preventative alternative to complete myocardial revascularization (Table 4). Hybrid revascularization can be performed concomitant or staged. Concomitant hybrid revascularization needs a specific operating room, whereas staged hybrid revascularization can be performed in every clinic. Percutaneous coronary intervention is applied before or after CABG. The decision depends on the severity of proximal lesions which may not be revascularized, and the aim is the avoidance of any perioperative myocardial infarction. Especially proximal or ostial left main or LAD serious stenosis should be treated

by stent, if single LIMA-to-LAD grafting cannot achieve complete blood supply to the LAD territory. Ungraftable RCA or Cx vessels with severe stenosis should be treated by percutaneous intervention to achieve complete revascularization.

1. Invisible coronary artery during surgery threatening a huge myocardium
2. Multiple stenosis with a very proximal lesion threatening proximal larger branches
3. To shorten cardiopulmonary and ischemic times
4. Absence of sufficient conduits for complete revascularization
5. Impaired or diseased conduits

Table 4. Indication for hybrid revascularization

Touch the Plaque Techniques

1. Long-segment (1-3 cm) anastomosis

This technique is chosen when the plaque with limited length obstructs the coronary blood flow. This simplest form includes a limited long-segment anastomosis of a conduit to eliminate the occlusion of the limited atherosclerotic plaque (Figure 3). This technique is a prolonged version of the standard anastomosis technique to revascularize proximal and distal segments of the coronary artery and makes jumping grafting with/without a second graft unnecessary. The whole diseased coronary artery segment is opened at full length of the atherosclerotic lesion and the arteriotomy is extended bidirectionally until the healthy coronary artery lumen comes out. The aim of this maneuver is to forward graft blood flow directly into the healthy coronary artery lumen bidirectionally. The distal end of the graft is opened longer than coronary arteriotomy to prevent any tension, tightening, stenosis or inadequately anastomotic length of the conduit, and then the graft is anastomosed on the coronary arteriotomy longitudinally. All attention should be directed to avoid any distal embolization of atherosclerotic debris or to prevent the continuity of the coronary artery.

2. Patch-plasty (> 3 cm) anastomosis

A diffusely diseased coronary artery cannot be grafted by conventional grafting technique and side branches and/or distal segment would not be revascularized. This technique is preferred mostly for the LAD, but the RCA or the Cx artery can be also bypassed with this technique. The patch-plasty technique is necessary if any kind of endarterectomy cannot be applied and the long-segment lesions should be opened in full length. The main principle is to avoid touching the atherosclerotic plaques during the patch reconstruction. The in situ or free conduit can be used alone (Figure 4a) or it can be anastomosed onto the second graft, which is sewn on the long-segment arteriotomy as a hood (Figure 4b). The arteriotomy can be made as long as the length of the attainable epicardial coronary artery, and then a conduit is used to close this arteriotomy without the occlusion of side branches. The graft should also be opened as long as the arteriotomy and anastomosed with a running single suture. In the standard approach, the bites can be taken at the free ends of the arteriotomy to get the largest lumen

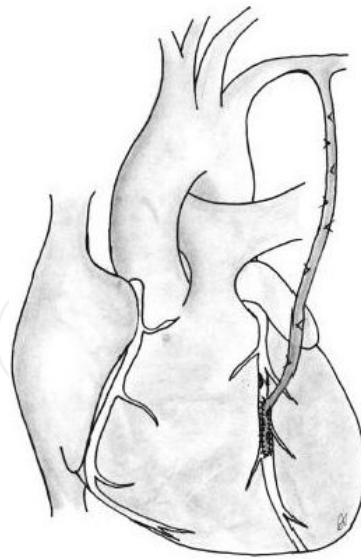


Figure 3. Long-segment anastomosis (1-3 cm) is the simplest alternative to eliminate the distal eccentric lesion.

(Figure 5a). If the lateral walls of the coronary arteriotomy are much calcified, the bites can also be taken very closely to the septal branches, however, this approach needs grafting epicardial side branches separately (Figure 5b). This technique is more useful for the diffusely occluded LAD to perfuse septal branches as far as possible or for the distal major branches of the RCA with septal branches. The Cx artery can be grafted with this technique to make the anastomosis safe.

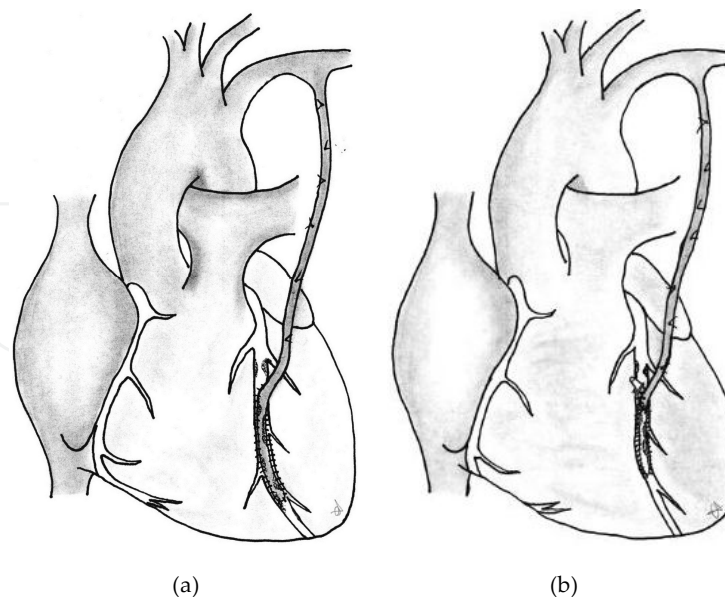


Figure 4. Patch-plasty is the best alternative to avoid endarterectomy in the extended long-segment (> 3 cm) diffuse coronary artery disease. **a)** The in situ or free conduit is anastomosed onto the long-segment coronary artery as a patch. **b)** The limited second conduit is anastomosed as a hood and the main conduit is anastomosed onto this conduit.

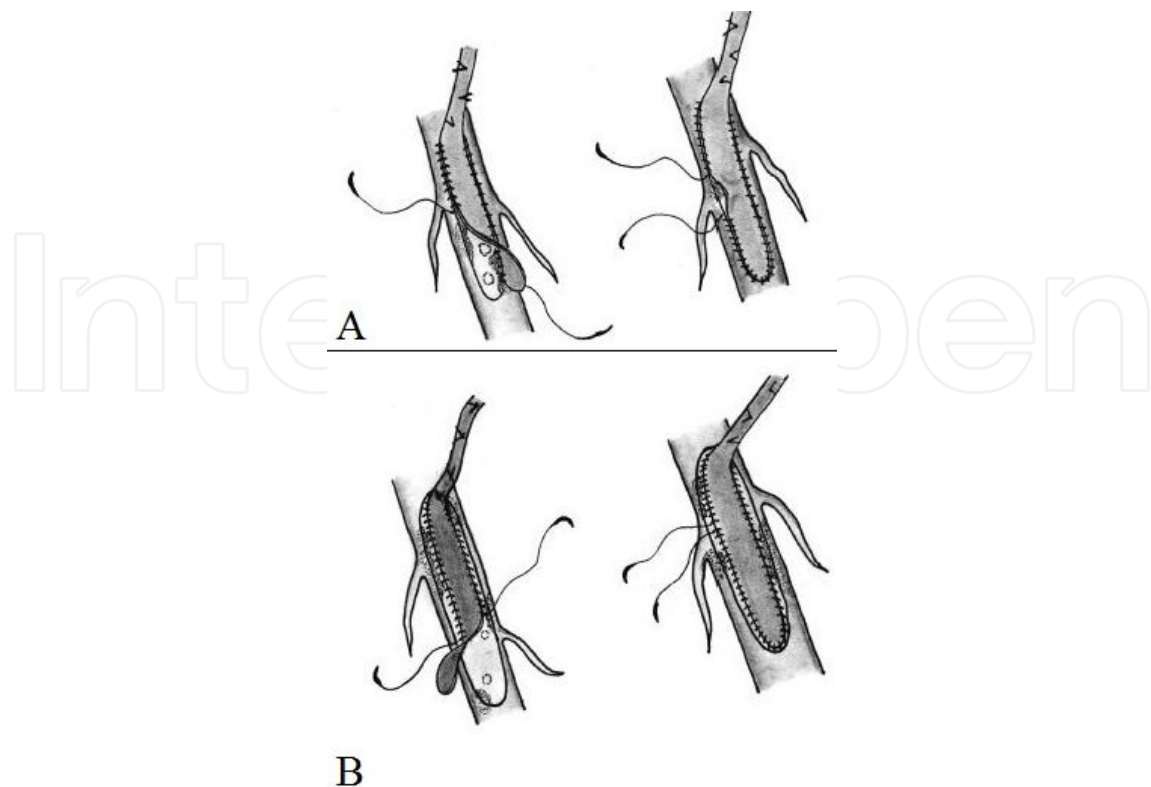


Figure 5. The stitching maneuvers of the patch-plasty technique. **a)** Bites on the free margins of the coronary arteriotomy. **b)** Bites close to the septal branches.

3. Endarterectomy with/without patch-plasty

In the accelerated form of coronary arteriosclerosis, the atherosclerotic plaque appears widespread and the full-length lumen of the coronary artery can be narrowed strictly or occluded totally. Coronary endarterectomy can be applied via off- or on-pump techniques, but the Cx endarterectomy with off-pump technique is used very seldom because it is more difficult and needs more competence [15]. This technique can be often used for every coronary artery, but it is usually preferred for the LAD and RCA [16]. The long-segment lesion is usually calcified and it inhibits any kind of stitching; however, the plaque can be separated easily from the arterial wall. Endarterectomy and graft anastomosis is preferred only to create an appropriate lumen in the total occluded coronary artery due to the removal of the atheromatous material. Long-standing atherosclerosis permits a successful endarterectomy to get adequate distal run-off. All debris and layer until the adventitia should be removed, and then the vessel wall is reconstructed with a conduit. The early occlusion of the endarterectomized coronary artery is caused by thrombosis or intimal flap formation, but the reason for late occlusion is intimal hyperplasia. The endarterectomy and patch plasty approach has a very satisfactory graft patency compared with the other approaches for the coronary territory [17,18].

a. Closed Endarterectomy

The closed approach is preferred for the LAD or RCA (Figure 6a). Approximately 2 cm arteriotomy is performed and an endarterectomy plane between the medial layer and the

adventitia is developed with the coronary scissors. The circumferential plane is performed and the core is pulled out from the distal arterial wall. Distal plaque removal causes usually a better coronary distal bed, but proximal plaque removal via a limited arteriotomy can cause poor outcomes as the native vessel laceration resulting native coronary artery dissection or a native passage of high blood flow from the aorta to the distal coronary resulting competition, and early thrombosis. To optimize the technique, avoiding proximal endarterectomy by the pull-out method and cutting the proximal part without any traction would come along with better results [19]. The core usually is separated cleanly from the distal vessel, but all debris must be cleaned from the septal ostia. If the core branches can be reached, major side branches are endarterectomized separately. The main aim is to get the distal core without any rupture; otherwise the arteriotomy should be extended until the ruptured distal end to continue the closed endarterectomy.

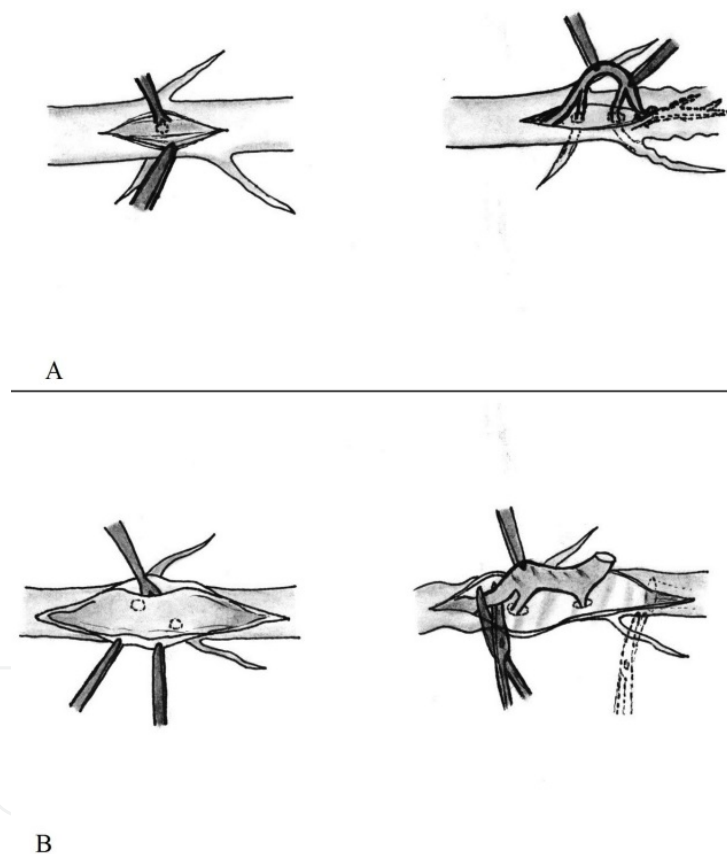


Figure 6. Endarterectomy is the most aggressive method for coronary bypass surgery. **a)** Closed endarterectomy. **b)** Open endarterectomy.

b. Open Endarterectomy + Patch-plasty

The open approach is a useful procedure for the total occluded LAD (Figure 6b). The open approach prevents any obstruction of septal branches and inadequate endarterectomy of diagonal branches. The arteriotomy is started at the middle segment of the LAD and extended bidirectionally as proximal and distal as possible. If septal branches are easy to be revascular-

ized with long-segment grafting, anastomosis can be finished without endarterectomy. If the direct anastomosis is impossible because of severe calcified vessel wall or no lumen, a long-segment endarterectomy should be performed to separate the core from the adventitia. The core is removed gently and both ends of the core at the ends of the arteriotomy should be cut without any traction. Because aggressive endarterectomy increases the operation risk, the arteriotomy should be extended until the normal lumen with normal intima in the distal and proximal segments of the coronary artery. All coronary arteries have very small lumen and thin wall at the distal, and the arteriotomy should be stopped 2-3 cm before the last bifurcation. The arteriotomy is reconstructed with a long segment of the conduit or a graft patch into which the in situ conduit is anastomosed.

Author details

Kaan Kırallı* and Yücel Özen

*Address all correspondence to: imkbkirali@yahoo.com

Department of Cardiovascular Surgery, Koşuyolu Herat and Research Hospital, Istanbul, Turkey

References

- [1] Gould KL, Johnson NP. Physiologic severity of diffuse coronary artery disease: Hidden high risk. (Editorial) *Circulation* 2015;131(1):4-6.
- [2] McNeil M, Buth K, Brydie A, MacLaren A, Baskett R. The impact of diffuseness of coronary artery disease on the outcomes of patients undergoing primary and reoperative coronary artery bypass grafting. *Eur J Cardiothorac Surg* 2007;31(5):827-833.
- [3] Hadi HA, Carr CS, Suwaidi JA. Endothelial dysfunction: Cardiovascular risk factors, therapy, and outcome. *Vasc Health Risk Manag* 2005;1(3):183-198.
- [4] Kurlansky P, Herbert M, Prince S, Mack MJ. Improved long-term survival for diabetic patients with surgical versus interventional revascularization. *Ann Thorac Surg* 2015;99(4):1298-1305.
- [5] Kappetein AP, Head SJ, Morice MC, et al. Treatment of complex coronary artery disease in patients with diabetes: 5-year results comparing outcomes of bypass surgery and percutaneous coronary intervention in the SYNTAX trial. *Eur J Cardiothorac Surg* 2013;43(5):1006-1013.
- [6] Fanari Z, Weiss SA, Zhang W, Sonnad SS, Weintraub WS. Meta-analysis of three randomized controlled trials comparing coronary artery bypass grafting with percu-

taneous coronary intervention using drug-eluting stenting in patients with diabetes. *Interactive Cardiovasc Thorac Surg* 2014;19(6):1002-1007.

- [7] Lehle K, Preuner JG, Vogt A, et al. Endothelial cell dysfunction after coronary bypass grafting with extracorporeal circulation in patients with type 2 diabetes mellitus. *Eur J Cardiothorac Surg* 2007;32(4):611-616.
- [8] Galili O, Sattler KJ, Herrmann J, et al. Experimental hypercholesterolemia differentially affects adventitial vasa vasorum and vessel structure of the left internal thoracic and coronary arteries. *J Thorac Cardiovasc Surg* 2005;129(4):767-772.
- [9] Wong D, Thompson G, Buth K, Sullivan J, Ali I. Angiographic coronary diffuseness and outcomes in dialysis patients undergoing coronary artery bypass grafting surgery. *Eur J Cardiothorac Surg* 2003;24(3):388-392.
- [10] Faccini A, Agricola E, Oppizzi M, et al. Coronary microvascular dysfunction in asymptomatic patients affected by systemic sclerosis. *Circ J* 2015;79(4):825-829.
- [11] Vecchiati A, Tellatin S, Angelini A, Iliceto S, Tona F. Coronary microvasculopathy in heart transplantation: Consequences and therapeutic implications. *World J Transplant* 2014;4(2):93-101.
- [12] Taqueti VR, Hachamovitch R, Murthy VL, et al. Global coronary flow reserve is associated with adverse cardiovascular events independently of luminal angiographic severity and modifies the effect of early revascularization. *Circulation* 2015;131(1):19-27.
- [13] Kaya E, Mansuroglu D, Göksedef D, et al. Long-term angiographic results of coronary artery bypass surgery with the use of arterial graft combinations. *Turkish J Thorac Cardiovasc* 2005;13(4):309-313.
- [14] Akıncı E, Uzun K, Erentuğ V, et al. The comparison of the early and midterm results of the proximal anastomosis techniques in sequential radial artery grafting. *Turkish J Thorac Cardiovasc* 2004;12(3):235-240.
- [15] Kırallı K, Sareyyüpoğlu B, Yıldırım Ö, et al [abstract]. Coronary artery endarterectomy: Off-pump or on-pump? 56th International Congress of the European Society for Cardiovascular Surgery, May 17-20, 2007; Venice, Italy. *Interact Cardiovasc Thorac Surg* 2007;6(Suppl 1):S52.
- [16] Kırallı K, Yıldırım Ö, Sareyyüpoğlu B, et al [abstract]. Coronary artery endarterectomy: Impact on morbidity and mortality. 56th International Congress of the European Society for Cardiovascular Surgery, May 17-20, 2007; Venice, Italy. *Interact Cardiovasc Thorac Surg* 2007;6(Suppl 1):S75.
- [17] Kırallı K, Sareyyüpoğlu B, Yıldırım Ö, et al [abstract]. Left anterior descending coronary artery endarterectomy: 15-year results. 56th International Congress of the European Society for Cardiovascular Surgery, May 17-20, 2007; Venice, Italy. *Interact Cardiovasc Thorac Surg* 2007;6(Suppl 1):S103.

- [18] Kırallı K, Yıldırım Ö, Sareyyüpoğlu B, et al [abstract]. Coronary endarterectomy for diffuse right coronary artery disease: 11 years results. 15th Annual Meeting of Asian Society of Cardiovascular Surgery, May 17-20, 2007; Beijing, China.
- [19] Sareyyüpoğlu B, Yıldırım Ö, Kırallı K. Different results of proximal coronary endarterectomy via conventional pull-out method. *Kosuyolu Heart J* 2012;15(2):90-91.

IntechOpen

IntechOpen