

We are IntechOpen, the world's leading publisher of Open Access books Built by scientists, for scientists

6,900

Open access books available

185,000

International authors and editors

200M

Downloads

Our authors are among the

154

Countries delivered to

TOP 1%

most cited scientists

12.2%

Contributors from top 500 universities



WEB OF SCIENCE™

Selection of our books indexed in the Book Citation Index
in Web of Science™ Core Collection (BKCI)

Interested in publishing with us?
Contact book.department@intechopen.com

Numbers displayed above are based on latest data collected.
For more information visit www.intechopen.com



Management of Diabetic Retinopathy and Other Ocular Complications in Type 1 Diabetes

Efraim Berco, Daniel Rappoport, Ayala Pollack, Guy Kleinmann and Yoel Greenwald

Additional information is available at the end of the chapter

<http://dx.doi.org/10.5772/61276>

Abstract

Type 1 diabetes can reduce vision by affecting various parts of the eye. Proactive, interdisciplinary coordination of treatment and timely referrals can aid in the minimization of visually threatening complications, significantly enhancing patient quality of life. The main causes of visual impairment in diabetes are proliferative diabetic retinopathy and macular edema. Until recently, the mainstay of treatment for both conditions was retinal laser, which prevented significant vision loss but was much less effective at improving vision, especially in macular edema. Over the past decade, exciting new advances in treating diabetic eye disease, namely intraocular steroid and antivascular endothelial growth factor injections, have greatly improved the visual prognosis for the majority of patients with diabetic eye disease.

Keywords: Diabetic retinopathy, Macular edema, Laser, Intraocular injection, Cataract

1. Introduction

Type 1 diabetes is a complex metabolic disease that involves multiple organ systems which can cause severe visual impairment. Almost all ocular structures may be afflicted in diabetes including: the extraocular muscles, the intraocular lens, the optic nerve, and the retina.

Diabetes is the leading cause of blindness between the ages of 20 and 74 in many developed countries. Individuals with diabetes are 25 times more likely to become legally blind than individuals without diabetes. The aspect of diabetic eye disease most responsible for vision loss is diabetic retinopathy, which accounts for ¼ of blind registrations in the Western world [1,2]. There are two main pathways by which diabetic retinopathy affects vision; fluid

accumulation in the center of vision, or macular edema, and the formation of pathological retinal vessels also known as proliferative diabetic retinopathy.

Prevention of severe visual impairment in type 1 diabetes includes: optimal glycemic control, the treatment of ancillary risk factors such as hypertension, and regular screening for early diagnosis and treatment of ocular complications.

In the following chapter, we will describe how diabetes affects different ocular structures and discuss the treatment options available today to combat these complications.

2. Extraocular muscles

Patients with diabetes may present with a sudden onset of diplopia (double vision). This is usually caused by a paresis of one of the extraocular muscles due to microvascular damage to the third, fourth, or the sixth cranial nerves [3,4].

When the extraocular muscle deficit is due to microvascular complications of diabetes the prognosis is good. Recovery of ocular motor function generally begins within three months of onset and recovery is usually complete. Although the diplopia can be debilitating, due to the generally limited course of these complaints, patients can usually be effectively managed conservatively with eye patching. When diplopia is from large divergence of the visual axes, patching one eye is the only practical short-term solution. When the deviation is smaller, the diplopia often can be resolved by using glasses with a horizontal or vertical prism or both. Surgery is rarely indicated.

If patients do not recover from a cranial nerve palsy within 6-12 months, eye muscle surgery to treat persistent and stable angle diplopia should be considered. These patients should consult with a neuro-ophthalmologist for continuing care.

3. Intraocular lens: Cataract

Cataract is a common cause of visual impairment in patients with diabetes. The Framingham study [5] revealed a three- to four fold increased prevalence of cataract in diabetic patients under the age of 65, and up to a twofold increased prevalence in patients above 65. Duration of diabetes and quality of glycemic control are the major risk factors for early cataract development [5].

Recurrent high levels of glucose in the lens lead to the glycolation of lens proteins from increased nonenzymatic glycation and oxidative stress to the lens [6]. This causes diabetic patients to develop age-related lens changes similar to nondiabetic age-related cataracts, except that they tend to occur at a younger age [7]. Several studies have analyzed the effect of vitamin and antioxidant supplements, such as vitamin C, E, and beta carotene and zinc, on preventing or slowing progression of age-related cataracts in diabetes without showing any statistically significant benefit with their use [6].

Early cataracts may cause mild visual impairment that can be managed reasonably with spectacle correction. Cataract surgery is indicated when visual function is significantly impaired by the cataract or if the cataract obscures the view of the retina and makes the diagnosis and treatment of diabetic retinopathy difficult.

Cataract surgery is safe in diabetic patients and there is a 95% success rate in terms of improved visual acuity [6]. Good glycemic control, fluid and electrolyte balance should be maintained perioperatively and the patient's treating physician and anesthesiologist should be involved in the process. It is recommended that the surgery be scheduled in the morning to minimize changes in the patient's usual schedule [8].

Some controversy exists regarding a potential association between cataract surgery and a subsequent worsening of diabetic retinopathy. Patients should be made aware of this risk preoperatively. Cataract surgery and its effect on diabetic retinopathy will be discussed in more detail in section 7.3.2.

4. Cornea

Corneal disorders secondary to diabetes (diabetic keratopathy) are increasingly recognized as a cause of ocular morbidity associated with diabetes. Patients with diabetes have structural changes of the corneal basement membrane that contributes to defects in the adhesion of corneal epithelial cells to the deeper stromal tissue [9]. This increases the risk of recurrent corneal erosions. In addition, accumulation of sorbitol in the cornea during periods of hyperglycemia leads to hypoesthesia (a loss of corneal sensation). Both hypoesthesia and epithelial adhesion dysfunction occur more frequently with increased severity and duration of diabetes. In patients with more long-standing or advanced diabetes, any corneal epithelial injury, either from trauma, during ocular surgery or from routine contact lens use, may result in prolonged healing times. This increases the risk of severe complications such as bacterial infiltration and ulceration.

Treatment of diabetic keratopathy is multifaceted, including artificial tears for mild cases, and the use of topical antibiotics, a bandage contact lens, eye patching, or closure for more severe cases.

5. Iris

Rubeosis iridis, neovascularization of the iris, is a serious complication of diabetes which occurs in patients with severe diabetic retinopathy [3]. Severe retinal ischemia stimulates the formation of numerous intertwining blood vessels on the anterior surface of the iris. These vessels can block aqueous outflow from the anterior chamber, leading to a sharp and persistent rise in intraocular pressure. This complication is known as neovascular glaucoma. This type of glaucoma is hard to treat and is often associated with pain from very high ocular pressure.

Topical medical therapy used commonly in other forms of glaucoma is less effective. Treatment should include aggressive control of the underlying diabetic retinopathy. The treatment of diabetic retinopathy will be discussed in more detail in section 7.

6. Retina – Diabetic retinopathy

Damage to the retinal capillaries, known as diabetic retinopathy, is the hallmark of diabetic eye disease. This condition is the major cause of blindness and visual disability in patients with type 1 diabetes.

There are two main pathways by which diabetic retinopathy can reduce vision: macular edema and proliferative retinopathy. These conditions can appear concomitantly or separately with the treatment protocol tailored to the relative severity each condition.

Macular edema develops when damaged retina vessels leak fluid and protein. These deposits collect on or under the macula of the eye where central vision is processed. This causes the macula to thicken and swell and may distort central vision.

Proliferative retinopathy occurs when diffuse injury to retinal vessels severely impairs retinal oxygenation. The hypoxia induces the release of proteins which stimulate the growth (or proliferation) of new, fragile retinal vessels. These new vessels have a propensity to bleed, which severely reduces vision.

In the following sections, we will discuss how retinopathy and macular edema develop and the various treatment options available to patients today, with a focus on exciting recent developments.

6.1. Epidemiology

Diabetic retinopathy is one of the most frequent causes of preventable blindness in working aged adults (20-74 years) [1,10]. In the USA, an estimated 86% of patients with type 1 diabetes have some degree of diabetic retinopathy. Data from the Wisconsin Epidemiologic Study of Diabetic Retinopathy (WESDR) showed that within 5 years of diagnosis of type 1 diabetes, 14% of patients developed retinopathy, with the incidence rising to 74% by 10 years [11,12]. In people with retinopathy at the WESDR baseline examination, 64% had their retinopathy worsen, 17% progressed to proliferative diabetic retinopathy (PDR), and about 20% developed diabetic macular edema during 10 years of follow-up.

The WESDR data in type 1 diabetics showed that 25 years after diagnosis, 97% of patients developed retinopathy, 43% progressed to PDR, 29% developed diabetic macular edema, and 3.6% of patients younger than 30 at diagnosis were legally blind [11]. The WESDR results also showed a reduction in the yearly incidence and progression of diabetic retinopathy during the past 15 years [12]. This may be signaling an improved ocular prognosis for diabetics today, possibly due to recent advances in glycemic control, ophthalmic treatment, and patient education.

The course of diabetic retinal disease in children with type 1 diabetes is fairly benign. Severe vision-reducing complications are uncommon in children before puberty [13].

6.2. Risk factors

There are several risk factors which influence the development and progression of diabetic retinopathy. The following list contains most of the important risk factors known today.

Modifiable risk factors:

1. **Hyperglycemia:** Good glycemic control has been shown to significantly prevent the development and progression of diabetic retinopathy. Every 1% decrease in hemoglobin A_{1c} leads to a 40% reduction in the risk of developing retinopathy, a 25% reduction in the risk of progression to vision-threatening retinopathy, and a 15% reduction in the risk of blindness [1,14,15].
2. **Hypertension:** Good blood pressure control is important in reducing the risk of retinopathy. Every 10 mmHg reduction in systolic blood pressure leads to a reduction of 35% in the risk of retinopathy progression and a reduction of 50% in the risk of visual loss [1].
3. **Obesity:** Obesity (BMI>30 kg/m²) is an important risk factor for diabetic retinopathy progression in type 1 diabetes, independent of HbA_{1c} levels [16].
4. **Smoking:** There is some evidence that smoking may be a risk factor in progression of retinopathy in type 1 diabetes [17].

Nonmodifiable risk factors:

1. **Diabetes duration:** The longer the duration of diabetes, the higher the risk of developing diabetic retinopathy and of having a severe manifestation of this disease [1].
2. **Genetic factors:** The Diabetes Control and Complications Trial [18] showed a heritable tendency for developing diabetic retinopathy, regardless of other risk factors. The abnormal development of new blood vessels is regulated by protein called vascular endothelial growth factor A (VEGF-A). Variation in the sequence of this gene is associated with the development of severe diabetic retinopathy [19].
3. **Ethnicity:** Diabetic retinopathy in America is more prevalent among African Americans, Hispanic and south Asian groups than in Caucasians with otherwise similar risk profiles [1].
4. **Gender:** there is an observed gender dimorphism with younger females being at greater risk for diabetic retinopathy early in the course of diabetes [20] and males demonstrating greater risk later in life [21].

Other risk factors:

Pregnancy: Pregnancy is associated with worsening of diabetic retinopathy [22]. All pregnant women need to be closely monitored throughout pregnancy. Pregnancy in type 1 diabetes is discussed in further detail in section 7.3.1.

6.3. Pathophysiology

Diabetic retinopathy develops when hyperglycemia and other causal risk factors trigger a cascade of biochemical changes which damage retinal blood vessels. Hyperglycemia increases sorbitol levels via the action of aldose reductase increasing oxidative stress by reducing intracellular levels of reduced glutathione, an important antioxidant [23]. Intracellular hyperglycemia also increases synthesis of diacylglycerol, an activating cofactor for protein kinase C (PKC). Activated PKC decreases the production of anti-atherosclerotic factors and increases production of pro-atherogenic factors, pro-adhesive and pro-inflammatory factors [23]. As well, intracellular hyperglycemia leads to a rise in intracellular N-acetylglucosamine levels. This by-product reacts with serine and threonine residues in transcription factors, resulting in pathologic changes in gene expression [23]. The final by-product of these pathological processes is increased inflammation and increased oxidative stress, which causes endothelial cell dysfunction in retinal blood vessels.

Endothelial cell dysfunction induces retinal arteriolar dilatation, which increases capillary bed pressure. This results in microaneurysm formation, vessel leakage, and rupture [1]. Vascular permeability is also increased from loss of pericytes and increased endothelial proliferation in retinal capillaries. The breakdown of the blood–retinal barrier allows fluid to accumulate in the deep retinal layers where it damages photoreceptors and other neural tissues. This is the mechanism by which macular edema reduces visual acuity.

In some capillaries there is endothelial cell apoptosis. Vessels become acellular, leading to vascular occlusion and nonperfusion of local retinal tissue [23]. The resultant retinal ischemia promotes the release of inflammatory growth factors, such as vascular endothelial growth factor, growth-hormone-insulin growth factor, and erythropoietin [1]. These factors influence neovascularization, the growth of new capillaries, which are generally ineffective in improving tissue oxygenation as they often grow up toward the vitreous cavity.

6.4. Clinical features and classification

Diabetic retinopathy is classified as nonproliferative diabetic retinopathy (NPDR) when the vascular changes are limited to the retinal surface. It is classified as proliferative diabetic retinopathy (PDR) in the more advanced stage when new blood vessels form, which grow from the retinal surface up toward the vitreous cavity.

Diabetic macular edema occurs when leaky capillary beds allow fluid to accumulate in the part of the retina responsible for central vision. This complication can occur in patients with any level of underlying retinopathy from mild NPDR to severe PDR. Visual impairment is usually related to the state of macular disease and the consequences of neovascularization such as vitreous hemorrhage and retinal detachment. As such, the level of retinopathy does not always correlate with visual function, and severe diabetic retinopathy can be present initially without significant visual loss.

6.5. Diabetic macular edema

Diabetic macular edema (DME) is the complication of retinopathy responsible for most of the moderate visual loss in retinopathy patients. The loss of vision is often very mild at first, but

without effective treatment it can progress and patients can lose the ability to perform activities of daily living such as reading and driving. Diabetic macular edema is assessed separately from the stage of retinopathy (NPDR/PDR) and it can manifest along a different and independent course.

The edema evolves when damage to the macular capillary bed causes increased retinal vascular permeability and fluid accumulation in the macula. Clinical examination can reveal rings of hard exudates (lipid-filled macrophages) that delineate the area of focal leakage.

Optical Coherence Tomography (OCT) is a useful ancillary imaging technique in DME. Recent technological advances in OCT technology have provided physicians with high-resolution images of the retina in cross-sectional slices. Aside from demonstrating areas of retinal thickening and intraretinal fluid, OCT obtains quantitative measurements of central retinal thickness. Serial OCT examinations are often used as a noninvasive and accurate method analyzing treatment response in DME patients [1].

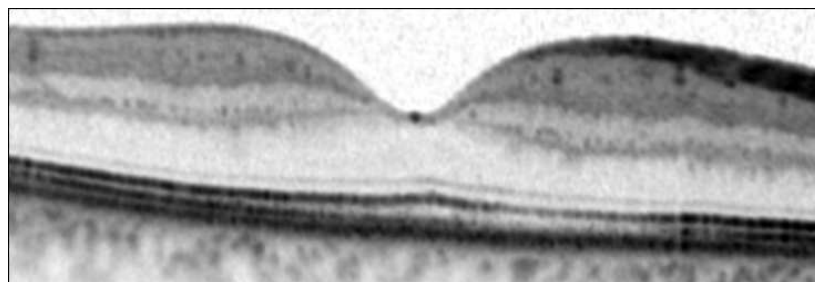


Figure 1. Normal OCT of the macular region.

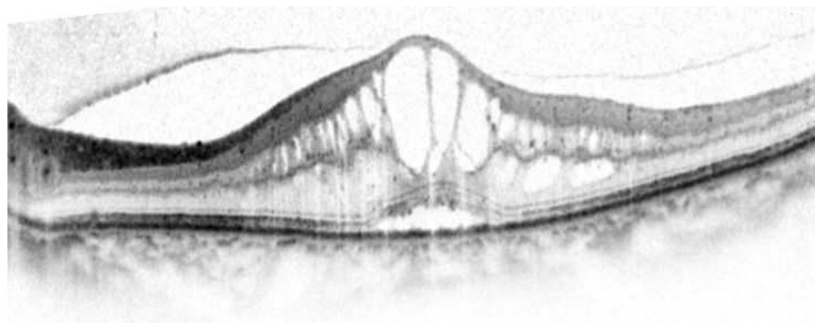


Figure 2. Macular edema: The OCT demonstrates the disruption of the normal macular anatomy due to macular edema.

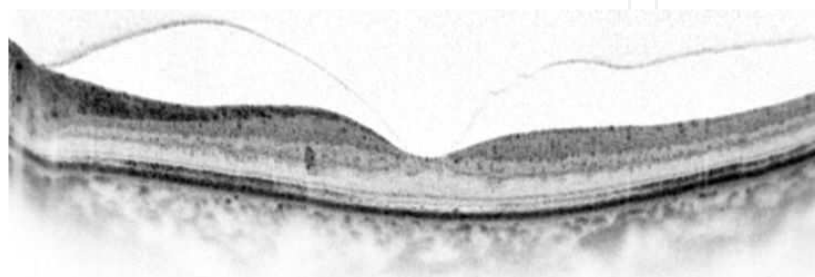


Figure 3. Posttreatment OCT: The same patient as in Figure 2 after treatment with intravitreal injections. The edema has been reabsorbed.

6.5.1. Nonproliferative Diabetic Retinopathy (NPDR)

In NPDR, the retinal microvascular changes do not extend beyond the surface of the retina. Clinical findings include microaneurysms (saccular enlargements of weakened capillaries), intraretinal hemorrhages, hard exudates (lipid-filled macrophages), cotton wool spots (nerve fiber layer infarcts), venous dilatations, and intraretinal microvascular abnormalities (dilated preexisting capillaries) [1,10].

NPDR is classified as mild, moderate, or severe, reflecting the risk of progression to PDR (Table 1) as determined by the Early Treatment in Diabetic Retinopathy Study [24].

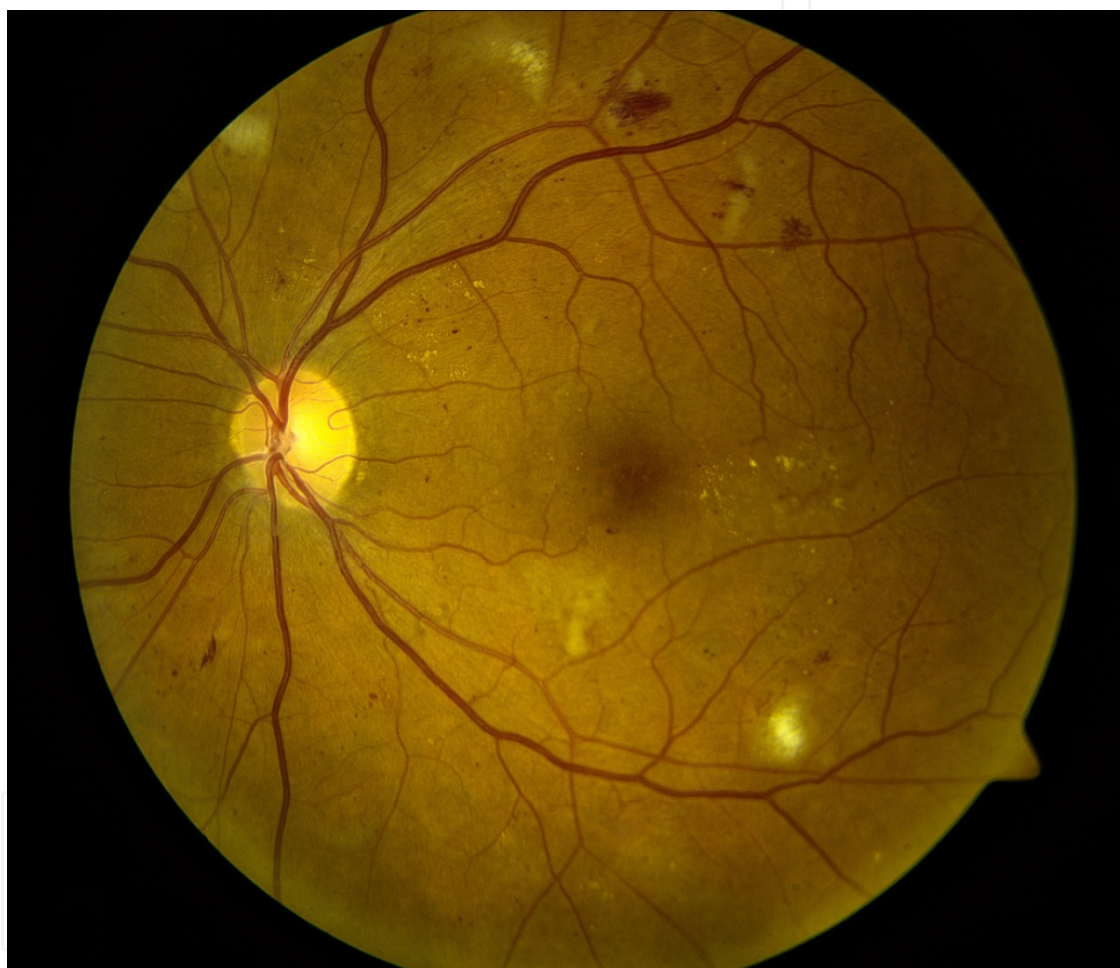

Figure 4. Nonproliferative diabetic retinopathy: Scattered hemorrhages (“dot and blot” shaped) can be seen throughout the retina.

6.5.2. Proliferative Diabetic Retinopathy (PDR)

Diabetic retinopathy advances to the proliferative stage when new vessels (neovascularizations) are formed which grow up from the retinal surface toward the vitreous cavity. The growth of these vessels is potentiated by the progression of diabetic retinal microvascular disease, causing severe retinal ischemia. This induces the release of proangiogenic factors

which promote the growth of these pathological vessels. Neovascularizations can be identified clinically as a jumble of disorganized, fine vessels emanating from the organized retinal vessel architecture. Angiography is also very effective at identifying neovascular lesions as the new vessels are porous and leak fluorescent dye into the vitreous cavity.

The new vessels in PDR evolve in three stages. Initially, the fine new vessels grow with minimal fibrous tissue. Then the new vessels increase in gauge and length with an increased fibrous component. Finally, the vessels regress and the residual fibrovascular tissue along the posterior surface of the vitreous body contracts.

Retinal neovascularizations (NV) are divided into two subtypes based on their relative risk of causing severe visual loss as demonstrated by the Diabetic Retinopathy Study (DRS). Vascular proliferations on or near the optic disc are termed NV-disc (NVD) and proliferations elsewhere are termed NV-elsewhere (NVE). The presence of NVD carries the higher risk of severe visual loss and requires more urgent treatment [25,26].

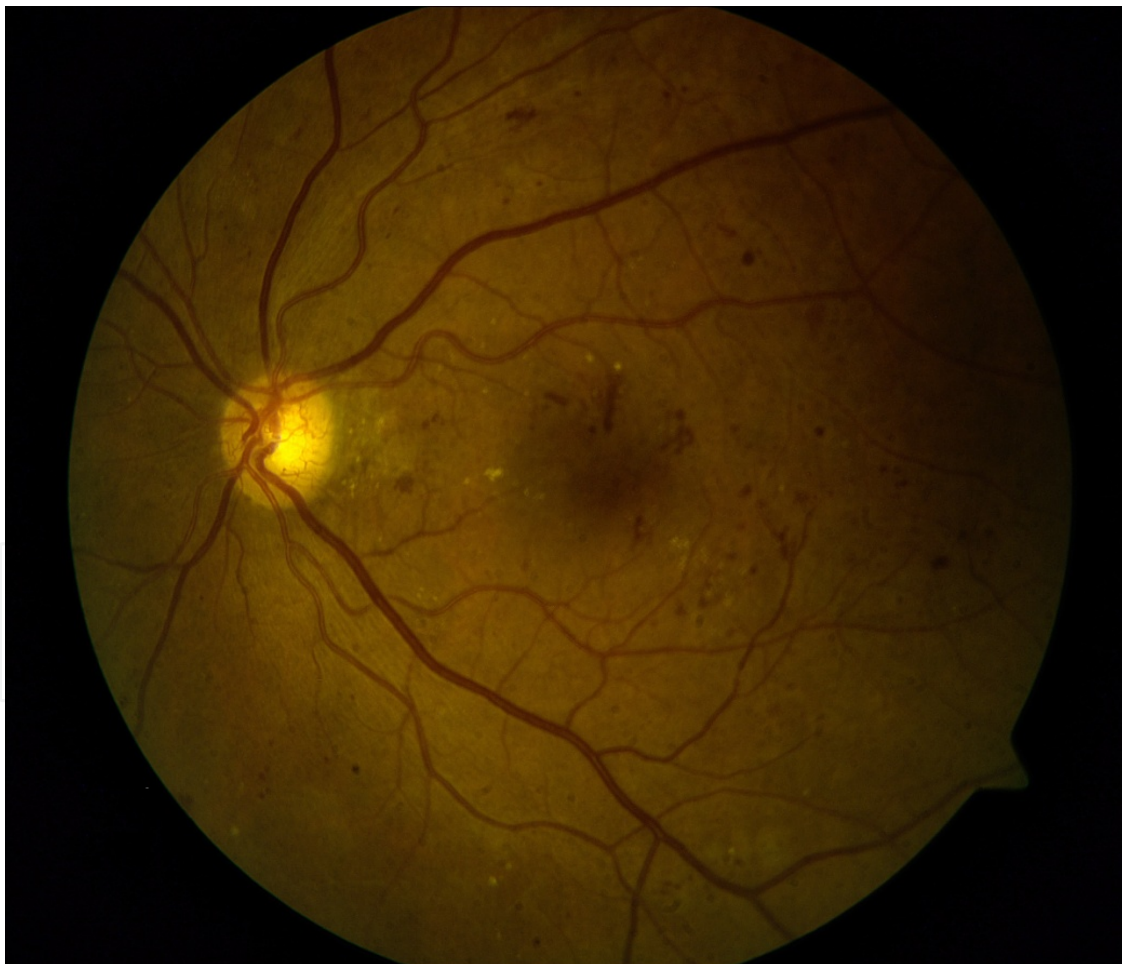

Figure 5. Neovascularization on the optic disc (NVD): The growth of fine new blood vessels can be seen on the optic disc. Urgent treatment is indicated to reduce the risk of vitreous hemorrhage.

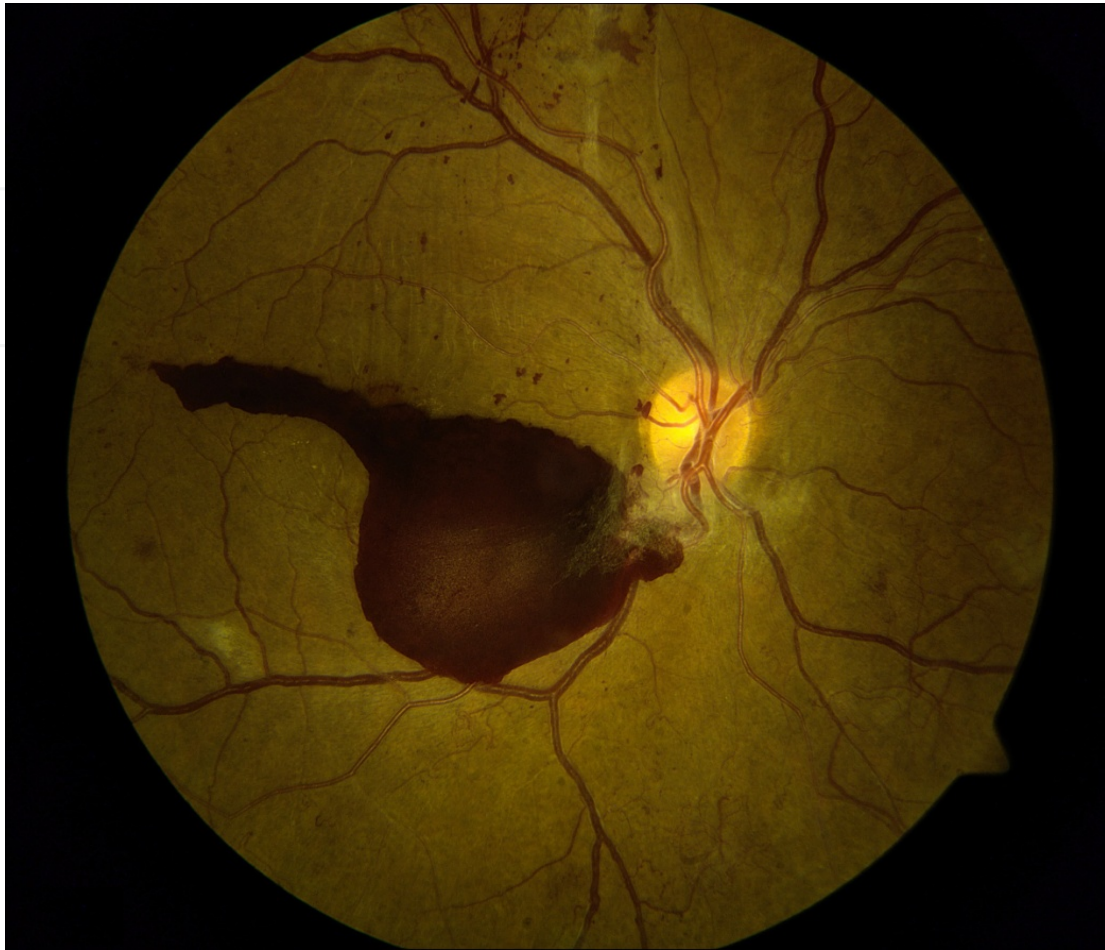

Figure 6. Vitreous hemorrhage with a neovascularization of the optic disc (NVD): The fragile blood vessels of the NVD have ruptured and a vitreous hemorrhage has collected, partially obscuring the macula and severely limiting vision.

PDR is graded from early to high risk according to the extent of the neovascular proliferations. The DRS [25,26] defined high-risk PDR as the presence of either: NVD with a vitreous hemorrhage, NVD larger than a quarter disc area without vitreous hemorrhage, or NVE larger than half disc area with vitreous hemorrhage. Without treatment, patients with early PDR have 50% risk of developing high-risk PDR in 1 year and those with high-risk PDR have a 25% risk of severe visual loss within 2 years. Treatment of PDR involving extensive peripheral laser ablation of the retina is discussed section 7.2.3.

The most common complication of PDR is vitreous hemorrhage caused by bleeding from the pathological neovascular vessels. Retinal detachments can also occur from the contraction of the neovascular tissue connecting the retinal surface to the vitreous.

Visual acuity in the absence of macular disease is often very good in PDR until a complication occurs; most commonly vitreous hemorrhage. This sudden transition from good vision to near blindness is often traumatic for patients who were unaware of the severity of their diabetic eye disease.

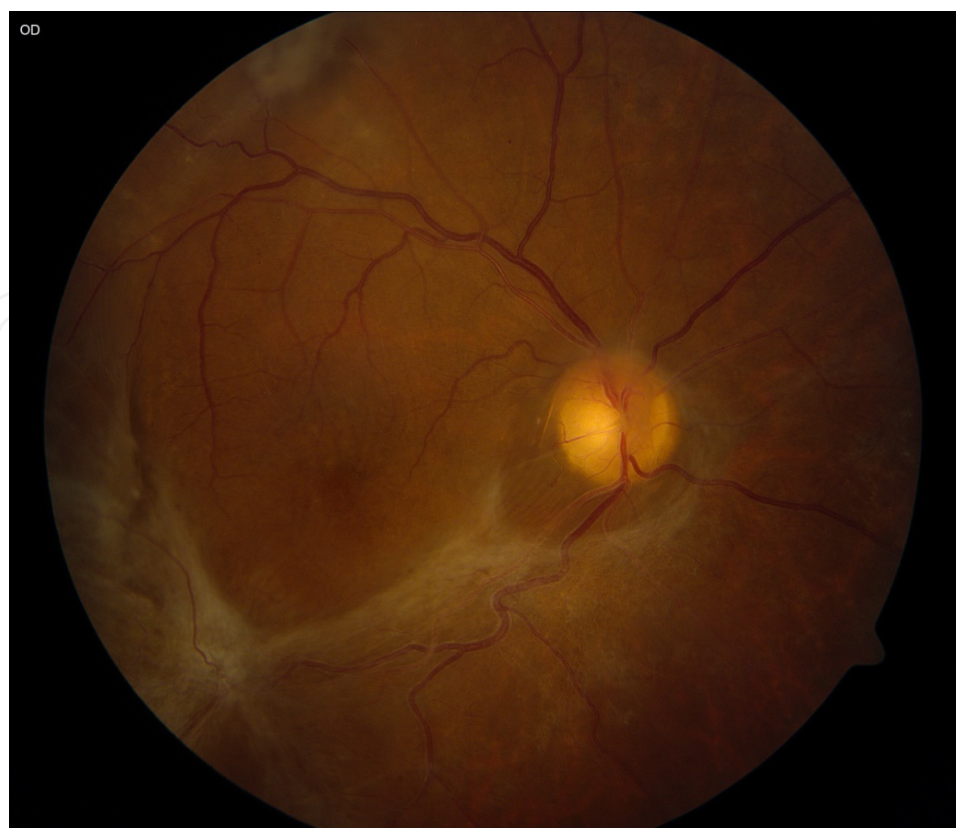

Figure 7. Traction Retinal Detachment: The neovascular tissue emanating from the optic disc and elsewhere has regressed leaving behind white fibrous tissue. This tissue has contracted and is distorting the retina in the macular region.

	Clinical Features	Progression Risk
Mild NPDR	Few microaneurysms	5% progress to PDR within 1 year
Moderate NPDR	Microaneurysms and other microvascular lesions	12-16% progress to PDR within 1 year
Severe NPDR (Meets 1 of 3 criteria)	<ul style="list-style-type: none"> • Extensive intraretinal hemorrhages and microaneurysms in all four quadrants • Venous beading in two or more quadrants • One IRMA 	52% progress to PDR within 1 year 15% progress to high risk PDR within 1 year
Very severe NPDR	Any two of the features of severe NPDR	75% progress to PDR within 1 year 45% progress to high risk PDR within 1 year
Early PDR		50% risk of developing high risk PDR in 1 year
High risk PDR		25% risk of severe visual loss within 2 years

Table 1. Clinical classification of nonproliferative and proliferative diabetic retinopathy

7. Treatment of diabetic retinopathy

The main goal of treatment of diabetic retinopathy is to prevent complications that can lead to vision loss. Treatment should include both ocular therapy and systemic medical intervention.

7.1. Medical treatment

Hyperglycemia, hypertension, and hyperlipidemia are known risk factors for the development and progression of diabetic retinopathy. Treating and controlling these factors is crucial to preventing and limiting disease progression.

The Diabetes Control and Complications Trial [14] showed that intensive glycemic control reduced both the risk of developing retinopathy and the rate of progression of existing retinopathy. Intensive glycemic control reduced the risk for progression to severe NPDR and PDR, and the incidence of diabetic macular edema. Every percent reduction in hemoglobin A_{1C} lowers the risk of retinopathy development by 30-40%.

Antihypertensive treatment with ACE (angiotensin-converting enzyme) inhibitors can slow progression of diabetic nephropathy. The EUCLID study [27] investigated the effect of Lisinopril on progression of retinopathy in normotensive type 1 diabetics. They found that Lisinopril can decrease retinopathy progression in nonhypertensive patients who have type 1 diabetes with little or no nephropathy, although the mechanism is unclear. Unfortunately, other studies investigating the effect of ACE inhibitors on the progression of DR in type 1 diabetics have shown no significant benefits.

7.2. Ocular therapy

Ocular therapy in diabetic retinopathy includes panretinal or focal laser photocoagulation, intravitreal injections of either steroids or inhibitors of Vascular Endothelial Growth Factor (VEGF), surgery, or a combination of the aforementioned treatments. The suitable treatment regimen must be tailored individually for each patient and is based on clinical status of the patient (ocular and systemic), previous treatments, and data from the several reported and ongoing studies.

7.2.1. Diabetic macular edema treatment

Treatment options for diabetic macular edema (DME) include focal laser photocoagulation, intravitreal injections of either steroids or anti-VEGF compounds, and surgery.

7.2.1.1. Focal laser treatment

Until recently, the mainstay of DME treatment was macular laser photocoagulation. Treatment criteria are based on the ETDRS recommendations [24], which showed that eyes with macular edema involving or adjacent to the central macula, defined as clinically significant macular edema (CSME), benefited from macular laser treatment. Laser treatment reduced the risk of

moderate visual loss (loss of three lines of vision) by 50% over 2 years compared with no treatment [24].

Macular laser treatment for CSME involves the application of discrete laser burns to areas of leakage in the macula. The treatment is not painful and can be repeated up to every 4 months.

Side effects of macular laser photocoagulation include: visual field loss, choroidal neovascularization, subretinal fibrosis, and inadvertent foveolar burns [10].

Modified photocoagulation techniques have been developed in response to these potential complications. The target of macular laser treatment for CSME is retinal pigment epithelium (RPE). Ideally, the laser energy would be absorbed only by the RPE and not spread to the surrounding tissues. Unfortunately, in conventional argon laser photocoagulation visible burns are created, indicating damage to the inner neural retina from the spread of thermal energy beyond the RPE.

Subthreshold diode laser micropulse (SDM) therapy delivers short pulses, which cause less thermal damage. Shorter laser exposure times confine the laser energy to a smaller zone, inflicting less damage on the neural retina and choriocapillaries. SDM laser has been shown to be as effective as a conventional laser with fewer side effects [28].

7.2.1.2. Steroid injections

Inflammatory factors play an important role in the development of diabetic retinopathy. Upregulation of adhesion molecules in blood vessels leads to leukostasis and the accumulation of macrophages in the retinal vessels. These macrophages release angiogenic growth factors [29] and cytokines which increase vascular permeability. Glucocorticoids block the action of these macrophages and downregulate ICAM-1, which mediates leukocyte adhesion and transmigration [30].

In addition, glucocorticoids alter the composition of endothelial basal membrane by changing the local ratio of two laminin isoforms [31], suppressing basement membrane dissolution, and strengthening tight junctions to limit permeability and leakage that cause macular edema [32]. For this reason, it has long been thought that ocular steroid injections may be beneficial in DME treatment.

Intravitreal triamcinolone acetonide

Triamcinolone acetonide (TA) is a synthetic steroid of the glucocorticoid family with a molecular weight of 434.50. In 2001–2002, the first reports were published of the use of intravitreal injection of triamcinolone acetonide for DME [33,34]. The most common dose used is 4 mg.

Sutter et al. [35] reported in a prospective, double-masked, and randomized trial comparing 4 mg intravitreal TA with sham injection (saline). This study reported that 55% of 33 eyes treated with 4 mg of intravitreal TA improved by 5 or more letters of vision at 3 months compared with 16% of 32 eyes treated with sham injection.

The **DRCR.net** (diabetic retinopathy clinical research network) protocol I [36] studied the use of 4 mg TA combined with macular laser. It found that TA combined with laser significantly improved vision over macular laser alone in patients who had previously undergone cataract surgery. In patients who had not previously undergone cataract surgery TA was much less effective.

Potential side effects of corticosteroid injections include cataract formation and glaucoma. Moreover, as the treatment effect wanes, patients require repeated injections that increase the glaucoma and especially the cataract risk.

Instead of intermittent bolus therapy, it is thought that sustained release of a lower-dose glucocorticoid may lead to greater efficacy with fewer complications. This has led to the development of slow-release steroid implants.

Dexamethasone intravitreal implant

Dexamethasone is a strong synthetic member of the glucocorticoid class of steroid, with an anti-inflammatory and immunosuppressant activity 30 times greater than cortisol and 6 times greater than triamcinolone.

A sustained-release intravitreal dexamethasone (DEX) implant (Ozurdex®, Allergan Inc, Irvine, CA) is biodegradable and is placed in the vitreous cavity using a 22-gauge applicator through a small self-sealing puncture.

Dexamethasone implants have been examined in several large studies; The **PLACID** study [37] compared a DEX implant (0.7 mg) to treatment with focal laser. This 1-year study did not show a statistically significant visual improvement with the DEX implant.

The **MEAD** study [38] combined the results of two multicenter 3-year sham-controlled, masked, randomized clinical studies comparing DEX injection to focal laser treatment. Patients receiving the 0.7 DEX implant required mean of 4.1 injections over 3 years. The average visual improvement with the 0.7 mg DEX implant was +6 letters versus +1 letter with focal laser. Rates of cataract-related adverse events in phakic eyes were 67.9% and 20.4% in the DEX implant 0.7 mg, and sham groups, respectively. Two patients (0.6%) in the DEX implant 0.7 mg group required trabeculectomy for severe glaucoma. Based on the MEAD study, the Food and Drug Administration (FDA) approved DEX implants for use in DME.

Fluocinolone acetonide

Fluocinolone acetonide is a corticosteroid with average mass of 452 Da. ILUVIEN is a non-bioerodable intravitreal implant in a drug delivery system containing fluocinolone acetonide. The fluocinolone acetonide (FA) intravitreal implant [39] is administered in the clinic using a 25-gauge inserter designed to release the drug slowly over 36 months. Unlike the DEX implant, it is not bioerodable.

The FAME studies [40] were two phase 3 clinical trials examining the effect of long-acting fluocinolone acetonide inserts in patients with DME. Patients were randomized in a 2:2:1 ratio to the 0.2 µg per day FA implant, the 0.5 µg per day FA implant, or sham injection (saline). The mean improvement in BCVA letter score between baseline and month 24 was 4.4 and 5.4

in the low- and high-dose groups, respectively, compared with 1.7 in the sham group. Cataract extraction was performed 74.9% of all phakic subjects at baseline in the low-dose insert group and 84.5% in the high-dose insert group compared with 23.1% in the sham group.

Severely elevated intraocular pressure requiring glaucoma surgery occurred in 8.1% of patients in the high dose group, 5.8% of patients in the low dose group, compared only 0.5% in the sham treatment group [40].

This FA implant was approved in Europe (Austria, France, Germany, and Portugal) for the treatment of DME unresponsive to all other therapies. However, it was recently denied approval for this use by the US FDA, due to concerns centering on the high risk of severe glaucoma.

7.2.1.3. Anti-vascular endothelial growth hormone compounds

Vascular Endothelial Growth Hormone (VEGF) is a subfamily of growth factors produced by hypoxic cells that act as signal proteins to stimulate angiogenesis and vascular permeability. One of the main drivers of diabetic eye disease is damage to retinal blood vessels leading to tissue ischemia [41]. Hypoxic cells are then stimulated to release VEGF. Unsurprisingly, elevated levels of VEGF have been demonstrated in the eyes of patients with diabetic retinopathy [42,43]. Elevated VEGF stimulates both retinal vessel proliferation and increased vascular permeability producing the macular edema seen in diabetic eye disease [44].

The injection of anti-VEGF agents to the vitreous is both effective and safe. Adverse ocular effects with an incidence rate of less than 1% and include: cataract formation, retinal detachment, vitreous hemorrhage, and infection. Potential systemic adverse effects include: hypertension, stroke, and myocardial infarction but these are very uncommon [45]. Although there is a theoretical risk for arterial thromboembolic events in patients receiving VEGF-inhibitors by intravitreal injection, the observed incidence rate has been low in all studies and similar to that seen in patients randomized to placebo [1,46].

Over the past 10 years, anti-VEGF agents have become the first line of therapy in treating DME. There are three commercially available anti-VEGF agents: (i) Ranibizumab, (ii) Bevacizumab, and (iii) Aflibercept.

Ranibizumab

Ranibizumab (Lucentis®; Genentech, South San Francisco, California) is a humanized monoclonal antibody fragment directed at all isoforms of VEGF-A. Ranibizumab contains only the Fab fragment of the parental anti-VEGF antibody with weight of 48 kDa. Several large clinical trials have investigated the role of Ranibizumab in the treatment of diabetic macular edema.

READ-2 [47] was a 6-month multicenter trial where patients were randomized in a 1:1:1 fashion to macular laser; monthly Ranibizumab; or a combination of laser and monthly Ranibizumab. At 6 months, the combination therapy and Ranibizumab-only groups gained 3.80 and 7.2 letters at month 6, respectively, compared with no change in the laser only group.

RESTORE [48] was a similar 12-month phase 3 clinical trial which compared Ranibizumab to both laser alone and to laser combined with Ranibizumab. All patients receiving Ranibizumab received three initial consecutive monthly injections followed by pro re nata (PRN, as needed) injections as determined at the monthly examination. At month 12, both the Ranibizumab alone and Ranibizumab with laser groups improved by 6 letters, while the laser alone group remained nearly unchanged. Patients required a mean of seven Ranibizumab injections and the change in vision was statistically significant.

As the data supporting Ranibizumab supplanting laser for primary treatment of center-involving DME grew, many physicians were unsure of the continuing role of focal laser in DME. To answer this among other questions, the **DRCR.net** [49,50] performed a randomized trial which notably compared two methods of combining adjuvant laser with Ranibizumab injections. In one arm of the study (prompt laser), focal laser was given to all the patients at initiation and repeated every 4 months as needed. In the other arm (delayed laser), focal laser could only be added if the edema persisted beyond 24 weeks of monthly Ranibizumab treatment. After 3 years of follow-up, the average gain in the prompt laser group was 7 letters compared with 10 letters in the delayed laser group. Based on these results, it is generally accepted that treatment for center-involving DME should begin with an anti-VEGF agent. Focal laser may be added only if the edema is persistent despite several consecutive anti-VEGF injections. The FDA approved Ranibizumab for treatment of DME in 2012.

Bevacizumab

Bevacizumab (Avastin®; Genentech, South San Francisco, California) is a full-length recombinant humanized monoclonal immunoglobulin G1 κ antibody weighing 149 kDa which inactivates all VEGF isoforms. It was FDA-approved in 2004 as a treatment for colon cancer. However, as emerging evidence pointed to VEGF as a central player in DME, ophthalmologists began to use bevacizumab as an “off-label” treatment.

One of the criticisms of Bevacizumab use is that it has not been specifically formulated for ocular use. Bevacizumab is sold in large vials intended for intravenous uses and compounding pharmacies aliquot the medication into prefilled syringes for ocular use. Although there have been case reports of contamination due to this extra step in the preparation process, the safety of Bevacizumab for ocular use has been well established in trials for Age-related Macular Degeneration with a side-effect profile similar to Ranibizumab [51].

Bevacizumab has yet to be approved by the FDA for use in DME. Despite this it is used in many jurisdictions because of its efficacy and its significantly lower cost compared with Ranibizumab. One study [52] estimated the cost of treating DME with Ranibizumab was 20-fold higher than treating with Bevacizumab.

BOLT [53], a 2-year trial comparing bevacizumab monotherapy with focal laser, is the best randomized trial supporting the use of Bevacizumab for center-involving DME. Eighty patients with center-involved DME were randomized to receive either every 6-weekly intravitreal bevacizumab injections (1.25 mg) or focal laser monotherapy.

At 2 years, there was a mean gain of 8.6 letters for Bevacizumab alone compared with a mean loss of 0.5 letters in the laser group.

Aflibercept

Aflibercept (EYLEA®-Regeneron Pharmaceuticals, Tarrytown, New York, NY, and Bayer Healthcare Pharmaceuticals, Berlin, Germany) is a 115-kDa anti-VEGF agent. This protein was developed by combining the extracellular binding domains of VEGF receptors 1 and 2 to the Fc segment of human immunoglobulin-G1. Similar to Ranibizumab and Bevacizumab, Aflibercept binds to all isomers of the VEGF-A family.

The phase II **DA VINCI** [54] trial compared two doses of Aflibercept, 0.5 mg and 2.0 mg, to laser treatment. The average improvement in visual acuity at 52 weeks was +11 letters for monthly 0.5 mg, +13 letters for monthly 2.0 mg and -1 letters for laser alone.

A separate arm of this trial received 3 monthly 2 mg doses followed by a scheduled dose every 8 weeks. Patients in this arm received an average of 7.2 injections per year, as compared with over 12 for monthly dosing. The average visual change was +10 letters. Ocular adverse events were consistent with those seen in other trials with anti-VEGF drugs.

The recently completed phase III **VIVID** [55] and **VISTA** [56] trials were similarly designed. Both supported the finding that a schedule of 5 monthly doses of Aflibercept followed by regular bimonthly dosing was of similar efficacy to continuous monthly injections.

In 2014, FDA approved EYLEA for the treatment of diabetic macular edema. The recommended dosage is 2 mg every 2 months, after five initial monthly injections.

Method of administration

The injection procedure should be carried out under aseptic conditions, which includes the use of surgical hand disinfection, sterile gloves, a sterile drape, and a sterile eyelid speculum (or equivalent). Adequate anaesthesia and a broad-spectrum topical microbicide to disinfect the periocular skin, eyelid and ocular surface should be administered prior to the injection, in accordance with local practice.

The injection needle should be inserted 3.5-4.0 mm posterior to the limbus into the vitreous cavity, avoiding the horizontal meridian and aiming toward the center of the globe. The injection volume of 0.05 ml is then delivered.

The use of pre- or postinjection topical antibiotics is not recommended as they have not been shown to alter the infection risk [57].

7.2.2. Nonproliferative diabetic retinopathy treatment

Visual acuity is not usually affected in nonproliferative diabetic retinopathy unless there is damage to the macula in the form of macular edema or ischemia. Ocular treatment at this stage is definitively indicated only if there is evidence of macular disease.

7.2.3. Proliferative diabetic retinopathy treatment

The goal of treatment in proliferative diabetic retinopathy (PDR) is to prevent complications and lower the risk of severe vision loss. The mainstay of treatment for PDR is laser ablation of

the peripheral retina where laser burns are placed over the entire retina, sparing the central macula. This treatment is called panretinal photocoagulation (PRP). PRP promotes the regression and arrest of progression of retinal neovascularizations by destroying ischemic retinal tissue and reducing ischemia-driven VEGF production [1,10].

The Diabetic Retinopathy Study (DRS) [25,26] evaluated efficacy of PRP treatment in eyes with advanced NPDR or PDR (DRS Group, 1981). The **DRS** study recommended prompt treatment in eyes with high-risk PDR (defined in section 6.4.3), because these eyes had the highest risk for severe visual loss. PRP treatment in these patients reduced the risk of severe visual loss by 50% over 5 years.

The **ETDRS** study [24,58] found that PRP treatment in eyes with early PDR reduced the risk of progression to high-risk PDR by 50%, and significantly reduced the risk of severe visual loss [24]. Based on these results, PRP treatment should be considered in eyes with any stage PDR especially if there is poor metabolic control, a noncompliant patient, or difficulty in maintaining close follow-up.

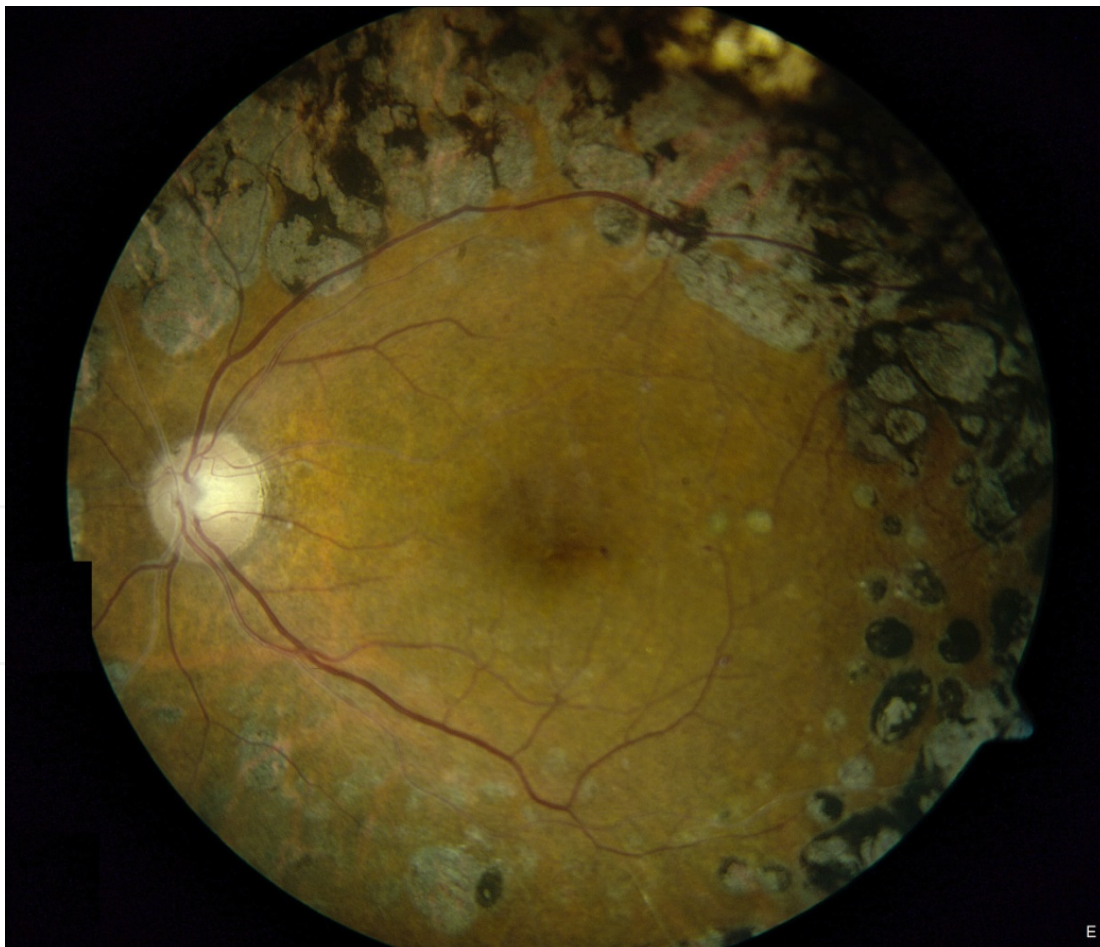


Figure 8. Panretinal photocoagulation: The retinal tissue surrounding the macular region has been ablated using Argon laser. Circular grey-black scars demark areas previously treated with laser burns.

Full PRP treatment as recommended by the **DRS** [25,26] and the **ETDRS** [24,58] includes as many as 5000 laser burns. PRP can be painful and is often performed over several sessions. After the initial treatment course, additional therapy can be applied if there is persistent neovascularization. After treatment, proliferative retinal tissue may regress and contract causing a vitreous hemorrhage or a traction retinal detachment from contracture of fibrovascular tissue. Side effects of PRP treatment also include decreased in night vision, decreased color vision, and loss of peripheral vision [10].

When PDR presents with macular edema, PRP treatment may initially increase the amount of edema [58]. In such case, it is recommended to treat the macular edema with an intravitreal injection before initiating PRP [59,60].

7.2.3.1. Surgery in proliferative diabetic retinopathy

Vitrectomy surgery is most commonly performed in PDR for a dense vitreous hemorrhage causing severe vision loss. If an eye which has not previously undergone PRP develops a significant hemorrhage and vision loss, vitrectomy is recommended when the hemorrhage persists beyond 1–3 months. Patients with vitreous hemorrhage that have preexisting complete PRP may undergo a longer observation period as many patients will have a spontaneous improvement beyond the initial 4 weeks [10,61]. Traction retinal detachment induced by the contraction of neovascular tissue connecting the retinal surface to the vitreous is another serious complication of PDR. If central vision is affected surgery is recommended. However, traction detachments which do not involve the central macula can remain stable for years. Surgery is indicated only when the traction retinal detachment involves or threatens the central macula or if a retinal tear develops [10].

Common complications after vitrectomy include corneal epithelial defects, cataract formation, elevated intraocular pressure, recurrent vitreous hemorrhage, iatrogenic retinal breaks, and rhegmatogenous retinal detachment. The development of these complications can be minimized by meticulous surgical technique and cautious postoperative follow-up.

7.2.3.2. Role of anti-VEGF agents

Several studies have evaluated the efficacy of adjunctive intravitreal anti-VEGF injections in patients with PDR [46]. Adding an anti-VEGF agent to eyes undergoing PRP reduces the risk of a vitreous hemorrhage 12 months after PRP [62]. In eyes with PDR and a dense vitreous hemorrhage, a Bevacizumab injection has been shown to aid significantly in clearing the hemorrhage [63]. This allows PRP to be completed and may reduce the number of patients ending up in surgery.

Bevacizumab has also been shown to enhance retinal surgery in patients with PDR. A single Bevacizumab injection given 1 week before vitrectomy for vitreous hemorrhage, results in decreased bleeding during surgery, decreased operating time, and less postoperative vitreous hemorrhage as compared to vitrectomy [46,64]. As separate study found that a preoperative Bevacizumab injection improved visual acuity 12 months postoperatively compared with vitrectomy alone [62].

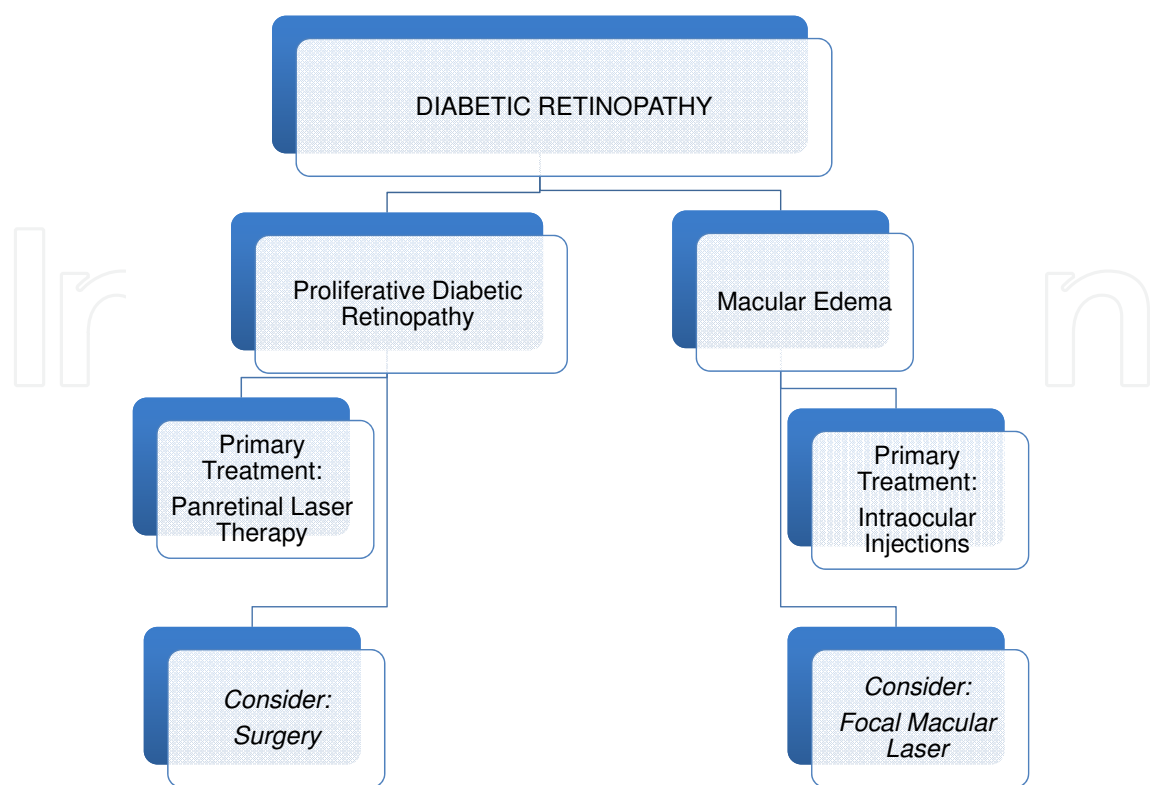


Figure 9. Summary of the two main pathways by which diabetic retinopathy can reduce vision.

7.3. Special considerations

7.3.1. Diabetic retinopathy in pregnancy

In women with preexisting diabetes, pregnancy is considered an independent risk factor for the development and progression of diabetic retinopathy [65]. Most of the progression of diabetic retinopathy in pregnancy occurs by the end of the second trimester. Although regression of retinopathy usually occurs postpartum, there is still an increased risk for progression during the first year postpartum [65]. Risk factors for the development and progression of diabetic retinopathy in pregnancy include longer duration of diabetes before conception, rapid normalization of hemoglobin A_{1c} at the beginning of pregnancy, poor glycemic control during pregnancy, diabetic nephropathy, high blood pressure, and preeclampsia [65,66].

Severity of diabetic retinopathy before or at beginning of pregnancy is also a strong predictor of progression of retinopathy during and after pregnancy. The **Diabetes in Early Pregnancy Study** [67] showed that 10.3% of women without diabetic retinopathy and 18.8% with mild NPDR experienced retinopathy progression during pregnancy, and 6.3% of women with mild NPDR progressed to PDR. In women with moderate NPDR, 54.8% suffered retinopathy progression and 29% developed PDR. Overall, progression to sight-threatening diabetic retinopathy, including macular edema and PDR, occurs in 6% of pregnant diabetic women [66].

Progression of retinopathy during pregnancy is probably related to the hypervolemic and hypercoagulable states in pregnancy, as well as elevated pro-inflammatory and angiogenic factor levels. This results in capillary occlusion and leakage-aggravating diabetic retinopathy mechanisms [65,68]. Ideally, good glycemic control and full treatment of preexisting diabetic retinopathy complications should be attained before conception.

All diabetic women who plan pregnancy should be referred by their treating physician to an ophthalmologist. The recommended follow-up of pregnant women with type 1 diabetes includes an ophthalmologic exam at the beginning of pregnancy and during the first trimester. Subsequent follow-up depends on the stage of diabetic retinopathy found on the initial examinations. In women with no retinopathy or very mild NPDR, an ophthalmologic exam is indicated when there are visual complaints. In moderate NPDR, an exam should be done at least once during the second trimester and every 4–6 weeks during the third trimester. In severe NPDR and PDR, close follow-up is needed, and an exam should be done every 4–6 weeks, from the beginning of the second trimester.

Treatment of diabetic retinopathy during pregnancy includes maximal control of both glucose levels and blood pressure [66]. Ocular therapy such as PRP should definitely be performed for PDR and be strongly considered in cases of severe NPDR. Disease progression can be very fast in pregnancy and waiting for PDR to clearly develop may result in severe complications that necessitate invasive surgery. Ocular therapy for PDR and macular edema during pregnancy can include PRP, focal laser, and intravitreal steroid injections. Although there are not much data on the safety of intravitreal injections of anti-VEGF agents during pregnancy, the literature includes some reports on the safe and effective use of Bevacizumab [69].

7.3.2. Cataract surgery in patients with diabetic retinopathy

Cataract development is major factor compromising vision in diabetic patients. Surgery often results in significant vision improvements but these can be mitigated by the progression of diabetic retinopathy and macular edema.

7.3.2.1. Macular edema progression following cataract extraction

Progression of macular edema following cataract extraction can limit the expected improvement in visual acuity from cataract surgery. The reported rates of macular edema following cataract extraction varies from 4% to 70%, depending upon the method used to identify macular edema (angiographic, biomicroscopic, OCT), the cataract extraction technique, and underlying comorbidities [70,71].

The **DRCR.net** [72] conducted a multicenter, prospective, observational study including 293 participants with diabetic retinopathy but without significant macular edema requiring treatment. The authors concluded that in eyes with diabetic retinopathy, the presence of noncentral-involved macular edema immediately prior to cataract surgery, or a history of macular edema treatment may increase the risk of developing central-involving macular edema 16 weeks after cataract extraction.

Topical Nonsteroidal Anti-inflammatory Agents

Controlling postsurgical inflammation is an important factor in preventing macular edema development. Prostaglandin release considerably contributes to fluid leakage from perifoveal capillaries into the extracellular space of the macular region. Multiple studies have reported the benefits of using nonsteroidal anti-inflammatory eye drops pre- and postoperatively to reduce the rate of edema progression [73,74].

Antivascular Endothelial Growth Factor Injections

Recent studies have shown a potential benefit using intravitreal anti-VEGF injections at the end of cataract surgery especially in cases with poorly controlled or refractory macular edema before surgery [46,75,76]. High-risk patients who received intravitreal Bevacizumab or Ranibizumab benefit from better outcomes in terms of visual acuity, macular thickness, and retinopathy progression.

7.3.2.2. *Diabetic retinopathy progression following cataract extraction*

Controversy exists in the ophthalmic community as to whether cataract surgery potentiates diabetic retinopathy progression. Several studies have reported worsening of diabetic retinopathy and macular edema after surgery [77-80]. Progression was seen during the first year after surgery and was highest in the first 3 months postoperatively. A review of several other studies, especially in the era of cataract surgery using the smaller incision phacoemulsification technique, showed no significant progression of diabetic retinopathy and macular edema after surgery [81,82]. Overall, it is likely that uncomplicated phacoemulsification does not result in a substantially increased risk of the DR progression [83]. The observed rates of progression after uncomplicated, small-incision surgery are similar to the natural course of retinopathy progression over time. The vision improvement and the ability to better visualize the retina to monitor retinopathy progression clearly outweigh the current risks of modern-day cataract extraction and subsequent retinopathy progression over time [83]. Overall, diabetics with cataracts benefit from surgery, and improved visual acuity is reported in 92–94% of patients [81]. The combined evidence suggests that in patients with low risk or absent diabetic retinopathy, there is no increased risk of retinopathy progression. However, patients with more advanced retinopathy have an increased risk for retinopathy progression and a worse visual acuity outcome.

7.3.2.3. *Summary*

A thorough evaluation of patients with diabetes is warranted before cataract surgery. Patients who have severe NPDR or PDR should be considered for PRP treatment prior to cataract removal [84]. Patients with significant macular edema should undergo treatment with a steroid or anti-VEGF agent preoperatively. Ideally, surgery should be delayed until stabilization of retinopathy and macular edema is achieved. In refractory cases, adjunctive therapy with a steroid or anti-VEGF agent at the end of cataract surgery should be considered. Close postoperative follow-up with an ophthalmologist is highly recommended in all patients with preexisting diabetic retinopathy.

8. Schedule for ophthalmologic examinations

Regular ocular examination can detect early ocular disease such as cataracts and glaucoma as well as retinopathy. Diabetic retinopathy in type 1 diabetes is rare during the first 5 years after diagnosis, so the baseline ophthalmologic examination could be extended to 5 years after diagnosis. In children with prepubertal diabetes, the baseline examination should be done at puberty [13].

The timing and frequency of follow-up ocular examinations depends on individual patient's status. In high-risk patients with long-term diabetes and poor systemic risk factor control, annual examinations should be performed even in the absence of retinopathy. In patients with known retinopathy, the examination schedule is based on the degree of retinopathy, and on the patient's compliance and adherence to regular follow-up. In mild NPDR, an examination should be performed every 9–12 months; in moderate NPDR, every 6 months; and in severe NPDR, PDR and CSME follow-up should be even more frequent even in the absence of ongoing treatment [10].

Severity of Retinopathy	Follow-up Schedule (Months)
None or minimal NPDR	12
Mild NPDR	9-12
Moderate NPDR	6
Severe NPDR	2-4
Non-high-risk PDR	2-4
High-risk PDR	2-4
Diabetic macular edema	1-3

NPDR = non-proliferative diabetic retinopathy; PDR = proliferative diabetic retinopathy

Table 2. Diabetic retinopathy (follow-up recommendations)

9. Conclusion

Diabetes is the leading cause of vision loss in working-age patients, mainly due to diabetic retinopathy. The mainstay in the prevention of disease progression remains optimizing glycemic control and controlling other ancillary risk factors. Laser treatments which prevent vision loss remain an important option for many patients with advanced diabetic retinopathy. Recent advances in medical treatment over the past decade, especially intraocular injections for macular edema, show great promise due to their ability to improve vision. Today, more than ever before, patients with even advanced diabetic eye disease have a good chance of maintaining functional vision for many years provided they undergo proper screening to

diagnose complications as they arise. The cost of these new treatments is significant both in financial terms and in terms of patient time investment, as frequent, often monthly, clinic visits are often recommended to optimize results. Additional studies are still needed in order to develop more effective and less costly treatments to further improve the visual prognosis for diabetic patients.

Author details

Efraim Berco^{1,2}, Daniel Rappoport^{1,2}, Ayala Pollack^{1,2}, Guy Kleinmann^{1,2} and Yoel Greenwald^{1,2*}

*Address all correspondence to: yoel.greenwald@gmail.com

1 Ophthalmology Department, Kaplan Medical Center, Rehovot, Israel

2 Hebrew University and Hadassah Medical School, Jerusalem, Israel

References

- [1] Cheung N, Mitchell P, Wong TY. Diabetic Retinopathy. *The Lancet* 2010; 376: 124-36. DOI: 10.1016/S0140-6736(09)62124-3.
- [2] Fauci AS, Brownwald E, Kasper DL et al. (Eds.) McGraw-Hill Powers AC. Diabetes Mellitus. *Harrison's Principles of Internal Medicine*. Retrieved from: <http://www.accessmedicine.com>
- [3] Thomas D, Graham E. Ocular disorders associated with systemic disease. In: Rior-dan-Eva P & Whitcher JP (Eds.) *Vaughan & Asbury's General Ophthalmology*, McGraw-Hill, 2008. Retrieved from: <http://www.accessmedicine.com>
- [4] Kline LB, Tariq-Bhatti M, Chung SM et al. (Eds.) Section 5: Neuro-ophthalmology. *Basic and Clinical Science Course, -2011, American Academy of Ophthalmology*. American Academy of Ophthalmology.
- [5] Leibowitz HM, Krueger DE, Dawber TR et al. The Framingham Eye Study monograph: An ophthalmological and epidemiological study of cataract, glaucoma, diabetic retinopathy, macular degeneration, and visual acuity in a general population of 2631 adults, 1973-1975. *Surv Ophthalmol* 1980; 24:335-610
- [6] Obrosova SS, Chung SS, Kador PF. Diabetic cataracts: mechanisms and management. *Diabetes/Metabol Res Rev* 2010;26(3):172-180. DOI:10.1002/dmrr. 1075

- [7] Bobrow JC, Blecher MH, Glasser D et al. (Eds.). Section 11: Lens and cataract. *Basic and Clinical Science Course, 2010-2011, American Academy of Ophthalmology*. American Academy of Ophthalmology.
- [8] Purdy EP, Bolling JP, Di-Lorenzo AL et al. (Eds.) Endocrine disorders. In: Section 1: Update on general medicine. *Basic and Clinical Science Course 2010-2011, American Academy of Ophthalmology*. 2010; 189-205, American Academy of Ophthalmology.
- [9] Reidy JJ, Bouchard CS, Florakis GJ et al. (Eds.) Metabolic disorders with corneal changes. In: Section 8: External disease and cornea. *Basic and Clinical Science Course 2010-2011, American Academy of Ophthalmology*. 2010; 307-308. American Academy of Ophthalmology.
- [10] Regillo C, Holekamp N, Johnson MW et al. (Eds.) Retinal vascular disease: Diabetic retinopathy. Section 12, Retina and vitreous. *Basic and Clinical Science Course, 2010-2011, American Academy of Ophthalmology*. 2010;109-132. American Academy of Ophthalmology.
- [11] Klein R, Knudtson MD, Lee KF et al. The Wisconsin Epidemiologic Study of Diabetic Retinopathy: XXII the twenty-five-year progression of retinopathy in persons with type 1 diabetes. *Ophthalmology* 2008;115(11):1859-1868. doi: 10.1016/j.ophtha.2008.08.023.
- [12] Varma R. From a population to patients: The Wisconsin Epidemiologic Study of Diabetic Retinopathy. *Ophthalmology* 2008; 115(11):1857-1858. DOI: 10.1016/j.ophtha.2008.09.023.
- [13] Raab EL, Aaby AA, Bloom JN et al. (Eds.) Vitreous and retinal diseases and disorders. In: Section 6: Pediatric ophthalmology and strabismus. *Basic and Clinical Science Course 2010-2011, American Academy of Ophthalmology*. 2010; 296-297/ American Academy of Ophthalmology.
- [14] DCCT 1995: Progression of retinopathy with intensive versus conventional treatment in the Diabetes Control and Complications Trial. Diabetes Control and Complications Trial Research Group. *Ophthalmology* 1995;102(4): 647-661.
- [15] Scanlon PH, Aldington SJ, Stratton IM. Epidemiological issues in diabetic retinopathy. *Middle East Afr J Ophthalmol* 2014;20:293-300. DOI: 10.4103/0974-9233.120007
- [16] Price SA, Gorelik A, Wentworth JM et al. Obesity is associated with retinopathy and macrovascular disease in type 1 diabetes. *Obes Res Clin Pract* 2014;8:178-182. DOI: 10.1016/j.orcp.2013.03.007.
- [17] Karamanos B, Porta M, Fuller JH et al. Different risk factors of microangiopathy in patients with type 1 diabetes mellitus of short versus long duration. The EURODIAB IDDM complications study. *Diabetologia*. 2000;43:348-355.

- [18] DCCT 1997: Clustering of long term complications in families with diabetes in the diabetes control and complications trial. The Diabetes Control and Complications Trial Research Group. *Diabetes* 1997;46(11):1829-1839.
- [19] Han L, Zhang L, Zhao J et al. The associations between VEGF gene polymorphisms and diabetic retinopathy susceptibility: a meta-analysis of 11 case-control studies. *J Diabetes Res* 2014;2014 DOI:10.1155/2014/805801.
- [20] Gallego PH, Craig ME, Donaghue KC et al. Role of blood pressure in development of early retinopathy in adolescents with type 1 diabetes: Prospective cohort study. *BMJ* 2008;337: 918. DOI: 10.1136/bmj.a918.
- [21] Harjutsalo V, Maric C, Groop PH, Finn Diane Study Group. Sex-related differences in the long-term risk of microvascular complications by age at onset of type 1 diabetes. *Diabetologia* 2011;54:1992-1999. DOI: 10.1007/s00125-011-2144-2
- [22] DCCT 2000: Effect of pregnancy on microvascular complications in the diabetes control and complications trial. The Diabetes Control and Complications Trail Research Group. *Diabetes Care* 2000; 23(8):1084-1091.
- [23] Stirban A, Rosen P, Tschoepe D. Complications of type 1 diabetes: new molecular findings. *Mount Sinai J Med* 2008; 75(4): 328-351. DOI: 10/1002/msj. 20057.
- [24] ETDRS 1995: Focal photocoagulation treatment of diabetic macular edema: relationship of treatment effect to fluorescein angiographic and other retinal characteristics at baseline. ETDRS Report 19. Early Treatment Diabetic Retinopathy Study Research Group. *Arch Ophthalmol* 1995;113(9):1144-1155.
- [25] DRS 1979: Four risk factors for severe visual loss in diabetic retinopathy. DRS Report 3. Diabetic Retinopathy Study Research Group. *Arch Ophthalmol* 1979; 97(4): 654-655.
- [26] DRS 1981: Photocoagulation treatment of proliferative diabetic retinopathy: clinical application of Diabetic Retinopathy Study (DRS) findings. DRS Report 8. Diabetic Retinopathy Study Research Group. *Ophthalmology* 1981;88(7):583-600.
- [27] Chaturvedi N, Fuller JH, Aiello LP, EUCLID study Group. Circulating plasma vascular endothelial growth factor and microvascular complications of type 1 diabetes mellitus: the influence of ACE inhibition. *Diabet Med.* 2001;18:288-294.
- [28] Venkatesh P, Ramanjulu R, Garg S et al. Subthreshold micropulse diode laser and double frequency neodymium: YAG laser in treatment of diabetic macular edema: a prospective, randomized study using multifocal electroretinography. *Photomed Laser Surg* 2011;29:727-733. DOI: 10.1089/pho.2010.2830.
- [29] Ingber DE, Madri JA, Folkman J. A possible mechanism for inhibition of angiogenesis by angiostatic steroids: induction of capillary basement membrane dissolution. *Endocrinology* 1986;119(4):1768-1775.

- [30] Stokes CL, Weisz PB, Williams SK et al. Inhibition of microvascular endothelial cell migration by beta-cyclodextrin tetradecasulfate and hydrocortisone. *Microvas Res* 1990;40(2):279-284.
- [31] Tokida Y, Aratani Y, Morita A et al. Production of two variant laminin forms by endothelial cells and shift of their relative levels by angiostatic steroids. *J Biol Chem* 1990;265(30):18123-9.
- [32] Ciulla TA, Harris A, McIntyre N, Jonescu-Cuypers C. Treatment of diabetic macular edema with sustained-release glucocorticoids: intravitreal triamcinolone acetate, dexamethasone implant, and fluocinolone acetate implant. *Rev Expert Opin Pharmacother* 2014;15:953-959. DOI: 10.1517/14656566.2014.896899
- [33] Jonas JB, Söfker A. Intraocular injection of crystalline cortisone as adjunctive treatment of diabetic macular edema. *Am J Ophthalmol* 2001;132:425-427.
- [34] Martidis A, Duker JS, Bauman C et al. Intravitreal triamcinolone for refractory diabetic macular edema. *Ophthalmology* 2002;109:920-927.
- [35] Sutter FK, Simpson JM, Gillies MC et al. Intravitreal triamcinolone for diabetic macular edema that persists after laser treatment: three-month efficacy and safety results of a prospective, randomized, double-masked, placebo-controlled clinical trial. *Ophthalmology* 2004;111:2044-2049.
- [36] DRCR network 2010a: The Diabetic Retinopathy Clinical Research Network. Randomized trial evaluating Ranibizumab plus prompt or deferred laser or Triamcinolone plus prompt laser for diabetic macular edema. *Ophthalmology* 2010;117(6):1067-1077. DOI: 10.1016/j.ophtha.2010.02.031.
- [37] Callanan D, Gupta S, Boyer D et al. Dexamethasone intravitreal implant in combination with laser photocoagulation for the treatment of diffuse diabetic macular edema. *Ophthalmology* 2013;120:1843-1851. DOI: 10.1016/j.ophtha.2013.02.018
- [38] Sadda S, Boyer D, He Yoon Y et al. Safety and efficacy of dexamethasone intravitreal implant in patient with diabetic macular edema: phase III, 3 year, randomized, sham-controlled study [MEAD]. 2014;10:1904-1914. DOI: 10.1016/j.ophtha.2014.04.024
- [39] Campochiaro PA, Hafiz G, Shah SM et al. Famous Study Group. Sustained ocular delivery of fluocinolone acetate by an intravitreal insert. *Ophthalmology* 2010;117(7):1393-1399. DOI: 10.1016/j.ophtha.2009.11.024
- [40] Campochiaro PA, Brown DM, Pearson A et al. Sustained delivery fluocinolone acetate vitreous inserts provide benefit for at least 3 years in patients with diabetic macular edema. *Ophthalmology* 2012;119(10):2125-2132. DOI: 10.1016/j.ophtha.2012.04.030
- [41] Semenza GL. Vascular responses to hypoxia and ischemia. *Arterioscler Thromb Vasc Biol* 2010; 30: 648-652. DOI: 10.1161/ATVBAHA.108.181644

- [42] Funatsu H, Yamashita H, Hori S. et al. Angiotensin II and vascular endothelial growth factor in the vitreous fluid of patients with diabetic macular edema and other retinal disorders. *Am J Ophthalmol* 2002;133:537-543.
- [43] Aiello LP, Avery RL, Park JE. et al. Vascular endothelial growth factor in ocular fluid of patients with diabetic retinopathy and other retinal disorders. *N Engl J Med* 1994; 331:1480-1487.
- [44] Miller JW, Le Couter J, Strauss EC, Ferrara N. Vascular endothelial growth factor a in intraocular vascular disease. *Ophthalmology* 2013; 120: 106-114 DOI: 10.1016/j.ophtha.2012.07.038
- [45] Van der Reis MI, La Heij EC, Schouten JS et al. A systematic review of the adverse events of intravitreal anti-vascular endothelial growth factor injections. *Retina* 2011 Sep;31:1449-1469. DOI: 10.1097/IAE.0b013e3182278ab4.
- [46] Nicholson BP, Schachat AP. A review of clinical trials of anti-VEGF agents for diabetic retinopathy. *Graefes Arch Clin Exper Ophthalmol* 2010; 248(7): 915-930. DOI: 10.1007/s00417-010-1315-z.
- [47] Nguyen QD, Shah SM, Khwaja AA et al. Two-year outcomes of the ranibizumab for edema of the macula in diabetes (READ-2) study. *Ophthalmology* 2010; 117: 2146-2151. DOI: 10.1016/j.ophtha.2010.08.016
- [48] Schmidt Erfurth U, Lang GE, Holz FG et al. Three year outcomes of individualized ranibizumab treatment in patients with diabetic macular edema. The RESTORE extension study. Ahead of print. *Ophthalmology* 2014;121:1045-1053. DOI: 10.1016/j.ophtha.2013.11.041
- [49] Elman MJ, Aiello LP, Beck RW et al. Randomized trial evaluating ranibizumab plus prompt or deferred laser or triamcinolone plus prompt laser for diabetic macular edema. *Ophthalmology* 2010;117:1064-1077.e35. DOI: 10.1016/j.ophtha.2014.08.047
- [50] Elman MJ, Qin H, Aiello LP et al. Intravitreal ranibizumab for diabetic macular edema with prompt versus deferred laser treatment: three-year randomized trial results. *Ophthalmology* 2012; 119: 2312-2318. DOI: 10.1016/j.ophtha.2012.08.022
- [51] Comparison of Age-related Macular Degeneration Treatments Trials (CATT) Research Group, Martin DF, Ferris FL et al. Ranibizumab and bevacizumab for treatment of neovascular age-related macular degeneration: two-year results. *Ophthalmology* 2012;119:1388-1398. DOI: 10.1016/j.ophtha.2012.03.053.
- [52] Stefanini FR1, Arevalo JF, Maia M. Bevacizumab for the management of diabetic macular edema. *World J Diabetes* 2013;4:19-26. DOI:10.4239/wjd.v4.i2.19.
- [53] Rajendram R, Fraser-Bell S, Kaines A, et al. A 2-year prospective randomized controlled trial of intravitreal bevacizumab or laser therapy (BOLT) in the management of diabetic macular edema: 24-month data: Report 3. *Arch Ophthalmol* 2012;130(8):972-979.

- [54] DA VINCI Study Group. One-year outcomes of the DA VINCI study of VEGF trap-eye in eyes with diabetic macular edema. *Ophthalmology* 2012;119(8):1658–1665. DOI: 10.1016/j.ophtha.2012.02.010
- [55] Heier J. Intravitreal aflibercept for diabetic macular edema: 12 month efficacy and safety results of phase 3, randomized, controlled VISTA-DME and VIVID-DME studies. 2014.
- [56] Diana D. Visual and anatomic outcomes from the VISTA-DME and VIVID-DME studies of intravitreal aflibercept injection in diabetic macular edema patients with and without prior treatment for DME. 2014.
- [57] Storey P, Dollin M, Garg SJ et al. Post-Injection Endophthalmitis Study Team. The role of topical antibiotic prophylaxis to prevent endophthalmitis after intravitreal injection. *Ophthalmology* 2014 Jan;121:283-289. DOI: 10.1016/j.ophtha.2013.08.037.
- [58] ETDRS 1991: Early photocoagulation for diabetic retinopathy. ETDRS Report 9. Early Treatment Diabetic Retinopathy Study Research Group. *Ophthalmology* 1991;98(5):766-785.
- [59] Silva PS, Sun JK, Aiello LP et al. Role of steroids in the management of diabetic macular edema and proliferative diabetic retinopathy. *Sem Ophthalmol* 2009;24(2):93-99. DOI: 10.1080/08820530902800355.
- [60] Mirshahi A, Roohipoor R, Lashay A et al. Bevacizumab-augmented retinal laser photocoagulation in proliferative diabetic retinopathy: a randomized double- masked clinical trial. *Eur J Ophthalmol* 2008;18(2):263-269.
- [61] El Annan J, Carvounis PE. Current management of vitreous hemorrhage due to proliferative diabetic retinopathy. *Int Ophthalmol Clin* 2014;54:141-153. DOI: 10.1097/IIO.0000000000000027.
- [62] Martinez-Zapata MJ, Marti-Crvajal AJ, Evans JR et al. Anti-vascular endothelial growth factor for proliferative diabetic retinopathy. 2014;11. DOI: 10.1002/14651858.CD008721.pub2.
- [63] Moradian S, Ahmadi H, Malihi M. et al. Intravitreal Bevacizumab in active progressive proliferative diabetic retinopathy. *Graefe's Arch Clin Exper Ophthalmol*. 2008;246(12):1699-1705. DOI: 10.1007/s00417-008-0914-4.
- [64] Ahmadi H, Shoeibi N, Entezari M, Monshizadeh R. Intravitreal Bevacizumab for prevention of early postvitrectomy hemorrhage in diabetic patients: a randomized clinical trial. *Ophthalmology* 2010; 116:1943-1948. DOI: 10.1016/j.ophtha. 2009.07.001
- [65] Shultz KL, Birnbaum AD, Goldsteir DA. Ocular disease in pregnancy. *Curr Opin Ophthalmol* 2005;16(5):308-314.

- [66] Vestgaard M, Ringholm L, Laugesen CS et al. Pregnancy-induced sight- threatening diabetic retinopathy in women with type 1 diabetes. *Diabet Med* 2010; 27(4):431-435. DOI: 10.1111/j.1464-5491.2010.02958.x.
- [67] Chew EY, Mills JL, Metzger BE et al. Metabolic control and progression of retinopathy. The Diabetic in Early Pregnancy Study. National Institute of Child Health and Human Development. Diabetes in Early Pregnancy Study. *Diabetes Care* 1995;18(5): 631-637.
- [68] Kastelan S, Tomic M, Pavan J, Oreskovic S. Maternal immune system adaptation to pregnancy – a potential influence on the course of diabetic retinopathy. *Reproduct Biol Endocrinol* 2010;8:124-128. DOI: 10.1186/1477-7827-8-124.
- [69] Tarantola RM, Folk JC, Culver Boldt H, Mahajan VB. Intravitreal Bevacizumab during pregnancy. *Retina*. 2010; 30(9): 1405-1411. DOI: 10.1097/IAE.0b013e3181f57d58.
- [70] Kim SJ, Equi R, Bressler NM. Analysis of macular edema after cataract surgery in patients with diabetes using optical coherence tomography. *Ophthalmology* 2007 May; 114:881-889.
- [71] Ostri C, Lund-Andersen H, La Cour M et al. Phacoemulsification cataract surgery in a large cohort of diabetes patients: visual acuity outcomes and prognostic factors. *J Cataract Refract Surg* 2011;37:2006-2011. DOI: 10.1016/j.jcrs.2011.05.030.
- [72] Diabetic Retinopathy Clinical Research Network Authors/Writing Committee, Baker CW, Almuthtar T, Stockdale C et al. Macular edema after cataract surgery in eyes without preoperative central-involved diabetic macular edema. *JAMA Ophthalmol* 2013;131:870-879. DOI: 10.1001/jamaophthalmol.2013.2313.
- [73] O'Brien TP. Emerging guidelines for use of NSAID therapy to optimize cataract surgery patient care. *Curr Med Res Opin* 2005 Jul;21:1131-1137.
- [74] Singh R, Alpern L, Sager D et al. Evaluation of nepafenac in prevention of macular edema following cataract surgery in patients with diabetic retinopathy. *Clin Ophthalmol* 2012;6:1259-1269. DOI: 10.2147/OPHTH.S31902.
- [75] Cheema RA, Al- Mubarak MM, Amin YM et al. Role of combined cataract surgery and intravitreal Bevacizumab injection in preventing progression of diabetic retinopathy; prospective randomized study. *J Cataract Refract Surg* 2009;35:18-25. DOI: 10.1016/j.jcrs.2008.09.019
- [76] Chen CH, Liu YC, Wu PC. The combination of intravitreal Bevacizumab and phacoemulsification surgery in patients with cataract and coexisting diabetic macular edema. *J Ocular Pharmacol Therapeut* 2009; 25,83-89. DOI: 10.1089/jop.2008.0068.
- [77] Pollack A, Dotan S, Oliver M. Course of diabetic retinopathy following cataract surgery. *Brit J Ophthalmol* 1991;75(1):2-8.

- [78] Hauser D, Katz H, Pokroy R. et al. Occurrence and progression of diabetic retinopathy after phacoemulsification cataract surgery. *J Cataract Refract Surg* 2004; 30(2): 428-432.
- [79] Jaffe GJ, Burton TC, Kuhn E. et al. Progression of nonproliferative diabetic retinopathy and visual outcome after extracapsular cataract extraction and intraocular lens implantation. *Am J Ophthalmol* 1992; 114(4):448-456.
- [80] Hayashi K, Igarashi C, Hirata A et al. Changes in diabetic macular edema after phacoemulsification surgery. *Eye (London)*. 2009; 23(2): 386-389.
- [81] Rashid S, Young LH. Progression of diabetic retinopathy and maculopathy after phacoemulsification surgery. *Int Ophthalmol Clin* 2010; 50(1): 155-166. doi: 10.1097/IIO.0b013e3181c555cf.
- [82] Shah AS, Chen SH. Cataract surgery and diabetes. *Curr Opin Ophthalmol*. 2010;21(1): 4-9. doi: 10.1097/ICU.0b013e328333e9c1.
- [83] Haddad NM, Sun JK, Silva PS et al. Cataract surgery and its complications in diabetic patients. *Rev Semin Ophthalmol* 2014;29:329-337. DOI: 10.3109/08820538.2014.959197.
- [84] Chew EY, Benson WE, Remaley NA et al. Results after lens extraction in patients with diabetic retinopathy; early treatment diabetic retinopathy study report number 25. *Arch Ophthalmol* 1999;117(12):1600-1606.

IntechOpen

