

We are IntechOpen, the world's leading publisher of Open Access books Built by scientists, for scientists

6,900

Open access books available

186,000

International authors and editors

200M

Downloads

Our authors are among the

154

Countries delivered to

TOP 1%

most cited scientists

12.2%

Contributors from top 500 universities



WEB OF SCIENCE™

Selection of our books indexed in the Book Citation Index
in Web of Science™ Core Collection (BKCI)

Interested in publishing with us?
Contact book.department@intechopen.com

Numbers displayed above are based on latest data collected.
For more information visit www.intechopen.com



Endoscopic Treatment of Gastrointestinal Bleedings

Paul Mitrut, Liliana Streba, Anca Oana Docea,
Adina Kamal, Sorin Ioan Zaharie ,
Nicolae-Dragoș Mărgăritescu and
Costin Teodor Streba

Additional information is available at the end of the chapter

<http://dx.doi.org/10.5772/61192>

Abstract

Digestive endoscopy represents an essential diagnostic and curative tool used when presented with a suspicion of gastrointestinal (GI) bleeding. Its role is not only confined to primary detection but also to establishing the severity of a lesion and providing relevant information regarding its risk of bleeding. New endoscopic techniques, accessories and compounds make the minimally invasive treatment suitable for a vast array of lesion types. Our main goal in this chapter is to summarize the main presentation of lesions at risk of bleeding, briefly classify them according to the gastrointestinal segment and finally detail the endoscopic treatment options currently available.

Therapeutic endoscopy significantly reduced mortality from upper gastrointestinal bleeding. Most common causes of lower gastrointestinal bleeding are: colon cancer, diverticulosis, colon polyps, inflammatory bowel disease, hemorrhoids, anal fissures and angiodysplasia. Digestive bleeding diagnosis strategy requires rapid clarification of the following elements: recognition of gastrointestinal bleeding, specifying the location of bleeding, assessment of its severity, specification of the etiology of bleeding and patient's risk factors. Early diagnosis of the cause of bleeding and endoscopic hemostasis reduced the need for hospitalization, blood transfusions and emergency surgery.

Keywords: endoscopic hemostasis, gastrointestinal, endoscopic treatment, colon cancer

1. Introduction

Digestive endoscopy represents an essential diagnostic and curative tool used when presented with a suspicion of gastrointestinal (GI) bleeding. Its role is not only confined to primary detection but also to establishing the severity of a lesion and providing relevant information regarding its risk of bleeding. New endoscopic techniques, accessories and compounds make the minimally invasive treatment suitable for a vast array of lesion types. Our main goal in this chapter is to summarize the main presentation of lesions at risk of bleeding, briefly classify them according to the gastrointestinal segment and finally detail the endoscopic treatment options currently available.

2. Endoscopic semiology

In general, we can describe four main types of gastrointestinal lesions that may present a risk of bleeding.

Hemorrhagic lesions are described as either *active injury bleedings* or the *stigmata of bleeding*. The first type is found mainly as point hemorrhagic lesions that bleed. They appear in uremic gastritis, some toxic or drug-induced gastritis. Bleeding stains are described as areas of 2-5 mm in diameter, highlighted in alcohol or NSAIDs-induced gastropathies. A hemorrhagic area of approximately 5-20 mm can present active bleeding, either diffuse, with areas of normal mucosa, caused by capillary bleeding, or bleeding from a vessel [1], either continuous (vein) or pulsating (arterial). *The stigmata of bleeding* persist after the bleeding has stopped, until full healing occurs. Re-bleeding can be predicted from injuries: ulcers, varices, hemorrhagic erosive gastritis [1-3].

They are described as petechial lesions (small hyperemic points that generally do not bleed), bruising (blue area of the mucosa caused by extravasated blood) and blood clots (blood vessel coated with a clot).

2.1. Flat lesions at risk of bleeding

The most commonly described is erythema, reddish appearance of the mucosa. Aftae are very superficial erosions covered by fibrin debris with peripheral leukocytes and surrounded by an intensely hyperemic halo. Deposits are usually purulent, a thin layer under which erosions are usually found. Angiodysplasia lesions are dilated vascular structures, usually pulsatile, and with multiple ramifications.

Vascular protrusions and protruding lesions at risk of bleeding are described as hemangiomas - clusters of capillaries and veins produced by anarchic proliferation; varices - dilated veins located in the submucosa, which protrude to the surface mucosa and have tortuous paths [4] and polyps (polypoid lesions - Figure 1) that may have an ulcerated surface, covered with detritus, or active bleeding.

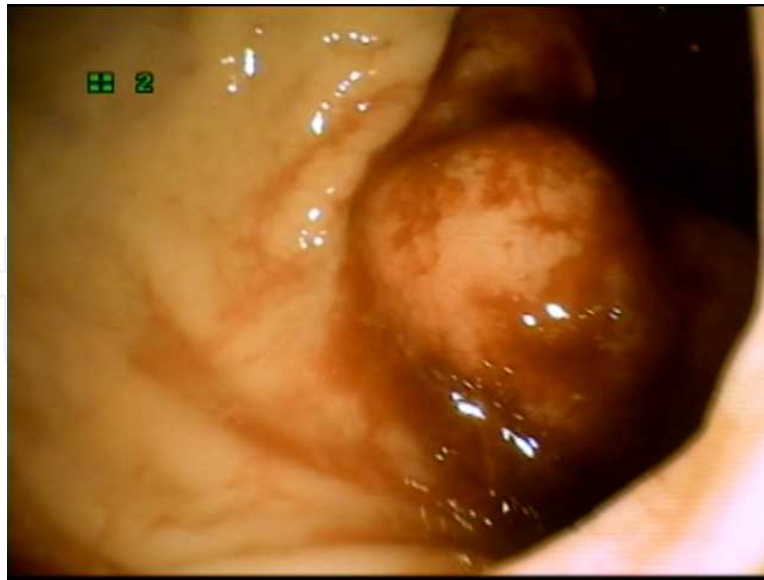

Figure 1. Bleeding polyp of the sigmoid

Excavated injury at risk of bleeding are either cracks, ulcerations or ulcers. Cracks are extremely narrow linear ulcerations that generally go deep and may be covered by necrotic or hemorrhagic debris. Ulcerations are superficial, up to 2 mm deep, with a more or less regular outline, having a diameter of 4-5 mm; they are generally acute. The ulcer (niche) represents a loss of substance above 2-3 mm, with generally well-cut edges. Their shape varies depending on the age of the lesion.

3. Lesions at risk of bleeding

3.1. Esophageal lesions

Esophageal varices are venous dilatations that continue gastric coronary veins, piercing the wall of the esophagus above the cardia or in the submucosa. They usually appear in portal hypertension of any etiology. Their color varies with depth: the deepest appear white, while superficial varicose veins display a more bluish hue.

The caliber of esophageal varices varies depending on peristalsis, being more turgid and more tortuous during movement. The classical classification of esophageal varices identifies 5 degrees, depending on size: Ist grade - protrude into the lumen, veins are tortuous, with sizes up to 1-1.5 mm; IInd grade have dimensions between 2 and 4 mm and 3-4 mm beyond the mucosa plan; IIIrd grade are more turgid, have more than 5 mm in diameter and may occupy half of the esophageal lumen; IVth grade varices are 6-7 mm in size, exceeding half of the esophageal lumen, without occluding it; Vth grade are larger than 6-7 mm (giant varices) and are extremely dilated, frequently occluding the lumen of the esophagus.

3.1.1. Early esophageal cancer

Malignant lesions limited to the mucosa and submucosa, with or without lymph node metastases. Upper endoscopy can highlight different aspects: background mucosa erosion, surface hyperemia and erythema, slightly elevated plates with grainy surfaces, or confluent plaques which give the appearance of “orange peel” edema and congestion as red spots that bleed easily. Cancer superficial erosion is friable, bleeding when touched by the endoscope, and represents the most common lesion. It can produce an enteric fistula with massive aortic bleeding which is often fatal.

3.1.2. Candidal esophagitis

Flat lesions with very thick fibrin and leukocyte deposits; underneath, we can find granulation tissue, hyperemia, spontaneous bleeding.

3.2. Pathology of the stomach

Congestive mucosa is characterized by hyperemia, edema and exudation; may be the result of irritation, functional disorders and gastritis. It can appear as red freckles distributed throughout the gastric mucosa; mosaic-like (multiple areas of erythema, bordered by a whitish reticular network); cherry-red spots, representing confluent areas of diffuse bleeding; black-brown spots representing hematin, indicating an old bleedings.

Hemorrhagic gastritis is defined by the presence of hemorrhagic spots, either as ecchymosis areas or diffuse gastric bleeding.

3.3. Vascular abnormalities of the colon

Angiodysplasia is diagnosed especially in the elderly, often in the cecum and ascending colon. **Hereditary hemorrhagic telangiectasia (Osler-Weber-Rendu disease)** is characterized by small lesions that are found on the skin, lips and the entire gastrointestinal tract.

Hemangiomatosis cavernous is a rare condition characterized by cavernous hemangiomas of the skin and is bluish in color in the gastrointestinal tract, including the colon. Cavernous hemangiomas may be located remote from the rectum.

Varices can be located on any segment of the colon or rectum, more frequently in patients with portal hypertension. Varicose veins of the anorectal junction are considered hemorrhoids.

Ischemic colitis can sometimes be encountered during the diagnosis of acute rectal bleeding. Endoscopic changes are varied and depend on the severity and duration of ischemia. Endoscopy finds pale mucosa with multiple petechiae and hemorrhagic necrosis of superficial areas. Similar ulcers may occur in late Crohn's disease (Figure 2), only less deep. Usually, these cases do not reach endoscopy as they present as an acute surgical abdomen, soliciting emergency intervention.

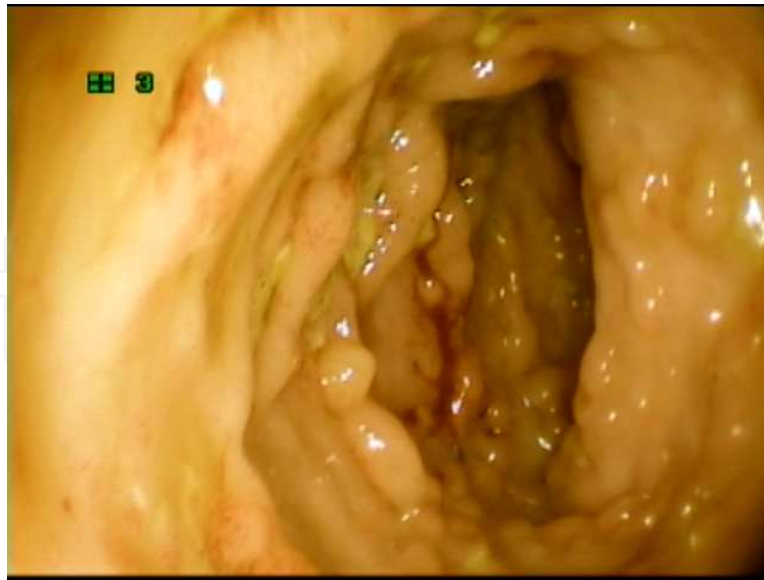


Figure 2. Crohn's disease

3.3.1. Bleeding after endoscopic procedures

Bleedings are rare and usually minor after gastrointestinal endoscopy diagnostic procedures, unless associated with anticoagulant therapy, thrombocytopenia and portal hypertension. Postbiopsy bleedings are minor and stop spontaneously. Upper endoscopy with biopsy diagnosis is generally a safe procedure, even at a platelet count of 20,000/mm³; currently available data suggest that anticoagulation therapeutic target in appropriate doses and treatment with standard doses of NSAIDs are not associated with increased risk of bleeding. However, both biopsy and therapeutic procedures should be avoided if the platelet count is below 20,000/mm³ or if the anticoagulant treatment is overdosed.

4. Endoscopic therapeutical options

4.1. Endoscopic hemostasis

Endoscopic hemostasis is one of the most common applications of interventional endoscopy procedures [5], due to the bleeding frequency and vital digestive and immediate risk that these entail. Endoscopic hemostasis requires techniques used in combination to stop gastrointestinal bleeding. Correct identification of the source of bleeding is a very important step as approximately 2% of lesions are not identified at the first endoscopy. Once the source of bleeding is identified, the next step is the application technique and hemostasis and the initiation of the pharmacological treatment. "Second-look" endoscopy, defined as endoscopic revaluation 24-48 hours after successful hemostasis, is a controversial practice.

The main techniques used for endoscopic treatment of digestive bleeding are: **endoscopic ligation, injection techniques** (such as injection of adrenaline or of sclerosing substances);

laser therapy; argon plasma; thermocoagulation; electrocoagulation; mechanical techniques (metal clips, sewing equipment or equipment for mechanical suture).

Endoscopic ligation is indicated in digestive bleeding caused by rupture of esophageal varices, Dieulafoy's lesions rupture of varices stomach (lower but effective). It is based on fitting a Saeed ligator multiband type (4-6-8 ligatures) at the end of therapeutic endoscope before the examination. Consists of a plastic cylinder that is fitted with elastic bands that are issued by tractioning a wire (non-metal or metal) into the biopsy channel. Ligatures of the wire are at risk of trauma on channel biopsy, although this risk is reduced. Complications are possible: postligature ulcerations (higher risk for varicose gastric), bacteremia, postligature pain and strictures.

Endoscopic sclerotherapy uses a wide range of sclerosing agents [6, 7]: 70 degrees alcohol or absolute alcohol sodium morrhuate, ethanolamine oleate and polidocanol. The main indication is represented by gastric or esophageal varices. Alcohol is cheaper, but most endoscopy centers in developed countries are using polidocanol. To gastric varices, the preferred technique is injecting N-butyl-2 cyanoacrylate histoacryl (super glue) through a special catheter. The main risks are the pulmonary embolism, as well as sticking of the biopsy channel of the catheter, which resulted in serious damage in endoscope and even irreversible. Varicose esophageal varices may be associated with risk of stricture of bacteremia and chest pain.

Sclerosing technique is relatively as simple as endoscopic ligation. Varicose is done by entering the sheath sclerotherapy biopsy channel, with the needle inside (to avoid damage to the biopsy channel). At the end of the sheath when viewing off peak endoscope, remove the needle from the sheath and inject about 1-2 ml tangent in variceal path immediately below the bleeding, repeating the procedure in the four quadrants. The maneuver can be repeated if bleeding is not found to stop within 1-2 minutes. Higher doses may be associated with local necrosis.

After the endoscope advances to the identified place, the endoscopist can place the tip of the endoscope immediately in place, as close as possible to the variceal path of the ligation cylinder. Maintaining aspiration, one can apply a ligature by tractioning the ligation wire, continuing for 2-3 seconds after the aspiration application of the ligature. Then repeat the procedure in the four quadrants and the variceal tracts projecting from the lower to the portion on top of the esophagus.

Injection of hemostatic solutions is useful in gastric ulcers, duodenal or anastomotic, Mallory-Weiss syndrome even more effective in bleeding tumors or bleeding Dieulafoy's lesions postpolypectomy [7]. The 1/10000 adrenaline solution used is prepared by diluting 1 ml adrenaline in 1/1000 9 ml saline. The needle sheath channel biopsy is used as in sclerotherapy of esophageal varices. Injection of adrenaline around the lesion is bleeding in all four quadrants, starting with the most distal point. The favorable effect is visible through bleaching and raising the lining around the area where the injection is stopping bleeding. Electrocoagulation consists in the application of high-power frequency of the tissue directly, resulting in a local heat of 100°C. Thus, the bleeding vessel is closed by coagulation necrosis of the surrounding tissue and the vascular wall. Efficiency of the method is shown in 80-95% of patients. The multipolar electrocoagulation version is the most common today, consisting of applying three

equally spaced bipolar electrodes. Multipolar electrocoagulation eliminates some drawbacks of monopolar as unpredictable depth of tissue damage, adherence of tissue and mobilization of clots.

The effectiveness of coagulation is expressed by flattening or even depression visible vessel, which indicates the need for pressure, otherwise rebleeding might occur. Both coagulation and polypectomy require an endoscopy laboratory device electrosurgical cutting and coagulation current. Thermocoagulation is defined as a source of bleeding and coagulation by means of an aluminum spatula coated with Teflon. The tool can be irrigated with a jet of water to prevent the accumulation of debris and tissue clots on it. The method of coagulation is similar to electrocoagulation.

Mechanical techniques include applying metallic clips and use of sewing machines and equipment for mechanical suture. The available applicators clips are placed on the biopsy channel and are applied by pressing the clip, then applicator detachment clip applicator is withdrawn, with the clip remaining at the bleeding.

The primary indication is bleeding from larger vessels, but can be used for closure of holes or iatrogenic postpolypectomy perforation. Both for hemostasis as well as for the treatment of perforations recommend using multiple clips at the same lesion site.

Argon plasma coagulation (APC) requires argon plasma apparatus with argon cylinders. Application is made from a distance of a few millimeters, without the need for direct contact with the mucosa. Safe coagulation is possible because the effect is limited to 3 mm depth [8]. Introducing excess gas is one of the adverse effects. The major indication is represented by angiodysplasia or diffuse bleeding from the rectum, but can also be used for palliative purposes such as radical digestive tumors. Adenomatous tissue remnants can be destroyed, postpolypectomy being useful in supplementing it. The laser can stop the bleeding by vasoconstrictive properties associated with protein wall degradation and dehydration, but its use in endoscopic hemostasis is reduced.

5. Endoscopic treatment of some of the most prominent gastrointestinal bleedings

5.1. Endoscopic treatment of variceal bleeding

Endoscopic sclerotherapy involves injecting sclerosing substances that cause coagulation necrosis and induces instantaneous and local thrombosis. Endoscopic sclerotherapy is superior to conservative measures, with a success rate of about 90% for the control of variceal bleeding; early rebleeding frequency decreases and increases survival [9].

Thrombosis of esophageal varices is achieved by endoscopic injection of sclerotic agents (absolute alcohol, sodium morrhuate 5%, ethanolamine oleate 5-10%, 1-2% sodium tetradecyl sulfate) just above the esogastric junction. Paravariceal injections are performed, both intra-

variceal or combinations. Comparative studies of the effectiveness of different substances are numerous, but the relative effectiveness of different substances is not clear.

The risk of rebleeding and complications is high. The most common cause of esophageal ulcers appears to be massive rebleeding and mortality of 2-3%. Almost all patients have fever, transient dysphagia and chest pain. Other possible complications are chest pain, aspiration pneumonia, pleural effusions and mediastinitis [10, 11]. Frequency of complications depends on the experience of the operator and is proportional to the amount of sclerosant injected; and mortality induced complications are between 2-5%.

Endoscopic variceal ligation uses small rubber rings or strips of nylon for varicose veins occlusion, promoting hemostasis by physical contraction, followed by local thrombosis. Ligation with multiple lanes is used which allows strangulation of esophageal tract, followed by local necrosis. Variceal path is drawn in clear plastic a cylinder loaded with elastic bands, followed by the release of the first bands. The effectiveness of elastic ligatures is similar to sclerotherapy to control acute bleeding esophageal varices rupture, the success rate of approximately 90%. The number of sessions required for eradication is significantly lower compared with sclerotherapy.

Complications are significantly reduced and mainly consist of dysphagia or esophageal ulcers. However, esophageal ulcers laid after ligation tend to be small, with low risk of perforation and strictures. Aspiration pneumonia is a complication of endoscopic examination in the context of upper gastrointestinal bleeding [12]. A recently described complication consisted of ligation circumference esophageal strictures after pushing to form a band with the endoscope into the stomach [13].

Compared with sclerotherapy, endoscopic ligation gives better results in terms of frequency of complications, prolonged survival but also a better control of active bleeding [14-16]. Meta-analysis of published studies demonstrated that esophageal varices ligatures are significantly more effective than sclerotherapy variceal rebleeding prevention, with fewer sessions needed on average for eradication and fewer major complications [17]. Endoscopic ligation efficiency of endoscopic sclerotherapy is superior to the use of somatostatin or octreotide drug therapy [16, 17]. Usually, six elastic bands are used in the ligation sessions. Using a higher number of bands is not associated with a higher efficiency and is accompanied by an increased time of the procedure [18].

Endoscopic treatment by ligation of esophageal varices is more effective than medical therapy in active variceal bleeding and to prevent early rebleeding [19]. Other options included the use of cutouts (Endoloop) compared with elastic ligatures that appeared to have a similar efficiency [20]. Plastic mini-loops (nylon) are passed through the biopsy channel and placed on the inside of the cylinder. Similar elastic bands in variceal path are drawn into the transparent cylinder, and then loop is detached and tightened. Similar elastic bands and sclerotherapy detachable loops are associated with these possible complications: esophageal ulcers laid, laid pierce, strictures and infections. Although the authors consider cutouts as an option compared to treatment with elastic ligatures, this method has not gained popularity due to technical difficulties using cutouts in acute hemorrhage.

5.2. Gastric varices

In esogastric varices Type I (continuation of esophageal along the lesser curve gastric), treatment should be similar to HDS treatment of esophageal varices rupture. If gastric varices are isolated using adhesive agents (N-butylcyanoacrylate, isobutyl-2-cyanoacrylate and thrombin), endoscopic ligation compared with sclerotherapy and alcohol is superior to a better initial control of bleeding and rebleeding rate of less [21, 22]. In a recent pilot study of a new adhesive agent, 2-octyl cyanoacrylate appears to be as effective in obtaining hemostasis and prevents rebleeding from initial background varices [23].

Other invasive treatments (TIPS, surgical shunts, splenectomy, retrograde transvenous obliteration balloon occlusion) are still used. An attractive option was to use elastic ligatures or cutouts, which are being evaluated, taking into account the low efficiency of sclerotherapy.

Endoscopic obstruction by 2-cyanoacrylate isobutyl (bucrylate) or 2-cyanoacrylate N-butyl- (histoacryl) is used for large esophageal or gastric varices. The mechanism of action consists in polymerization and rapid solidification after intravariceal injection. Complications include emboli (lung, kidney, brain, etc.) in up to 5% of the patients, the passage of the adhesive through the inferior vena cava or gastroduodenal or damage to the endoscope (channel occlusion) or needle impaction varices. Dilution with lipiodol is preferred since the polymerization process delays by 20 sec [24].

In the absence of tissue adhesives, conventional endoscopic techniques involve the use of elastic ligatures with or without combinations with sclerotherapy. Sclerotherapy classic sclerosing substance is not currently listed, complications are due to large and high frequency of severe and fatal rebleeding [24]. Elastic ligatures combined use of sclerotherapy with cyanoacrylate seems to be superior to simple methods [25, 26].

Combined treatment (ligatures + sclerotherapy) in patients with gastric variceal bleeding assets seems very promising, 100% taking into account initial hemostasis (after ligation and injection of 1% polidocanol into the neighboring submucosa) [27]. These promising results will be confirmed in prospective studies with large numbers of patients. Retrograde transvenous obliteration occlusion balloon is a method recently used with good results in patients with gastric and gastroduodenal varices [28, 29]. Left adrenal vein is cannulated through a retrograde path from the right femoral vein or right internal jugular vein. After vein occlusion, left renal venography is performed and sclerosating agents are injected (ethanolamine oleate) mixed with iopamidol, with radiological control up to complete filling of gastric varices. Compared to treatment with TIPS, transvenous obliteration has the same proportion of hemostasis, rebleeding and encephalopathy, the major drawback being that it cannot be performed in patients with gastroduodenal varices [18].

5.3. Non-variceal upper gastrointestinal bleedings

Endoscopic treatment allows definitive stop of active bleeding in over 90% of the cases [30-32]. Meta-analysis of published studies have clearly indicated that active bleeding stops endoscopic treatment in most cases and significantly reduces the frequency of rebleeding, transfusion requirements, emergency surgical interventions and mortality [33-35]. Mortality is

directly correlated with rebleeding, both dependent on different variables and clinical stigmata of bleeding as defined by Forrest classification. A consensus was reached that endoscopic treatment must be performed only in patients with increased risk of bleeding or rebleeding and thus increased mortality [36].

Patients with active bleeding (Forrest Ia and b) and visible vessel (Forrest IIa) are treated by endoscopy. Although initial studies recommended treatment of ulcers with adherent clot (Forrest IIb), several recent studies have demonstrated these patients require treatment by endoscopic removal of the adherent clot [37, 38]. Patients with pigment spots in the ulcer crater (Forrest IIc) or clean base (Forrest III) did not receive endoscopic treatment; with a low frequency of rebleeding, a proton pump inhibitor treatment is sufficient. Different endoscopic hemostasis treatments are currently available for endoscopic hemostasis: injection (adrenaline or sclerosing agents), thermal methods (argon plasma coagulation or multipolar) or mechanical methods (clips, ligatures elastic). The primary hemostasis is achieved in over 95% of cases, rebleeding seen in 5-10% of patients, respectively mortality of approximately 5% [39]. However, there is an extremely high variability of methods used and results obtained from different centers, probably due to experienced endoscopists and risk category included for patients (age, associated diseases, etc.) [40].

5.4. Hemostasis injection

Endoscopic hemostatic treatment by injection is applied using a metal retractable catheter needle, which is inserted through the biopsy channel of the endoscope. Live view of the needle tip allows precise positioning of endoscopic control. If the lesions are located at tangential face of needle, the needle can be removed to cling to the lining and to facilitate positioning catheter. Injection of epinephrine 1:10,000 is used frequently in ulcer bleeding but can be used on other types of non-variceal lesions). Injection of epinephrine 1:10,000 has very few risks and complications. The risk of perforation is also negligible. According to a recent study, it was shown that injection of submucosa adrenaline can cause significant hemodynamic changes that can lead to severe cardiac adverse effects [41]. In this regard, monitoring heart after administration of epinephrine is the recommended cautious attitude more especially when used in large doses. In the treatment of bleeding lesions, esophagus total dose of adrenaline should be carefully titrated and should be used with a minimum dose that can achieve hemostasis. Sclerosing substances are generally reserved for hemostasis in patients with variceal bleeding, especially for esophageal varices. Histoacryl (N-butyl-2-cyanoacrylate) is a tissue adhesive which instantly coagulates in contact with blood. Injection of the varices histoacryl determines the solidification path of the variceal occlusion by inducing thrombosis vein, being used mainly for gastric varices. Rubber band ligation is not effective in mucous coating and is gradually affected by exulceration favoring the use of extrusion solidified adhesive, with the emergence of a profound ulcer. The main complication consists of glue embolization at brain and lung.

Thermal hemostasis methods can be divided into direct contact and non-contact thermal coagulation. Non-contact coagulation refers to the use of laser treatment or argon plasma coagulation jet. Coagulation is used in baked, i.e. non-variceal, hemorrhage when a vessel is visible. There are significant differences between monopolar coagulation probes, bipolar and

multipolar heater samples and the mechanism of action is similar [42]. Area bleeding or visible vessel is compressed while applying electrical or thermal energy in pulses that lasts up to 8 consecutive seconds. The preferable accessories are large (3.2 mm) and a current of 15-25 W. The application of thermal energy in the absence of compression of the vessel wall may worsen breakthrough of bleeding vessel wall. The risk of perforation is substantially increased in acute ulcers approached by thermal coagulation.

Argon plasma coagulation (APC) transmits heat to tissues through ionized gas and does not require direct contact probe to target lesion. APC cannula is placed 1-2 mm distance from target lesion and activated to induce coagulation of tissue surrounding surface. The risk of perforation is lower, excluding attachment of the cannula tube to the wall tract. Argon plasma coagulation is used for the treatment of superficial injury of vascular malformation type. In addition, APC was elastic ligatures used in combination with secondary prophylaxis variceal bleeding due to reduction of variceal recurrence. Although they are highly effective achieving hemostasis, mechanical devices are extremely difficult to place in lesions that are difficult to reach (small gastric curvature and posterior wall of the duodenum).

Metal clips are similar to surgical sutures and can be placed endoscopically under direct vision. Two to five clips are generally placed for achieving hemostasis in the area of bleeding or visible vessel. The main advantage lies in the absence of tissue damage and the possibility of using in deep ulcers or large blood vessels. Videos can also be used to close small punctures on them, although difficult to locate, especially when using tangential or ulcers central fibrosis.

Elastic ligatures are currently considered the treatment of choice for the rupture of esophageal varices. Elastic ligatures are particularly effective for stopping jet bleeding (spurting), although equally difficult to place in conditions like fibrosis of ulcers [43-45]. Placement is facilitated by the injection of mucosa adrenaline 1:10,000. Both clips as well as elastic ligatures are relatively easy to place and have good efficiency in cases of non-variceal HDS of due to non-ulcer: Mallory-Weiss syndrome, arteriovenous malformations, Dieulafoy's lesion, or bleeding postpolypectomy, such as endoscopic mucosa resection [46-48]. Rebleeding seems to be greatly reduced by using mechanical hemostasis (clips or ligatures) versus adrenaline injection in patients with Dieulafoy's lesions [49]. Removable clips were initially used to reduce bleeding occurring after the resection of formations protruding the mucosa, tailored with a plastic cylinder used for variceal bleeding. In patients with chronic colitis with HDS, non-variceal hemostasis is more effective in combination by applying heat treatment and injection.

Hemostasis techniques may be ineffective in a variable number of cases. In these situations, alternative techniques are used which include coagulation jet argon plasma (APC) or mechanical devices (metal clips, ligatures removable nylon elastic loops) [50-52]. Good results occur after placement of the ligatures, elastic, in particular small lesions (Dieulafoy's lesions, hemangiomas, small ulcers <1 cm, etc.).

5.5. Rebleeding and "second-look" endoscopy

Active bleeding cannot be controlled by endoscopic and it requires emergency surgical intervention [53]. Patients who rebleed after endoscopic treatment must repeat endoscopy to confirm the source of bleeding and bleeding stigmata. After rebleeding, endoscopic retreat-

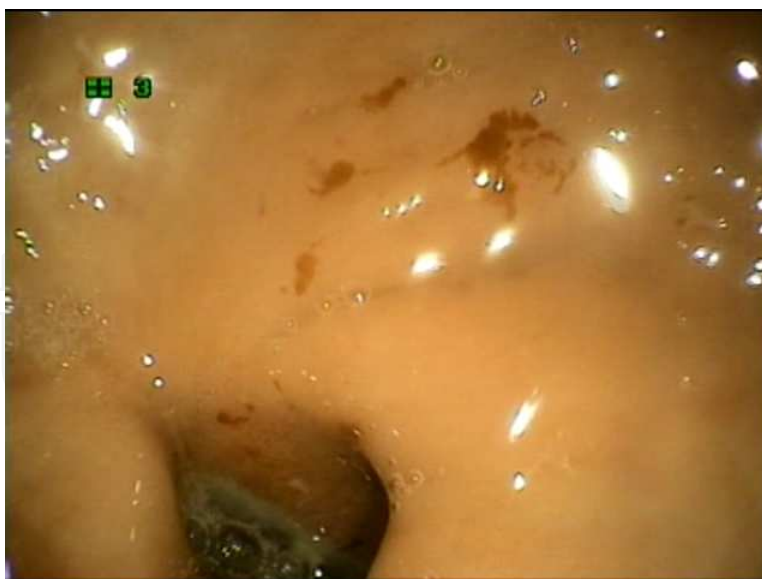

Figure 3. Gastric angiodysplasia and duodenal ulcer

ment intervention is comparable to surgical prognosis [54]. The management of rebleeding after endoscopic treatment and correct medical treatment depend largely on local expertise and clinical judgment [53]. Endoscopic or surgical treatment decision after rebleeding obviously depends on the age, associated diseases and bleeding stigmata. Thus, a patient duodenal ulcer with a giant rear face with stigmata of recent hemorrhage requires surgical intervention, while a young patient without leather rot associated with a small curvature gastric ulcer on endoscopy can be restated. “Second-look” endoscopy is controversial, published studies have demonstrated only a smaller proportion of rebleeding, but the same survival and required surgical intervention [55]. Repeat endoscopy is indicated in patients with clinical suspicion of rebleeding (hematemesis, melena, tachycardia, decreased pressure). Although some patients require direct surgical intervention, the majority of repeat endoscopy are indicated to confirm rebleeding [53].

5.6. Vascular malformations

Vascular malformations laid comprise several entities: angiodysplasia (Figure 3), telangiectasia (Osler-Weber disease, Rendu syndrome or Turner CREST) phlebectasia (varicosities and well-defined circular) and hemangiomas. Moreover, although endoscopically identified as a possible cause of bleeding, they cannot be differentiated based on endoscopic appearance. The diagnosis of leather rot are used and other imaging techniques such as angiography or, more recently, positron endoscopic optical coherence Doppler (Doppler optical coherence tomography) is a method that detects different vascular patterns [56].

Angiodysplasia (Figure 3) are found within 5% of gastrointestinal bleeding higher, being more common in the stomach, duodenum and proximal portion small intestine. Prevalence of angiodysplasia appears to be greater in patients with chronic renal insufficiency. Endoscopic treatment was performed along time with different methods (injection, multipolar electroco-

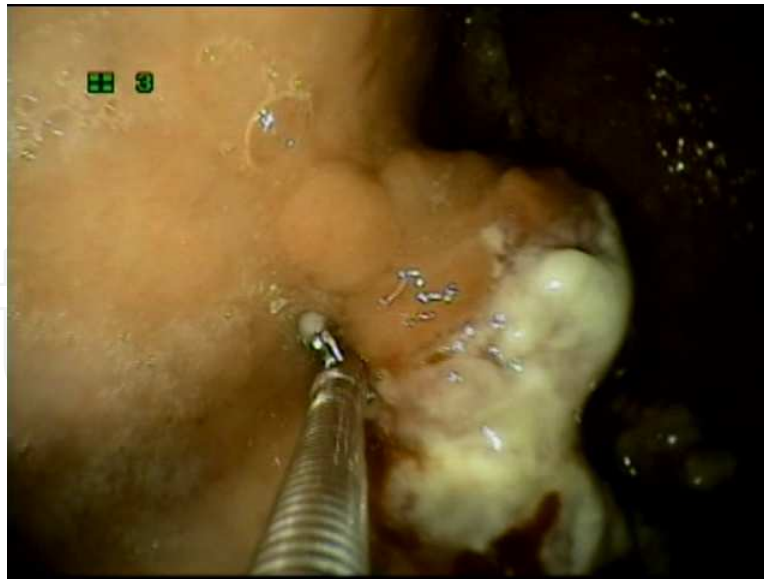


Figure 4. Gastric adenocarcinoma

gulation and bimechanical methods), but the degree of success is variable. Rebleeding is frequently encountered by all forms of treatment, due to the presence of lesions that are multifocal, inaccessible and the potential for the formation of new lesions [57]. The most common method remains bipolar coagulation and laser treatment Nd: YAG [58]. Recent studies have indicated the usefulness of eradication lesions using argon plasma coagulation (APC) [59]. Isolated gastric angiodysplasia can be treated with elastic ligatures [60]. Multiple other non-endoscopic treatments of angiodysplasia were tested with variable results: hormonal medication, administration of octreotide, antiangiogenic agents used in oncology and (thalidomide, lenalidomide bevacizumab, etc.), the management of acid aminocaproic [61-63]. Endoscopic treatment reduces the rebleeding and transfusion needs. Surgery is an indication only in cases with severe or acute hemorrhage in patients with severe anemia; persistent bleeding in the intestinal segment is usually well defined.

5.7. Gastrointestinal tumors

Gastrointestinal tumors are a common cause of non-variceal bleeding, most cases the gastric adenocarcinomas (Figure 4). Other tumors encountered are ampullary or duodenal tumor invasion of pancreatic head cancers, submucosal or metastatic tumors. Immediate survival of these patients is similar to other patients with non-variceal HDS, but prognosis term is reserved. Endoscopic treatment has limited benefits; endoscopic hemostasis has a role to delay until the intervention is definitive or palliative surgery. Inoperable patients may benefit from palliative treatment with laser or argon plasma.

5.8. Esophagitis and esophageal ulcers or contravention of junction esogastric

Reflux esophagitis occurs due to prolonged contact of contents of peptic esophageal mucosa and being characterized pathologically by esophageal mucosal inflammatory lesions that are

potential sources of bleeding [64]. 5% of reflux esophagitis and be complicated by gastrointestinal bleeding. It can be located at esogastric junction or mucosal metaplasia of Barrett's esophagus, requiring repeat biopsies to exclude esophageal cancer that can develop within the lesion. Reflux esophagitis occurs frequently in the presence of hiatal hernia. In the context of the presence of hiatal hernias, large Cameron ulcers can occur, which are longitudinal ulcers identified in approximately 1/3 of patients [65].

Esophagitis can occur during or after radiation treatment for lymphoma, lung cancer, breast cancer or other mediastinal malignancies. These patients have increased risk of developing esophageal cancer in a few years. Acute necrotizing esophagitis (black esophagus) is a particular form of severe damage to the esophagus, rarely met, but frequently associated with upper gastrointestinal bleeding. It generally appears in patients with severe general condition, with cancer or after severe infections.

5.9. Erosive gastritis and hemorrhagic gastropathy

Erosive gastritis stress and hemorrhagic gastropathy accounts for 25% of cases of non-variceal bleedings [64]. Stress gastritis generally occurs in patients with shock, burns, sepsis, severe trauma, multiple organ insufficiency after complicated surgical interventions and so on. In general, stress gastritis is characterized by the occurrence of multiple superficial gastric ulcers, with diffuse bleeding. These lesions are located initially at the back of the gastric body then extend throughout the gastric surface. In most patients the bleeding stops spontaneously, but medical treatment and angiographic or surgical excision may be necessary to a small fraction of patients [64]. Prophylaxis of stress gastritis is much more important, being necessary to prevent bleeding by increasing digestive intragastric pH above 4. Hemorrhagic erosive gastropathy consists of multiple erosive and subepithelial bleeding, endoscopic views, which may cause digestive bleeding. These injuries occur in different clinical circumstances, the most common being the intake of NSAIDs, aspirin and alcohol. Bleeding from gastric and gastropathy have low severity, stop spontaneously, and mortality is relatively low. Stop the NSAID or aspirin and patients are treated with standard PPI doses. Endoscopic treatment is not necessary.

Author details

Paul Mitrut, Liliana Streba*, Anca Oana Docea, Adina Kamal, Sorin Ioan Zaharie ,
Nicolae-Dragoş Mărgăritescu and Costin Teodor Streba

*Address all correspondence to: lilianastreba@gmail.com

University of Medicine and Pharmacy of Craiova, Romania

References

- [1] Dennis MJ. Endoscopic screening for varices in cirrhosis: findings, implications, and outcomes. *Gastroenterology* 2002;122(6):1620-30.
- [2] Laine L, Cohen H, Sloane R, Marin MS, Weinstein WM. Interobserver agreement and predictive value of endoscopic findings H. pylori and gastritis in for normal volunteers. *Gastrointest Endosc* 1995;42:420-3.
- [3] De Lange T, Larsen SL. Image Aabakken documentation of endoscopic findings in ulcerative colitis: photographs or video clips? *Gastrointest Endosc* 2005;61(6):715-20.
- [4] Cotton PB, Williams CB. Recognition of lesions. In: Cotton PB, Wiliams CB. (eds.) *Practical Gastrointestinal Endoscopy. The Fundamentals*, fifth edition, Blackwell Publishing, 2003; pp. 49-53.
- [5] Henrion J, Schapira M, Ghilain JM, et al. Upper gastrointestinal bleeding: what has changed during the last 20 years? *Gastroentérol Cliniq Biologiq* 2008;32:839-47.
- [6] Celinski K, Cicho-Lach H, Mydro A, et al. Non-variceal upper gastrointestinal bleeding guidelines on management. *J Physiol Pharmacol* 2008;59(2):215-29.
- [7] Aabakken L. Nonvariceal upper gastrointestinal bleeding. *Endoscopy* 2005;37:195-200.
- [8] Celinski K, Cicho-Lach H. Therapeutic endoscopy in gastroenterology. *J Physiol Pharmacol* 2007;58(3):33-41.
- [9] Sampliner RE. Barrett's esophagus: electrocoagulation. *Gastrointest Endosc* 1999;49:S17-9.
- [10] Hayes PC, Ferenci P. Portal hypertension. *Eur J Gastroenterol Hepatol* 2001;13:307-8.
- [11] Bhasin DK, Siyad I. Variceal bleeding and portal hypertension: new lights on old horizon. *Endoscopy* 2004;36:120-9.
- [12] Bhasin DK, Malhi NJS. Variceal bleeding and portal hypertension: much to learn, much to explore. *Endoscopy* 2002;34:119-28.
- [13] Saftoiu A, Ciurea T. Aphagia caused by accidental banding of the esophageal circumference: how much can we ligate? *Endoscopy* 2002;34:1030-1.
- [14] Stiegmann GV, GoV JS, MichaletzOnody PA, et al. Endoscopic sclerotherapy as compared with endoscopic ligation for bleeding esophageal varices. *N Engl J Med* 1992;326:1527-32.
- [15] Lo GH, Lai KH, Cheng JS, et al. A prospective, randomized trial of sclerotherapy versus ligation in the management of bleeding esophageal varices. *Hepatology* 1995;22:466-71.

- [16] Laine L, Cook D. Endoscopic ligation compared with sclerotherapy for treatment of esophageal variceal bleeding. A meta-analysis. *Ann Intern Med* 1995;123:280-7.
- [17] Gross M, Schiemann U, Muhlhofer A, Zoller WG. Meta-analysis: efficacy of therapeutic regimens in ongoing variceal bleeding. *Endoscopy* 2001;33:737-46.
- [18] Ramirez FC, Colon VJ, Landan D, Grade AJ, Evanich E. The effects of the number of rubber bands placed at each endoscopic session upon variceal outcomes: a prospective, randomized study. *Am J Gastroenterol* 2007;102:1372-6.
- [19] Vlavianos P, Westaby D. Management of acute variceal haemorrhage. *Eur J Gastroenterol Hepatol* 2001;13:335-42.
- [20] Naga MI, Okasha HH, Foda AR, et al. Detachable endoloop vs. elastic band ligation for bleeding esophageal varices. *Gastrointest Endosc* 2004;59:804-9.
- [21] Sarin SK, Jain AK, Jain M, Gupta R. A randomized controlled trial of cyanoacrylate versus alcohol injection in patients with isolated fundic varices. *Am J Gastroenterol* 2002;97:1010-5.
- [22] Lo GH, Lai KH, Cheng JS, Chen MH, Chiang HT. A prospective, randomized trial of butyl cyanoacrylate injection versus band ligation in the management of bleeding gastric varices. *Hepatology* 2001;33:1060-4.
- [23] Rengstorff DS, Binmoeller KF. A pilot study of 2-octyl cyanoacrylate injection for treatment of gastric fundal varices in humans. *Gastrointest Endosc* 2004;59:553-8.
- [24] Mumtaz K, Majid S, Shah H, et al. Prevalence of gastric varices and results of sclerotherapy with N-butyl 2 cyanoacrylate for controlling acute gastric variceal bleeding. *World J Gastroenterol* 2007;13:1247-51.
- [25] Joo HS, Jang JY, Eun SH, et al. Long-term results of endoscopic histoacryl (N-butyl-2-cyanoacrylate) injection for treatment of gastric varices—a 10-year experience. *Korean J Gastroenterol* 2007;49:320-6.
- [26] Sugimoto N, Watanabe K, Watanabe K, et al. Endoscopic hemostasis for bleeding gastric varices treated by combination of variceal ligation and sclerotherapy with N-butyl-2-cyanoacrylate. *J Gastroenterol* 2007;42:528-32.
- [27] Arakaki Y, Murakami K, Takahashi K, et al. Clinical evaluation of combined endoscopic variceal ligation and sclerotherapy of gastric varices in liver cirrhosis. *Endoscopy* 2003;35:940-5.
- [28] Imazu H, Seewald S, Omar S, Zhong Y, Soehendra N. Endoscopic treatment for portal hypertension: what's new in the last 12 months? *Endoscopy* 2005;37:116-21.
- [29] Choi YH, Yoon CJ, Park JH, et al. Balloon-occluded retrograde transvenous obliteration for gastric variceal bleeding: its feasibility compared with transjugular intrahepatic portosystemic shunt. *Korean J Radiol* 2003;4:109-16.

- [30] Laine L, Peterson WL. Bleeding peptic ulcer. *N Engl J Med* 1994;331:717-27.
- [31] Lichtenstein DR. Nonvariceal upper gastrointestinal hemorrhage. In: Wolfe MM. (ed.) *Therapy of Digestive Diseases*, W.B. Saunders, 2000; 10: pp. 127-152.
- [32] Stollman NH, Putcha RV, Neustater BR, et al. The uncleared fundal pool in acute upper gastrointestinal bleeding: Implications and outcomes. *Gastrointest Endosc* 1997;46:324-7.
- [33] Sacks HS, Chalmers TC, Blum AL et al. Endoscopic therapy: an effective therapy for bleeding peptic ulcers. *JAMA* 1990;264:494-9.
- [34] Cook DJ, Guyatt GH, Salena BJ, Laine L. Endoscopic therapy for acute nonvariceal upper gastrointestinal hemorrhage: a meta-analysis. *Gastroenterology* 1992;102:139-48.
- [35] Chung SC. Peptic ulcer bleeding. *Am J Gastroenterol* 2001;96:1-3.
- [36] Bini EJ, Cohen J. Endoscopic treatment compared with medical therapy for the prevention of recurrent ulcer hemorrhage in patients with adherent clots. *Gastrointest Endosc* 2003;58:707-14.
- [37] Jensen DM, Kovacs TO, Jutabja R, et al. Randomized trial of medical or endoscopic therapy to prevent recurrent ulcer hemorrhage in patients with adherent clots. *Gastroenterology* 2002;123:407-13.
- [38] Laine L, Stein C, Sharma V. A prospective outcome study of patients with clot in an ulcer and the effect of irrigation. *Gastrointest Endosc* 1996;43:470-3.
- [39] Church NI, Palmer KR. Ulcers and nonvariceal bleeding. *Endoscopy* 2003;35:22-6.
- [40] Mahadeva S, Linch M, Hull M. Variable use of endoscopic hemostasis in the management of bleeding peptic ulcers. *Postgrad Med J* 2002;78:347-51.
- [41] Von Delius S, Thies P, Umgelter A, et al. Hemodynamics after endoscopic submucosal injection of epinephrine in patients with nonvariceal upper gastrointestinal bleeding: a matter of concern. *Endoscopy* 2006;38:1284-8.
- [42] Stiegmann GV, GoV GS. Endoscopic esophageal varix ligation: preliminary clinical experience. *Gastrointest Endosc* 1988;34:113-7.
- [43] Koutsomanis D. Endoscopic ligation in ulcer bleeding: a controlled trial. *Endoscopy* 1995;27:S18.
- [44] Tseng C, Burke S, Connors P, et al. Endoscopic band ligation for treatment of non-variceal upper gastrointestinal bleeding. *Endoscopy* 1991;23:297-8.
- [45] Matsui S, Inou I, Takahei K, et al. Endoscopic band ligation for hemostasis of non-variceal upper gastrointestinal bleeding. *Endoscopy* 1996;28:S67.

- [46] Soehendra N, Sriram PVJ, Ponchon T, Chung SCS. Hemostatic clip in gastrointestinal bleeding. *Endoscopy* 2001;33:172-80.
- [47] Abi-Hanna D, Williams SJ, Gillespie PE, et al. Endoscopic band ligation for non-variceal upper gastrointestinal hemorrhage. *Gastrointest Endosc* 1998;48:510-4.
- [48] Wong RM, Ota S, Katoh A, et al. Endoscopic ligation for non-esophageal variceal upper gastrointestinal hemorrhage. *Endoscopy* 1998;30:774-7.
- [49] Chung IK, Kim EJ, Lee MS, et al. Bleeding Dieulafoy's lesions and the choice of endoscopic method: comparing the hemostatic efficacy of mechanical and injection methods. *Gastrointest Endosc* 2000;52:721-4.
- [50] Chau CH, Siu WT, Law BKB, et al. Randomized controlled trial comparing epinephrine injection plus heat probe coagulation versus epinephrine injection plus argon plasma coagulation for bleeding peptic ulcers. *Gastrointest Endosc* 2003;57:455-61.
- [51] Chou Y-C, Hsu P-I, Lai K-H, et al. A prospective, randomized trial of endoscopic hemoclip placement and distilled water injection for treatment of high-risk bleeding ulcers. *Gastrointest Endosc* 2003;57:324-8.
- [52] Matsui S, Kamisako T, Kudo M, et al. Endoscopic band ligation for control of nonvariceal upper GI hemorrhage: comparison with bipolar electrocoagulation. *Gastrointest Endosc* 2002;55:214-8.
- [53] Targownik LE, Murthy S, Keyvani L, Leeson S. The role of rapid endoscopy for high-risk patients with acute nonvariceal upper gastrointestinal bleeding. *Can J Gastroenterol* 2007;21:425-9.
- [54] Lau JY, Sung JJY, Lam T, et al. Endoscopic retreatment compared with surgery in patients with recurrent bleeding after initial endoscopic control of bleeding ulcers. *N Engl J Med* 1999;340(10):751-6.
- [55] Rollhauser C, Fleischer DE. Nonvariceal upper gastrointestinal bleeding: an update. *Endoscopy* 1997;29:91-105.
- [56] Yang VX, Tang SJ, Gordon ML, et al. Endoscopic Doppler optical coherence tomography in the human GI tract: initial experience. *Gastrointest Endosc* 2005;61:879-90.
- [57] Lichtenstein DR. Nonvariceal upper gastrointestinal hemorrhage. In: Wolfe MM. (ed.) *Therapy of Digestive Diseases*, W.B. Saunders, 2000; 10: pp. 127-152.
- [58] Rollhauser C, Fleischer DE. Upper gastrointestinal nonvariceal bleeding: a review covering the years 1996-1997. *Endoscopy* 1998;30:114-25.
- [59] Delis V, Balatsos V, Vamvakousis V, et al. Elastic band ligation for gastric angiodysplasias. *Endoscopy* 1996;28:S65.
- [60] Mulder CJJ, den Hartog G, Thies JE. Pilot experience with argon plasma coagulation in gastrointestinal endoscopy. *Gastrointest Endosc* 1996;43:54-6.

- [61] Lewis B, Salomon P, Rivera-MacMurray S, et al. Does hormonal therapy have any benefit for bleeding angiodysplasia? *J Clin Gastroenterol* 1992;15:99-103.
- [62] Aabakken L. Nonvariceal upper gastrointestinal bleeding. *Endoscopy* 2001;33:16-23.
- [63] Saba HI, Morelli GA, Logrono LA. Treatment of bleeding in hereditary hemorrhagic telangiectasia with aminocaproic acid. *N Engl J Med* 1994;330:1789-90.
- [64] ASGE Standards of Practice Committee. ASGE guideline: the role of endoscopy in acute non-variceal upper GI hemorrhage. *Gastrointest Endosc* 2004;60:497-503.
- [65] Lin CC, Chen TH, Ho WC, Chen TY. Endoscopic treatment of a Cameron lesion presenting as life-threatening gastrointestinal hemorrhage. *J Clin Gastroenterol* 2001;33:423-4.

