

We are IntechOpen, the world's leading publisher of Open Access books Built by scientists, for scientists

6,900

Open access books available

185,000

International authors and editors

200M

Downloads

Our authors are among the

154

Countries delivered to

TOP 1%

most cited scientists

12.2%

Contributors from top 500 universities



WEB OF SCIENCE™

Selection of our books indexed in the Book Citation Index
in Web of Science™ Core Collection (BKCI)

Interested in publishing with us?
Contact book.department@intechopen.com

Numbers displayed above are based on latest data collected.
For more information visit www.intechopen.com



Echinococcosis — Rare Locations and Uncommon Clinical Manifestations

Antonio Di Cataldo[#], Giuseppe Petrillo[#], Claudia Trombatore[#],
Stefano Palmucci[#], Antonella Agodi[#], Martina Barchitta,
Annalisa Quattrocchi, Nunzio Crimi, Silvia Fichera, Stefano Puleo,
Amy Giarrizzo, Martina Calabrini, Rosalia Latino and Rosanna Portale

Additional information is available at the end of the chapter

<http://dx.doi.org/10.5772/61126>

Abstract

Echinococcosis is a zoonotic infection caused by tiny tapeworms of the genus *Echinococcus*. Cystic Echinococcosis, also known as hydatid disease, is caused by *Echinococcus granulosus* and rarely by *Echinococcus multilocularis*.

Although the worldwide incidence and prevalence of Echinococcosis dramatically decreased in the last decades, it remains a major public health issue in several countries, where the infection is currently considered an endemic disease.

The disease is characterized by cystic lesions especially in the liver and lungs. If the parasites go beyond the lung filter, it can spread to other locations that are classified as rare, very rare, or extremely rare locations.

In these rare locations, the disease is often asymptomatic and is frequently incidentally diagnosed.

Usually, there are mechanical clinical features that will be different according to the organ where the cyst is located. Serological tests, ultrasound, and imaging radiological studies are generally used in order to make the correct diagnosis.

Keywords: Echinococcosis, surgical procedures, operative, diagnostic imaging, parasitic diseases, infection

1. Introduction

Hydatid disease is a parasitic infection that is endemic in Mediterranean countries, but it is worldwide present in consequence of the migratory phenomena. The disease is characterized by cystic lesions especially located in the liver and in the lungs. If the parasite goes beyond the pulmonary filter, it can spread to other localizations that are classified rare, very rare, or extremely rare locations [1].

2. Epidemiology of Echinococcosis

Hydatid disease is known since the ancient times and Hippocrates first described it as being located in the liver. *Echinococcosis* is a major parasitic zoonosis, of public health importance worldwide, that in humans occurs in two main forms depending on the causative species: cystic *Echinococcosis* (CE, also known as hydatidosis) and alveolar *Echinococcosis* (AE), caused by the tapeworms *Echinococcus granulosus* and *E. multilocularis*, respectively. Both diseases can cause serious morbidity and death [2, 3] if the management is not correct, and both can be regarded as emerging or re-emerging diseases [4].

CE is globally distributed, with highly endemic areas mostly found in the eastern part of the Mediterranean region, northern Africa, southern and Eastern Europe, at the southern tip of South America, in Central Asia, Siberia, and western China. AE is confined to the northern hemisphere, in particular to regions of western and northern China, the Russian Federation, most countries of continental Europe, and northern countries of North America [3]. CE occurs commonly in Bulgaria, Poland, Slovenia, and in Spain and elsewhere in Eastern and Central Europe, it is considered a serious public health problem in Turkey. AE has also emerged in Central and Eastern Europe in association with increases in fox populations. The infection has been reported in Germany, Lithuania, Slovakia, Slovenia, and Switzerland [5].

CE has a renewed importance in Europe, as reemerging cases have been documented [6]. Furthermore, CE is reported in immigrants or persons with a history of travel to endemic areas [7]. Several national surveillance systems for CE and AE exist in European countries based on voluntary data entry or on compulsory notification [8].

The recent Annual epidemiological report on food and waterborne diseases and zoonoses of the European Centre for Disease Prevention and Control (ECDC) [8] relates that in 2012 the case rate of *Echinococcosis* was 0.19 cases per 100,000 population in the European Union and European Economic Area (EEA) countries. The rate of *Echinococcosis* has been fairly stable in the last years and the number of cases reported with AE has increased, most likely reflecting the increasing spatial distribution of the parasite in animals. The highest population-based risk was noted in Bulgaria, where the notification rate in 2012 was 23 times higher than the overall EU/EEA case rate (4.37 cases per 100,000 population; 39% of the reported number of cases in Europe). No significant differences were found in *Echinococcosis* rates by gender (male-to-female ratio: 0.98:1 in 2012). The highest case rate was in males aged 65 years old and over (0.22

per 100,000) followed by females aged 65 years old and over (0.17 per 100,000). Rates were generally higher in males than in females for cases aged 25 years and older. Notably, the higher rates observed in the elderly can be explained by the extensive incubation period of several years. Furthermore, no seasonality has been observed for *Echinococcosis*, as expected for a disease with a very long incubation period. The most frequently isolated species was *E. granulosus* (81%), followed by *E. multilocularis* (18%), and by other *Echinococcus* species (1%). Over the last five years, an increasing number of cases infected with *E. multilocularis* (AE) was observed and this is an important issue since untreated disease is often fatal. Notably, as highlighted by the ECDC [8], most European surveillance systems capture only a proportion of the cases occurring in their countries and some cases of disease remain undiagnosed or are diagnosed but not reported to public health authorities. Furthermore, the direct comparison of *Echinococcosis* rates between countries should be undertaken with caution. In fact, in most cases, differences in case rates reflect not only differences in the occurrence of the disease, but also in systematic differences in health and surveillance systems [8].

Mandatory notification of CE to the Italian Ministry of Health has been discontinued since 1991 (D. Min. San. 15.12.1991), and thus, the data on CE occurrence have only produced by the regional cases summaries. Therefore, information on CE distribution in Italy is still incomplete and insufficient and no data has been submitted for the European surveillance. However, an Italian Registry of CE was established by the Istituto Superiore della Sanità (<http://www.iss.it/riec/>). In Italy, the prevalence of the CE is high on the islands and medium in the central and southern regions of Italy [9–10] where farming and raising sheep are frequent activities, confirming that the disease is often an occupational one, and farming and raising sheep seem to be risk factors [11–12]. Data from the Italia registry reports that up to 75% of sheep and goats can be infected and up to 14 cases per 100,000 inhabitants (1,400 cases/year estimated) (<http://www.iss.it/riec/>).

As suggested, compulsory notification of *Echinococcosis* and harmonization of the data entry system are essential instruments for the surveillance of human diseases in order to make both clinical and epidemiological data accessible to clinicians, epidemiologists, and policymakers [12]. In fact, surveillance data are useful to assist policymakers and health leaders in making evidence-based decisions to plan and improve programs, services, and interventions for preventing, managing, and treating these diseases [8].

In 2013, the EchinoWorld website (www.echinoworld.org), sponsored by the International Association of Hydatidology, was developed. It provides a feasible and effective platform for professionals and scholars around world in the field of hydatid disease, with the aim to help prevention, diagnosis, and treatment especially in endemic countries and globally.

CE can be prevented by periodic deworming of dogs; improved hygiene in the slaughtering of livestock, including proper destruction of infected offal; and public education campaigns. Vaccination of livestock offers encouraging prospects for prevention and control. The World Health Organization reports that a program combining vaccination of lambs, deworming of dogs, and culling of older sheep could lead to the elimination of human cystic *Echinococcosis* in less than 10 years [3]. Because of the unique sylvatic nature of AE, it is one of the few helminth infections in Europe that is not linked to poverty and inadequate sanitation [1–5]. Prevention

and control of AE is particularly complex as the cycle involves wild animal species as both definitive and intermediate hosts. Regular deworming of domestic carnivores that have access to wild rodents should help to reduce the risk of infection to humans. However, sustainability and cost–benefit effectiveness of such campaigns are controversial [3].

3. Unusual locations of echinococcosis

About 90% of the hydatid cysts occur in the liver (65%–75%) and lungs (15%–20%), organs that can be affected simultaneously in about 5%–13% of the cases. If the cyst goes beyond the hepatic and pulmonary filters, it can spread to other organs. A possible dissemination through lymphatic channels could explain the presence of the cysts in uncommon sites [13].

The diameter of the parasite is about 25 microns–35 microns, and it can pass through the hepatic sinusoids (10 microns–100 microns), depending on the biophysical and structural features of the parasite, which has ameboid movements and different dimensions in the different stages of its biological cycle. It is as an emulsoid that adapts itself to the different diameters of the anatomic structures. Other factors such as pH, surface tension, and the presence of the colloids are also involved in explaining the passage of the parasite through the hepatic sinusoids. However, it is also possible that the parasite reaches the peripheral locations by passing the hepatic sinusoids through the presence of arteriovenous anastomoses or through anastomoses between the portal and hepatic veins. Furthermore, we should believe that the parasite is able to bypass the pulmonary capillary vessels in a similar way, otherwise, the incidence of the parasite in the lungs should be higher than in the liver [14].

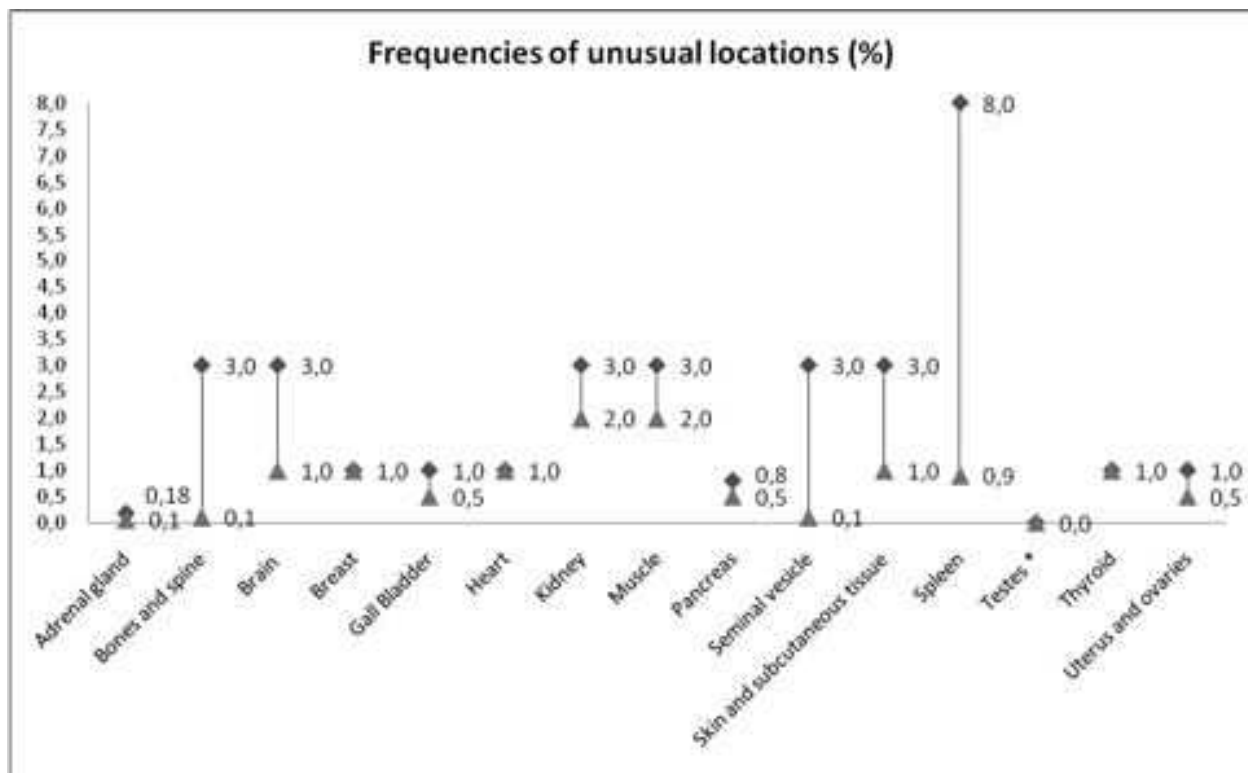
In 1964, Grassi classified the peripheral locations of the hydatid disease into three groups:

- a. rare locations: spleen, kidney, bone, muscle;
- b. very rare locations: diaphragm, pancreas, thyroid, brain, salivary glands, subcutaneous tissue;
- c. extremely rare locations: thymus, lymphatic nodes, adrenal gland, hypophysis, tonsils [1].

The percentage of site involvement varies and the exact incidence in unusual locations is about 8%–10%, but it is difficult to ascertain, as they are only reported as case reports [4].

Previous data reported that incidence of CE involving the spleen, kidney, peritoneal cavity, skin, and muscles was about 2–3% each and incidence of the heart, brain, vertebral column, ovaries, pancreas, gall bladder, thyroid gland, bones, and breast involvement was about 1% or less, each [15]. Figure 1 summarizes updated data on frequencies of unusual locations of CE as reported in different scientific articles.

A recent meta-analysis conducted in Iran where *Echinococcosis* is endemic, focused on the unusual locations (i.e., other than the liver and lung) diagnosed in the last 20 years (1990–2011). About 463 cases of the hydatid cyst located in different parts of the body, excluding the liver and lung, have been published from Iran. The most common locations were



* Only five case reports of testicular location

(Adrenal gland: Akcay et al., 2004 [42]; Bones and spine: Drimousis et al., 2006 [43]; Brain: Greenberg SM, 2001 [44]; Altas et al., 2010 [45]; Breast: McManus et al., 2003 [15]; Gall Bladder: Raza et al., 2003 [46]; Mushtaque et al., 2011 [47]; Heart: McManus et al., 2003 [15]; Kidney: Gogus et al., 2003 [48]; Muscle: Verasaci et al., 2005 [49]; Arora et al., 2011 [50]; Pancreas: Palaivelu C, 2007 [51]; Moosavi et al., 2007 [52]; Seminal vesicle: Vasileios et al., 2002 [53]; Safioleas et al., 2006 [54]; Skin and subcutaneous tissue: Zulfikaroglu et al., 2005 [55]; Dirican et al., 2008 [56]; Spleen: Polat et al., 2003 [57]; Testes: Tlili et al., 2014 [58]. Thyroid: McManus et al., 2003 [15]; Uterus and ovaries: Arora et al., 2005 [59]; Palaivelu C, 2007 [59])

Figure 1. Frequencies of unusual locations of cystic *Echinococcosis* as reported in different scientific articles.

the central nervous system (brain, spinal cord, and orbit), musculoskeletal system, heart, and kidney, whereas some less common locations were the spleen, pancreas, appendix, thyroid, salivary gland, adrenal gland, breast, ovary, retroperitoneum, and mediastinum [16].

With the advent of modern DNA-based methods, the genetic variability of *E. granulosus* was confirmed and a number of genotypes were recognized (named G1–G10). *E. granulosus* comprises several intraspecific variants or strains that have substantial variation at the genetic level. By contrast, there seems to be very limited genetic variation within *E. multilocularis* [17]. A recent study has reported results of analyses conducted on agents responsible for causing 10 cases of cerebral hydatid disease. Strain differentiation was possible for eight cases and all were found to be of the G6 genotype, suggesting that this genotype may have a propensity for infecting the brain [18]. Further genetic investigations in unusual localizations are recommended to evaluate a possible cluster of genotypes and or subtypes by different location in order to support differential diagnosis of *Echinococcosis* for any cystic mass found in patients, especially from endemic areas [4].

4. Diagnostic serological tests

Immunodiagnosis is an important tool for diagnosis of hydatid infection. The increase in serum IgE is characteristic for helminthic disease and is stimulated by the synthesis of IL-4 from Th2 lymphocytes [19]. Different serological tests were developed and applied. Usually, they detect anti-Echinococcus IgG, but there are also methods for examination of IgE in serum such as RAST (RIA), ELISA, and Western blot. The sensitivity of the ImmunoCAP system, in some studies, is significantly lower than the sensitivity of both the ELISA and Western blot. In contrast, the ImmunoCAP system demonstrated increased specificity and decreased cross-reactivity compared with the ELISA. Western blot remains the principle method for the detection of CE because of its significantly higher sensitivity. The lower sensitivity of the ImmunoCAP system for detecting anti-Echinococcus IgE compared with the tests for specific IgG can be explained by the stronger IgG response in CE. Comparison of anti-Echinococcus IgE in hepatic and pulmonary CE showed significant differences in the immune response that were not only qualitative (more often positive in hepatic CE) but also quantitative (lower antibody levels in pulmonary CE). While there was a detectable difference in anti-Echinococcus IgG by ELISA and Western blot, the discrepancy was not significant. In rare locations of the disease, that are often peripheric locations, serological tests have shown a lower sensitivity. In conclusion, detection of anti-Echinococcus IgE could be applied as an additional confirmatory method when false-positive results are suspected from other immunological tests [20].

5. Imaging features

Radiological signs of *Echinococcosis* are usually non-specific, and the serologic tests are necessary to confirm the diagnosis [21]. The liver (75%) and lungs (15%) are the most commonly involved organs, but the disease can be seen anywhere in the body (10%) [21–22]. Most typical imaging findings of the hydatid disease are cystic lesions in the affected organs; namely, imaging features vary according to the stage of cyst development [23]. In the early stage, the cysts usually show as a simple cyst, with a homogeneous fluid content with both CT attenuation values and MRI signal similar than water. Cystic content is generally hypointense on T1-weighted images, and homogeneously hyperintense on T2-weighted sequences. Then, imaging appearance may be slightly different due to the presence of intracystic debris, hydatid sand, and inflammatory cells. During the natural evolution of the hydatid cyst, a ring-like calcification of the cystic wall can be seen and this sign is more common in the liver, spleen, and kidney. However, calcification of the pericyst does not necessarily indicate death of parasite. It is, instead, highly likely when the cyst is completely calcified [24]. The endocyst may detach partially or completely from the pericyst causing “floating membranes” inside the cavity, a finding that is highly specific for hydatid disease. When there are daughter cysts inside the hydatid cyst, it appears multi-vesicular with a “honeycomb pattern” [22] (Figure 2); daughter vesicles are located peripherally and they usually contain fluid with a lower attenuation than that of the fluid in the mother cyst [24].

In addition to the liver and lungs, echinococcosis could be also found in different other organs; in these cases, the diagnosis could be difficult, and differential diagnosis is generally required.

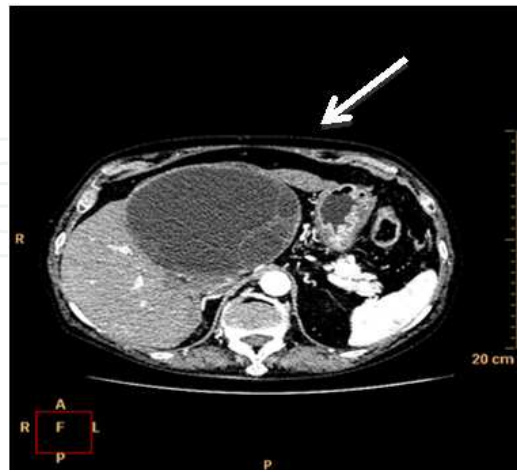


Figure 2. Typical hydatid cyst of the liver, with some peripheral daughter cysts (arrow).

Uncommon locations are briefly discussed, emphasizing imaging features.

Spleen is the most common affected organ after the liver and lungs and its involvement ranges from 0.9% to 8%. Primary splenic hydatidosis is rare (less than 2%) [22].

Splenic cysts are commonly solitary and often develop secondary to systemic dissemination or intraperitoneal spread from ruptured liver hydatid cysts. Differential diagnosis includes epidermoid cyst, pseudocysts, abscess, or hematoma; also cystic neoplasms should be differentiated from hydatid splenic disease [21].

Pancreas is involved very rarely (0.25% of the cases). Patients could experience specific symptoms as abdominal discomfort, nausea, and vomiting. In a case report described by Szanto et al., a hydatid pancreatic cyst was found on the tail of the pancreas, causing portal hypertension and splenic veins congestion [25]. In cases of pancreatic locations, lesions show typical imaging findings: cystic appearance, sometimes with wall calcifications and daughter cysts. Clear fluid content is generally represented as hypodense on CT images. Additionally, signs of vascular compression could be detected on CT and MR imaging. Differential diagnosis from other pancreatic cystic lesions (pseudocyst, serous cystadenoma, and mucinous cystic neoplasm) may be difficult; it is based on the presence of a more thickened and laminated cystic wall, often with thin calcifications.

Kidney is a rare location of Echinococcosis. Symptoms are often nonspecific and, when the cysts are intact and the antigenic stimulation is too low, imaging is crucial for a correct diagnosis [26]. Renal cysts are usually unilateral and located in the cortex of the upper or lower pole; they appear unilocular or multilocular if there are daughter cysts inside the parental cyst. Three types of cysts have been described by Ishimitsu [27]:

- type 1: unilocular cysts (initial stage of parasite development)

- type 2: multiple daughter cysts within the mother cyst (intermediate stage of parasitic development)
- type 3: completely calcified cysts (death of the parasite)

In type 1 and type 2 cysts, the cyst wall may be thick or calcified (Figure 3), and both the wall and the internal septa may show enhancement after e.v. administration of the contrast agent. In up to 18% of cases, the cyst may rupture into the collecting system and at imaging several round filling defects may be seen due to the migration of daughter cysts within calices and renal pelvis [24]. Differential diagnosis of renal hydatidosis includes simple or infected renal cyst, abscess, and cystic or necrotic neoplasms [22].

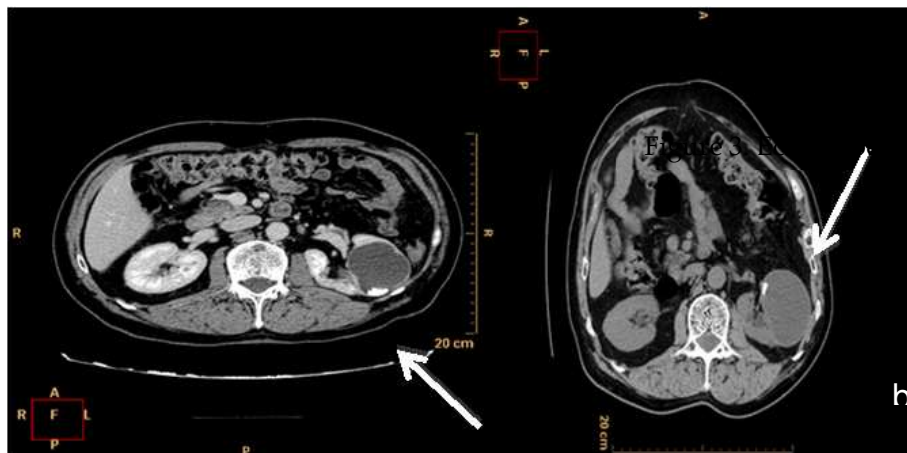


Figure 3. Unilocular hydatid cyst of the left kidney with internal calcifications that move (arrows) changing patient's decubit: supine (a) and on the right flank (b).

Hydatid cysts of the *adrenal gland* are very rare, with an incidence at autopsy of 0.06%–0.18%. They are usually secondary to a systemic *Echinococcosis* beyond the hepatic and the pulmonary filters.

Organs of female genital tract are rarely involved; first articles have been reported more than 50 years ago. It is generally associated to the developing of other parasitic cysts in the pelvis after the rupture of a primary lesion located in an abdominal organ (Figure 4). Ovaries are more affected than the uterus; differential diagnosis includes all the other ovarian cystic lesions.

Involvement of the *peritoneum* represents about the 13% of all abdominal hydatidosis [22]. Primary peritoneal disease is extremely rare. Peritoneal cysts generally develop as a consequence of seeding from either spontaneous rupture or prior surgery of hepatic, splenic, or mesenteric cysts [28]. Peritoneal cysts may be multiple and located anywhere in the peritoneal cavity [24]; they can enlarge and cause abdominal distension or obstruction [21]. Isolated retroperitoneal hydatid cysts of *retroperitoneum* are rare; they usually are secondary to the involvement of the liver [22]. The invasion of the *abdominal wall* by liver hydatid cysts has already been reported in literature. A cyst usually passes through a small orifice and develops within the abdominal wall, keeping communication with its hepatic component and showing a typical “hourglass” configuration.

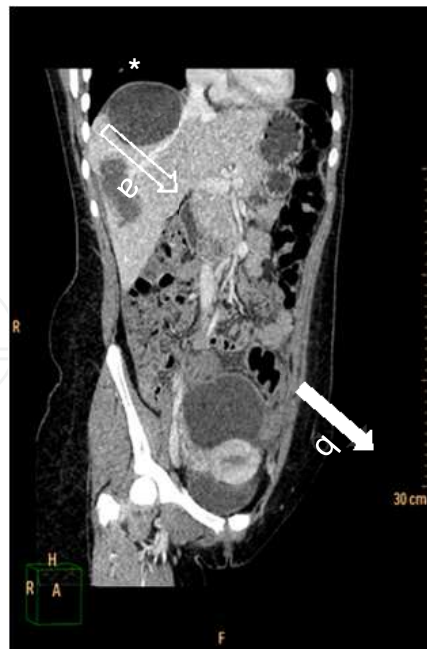

Figure 4. Pelvic hydatid cyst above the uterus (arrow), formed after the rupture of a liver cyst (open arrow). Asterisk shows another cyst at the hepatic dome.

Primary *soft-tissue* involvement is extremely rare and represents 0.5%–4.7% of patients. Clinical manifestation often consists of a palpable mass. Imaging findings are nonspecific and may include unilocular or multilocular cysts and complex solid lesions if some inflammatory changes overlap.

Diaphragmatic localization has an incidence of 1% and is often associated with liver disease. It is believed that the lack of peritoneum in the bare area of the liver is usually the weak point, which favors the transdiaphragmatic migration of a liver hydatid cyst. Diaphragm may appear thickened and lobulated with unilocular or multilocular cysts. When the chest is reached, possible complications may be represented by a rupture into the pleural cavity, seeding in the pulmonary parenchyma and chronic bronchial fistula.

6. Clinical presentation

The unusual anatomic locations may cause difficulties in making the differential diagnosis, as *E. granulosus* is usually not suspected in some locations of the body [29]; signs and symptoms may be easily confused with those of other illnesses [30]. In these peripheral locations the clinical picture is extremely variable and depends upon the involved organs. Mechanical symptoms on adjacent structures are often present, in other cases complications arise, due to secondary infection or rupture with unforeseeable anaphylactic reactions [3].

It is not easy, neither simple, to describe the clinical manifestations of a hydatid cyst located in a peripheric organ, very often each case presents different clinical features, as it appears from our series. In the rare localizations the hydatid disease in the beginning is almost always

asymptomatic, due to the slow growth of the cyst, and frequently is incidentally diagnosed. While the clinical signs of the hepatic cysts depend on its size and location inside the liver, when it is located in the peripheric organs, after an initial period during which the cyst is asymptomatic, clinical signs appear only when the diameter of the cyst increases and determines “mechanical” clinical features, which will be different according to the organ where the cyst is located. Splenic hydatid disease is mainly produced by systemic dissemination or intraperitoneal spread from a ruptured liver cyst [24].

The clinical manifestations include abdominal pain, enlarged spleen, and fever [21]. In renal hydatid disease, patients may be asymptomatic or refer non-specific clinical manifestation (flank mass, renal colic, persistent fever, hematuria, dysuria, pyuria, or hypertension) [21].

In *Echinococcosis* of the adrenal gland, when symptoms are present, they are related to local visceral compression. In the patient present in our personal series, abdominal pain and dyspeptic symptoms were present [14].

6.1. Personal series

In the Department of General Surgery of the University of Catania, Italy, from 1974 to 2014, 434 patients underwent surgical treatment for hydatid disease: in 319 cases (73.50%) the cyst was located in the liver, while in 79 cases (18.20%) it was located in the lungs. The remaining 36 patients (8.29%) presented a rare localization of the disease: in 3 patients (0.69%) the cyst was in the mediastinum, in 3 patients (0.69%) in the diaphragm, in one case (0.23%) in the dorsal muscle, and in 1 case (0.23%) in the subcutaneous tissue of the right lumbar region. In 28 cases (6.45%) the rare localization of the hydatid cyst was in the abdominal cavity: 11 cysts (2.53%) were in the peritoneal serosa, 9 (2.07%) in the spleen, 6 (1.38%) in the kidney, 1 (0.23%) in the adrenal gland, and 1 (0.23%) in the retroperitoneal region.

In the patients in whom the cyst was located in the peritoneal serosa, pain was present in 6 cases, a palpable mass in 4 cases, while in the other cases the cyst was incidentally diagnosed in an asymptomatic phase. Nine patients had a splenic localization and in 3 of them a hepatic cyst was also present. In 4 patients, a palpable mass in the left hypochondrium was present, 3 patients complained of a painful clinical picture, while 2 patients were asymptomatic. The patient with a cyst in the retroperitoneal space complained of a continuous pain in the right gluteal region with diffusion to the iliac bone and the omolateral thigh. A palpable mass was present in the mesogastrium. The patient with an adrenal cyst had perceived abdominal pain and dyspeptic symptoms with nausea [14]. The patient with the localization in the dorsal muscle was a woman who had noticed a mass in the lower lateral part of the axilla, which had increased until it reached a diameter of 12 cm.

6.2. Atypical manifestations

Absolutely unexplainable was the growth pattern of the cyst located in the subcutaneous tissue of the lumbar region in a 77-year-old woman that we observed in 2007. The diameter of the mass was about 8 cm, and clinical examination revealed that the mass had a smooth surface with distinct margins (Figure 5a). Absolutely unusual, the report of CT that displayed the

atypical behaviour of the cyst that seemed to originate from the liver through a little peduncle and then went into the muscle layer and reached the subcutaneous tissue of the lumbar region (Figure 5b) [31]. These data were confirmed at surgery but a clear explanation of this atypical case has not been obtained. If a hydatid cyst develops into the liver, usually it grows inside the liver and outside it towards the peritoneal cavity, it can reach a great dimension but does not go over the abdominal wall muscles as an infiltrating tumor. A similar growth pattern may occur in cysts located in the liver cupola when, in consequence of an inflammatory process, go into the diaphragm and open to the bronchial tubes. However, in our case, infective processes were not present and so this case remains unexplainable.

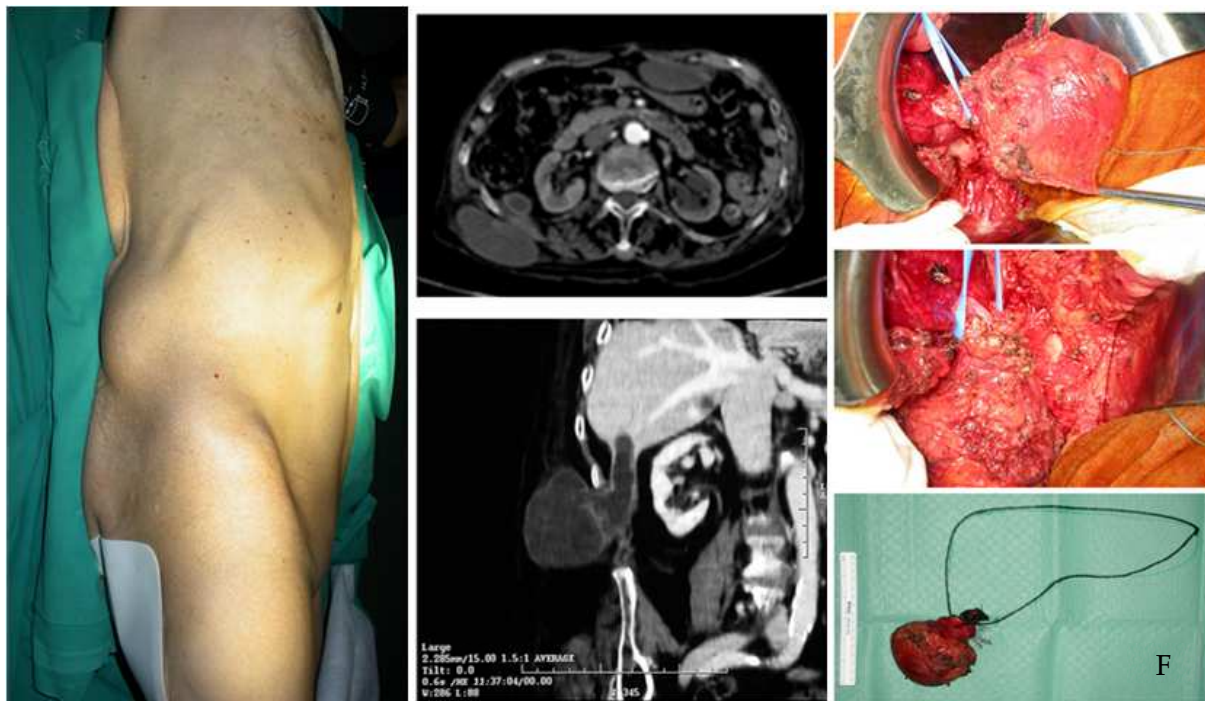

Figure 5. Clinical (a), radiological (b) and surgical (c) appearance of a rare hydatid cyst of the subcutaneous tissue of the lumbar region, correlated to the liver through a little peduncle [31].

6.3. Diagnostic evaluation and surgical treatment

In our experience, immunological tests have been very useful when the hydatid cyst was located in the liver, but have not showed the same diagnostic profit in patients affected by rare locations of the disease. In these cases, globally considered, echinotest has been positive in about one third of the cases. Diagnostic tools that have been essential to obtain the diagnosis were ultrasound and CT. The surgical treatment of the hydatid cysts peripherally located is not standardized, usually they are cases sporadically reported and the same great experience gained in the surgical treatment of the hepatic cysts is lacking. In hepatic cysts, a considerable reduction of the conservative surgical approaches has been reported and nowadays an increase in radical surgery is the preferred treatment.

In peripheric locations, the radical surgical removal without spreading the disease due to spillage of cystic fluid has been the treatment of choice, and this method has been applied to the cysts located in the peritoneum. In the splenic localization, splenectomy has always been performed and the patients underwent the standardized protocols to avoid the consequences of the overwhelming postsplenectomy infection [32]. In the renal localizations it has been possible to avoid nephrectomy and realize a partial pericystectomy and no recurrences have been observed. The cyst located in the adrenal gland was treated by surrenectomy and the cysts located in the dorsal muscle and in the subcutaneous tissue of the lumbar region (Figure 5c) were easily removed.

7. Echinococcosis and allergy — Anaphylaxis

Echinococcus granulosus and *E. multilocularis* are involved in parasitic disease in humans: cystic *Echinococcosis* (CE) (“hydatid diseases”) and alveolar *Echinococcosis* (AE), respectively. Both diseases and parasites have tight links with allergy because of the immunological characteristics that contribute to maintaining the larva in its human host, as well as their potential in inducing clinical anaphylactic reactions in some patients [19].

Allergic reactions and anaphylaxis are well-known features of CE. Elevated total IgE, as well as occurrence of specific IgE against *Echinococcus* antigens in the serum of patients with CE are also key biological features of the disease [33–34]. IgE-dependent immune reactions were long neglected in AE; obviously, anaphylactic reactions are far less frequent than in CE. However, specific IgE antibodies against *E. Multilocularis* antigens may be found in patients with AE [19]. Anaphylactic reactions have been reported in cystic *Echinococcosis* for several decades and are usually observed in case of overt or unapparent rupture of the parasitic cyst [19]. A variety of allergic symptoms has been described in patients with CE. They include urticaria that may be only mild or present as chronic and apparently “idiopathic” urticaria, or as giant urticaria associated with systemic signs and symptoms. Respiratory symptoms may also be observed; asthma may be the first manifestation of hepatic hydatidosis and acute bronchospasm may occur when the cyst is manipulated at surgery. Anaphylactic shock is the most impressive and severe clinical presentation of IgE-dependent allergic reactions in CE. It may occur spontaneously and precede any other symptoms. Recurrent life-threatening anaphylactic shocks, with or without laryngospasm, may be due to small, incomplete rupture of the cyst [35–36]. Overt rupture of the cyst, however, is a much more frequent cause of anaphylaxis; it may be observed after trauma, even trivial, such as that derived from a sport (football) accident. Sometimes, however, intraperitoneal perforation of a hepatic hydatid cyst can happen without anaphylactic reaction, confirming the inaccurate knowledge of the mechanisms that control the allergic phenomena produced by the parasite [37]. The most usual circumstance is surgery, however, even in the immediate postoperative period, or laparoscopy. As for other etiologies of anaphylactic shock, tryptase measurement is of help for diagnosis [19]. In AE, the low rate of anaphylactic symptoms could be related to a more “masked” form of *Echinococcus* antigens in patients with AE than in those with CE: the extremely fibrotic lesions of AE cannot rupture, and the echinococcal fluid may never be in contact with mast cell-bound IgE [38].

8. Medical treatment

In patients treated for liver and/or lung hydatid cysts, the possibility of secondary *Echinococcosis* can be minimized by concurrent treatment with benzimidazoles [39].

Mebendazole (MBZ) and albendazole (ABZ) are the benzimidazole (BMZ) agents used for the treatment of hepatic CE. They interfere with the absorption of glucose through the wall of the parasite, causing glycogen depletion, and degenerative changes in echinococcal mitochondria and endoplasmic reticulum. BMZ may be favorably used alone for the treatment of small (<5 cm) CE liver cysts or for inoperable patients; BMZ is also usually associated with PAIR or surgery to prevent secondary CE. BMZ is not indicated for the treatment of inactive or calcified asymptomatic cysts, unless they are complicated lesions. Both ABZ and MBZ are effective, but ABZ is considered the drug of choice. The usual dose of orally administered ABZ is 10–15 mg/kg/day in two divided doses; if using MBZ, the daily dose is 40–50 mg/kg in three divided doses. Treatment with BMZ should be administered continuously for 3–6 month. Praziquantel has been used (40 mg/kg once a week) with ABZ for combined treatment of CE; this therapeutic association seems to be more effective than ABZ alone [40–41]. Usual adverse effects include nausea, hepatotoxicity, neutropenia, and occasionally alopecia [39]. In patients treated for rare peripheric locations, in our opinion, treatment with BMZ should be especially recommended. In these patients, hepatic and pulmonary filters have been bypassed, so the disease should be considered systemic and chemotherapy should be promising in preventing further recurrences.

9. Conclusions

Although the incidence of *Echinococcosis* has dramatically reduced in recent decades, many cases can still be found in daily medical practice. The surgeon must keep in mind that this parasitosis can occur even in uncommon locations and therefore it should be regarded as a potentially systemic disease. In these cases the diagnosis is challenging and can be achieved only through a complete interdisciplinary evaluation of clinical, laboratory, and radiological data.

Acknowledgements

Part of the text of paragraph 6.2. “Atypical manifestations” and Figure 5 are used with kind permission of the publisher for World Journal of Gastroenterology. The Authors wish to thank Bench srl for the technical support. Main Authors (Antonio Di Cataldo, Giuseppe Petrillo, Claudia Trombatore, Stefano Palmucci, Antonella Agodi) did study conception, acquisition and interpretation of data, wrote the manuscript and performed the final critical revision. Other Authors cooperated in the writing the manuscript, according to their competence and specific knowledge.

Author details

Antonio Di Cataldo^{1*#}, Giuseppe Petrillo^{2#}, Claudia Trombatore^{2#}, Stefano Palmucci^{2#}, Antonella Agodi^{1#}, Martina Barchitta¹, Annalisa Quattrocchi¹, Nunzio Crimi³, Silvia Fichera³, Stefano Puleo¹, Amy Giarrizzo¹, Martina Calabrini¹, Rosalia Latino¹ and Rosanna Portale¹

*Address all correspondence to: dicataldoa@tiscali.it

1 Department of Medical and Surgical Sciences, Advanced Technologies GF Ingrassia, University of Catania, Italy

2 Radiodiagnostic and Radiotherapy Unit, University Hospital Policlinico-Vittorio Emanuele, Catania, Italy

3 Department of Respiratory Diseases and Allergology, University of Catania, Italy

#Principal authors

References

- [1] Grassi G: Contributo allo studio di alcune localizzazioni rare delle cisti d'echinococco. *Gazz San* 9: 428-433, 1965.
- [2] Craig PS, McManus DP, Lightowlers MW: Prevention and control of cystic echinococcosis. *Lancet Infectious Diseases* 7: 385–394, 2007.
- [3] Sachar S, Goyal S, Sangwan S: Uncommon locations and presentations of hydatid cyst. *Ann Med Health Sci Res* 204:447-522014.
- [4] World Health Organization. About echinococcosis. Available online at: http://www.who.int/echinococcosis/about_disease/en/.
- [5] Hotez PJ, Gurwith M: Europe's neglected infections of poverty. *Int J Infectious Diseases* 15: e611–e619, 2011.
- [6] Rojo-Vazquez FA, Pardo-Lledias J, Francos-Von Hunefeld M: Cystic echinococcosis in Spain: Current situation and relevance for other endemic areas in Europe, *PLoS Neglected Tropical Diseases* 5: article e893, 2011.
- [7] Polat P, Kantarci M, Alper F: Hydatid Disease from Head to Toe. *Radiographics* 23: 475-494, 2003.
- [8] European Centre for Disease Prevention and Control. Annual epidemiological report 2014—food and waterborne diseases and zoonoses. Stockholm: ECDC; 2014.

- [9] Garippa G: Updates on Cystic Echinococcosis (CE) in Italy. *Parassitologia* 48: 57–59, 2006.
- [10] Garippa G, Manfredi MT: Cystic Echinococcosis in Europe and in Italy. *Veterinary Research Communications* 33: supplement S35–S39, 2009.
- [11] Moro P, Schantz PM: Echinococcosis: A review. *Int J Infectious Diseases* 13: 125–133, 2009.
- [12] Petrone L, Cuzzi G, Colace L: Cystic Echinococcosis in a Single Tertiary Care Center in Rome, Italy. *BioMed Res Int*, Article ID 978146, 2013.
- [13] Wani RA, Wani I, Malik AA, Parray FQ, Wani AA, Dar AM: Hydatid disease at unusual sites. *IJCR* 3:1–6, 2012.
- [14] Di Cataldo A, Trombatore G, Greco R, Lanteri R, Li Destri G, Licata A: Hydatid disease in a very unusual location: The adrenal gland. A case report. *Chir. Ital.* 55: 275–278, 2003.
- [15] McManus DP, Zhang W, Li J, Bartley PB: Echinococcosis. *Lancet* 362:1295–304, 2003
- [16] Geramizadeh B: Unusual locations of the hydatid cyst: A review from Iran. *Iran J Med Sci.* 38:2–14, 2013.
- [17] Alvarez Rojas CA, Romig T, Lightowlers MW: *Echinococcus granulosus* sensu lato genotypes infecting humans—Review of current knowledge. *Int J Parasitol.* 44:9–18, 2014.
- [18] Sadjjadi SM, Mikaeili F, Karamian M, Maraghi S, Sadjjadi FS, Shariat Torbaghan S, Kia EB: Evidence that the *Echinococcus granulosus* G6 genotype has an affinity for the brain in humans. *Int. J. Parasitol.* 43: 875–877, 2013.
- [19] Vuitton A: Echinococcosis and allergy. *Clin Rev Allergy Immunol* 26: 93–104, 2004.
- [20] Marinova I, Nikolov G, Michova A, Kurdova R, Petrunov B: Quantitative assessment of serum-specific IgE in the diagnosis of human cystic echinococcosis. *Parasite Immunol.* Jul; 33(7): 371–6, 2011.
- [21] Gossios KJ, Kontoyiannis DS, Dascalogiannaki M, Gourtsoyiannis NC: Uncommon locations of hydatid disease: CT appearances. *Eur Radiol* 7: 1303–1308, 1997.
- [22] Ilica A, Kocaoglu M, Zeybek N, Guven S, Adaletli I, Basgul A, Coban H, Bilici A, Bukte Y: Extrahepatic abdominal hydatid disease caused by *echinococcus granulosus*: Imaging findings. *AJR* 189:337–343, 2007.
- [23] Ortega CD, Ogawa NY, Rocha MS, Blasbalg R, Motoyama Caiado AH, Warmbrand G, Cerri GG. Helminthic diseases in the abdomen: An epidemiologic and radiologic overview. *RadioGraphics* 30:253–267, 2010.
- [24] Pedrosa I, Saíz A, Arrazola J, Ferreirós J, Pedrosa CS: Hydatid disease: Radiologic and pathologic features and complications. *RadioGraphics* 20: 795–817, 2000.

- [25] Szanto P, Goian I, Al Hajjar N, Badea R, Seicean A, Manciu D, Serban A: Hydatid cyst of the pancreas causing portal hypertension. *Maedica (Buchar)*. 5(2): 139–41, 2010.
- [26] Volders WK, Gelin G, Stessens RC: Hydatid cyst of the kidney: Radiologic-pathologic correlation. *RadioGraphics* 21: S255–S260, 2001.
- [27] Ishimitsu DN, Saouaf R, Kallman C, Balzer BL: Best cases from the AFIP: Renal hydatid disease. *RadioGraphics* 30: 334–337, 2010.
- [28] Pickhardt PJ, Bhalla S: Unusual non-neoplastic peritoneal and subperitoneal conditions: CT findings. *RadioGraphics* 25: 719–730, 2005.
- [29] Yuksel M, Demirpolat G, Sever A, Bakaris S, Bulbuloglu E, Elmas N: Hydatid disease involving some rare locations in the body: A pictorial essay. *Korean J Radiol* 8: 531–540, 2007.
- [30] Yildirim M, Erkan N, Vardar E: Hydatid cyst with unusual localizations: Diagnostic and treatment dilemmas for surgeons. *Ann Trop Med Parasitol* 100: 137–142, 2006.
- [31] Di Cataldo A, Latino R, Cocuzza A, Li Destri G: Unexplainable development of a hydatid cyst. *World J Gastroenterol* 15: 3309–3311, 2009.
- [32] Di Cataldo A, Puleo S, Li Destri G, Racalbuto A, Trombatore G, Latteri F, Rodolico G: Splenic trauma and overwhelming post-splenectomy infection. *Br J Surg* 74: 343–345, 1987.
- [33] Guisantes JA, Vincente-Garcia F, Abril JM, Eraso E, Martinez J: Total and specific IgE levels in human hydatid disease determined by enzyme immunoassay: Serological follow-up after surgery. *J Investig Allergol Clin Immunol* 4: 301–304, 1994.
- [34] Riganò R, Ioppolo S, Ortona E, Margutti P, Profumo E, Ali MD, Di Vico B, Teggi A, Siracusano A: Long-term serological evaluation of patients with cystic echinococcosis treated with benzimidazole carbamates. *Clin Exp Immunol* 129: 485–492, 2002.
- [35] Boyano T, Moldenhauer F, Mira J, Joral A, Saiz F: Systemic anaphylaxis due to hepatic hydatid disease. *J Investig Allergol Clin Immunol* 4: 158–159, 1994.
- [36] Saenz de San Pedro B, Cazaña JL, Cobo J, Serrano CL, Quiralte J, Contreras J, Martinez F: Anaphylactic shock by rupture of hydatid hepatic cyst. Follow-up by specific IgE serum antibodies. *Allergy* 47: 568–570, 1992.
- [37] Di Cataldo A, Lanteri R, Caniglia S, Santangelo M, Occhipinti R, Li Destri G: A rare complication of the hepatic hydatid cyst: Intraperitoneal perforation without anaphylaxis. *Int Surg* 90: 42–44, 2005.
- [38] Vuitton DA, Bresson-Hadni S, Lenys D, Flausse F, Liance M, Wattre P, Miguet JP, Capron A: IgE-dependent humoral immune response in *Echinococcus multilocularis* infection: circulating and basophil-bound specific IgE against *Echinococcus* antigens in patients with alveolar echinococcosis. *Clin Exp Immunol* 71: 247–252, 1988.

- [39] Nunnari G, Pinzone MR, Gruttadauria S, Celesia BM, Madeddu G, Malaguarnera G, Pavone P, Cappellani A, Cacopardo B: Hepatic echinococcosis: Clinical and therapeutic aspects. *World J Gastroenterol* 18: 1448–1458, 2012.
- [40] Kumar A, Lal BK, Chattopadhyay TK: Hydatid disease of the liver non-surgical options. *J Assoc Physicians India* 41: 437–443, 1993.
- [41] Vutova K, Mechkov G, Vachkov P, Petkov R, Georgiev P, Handjiev S, Ivanov A, Todorov T: Effects of mebendazole on human cystic echinococcosis: The role of dosage and treatment duration. *Ann Trop Med Parasitol* 93: 357–365, 1999.
- [42] Akcay MN, Akcay G, Balik AA, Boyuk A: Hydatid cysts of the adrenal gland: Review of nine patients. *World J Surg* 28: 97–99, 2004.
- [43] Drimousis PG, Stamou KM, Koutras A, Tsekouras DK, Zografos G: Unusual site of recurrent musculoskeletal hydatid cyst: Case report and brief review of the literature. *World J Gastroenterol* 12: 5577–5578, 2006.
- [44] Greenberg SM: *Handbook of Neurosurgery*. 1st ed. New York: Thieme Medical Publisher 2001. p. 238-239.
- [45] Altas M, Aras M, Serarslan Y, Davran R, Evirgen O, Yilmaz N: A medically treated multiple cerebral hydatid cyst disease. *J Neurosurg Sci* 54: 79–82, 2010.
- [46] Raza MH, Harris SH, Khan R: Hydatid cyst of gall bladder. *Indian J Gastroenterol* 22: 67–68, 2003.
- [47] Mushtaque M, Malik AA, Malik RA: Hydatid cyst of the gall bladder: A rare location. *East J Med* 16: 83–86, 2011.
- [48] Gogus C, Safak M, Baltaci S, Turkolmez K: Isolated renal hydatidosis: Experience with 20 cases. *J Urol* 169: 186–189, 2003.
- [49] Verasaci A, Scuderi G, Rosato A: Rare localizations of echinococcosis; personal experience. *ANZ J Surg* 75: 986–991, 2005.
- [50] Arora M, Gupta CR, Jindal S, Kapoor N: An unusual case of hydatid cyst of broad ligament. *J Indian Acad Clin Med* 6: 86–87, 2005.
- [51] Palaivelu C: Laparoscopic management of hydatid cysts of liver. *Art of Laparoscopic surgery. Textbook and Atlas*. Dehli Jaypee Publishers; 2007. p. 757–783.
- [52] Moosavi SR, Kermany HK: Epigastric mass due to a hydatid cyst of the pancreas. A case report and review of the literature. *JOP* 8: 232–234, 2007.
- [53] Vasileios R, Athanasios P, Stavros T: Echinococcal cyst of the seminal vesicles: A case report and literature review. *Int Urol Nephrol* 34: 527–530, 2002.
- [54] Safioleas M, Nikiteas N, Stamatakos M: Echinococcal cyst of the subcutaneous tissue: A rare case report. *Parasitol Int* 57: 236–238, 2008.

- [55] Zulfikaroglu B, Koc M, Ozalp N, Ozmen MM: A rare primary location of echinococcal disease: Report of a case. *Ups J Med Sci* 110:167–171, 2005.
- [56] Dirican A, Unal B, Kayaalp C, Kirimlioglu V: Subcutaneous hydatid cysts occurring in the palm and the thigh: Two case reports. *J Med Case Rep* 2: 273, 2008.
- [57] Polat P, Kantarci M, Alper F, Suma S, Koruyucu MB, Okur A: Hydatid disease from head to toe. *Radiographics* 23: 475–494, 2003.
- [58] Tlili G, Bouassida K, Slama A, Tlili T, Ziadi S, Taher MA: Hydatid cyst of the scrotum miming a testicular tumor. *J Case Reports* 4: 151–154, 2014.
- [59] Arora V, Nijjar IS, Gill KS, Singh G: Case report: Primary hydatid cyst of muscle—A rare site. *Indian J Radiol Imaging* 16: 239–241, 2006.