

We are IntechOpen, the world's leading publisher of Open Access books Built by scientists, for scientists

6,900

Open access books available

186,000

International authors and editors

200M

Downloads

Our authors are among the

154

Countries delivered to

TOP 1%

most cited scientists

12.2%

Contributors from top 500 universities



WEB OF SCIENCE™

Selection of our books indexed in the Book Citation Index
in Web of Science™ Core Collection (BKCI)

Interested in publishing with us?
Contact book.department@intechopen.com

Numbers displayed above are based on latest data collected.
For more information visit www.intechopen.com



Echinococcosis in Colombia

— A Neglected Zoonosis?

Alfonso J. Rodriguez-Morales,
Lauren Sofia Calvo-Betancourt,
Camila Alarcón-Olave and Adrián Bolívar-Mejía

Additional information is available at the end of the chapter

<http://dx.doi.org/10.5772/60731>

Abstract

Echinococcosis or hydatid disease is a near-cosmopolitan parasitic zoonosis caused by the larval stages of cestodes of the genus *Echinococcus*, whose spectrum of clinical manifestations can vary from asymptomatic infection to death, the liver being the most frequently affected organ. In the absence of an adequate treatment, case fatality rate of affected patients may reach 100%, so clinical suspicion should always be accompanied by a complete workup and a prompt treatment. Like other zoonotic parasitic diseases, echinococcosis is associated with low socioeconomic and cultural levels, especially affecting rural areas of developing countries, not only by the morbidity and mortality it produces, but also by the economic impact associated to health care costs and productivity losses. Despite this, in Colombia and in other South American countries, epidemiological studies of this disease are limited, so it is not known with certainty the incidence, the prevalence, and the burden of the disease. The objective of this chapter is to summarize and describe epidemiological and clinical updated aspects of the disease, focusing on evidences and published research articles on echinococcosis in Colombia, finally questioning if this cestode zoonotic disease has been largely neglected.

Keywords: Echinococcosis, *Echinococcus*, Colombia, neglected diseases, zoonotic infectious diseases

1. Introduction

Echinococcosis or hydatid disease is a near-cosmopolitan parasitic zoonosis caused by the larval stages (paratenic for humans) of cestodes of the genus *Echinococcus* (Figure 1) [1, 2]. This helminthiasis causes an important economic loss over agricultural and pastoral regions of limited resources, particularly in developing countries [3]. In addition, it is also important to notice that this is one of the important infectious disease groups caused by larval stages of cestodes, which also include cysticercosis (caused by larval stages of *Taenia solium*), coenuriasis (caused by larval stages of *Taenia multiceps gaigeri*), and sparganosis (caused by larval stages of *Spirometra*), among others.

Biologically and taxonomically, although in the past it was considered as part of the genus *Taenia*, *Echinococcus* genus belongs to the family *Taeniidae* (order Cyclophyllidea, subclass Eucestoda, class Cestoda, phylum Platyhelminthes). Family *Taeniidae* also includes the genus *Taenia*. Order Cyclophyllidea has two important families that infect humans: *Hymenolepididae* (*Hymenolepis*) and *Dipylidiidae* (*Dipylidium*). Subclass Eucestoda includes the order Diphyllbothriidea that belongs to family *Diphyllbothriidae* and genus *Diphyllbothrium*.

Although, 12 species have been recognized, only four are of public health concern and produce human pathology: *Echinococcus granulosus* (cystic echinococcosis), *E. multilocularis* (alveolar echinococcosis), *E. vogeli*, and *E. oligarthrus* (both causing polycystic echinococcosis). The first two species are etiological agents of life-threatening diseases, having high fatality rate and poor prognosis if careful clinical management is not given [2]. *E. vogeli* and *E. oligarthrus* are responsible for polycystic echinococcosis in Central and South America [2]. Majority of the cases reported in these regions, till 2008, have corresponded to *E. vogeli* (54 of 172; 31.4%) and *E. cf. vogeli (confer, species affinis)* (114 of 172; 66.3%) [3]. Only three cases (1.7%) have been identified that have corresponded to *E. oligarthrus* and one has corresponded to *E. granulosus* (0.6%) [3]. In the past, it was believed that *E. multilocularis* was not present in Central and South America.

Living or having lived in rural areas where farming and animal husbandry are common is an important risk factor for this disease, in some areas particularly where people frequently come in contact with dogs that accompany paca hunters as well as where wild animal hunting for food is common practice (e.g., hunters and aboriginal people) [4]. In addition, new population migration patterns over the past four decades have caused a change in the profile of this disease, allowing its worldwide distribution [4]. In addition, in general, now it is considered that there is a risk of getting echinococcosis infection, as well other cestodiasis, while traveling to endemic zones.

This disease is related with extensive livestock or poor health infrastructures; usually associated with a low socioeconomic level and lack of education. Its public health importance is related not only to the high fatality rate in humans but also with reduced work performance, costs of hospitalization, interventions, and disabilities [5].

Although echinococcosis has been recognized for centuries (at the 17th century, Francesco Redi illustrated that the hydatid cysts of echinococcosis were of “animal” origin), in some countries

of the neotropic region, such as Colombia, this disease was discovered during 20th century). Studies in this context in this country, as well as in other countries of South America, are still limited. Therefore, the objective of this chapter is to summarize and describe epidemiological and clinical updated aspects of this disease, focusing on evidences and published research articles on echinococcosis in Colombia, finally questioning if this cestode zoonotic disease has been largely neglected [1-84].

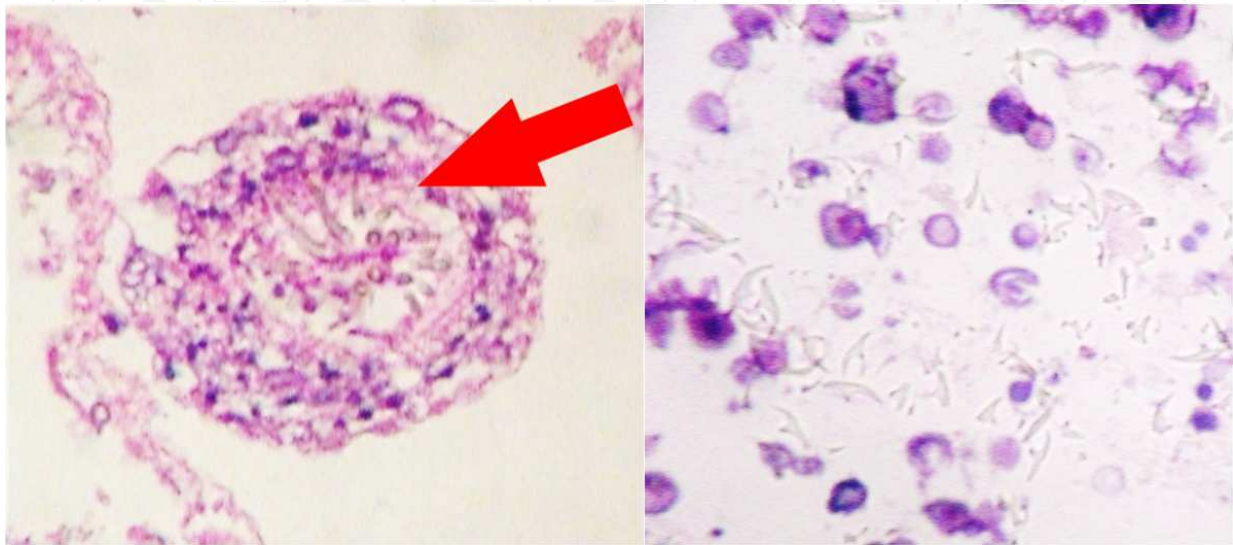


Figure 1. Scolex and hooks of *Echinococcus granulosus* (pictures by A. J. Rodriguez-Morales).

2. Organisms causing human disease

2.1. *Echinococcus granulosus*

(Cystic echinococcosis)

E. granulosus is a cestode whose life cycle involves dogs (*Canis lupus familiaris*) and other canids (coyote, dingo, red fox, among others) as definitive hosts for the intestinal tapeworm, which are infected by ingestion of food containing hydatid cysts with viable protoscoleces, and domestic and wild ungulates as intermediate hosts for the tissue invading metacestode (larval) stage (Figure 1) [1]. The metacestode (or hydatid cyst) consists of two parasite-derived layers: an inner nucleated germinal layer, and an outer acellular laminated layer surrounded by a host-derived fibrous capsule [2]. Intermediate host species depends on the infecting strain of *E. granulosus*, regional or local differences in the availability of the various intermediate host species, and other factors [2], but would include primarily ungulates, also marsupials [which for the case of Colombia would make think the possibility of occurrence in the country given the wide presence of them, such as *Didelphis marsupialis* (locally called “chucha”)]. Ten strains of *E. granulosus* have been identified so far (G1–G10) with different host affinities: G1–G2 being sheep strains, G3 and G5 bovid strains, G4 a horse strain, G6 a camelid strain, G7 a pig strain,

G8 a cervid strain, G9 has been described in swine in Poland, and G10 in reindeer in Eurasia [1, 81]. The sheep strain (G1) is most commonly associated with human infections [1]. The presence of diverse strains of *E. granulosus* has important implications for public health. The shortened maturation time of the adult form of the parasite in the intestine of dogs suggests that the interval period for administering anti-parasite drugs to infected dogs will have to be shortened in those areas where the G2, G5, and G6 strains are found [1]. The adult *E. granulosus* is 2.0 to 7.0 mm in length. It has three proglottids (range 4–6). It is supposed that *E. granulosus* is found worldwide; however, in many countries (including Colombia and other countries in South America), its presence has not been confirmed both in humans and in animals. Hydatid cysts are predominantly found in liver and lungs (Figure 1).

2.2. *Echinococcus multilocularis*

(Alveolar echinococcosis)

E. multilocularis is the etiological agent of the alveolar echinococcosis, its infection is perpetuated in a sylvatic cycle, with wild carnivores—mainly red (*Vulpes vulpes*) and arctic (*Alopex lagopus*) foxes—regarded as the most important definitive hosts. Domestic dogs and cats may be involved in a synanthropic cycle, and also raccoon dog and coyotes [2]. Small mammals (usually microtine and arvicolid rodents) act as intermediate hosts. The metacestode of *E. multilocularis* is a tumor-like, infiltrating structure consisting of many small vesicles embedded in stroma of connective tissue. The metacestode mass usually contains a semisolid matrix rather than fluid. The adult tapeworm is different in size than adult *E. granulosus* (1.2–4.5 mm) and its eggs are indistinguishable by light microscopy. The hydatid cysts do not form hyaline membrane and the scolices, which are abundant in rodents but absent in humans. People become exposed to *E. multilocularis* by handling of infected hosts, or by ingestion of food contaminated with eggs of the parasite [2].

It is endemic in North America, Alaska, Europe, Central Russia, China, Turkey, Japan, Uruguay, and Argentina. In humans, the most frequently affected organs are the liver (80%), lungs (10%), brain (5%), and other organs such as kidney and pancreas (5%) [6]. *E. multilocularis* has five proglottids (range 2–6). Hydatid cysts are primarily hepatic, with metastases in lungs, brain, and bones among other organs.

2.3. *Echinococcus oligarthrus*

(Polycystic echinococcosis)

E. oligarthrus is the smallest species of the genus, it only measures, in its adult form, 2.2 to 2.9 mm. Definitive hosts are different species of wild felidae (pampas cats, Geoffrey's cat, ocelot, jaguar, cougar, jaguarandi, puma, boat cats) and intermediate hosts are rodents like rats (spiny rat), agoutis, and pacas (both, very highly distributed in the whole territory of Colombia and in most of the tropical areas of South America, including Brazil, Paraguay, Bolivia, Peru, Ecuador, Venezuela, Guyana, Suriname, and French Guyana) [6]. Hydatid cysts are located in an extrahepatic location, mostly in the intermuscular tissue, pleural, and peritoneal cavity [6].

E. oligarthrus has three proglottids. Larval parasite of this species can be also located in eye and heart.

2.4. *Echinococcus vogeli*

(Polycystic echinococcosis)

E. vogeli also causes polycystic echinococcosis and has been reported only in Central and South America. However, not every country in this region has reported cases of *E. vogeli*. Brazil (98 cases) and Colombia (30 cases) have been the countries with the highest number of reported cases, till 2010 (including *E. cf. vogeli*) [6]. The adult tapeworm measures 5.6 mm. The eggs are similar to that of the *Taenia* genus. Definitive hosts are domestic and wild dogs (bush dog and domestic dog). The bush dog, *Speothos venaticus*, is widely distributed in South America, particularly not only in Brazil (>80% of the territory) but also in most parts of Venezuela, Guyana, Suriname, and French Guyana, as well as in some areas of Colombia, Panama, Ecuador, Peru, Paraguay, Argentina, and Uruguay. Intermediate hosts are rodents, but mainly the agoutis and pacas. In this species, the hydatid cyst is of endogenous proliferation and it forms bags or folds inside the primary bladder [6]. While in rodent the larvae is limited, in humans it disseminates, due to exogenous vesiculation and due to the amount of scolices inside the cyst, which can cause reinfection when it breaks spontaneously or by medical manipulation [6]. The adult *E. vogeli* is 3.9 to 5.6 mm in length. *E. vogeli* has three proglottids.

The results of a survey (carried out to detect *Echinococcus* infections) involving more than 4,000 Colombian mammals showed interesting findings regarding *E. vogeli* and *E. oligarthrus*. Adult worms were found in 5 of 121 carnivores: *E. oligarthrus* in 1 of 11 ocelots, 2 of 9 jaguarundi cats, and single puma; and *E. vogeli* in 1 of 15 domestic dogs. Although bush dogs were present, none could be examined. Polycystic larvae were found in 96 of 325 pacas (29.5%) and in 6 of 1,168 (0.5%) spiny rats, *Proechimys spp.* None of the 118 agouti showed hydatid cysts but an infected heart was provided by hunters. The paca's infection rate increased with age but was not related to gender or geographic region. In 73 of 96 pacas, the infection was due to *E. vogeli*, and the cysts were located in the liver. In three cases, it was due to *E. oligarthrus* and the hydatid cysts were extrahepatic, mainly attached to muscles. In the remaining 20, the species involved could not be determined. The parasites in two of the spiny rats, and in the agouti heart were *E. oligarthrus* [48]. Although most of the infected animals were collected in the eastern plains, other records and verbal information indicate that, at least in Colombia where man has not exterminated pacas, agoutis, wild canids, and felids, one still can find enzootic neotropical *Echinococcus* infection. The cycle of *E. vogeli* involves the bush dog and paca as hosts, and that of *E. oligarthrus*, the paca, agouti, spiny rat, and several species of wild felids [48].

Other species in the genus *Echinococcus* have also been discovered and identified. Currently, there are 12 species, including those four causing human pathology, six identified in animals: *E. canadensis* (main intermediate host: cervids; known definite hosts: wolves, dog), *E. equinus* (main intermediate host: horses; known definite host: dogs), *E. felidis* (main intermediate host: warthogs; known definite host: lions), *E. intermedius* (main intermediate hosts: camels, pigs, sheep; known definite hosts lions), *E. ortleppi* (main intermediate host: cattle; known definite hosts dogs), and *E. shiquicus* (main intermediate host: pika; known definite host: Tibetan fox);

and two to be assigned to name species (*Echinococcus* sp. GL-2010 and *Echinococcus* sp. GL-2012) (<http://www.ncbi.nlm.nih.gov/Taxonomy/Browser/wwwtax.cgi?id=6209>) [46].

Some authors have recently exposed that all these species would be infectious for humans, probably with the exception of *E. equinus*, *E. felidis*, and *E. shiquicus*, and also the two to be assigned to name species [46]. Probably, with more studies in molecular epidemiology in the future, their role will become clear. However, it is interesting to note that at the GenBank (<http://www.ncbi.nlm.nih.gov/gene/?term=echinococcus>), there are 271 genes identified from different species of *Echinococcus*: *E. oligarthrus* (36 genes), *E. vogeli* (36 genes), *E. shiquicus* (36 genes), *E. canadensis* (36 genes), *E. equinus* (36 genes), *E. felidis* (36 genes), *E. orteppi* (14 genes), *E. multilocularis* (12 genes), and *E. granulosus* (12 genes). At GenBank, there are also 43,971 sequences of proteins of the genus *Echinococcus* (<http://www.ncbi.nlm.nih.gov/protein/?term=echinococcus>): *E. granulosus* (24,310 sequences), *E. multilocularis* (18,670 sequences), *E. canadensis* (476 sequences), *E. shiquicus* (111 sequences), *E. equinus* (77 sequences), *E. orteppi* (66 sequences), *E. vogeli* (51 sequences), *E. oligarthrus* (47 sequences), and *E. felidis* (34 sequences).

More importantly, a draft genomic sequence for *E. granulosus* comprising 151.6 Mb encoding 11,325 genes has been achieved [47], including the evaluation of the regulation of genes in the adult, oncosphere, hydatid cyst, and protoscoleces, which would be of great significance for further studies in diagnostic as well in the immunology and vaccine development, among other things.

3. Life cycle

The adult *E. granulosus* lives in the small intestine of the definitive hosts (dogs or other canids) (Figure 2). Gravid proglottids release eggs that are passed in the feces of these animals (which would come in close contact with humans). After ingestion by a suitable intermediate host (sheep, goat, swine, cattle, horses, camel, under usual natural conditions), embryonated eggs are hatched in the small intestine of the intermediate host and release the oncosphere which penetrates the intestinal wall and migrates through the circulatory system into various organs, especially the liver and lungs (Figure 2).

In these organs, the oncosphere develops into a cyst that enlarges gradually, producing protoscolices and daughter cysts that fill the cyst interior (Figure 2). The definitive host becomes infected by ingesting the cyst-containing organs of the infected intermediate host (Figure 2). After ingestion, the protoscolices evaginate, attach to the intestinal mucosa, and develop into adult stages in approximately 32 to 80 days (Figure 2). Humans can also get infected by ingesting eggs from feces of definitive hosts infected, then resulting with the release of oncospheres in the intestine and the development of cysts in different organs (mainly liver and lungs) (Figure 2).

The same life cycle occurs with *E. multilocularis*, *E. vogeli*, and *E. oligarthrus*, with the differences in the definitive or main hosts and the intermediate hosts involved for these species (Figure 2).

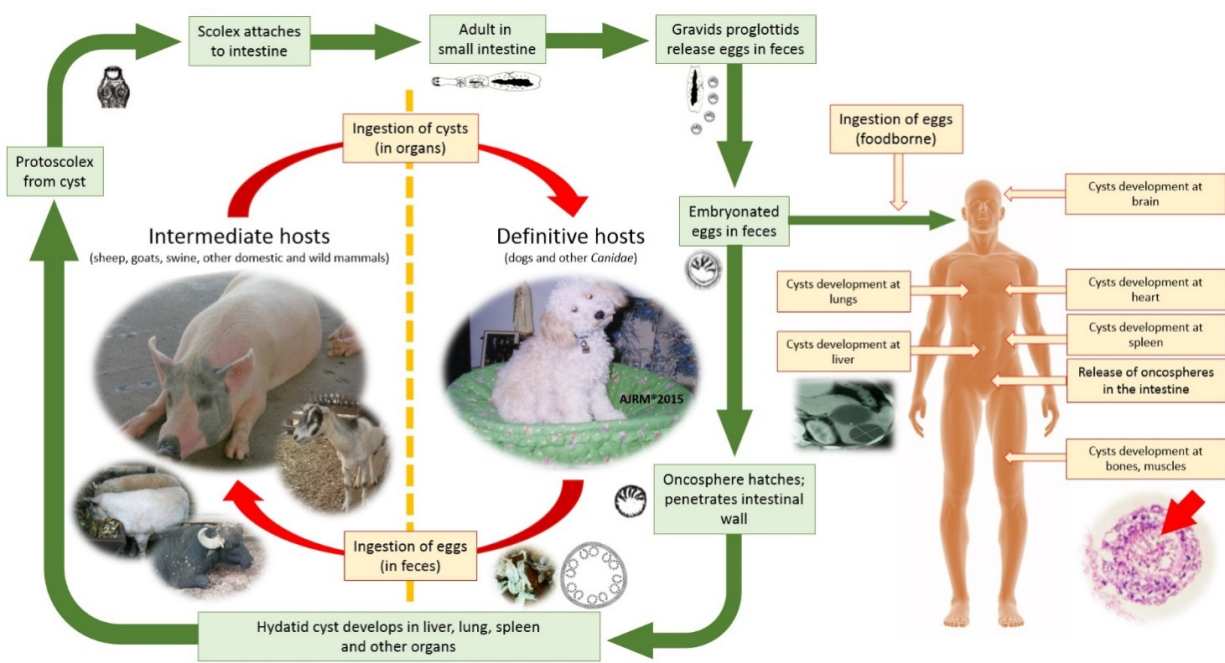


Figure 2. Life cycle of echinococcosis (pictures by A. J. Rodriguez-Morales).

4. Geographical distribution

Cystic echinococcosis or cystic hydatidosis (caused by *E. granulosus*) is an important public health problem in South America, the Middle East and Eastern Mediterranean, some sub-Saharan African countries, China, the former Soviet Union, Russia, and the new related countries (Figure 3) [7, 8]. The overall prevalence of echinococcal infection is underestimated in many countries because systematic population surveys are not performed in all endemic areas, and this disease is not under surveillance neither in humans nor in animals in most of these countries [9]. Even more, in some countries, such as Colombia, there are reports from animal health authorities claiming that echinococcosis as a disease has “never” been registered in the country [49]. In endemic areas, its incidence has been estimated to be around 50 cases per 100,000 population per year [10].

In South America, although there is underreporting, it has been estimated that each year there would be occurring 2,000 cases [3], but these are not the exact figures. Uruguay has reported 9.2 cases per 100,000 population in 1995, and Chile has reported between 6.6 and 8.4 new cases per 100,000 population per year. Besides this, echinococcosis is also a health problem in Argentina, Bolivia, Brazil, and Peru [10, 82]. In the Peruvian Andes, observed prevalence rates in one study among humans, canines, and sheep were 9%, 46%, and 32%, respectively [9].

World Health Organization (WHO) had developed a global map of the distribution of *E. granulosus* and cystic echinococcosis (hydatidosis, 2009); however, there is no recent official WHO map for distribution of other *Echinococcus* species (Figure 3) [50]. However, in 2001, WHO and World Organization for Animal Health also developed a map of the approxi-

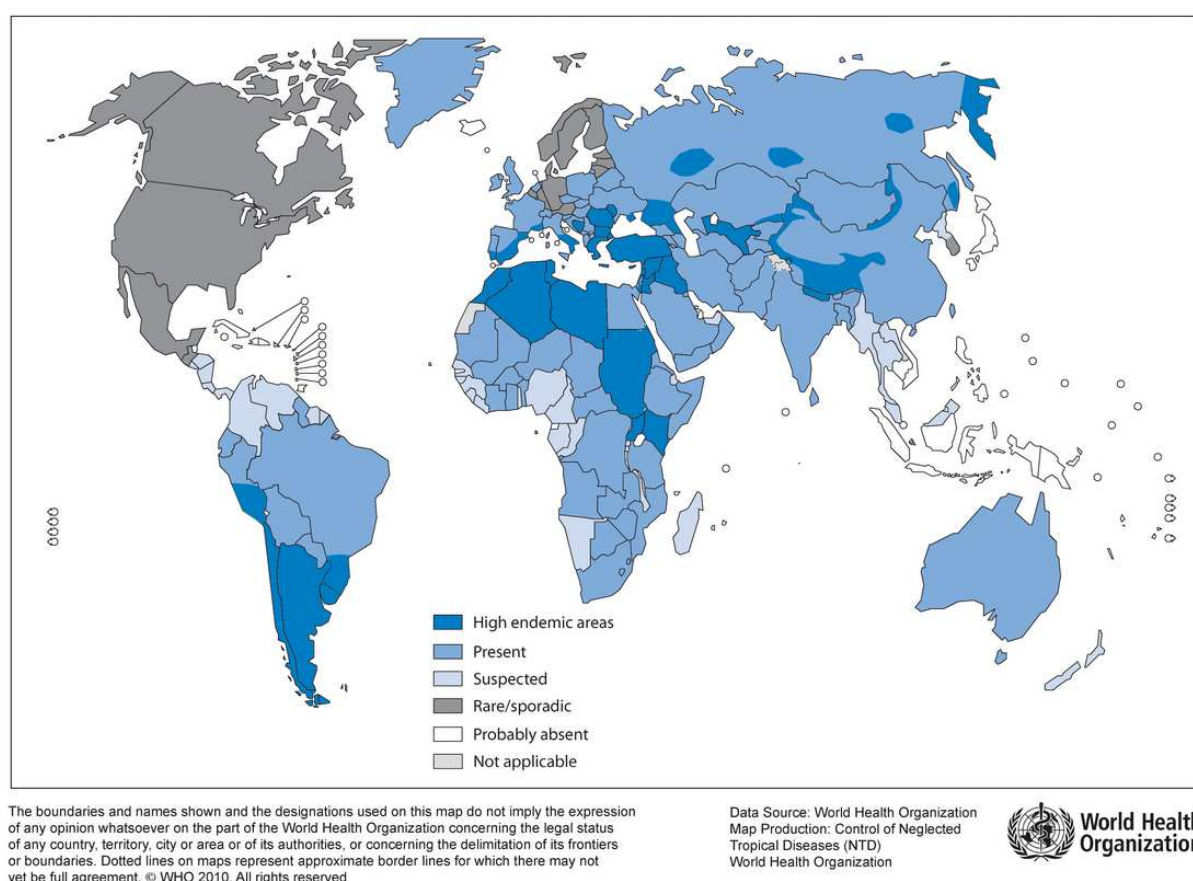


Figure 3. Distribution of *Echinococcus granulosus* and cystic echinococcosis (hydatidosis), 2009 (2010) [50].

mate geographical distribution of *E. multilocularis* and alveolar echinococcosis (1999) (Figure 4) [51, 52].

E. multilocularis is limited to the northern hemisphere (Figure 4). It occurs in Central and Eastern Europe, the former Soviet Union (now Russia), Turkey, Iraq, northern India, central China, some Japanese islands, some provinces of Canada, Alaska, and some north central states of the United States [9] (Figure 4).

Distribution of *E. oligarthrus* and *E. vogeli* is limited to South and Central America, but there is no precise map regarding their presence in the countries of these regions.

Since definitive host of *E. vogeli* exists only from Panama to the North of Argentina, cases of polycystic hydatidosis outside of this region of the world are probably imported by *E. oligarthrus* [9]. However, there are no precise estimations of *E. oligarthrus*. An attempt to map the distribution of *E. vogeli* was presented in 2005 by Colombian authors (Figure 5).

Normally, infections from species of the genus *Echinococcus* involve wild and rural hosts; however, due to human actions (temporary by recreation and work, but also definitive) which have permanently used dogs in work grazing and fed them with viscera of sacrificed animals, this cycle has been altered [6]. Since all types of echinococcosis or hydatidosis are acquired by ingestion of water or food contaminated with the eggs in the feces shed by the carnivores, it

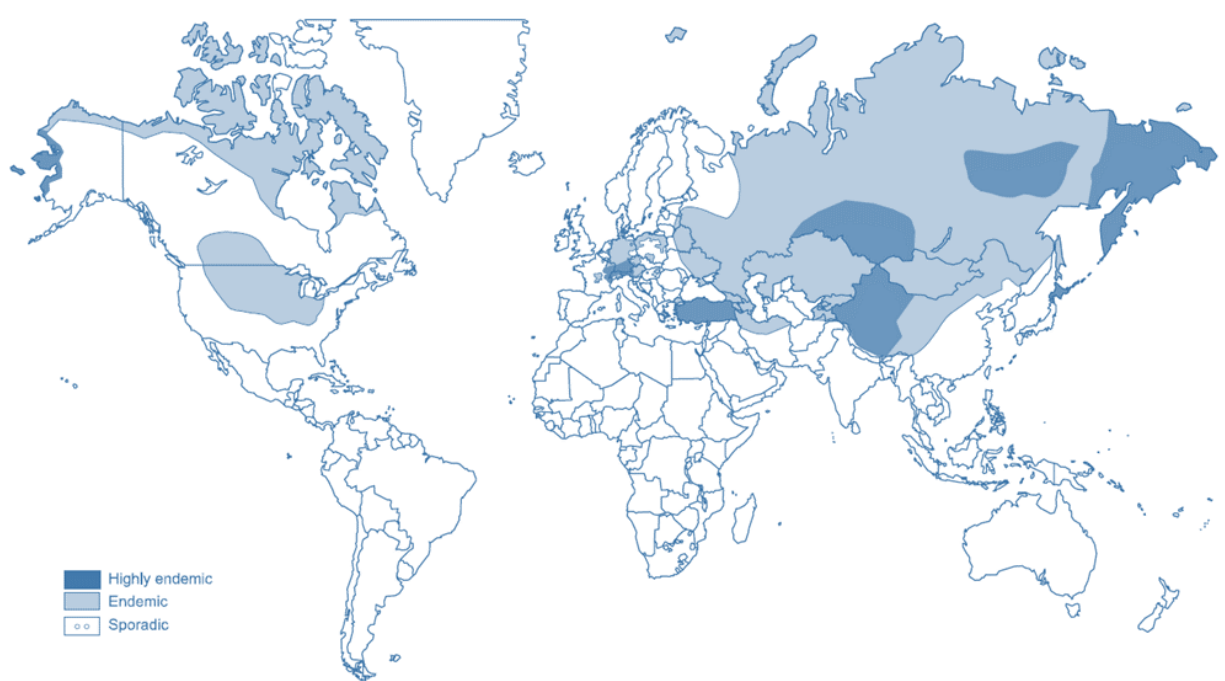


Figure 4. Approximate geographical distribution of *Echinococcus multilocularis* and alveolar echinococcosis (1999) [51, 52].

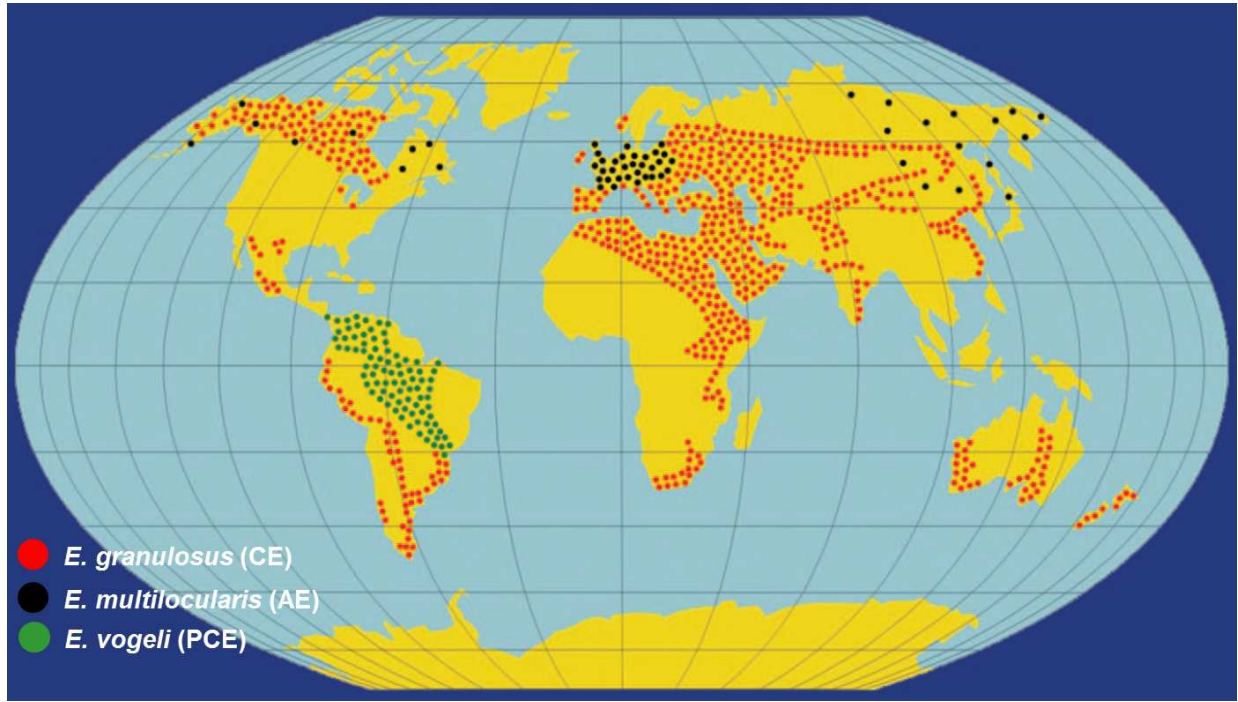


Figure 5. Drawing illustrates the geographic distribution of hydatid disease from *Echinococcus granulosus* (red dots), *E. multilocularis* (black dots), and *E. vogeli* (green dots). *E. granulosus* is the most common of the *Echinococcus* species (1999) [53]. This is not precise and requires more specific information from the countries regarding the distribution of cases by the territories included in the map.

is advisable to take special care with the feces of these animals, especially when considering that these eggs resist partial desiccation for several months [6].

5. Echinococcosis studies in Colombia

In Colombia, echinococcosis does not seem to be a major problem if we base such assumptions from human and animal health authorities [49]. But, as has been evidenced, cases of infection with the larval forms of *E. granulosus* have been reported [11]. However, prevalence and incidence of this entity have not been determined. Echinococcosis is not under surveillance and there is no obligation to report cases related to this infection to health authorities in the country; then known cases have been just those reported in national and international biomedical literature (Figure 6).

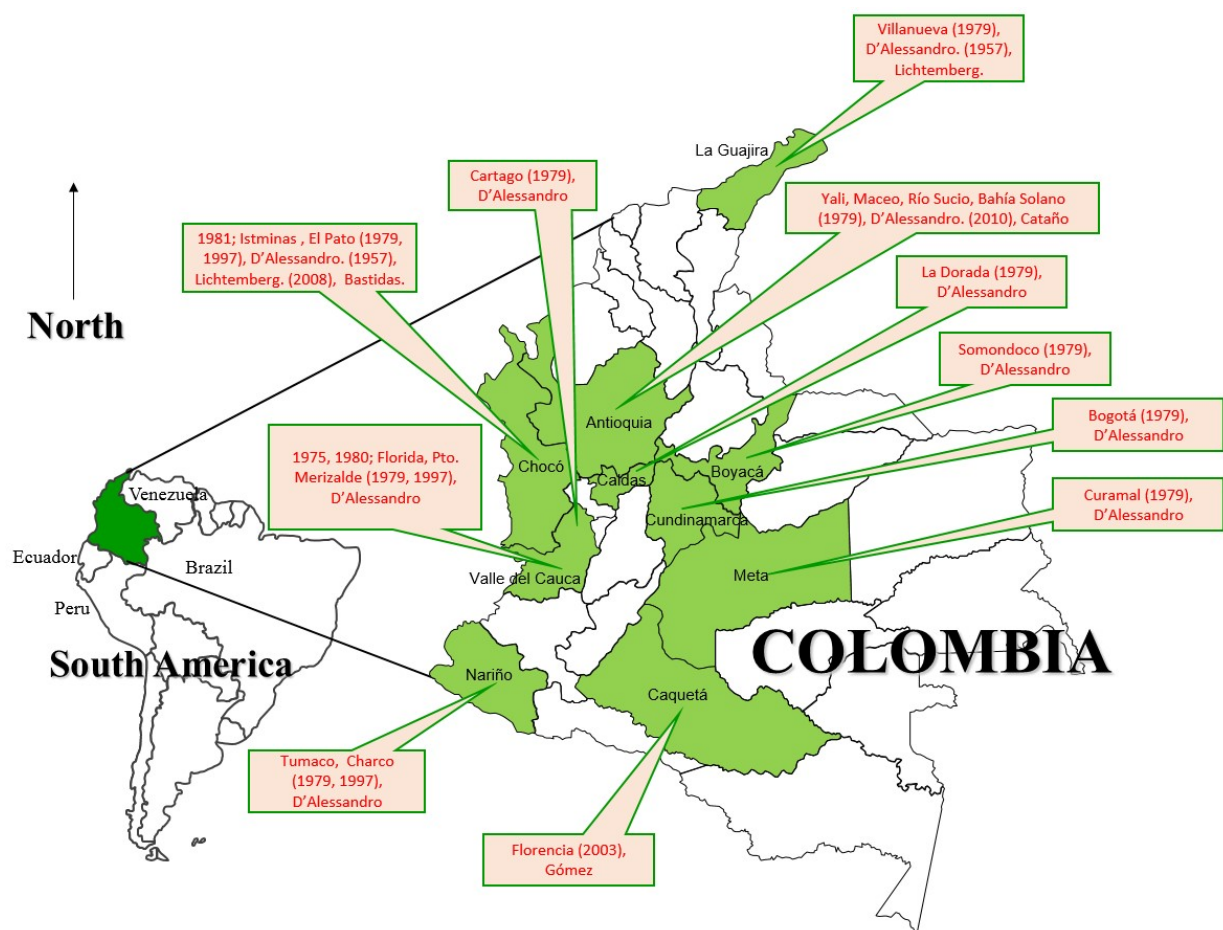


Figure 6. Departments of Colombia where cases of echinococcosis have been reported. (First date reported is the year of the case, then the location, year of publication in parenthesis, and main author.)

The first case was reported in 1941 [12], but since 1957, more cases had been reported [54] (Figure 6). Two decades later, D'Alessandro began studies in the country. This author found

more than a dozen of human cases of polycystic echinococcosis produced by the larval stage of *E. vogeli* whose definitive hosts were wild and domestic dogs and intermediate host was paca ("guagua," *Cuniculus paca*) [3, 55], after suspecting the presence of disease due to four cases of calcified hydatid cysts [55].

Most of the infected people were native from Colombia who acquired the disease by ingesting food or water contaminated with dog feces and by eating raw viscera of "guagua." Botero et al. describe three more unpublished cases: two from the coast of the Pacific Ocean and one from Santa Marta [13, 14]. D'Alessandro's studies demonstrated that in Colombia, the guagua is the main intermediate host and the wild dogs known as gouache fox is the definitive host. The guatin, which is also an edible animal for Colombian indigenous tribes, is a more specific host for *E. oligarthrus* [6].

Till 2008, the country in South America with the highest number of cases reported was Brazil, with 99 cases, followed by Colombia with 29 (Figure 6) [3, 50-60]. In Colombia, some authors believe that there are more cases not reported, in fact due to the lack of records. This also probes that occurrence of echinococcosis is more evidently reported, when people in the rural and jungle areas receive health services and physicians are more aware of the disease [60].

Two years later, in 2010, another and the last case till March 2015, has been reported [61]. A case of cardiac echinococcosis, detected in echocardiographic finding in an 18-year-old woman diagnosed in Medellin, Antioquia [61]. Fortunately in this case, physicians suspected of this cestode infection; however, more awareness among physicians regarding the compromise of cardiovascular system in many parasitic diseases is still necessary, particularly in endemic areas [63-67].

Based on this review of cases, including information from the departments of the country where this disease has been reported, a map for Colombia has been proposed (Figure 6). This map shows the departments of the country (including locations of origin of one or more cases), where echinococcosis have been reported (Figure 6). At least 10 departments (out of 32 in total) have reported cases of echinococcosis (Figure 6) [14, 54, 59-61, 72].

Beyond this, with an increasing number of published reports concerning this disease, medical personnel in tropical areas, as in Colombia and more recently in Brazil, have been keenly interested in undertaking epidemiological surveys [3, 68, 69]. Even more, there is a significant zoonotic potential, given the fact that the investigations in Colombia demonstrated a large enzootic areas of transmission in the oriental plains of that country [3, 58], where multiple species and a high number of animals have been found positive in the evaluations for *Echinococcus*, particularly *E. oligarthrus*.

As in other zoonotic diseases, parasitic and of other etiologies, there is a clear need of more studies, as well as more interaction between physicians and veterinarians. More research is necessary; currently, there are just 10 reports available in Medline for Colombia (using the terms "Colombia" AND "Echinococc*" [means *Echinococcus* and/or echinococcosis]) [53, 55-60, 62, 70, 71]. There is no significantly different information available at Scopus. At SciELO, there is one additional case, a patient with hepatic hydatidosis who appeared as an eosinophilic

pleural effusion serologically confirmed, treated with combined therapy with albendazole and the percutaneous aspiration-injection-reaspiration drainage technique [72].

Finally, an undergoing research of our group is analyzing a new source of information for communicable diseases, which are not under surveillance and require compulsory notification. In Colombia, there is a service, which is now available for analyses, the so-called personal health records (*Registro Individual de Prestación de Servicios*, RIPS), where diagnoses are classified according to WHO cause groups International Classification of Diseases version 10 (ICD-10). At this system, we retrieved the cases of echinococcosis between years 2009 and 2013, finding 303 cases (Figure 7).

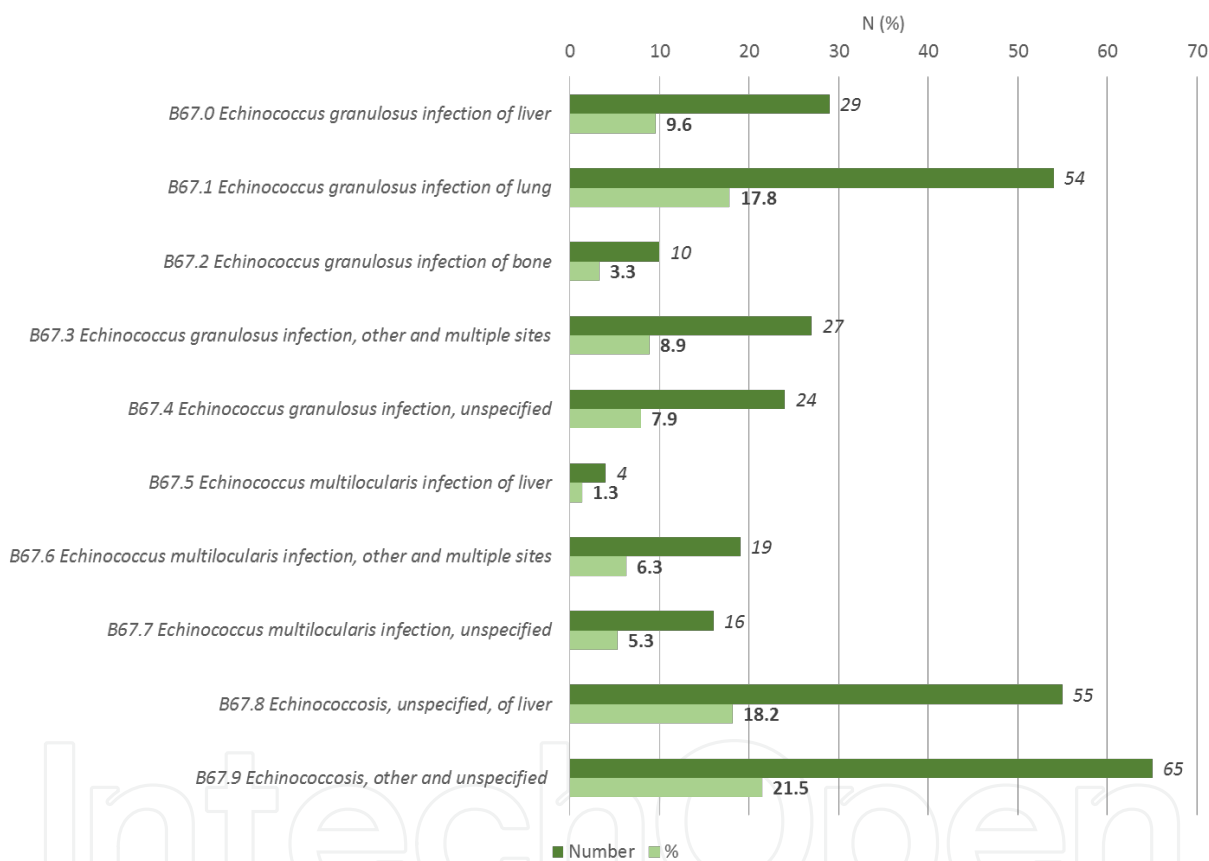


Figure 7. Cases of echinococcosis (ICD-10 codes B67.0 to B67.9) reported to the personal health records of Colombia (RIPS) during 2009–2013.

Although these cases corresponded in 18.2% to “Echinococcosis, unspecified, of liver” (B67.8) and 21.5% to “Echinococcosis, other and unspecified” (B67.9), there are 60.4% (n = 183) of them classified as infection due to *E. granulosus* (47.5%) and *E. multilocularis* (12.9%) in different organs (Figure 7), mainly lung for *E. granulosus* (17.8%) (Figure 7). Although there are limitations to this source, there is useful information that should be further analyzed. Epidemiological factors (geographic distribution, age groups, gender) involved in these cases would be of high interest in describing the situation of echinococcosis in the country.

In these cases, looked retrospectively, the limitation in the approach is that there is no information regarding the diagnostic techniques implemented in each case, and how these cases were therapeutically managed. Then, based on this information, cross-sectional and prospective studies should be implemented in the countries, and there should also be an increase in the awareness about the existence and occurrence of such diseases in different areas of the country, and particularly in those that had previously reported case reports and case series since early decades (Figure 6).

6. Economic burden of echinococcosis

According to the World Bank, economic losses due to this disease stand at the fourth position after other diseases and trauma [3].

Echinococcosis also affects the economy of the endemic regions. In humans, losses are due to costs of hospitalization, treatment, disability, etc. However, in livestock, losses are due to lost productivity, losses in quality of the wool and meat, and decreased milk production and fertility [15]. Estimated annual economic losses in Peru are \$ 178,705 [10]. In Colombia, estimation of the economic burden of this disease has not been reported, but given the increase in the number of economic evaluations of infectious diseases in the country and in the region [73, 74], there would be more clear details once the number of cases reported would be defined.

7. Clinical manifestations

Regardless of the etiology, a new concept of organ compromise was proposed in 2014, when two or more organs are affected by echinococcosis at the same time in a patient. This has been defined as multivisceral echinococcosis, simultaneous localization of hydatid cysts in more than one organ [83]. Multivisceral echinococcosis should be differentiated from multiple echinococcosis [83]. The latter is the localization of multiple cysts in one organ [83]. Even in paired organs (lungs, kidneys) if both are compromised, it will be a case of multivisceral echinococcosis, given the implications not just in diagnosis, but particularly in surgical management.

7.1. *Echinococcus granulosus*

Echinococcosis is a larval infection caused in humans by *Echinococcus* species, a metacestode with the ability to create a large spectrum of clinical manifestations, including the asymptomatic infection, and a severe and fatal disease. There are four species of echinococcosis that have been recognized that cause various forms of the disease, specifically the *E. granulosus* species which is responsible for cystic echinococcosis [16].

7.1.1. *Cystic echinococcosis*

As a general rule, the phase of primary infection is always asymptomatic because the cysts are located in different organs, characterized by their small size, which is less than 5 cm and are encapsulated. This first phase is not been associated with major pathology and might remain asymptomatic for a long period or permanently [16, 17]. The incubation period is undefined but it could be in around months or even years, before the infection becomes symptomatic. There have been reported cases of spontaneous cure due to cyst calcification and collapse and on the other hand, there are cases of early symptomatology because of cyst rupture [16, 18].

7.1.2. *Patient characteristics*

Cystic echinococcosis is seen in all ages, including patients aged below 1 year and above 75 years, with a majority between 6 and 15 years, 21 and 30, and 30 and 40 years. The most risky profession involves farm labors [16].

7.1.3. *Symptoms*

There is a huge spectrum of clinical manifestations that are variable among the patients and none of these are considered as pathognomonic of echinococcosis [16]. All the symptoms might depend on different characteristics such as the host-parasite interaction, the different organs involved, cyst size, and the presence of different complications such as cyst rupture or trauma [16, 18]. The most commonly compromised organs are the liver, followed by lung, kidney, spleen, and less common organs like muscles, skin, abdominal cavity, and pelvic cavity. The symptoms may vary in accordance with the organ involved [16-18].

Liver infections include symptoms such as hepatomegaly, cholecystitis, jaundice, liver abscess, or secondary biliary cirrhosis. Lung infections include symptoms like chest pain, expectoration, hemoptysis, and dyspnea [19]. Other severe manifestations include cyst getting rupture into biliary tree causing biliary colic, jaundice and can be confused with pancreatitis or cholangitis [16, 19].

7.1.4. *Liver involvement*

The liver is the most commonly involved organ, representing around two-thirds of the cases. The right lobe is compromised in the majority of the cases (60% to 80%) but it frequently does not produce symptoms and when these once occur, it is estimated that the cyst size is around 10 cm [20, 21]. Once a cyst develops a larger size, hepatomegaly might occur and other symptoms like right upper quadrant pain, nausea, and vomiting can also result. Due to the mass defect of the cyst compression of the portal and hepatic veins, it can result in Budd-Chiari syndrome [19, 20].

7.1.5. *Lung involvement*

The most common symptom of lung infection is the presence of cough in around 53% to 62% of the patients, followed by chest pain, dyspnea, and hemoptysis. But generally, most of the patients with lung infection are asymptomatic [21, 22].

7.1.6. *Other organs*

Heart infection might generate rupture with pericardial tamponade, cardiac insufficiency, embolism or pericardial effusion [23-25, 60, 64, 66]. The central nervous system can lead to seizures or symptoms due to an increase in the intracranial pressure [26]. Kidney disease can cause hematuria, and even glomerulonephritis and nephrotic syndrome have been described. Bones are mostly asymptomatic and only develop manifestations when a pathological fracture occurs [23].

7.1.7. *Outcome*

Surgeries are performed in around 15% of the patients after the initial diagnosis. And in patients without surgery, majority would remain asymptomatic through many years [18].

7.2. *Echinococcus multilocularis*

The most common presenting complaints include malaise, weight loss, and right upper quadrant discomfort due to hepatomegaly. Cholestatic jaundice, cholangitis, portal hypertension, and the Budd-Chiari syndrome can also occur. The clinical presentation may mimic that of hepatocellular carcinoma [18].

Extrahepatic primary disease is very rare (1% of cases). Multiorgan disease was described in 13% of cases in one series in which metacestodes involved the lungs, spleen, or brain in addition to the liver [2]. If left untreated, more than 90% of patients will die within 10 years of the onset of clinical symptoms, and virtually 100% will die by 15 years [18].

7.3. *Echinococcus oligarthus* and *Echinococcus vogeli*

These species cause polycystic echinococcosis, but they represent a very rare cause of echinococcosis disease, found in muscles and skin but it has been only described in a few cases in Brazil, Venezuela, and Surinam [16, 18, 28, 29].

8. **Diagnosis**

For an optimal diagnosis, both imaging and serological tests are required.

8.1. **Imaging**

The cysts may be visualized by ultrasonography, computed tomography (CT), or magnetic resonance imaging (MRI). However ultrasonography is the most commonly employed technique due to its easy performance and low cost. The sensitivity of ultrasonography for the evaluation of echinococcosis is 90% to 95% and the appearance of a cyst in the ultrasound is as an anechoic and smooth cyst. Another important aspect of the ultrasonography is that it helps in the classification of the disease, according to the WHO echinococcosis classification based on their ultrasound appearance. CT has an overall sensitivity of 95% to 100% and is the

preferred imaging test to describe the size, location, and number of cysts. MRI has the same sensitivity as that of CT and has no major advantages over CT, but it is better for the determination of intra- and extra-hepatic changes; however, it is not usually a routine examination technique in the patients [18, 27].

8.2. Serological tests

They are used in the diagnosis and follow-up of the patients. Some of the laboratory tests include complement fixation, latex agglutination, and indirect immunofluorescence [27, 84]. However, there are two important antigens of the *E. granulosus* disease [18]:

- Antigen 5 which is a parasite antigen; however, the studies have shown low specificity of its extensive use in the diagnosis [18].
- Antigen B is a lipoprotein and is related with a superior specificity in comparison with the antigen 5 [18].

8.3. Other laboratory tests for diagnosis

Nonspecific leukopenia or thrombocytopenia, mild eosinophilia, and nonspecific liver function may be detected but are not diagnostic. Hypergammaglobulinemia and elevated serum IgE levels are present in more than 50% of cases.

Imaging: On ultrasonography or CT, the lesions usually have an irregular contour with no well-defined wall, central necrosis, and irregular intralesional and wall calcifications.

8.4. Comparing serologies

Serologic tests are more reliable for diagnosis of *E. multilocularis* infection than for *E. granulosus* infection; sensitivity and specificity rates are 95% to 100%. A specific *E. multilocularis* antigen such as the affinity purified Em2 antigen from alveolar echinococcosis metacestodes is often used; the Em2-ELISA can discriminate between *E. granulosus* and *E. multilocularis* in 95% of cases. Serology usually remains positive indefinitely; following complete surgical resection, serology may normalize within a few years [18].

Cyst aspiration or biopsy: In the absence of a positive serologic test, percutaneous aspiration or biopsy may be required to confirm the diagnosis by demonstrating the presence of proto-scolices, hooklets, or hydatid membranes.

Polymerase chain reaction: Polymerase chain reaction techniques are limited to research settings but may play a diagnostic role in the future. DNA probes using Southern hybridization tests are also being developed.

9. Treatment

Echinococcosis treatment includes a multidisciplinary conduct and a general overview of the patient condition in order to provide the best management that includes surgical treatment,

pharmacological treatment, the “watch and wait,” and both of them, depending on the specific characteristics of the disease and most importantly the type of Echinococcosis that the patient develops. The overall approach depends on the different species that infect humans, particularly two of them: *E. granulosus* and *E. multilocularis*, causing cystic echinococcosis (CE) and alveolar echinococcosis (AE), respectively [85].

9.1. Cystic echinococcosis

As mentioned earlier, the treatment is complex, and even these days there are no clinical trials and studies that compare the different modalities to say which one is superior to the other. However, it is accepted that the surgical treatment can potentially remove all the *E. granulosus* cysts for complete cure [30]. The different treatment strategies include surgery, percutaneous management, pharmacological management, and observation [31].

Overall, the diagnosis approach depends on the WHO diagnostic classification, performed in 2003, when the Informal Working Group on echinococcosis established a standardized ultrasound classification based on the status of the cyst by its ultrasound appearance. This classification has the intention to promote uniform standards of diagnosis and treatment, and has important implications for the clinical decision.

There are three different stages, including CE1 and CE2 that are cyst-containing protoscolices. The CE3 stage is divided in CE3a, a detached endocyst, and CE3b, a solid cyst with daughter cysts [32]. Recommendations indicate that CE1 and CE3a stages, in which the cyst size is less than 5 cm, should be treated with albendazole only. Stages CE1 and CE3a with cyst size more than 5 cm may be treated with albendazole in combination with percutaneous treatment via PAIR (puncture, aspiration, injection, and reaspiration). The CE2 and CE3b stages are characterized by multiple cyst compartments that require individual puncture, and these patients usually require PAIR. However, the optimal choice among the different approaches (PAIR, surgery, or drug therapy) is uncertain. Finally, stages CE4 and CE5 involve inactive cysts that only require observation [33, 34].

9.2. Treatment options

9.2.1. Surgery

It is the first treatment option in cases of complicated cysts, including a cyst rupture or infection and hemorrhage. It is also an alternative treatment option for those cysts with many daughter vesicles that are not suitable for percutaneous treatment. Other indications are large liver cysts, cyst diameter more than 10cm, extrahepatic disease (lung, bone, or brain), cysts situated superficially with high risk of rupture, and cysts affecting the biliary tree [31, 35]. Contraindications are relative to each patient; for example, old-aged people, people suffering from concomitant diseases, pregnant women, or patients with small cysts [7]. As far as the complications are concerned, secondary infection, intra-abdominal abscess, fistula, or sclerosing cholangitis have been reported. Recurrent echinococcosis may occur in 2% to 25% of the cases, depending basically on the surgeon's experience [35].

Before choosing the surgical technique, it's important to administrate drug therapy to minimize the surgical risk of secondary echinococcosis from seeding of protoscolices in the abdominal cavity. Usually, albendazole is administered a week before surgery, and continued at least four weeks after the surgery. Praziquantel is another option, but there is no specific evidence regarding its efficacy [31, 36].

Surgical approach must be individualized, depending on each patient disease and its characteristics. There are two options; the first one is to remove the intact cyst, and another option is to open the cyst with protoscolicidal agents, such as hypertonic saline, followed by the evacuation of the cyst contents and removal of the cyst [31]. Other protoscolicidal used includes 70% to 95% ethanol and 0.5% cetrimide solution. The protoscolicidal agent must be in contact with the germinal layer for at least 15 minutes to make its effect. Albendazole, ivermectin, and praziquantel have been also used as protoscolicidal agents, but their efficacy and safety need more studies. Protoscolicidal agents should not be used in the presence of biliary communication, because of the risk of sclerosing cholangitis or pancreatitis [31, 35].

There is also the possibility of laparoscopic surgery for the treatment of echinococcosis; however, there are no randomized trials done yet comparing the efficacy of laparoscopy with open procedures. Possible indications for laparoscopic treatment are the presence of anteriorly located hepatic cysts, although this procedure is related with associated risk of spillage because of the elevation of intra-abdominal pressures due to the pneumoperitoneum. Contraindications include deep intraparenchymal cysts, the presence of calcified walls cyst, and cysts located next to the vena cava [31].

In a review article published in 2014 with the aim to study the world literature of the laparoscopic treatment of liver hydatid cyst, a total of 914 patients were identified to evaluate the mortality, morbidity, and clinical outcomes of the laparoscopic treatment. It was found that the most common procedure was cystectomy in 60.39% of patients, followed by partial pericystectomy with 14.77% of patients, and finally pericystectomy with 8.21% of patients, and the rest of them were treated via segmentectomy. They also reported that conversion of laparoscopy to open laparotomy occurred in the 4.92% of the cases, due to anatomical limitations and inaccessible locations. Mortality was reported in 0.22% of the patients and morbidity was reported in 15.07% of the patients. There was no intraoperative deaths reported and the most reported complication was bile leakage. In general terms, they concluded that the laparoscopic procedure is safe, with acceptable ranges of mortality and morbidity and clinical outcomes comparable to open surgery [37].

9.2.2. Percutaneous management

There are two percutaneous techniques. The first one called PAIR (puncture, aspiration, injection of a protoscolicidal agent, and reaspiration) is usually effective in the treatment of cysts without daughter cysts. And the second one, that involves the evacuation of the cyst with a large bore catheter. This technique helps in cases in which the drain becomes difficult or tends to relapse after PAIR, like in the case of WHO stages CE2 and CE3b cysts [31, 38].

Percutaneous treatment is associated with anaphylaxis, happening according to a review in the 1.6% of the patients [39]. And as in surgery, albendazole must be administered for at least one month after the percutaneous treatment [31].

9.2.3. PAIR procedure

It was first introduced in the mid-1980s and includes the realization of percutaneous puncture of the cyst by ultrasonic guidance, aspiration of the cyst fluid, injection of a protoscolicidal substance, and finally reaspiration of the cyst fluid. PAIR has the advantages of being less invasive than surgery and can be a diagnostic and therapeutic procedure and it has a success rate of more than 95%. This procedure may be used in cases of echinococcosis of WHO stages CE1 and CE3a as primary treatment and for the relapse after medical therapy in stages CE1 and CE3a, and in case of relapse after surgery. PAIR also showed to be successful in the management of liver cysts and in those cysts located in other abdominal parts such as kidney, spleen, and in the abdominal cavity. There are controversies in the use of PAIR in pregnant women and in children, although the application of PAIR is indicated in symptomatic pregnant women [16, 31, 38].

The procedure is performed by ultrasound or by CT guidance. Then the cyst is punctured and the fluid aspiration is realized and a histopathological study must be done to evaluate the presence of protoscolices. After the administration of protoscolicidal agent, the reaspiration must be done for at least 10 to 15 minutes. Four hours before PAIR, adjunctive drug therapy with albendazole or mebendazole should be administrated. Recommendations indicate that albendazole should be continued after a month of the procedure and mebendazole should be continued for three months. The most important contraindications of the PAIR are the following: the presence of cysts without drainable solid material, superficial cyst with risk of rupture in the abdominal cavity, calcified cysts, and cyst with biliary communication [31, 40].

9.2.4. Drug therapy

In most of the cases, it is useful as an adjunctive therapy to surgery and percutaneous treatment. The use of pharmacological approach as definitive management is indicated in few cases. The recommendations indicate that in cases of small cysts of WHO stages CE1 and CE3a with cyst size less than 5 cm, the initial management with only drug therapy is appropriate, with optimal duration of treatment depending on the clinical factors, but usually estimated in around one to six months. The effectiveness of pharmacological therapy decreases with the presence of a cyst size more than 5 cm, with multiple compartments of cysts [16, 31, 39].

As an adjunctive treatment, albendazole is used as perioperative drug therapy in surgery or in percutaneous treatment. It reduces the risk of recurrent disease by the inactivation of the protoscolices. There is no general consensus of the duration of the treatment, but generally it is initiated four days before surgery and continued at least one month after the surgery in case of albendazole and for three months in case of mebendazole [16, 31, 40, 42].

Albendazole is the first drug option and the primary antiparasitic agent for treatment of *E. granulosus*, and in cases of absence of albendazole, mebendazole may be used as an alternative, but it is less absorbed than albendazole. The primary action of albendazole is that it inhibits microtubules assembly, causing a glycogen depletion, followed by the degeneration of the mitochondria and the endoplasmic reticulum, finally causing the cell death. It is reported that albendazole helps cyst resolution in 30% of the patients, cyst size reduction in 30% to 50% patients, and in 20% to 40% of the patients, there are no changes in the cysts. However, the outcome of the treatment with albendazole depends on multiple factors like the clinical characteristic of the patient, the cyst size, and its location [31, 43].

However, albendazole has more advantages than mebendazole. For example, albendazole is well tolerated by patients and it takes a shorter duration of therapy. Dose of albendazole is usually 10 to 15 mg/kg per day divided in two doses and mebendazole dose is 40 to 50 mg/kg per day divided in three doses. Adverse effects include hepatotoxicity in 1% to 5% of the patients, cytopenia, and alopecia in less than 1% of the patients. Due to hepatotoxicity, there might be an increase in aminotransferase enzymes. Other rare side effect like agranulocytosis has also been reported. Contraindications of using albendazole include patients with liver disease or bone marrow suppression [31, 44]. Patients with pharmacological therapy must be monitored every two to three weeks for first three months and then monthly [31]. Praziquantel has protoscolicidal activity, but its efficacy in clinical studies is variable, but is considered as an alternative when the albendazole treatment cannot be administrated [44, 45].

Observation: Also known as the “watch and wait,” indicated in the WHO stages CE4 and CE5, in patients with absence of complications or inactive liver cysts [40].

9.3. Alveolar echinococcosis

Unfortunately, the treatment of alveolar echinococcosis is less effective than the treatment of cystic echinococcosis. The general approach to the treatment is based on surgery. The main idea is to remove all the infected tissue and sometimes it is necessary to also remove part of the host tissue. Management with albendazole is recommended after surgery with an uncertain optimal duration. The benefit of preoperative albendazole administration has not been reported [31].

10. Conclusions

Echinococcosis has always been neglected worldwide and especially in Colombia. Particularly in this country, research was done and published only between 1950s and 1990s. There is no subsequent interest in the occurrence of this disease and all its implications.

Due to the impact of echinococcosis, the burden it creates, and the consequences in the patients, it becomes important to create strategies in order to improve and have a better control on this disease in our country. This probably should begin at medical schools, where more emphasis

on teaching about this parasitic disease, would increase awareness about it. As has been mentioned earlier, there should be regular interaction among physicians, biologists and veterinarians to better understand the implications of this zoonotic disease, which at least from an enzootic point of view is clearly extended. As an additional reflection in the middle of the process and discussion about peace in Colombia, there are chances that once this would be reached, after the La Habana discussions, more people, not only missionary, health, and military corps, would be allowed to enter in the guerrillas-controlled areas, which are precisely located where enzootic evidences of echinococcosis have been reported, increasing the exposure to species of *Echinococcus* and probably making more visible the occurrence of this disease in the country [78].

Even more, it's not clear yet, if Colombia would be considered properly a risky area for travelers visiting the country in the view of acquisition of echinococcosis. But certainly in other highly endemic countries, echinococcosis is included in the list of infectious diseases that can be acquired during travel, and cases of echinococcosis, as well from other cestodiasis, have been reported increasingly during the last few years [75-78].

Therefore, it becomes crucial to create a clear and easy consensus to help and guide the physicians to make a better approach towards helping the patients in finding the opportune diagnosis and the best treatment option. The creation of a normative and the global vision of echinococcosis as a public health problem might help improve the control of this disease.

Echinococcosis, and other zoonotic diseases, can re-emerge just when they are considered to be under control or eliminated. They can go into hiding in the animal reservoirs, so there is no possibility for complacency [78]. Epidemiology of zoonoses such as echinococcosis is complex and dynamic, being influenced by varying parameters that can roughly be categorized as human-related, pathogen-related, and climate/environment-related [79, 80]. But certainly for echinococcosis, there is still much to understand.

Acknowledgements

Authors would like to thank the critical comments of anonymous reviewers. Also, Dr. Rodriguez-Morales would like to thank Dr. Juliana Buitrago-Jaramillo, Dean, Faculty of Health Sciences, Universidad Tecnológica de Pereira, Pereira, Risaralda, Colombia, for her support to his research group during the activities in year 2014, including presentation and conferences at major international meetings (mainly in Peru, Mexico, and Cuba), and also in 2015 (Ecuador). The authors would also like to thank the Asociación Colombiana de Infectología and International Society for Chemotherapy, for supporting the research and presentations of studies in zoonoses since 2011 (Italy, Japan, Brazil, Ecuador, Mexico, Peru, Cuba). Finally, the authors would like to thank the Ministry of Health of Colombia, for the access to SIVIGILA and RIPS databases through the system Cubo de datos del SISPRO.

Author details

Alfonso J. Rodriguez-Morales^{1,2,3*}, Lauren Sofia Calvo-Betancourt⁴, Camila Alarcón-Olave⁵ and Adrián Bolívar-Mejía⁶

*Address all correspondence to: arodriguez@utp.edu.co

1 Public Health and Infection Research Group, School of Medicine and School of Veterinary Medicine and Zootechnics, Faculty of Health Sciences, Universidad Tecnológica de Pereira, Pereira, Risaralda, Colombia

2 Committee on Zoonoses and Haemorrhagic Fevers, Asociación Colombiana de Infectología, Bogotá, DC, Colombia

3 Working Group on Zoonoses, International Society for Chemotherapy, Aberdeen, United Kingdom

4 Fundación Cardiovascular de Colombia, Floridablanca, Santander, Colombia

5 Universidad Autónoma de Bucaramanga, Bucaramanga, Santander, Colombia

6 Clínica FOSCAL Internacional, Floridablanca, Santander, Colombia

References

- [1] Moro P, Schantz P. Echinococcosis: A review. *Int J Infect Dis.* 2009;13: 125-133.
- [2] McManus D, Zhang W, Li J, Bartley P. Echinococcosis. *Lancet.* 2003;362:1295-1304.
- [3] D'Alessandro A, Rausch RL. New aspects of neotropical polycystic (*Echinococcus vogeli*) and unicystic (*Echinococcus oligarthrus*) echinococcosis. *Clin Microbiol Rev.* 2008;21(2):380-401.
- [4] Khanfar N. Hydatid disease: A review and update. *Curr Anaesth & Crit Care.* 2004;15:173-183.
- [5] Soledad S, Rodríguez V, Candia M, Bonastre P. Hidatidosis Pulmonar. *Revista de Posgrado de la VIa Cátedra de Medicina.* 2005;152:16-18.
- [6] Bonilla C. Hidatidosis: Una zoonosis de múltiples Presentaciones clínicas. *Revista Investigación y Desarrollo Social. Universidad Militar Nueva Granada.* 2001;24:89-106.
- [7] Jenkins DJ, Romig T, Thompson RC. Emergence/re-emergence of *Echinococcus* spp. A global update. *Int J Parasitol.* 2005;35:1205-1219.

- [8] Romig T, Dinkel A, Mackenstedt U. The present situation of echinococcosis in Europe. *Parasitol Int.* 2006;55:S187-S191.
- [9] Moro P. Epidemiology and control of echinococcosis. UpToDate. Last updated October 15, 2014.
- [10] Salgado, DS, Suárez-Ognio, L & Cabrera, R. Características clínicas y epidemiológicas de la equinococosis quística registrados en un área endémica en los andes centrales del Perú. *Neotrop Helminthol.* 2007;1(2):69-83.
- [11] Moro P, Schantz P. Cystic echinococcosis in the Americas. *Parasitol Int.* 2006;55:S181-S186.
- [12] Perez V. Origen, desarrollo y extensión de la hidatidosis en América. *Boletín de la oficina sanitaria panamericana.* February 1949; 124-156.
- [13] Botero D. Parasitosis intestinales, cisticercosis e hidatidosis. *Iatreia.* 1990;3(3):165-171.
- [14] Alessandro A. Polycystic echinococcosis in tropical America: *Echinococcus vogeli* and *E. oligarthrus*. *Acta Trop.* 1997;67:43-65.
- [15] Torgerson, PR. Economic effects of echinococcosis. *Acta Trop.* 2003;85:113-118.
- [16] WHO Informal Working Group. International classification of ultrasound images in cystic echinococcosis for application in clinical and field epidemiological settings. *Acta Trop.* 2003;85(2):253-261.
- [17] Gottstein B, Wang J, Blagosklonov O, et al. *Echinococcus metacestode*: In search of viability markers. *Parasite.* 2014;21:63. Epub; November 28, 2014.
- [18] Moro P. Clinical manifestations and diagnosis of echinococcosis. UpToDate. Last updated October 21, 2014.
- [19] Touma D, Sersté T, Ntounda R, et al. The liver involvement of the hydatid disease: A systematic review designed for the hepato-gastroenterologist. *Acta Gastroenterol Belg.* 2013;76(2): 210-218.
- [20] Stojkovic M, Junghanss T. Cystic and alveolar echinococcosis. *Handb Clin Neurol.* 2013;114:327-334.
- [21] Santivanez S, Garcia HH. Pulmonary cystic echinococcosis. *Curr Opin Pulm Med.* 2010;16:25.
- [22] Arinc S, Kosif A, Ertugrul M, et al. Evaluation of pulmonary hydatid cyst cases. *Int J Surg.* 2009;7:192.
- [23] Dziri C, Haouet K, Fingerhut A, Zaouche A. Management of cystic echinococcosis complications and dissemination: where is the evidence? *World J Surg.* 2009;33:1266.
- [24] Turgut AT, Altinok T, Topçu S, Koşar U. Local complications of hydatid disease involving thoracic cavity: Imaging findings. *Eur J Radiol.* 2009;70:49.

- [25] Díaz-Menéndez M, Pérez-Molina JA, Norman FF, et al. Management and outcome of cardiac and endovascular cystic echinococcosis. *PLoS Negl Trop Dis*. 2012;6:e1437.
- [26] Nourbakhsh A, Vannemreddy P, Minagar A, et al. Hydatid disease of the central nervous system: A review of literature with an emphasis on Latin American countries. *Neurol Res*. 2010;32:245.
- [27] Wuestenberg J, Gruener B, Oeztuerk S, et al. Diagnostics in cystic echinococcosis: Serology versus ultrasonography. *Turk J Gastroenterol*. 2014;25(4):398-404.
- [28] Soares Mdo C, Rodrigues AL, Moreira Silva CA, et al. Anatomic-clinical and molecular description of liver neotropical echinococcosis caused by *Echinococcus oligarthrus* in human host. *Acta Trop*. 2013;125(1):110-114.
- [29] Zimmerman DM, Douglass M, Reavill DR, Greiner EC. *Echinococcus oligarthrus* cystic hydatidosis in Brazilian agouti (*Dasyprocta leporina*). *J Zoo Wildl Med*. 2009;40(3):551-558.
- [30] Brunetti E, Kern P, Vuitton DA. Expert consensus for the diagnosis and treatment of cystic and alveolar echinococcosis in humans. *Acta Trop*. 2010;114(1):1-16.
- [31] Moro P. Treatment of echinococcosis. UpToDate. Last updated March 06, 2013.
- [32] Brunetti E, Filice C. Echinococcosis Hydatid Cyst Workup. Medscape. Last updated October 19, 2011.
- [33] Rinaldi F, Brunetti E, Neumayr A, et al. Cystic echinococcosis of the liver: A primer for hepatologists. *World J Hepatol*. 2014;6(5):293-305.
- [34] Stojkovic M, Rosenberger K, Kauczor HU, Junghanss T, Hosch W. Diagnosing and staging of cystic echinococcosis: How do CT and MRI perform in comparison to ultrasound? *PLoS Negl Trop Dis*. 2012;6(10):e1880.
- [35] McNanus D, Gray DJ, Zhang W, Yang Y. Diagnosis, treatment, and management of Echinococcosis. *BMJ*. 2012;344:e3866.
- [36] Bygott JM, Chiodini PL. Praziquantel: Neglected drug? Ineffective treatment? Or therapeutic choice in cystic hydatid disease? *Acta Trop*. 2009;111:95.
- [37] Tuxun T, Zhang JH, Zhao JM, et al. World review of laparoscopic treatment of liver cystic echinococcosis—914 patients. *Int J Infect Dis*. 2014;24:43-50.
- [38] Ormeci N. PAIR vs Örmeci technique for the treatment of hydatid cyst. *Turk J Gastroenterol*. 2014;25(4):358-364.
- [39] Neumayr A, Troia G, de Bernardis C, et al. Justified concern or exaggerated fear: the risk of anaphylaxis in percutaneous treatment of cystic echinococcosis—a systematic literature review. *PLoS Negl Trop Dis*. 2011;5:e1154.

- [40] Rinaldi F, De Silvestri A, Tamarozzi F, et al. Medical treatment versus "Watch and Wait" in the clinical management of CE3b echinococcal cysts of the liver. *BMC Infect Dis.* 2014;14:492.
- [41] Neumayr A, Tamarozzi F, Goblirsch S, Blum J, Brunetti E. Spinal cystic echinococcosis—a systematic analysis and review of the literature: Part 2. Treatment, follow-up and outcome. *PLoS Negl Trop Dis.* 2013;7(9):e2458.
- [42] Popa GL, Tanase I, Popa CA, et al. Medical and surgical management of a rare and complicated case of multivisceral hydatidosis: 18 years of evolution. *New Microbiol.* 2014;37(3):387-391. Epub Jul 1, 2014.
- [43] Pensel PE, Castro S, Allemandi D2, et al. Enhanced chemoprophylactic and clinical efficacy of albendazole formulated as solid dispersions in experimental cystic echinococcosis. *Vet Parasitol.* 2014;203(1-2):80-86.
- [44] Alvela-Suárez L, Velasco-Tirado V, Belhassen-Garcia M, et al. Safety of the combined use of praziquantel and albendazole in the treatment of human hydatid disease. *Am J Trop Med Hyg.* 2014;90(5):819-22.
- [45] Larrieu E, Zanini F. Critical analysis of cystic echinococcosis control programs and praziquantel use in South America, 1974-2010. *Rev Panam Salud Publica.* 2012;31(1):81-87.
- [46] Thompson RC. Neglected zoonotic helminths: *Hymenolepis nana*, *Echinococcus canadensis* and *Ancylostoma ceylanicum*. *Clin Microbiol Infect.* 2015;S1198-743X(15)00184-6. doi: 10.1016/j.cmi.2015.01.004. [Epub ahead of print]
- [47] Zheng H, Zhang W, Zhang L, et al. The genome of the hydatid tapeworm *Echinococcus granulosus*. *Nat Genet.* 2013;45(10):1168-1175. doi: 10.1038/ng.2757.
- [48] D'Alessandro A, Rausch RL, Morales GA, Collet S, Angel D. *Echinococcus* infections in Colombian animals. *Am J Trop Med Hyg.* 1981;30(6):1263-1276.
- [49] ICA. Sistema de información y vigilancia epidemiológica. Sanidad Animal 2008. Situación epidemiológica en Colombia con respecto de las enfermedades. 2008. Available at: [http://www.ica.gov.co/getattachment/e205da92-1991-4de4-b412-29d6dae2ae40/2008-\(1\).aspx](http://www.ica.gov.co/getattachment/e205da92-1991-4de4-b412-29d6dae2ae40/2008-(1).aspx).
- [50] World Health Organization. Distribution of *Echinococcus granulosus* and cystic echinococcosis (hydatidosis), 2009. 2010. Available at: http://gamapserver.who.int/mapLibrary/Files/Maps/Global_echinococcosis_2009.png.
- [51] World Health Organization Office International des Epizooties. WHO/OIE Manual on Echinococcosis in Humans and Animals: A Public Health Problem of Global Concern. 2001; Paris, France: World Organization for Animal Health.
- [52] Eckert J, Deplazes P. Biological, epidemiological, and clinical aspects of echinococcosis: A zoonosis of increasing concern. *Clin Microbiol Rev.* 2004;17(1):107-135.

- [53] Martínez S, Restrepo CS, Carrillo JA, et al. Thoracic manifestations of tropical parasitic infections: A pictorial review. *Radiographics*. 2005;25(1):135-155.
- [54] Lichtember E. Equinococosis humana (quiste hidatídico) dos casos. *Revista de la Facultad de Medicina (Bogotá)*. 1957; 25(3-4):119-127.
- [55] D'Alessandro A, Lega J, Vera MA. Cystic calcifications of the liver in Colombia. Echinococcosis or calcified abscesses? *Am J Trop Med Hyg*. 1966;15(6):908-913.
- [56] D'Alessandro A, Rausch RL, Morales GA, Collet S, Angel D. Echinococcus infections in Colombian animals. *Am J Trop Med Hyg*. 1981;30(6):1263-1276.
- [57] Rausch RL, D'Alessandro A, Rausch VR. Characteristics of the larval Echinococcus vogeli Rausch and Bernstein, 1972 in the natural intermediate host, the paca, Cuniculus paca L. (Rodentia: Dasyproctidae). *Am J Trop Med Hyg*. 1981;30(5):1043-1052.
- [58] Wells EA, D'Alessandro A, Morales GA, Angel D. Mammalian wildlife diseases as hazards to man and livestock in an area of the Llanos Orientales of Colombia. *J Wildl Dis*. 1981;17(1):153-162.
- [59] D'Alessandro A, Rausch RL, Cuello C, Aristizabal N. Echinococcus vogeli in man, with a review of polycystic hydatid disease in Colombia and neighboring countries. *Am J Trop Med Hyg*. 1979;28(2):303-317.
- [60] Cataño J. Cardiac echinococcosis, an unusual echocardiographic finding. *Am J Trop Med Hyg*. 2010;82(2):173.
- [61] Gómez G, Córdoba E, Córdoba A. Quiste hidatídico hepático. *Rev Colomb Gastroenterol*. 2003;18:183-186.
- [62] Morales GA, Guzman VH, Wells EA, Angel D. Polycystic echinococcosis in Colombia: The larval cestodes in infected rodents. *J Wildl Dis*. 1979;15(3):421-428.
- [63] Bolívar-Mejía A, Rodríguez-Morales AJ, Paniz-Mondolfi AE, Delgado O. Cardiovascular manifestations of human toxocariasis. *Arch Cardiol Mex*. 2013;83(2):120-129.
- [64] Hidron A, Vogenthaler N, Santos-Preciado JJ, et al. Cardiac involvement with parasitic infections. *Clin Microbiol Rev*. 2010;23(2):324-349.
- [65] Franco-Paredes C, Rouphael N, Méndez J, et al. Cardiac manifestations of parasitic infections. Part 1: Overview and immunopathogenesis. *Clin Cardiol*. 2007;30(4):195-199.
- [66] Franco-Paredes C, Rouphael N, Méndez J, et al. Cardiac manifestations of parasitic infections. Part 2: Parasitic myocardial disease. *Clin Cardiol*. 2007;30(5):218-222.
- [67] Franco-Paredes C, Rouphael N, Méndez J, et al. Cardiac manifestations of parasitic infections. Part 3: Pericardial and miscellaneous cardiopulmonary manifestations. *Clin Cardiol*. 2007;30(6):277-280.

- [68] Pastore R, Vitali LH, Macedo Vde O, Prata A. A serological survey of the infection by *Echinococcus* sp. in the municipality of Sena Madureira, AC. *Rev Soc Bras Med Trop*. 2003;36(4):473-477.
- [69] Rodrigues-Silva R, Peixoto JR, de Oliveira RM, MagalhãesPinto R, Gomes DC. An autochthonous case of *Echinococcus vogeli* Rausch & Bernstein, 1972 polycystic echinococcosis in the state of Rondônia, Brazil. *Mem Inst Oswaldo Cruz*. 2002;97(1):123-126.
- [70] Thatcher VE. Neotropical echinococcosis in Columbia. *Ann Trop Med Parasitol*. 1972;66(1):99-105.
- [71] Howells RE, Schnur LF. Hydatid cysts in spiny rats in Amazonas, Colombia. *Ann Trop Med Parasitol*. 1978;72(4):395-396.
- [72] Bastidas A, Velásquez JC, Pérez CE. Derrame pleural eosinofílico por hidatidosis hepática: presentación de caso clínico y revisión de la literatura. *Revista Med*. 2008;16(1):45-55.
- [73] De la Hoz F, Alvis N, Narváez J, et al. Potential epidemiological and economical impact of two rotavirus vaccines in Colombia. *Vaccine*. 2010;28(22):3856-3864.
- [74] Mezones-Holguín E, Bolaños-Díaz R, Fiestas V, et al. Cost-effectiveness analysis of pneumococcal conjugate vaccines in preventing pneumonia in Peruvian children. *J Infect Dev Ctries*. 2014;8(12):1552-1562.
- [75] Branci S, Ewertsen C, Thybo S, et al. Cystic echinococcosis of the liver: Experience from a Danish tertiary reference center (2002-2010). *J Travel Med*. 2012;19(1):28-34.
- [76] Hellgren U, Botero-Kleiven S, Jansson A, Isaksson B. [Cystic echinococcosis. An imported severe parasitic disease.] *Lakartidningen*. 2012;109(1-2):30-33.
- [77] Ito A, Budke CM. Culinary delights and travel? A review of zoonotic cestodiasis and metacestodiasis. *Travel Med Infect Dis*. 2014;12(6 Pt A):582-591.
- [78] Rodriguez-Morales AJ, Schlagenhauf P. Zoonoses and travel medicine: "one world--one health". *Travel Med Infect Dis*. 2014;12(6 Pt A):555-556.
- [79] Cascio A, Bosilkovski M, Rodriguez-Morales AJ, Pappas G. The socio-ecology of zoonotic infections. *Clin Microbiol Infect*. 2011;17(3):336-342.
- [80] Pappas G, Cascio A, Rodriguez-Morales AJ. The immunology of zoonotic infections. *Clin Dev Immunol*. 2012;2012:208508.
- [81] Otero-Abad B1, Torgerson PR. A systematic review of the epidemiology of echinococcosis in domestic and wild animals. *PLoS Negl Trop Dis*. 2013;7(6):e2249.
- [82] Mayor P, Baquedano LE, Sanchez E, et al. Polycystic echinococcosis in Pacas, Amazon region, Peru. *Emerg Infect Dis*. 2015;21(3):456-459.

- [83] Grozavu C, Ilias M, Pantile D. Multivisceral echinococcosis: Concept, diagnosis, management. *Chirurgia (Bucur)*. 2014;109(6):758-768.
- [84] Wuestenberg J, Gruener B, Oeztuerk S, et al. Diagnostics in cystic echinococcosis: Serology versus ultrasonography. *Turk J Gastroenterol*. 2014;25(4):398-404.
- [85] Gomez I, Gavara C, López-Andújar R, et al. Review of the treatment of liver hydatid cysts. *World J Gastroenterol*. 2015;21(1):124-131.