

We are IntechOpen, the world's leading publisher of Open Access books Built by scientists, for scientists

6,900

Open access books available

186,000

International authors and editors

200M

Downloads

Our authors are among the

154

Countries delivered to

TOP 1%

most cited scientists

12.2%

Contributors from top 500 universities



WEB OF SCIENCE™

Selection of our books indexed in the Book Citation Index
in Web of Science™ Core Collection (BKCI)

Interested in publishing with us?
Contact book.department@intechopen.com

Numbers displayed above are based on latest data collected.
For more information visit www.intechopen.com



Radiological Characteristics of Pulmonary Hydatid Cysts

Dilek Emlik, Kemal Ödev, Necdet Poyraz and
Hasan Emin Kaya

Additional information is available at the end of the chapter

<http://dx.doi.org/10.5772/60884>

Abstract

Hydatid disease is a parasitic infection caused by *Echinococcus granulosus* (EG), characterized by cystic lesions in the liver, lungs, and rarely in other parts of the body. Lungs and liver are the most frequent sites involved. Simultaneous lung and liver cysts are observed in less than 10% of the cases. Hydatid cysts are found more frequently in the lungs of children and adolescents than in their liver, while most cysts in adults are hepatic and relatively few are in the lungs. The hydatid serology results are often negative in patients with isolated pulmonary hydatidosis, and hence may not be helpful in problematic cases. Radiologic approach to the intact, complicated, or ruptured pulmonary hydatid cysts includes a CT scan following the chest radiograph. Thoracic CT may be supplemented with magnetic resonance (MR) imaging and occasionally with ultrasound (US) in clarifying a pleural-based hydatid cyst as extrapleural, pleural, or parenchymal.

Keywords: Thoracic hydatid disease, radiography, CT, MRI

1. Introduction

Echinococcus granulosus is a tapeworm of dogs and other carnivores. Eggs are passed in the feces of the dog and ingested by an intermediate host, commonly sheep or cattle, where they develop and grow into cystic structures [1]. After ingesting the cysts by carnivorous dogs, the life cycle is completed and numerous tapeworms develop in the intestine of the definitive host. Humans act as accidental intermediate hosts and harbor cysts that are most

commonly found in the liver and lung but echinococcal cysts may develop in almost any part of the body except hair, teeth, and fingernails [2]. The liver is the most common site of infection followed by the lung in 15%-25% of the cases, and other sites (spleen, kidney, brain, bone) in about 10% of the cases [3-5].

Hydatid disease, caused by EG, is endemic in some countries, particularly those where sheep and cattle are raised, such as Australia, New Zealand, the Mediterranean countries, the Middle East, and South America [5-7]. Hydatid disease affects not only those living in endemic regions but also those in regions with a high rate of immigration from endemic areas [8].

The purpose of this chapter is to show the spectrum of the pathogenesis, clinical manifestations and imaging findings of pulmonary hydatid cysts in adults and children based on our experience.

2. Pathogenesis and pathology

Hydatid cyst may develop in almost any part of the body except hair, teeth, and fingernails [2]. Liver is the most frequently involved organ (60%-70%) [2, 5]. Thoracic involvement may occur via a transdiaphragmatic route (0.6%-16% of cases of hepatic disease) or by means of haematogenous spread. The former results from the migration of the parasite from the liver to the pleural cavity. Pulmonary parenchymal involvement and chronic bronchial fistula can also be found. The lung is the second most common site of involvement in adults (10%-30% of cases) and the most frequent site of involvement in children and young adults [9-11]. Compressible organs, such as the lung or brain, facilitate the growth of the cyst and this has been proposed as a reason for the high prevalence of the disease in children [12, 13].

Echinococcal cysts have three layers composed of both host and parasite tissue. A non-ruptured hydatid cyst is surrounded by the pericyst, a layer derived from compressed host tissue and chronic inflammatory cells. The true cyst wall is derived from the parasite and is arranged in two layers. The acellular outer laminated ectocyst is 1 mm-2 mm thick and is lined by a one-cell-thick germinal membrane, the endocyst [12].

3. Clinical findings

Adult patients with pulmonary hydatid cyst (PHC) present with nonspecific symptoms including cough, dyspnea, hemoptysis, pleurisy, and a bulge on the thoracic wall. The majority of the intact pulmonary cysts are known to produce no symptoms or are occasionally responsible for a non-productive cough or minimal hemoptysis. Pulmonary hydatid cyst usually remains asymptomatic until the time of rupture, and the clinic presentation in these patients is directly related to whether the cyst is intact or ruptured. The cyst may rupture spontaneously or due to antihelminthic treatment, percutaneous aspiration, or coughing and can lead to severe complications, such as massive hemoptysis and tension pneumothorax. Moreover, an acute hypersensitivity reaction or severe and life threatening problems can be encountered [14-17].

Compared with adults, PHCs in children frequently remain asymptomatic and cysts are often found by chance during physical examination or by imaging studies for other reasons. Moreover, pediatric patients may have symptoms such as chest pain, fever, purulent sputum, cough, and hemoptysis in the early period of the disease caused by compression of the surrounding tissue or perforation of the cyst [16].

4. Laboratory tests

Although the diagnosis of PHCs relies heavily on radiographic appearance and epidemiologic setting, serologic tests [e.g., immunoelectrophoresis (IEP) or electrosyneresis, indirect immunofluorescence (IIF), enzyme-linked immunosorbent assay (ELISA) or hemagglutination] can provide indirect evidence of echinococcosis. They are all sensitive methods but are compromised by nonspecific cross reactivity with other helminths [51]. The hydatid serology results are often negative in patients with isolated pulmonary hydatidosis and hence may not be helpful in problematic cases [15, 18]. Serologic tests have false-positive or false-negative rates of 15%-20% and positive tests may not revert to normal until several years after cyst removal [4].

5. Imaging findings

A brief description of the morphological characterization of PHCs is essential for the understanding of various conventional chest radiographic and CT appearances that will be discussed. In adults, the typical hydatid cyst of the lungs, when discovered by chest radiography, usually presents as a large well-demarcated, spherical, homogeneous single mass (Figure 1a, 1b), multiple nodules (Figure 2a, 2b) or masses [5, 14]. The cysts may range between 1 cm and 20 cm in diameter. Large cysts can shift the mediastinum, and peripheral cysts can produce a pleural reaction, or cause atelectasis of adjacent parenchyma [5, 14, 19]. Radiographically, the closed or simple cyst (intact cyst) may simulate carcinoma of the lung, primary sarcoma of the lung, solitary metastasis, hematoma, arteriovenous aneurysm, granuloma of different etiology, benign tumors, inflammatory masses, solid or fluid-filled cysts (e.g., bronchogenic cyst, bronchiectatic cyst, dermoid cyst), and mesothelioma [5, 19]. When the cystic opacity is localized in the juxtamediastinal area, it may look like an aneurysm of the aorta, a tumor in the mediastinum or a huge left auricula. A cyst attached to the thoracic wall may resemble a tumor, a cold abscess or loculated pleural effusion. In fact, sharply circumscribed homogeneous opacity in the lung is of great value in a country with endemic hydatid disease. Multiple cysts can be confused with pulmonary metastases. The imaging studies comprise only some of the diagnostic resources that must be used [15]. Calcifications of cysts in the liver and abdomen, and even in the rest of the body, are not uncommon but in the lung parenchyma they are extremely rare [4, 5]. However, on occasion they are found in the mediastinum including heart [5].

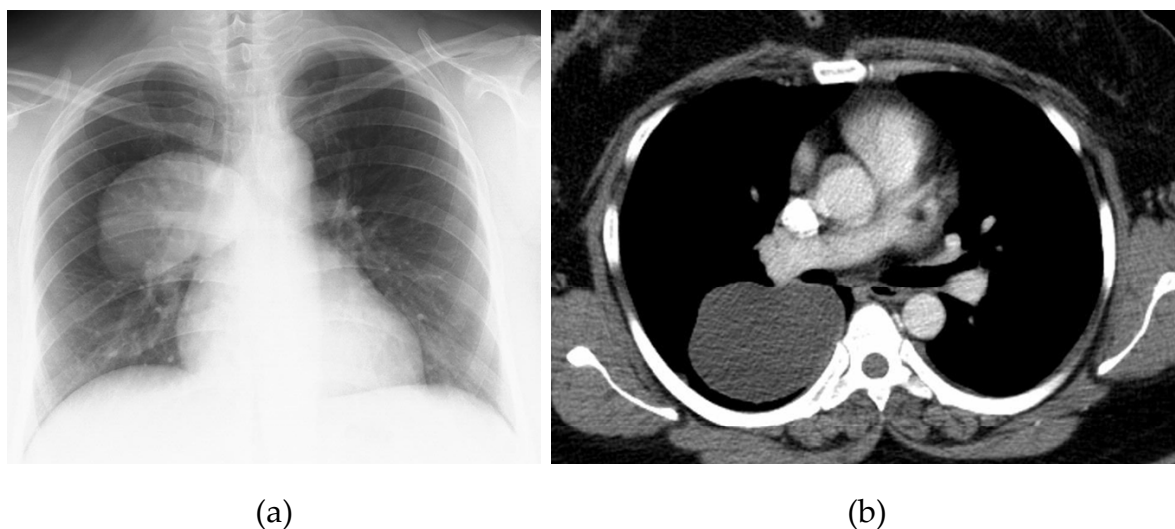


Figure 1. Intact simple cyst: (a) Chest radiograph shows a well-defined opacity located in the upper and middle zone of the right lung. (b) CT image shows that the mass has water attenuation.

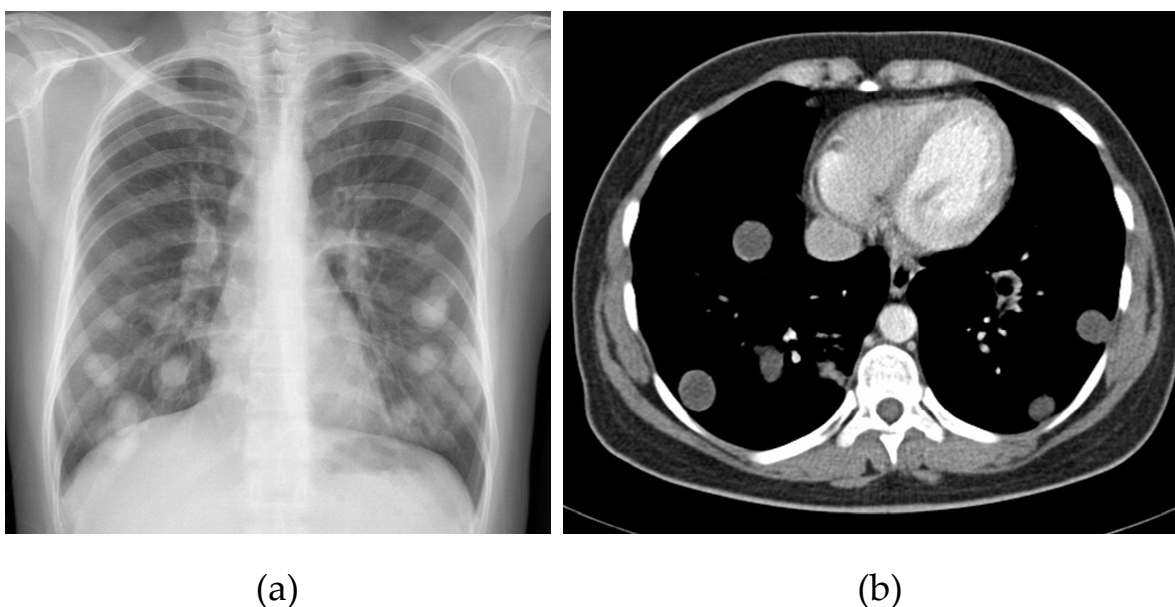


Figure 2. (a) Chest radiograph shows multiple hydatid cysts located in both lungs as well-defined lesions. (b) CT scan shows multiple hydatid cysts in both lungs as well-demarcated cystic masses.

Unlike adults, in children the rate of growth of the cyst in the lung is progressive and more constant than in the liver due to elastic capability and low resistance of the lungs. This may explain the high incidence of pulmonary disease in children [21-23]. In the literature, it has been reported that giant PHCs (greater than 15 cm) were prevalent in children (Figure 3) [22].

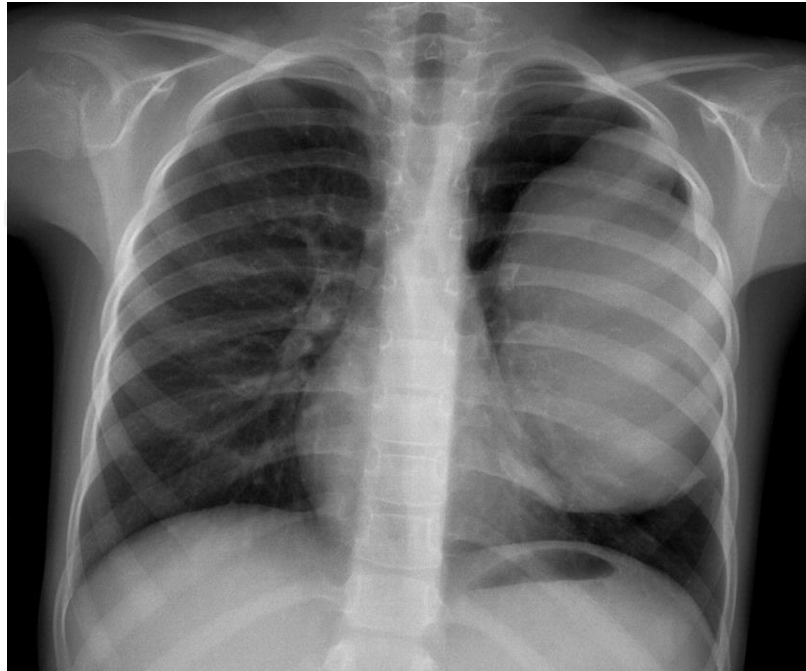


Figure 3. A 15-year-old boy. Chest radiograph shows a huge hydatid cyst located in the upper and mid-zone of the left lung causes displacement of the mediastinum to the right.

Computed tomography (CT) shows simple cysts to have smooth walls of variable thickness and homogenous internal contents of water or near-water density. The adventitious (pericyst), laminated, and germinal layers in an intact cyst are averaged together and seen as a single wall. On contrast enhanced CT, enhancement of the vascularized pericyst may not be a significant feature in intact cystic masses. However, in those cases exhibiting obvious enhancement, this finding has little or no diagnostic value [15, 18]. Chest CT can be of value in determining the presence of cysts in areas difficult to visualize with chest radiography, especially in the posterior and anterior costophrenic angles, as has been illustrated (Figure 4a, 4b) [18]. Also CT is superior to chest radiography in the cystic characterization of the parenchymal abnormality. Furthermore, determination of wall thickness is more accurate with CT, as compared with chest radiography. Multiple PHCs cause a diagnostic problem since they should be differentiated from metastatic disease, Wegener granulomatosis, and other granulomas [24]. Moreover, simple hydatid cyst cannot be differentiated from water-density lung cysts of different etiology in the basis of CT appearance alone. However, in endemic regions the CT demonstration of the cystic nature of a lung mass provides collaborative evidence in clinically suspected cases [18].

A patient with intact PHC is usually asymptomatic until the time of rupture and clinical presentation in these patients is directly related to whether the cyst is intact or ruptured. The cyst may rupture spontaneously due to trauma, degeneration by aging, or toxins. Moreover, infections, chemotherapy, or lack of nutrients may lead to the damage of the

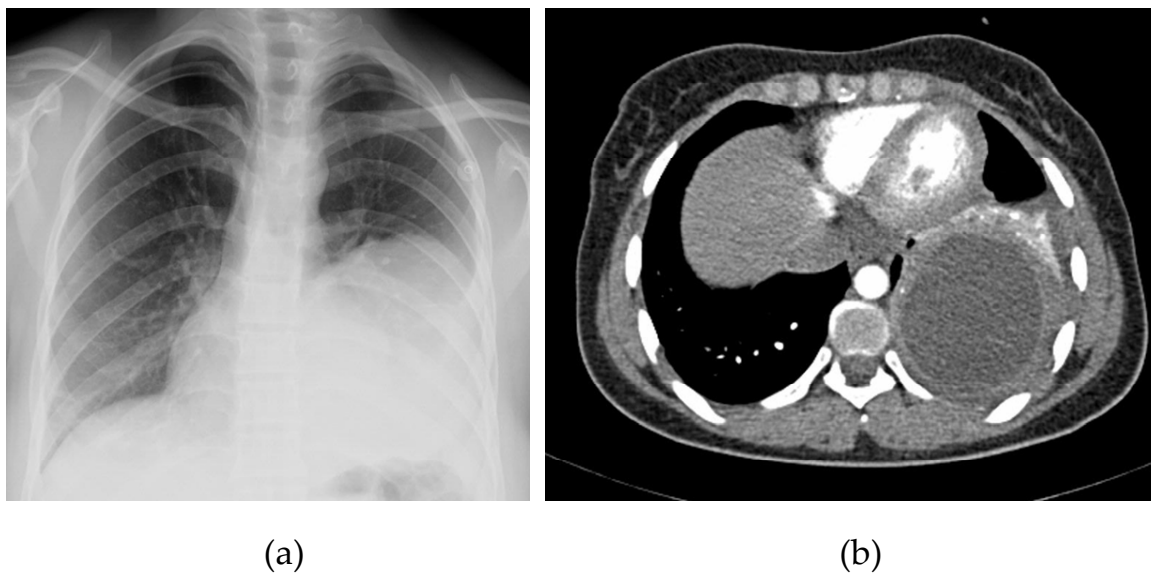


Figure 4. (a) Chest radiograph shows well-defined mass in the lower zone of the left lung obscuring the left ventricular margin and costophrenic sinus. (b) Axial CT obtained through the postero-basal segment of the left lung shows a high-density cystic lesion and also parenchymal consolidation adjacent to the HC.

cystic wall with an increased risk of rupture. As a consequence, the fragile parasite membranes may split and pressure necrosis may result in a communication with a bronchiole allowing air to dissect into the cyst wall. If air enters into the potential space between the pericyst and ectocyst (laminated membrane of the parasite), the local detachment of parasitic membranes from the pericyst is called 'the sign of detachment'. This segmental peripheral radiolucency is called 'the crescent' or the 'meniscus sign' (Figure 5). Some authors have stated that when the air enters the potential space between the pericyst and endocyst and separates the parasitic membranes, air meniscus or the crescent sign is formed [4, 14, 15]. This sign is highly reliable for hydatid disease but not pathognomonic [11, 20]. In non-endemic areas, cavities with fungus balls (mycetoma) are the most common cause of the meniscus sign, but blood clots, carcinoma, pulmonary gangrene, tuberculosis, sarcoma, and aircap within a tumor may also present with pulmonary meniscus sign [20, 25].

Expanding cysts sooner or later reach a bronchiolus and after erosion of the bronchiolus, a communication between the pericyst and bronchial tree is established. This condition causes a variety of more or less characteristic radiographic signs of ruptured PHCs, which may raise suspicion about the presence of hydatid cyst(s) or even allow a specific diagnosis of the disease. In the literature, radiologic signs related to ruptured HC have been well-described [5, 14, 20, 26, 27]. Some of these signs are double-arch or cumbo sign (Figure 6a, 6b), iceberg sign, sign of the rising sun, serpent sign, and whirl sign (Figure 7). If more air is introduced to the parasitic membranes, the endocyst collapses and an air-fluid level is seen. If the parasitic membranes are floating on the fluid surface, this produces the 'water lily sign' or 'Camelot sign' resembling leaves of a water lily (Figure 8a, 8b). If all the parasitic

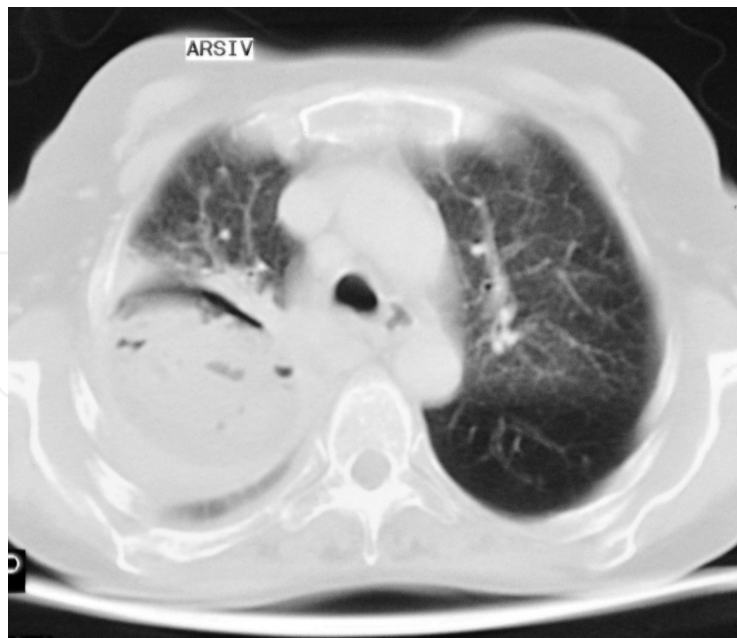


Figure 5. CT appearance of meniscus sign: A crescent shaped air is seen in the potential space between the pericyst and ectocyst of the cystic lesion.

contents are evacuated and only the pericyst produced by the host remains, it may even be filled with air. This condition is called the 'empty cyst sign' (Figure 9) [4, 14].

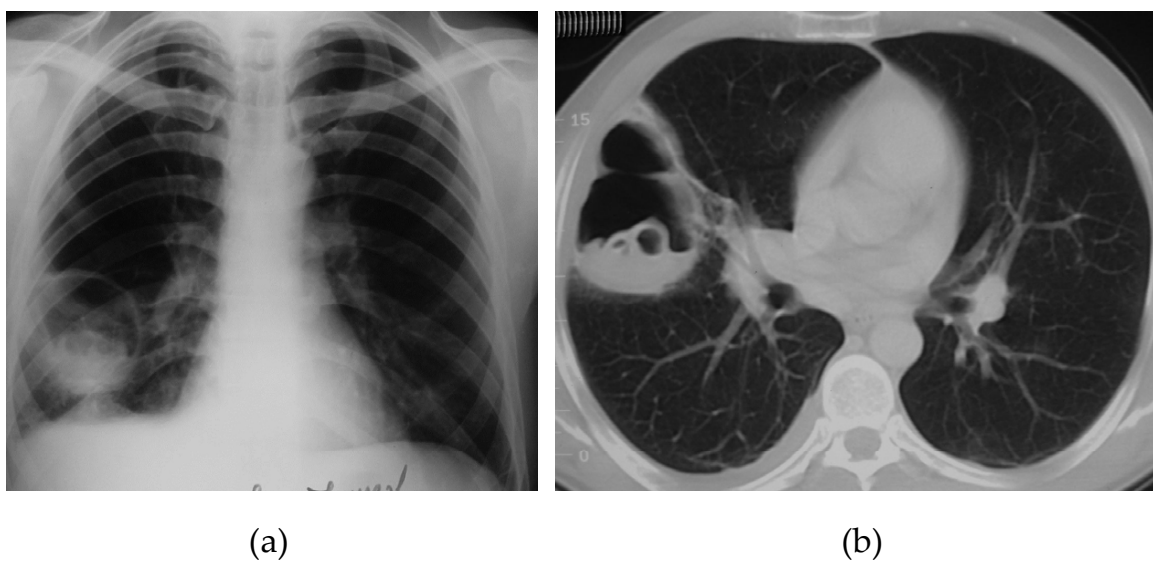


Figure 6. Cumbo sign: Double air arc is seen in (a) chest radiography and (b) CT scan.

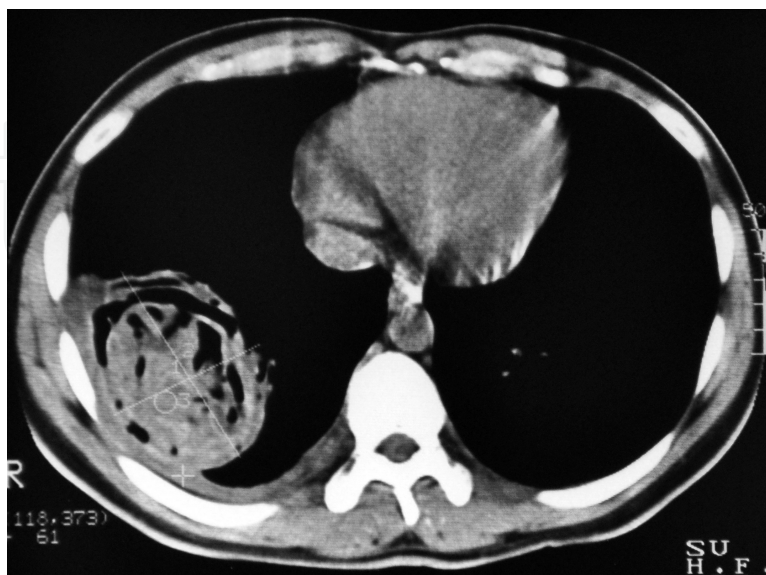


Figure 7. Whirl sign: CT scan (mediastinal window) shows floating detached membranes in the cystic cavity with minimal pleural effusion.

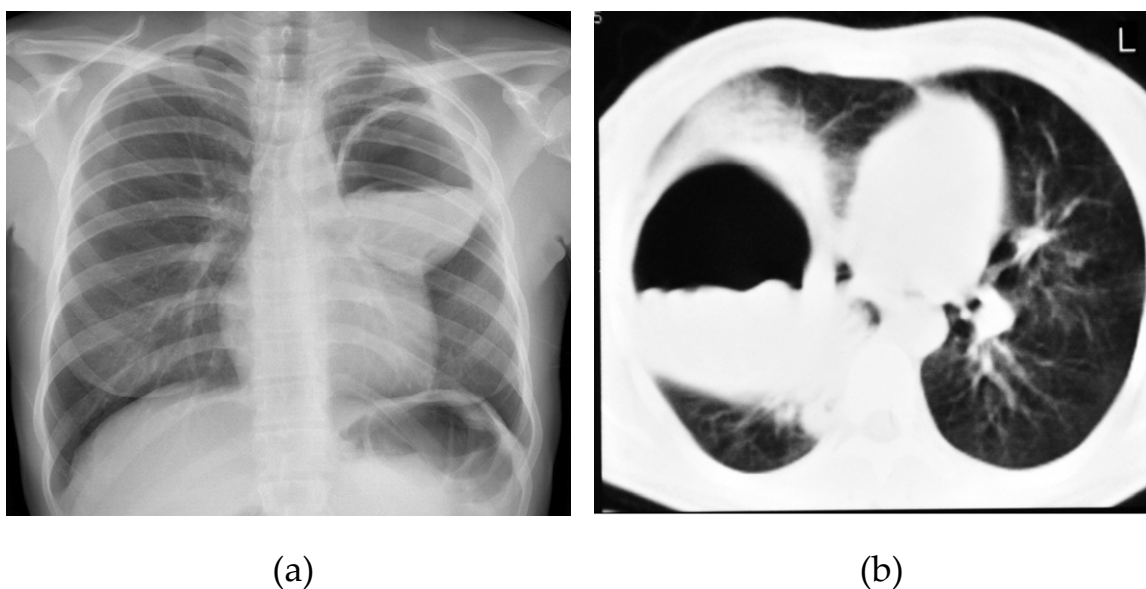


Figure 8. Water lily or Camelot sign: (a) chest radiography shows a cavitary lesion with a germinative layer in the left lung. (b) On CT scan (mediastinal window), a cystic cavitary lesion with dependent wavy contour created by floated parasitic membranes is seen.

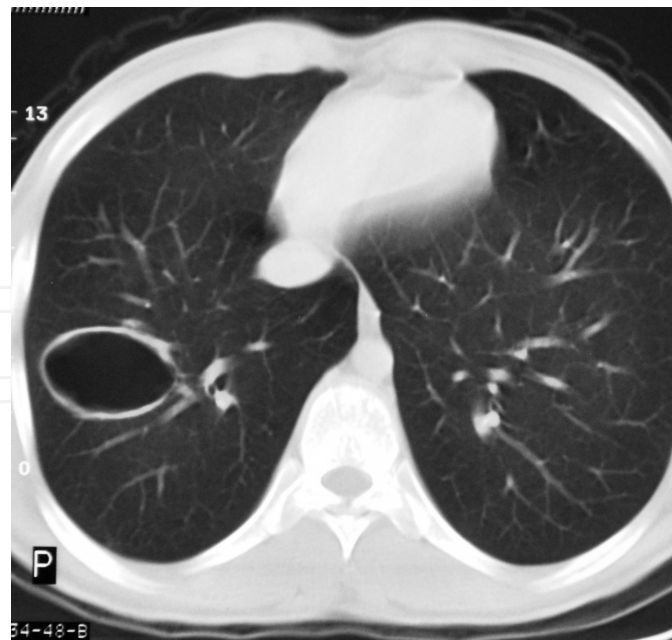

Figure 9. Empty cyst sign: CT scan of the chest shows an empty cavity with thin walls after complete evacuation of the hydatid membrane.

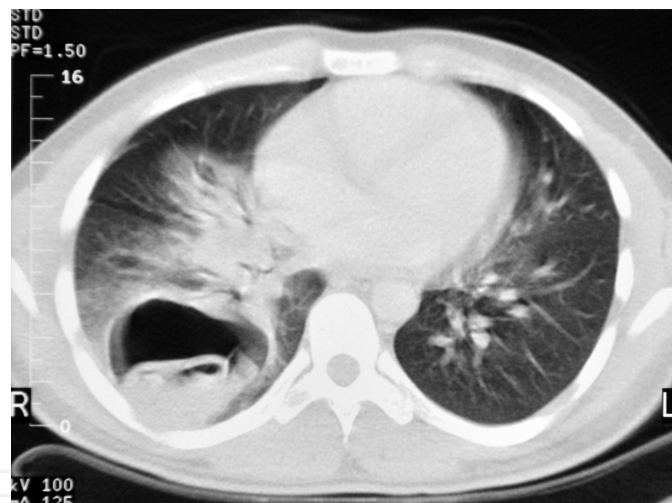


Figure 10. CT scan (mediastinal window) of the chest shows a collapsed cystic lesion.

Pathognomonic features of ruptured PHCs on CT are detached or collapsed endocyst membranes, collapsed daughter cyst membranes (Figure 10), and intact daughter cysts [18]. The most frequent complication of ruptured PHC is bacterial infection. Purulent sputum and fever are strong indicators of pneumonia or infected cyst. The presence of air pockets or air bubbles within the cyst and ring enhancement of the pericyst on contrast enhanced CT indicate either infection or communication with the bronchial tree (Figure 11a, 11b) [5, 27]. Because of the high density of infected hydatid cyst, the differentiation from a solid or fluid-filled cysts, abscess, or neoplasm is usually impossible [20, 28, 29].

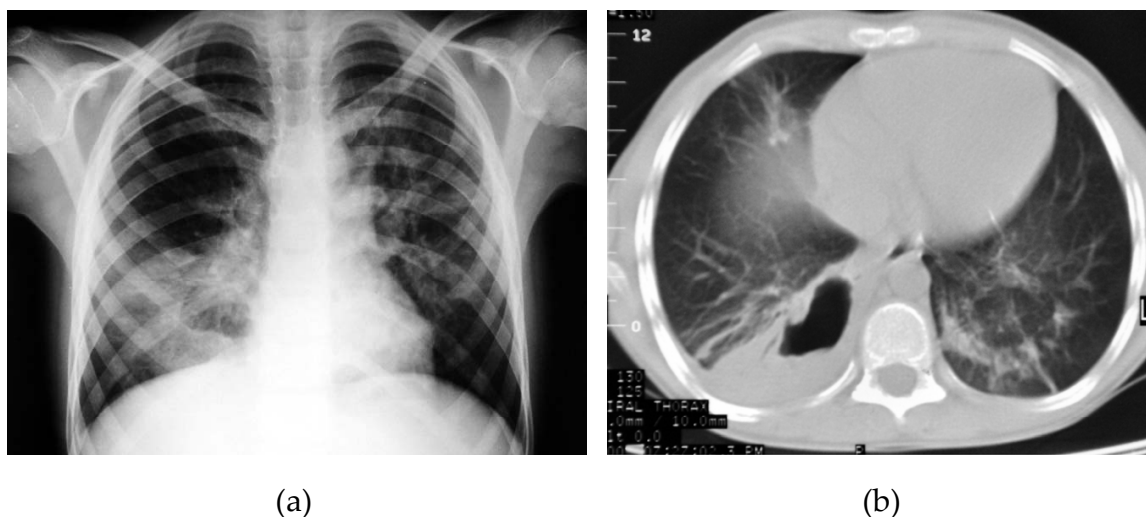


Figure 11. Infected HC: (a) Chest radiograph and (b) enhanced CT scan show an infected cavitory lesion with adjacent parenchymal consolidation in the right lung.

Infected hydatid cyst may cause uncontrolled bacterial infection and hydatid lung abscess. Further disintegration of membranes and the purulent cystic content may produce an air-fluid level with no demonstrable floating membranes [14]. A hydatid cyst with such an appearance cannot be differentiated from ordinary pyogenic abscess by CT even in endemic regions and false-positive diagnosis is inevitable. Complicated PHCs, either ruptured or infected, may have higher CT attenuation numbers than that of water due to mucus, hemorrhagic content or infection (Figure 12a, 12b). These lesions are also difficult to differentiate from other cavitory lesions, such as infarctions, hemorrhage, carcinoma, benign tumors, inflammatory masses, fluid-filled cystic lesions, and active cavitory tuberculosis [24, 26, 28-31]. Thus, transthoracic aspiration or bronchoscopic biopsy can be attempted in PHCs with atypical or complicated radiologic appearances, if there is radiologic evidence of a coexisting mass [24, 30-32].

Pulmonary arteries are exceptional localizations for hydatid cysts [33]. Most frequent cause is embolism from primary cardiac locations [34, 35]. Another possibility is that the embryos of EG pass through the liver, into the inferior vena cava, and from there via the right cardiac chambers to the pulmonary arteries [33, 36]. On contrast enhanced CT, the cystic lesions within the pulmonary arteries show the typical hypodense appearance, quite similar to other cysts in the lung. These findings should be differentiated from other intraluminal filling defects such as pulmonary embolism and pulmonary artery tumors [33, 34, 37]. On MR imaging intra-arterial cyst is typical with low signal intensity on T1 weighted images and high signal intensity on T2 weighted images (Figure 13a, 13b).

Cardiac involvement of hydatid disease is very rare. It is known that cardiac involvement is approximately 0.02%-2% of all cases of human hydatidosis (Figure 14a, 14b) [11, 33, 34]. Rupture into the heart chambers may result in embolisation of hydatid tissue in the pulmonary arteries or organs of the major circulation (secondary metastatic hydatidosis) [15, 34, 38]. Infrequently, as a result of the rupture of the right ventricle and right atrium cysts into the

pulmonary arteries, acute, subacute, or chronic recurrent embolization of hydatid cysts may be seen [34].

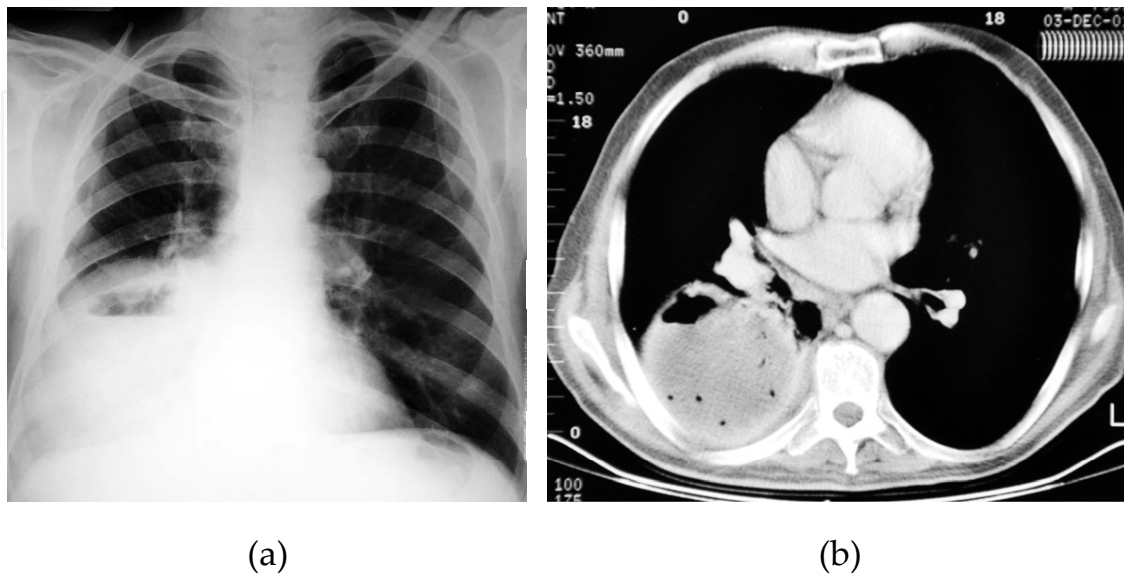


Figure 12. Abscesses: (a) Chest radiograph and (b) CT image show a thick-walled cystic lesion with air-fluid level located at the right paracardiac region with surrounding consolidation.

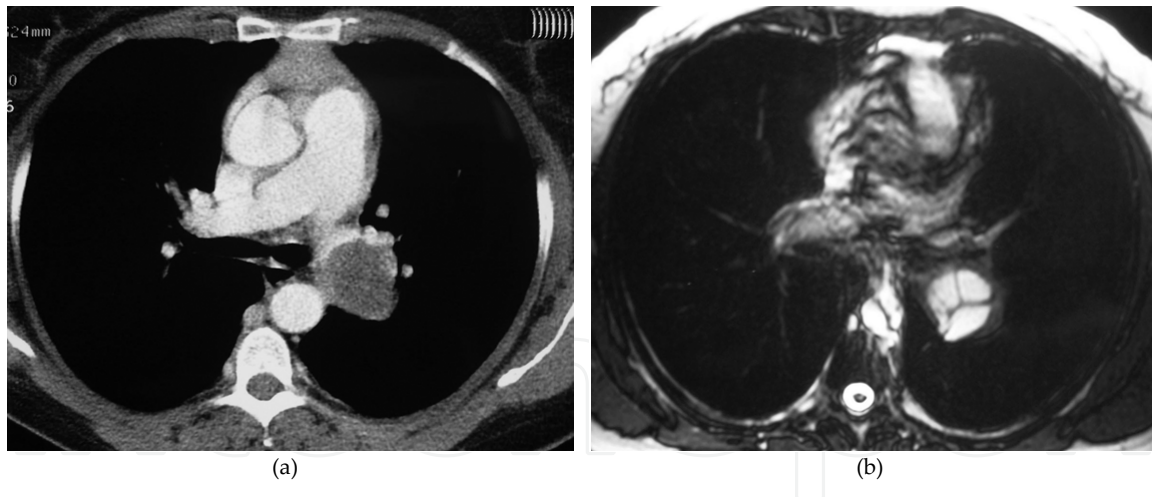


Figure 13. (a) CT scan and (b) MRI of the chest show hydatid cyst with daughter cysts inside the left pulmonary artery.

Cysts that are localized in the chest wall, mediastinum, pericard, myocard, fissure, and pleura have been reported in the literature as intrathoracic extrapulmonary cysts [39, 40]. Intrathoracic extrapulmonary hydatid cysts have been reported in 7.4% of patients [39]. Primary pleural echinococcosis, including pleural fissure (Figure 15a, 15b, 15c) is relatively uncommon even in pastoral or domestic echinococcosis [41]. Rarely infection follows the primary hematogenous dissemination of larvae to the pleural tissues.

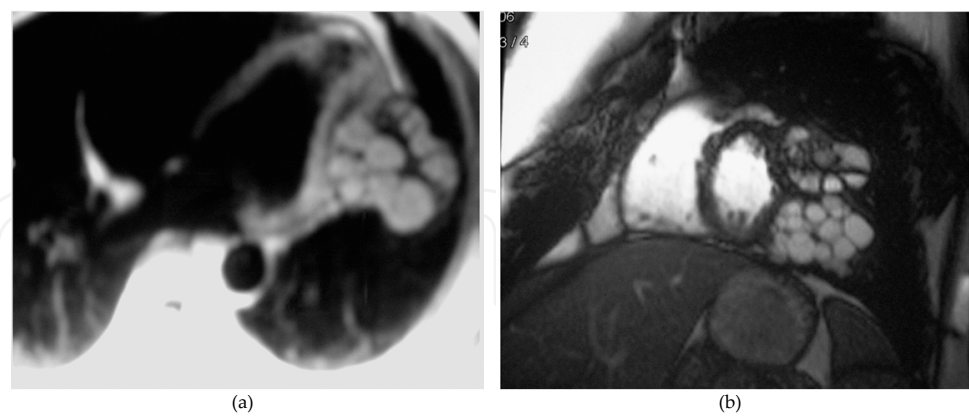


Figure 14. Primary pericardial multilocular HC. (a) Proton density weighted axial MR image shows high signal intensity of the multilocular pericardial cysts with a low signal intensity capsule in the pericardium. (b) The pericardial daughter cysts are best demonstrated with T2-weighted MR image.

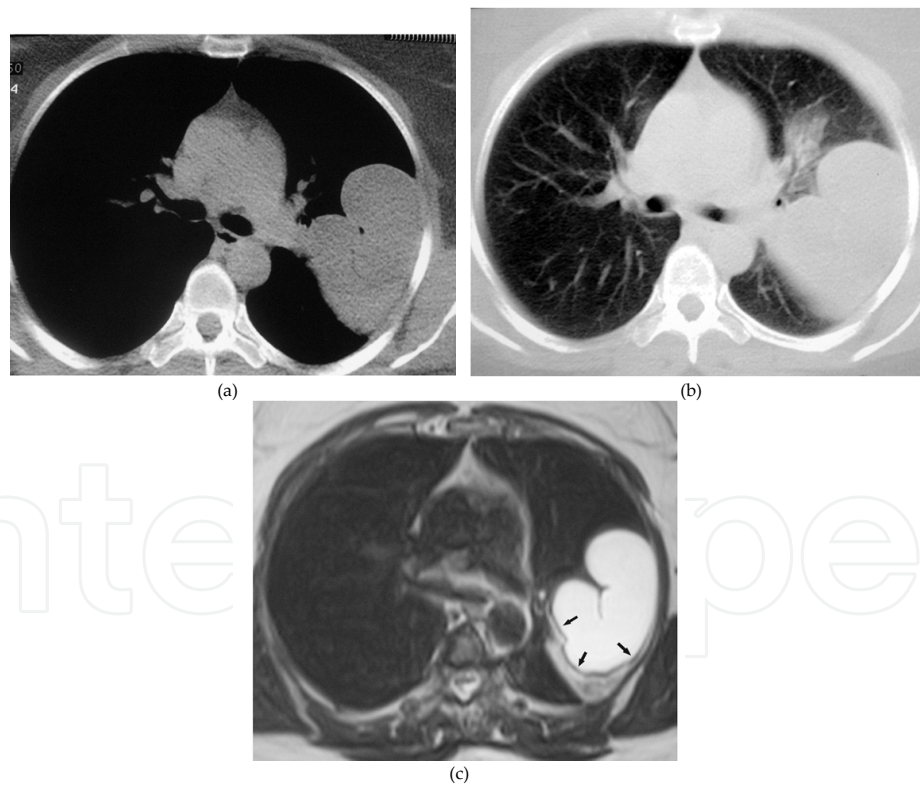


Figure 15. Primary hydatid cyst in the pleural fissure (a, b) Enhanced CT images show a hypodense lobulated mass in the left upper lung parenchyma on the mediastinal and lung window settings. (c) Axial T2-weighted MR image showing a high signal intensity cyst with a low signal intensity capsule in the left major fissure (arrows).

Pleural hydatid cyst is rare and usually caused by the rupture of a pulmonary or hepatic cyst into the pleural space, but on rare occasions it may be primary (Figure 16) [11]. Hydatid cyst that perforates into the pleural cavity (secondary pleural hydatidosis or SPH) can cause pneumothorax, tension pneumothorax, hydropneumothorax, pleural effusions, or empyema [15, 16, 56]. The documented rate of simple pneumothorax in patients with PHC ranges from 2.4% to 6.2% [15, 42]. Secondary pleural hydatidosis may also occur after percutaneous transthoracic needle puncture performed for diagnostic purposes. Secondary pleural hydatidosis may be due to hematogenous dissemination of the larvae of EG or by the rupture of neighboring hydatid cysts (multiple daughter cysts and scolices) along the pleura [41, 43]. This is a rare condition occurring in less than 10% of such cases. Although not frequent, involvement of the diaphragm (Figure 17) [44, 58], thoracic cavity or pleural space occurs in 0.6%-16% of cases of hepatic hydatid disease [13]. Transdiaphragmatic migration of hydatid disease from the posterior segment of the right hepatic lobe has been reported to be a common complication. This condition varies from simple adherence to the diaphragm to rupture into the pleural cavity [13, 45, 46]. Although ultrasound of the thorax and abdomen is useful for diagnosis of pulmonary hydatidosis [46], MR imaging is more useful in evaluation of cases with synchronous pulmonary and liver involvement and in depicting its close connection with thoracic lesions (Figure 18a, 18b, 18c) [47].

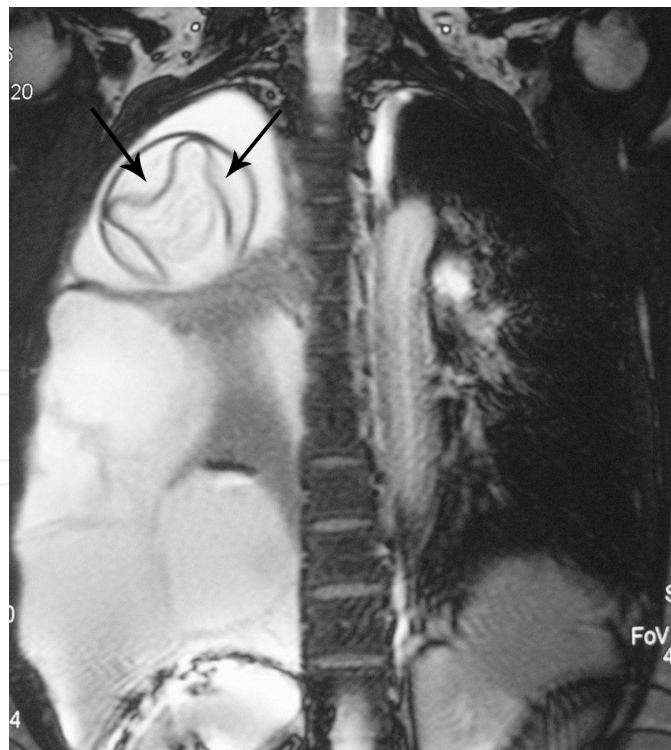


Figure 16. Ruptured primary pleural HC with diffuse pleural effusion. Coronal MRI shows a pleural HC after rupture. Detached germinal membranes are clearly seen as hypointense structures.

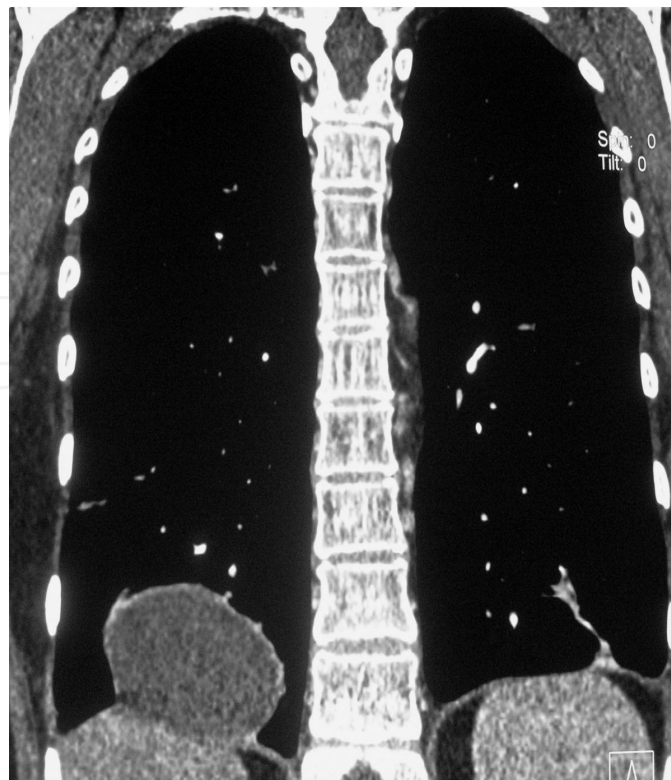


Figure 17. Primary diaphragmatic HC. Coronal and reformatted CT scans show a hydatid cyst in the right diaphragm.

Mediastinal hydatid cysts (MHCs) are very rare and are seen with an incidence ranging from 0% to 6% [11]. Several patterns of MHCs including, unilocular cyst or type 1, cyst with daughter cysts (multivesicular) or type 2 (Figure 19a, 19b), calcified cyst or type 3, and complicated cyst or type 4, have been described by using imaging techniques [47]. Characteristic finding of echinococcal cysts (e.g., floating membranes, daughter cysts, and vesicles) can usually help in establishing the diagnosis of MHCs [11, 47]. CT best demonstrates cyst wall calcification. MR imaging has the capacity of providing more information about anatomical location of MHCs. Type 2 and type 3 MHCs in the anterior mediastinum should be differentiated from cystic teratoma, thymoma, and necrotic neoplasms [11, 48].

Primary chest wall hydatid cyst is an exceptional entity. Chest wall disease presents with involvement of the anterior or lateral thoracic wall soft tissues. On contrast enhanced CT or MR imaging, the appearance of chest wall echinococcal cysts is characteristic as in other organ involvements. On contrast enhanced CT, chest wall involvement may occur as a multiloculated mass with daughter cysts in the chest wall. Multiloculated osteolytic lesion in the rib due to hydatid cyst may present as an extrapleural soft tissue mass and cause cortical expansion or destruction of the rib. This primary rib lesion slowly grows and may involve the adjacent structures such as vertebra, pleura, or subcutaneous soft tissues. The radiologic differential diagnosis includes round cell tumors, plasmacytoma, osteolytic metastases, neurofibromas, and other similar conditions that are associated with extrapleural soft tissue masses (Figure 20a, 20b) [49, 50].

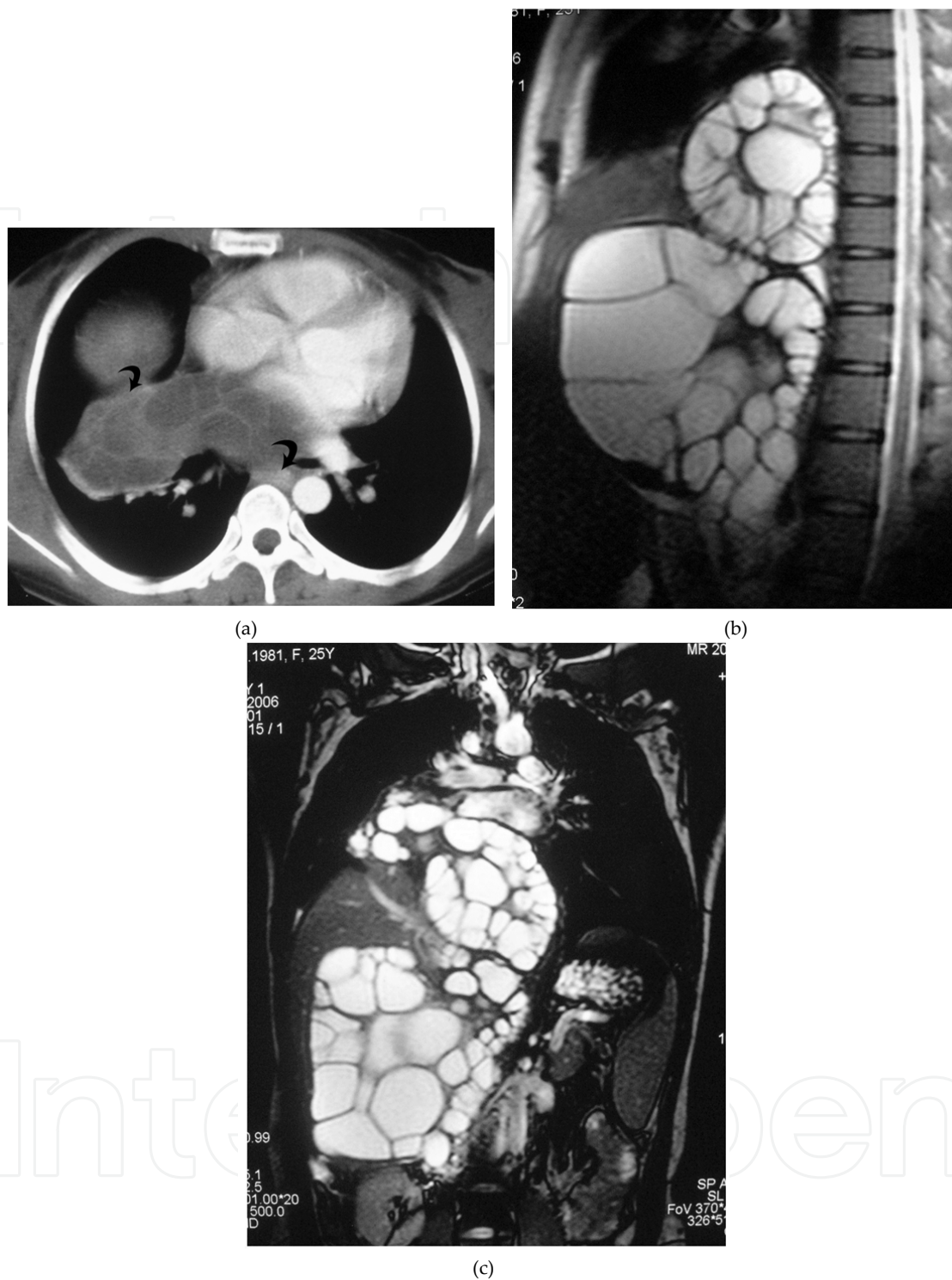


Figure 18. Posterior mediastinal HC with transdiaphragmatic extension from the abdomen. (a) Enhanced CT scan shows a large cystic mass containing multiple daughter cysts in the posterior mediastinum. (b) Sagittal and (c) coronal T2-weighted MR images show a huge cystic mass extending through the diaphragm to the posterior mediastinum from abdomen.

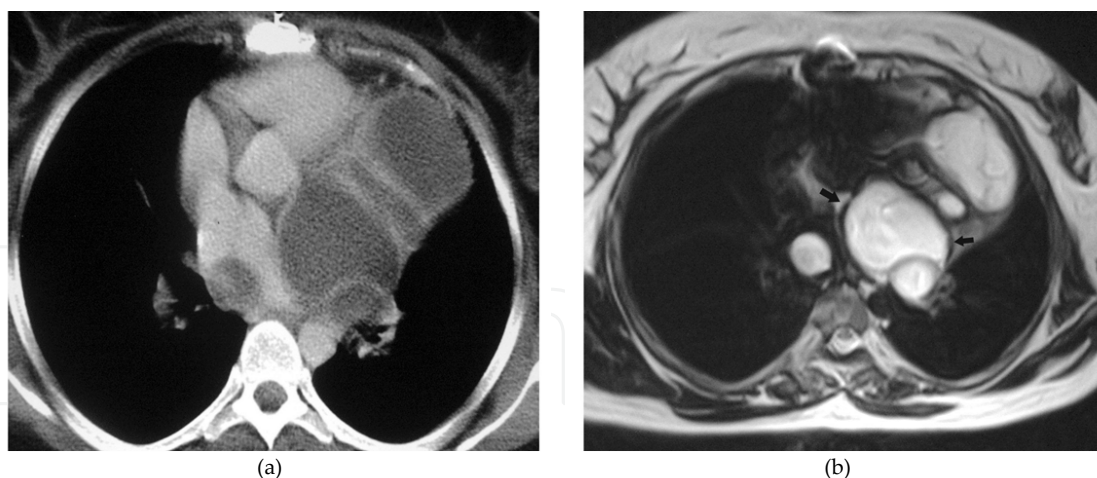


Figure 19. Mediastinal multilocular HC. (a) Enhanced CT scan shows a multilocular HC with mediastinal involvement. (b) T2-weighted MRI shows multiple high signal intensity daughter cysts with a low signal intensity capsule (arrows) in the mediastinum.

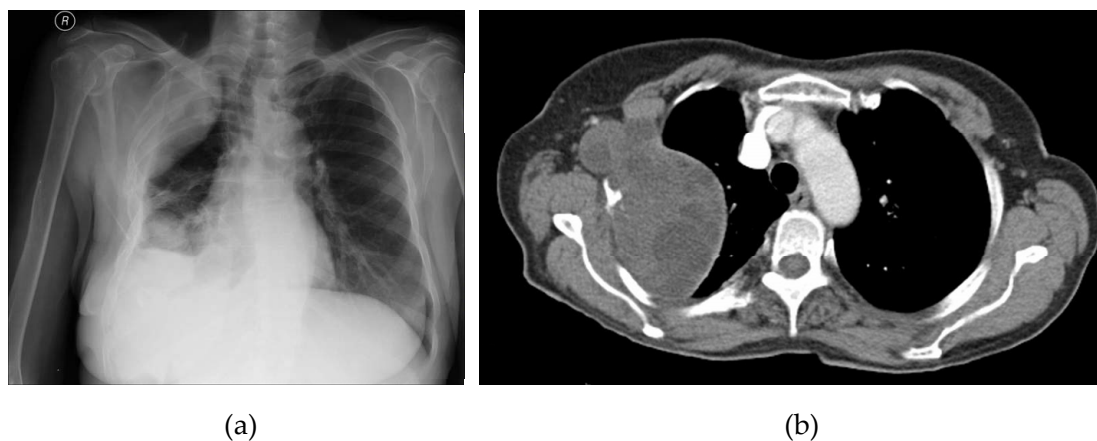


Figure 20. Chest wall HC. (a) Chest radiograph shows a bulging soft tissue mass extending to the thoracic cavity. (b) CT shows multivesicular cystic lesion involving right chest wall and adjacent ribs.

6. Conclusion

Primary diagnostic method in pulmonary hydatid disease is the plain radiograph. This method is helpful for the diagnosis of intact cysts, but it may be inadequate for the assessment of complicated cyst morphology. Computed tomography depicts certain details of the lesions and can detect others that are not visible by chest radiograph. CT examination can elucidate the cystic nature of the pulmonary lesion and provide accurate localization for planning of surgical treatment of complicated cysts. Multiplanar and multiparameter imaging features of MRI facilitate comprehensive evaluation of intrathoracic but extrapulmonary hydatid cysts (e.g., chest wall, mediastinal, pericardial, fissural, and pleural localization).

Author details

Dilek Emlik*, Kemal Ödev, Necdet Poyraz and Hasan Emin Kaya

*Address all correspondence to: drdemlik@hotmail.com

Necmettin Erbakan University, Meram Medicine School, Department of Radiology, Meram, Konya, Turkey

References

- [1] Neva FA, Brown HW. Intestinal helminths. In: Basic clinical parasitology. Norwalk, Conn.: Appleton & Lange. 1994;128-133.
- [2] Ismail MA, Al-Dabagh MA, Al-Janabi TA, et al. The use of computerised axial tomography (CAT) in the diagnosis of hydatid cysts. Clin Radiol. 1980;31(3):287-90.
- [3] Kiresi DA, Karabacakoglu A, Odev K, et al. Uncommon locations of hydatid cysts. Acta Radiol. 2003;44(6):622-36.
- [4] Beggs, I. The radiology of hydatid disease. American Journal of Roentgenology. 1985; 145(3):639-648.
- [5] Von Sinner W. Radiographic, CT and MRI spectrum of hydatid disease of the chest: A pictorial essay. European Radiology. 1993;3(1):62-70.
- [6] Sarsam A. Surgery of pulmonary hydatid cysts. Review of 155 cases. J Thorac Cardiovasc Surg. 1971;62(4):663-8.
- [7] Aytac A, Yurdakul Y, Ikizler C, et al. Pulmonary hydatid disease: Report of 100 patients. The Annals of Thoracic Surgery. 1977;23(2):145-51.
- [8] Martínez S, Restrepo CS, Carrillo JA, et al. Thoracic manifestations of tropical parasitic infections: A pictorial review 1. Radiographics. 2005;25(1):135-55.
- [9] Doğan R, Yüksel M, Cetin G, et al. Surgical treatment of hydatid cysts of the lung: Report on 1055 patients. Thorax. 1989;44(3):192-9.
- [10] Gottstein B, Reichen J. Hydatid lung disease (echinococcosis/hydatidosis). Clinics in Chest Medicine. 2002;23(2):397-408.
- [11] Polat P, Kantarci M, Alper F, et al. Hydatid disease from head to toe 1. Radiographics. 2003;23(2):475-94.
- [12] Lewall DB, McCorkell SJ. Rupture of echinococcal cysts: diagnosis, classification, and clinical implications. American Journal of Roentgenology. 1986;146(2):391-394.

- [13] Pedrosa I, Saiz A, Arrazola J, et al. Hydatid disease: radiologic and pathologic features and complications 1: (CME Available in print version and on RSNA Link). Radiographics. 2000;20(3):795-817.
- [14] Balikian JP, Mudarris FF. Hydatid disease of the lungs: a roentgenologic study of 50 cases. American Journal of Roentgenology. 1974;122(4):692-707.
- [15] Ramos G, Orduña A, García-Yuste M. Hydatid cyst of the lung: Diagnosis and treatment. World Journal of Surgery. 2001;25(1):46-57.
- [16] Kuzucu A, Soysal Ö, Özgel M, et al. Complicated hydatid cysts of the lung: Clinical and therapeutic issues. The Annals of Thoracic Surgery. 2004;77(4):1200-4.
- [17] Balci AE, Eren N, Ülkü R. Ruptured hydatid cysts of the lung in children: Clinical review and results of surgery. The Annals of Thoracic Surgery. 2002;74(3):889-892.
- [18] Saksouk FA, Fahl MH, Rizk GK. Computed tomography of pulmonary hydatid disease. Journal of Computer Assisted Tomography. 1986;10(2):226-232.
- [19] Morar R, Feldman C. Pulmonary echinococcosis. European Respiratory Journal. 2003; 21(6):1069-1077.
- [20] von Sinner WN. New diagnostic signs in hydatid disease: Radiography, ultrasound, CT and MRI correlated to pathology. European Journal of Radiology. 1991;12(2): 150-159.
- [21] Karaoglanoglu N, Kurkcuoglu IC, Gorguner M, et al. Giant hydatid lung cysts. European Journal of Cardio-thoracic Surgery. 2001;19(6):914-7.
- [22] Montazeri V, Sokouti M, Rashidi H. Comparison of pulmonary hydatid disease between children and adult. Tanaffos. 2007;6(1):13-8.
- [23] Tantawy IM. Hydatid cysts in children. Annals of Pediatric Surgery. 2010;6(2): 98-104.
- [24] Gouliamos A, Kalovidouris A, Papailiou J, et al. CT appearance of pulmonary hydatid disease. CHEST Journal. 1991;100(6):1578-81.
- [25] Reeder MM. RPC 1 of the month from the AFIP 2. Radiology. 1970;95(2): 429-437.
- [26] Ramos L, Hernández-Mora M, Illanas M, et al. Radiological characteristics of perforated pulmonary hydatid cysts 1. Radiology. 1975;116(3):539-42.
- [27] Odev K, Guler İ, Altinok T, et al. Cystic and cavitary lung lesions in children: Radiologic Findings with pathologic correlation. Journal of Clinical Imaging Science. 2013;3.
- [28] Köktürk O, Öztürk C, Diren B, et al. "Air bubble": A new diagnostic CT sign of perforated pulmonary hydatid cyst. European Radiology. 1999;9(7):1321-3.

- [29] Koul PA, Koul AN, Wahid A, et al. CT in pulmonary hydatid disease: Unusual appearances. *CHEST Journal*. 2000;118(6):1645-7.
- [30] Köksal D, Altinok T, Kocaman Y, et al. Bronchoscopic diagnosis of ruptured pulmonary hydatid cyst presenting as nonresolving pneumonia: Report of two patients. *Lung*. 2004;182(6):363-8.
- [31] Tor M, Özvaran K, Ersoy Y, et al. Pitfalls in the diagnosis of complicated pulmonary hydatid disease. *Respiratory Medicine*. 2001;95(3):237-9.
- [32] Saygi A, Oztek I, Guder M, et al. Value of fiberoptic bronchoscopy in the diagnosis of complicated pulmonary unilocular cystic hydatidosis. *European Respiratory Journal*. 1997;10(4):811-4.
- [33] Yagüe D, Lozano M, Lample C, et al. Bilateral hydatid cyst of pulmonary arteries: MR and CT findings. *European radiology*. 1998;8(7):1170-2.
- [34] Odev K, Acikgözoglu S, Gormüs N, et al. Pulmonary embolism due to cardiac hydatid disease: imaging findings of unusual complication of hydatid cyst. *European Radiology*. 2002;12(3):627-33.
- [35] Alper H, Yünter N, ScSener R. Intramural hydatid cysts of pulmonary arteries: CT and MR findings. *European Radiology*. 1995;5(6): 666-668.
- [36] Oztürk C, Ağildere A, Cila A, et al. Pulmonary arterial embolism secondary to hydatid cyst of the liver. *Canadian Association of Radiologists journal (Journal l'Association Canadienne des Radiologistes)*. 1992;43(5):374-6.
- [37] Bressler EL, Nelson JM. Primary pulmonary artery sarcoma: Diagnosis with CT, MR imaging, and transthoracic needle biopsy. *AJR. American Journal of Roentgenology*. 1992;159(4):702-704.
- [38] von Sinner W. CT and MRI findings of cardiac echinococcosis. *European Radiology*. 1995;5(1): 66-73.
- [39] Oğuzkaya F, Akçali Y, Kahraman C, et al. Unusually located hydatid cysts: intrathoracic but extrapulmonary. *The Annals of Thoracic Surgery*. 1997;64(2):334-7.
- [40] Burgos L, Baquerizo A, Munoz W, et al. Experience in the surgical treatment of 331 patients with pulmonary hydatidosis. *The Journal of Thoracic and Cardiovascular Surgery*. 1991;102(3):427-30.
- [41] Xanthakis D, Efthimiadis M, Papadakis G, et al. Hydatid disease of the chest report of 91 patients surgically treated. *Thorax*. 1972;27(5):517-28.
- [42] Aguilar X, Fernandez-Muixi J, Magarolas R, et al. An unusual presentation of secondary pleural hydatidosis. *European Respiratory Journal*. 1998;11(1):243-5.
- [43] Skerrett SJ, Plorde JJ. Parasitic infections of the pleural space. *Semin Respir Med*. 1982;13:242-258

- [44] Cattelani L, D'Ippolito R, Facciolongo N, et al. [Localization of hydatid cysts in the left hemidiaphragm. Description of a case]. *Acta bio-medica de L'Ateneo parmense: organo della Societa di medicina e scienze naturali di Parma*. 1987;59(1-2):41-7.
- [45] Gómez R, Moreno E, Loinaz C, et al. Diaphragmatic or transdiaphragmatic thoracic involvement in hepatic hydatid disease: surgical trends and classification. *World Journal of Surgery*. 1995;19(5):714-9.
- [46] Kilani T, El Hammami S, Horchani H, et al. Hydatid disease of the liver with thoracic involvement. *World Journal of Surgery*. 2001;25(1):40-5.
- [47] Emlik D, Kiresi D, Sunam GS, et al. Intrathoracic extrapulmonary hydatid disease: Radiologic Manifestations. *Canadian Association of Radiologists Journal*. 2010;61(3):170-6.
- [48] Ödev K, Arıbaş BK, Nayman A, et al. Imaging of cystic and cyst-like lesions of the mediastinum with pathologic correlation. *Journal of Clinical Imaging Science*. 2012;2.
- [49] Bonakdarpour A, Zadeh YFA, Maghssoudi H, et al. Costal echinococcosis: Report of six cases and review of the literature. *American Journal of Roentgenology*. 1973;118(2):371-7.
- [50] Ozdemir N, Akal M, Kutlay H, et al. Chest wall echinococcosis. *Chest*. 1994;105(4):1277-9.
- [51] Force L, Torres JM, Carrillo A, Buscá J. Evaluation of eight serological tests in the diagnosis of human echinococcosis and follow-up. *Clin Infect Dis*. 1992;15:473-480.