

We are IntechOpen, the world's leading publisher of Open Access books Built by scientists, for scientists

6,900

Open access books available

186,000

International authors and editors

200M

Downloads

Our authors are among the

154

Countries delivered to

TOP 1%

most cited scientists

12.2%

Contributors from top 500 universities



WEB OF SCIENCE™

Selection of our books indexed in the Book Citation Index
in Web of Science™ Core Collection (BKCI)

Interested in publishing with us?
Contact book.department@intechopen.com

Numbers displayed above are based on latest data collected.
For more information visit www.intechopen.com



Current Challenges in Understanding the Story of Skin Pigmentation — Bridging the Morpho-Anatomical and Functional Aspects of Mammalian Melanocytes

Sharique A. Ali and Ishrat Naaz

Additional information is available at the end of the chapter

<http://dx.doi.org/10.5772/60714>

Abstract

Melanocytes are specialized dendritic melanin producing pigment cells, which have originated from the pluripotent embryonic cells and are termed as neural crest cells (NCC). The primary locations of these cells are basal layer of epidermis and hair follicles. Besides this, they are also found in the inner ear, nervous system, and heart with spatial specific functions. There are other cells able to produce melanin but of different embryonic origin (pigmented epithelium of retina, some neurons, and adipocytes). Melanocytes of the epidermis and hair are cells which share some common structural features but in general they form biologically different populations living in unique niches of the skin. Ultra structurally, melanocytes differ from each other on the basis of their locations and function. Principal function of epidermal melanocytes is photoprotection and thermoregulation by packaging melanin pigment into melanosomes and delivering them to neighboring keratinocytes. It is unfair to think that melanocytes reap all the glory for their role in pigmenting the skin and providing it critical protection against UV damage. They probably play a significant role in diverse physiological functions and their particular functions in all target places are much wider than the melanin synthesis only. Alternation in any structure and function of these pigmentary cells affects the process of pigmentation/melanogenesis which leads to pigmentary disorders like hyperpigmentation or hypopigmentation.

Keywords: Melanocytes, ultrastructure, receptors, pigmentation, disorders

1. Introduction

The biology of skin pigmentation plays a critical role in assorted physiological faculties from lower to higher vertebrates, like social interaction, camouflage, mimicry, sexual display as well as distinct racial coloration as seen in human beings. The pigmented biopolymer referred to as melanin is predominant in contributing color to skin, hair, and eyes of mammals. Melanin destined for pigmentation is produced in melanosomes, which are exclusively synthesized within melanocytes and in retinal pigment epithelial (RPE) [1]. Melanocytes are the key components of the pigmentary system because of their ability to produce melanin. These cells are found at many locations throughout the body. Mammalian melanocytes can be classified as “cutaneous” (follicular and epidermal) and “extracutaneous” (e.g., choroidal, cochlear) [2]. Though all of them have derived from pluripotent, NCC and have the capacity to synthesize melanin, their distinct task in all target places are much broader than the melanin synthesis solely.

The existence of melanocytes is not only restricted to the epidermis but they are also found in other locations of the human body such as hair, iris, part of heart, nervous system, inner ear, etc. Here it is important to notice that ability of melanin synthesis is not confined to melanocytes only, but also other cells such as pigmented epithelium of retina, epithelia of iris and ciliary body of the eye, some neurons and adipocytes, which can also generate melanin [3]. Two types of melanocytes have been found: first are the differentiated melanocytes of neural crest origin which are also present at various locations within the body and the other are the RPE cells, originated from the outer layer of the optic cup of brain [4]. The RPE cells perform a critical role in the phagocytosis, that is, turnover and renewal of shed photoreceptor membrane as well as maintenance of normal visual functions [5].

Melanocytes and their production of melanin pigment have important roles in determining the physiology of mammal skin. They synthesize melanin inside a special membrane bound organelle, termed as melanosomes. Melanosomes are transferred via dendrites to surrounding keratinocytes where keratinocytes arrange them to form a critical protective barrier (known as supranuclear “caps”) to shield the DNA from UV radiation. The anatomical relationship between keratinocytes and melanocytes is known as “the epidermal melanin unit” and it has been estimated that each melanocyte is in contact with 36 keratinocytes in the basal and suprabasal layers [6].

The amount and type of melanin produced, that is, eumelanin or pheomelanin, as well as its eventual distribution in the epidermis, dramatically affects visible color, which ultimately determines the various functions of the pigment, such as photoprotection. “Normal” pigmentation is regulated by more than 250 genes and which function during the development, migration, survival, proliferation, and differentiation of melanocytes from their precursors, that is, melanoblasts [7].

The present chapter is proposed to provide morphological and ultra structural details of melanocytes, found in different locations of the body along with their significant functions. Here we will also highlight some miscellaneous functions of melanocytes, other than melanin

production. The present chapter will provide significant knowledge on the basics of mammalian melanocytes from origin to different stages of development along with their specific markers. Signaling pathways of skin melanocytes along with the diseases associated with their disruption have also been elaborated. Concurrently, their etiologies along with the ultrastructural details of pigmentary disorders and the role of receptors have also been discussed.

2. Origin and development of melanocytes

The embryonic development of melanocytes provides an opportunity to better understand the story of skin pigmentation and its related skin diseases. Melanocytes derived from the pluripotent, NCC are also known as the fourth embryonic layer [8]. In addition to melanocytes, they give rise to neurons and glial cells, adrenal medulla, cardiac cells, and craniofacial tissue.

Originating from the border between the dorsal neural tube and overlying ectoderm, NCC appears following closure of the neural tube during neurulation. Induction of the neural crest population requires the action of several transcription factors including; *Msx1*, *Pax3* (paired-box 3), *FoxD3*, *Zic1*, *Snail2*, *AP-2*, and *Sox10* (sex-determining region Y (SRY)-box 10), microphthalmia induced transcription factor (MITF), endothelin 3, and endothelin receptor B (EDNRB) [9,10]. Expression of these factors is in turn regulated by Wnt and Bone Morphogenic Protein (BMP) signalling [11]. These proteins and signaling pathways provide integrated spatial and temporal signals to create the proper environment for development and migration [12].

NCC migrates extensively around the embryo, during which they differentiate into specialized cell types. The fate of the NCC depends on environmental factors they meet on the migratory pathways. At the trunk, from somite eight to twenty eight, NCC emerge after an epithelio-mesenchymal transition (EMT), proliferate extensively and follow two main migration paths; the dorso-lateral and the dorso-ventral pathways. The cells that migrate along the dorso-lateral pathway, between somite and ectoderm, are thought to be the main source for melanocytes while dorso-ventrally migrating cells give rise to the peripheral nervous system and adrenal medulla [13].

Melanoblasts, which are the precursors of melanocytes, migrate, proliferate, differentiate, and spread to their final destinations in the basal layer of epidermis and hair follicles; however, precise distribution of melanocytes varies among various species [14]. Cell type-specific markers are useful tools to demystify the development of certain cell types. *Tyrp-2/Dct* is reported to be a specific marker of melanoblasts development [15]. It has been reviewed by [16] that the markers for the precursors for melanocytes are: a tyrosinase kinase receptor KIT (c-kit) and transcription factors such as MITF, SOX10, Pax3. Melanocytes are usually identified by their expression of melanocyte-specific proteins, for example tyrosinase (TYR), TYRP1, DCT, Pmel17/gp100, MART-1, and/or MITF (Figure 1).

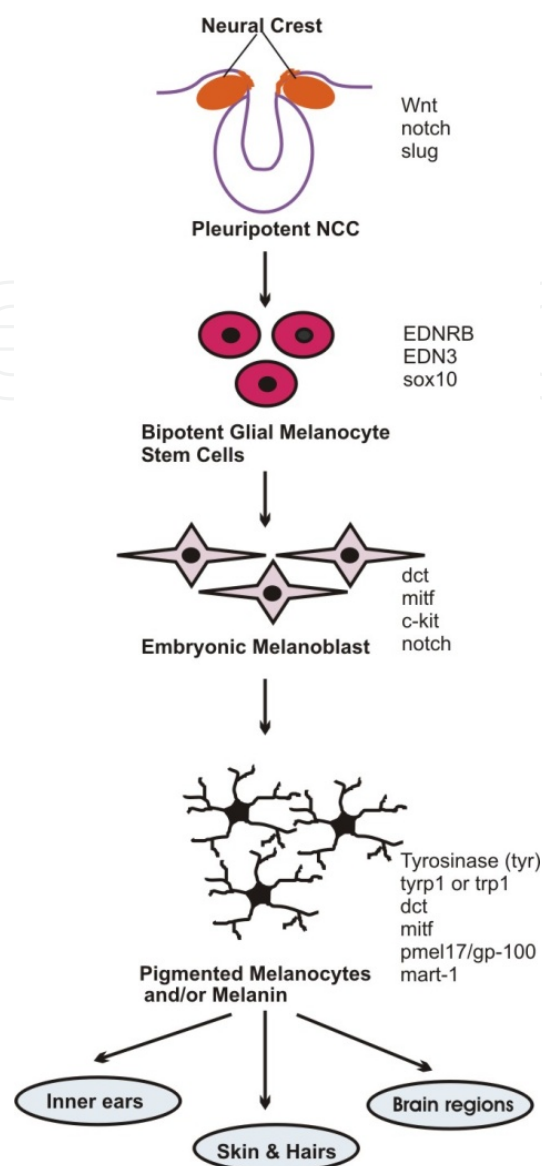


Figure 1. Embryonic development of melanocytes from NCC. Melanocytes originate from the pluripotent NCC which in turn develop from dorsal most point of neural tube. *Wnt*, *slug*, and *notch* are the specified marker genes involved in the development pathway of early NCC. The bipotent stem cells of melanocytes differentiate into specialized cells termed as melanoblast with its specific marker genes. Melanoblasts are the precursor of melanocytes which migrate, proliferate, differentiate, and spread to their final destination in epidermis and hair follicles, stria vascularis of inner ears, the uveal track of eyes, substantia nigra, and locus coeruleus of brain and finally evolve into the mature melanocytes.

3. Morpho-anatomical aspects of mammalian melanocytes

The pigment cells of lower vertebrates/mammals (melanophores/melanocytes) are specialized type of smooth muscle cells, which due to their intracellular movement of melanin granules, control skin color. Several studies have been conducted on the effects of various hormones, factors, and pharmacological agents on vertebrate pigment cells and it has been widely

accepted that they are controlled by either nerves alone or by hormones or by a combination of both [17–20]. Several cytokines, growth factors and other receptors have also been established to support the transformation of migrating melanoblasts to differentiated functional melanocytes. Receptors from a long time have evaded scientific investigations and are present on melanophores/melanocytes. These mysterious protein molecules mediate a host of physiological and pharmacological actions through endogenously as well as exogenously applied drugs. Receptor systems participate in a very coordinated manner in mediation of responses of color change [21]. Cellular receptors of adrenergic, cholinergic, histaminergic, and serotonergic nature have been found to regulate pigmentation via melanin displacement in various animal melanocyte models [22–24].

A number of researches have revealed that there is a close association between cell shape and function. Cell form can be affected by the topography of the surface, where the cells are full-grown, each in cell culture as well as in an animal [25]. Depending on the localization, two types of melanocytes can be identified in the skin. These are (a) epidermal melanocytes occurring in the stratum basal of interfollicular epidermis and (b) follicular melanocytes residing within the hair follicle. Various electron microscopic, histochemical studies have been carried out in order to find out the ultrastructural details of melanocytes present in epidermis, hair follicles, uvea of eyes, etc.

3.1. Morpho-Anatomical Details of Epidermal Melanocytes

a. Morphological Structure of Epidermal Melanocytes

The epidermis is a stratified squamous epithelium consisting mainly of cells with two different origins: keratinocytes and melanocytes, of which keratinocytes form the 90–95% of epidermis. Melanocytes comprise from 5% to 10% of the cells in the basal layer of epidermis. Epidermal melanocytes are thin, elongated cell with branched structures, consisting of a central cell body and long numerous branches, or dendrites through which they interact with the adjacent keratinocytes of the basal epidermal layer [26]. Kemkemera *et al.* [27] have examined the cell shape of normal melanocytes (M-C) and of melanocytes from the skin of one neurofibromatosis type 1 patient (M-NFS) *in vitro*. They have reported that all cell types are bipolar and orient parallel to the grooves on the structured surface part, while all melanocytes remain distributed randomly. It has been reported by Valia [28] that although the size of melanocytes can vary, they are typically 7 μm in length. In human body variable pigmentation is seen due to variation in melanocyte population in different regions of the body. However there is no sexual or racial variation in the density of melanocytes in the skin. Thus the cellular activity is considered as the main contributor to racial differences in skin pigmentation [29].

b. Ultrastructural Details of Epidermal Melanocytes

At the ultrastructural level the melanocyte is a distinctive cell. It was noticed by some workers that the melanocyte is free of the fibrillar material (tonofibrils, desmosomes, and tonofilaments) typical of the keratinocytes, and that intercellular bridges between them and the other cells of the epidermis are also absent. The nucleus of a melanocyte is smaller and more deeply basophilic than that of a basal keratinocyte. Also the presence of dendrites makes it distin-

guished from neighboring keratinocytes [30]. Dendrites of melanocytes are revealed more effectively with silver salts that stain the melanin black; they then are seen to arborize in all directions among neighboring keratinocytes and even extend into the uppermost part of the dermis. Unlike the keratinocyte, mitochondria are abundant in melanocytes. Micro fibrils, as distinct from tonofilaments, are seen in the cytoplasm. Unlike tonofilaments they show no tendency to form bundles and are often seen as parallel arrays of fine filaments. The Golgi apparatus is usually prominent and the endoplasmic reticulum is well developed.

The characteristic organelle of the melanocytes is the melanosome. Melanosomes are produced inside the melanocytes, and they pass through several developmental stages, starting in the middle of the melanocyte, migrating to the outer edge of the cell through the dendrites. In 1971, the following four stages (see Figure 2) in the development of the melanosome were recognized by Fitzpatrick *et al.* [31].

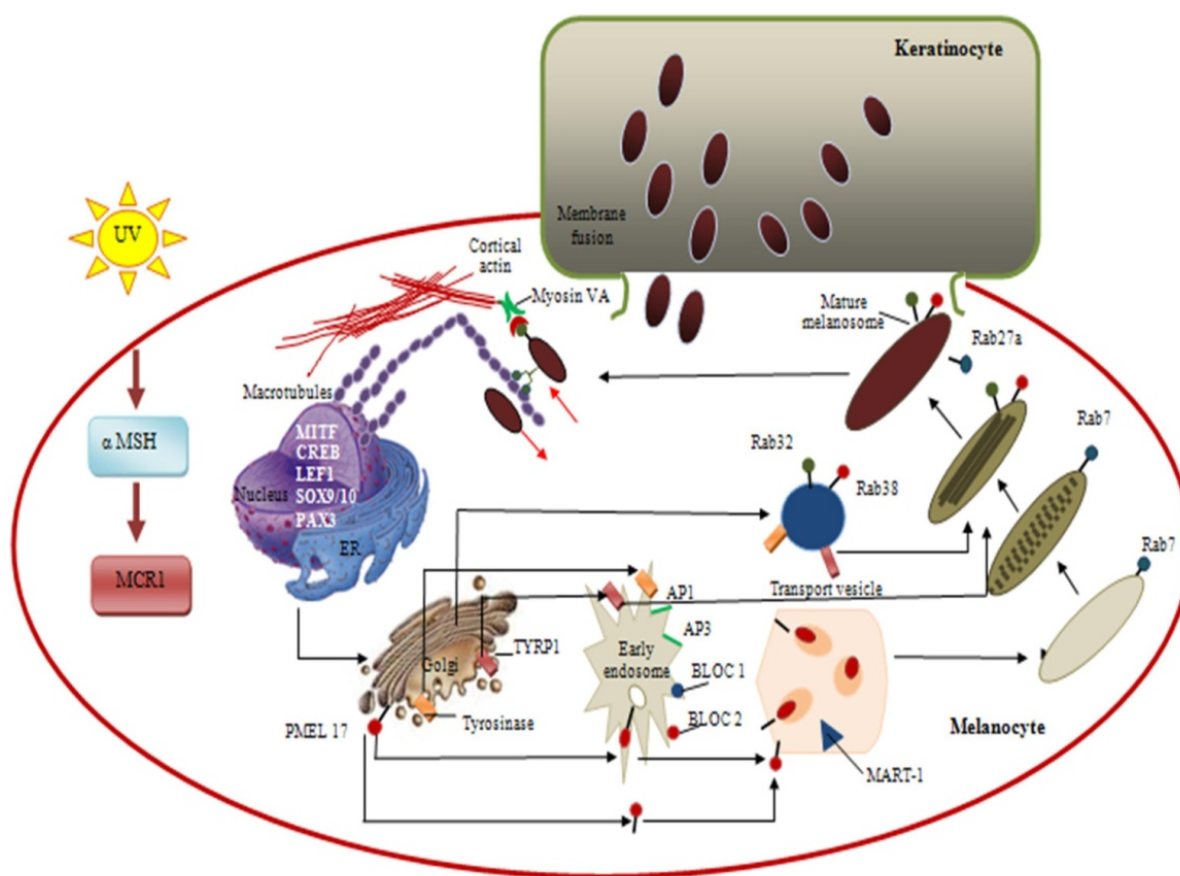


Figure 2. Development and maturation of melanosomes. The synthesis, maturation, and translocation of melanosomes to the keratinocytes are the result of complex regulatory processes involving various sub-cellular organelles, enzymes, proteins, cytoskeleton, intracellular signal transduction pathways, etc. Stage I premelanosomes are ovoid and have poorly defined protein matrix assumed to be originated from the endoplasmic reticulum in which tyrosinase is transferred from Golgi body through vesicular transport. Stage II premelanosomes are tyrosinase positive and have fibrillar matrix but no deposition of melanin takes place in this stage. Stage II premelanosomes matures to Stage III melanosomes in which synthesis of melanin takes place and hence it was seen as partial electron dense structure. Finally, stage IV melanosomes evolved as complete electron dense structure in which the fibrillar matrix become indistinguishable due to complete deposition of melanin.

Stage I. The Stage I melanosomes or premelanosomes likely develop from endoplasmic reticulum (ER). They have an amorphous matrix and display internal vesicles that form as a result of membrane invagination. Premelanosomes already contain the glycoprotein Pmel17 (gp100), but it requires further processing to become a component of the final fibrillar matrix. These filaments have a distinct periodicity of 100 Å.

Stage II. The organelle is oval and shows numerous membranous filaments, with or without cross linking, having a distinct periodicity. Although no active melanin synthesis takes place in this stage, they already contain the enzyme tyrosinase.

Stage III. The internal structure, characteristic of Stage II has become partially obscured by electron-dense melanin due to deposition of melanin in its fibrillar matrix.

Stage IV. The oval organelle is electron-opaque without discernible internal structure in routine preparations.

Weiss and Zelickson [32] reported that melanocytes containing melanosomes of several developmental stages were present in the epidermis of 15-day-old C57BL16 mouse embryo and subsequently increased in number. Stage I melanosomes are seen as spherical vesicles near the Golgi apparatus. The other stages are usually seen scattered singly throughout the cytoplasm though there is a preponderance of Stage III and Stage IV melanosomes in the dendritic processes. If preservation is good, a distinct unit membrane can be seen surrounding the internal structure of the organelles.

Later, Hach [33] divided the melanosomes into two basic groups based on their ultrastructure: (1) elliptical (Ovoid) lamellar or fibrillar melanosomes with a protein matrix arranged into coiled lamella or fibrils or rolled up sheets arranged parallel to the long axis of the organelle; (2) spherical globular melanosomes characterized by a granular appearance possibly due to a sponge-like architecture of their structural proteins with melanin stuffing the empty space. Melanocytes may produce eumelanosomes or pheomelanosomes at different times, switching from one to the other.

Schraermeyer [34] reviewed a comparison between eu- and pheomelanogenesis and further revealed that the earliest form of melanosomes is identical. The vasiculo-globular bodies are involved in melanosomal constituents [35]. In pheomelanogenesis, pheomelanosomes are smaller (~0.7 µm in diameter), ovoid to sub-spherical in shape, and their glycoprotein matrix appears disorganized and loose as lamellae are not formed, but these bodies fuse with each other to form an amorphous matrix on complete differentiation of melanosomes. Mature eumelanosomes in eumelanogenesis are large, (~0.9–0.3 µm), typically elliptical in shape with rounded ends and contain a highly structured fibrillar glycoprotein matrix required for eumelanin synthesis [34]. Melanosomes are numerous in melanocytes of Negroids and Caucasoid individuals, with a dark complexion though they are seen without difficulty in the melanocytes of those with a fair skin. They are ovoid or rod shaped bodies measuring 0.4–1.0 µm in length and 0.1–0.5 µm in diameter.

As lower vertebrates share similar mechanism of skin pigmentation with human beings, they have outstanding potential as phylogenetical tools to demystify and better understand their

role in pigmentation biology and its evolutionary significance. Several detailed elucidations have been done on the fine structure of melanophores of various classes of vertebrates like teleosts and lung fishes [36–38], larval amphibians, Indian toad [39], and reptiles [40], which have revealed remarkably consistent fine structural features of these melanosomes synthesizing cells in order to explain their role in color changes. In the cytoplasm of the epidermal and sub-epidermal melanophores, well developed nucleus, tubular type of vesicular mitochondria, Golgi body, vesicular endoplasmic reticulum with oval to elliptical melanosomes of various degree of melanization have been found to remain randomly scattered [39], resembling similar ultrastructural features of mammalian melanocytes. From these studies it is concluded that the presence of immature, pre-melanosomes to highly electron dense, mature melanosomes showing progressive degrees of melanization from stage I to stage IV melanosomes, in lower vertebrate melanophores is similar to mammalian melanocytes with same mode of development [41,42]. Hence, the ultrastructure of melanophores of these animal models appears to have a treasure of information, which may have physiological links with the human melanosomes from phylogenetic and therapeutic points of view.

c. Intracellular Site of Melanin Synthesis in Epidermal Melanocytes

In 1976, it was reported by Hunter [43], that the information gathered from electron microscopy, electron microscopic cytochemistry, autoradiography, and cell particle fractionation supports the view that tyrosinase is synthesized on the ribosomes. It is then transferred via the rough endoplasmic reticulum (RER) to the Golgi apparatus, from where it is channeled via tubular elements to a focal dilatation of the smooth endoplasmic reticulum in which the coiled melanosomal matrix has independently formed. Melanisation of the structural protein can then take place and once this is completed, the connection with tubular system is severed [44,45].

3.2. Morpho-anatomical details of hair follicular melanocytes

a. Morphological Description of Hair Follicular Melanocytes

Hair bulb matrix is the principal site for the fully developed follicular melanocytes, which differs from epidermal melanocytes by a larger size, larger dendrites containing more developed Golgi and RER and producing two to four fold larger melanosomes [46]. Also, they have a supplement of fewer keratinocytes in contrast to epidermal melanocytes (30–40 keratinocytes) [47]. These melanogenically active melanocytes along with the neighboring immature pre cortical keratinocyte constitute the follicular melanin unit, which usually consists of one melanocyte for every five keratinocytes in the hair bulb region, but in the basal epithelial layer next to the dermal papilla the ratio is 1:1 [48]. Pigmentation of hair is regulated by this follicular melanin unit [10].

Hair structure is divided into three morphological components: the multicellular cuticle sheath, the fibrous cortex, and the medulla. Follicular melanocytes in the fully developed hair follicle (HF) are localized in distinct anatomic compartments based on their differentiation status. Formation of hair begins with the inward folding of epidermis into the dermis. The dermis forms thickening from below and the edge of the inward folding comes to enclose it.

These dermal thickenings mature into the dermal papilla, while the adjacent parts of inward folding forms the hair bulb (Figure 3). The hair follicular melanocytes derived from epidermal melanocytes are highly dendritic cells and colonize the hair matrix, lower half of the hair bulb. Hair bulb melanocytes secrete stage IV melanosomes into keratinocytes consisting of hair bulb and as a result hair cortex and medulla develops [49].

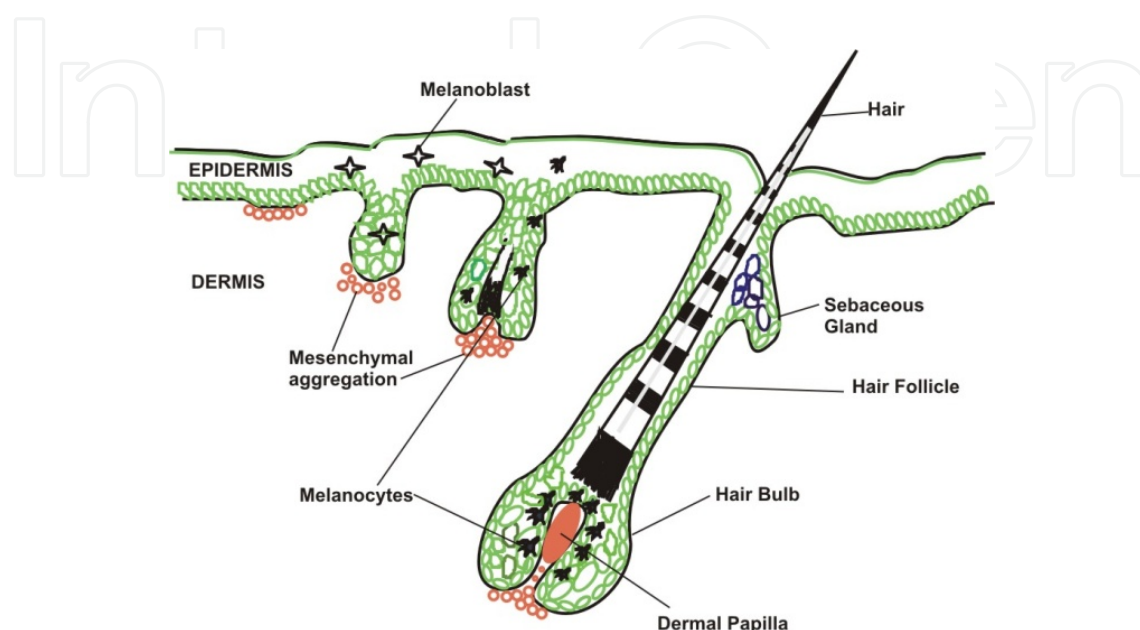


Figure 3. Developmental stages of mammalian hair follicles. Formation of hair begins with the inward folding of epidermis into the dermis. The dermis forms thickening from below and the edge of the inward folding comes to enclose it. These dermal thickenings mature into the dermal papilla, while the adjacent parts of inward folding forms the hair bulb. Hair bulb melanocytes secrete stage IV melanosomes into keratinocytes consisting of hair bulb and as a result hair cortex and medulla develops.

In mice, the process of morphogenesis of hair follicle structures is cyclic [50] and called hair growth cycle [47]. The hair growth cycle consists of three stages: resting (telogen); growth (anagen); and regression (catagen). Anagen phase is divided into six sub stages (anagen I–VI). Melanogenesis is strictly coupled to the growth phase of the hair growth cycle (anagen III–VI). Melanogenesis ceases early in catagen and is completely absent in telogen [51]. During early anagen, melanocyte stem cells residing in the lower permanent portions of the hair follicle are recruited for the regeneration of melanogenically active follicular melanocytes. This melanocyte stem cell progeny on activation migrated out from niche, amplifies and differentiates into pigmented melanocytes. The vacant niches are again repopulated by the melanocyte stem cells and remain quiescent till the next early anagen [52]. Towards the end of anagen the number of identifiable melanocytes decreases and melanocytes lose their dendrites, shrink and become less pigmented, and then they disappear in catagen [47]. However, a small number of dedifferentiated cells (melanoblasts) positive to the combined dopa-premelanin reaction still remain in the hair bulbs.

Melanocytes occurring in hair follicles outer root sheath (ORS) express tyrosinase related protein-2 (TRP-2) and relatively weak tyrosinase related protein-1 (TRP-1). Unlike the bulge

melanocytes, they display proliferative activity during the early and mid-anagen stage of hair cycle. They represent the differentiating melanocytes. Melanocytes, which actively produce melanin in the hair follicle, are located in the hair matrix above the dermal papilla. They express all melanogenic enzymes – tyrosinase (TYR), TRP1, and TRP2 – and proliferate only during mid-anagen [53].

b. Ultrastructural Details of Hair Follicular Melanocytes

The ultra structure of amelanotic melanocytes from human hair follicles is different from that of epidermal melanocytes, and these characteristics determine the functional nature of amelanotic melanocytes. The fine-structure observation of the cultured melanocytes revealed round or elliptical shape, single huge nucleus and the karyotheca were double layered. The clear euchromosomes and meager heterochromosomes were observed within the nucleus. The cytoplasm was furnished with several organelles, such as unit membranous melanosomes of similar size, RER, ribosomes, as well as mitochondria were also present. While the Golgi apparatus in the cells was not seen easily, the electron dense melanin granules were concentrically deposited within the melanosomes [54]. The hair melanosomes are two to four times larger than the epidermal melanosomes. It has been reviewed by Ortonne and Paul [55] that the different stages of hair cycle of hair melanocytes have their own unique ultrastructure features. In hair follicles of C57 black mice, early anagen (growth) stage of hair cycle extensive growth occurred in melanocytes where cytoplasm volume increased, with increase in dendricity, elaborate RER, and Golgi zone along with increase in size and number of melanosomes. However, during catagen and telogen stage of hair cycle some degenerative changes takes place in melanocyte, with only a few small premelanosomes. The volume of cytoplasm decreases with less well developed Golgi complex and RER as well as nuclei with prominent heterochromatin patterns. Hair melanocytes transfer melanosomes to follicular epithelial cells. Medullary cells receive their melanin from melanocytes in the upper part of the hair bulbs similar to the way described for epidermal melanin unit. Melanosomes are also transferred to immature corticle cells. Due to their larger size, melanosomes are usually distributed singly, whatever the ethnic background.

Many studies have been carried out to demystify the ultrastructural aspects of hair melanin pigmentation. Earlier, it was revealed by Jimbow *et al.* [56] that human red hair, specified as pheomelanin, its melanocytes contain spherical melanosomes with vasiculo-globular and proteinaceous matrices on which melanin deposition is spotty and granular. Melanin granules are smaller and less numbered in blonde than in dark-hair human subjects [57]. Melanosomes are not fully melanized even in the dendritic processes of melanocytes. Whereas ultrastructure of follicular melanocytes of black hair is identical to the melanocytes in the epidermis of negroids as they observed to contain typical ellipsoidal melanosomes, at various stages of melanization and large melanosomes are transferred singly to the neighboring keratinocytes [58]. In brown hair, the follicular melanocytes also contain all the developmental stages of melanosomes. Lighter brown hairs have smaller melanosomes [59]. In the melanocytic zone of the senile gray hair bulb, the number of melanocytes appears normal or reduced [60]. These cells show little melanogenic activity and contain very few melanosomes.

3.3. Morpho-anatomical aspects of ocular melanocytes

Ocular melanocytes are found in the uveal tract, which consist of cells of the choroid, iris, ciliary body [61]. The RPE is a monolayer that lies between photoreceptors and choroid. Melanin is produced in RPE and choroid of eyes. Melanocytes and RPE cells have a different embryonic origin and development [62]: While RPE cells emerge from the neural tube, melanocytes are neural crest-derived cells. Consequently some differences exist between melanocyte and RPE melanogenesis [63]. Ocular melanocytes are in contact with only each other, and they do not transfer their melanosomes. The RPE is a monolayer of pigmented cells of neural tube origin in the background of the eye. Together with the endothelial cells of the chorio-capillaris it forms the blood-retinal barrier [64]. RPE cells are cubical and highly polarized. Basal infoldings and apical microvilli serve as enlargement of the surface. The shape of mature RPE melanosomes differs from that of melanocytes in being oval [65].

The typical oval shaped melanosomes of the RPE are located in the microvilli, and round shaped melanosomes in the cytoplasm near the nucleus. In spite of this RPE cells and the epidermal melanocytes have been described to follow the standard pathway of melanogenesis. It was reported that they exploit the similar melanogenic proteins and the fine structural characterization of both the epidermal melanocytes and pre-natal RPE cells confirmed the presence of distinct melanosomes of various stages (I–IV) of development [66]. Schraemeyer [67] reported that the formation of classical premelanosomes in RPE have been induced by illumination. Ocular melanin content differs among species. Stages II–IV melanosomes have been found in the RPE of squirrels [68]. Although melanogenesis in RPE and choroid seems to follow a common pathway, the RPE of adult hamsters and probably all the vertebrates, contains unique melanosomes never present in the melanosomes of choroid. These are large, spherical melanosomes with loosely packed melanofilaments. Whereas the high numbers of melanin granules are spindle shaped in the RPE, they are smaller and more spherical in the choroid. The large type melanosomes often fuse with earlier-stage melanosomes and have been described as late immature melanosomes in the prenatal RPE of humans. In the RPE melanosomes contain melanofilament ordered concentrically as are the membrane in phagosomes [69]. In the RPE of chicken, parallel filaments which appeared to have the same structure as those forming the framework of melanosomes were frequently found in phagosomes [70]. Ultrastructural similarities between phagosomes and melanosomes have also been reported. In the RPE of cattle, phagosomes were found that contain an electron dense melanin-like material that was not autofluorescent and therefore not lipofuscin. Additionally electron dense vasiculo-globular bodies (10–100 nm) were found in phagosomes during disk membrane degradation as well as within melanin granules [71].

4. Functional aspects of melanocytes

Although melanocytes are distinguished for their ability of skin pigmentation, but this is possibly not the single occupation of these pigment bearing cells. In fact, melanocytes have plentiful enzymes which are proficient in biochemical, genetical, and functional association to the immune system as well as antimicrobial protection [72].

4.1. Cutaneous pigmentation

Cutaneous pigmentation is the product of two crucial events: biosynthesis of melanin granules within melanocytes and their subsequent transfer to the neighboring keratinocytes. Though the quantity of melanocytes in all human races is basically invariable, the amount, size, and the way in which melanosomes are spread within keratinocytes may differ [1]. The quantity of melanin granules of human epidermal melanocytes is diverse not only among different skin types but also among different locations of the skin from the same person [73]. This diversity is vastly controlled by gene expression of melanosomal proteins, which regulate the complete activity and expression of melanosomal proteins inside the particular melanocytes [74]. It has been noticed that those melanocytes having low quantity of melanin pigment, produce TYR very slowly but degrade it very rapidly, than melanocytes having higher quantity of melanin pigment and TYR activity [75]. Indeed, darkly pigmented skin possesses several single, large (0.5–0.8 mm in diameter), elliptical, highly electron dense melanosome particles of Stage IV. However, the lighter skin pigmentation is linked with smaller (0.3–0.5 mm in diameter), immature, less dense melanosomes of stages II and III which remain clustered in membrane-bound groups (FIGURE 4) [76]. These varied configurations of melanosome stages or types as well as distribution exist since birth and are not influenced by external factors (such as sun exposure). They are liable for wide range of skin tones [26].



Characteristic features	Darkly pigmented skin	Lightly pigmented skin
Stage of melanosomes	Stage IV	Stage II & III
Size (Diameter)	0.5-0.8 mm	0.3-0.5 mm
Number of melanosomes per cells	>200	< 20
Transport to keratinocytes	Single	Group of 2-20
Rate of degradation	Fast	Slow
		

Figure 4. Variations in human skin pigmentation due to different types of melanosomes within epidermal melanocytes.

4.2. Protection from Ultraviolet Radiations (UVR)

The principal function of melanin is to protect the skin from harmful effects of sunlight, a task accomplished by its capability to scatter and absorb ultraviolet light [77]. So the primary role of melanocytes is to act as natural sun block. Adaptive pigmentation or tanning is the natural

physiologic response of the skin against exposure of UVR. Melanin bearing melanocytes, situated in the basal layer of epidermis have vital tasks in the skin's barrier function by preventing damage by UVR. In the basal layer of the epidermis, melanin pigment creates a protective cover over the nuclei of keratinocytes; in the outer layers, they are more evenly distributed. Melanin absorbs UV radiation, thus protecting the cell's nuclei from DNA (deoxyribonucleic acid) damage [78]. UV radiation induces keratinocyte proliferation, leading to thickening of the epidermis [79]. Hence, it is concluded that the tanning involves both an increase in the amount of melanin pigment and epidermal thickening. Both changes serve to increase melanin accumulation in the epidermis, so that the skin is better protected against subsequent UV exposures [80].

4.3. Determination of eye color

The external origin of eye color is determined by the distribution and quantity of melanocytes in the uveal tract of the eye. The amount of melanocytes does not vary between eye colors [81], but it is the intracellular melanin content, types, and its packaging within the melanosomes that vary, which provides a wide variety of eye colors. There are two forms of melanin pigment particles (skin and hair melanocytes) produced during melanogenesis and both occur in the iris of the humans [82,83]. The quantity and types of melanin in the iridal melanocytes vary with iris color. However, unlike the skin and hair in which melanin is produced continuously and secreted, in the eye the melanosomes containing the pigment are retained and accumulate in the cytoplasm of the melanocytes within the iris stroma. White light entering the iris can absorb or reflect a spectrum of wavelengths giving rise to the three common iris colors: blue, green-hazel, and brown. Even though blue colored eyes have same number of melanocytes but they possess low melanin pigment and few melanosomes; green-hazel color of irides are the outcome of average number of melanin granules as well as melanosome number; and brown colored iridies are the product of huge numbers of melanin granules along with melanosome particles [84].

4.4. Other incomparable abilities of melanocytes

Melanocytes are now beginning to take more and more fascinating roles in other tissues of the body. The existence of melanin and melanocytes are not limited to the skin, hairs, and RPE [85] only, besides, they are reported to be present in the leptomeninges, stria vascularis of the cochlea, in the heart, as well as in the substantia nigra and locus coeruleus of the brain. They have also been verified to function in hostile regions of our body, such as adipose tissues. In stria vascularis of the cochlear melanocytes remains present as intermediate cells. The stria intermediate cells play crucial role in the initiation of endolymph-mediated action potentials that is essential for normal hearing. Melanin granules produced by melanocytes in the inner ear even play important roles in body balance [86].

Extracutaneous melanocytes located in the brain may have several neuroendocrine functions. Pigment granules found in brain are known as neuromelanin, consists of giant, dense eumelanin covered pheomelanin core which may also include aliphatic and peptides [87]. Neuromelanin is predominantly confined to dopaminergic neurons of substantia nigra as well as in

the locus coeruleus, and ultimately gets accumulated in the human substantia nigra with age [88]. Several researches have favored the view that neuromelanins have a defensive role by binding/elimination of reactive oxygen species (ROS) along with metals that would otherwise be extremely toxic to neurons [89]. In a recent study, it has been reported that nearly all brain tissues hold significant quantity of neuromelanin, which is supposed to play crucial tasks in reducing organ toxicity [90].

Interestingly, it has been observed that melanocytes are also situated in the valves and septa of heart [91]. It was further hypothesized that the origin of cardiac melanocytes may take place from the same precursor population as that of skin melanocytes because of its dependency on the same signaling molecules which is needed for the appropriate development of skin melanocytes [92], but their exact function in this location is still unclear. The synthesis of melanin is not always beneficial, either in heart or in other tissues, for example, in the lungs where in an unusual ailment known as Lymph angioleio myomatosis (LAM) [93], the muscle cells slip back into their developmental stages along with the expression of melanocytes like specific markers *Pmel17*, tyrosinase, etc. The resulting production and accumulation of melanin in lung tissues is eventually lethal.

Randhawa *et al.* [94] reported that the biosynthesis of melanin also occurs in the adipose tissue of morbidly obese humans. It was also assumed that the ectopic synthesis of melanin in the cytosol of obese adipocytes possibly provide a balanced mechanism to work as anti-inflammatory factor as well as it decreases the oxidative damage. In the course of enhanced deposition of cellular fat, adipocytes become more exposed to endogenous apoptotic signals especially with ROS, which could be counteracted by ectopically produced melanin. In addition, adipocytic melanin may also suppress the secretion of proinflammatory molecules [3].

5. Etiology of pigment cell disorders

Skin color is a very important social and cultural human characteristic. Even a minor alteration of cutaneous pigmentation can result in a major esthetic concern, with psychological implications. Skin color is primarily due to the pigment melanin, which is produced by melanocytes, and normal pigmentation is dependent on the normal structure and function of these cells. Any defect affecting the complex process of skin pigmentation may result in pigmentary disorder, which may be either (a) hyperpigmentary or (b) depigmentary/hypopigmentary.

5.1. Pathology and ultrastructure of hyperpigmentary disorders

Hyperpigmentary skin disorders may be defined as enhanced pigmentation of the skin above the normal level. Such increase in melanin production may occur in the epidermis, dermis, or both. Epidermal hyperpigmentary disorders exclusively occur due to the increase of melanin pigment and are characterized by “brown hyperpigmentation” because of their brown color. They may be associated with (melanocytic epidermal hyperpigmentation) or without (melanotic epidermal hyperpigmentation) an actual increase in the melanocytes number. On the other hand, in dermal hyper pigmentary diseases, collectively known as “blue hyperpigmen-

tation” or circuloderma, either melanin pigments (melanin dermal hyperpigmentation) or non-melanin pigments (non-melanin dermal hyperpigmentation) are involved [95]. Generally hyperpigmentary disorders can be congenital or acquired [96].

a. Melanotic Melanoma

The incidence of malignant melanoma is continuously increasing worldwide. The detailed fine structure of melanotic melanoma cells studied by Wellings *et al.* [97] was of the pale melanocyte variety. It has been reviewed by Polnikorn [98] that there is increased number of epidermal and follicular melanocytes (approx. 30%) in the melanotic lesions. Melanotic melanocytes were either round, elliptical or at times irregular and possessed numerous cytoplasmic microvilli. The ratio of the nucleus to the cytoplasm was low. The nuclei, which contained light chromatin, were usually ovoid, with a definite indentation on one side, thus giving the cell an appearance of polarity. Some of the nucleoli contained masses of fine granules and had clear round areas within them. The endoplasmic reticulum consisted of slender sac-like forms with lamellae and vesicles, which infrequently were slightly swollen. The endoplasmic reticulum often was found surfaced with ribosomes, but some de-granulated forms of it were also observed. The Golgi apparatus and centrioles occupied an extensive part of the cytoplasm of most cells and usually were located immediately adjacent to the indented part of the nucleus, when such was present. In the immediate vicinity of the Golgi area, numerous vesicles, premelanosomes and immature melanosomes at various stage of development, dense areas of ribosomes and many mitochondria were present; however, melanosomes in various stages of development also were observed in areas of the cytoplasm far from the Golgi apparatus [99].

The intermediate vesicle, which originated in the Golgi apparatus, underwent changes which ultimately led to the fully-developed melanosome. The most striking feature of pigmented melanoma cells of humans was the occurrence of numerous melanosomes that varied considerably in size and shape, particularly the spheroidal melanosomes with a diameter ranging between 200 nm and 500 nm. Some of the melanosomes showed ellipsoidal profiles and melanosomes showing a granular structure were common, whereas lamellar melanosomes were seen less frequently. As the melanosome became completely electron dense due to the deposition of melanin granules, the pigment tended to disturb the arrangement and to leak into the cytoplasm [100]. The cultures of pigment cell lines were observed to have lower growth rate and viability in comparison to the non-pigmented cell lines. Extremely pigmented cells died and discharged their distinct melanin granules into the medium. The “amelanotic” melanoma cells were examined to have minimal synthesis as well as faulty development of premelanosomes. Also, it was noticed that they did not possess the distinct fibrillar structure and had less deposition of melanin as reported in the “melanotic” melanoma cells. It seems that the formation of discrete fibrillar pattern may be the fundamental step for the normal synthesis and deposition of melanin along with the development of melanosomes [101].

5.2. Pathology and ultrastructure of hypopigmentary disorders

Hypopigmentary/depigmentary disorder of the skin is characterized by the reduction/complete loss of skin pigmentation. Usually they may be of two types: (a) melanopenic

(melanocytopenic), which is related to the melanin pigment, and (b) non-melanopenic, which is not related to the melanin pigment. Melanopenic hypopigmentation mainly occurs due to the disruption in the complex process of skin pigmentation. Non-melanopenic hypopigmentary disorders may be associated with anemia, edema, and Raynaud's phenomenon.

a. Vitiligo

Vitiligo is a hypopigmentary disorder of the skin in which cutaneous and ocular melanocytes are selectively destroyed that result in loss of pigmentation. It affects 1–2% of the population including both sexes and all races equally [102]. Multiple theories have been proposed, including genetic, neural, biochemical, viral, and autoimmune mechanisms. However, an autoimmune mechanism has been proposed as the most accepted cause of vitiligo. In previous studies, it has been demonstrated that most important feature in vitiligo is alternation of the melanocyte ratio at the dermal-epidermal junction [103,104]. The long dendritic, melanin granules filled, dopa positive melanocytes were found to be prominent in the outer peripheries of vitiligo lesions [105].

Study conducted by Mohamed and El-Saman [106] on vitiligo patients using light and electron microscopy, showed complete loss of melanin pigment granules in the epidermis, mononuclear cellular infiltration in the dermis, and marked positive ICAM-1 expression over keratinocytes in the epidermis and around endothelial and inflammatory cells in the dermis of the vitiligo sections. The above authors have reported that the biopsies of vitiliginous skin samples exhibited significant ultrastructural changes of degenerative nature in the keratinocytes. This was conspicuous by the presence of electron dense cytoplasm with vacuolization and fragmentation of keratin tonofilaments. Large, irregular indented nuclei were also observed in the biopsies. Besides, the cytoplasm of keratinocytes becomes completely deficient of melanosomes in contrast with the control group. Dilated intercellular spaces (edema) and loss of intercellular junctions with or without remnants were also observed. Complete absence of melanocytes and obvious presence of lymphocytes in the basal layer and dermis were evident. These findings give strong fine structural evidence that the vitiligo leads to the degenerative changes in the structure of melanocytes.

We have recently shown that active ingredients of plants like *psoralea corylifolia*, (psoralen), *nigella sativa* (thymoquinone), *piper nigrum* (piperine), and *withania somnifera* (withaferin), *berberis vulgaris* (berberine) all have powerful melanogenic (skin darkening) properties and are excellent activators of melanosomal receptors, which when properly stimulated can cause skin darkening in some of the animal models studied in our laboratory [107–112]. Whether these have a similar role in mammalian melanocytes and specific cell lines is yet to be determined at the cellular level. Therefore, it could be an interesting possibility to further explore the herbal ingredient-activated melanosomal receptor signaling cross talk within the melanogenetic pathways, where different receptors participate in skin pigmentation and its dysfunctions.

6. Conclusion

The morphoanatomical activities of the melanocytes have evolved to enable them to perform specific functions with great efficiency: the regulated production and distribution of melanin

within the epidermis. It is unfair to think that melanocytes reap all the glory for their role in pigmenting the skin and providing it critical protection against UV damage. They also play a significant role in diverse physiological functions such as phagocytosis, vision, hearing, balancing and several neuroendocrinal functions. Ultrastructural diversity is found in melanocytes, based on their specific locations like type of melanin produced (pheo- or eumelanin), shape, size, and number of melanosomes. These structural differences result in functional differences as well, such as the cutaneous and hair pigmentation. There is increasing evidence that melanocytes are associated with pathophysiological circumstances as well. Diverse effects such as hyperpigmentation and hypopigmentation are associated with malfunctioning of the pigmentary system of unknown etiology. Further study of these organelles may not only furnish insights into the underlying intricate mechanisms of pigmentation, but could also yield therapeutic tools for skin disorders.

Acknowledgements

The authors extend heartfelt appreciation to the Secretary and Principal of Saifia College of Science, Bhopal, India, for encouragement.

Author details

Sharique A. Ali* and Ishrat Naaz

*Address all correspondence to: drshariqueali@yahoo.co.in

Department of Biotechnology, Saifia Science College, Bhopal, India

References

- [1] Kondo T, Hearing VJ. Update on the regulation of mammalian melanocyte function and skin pigmentation. *Expert Rev Dermatol*, 2011;6: 97–108.
- [2] Tsatmali M, Ancans J, Thody AJ. Melanocyte function and its control by melanocortin peptides. *J Histochem Cytochem*, 2002;50: 125–133.
- [3] Randhawa M, Huff T, Valencia JC, *et al.* Evidence for the ectopic synthesis of melanin in human adipose tissue. *FASEB J*, 2008;23: 835–843.
- [4] Bharti K, Nguyen MT, Skuntz S, Bertuzzi S, Arnheiter H. The other pigment cell: specification and development of the pigmented epithelium of the vertebrate eye. *Pigment Cell Res*, 2006;19: 380–394.

- [5] Bok D. The retinal pigment epithelium: a versatile partner in vision. *J Cell Sci Suppl*, 1993;17: 189–195.
- [6] Kippenberger S, Bernd A, Bereiter-Hahn J, Ramirez-Bosca, Kaufman R. The mechanism of melanocytes dendrite formation: the impact of differentiating keratinocytes. *Pigment Cell Res*, 1998;11: 34–37.
- [7] Hearing VJ. Milestones in melanocytes/melanogenesis. *J Invest Dermatol*, 2011;131:E1
- [8] Le Douarin NM, Kalcheim, C. The neural crest, 2nd edn. Cambridge: Cambridge University Press, 1999.
- [9] Steventon B, Carmona-Fontaine C, Mayor R. Genetic network during neural crest induction: from cell specification to cell survival. *Semin Cell Dev Biol*, 2005;16: 647–654.
- [10] Tobin DJ. Aging of the hair follicle pigmentation system. *Intern J Trich* 2009;1: 83–93
- [11] Abu-Elmagd M, Garcia-Morales C, Wheeler GN. (2006). Frizzled 7 mediates canonical Wnt signaling in neural crest induction. *Dev Biol*, 2006;298: 285–298.
- [12] Thomas AJ, Erickson CA. The making of a melanocyte: the specification of melanoblasts from the neural crest. *Pigment Cell Melanoma Res* 2008;21: 598–610.
- [13] Le Douarin NM, Creuzet S, Couly G, Dupin E. Neural crest cell plasticity and its limits. *Development*, 2004;131: 4637–4650.
- [14] Cramer SF, Fesyuk A. On the development of neurocutaneous units-implications for the histogenesis of congenital, acquired, and dysplastic nevi. *Am J Dermatopathol*, 2012;34: 60–81.
- [15] Steel KP, Davidson DR, Jackson IJ. TRP-2/DT, a new early melanoblast marker, shows that steel growth factor (c-kit ligand) is a survival factor. *Development*, 1992;115: 1111–1119.
- [16] Betters E, Liu Y, Kjaeldgaard A, Sundström E, García-Castro MI. Analysis of early human neural crest development. *Dev Biol*, 2010;344: 578–592.
- [17] Bagnara JT, Hadley ME. Chromatophores and colour change. Engle-wood Cliffs: Prentice Hall; 1973. p202.
- [18] Aspengren S, Hedberg D, Skold HN, Wallin M. New insights into melanosomes transport in vertebrate pigment cell. *Int Rev Cell Mol Biol*, 2009;272: 245–302.
- [19] Salim S, Ali SA. Vertebrate melanophores as potential model for drug discovery and development. *Cell Mol Biol Lett*, 2011;16: 162–200.
- [20] Salim SA, Ali SA. Melanophores: smooth muscle cells in disguise. In: Current basic and pathological approaches to the function of muscle cells and tissues – From molecules to humans. Harou Sugi, Ed, In tech; 2012. p133–158.

- [21] Aspengren S, Hedberg D, Wallin M. Melanophores: a modelsystem for neuronal transport and exocytosis? *J Neurosci Res*, 2006;85: 2591–2600.
- [22] Ali AS, Peter J, Ali SA. Role of cholinergic receptors in melanophore responses of amphibians. *Acta Biol Hung*, 1995;46: 61–73.
- [23] Ali SA, Peter J, Ali SA. Histamine receptors in the skin melanophores of Indian Bull frog, *Rana tigerina*. *Comp Biochem Physiol A*, 1998;121: 229–234.
- [24] Ali SA, Salim S, Sahni T, Peter J, Ali AS. 5-HT receptors as novel targets for optimizing skin pigmentary responses in Indian bullfrog *Hoplobatrachus tigerinus*. *Br J Pharmacol*, 2012;165: 1515–1525.
- [25] Chen CS, Mrksich M, Huang S, Whitesides GM, Ingber DE. Geometric control of cell life and death. *Science*, 1997; 276: 14–25.
- [26] Costin GE, Hearing VJ. Human skin pigmentation: melanocytes modulate skin color in response to stress. *The FASEB J*, 2007;24: 976–994.
- [27] Kemkemera R, Cseteb M, Schrankc S, Kaufmannc D, Spatza J. (2003). The determination of the morphology of melanocytes by laser-generated periodic surface structures. *Mater Sci and Eng*, 2003;C 23: 437–440.
- [28] Valia RG. Editor-in-chief, Textbook and Atlas of Dermatology, Vol. 1, Bhalani Publishing house, Bombay, India, 1994; p8–12.
- [29] Fitzpatrick TB, Szabo G. The melanocyte: cytology and cytochemistry. *J Invest Dermatol*, 1959;32: 197–209.
- [30] Hunter JAA. (1976). Causes of skin colouration, origin, development and structure of pigment cells. *J Soc Cosmet Chem*, 1976;2: 621–627.
- [31] Fitzpatrick TB, Quevedo WC. Jr., Szabo G, Seiji M. Biology of the melanin pigmentary system. In: *Dermatology in General Medicine*. Fitzpatrick TB, Arndt KA, Clark WH, Eison AZ, 'Van Scott EJ, Vaughan JH, Eds, New York: McGraw Hill, 1971. p117.
- [32] Weiss LM, Zelickson AS. Embryology of epidermis: ultrastructural aspects. III. Maturation and primary appearance of dendritic cells in the mouse with mammalian comparison. *Acta Dermatovener*, 1975;55: 431–442.
- [33] Hach P, Barovansky J, Vedrolowa E. Melanosome- A sophisticated organelle. *Sborn Lek*, 1993;94: 113–123.
- [34] Schraermeyer U. The intracellular origin of the melanosomes in the pigment cells. A review of ultrastructural data. *Histol Histopathol*, 1996;11: 445–462.
- [35] Ito M, Hashimoto K, Organisciak DT. Ultrastructural, histochemical studies of the melanin metabolism in pallid mouse eye. *Curr Eye Res*, 1982;2:13–28.
- [36] Fujii R, Novales RR. Cellular aspects of the control of physiological color changes in fishes. *Am Zool*, 1969;9: 453–463.

- [37] Imaki H, Chavin W. Ultrastructure of the integumental melanophores of the Australian lungfish, *Neoceratodus forsteri*. *Cell Tissue Res*, 1975a;158:365–373.
- [38] Imaki H, Chavin W. Ultrastructure of the integumental melanophores of the South American lungfish (*Lepidosiren paradoxa*) and the African lungfish (*Protopterus* sp.). *Cell Tissue Res*, 1975b;158: 375–389.
- [39] Ali SA, Naaz I. Comparative light and electron microscopic studies of dorsal skin melanophores of Indian toad, *Bufo melanostictus*. *J Microsc Ultrastruct*, 2014;2: 230–235.
- [40] Roth SI, Jones WA. The ultrastructure and enzymatic activity of the boia constrictor (*Constrictor constrictor*) skin during the resting phase. *J Ultrastruct Res*, 1967;18: 304–323.
- [41] Seiji M, Shimao K, Birbeck MSC, Fitzpatrick TB. Subcellular localization of melanin biosynthesis. *Ann N Y Acad Sci*, 1963;100: 497–533.
- [42] Jimbow K, Kutika A. Fine structure of pigment granules in the human hair bulb: ultrastructure of pigment granules. In: *Biology of normal and abnormal melanocytes*. Kawamura T, Fitzpatrick TB, Seiji M, Ed. Baltimore: University Park Press; 1971: 171–193.
- [43] Hunter JAA. Causes of skin colouration, origin, development and structure of pigment cells. *J Soc Cosmet Chem*, 1976;2(8): 621–627.
- [44] Seiji M, Fitzpatrick TB, Birbeck MSC. The Melanosome: a distinctive subcellular particle of mammalian melanocytes and the site of melanogenesis. *J Invest Dermatol*, 1961;36: 236–243.
- [45] Hunter JAA, Mottaz JH, Zelickson AS. Melanogenesis: ultrastructural histochemical observations on ultraviolet irradiated human melanocytes. *J Invest Dermatol*, 1970; 54: 213–221.
- [46] Bell M. Ultrastructure of differentiating hair follicles. In: *Advances in Biology of Skin*. Montagna W, Dobson RL, Eds. New York: Pergamon, 1967; 61–81.
- [47] Chase HB. Growth of the hair. *Physiol Rev*, 1954;34: 113–126.
- [48] Tobin DJ, Paus R. Graying: gerontobiology of the hair follicle pigmentary unit. *Exp Gerontol*, 2001;36: 29–54.
- [49] Araújo R, Fernandes M, Cavaco-Paulo A, Gomes A. Biology of human hair: know your hair to control it. *Adv Biochem Engin/Biotechnol*, 2010. (DOI: 10.1007/10_2010_88)
- [50] Dry FW. The coat of the mouse (*Mus musculus*). *J Genet*, 1926;16: 287–340.
- [51] Slominski A, Wortsman J, Plonka PM, Schallreuter KU, Paus R, Tobin DJ. Hair Follicle Pigmentation. *J Invest Dermatol*, 2005;124: 13–21.

- [52] Nishimura EK, Jordan SA, Oshima H, Yoshida H, Osawa M, Moriyama M, Jackson U, Barrandon Y, Miyachi Y, Nishikawa S. Dominant role of the niche in melanocyte stem-cell fate determination. *Nature*, 2002;416: 854–860.
- [53] Botchkareva NV, Khlgatian M, Longley BJ, Botchkarev VA, Gilchrist BA. SCF/c-kit signaling is required for cyclic regeneration of the hair pigmentation unit. *FASEB J*, 2001;15: 645–658.
- [54] Zhang R, Zhu W, Xia M, Wang D, Ma H. Ultrastructure of amelanotic melanocytes from human hair follicles. *J of Nanj Med Univ*, 2007;21: 42–46.
- [55] Ortonne Jean-Paul, Prota G. Hair melanin and hair color: ultrastructural and biochemical aspects. *J Invest Dermatol*, 1993;101: 82S–89S.
- [56] Jimbow K, Ishida O, Ito S, Hori Y, Witkop CJ, King RA. Combined chemical and electron microscopic studies of pheomelanosomes in human red hair. *J Invest Dermatol*, 1983;81: 506–511.
- [57] Cesarini JP. Human melanin and hair color. In: *Hair and hair diseases*. Orfanos CE, Ed. *Hair and hair diseases*. New York: Springer-Verlag, 1990; p165–197.
- [58] Jimbow A, Kutika A. Fine structure of pigment granules in human hair bulb: Ultrastructure of pigment granules. In: *Biology of normal and abnormal melanocytes*. Kawamura T, Fitzpatrick TB, Seiji M, Eds. Tokyo: University Park, 1971; p191–208.
- [59] Birbeck MCS, Bernicott NA. Electron microscopic studies on pigment formation in human hair follicles. In: *Pigment Cell Biology*. Gordon M, Ed. New York: Academic Press, 1959; p549–561.
- [60] Herzberg J, Guzek W. Das Ergrauen des kopfhaares. *Arch Klin Exp Dermatol*, 1970;236: 268–284.
- [61] Marks MS, Seabra MC. The melanosome: membrane dynamics in black and white. *Nat Rev Mol Cell Biol*, 2001;2: 738–748.
- [62] Smith-Thomas L, Richardson P, Thody AJ, Graham A, Palmer I, Flemming L, Parsons MA, Rennie IG, MacNeil S. Human ocular melanocytes and retinal pigment epithelial cells differ in their melanogenic properties in vivo and in vitro. *Curr Eye Res*, 1996;15: 1079–1091.
- [63] Bharti K, Liu W, Csermely T, Bertuzzi S, Arnheiter H. Alternative promoter use in eye development: the complex role and regulation of the transcription factor MITF. *Development*, 2008;135: 1169–1178.
- [64] Konari K, Sawada N, Zhong Y, Isomura H, Nakagawa T, Mori M. Development of the blood-retinal barrier in vitro: formation of tight junctions as revealed by occludin and ZO-1 correlates with the barrier function of chick retinal pigment epithelial cells. *Exp Eye Res*, 1995;61: 99–108.

- [65] Schraermeyer U, Heimann K. Current understanding on the role of retinal pigment epithelium and its pigmentation. *Pigment Cell Res*, 1999;12: 219–236.
- [66] Lopes VS, Wasmeier C, Seabra MC, Futter CE. Melanosome maturation defect in Rab38-deficient retinal pigment epithelium results in instability of immature melanosomes during transient melanogenesis. *Mol Biol Cell*, 2007;18: 3914–3927.
- [67] Schraemeyer U. The intracellular origin of the melanosomes in the pigment cells: a review of ultrastructural data. *Histol Histopathol*, 1996;11: 445–462.
- [68] Tabor S., Fisher K, Don Anderson H. Evidence for melanin turnover in mammalian retinal pigment epithelium. *Invest Ophthalmol Visual Sci*, 1980;0 (Supple): 163.
- [69] Schraermeyer U. Does melanin turnover occur in the eyes of adult vertebrates? *Pigment Cell Res*, 1993;6: 193–204.
- [70] Young RW. The daily rhythm of shedding and degeneration of rod and cone outer segment membranes in the chick retina. *Invest Ophthalmol Visual Sci*, 1978;17: 105–116.
- [71] Hong L, Simon JD, Sarna T. Melanin structure and the potential functions of uveal melanosomes. *Pigment Cell Res*, 2006;19: 465–466.
- [72] Mackintosh JA. The antimicrobial properties of melanocytes, melanosomes, and melanin and the evolution of black skin. *J Theor Biol*, 2001;211: 101–113.
- [73] Cichorek M, Wachulska M, Stasiewicz A, Tymińska A. Skin melanocytes: biology and development. *Postep Derm Alergol* 2013;30: 30–41.
- [74] Sturm RA, Box NF, Ramsay M. Human pigmentation genetics: the difference is only skin deep. *Bioessays*, 1998;20: 712–721.
- [75] Halaban R, Pomerantz SH, Marshall S, Lambert DT, Lerner AB. Regulation of tyrosinase in human melanocytes grown in culture. *J Biol Chem*, 1983;97: 480–488.
- [76] Toda K, Pathak MA, Parris JA, Fitzpatrick TB, Quevedo WC Jr. Alterations of racial differences in melanosome distribution in human epidermis after exposure to ultraviolet light. *Nat New Biol*, 1972;236: 143–145.
- [77] Svobodova A, Walterova V, Vostalova J. Ultraviolet light induced alteration to the skin. *Biomed Pap Med Fac Univ Palacky Olomouc Czech Repu*, 2006;150: 25–38.
- [78] Abdel-Malek ZA, Swope VB. Epidermal melanocytes: regulation of their survival, proliferation, and function in human skin. In: *Melanoma Development: Molecular Biology, Genetics, and Clinical Applications*. Bosserhoff A, Ed. Springer-Verlag/Wien; 2011; p7–33.
- [79] Gawkrödger DJ. *Dermatology, an illustrated colour text*. 3rd ed. Edinburgh: ChurchillLivingstone, 2002.

- [80] Ravnbak MH. Objective determination of Fitzpatrick skin type. *Dan Med Bull*, 2010;57: B4153.
- [81] Imesch PD et al. The color of the human eye: a review of morphologic correlates and of some conditions that affect iridial pigmentation. *Surv Ophthalmol*, 1997;41: S117–S123.
- [82] Wielgus AR, Sarna T. Melanin in human irides of different color and age of donors. *Pigment Cell Res*, 2005;18: 454–464.
- [83] Prota G, Hu DN, Vincensi MR, McCormick SA, Napolitano A. Characterization of melanins in human irides and cultured uveal melanocytes from eyes of different colors. *Exp Eye Res*, 1998;67: 293–299.
- [84] Wakamatsu K, Hu DN, McCormick SA, Ito S. Characterization of melanin in human iridal and choroidal melanocytes from eyes with various colored irides. *Pigment Cell Res*, 2008;21, 97–105.
- [85] Rozanowski B, Cuenco J, Davies S, Shamsi FA, Zadlo A, Dayhaw-Barker P, Rozanowska M, Sarna T, Boulton ME. The phototoxicity of aged human retinal melanosomes. *Photochem Photobiol*, 2008;84: 650–657.
- [86] Takeda K, Takahashi NH, Shibahara S. Neuroendocrine functions of melanocytes: beyond the skindeep melanin maker. *Tohoku J Exp Med*, 2007;211: 201–221.
- [87] Bush WD, Garguilo J, Zucca FA, Albertini A, Zecca L, Edwards GS, Nemanich RJ, Simon JD. The surface oxidation potential of human neuromelanin reveals a spherical architecture with a pheomelanin core and a eumelanin surface. *Proc Natl Acad Sci USA*, 2006;103: 14785–14789.
- [88] Zecca L, Tampellini D, Gatti A, Crippa R, Eisner M, Sulzer D, Ito S, Fariello R, Gallorini M. The neuromelanin of human substantia nigra and its interaction with metals. *J Neural Transm*, 2002;109: 663–672.
- [89] Sulzer D, Bogulaysky J, Larsen KE, Behr G, Karatekin E, Kleinman MH, Turro N, Krantz D, Edwards RH, Greene LA, Zecca L. Neuromelanin biosynthesis is driven by excess cytosolic catecholamines not accumulated by synaptic vesicles. *Proc Natl Acad Sci USA*, 2000;97: 11869–11874.
- [90] Zecca L, Bellei C, Costi P, Albertini A, Monzani E, Casella L, Gallorini M, Bergamaschi L, Moscatelli A, Turro NJ, Eisner M, Crippa PR, Ito S, Wakamatsu K, Bush WD, Ward WC, Simon JD, Zucca FA. New melanic pigments in the human brain that accumulate in aging and block environmental toxic metals. *Proc Natl Acad Sci USA*, 2008;105: 17567–17572.
- [91] Yajima I, Larue L. The location of heart melanocytes is specified and the level of pigmentation in the heart may correlate with coat color. *Pigment Cell Melanoma Res*, 2008;21: 471–476.

- [92] Brito FC, Kos L. Timeline and distribution of melanocyte precursors in the mouse heart. *Pigment Cell Melanoma Res*, 2008;21: 464–470.
- [93] Ferrans VJ, Yu ZX, Nelson WK, Valencia JC, Tatsuguchi A, Avila NA, Riemenschn W, Matsui K, Tavis WD, Moss J. Lymphangioliomyomatosis (LAM): a review of clinical and morphological features. *J Nippon Med Sch*, 2000;67: 311–329.
- [94] Randhawa M, Huff T, Valencia JC, Younossi Z, Chandhoke V, Hearing VJ, Baranova A. evidence for the ectopic synthesis of melanin in human adipose tissue. *FASEB J*, 2009;23: 835–843.
- [95] Valia RG. Editor-in-chief, Textbook and Atlas of Dermatology, Vol. 1, Bhalani Publishing house, Bombay, India, 1994; p8–12.
- [96] Berger TG. Skin, hair, and nails. In: *Current Medical Diagnosis & Treatment*. Tierney LM Jr, McPhee SJ, Papadakis MA, Eds. New York: Lange Medical Books/McGraw-Hill, 2003; p138–140.
- [97] Wellings SR, Siegel BV. Role of Golgi apparatus in the formation of melanin granules in human malignant melanoma. *J Ultrastr Res*, 1959;3: 147–154.
- [98] Polnikorn N. New approach for laser treatment of melasma and hyperpigmented lesions. *Pigmentary Disorders*, 2014;1: 1–4.
- [99] Maul GG, Brumbaugh JA. On the possible function of coated vesicles in melanogenesis of the regenerating fowl feather. *J Cell Biol*, 1971;48: 41–48.
- [100] Riehl R, Scharf M, Kollinger G. Comparative studies on the ultrastructure of malignant melanoma in fish and human by freeze-etching and transmission electron microscopy. *J Cancer Res Clin Oncol*, 1984;107: 21–31.
- [101] Foa C, Aubert C. Ultrastructural comparison between cultured and tumor cells of human malignant melanoma. *Cancer Res*, 1977;37: 3957–3963.
- [102] Moreira CG, Horinouchia CDS, Souza-Filho CS, Campos FR, Barisonb A, Cabrinia DA, Otuki MF. Hyperpigmentant activity of leaves and flowers extracts of *Pyrostegia venusta* on murine B16F10 melanoma. *J Ethnopharmacol*, 2012;141:1005–1011.
- [103] Moellmann G, Klein-Angerer S, Scollay DA. Extracellular granular material and degeneration of keratinocytes in the normally pigmented epidermis of patients with vitiligo. *J Invest Dermatol*, 1982; 79: 321–330.
- [104] Galadari E, Mehregan AH, Hashimoto K. Ultrastructural study of vitiligo. *Int J Dermatol*, 1993; 32: 269–271.
- [105] Yaghoobi R, Omidian M, Bagherani N. Vitiligo: A review of the published work. *J Dermatol*, 2011;38: 419–431.

- [106] Mohamed AAK, El-Saman SFM. (2011). Light and electron microscopic studies of the effect of combined topical calcipotriol and PUVA therapy on patients with vitiligo. *The Egypt J Histolo*, 2011;34:15–27.
- [107] Ali SA, Sultan T, Galgut JM, Sharma R, Meitei KV, Ali AS. 2011. *In vitro* responses of fish melanophores to lyophilized extracts of *Psoralea corylifolia* seeds and pure psoralen. *Pharm Biol*, 2011;49: 422–427.
- [108] Sultan T, Ali SA. *Psoralea corylifolia* extracts stimulate cholinergic like psoralen receptors of tadpole tail melanophores leading to skin darkening. *J Recept Signal Transduct*, 2011; 31: 39–44.
- [109] Sajid M, Ali SA. Mediation of cholino-piperine like receptors by extracts of *Piper nigrum* induces melanin dispersion in *Rana tigerina* tadpole melanophores. *J Recept Signal Transduct*, 2011;31: 286–290.
- [110] Ali SA, Meitei KV. *Nigella sativa* seed extract and its bioactive compound thymoquinone the new melanogens causing hyperpigmentation in the wall lizard melanophores. *J Pharm Pharmacol*, 2011;63: 741–746.
- [111] Ali SA, Meitei KV. *Withania somnifera* root extracts induce skin darkening in the wall lizard melanophores via stimulation of cholinergic receptors. *Nat Prod Res*, 2012;26: 1645–1648.
- [112] Ali SA, Naaz I, Choudhary RK. Berberine induced pigment dispersion in *Bufo melanostictus* melanophores by stimulation of beta-2 adrenergic receptors. *J Recept Signal Transduct*, 2014;34: 15–20.

