

# We are IntechOpen, the world's leading publisher of Open Access books Built by scientists, for scientists

6,900

Open access books available

186,000

International authors and editors

200M

Downloads

Our authors are among the

154

Countries delivered to

TOP 1%

most cited scientists

12.2%

Contributors from top 500 universities



WEB OF SCIENCE™

Selection of our books indexed in the Book Citation Index  
in Web of Science™ Core Collection (BKCI)

Interested in publishing with us?  
Contact [book.department@intechopen.com](mailto:book.department@intechopen.com)

Numbers displayed above are based on latest data collected.  
For more information visit [www.intechopen.com](http://www.intechopen.com)



---

# Contemporary Rhinoplasty Techniques

---

Payam Varedi and Behnam Bohluli

Additional information is available at the end of the chapter

<http://dx.doi.org/10.5772/59811>

---

## 1. Introduction

Rhinoplasty has evolved during the past two decades. The popular trend to have a smaller nose is gradually changing to having a normal looking nose. Nowadays, functional considerations are an integral part of any treatment plan. A major effort is usually made to detect any deficits in the nasal airway before aesthetic surgery to be solved or improved by a proper treatment plan. Grafting and suturing techniques have replaced some older destructive techniques. This chapter gives an overview of current concepts in rhinoplasty; we also present logical approaches in case selection and evaluation.

## 2. Preoperative evaluations

Like any other aesthetic procedure, a comprehensive preoperative evaluation, may directly affect the final outcome of the operation. The first step is usually started by a thorough psychological assessment, and then functional assessment of the nose is performed. Structural and aesthetic evaluations are usually the last stages followed by the treatment plan and finally operation [1].

### 2.1. Psychological evaluation

Psychological assessment of the rhinoplasty candidates is the first step to build up a proper treatment plan. Unrealistic demands and personality disorders are best detected at this stage. An open discussion with the patient may clarify many potential problems. Any previous psychological medications or therapies should be clarified. Patient may be asked to bring up their ideal nose models; computerized simulation is another modality that may help the surgeon communicate with the patient and seek their real demands and expectations. It is clear

that an ideal surgery with perfect results in an unsatisfied patient is a big failure and is best prevented in this preoperative phase [2-3].

## 2.2. Functional evaluation

The human nose bears a complex physiologic and functional role in breathing and smelling. For this reason it is logically expected that this delicate organ be preserved and even improved during aesthetic surgery. This evaluation usually starts with verbal interview with the patient. Any breathing problems may be easily detected. Exacerbating factors or problems are usually best described by the patient, and then the evaluation continues with direct inspection of the nose. Any deviation or deformity should be observed and documented. To assess the septum and turbinates sufficient light and a nasal speculum are necessary. A few drops of a vasoconstrictor such as phenylephrine in each nostril may be applied for better visualization [4-7]. The final step is to check the valve. The Cottle test is a known method to assess the internal nasal valve. The patient is asked to take a deep breath through the nose, and then inhalation is repeated while the patient is retracting his/her nasal side wall. If a considerable improvement occurs (positive Cottle test), this means a serious weakness exists in the internal nasal valve (Figure1). [8]. It is clear that a reinforcement or total reconstruction of the internal valve should be considered in treatment planning. This test should be done on both sides and documented properly.



**Figure 1.** Cottle test.

To assess the external valves the patient is asked to tilt the head backward and take a deep. The nose is closely observed by the surgeon. This test may be documented by simple standard photography. Excessive medial movements of the nostrils and/or collapse means that some kind of reinforcement technique needs to be considered in the rhinoplasty procedure [9-10].

### 3. Additional diagnostic techniques

**Water's view** radiograph is commonly used to evaluate the maxillary sinuses and nasal septum. In case a complex deformity or deviation is found, CT scan may help the surgeon better analyze the problem.

**Lateral nasal view** may help the surgeon measure the length and height of the bony vault though measurement, palpation and tactile sensation may easily provide the same data for the surgery.

CT scans are commonly used to assess internal compartments of the nose. Septal deformities and spicules are easily detected and documented. Nasal turbinates and paranasal sinuses are also clearly observed on CT scans. Nasal valve diameters are sometimes measured and documented as well.

### 4. Structural assessment

Structurally the nose is formed from cartilage, bone, muscle, connective tissue and skin. It is clear that the quantity and quality of these components play a determining role in the outcome of aesthetic nasal surgery. For structural evaluation, the nose is gently palpated by the surgeon. The quality and thickness of the overlying skin is size and length of the bony vault is grossly measured and then subtle finger pressure is applied over the tip to determine the strength and support of the cartilage framework. Then, the patient is asked to smile. Excessive drooping of the nose or unpleasant widening may be an indicator of muscular hyperactivity or structural weakness that both may be easily corrected with a thorough treatment plan.

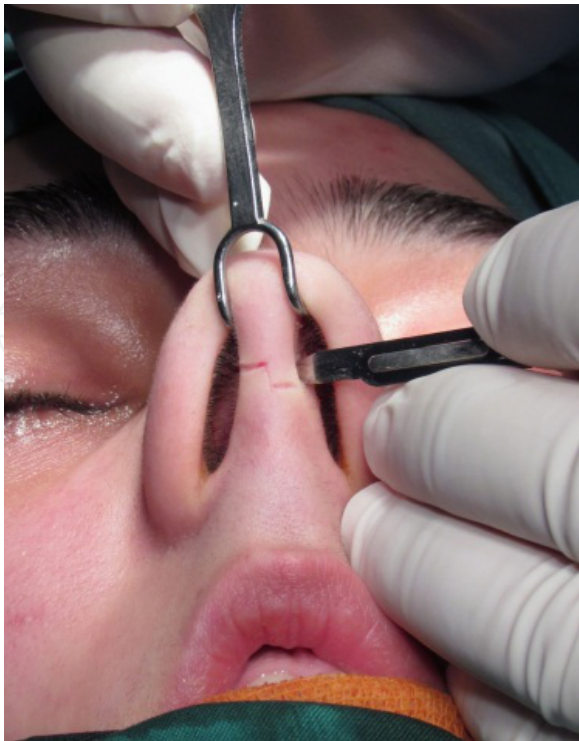### 5. Basic techniques in rhinoplasty

#### 5.1. Incisions

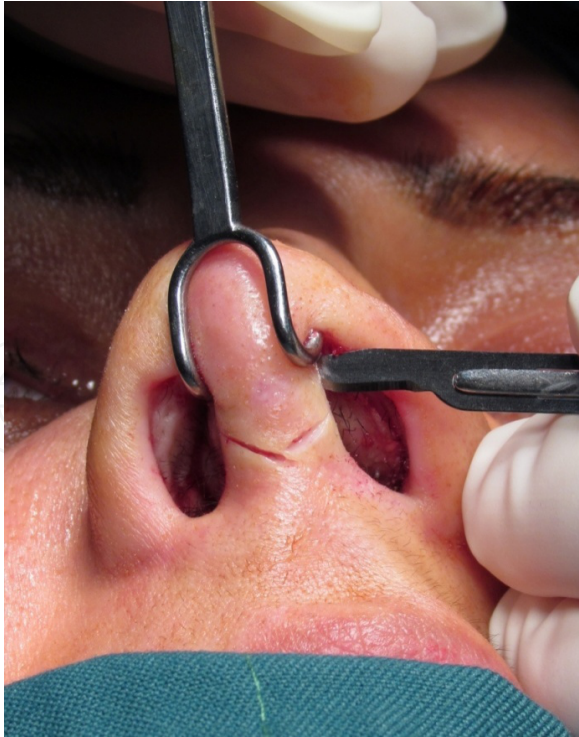Open approach rhinoplasty needs two basic incisions namely, skin incision and rim incisions. These two incisions are connected to each other and skeletonization is started.

#### 5.2. Skin incisions

The skin incision is placed in the mid-columellar skin. An inverted-V (Figure 2) or stair-step (Figure 3) design will provide a longer incision line and logically better healing and less visible scar. On the other hand, the geometric incision may help the surgeon return the flap to its exact position thus, distortion or deformities are prevented.



**Figure 2.** Inverted-V incision

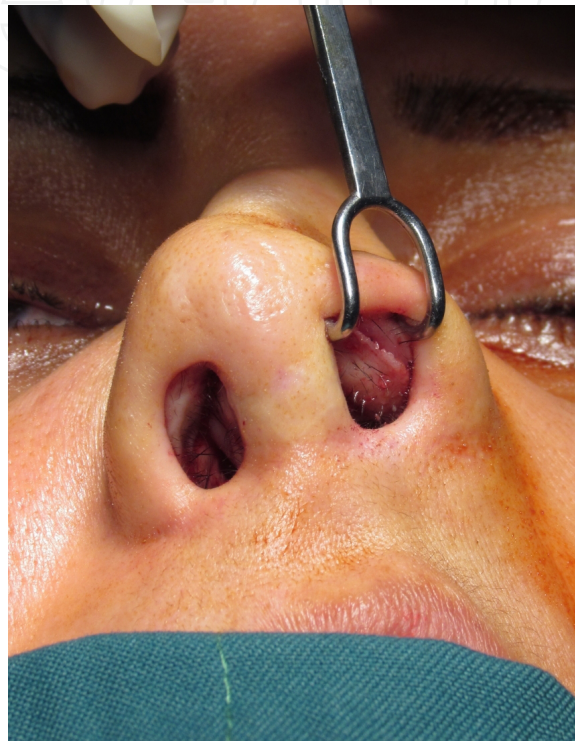

**Figure 3.** Stair-step incision



### 5.3. Rim incision

The rim incision is an intranasal incision along the caudal edge of the lower lateral cartilages (Figure 4). Care should be taken to remain close to the cartilage edge. In this way a proper incision will follow the normal anatomy of the lower lateral cartilages. For this reason, the incision line will be close to the nostril margins in the dome area and will move caudally as it is continued along the border of the lateral crural cartilage.



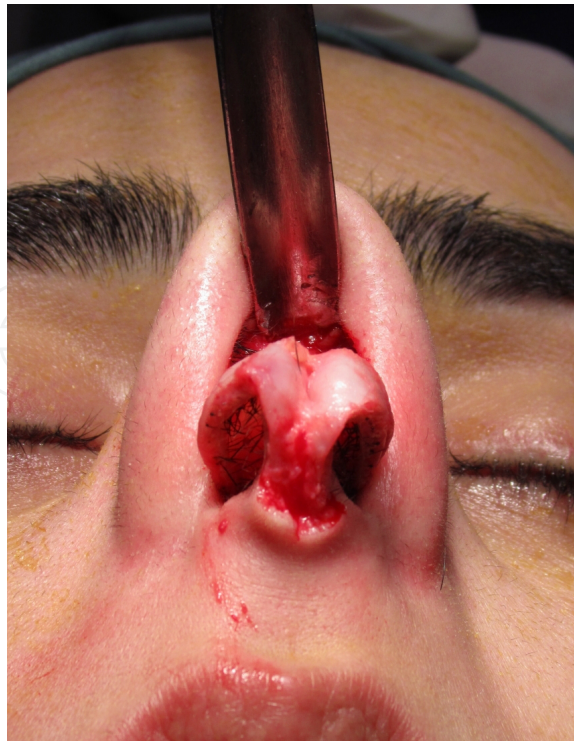**Figure 4.** Rim incision

### 5.4. Skeletonization

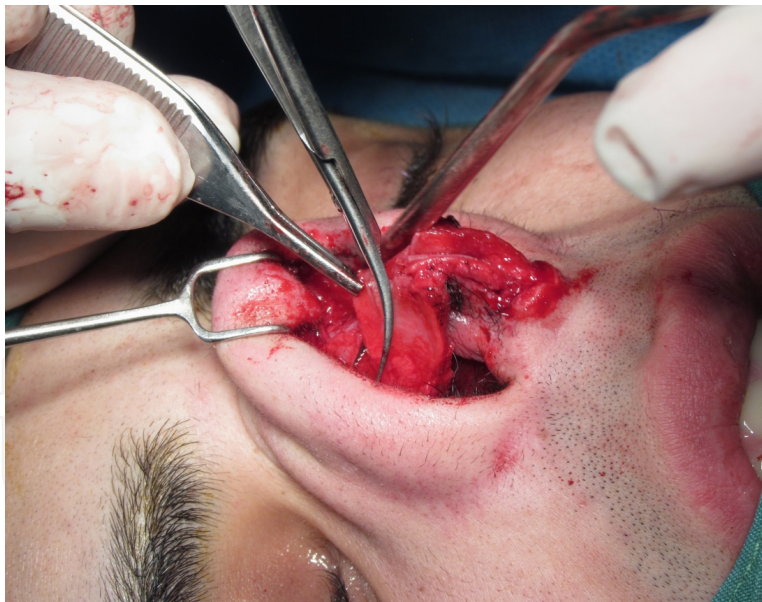Skeletonization is usually done to gain access to cartilaginous and bony framework of the nose. To do so, columellar and marginal incisions are connected to each other and with delicate scissors the skin flap is reflected gradually. Care is usually taken to move close to the cartilage and bone during dissection (Figure 5). A deeper plane will provide a skin coverage that will conceal subtle irregularities while intradermal dissections may lead to color changes or surface irregularities.

### 5.5. Tip-plasty

Tip-plasty is a combination of many reductive, suturing and grafting techniques that are done to refine or shape a malformed asymmetric tip. Basic techniques are usually enough in most cases. Though in some complicated noses such as revision or cleft noses some advanced methods may be applied that require skill and training.



**Figure 5.** Skeletonization is completed.



**Figure 6.** Cephalic trimming.

### **5.6. Cephalic trimming**

In this technique, a narrow strip of lateral crural cartilage is marked, incised and separated from underlying skin. The main purpose of cephalic trimming is to refine the tip and make enough space for tip rotation (Figure 6). [11].

### 5.7. Salient points

This technique is potentially destructive and may weaken the tip. Vigorous cartilage resection may result in severe pinch deformities and external nasal valve incompetency. As a rule all respective techniques must be done conservatively and is best avoided in narrow or weak lower lateral cartilages.

### 5.8. Tip spanning suture

Tip spanning suture is a mattress suture that is done on each dome. This suture will make a sharper dome on each side and as result more definition of the tip will be apparent (Figure 7).

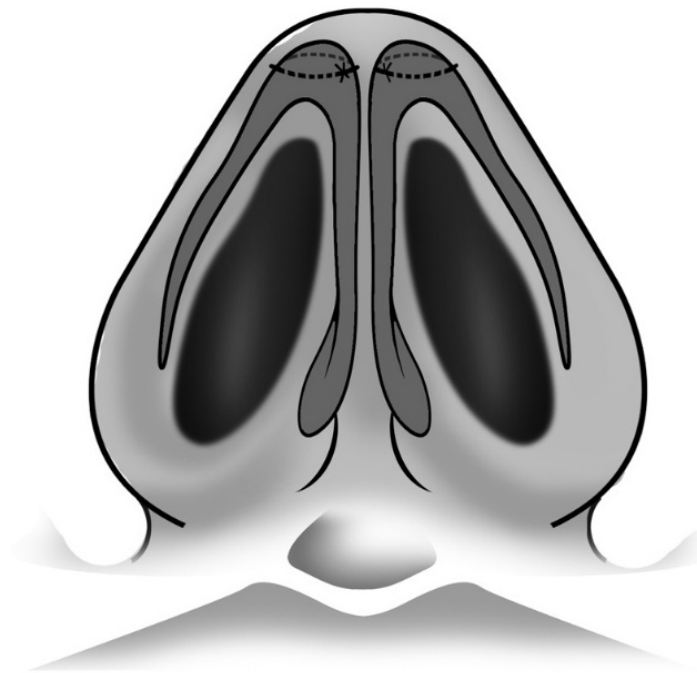


Figure 7. Tip spanning suture

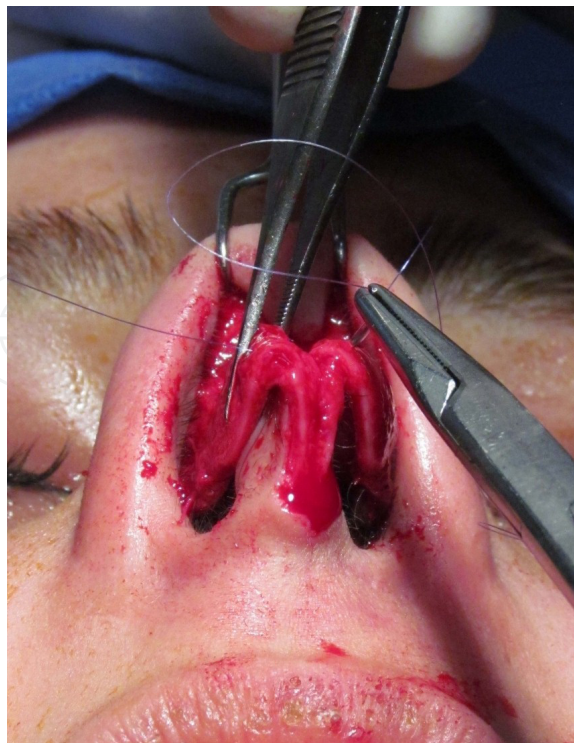### 5.9. Common mistakes

Big suture bites over the dome area or over-tightening of the tip spanning suture may lead to a pinch deformity or tip destruction. Gentle tightening of sutures and use of delicate suture material (PDS 6-0) is enough to shape the structure of the lower lateral cartilages.

## 6. Interdomal suture

Interdomal suture is a simple suture that approximates the two lateral crura. This simple suture is the most effective approach to correct a boxy and/or bifid tip (Figure 8.)





**Figure 8.** Interdomal suture

### 6.1. Common mistakes

The interdomal suture should be done in a way that two domes form a 45 degree angle to each other. Careless non-anatomic interdomal suturing will provide a pointed tip that has no definition and is not aesthetically pleasing. [12-15].

## 7. Basic grafts in tip plasty

### 7.1. Collumellar strut

The columellar strut is a quadrangular piece of cartilage that is inserted and fixed, in a pocket between the two medial crura. The columellar strut is aimed to reinforce tip support; the strut may indirectly have positive effects on tip rotation and increasing tip projection (Figure 9). [16].

### 7.2. Cap graft

The cap graft is a small ovoid cartilage that is prepared from septal cartilage, remnants of excised cephalic trimming or choncal cartilage. This graft is placed and fixed over the domes (Figure10). Cap grafts may have several aesthetic results namely:

1. Slightly increases tip projection
2. Shapes the tip

3. Covers the irregularities of the tip cartilages

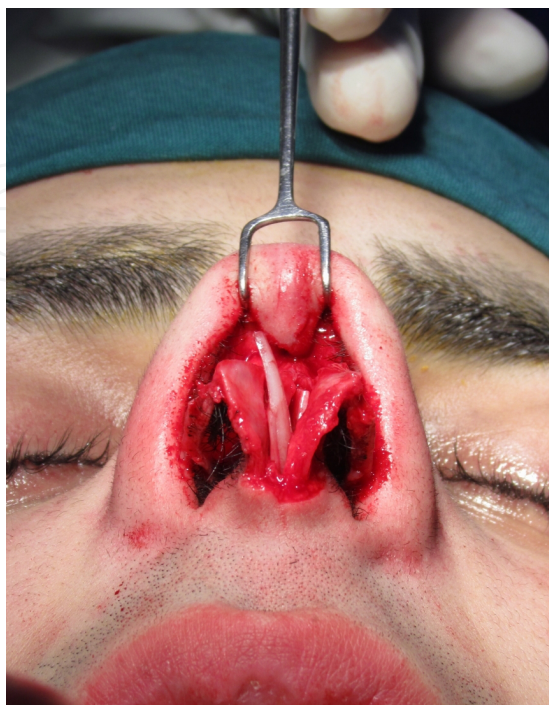

Figure 9. Collumellar strut

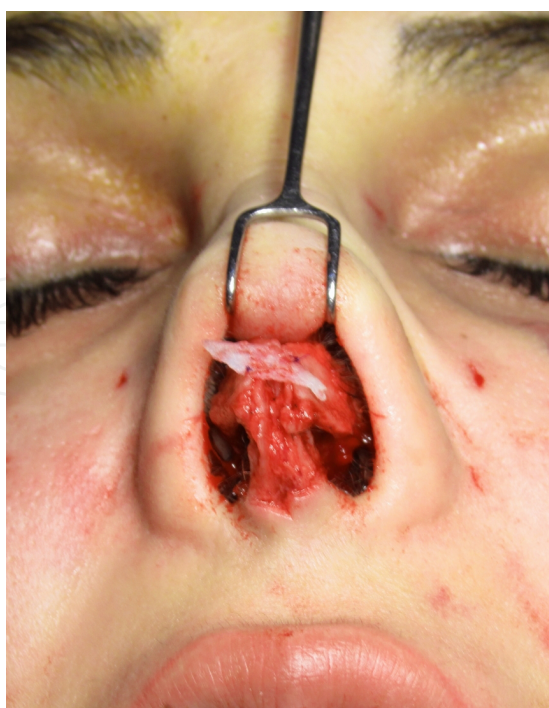

Figure 10. Cap graft

### 7.3. Shield graft

Shield graft is a quadrangular piece of a cartilage that is formed and trimmed according to the aesthetic needs of the deformity. A shield graft is generally placed and fixed caudal to the medial crural cartilages (Figure 11). This graft has nearly the same role as a cap graft though its heavier and stronger; there are two specific uses for it:

1. To form the bulky tip
2. To increase tip projection [17-21]

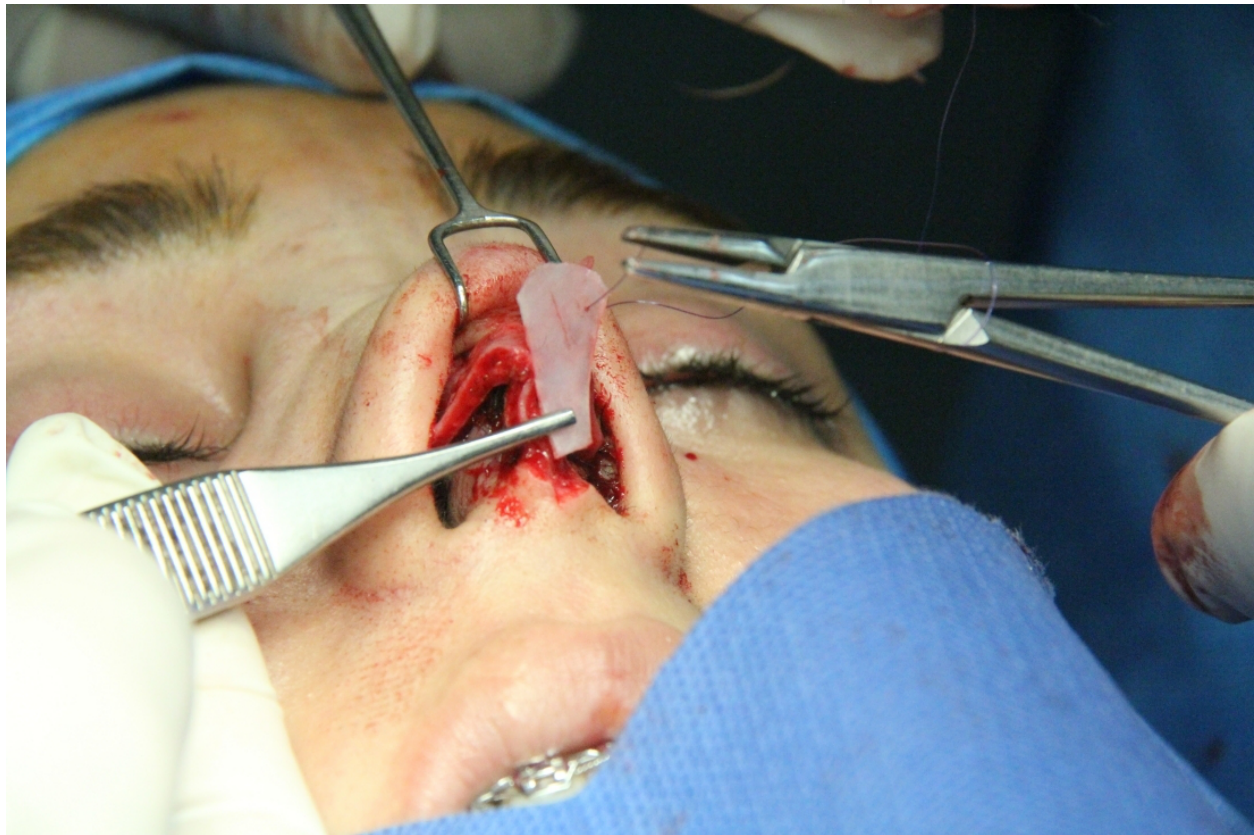



Figure 11. Shield graft

### 8. Crushed cartilage

A small piece of cartilage is placed in a crusher and with few strokes of a mallet, a smooth soft texture is provided that may be used to cover the irregularities or fill subtle deformities (Figure 12). Tip grafts are best fixed by delicate 6-0 PDS sutures to prevent any future dislodgment or displacement. The skin may be re-draped several times to seek any spicules. Sharp edges or shadows of tip grafts are corrected intra-operatively to avoid later revisions. [22]





**Figure 12.** Crushed cartilage

## 9. Hump modification

The dorsal hump is a complex anatomic component of the nose. The nasal hump is formed by two upper lateral cartilages, the septal cartilage and two nasal bones. Dorsal modification is usually started with resection of excessive parts and in some cases augmentation of shallow and defective parts. Hump resection may be done in a way that all excessive parts are resected in one piece (composite resection) or in a way that each component is trimmed and resected separately in an incremental manner (component resection).

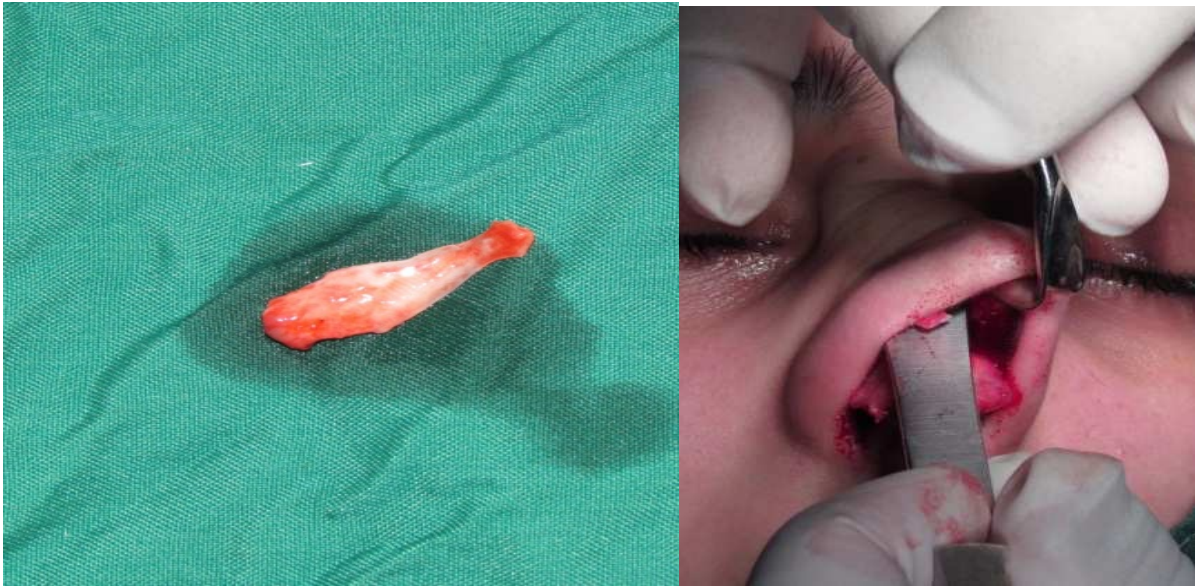### 9.1. Composite hump surgery

When it is planned to remove a maximum of 2 or 3mm of dorsal hump, composite resection may be done. In this technique, cartilaginous part is cut by surgical knife and a hump osteotome is inserted beneath the cut cartilage and hump resection is continued with mallet strokes to cut the excessive bone; then the resected hump is simply removed (Figure 13).

### 9.2. Salient points

1. Integrity of the underlying mucous is crucial in internal nasal valve function so this technique is best preserved for minor resections and in case further resection is necessary component resection should be performed.

2. The resected hump is a potential graft material that may be used as a strut, tip graft or as an ideal material for dorsal augmentation.



**Figure 13.** Composite hump surgery

### 9.3. Component hump resection

In this technique the upper lateral cartilages are precisely separated from the nasal septum and underlying mucosa, then excessive septal cartilage is trimmed until the ideal position is achieved. To adjust the bony part, a bone rasp or osteotome is used. In final steps excessive upper laterals may be trimmed very conservatively.

### 9.4. Important points

1-In major hump resections (more than 3mm), the dorsal hump may be reconstructed to avoid breathing problems and to provide a pleasant aesthetic brow line. A spreader graft is the gold standard with which to reconstruct the internal nasal valve; additionally, autospreader grafts and splay grafts are also effective methods in indicated cases [23-24].

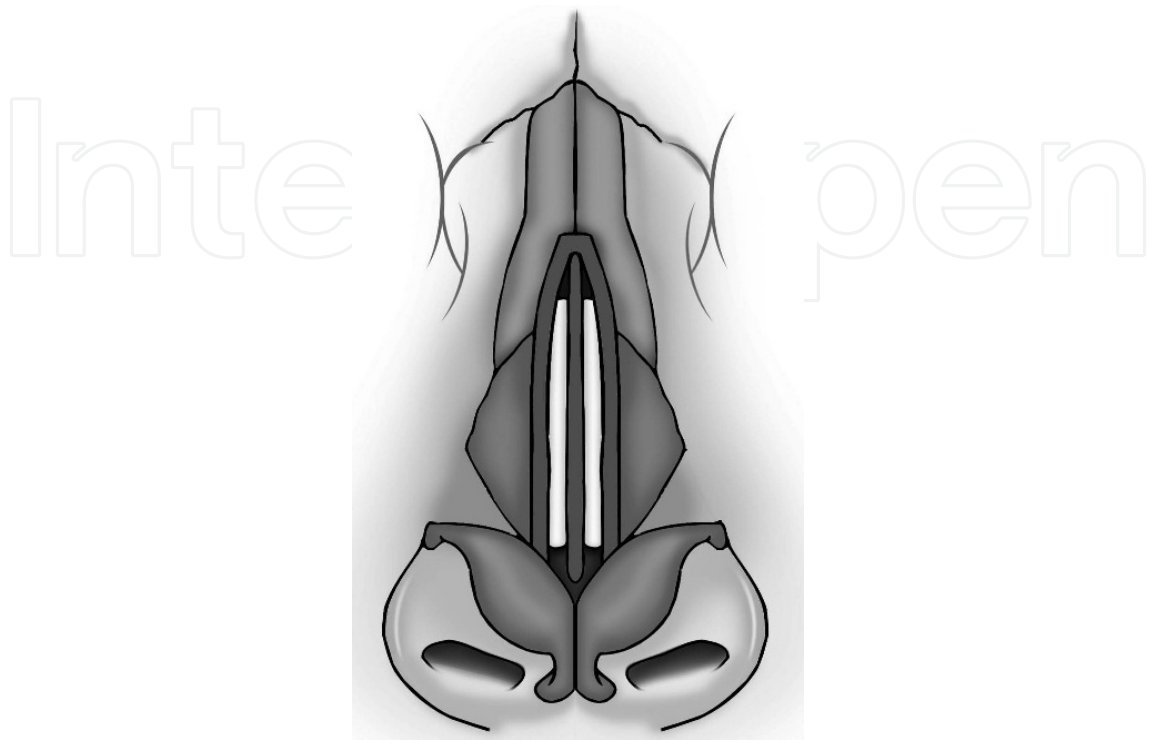
## 10. Basic grafting techniques in dorsal surgery

### 10.1. Spreader grafts

Spreader grafts are two quadrangular pieces of cartilage (3mm in width and 20mm in length) that may be modified according to the patients' specific needs. These cartilages are placed on both sides of nasal septum and fixed with 5-0 PDS sutures. This grafting technique



will change the geometry of internal nasal valve and prevent internal nasal valve incompetency (Figure 14). [25-27].



**Figure 14.** Spreader grafts.

### **10.2. Crushed cartilage**

Crushed cartilage is an ideal augmentation material that may be precisely added to defective dorsal segments and cover irregularities.

### **10.3. Temporalis fascia**

Temporalis fascia is a soft smooth graft material that is frequently reported to be used in augmentation rhinoplasty. This graft easily blends-in with normal nasal tissues and does not make shadows or visible borders. To harvest temporalis fascia a 5cm curvilinear incision is made on the posterior hairline. With upward and anterior subcutaneous dissection, ideal access to temporalis fascia is obtained then adequate fascia is harvested and placed in the recipient site in the nose. This approach provides ideal access to the area. A direct incision in hair-bearing areas of the temporalis area is also frequently used.

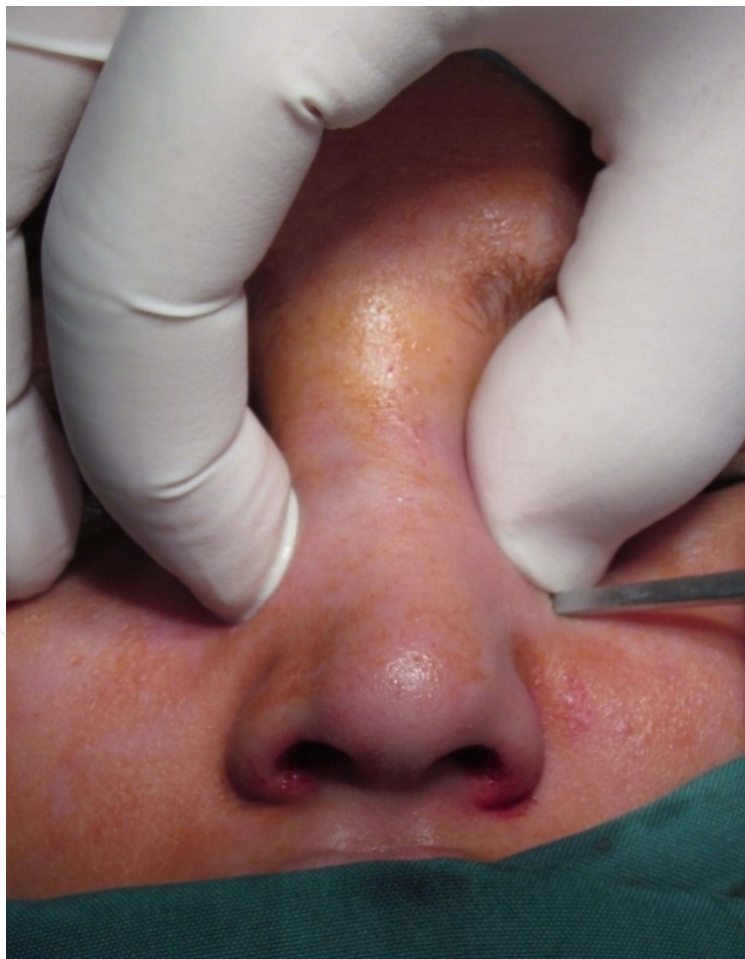### **10.4. Lateral osteotomy**

Lateral osteotomy is generally done to narrow a wide bony vault and/or to close an open roof deformity. This is beneficial to reshape a malformed bony vault (like traumatic noses). Lateral osteotomy may be done by two main options; external perforating osteotomy or internal

continuous osteotomy. Both techniques have their own advantages and disadvantages; the literature has shown that both work well in the hands of skilled and trained surgeons.

### 10.5. External perforating osteotomy

The osteotomy line is planned and marked over the skin. A small stab incision is made on the nasal skin, midway of the bony vault; then a 2mm osteotome is inserted through the incision line. Using sweeping movements of the osteotome it finds its proper place at the beginning of marked osteotomy line under the periosteum of the bony vault. Then, with mallet strokes the osteotomy is started. After performing one osteotomy site, the osteotome is gently pulled out of the bone in a way that it stays inside the skin incision and is guided in the planned osteotomy line and the next osteotomy site is done adjacent to first one. In this way several osteotomy holes are made along the planned line. Then a gentle finger pressure is applied over the bony vault and the osteotomized bony segment is moved medially. Gauze soaked in cold serum is pressed over the osteotomy region and held for a few minutes to control bleeding and edema (Figure 15).



**Figure 15.** External perforating osteotomy

## 10.6. Internal continuous osteotomy

A 3 to 4mm guided osteotomy is usually used in this method of osteotomy. First a nasal speculum is used to find the best place in pyriform aperture. A small 5 mm incision is done. Then the osteotome is inserted inside the incision in a way that the guide stays laterally and blade medially toward the nostrils. With mallet strokes, the osteotomy is started and continues toward the medial canthus in the planned line. Then gentle finger pressure is applied to medialize the bony segment. The same procedure is done on the other side and gauze is pressed over the bony nasal vault and held for few minutes to control the bleeding and edema.

## 10.7. Salient points

1. Medial movements of the bony pyramid can be done by gentle finger pressure after lateral osteotomy. Failing to do so means that inadequate osteotomy is performed and osteotomy should be repeated properly. Aggressive use of force to in-fracture the bony segments by the surgeon or osteotome handle may dislodge the segments or lead to severe bony collapse.
2. It is generally suggested to limit the osteotomy line up to the medial canthus; further extension does not lead to acceptable results and will add the possibility of complications [28-32].

## 11. Nasal base surgery

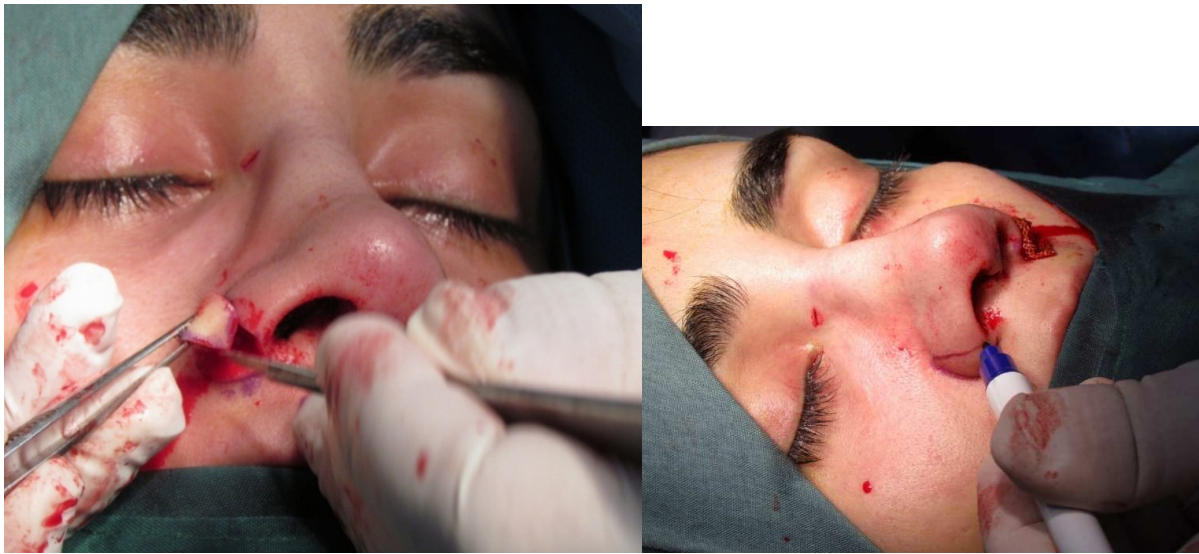The nasal base is a triangular view of the nose that is formed by two nostrils, nasal columella that separates these two nostrils and nasal lobule or the area above the nostrils. Nasal base surgery is usually based on thorough preoperative evaluations. It should be kept in mind that this stage of rhinoplasty is quite irreversible and any mistake in design or incision line will result in valve incompetency, nasal base deformity and visible scars (Figure 16).

### 11.1. Suturing and taping

After finishing the operation the skin flap is turned back to its proper place and all the details are checked several times. When the surgeon is sure that the desired result is achieved, suturing is done. As a rule, all the incisions must be closed by sutures to avoid unfavorable scars or dead spaces. It is suggested to irrigate the wound during suturing to avoid clot formation over incision lines. The incisions are immediately covered by antibiotic ointment. Taping helps to control dead spaces and edema; after suturing, a one centimeter tape is applied to re-drape the skin flap over newly formed cartilaginous and bony structure. This taping is applied immediately after suturing and is continued for one month or longer after operation.

### 11.2. Intranasal splint fixation

Internal splints usually have small tubes that help the patient breathe through the nose in the first post-operative days. It's believed that internal splints prevent intranasal edema and



**Figure 16.** Nasal base surgery

synechia. Internal splints may be removed after 24 hours; however, it is possible to preserve it for one week or longer according to septal or turbinate manipulations done during surgery.

### 11.3. External splint application

External splints are usually thermoplastic stents softened in warm water and trimmed to provide suitable protection. The splint is gently placed over the taped nose. Irrigation with cold water will fix the splint in place. The splint is held for 5 days to one week. It is believed that external splints will hold the bony segments in their new position and will help the skin envelope re-drape over its new structure [33-35].

### 11.4. Post-operative care

Careful post-operative care will help the operated nose achieve its ideal shape in a predictable period of time. Sutures are usually removed in 5-7 post-operative days. Internal and external splints are usually removed on the same day though in some cases due to some specific indications such as extensive septoplasty splints may be preserved for a longer period of time. Clot and debris are gently cleaned in periodic postoperative visits. Frequent normal saline rinse by the patient and phenylephrine drops (only for three days after operation) may help the patient breathe better in the immediate post-op period. Taping is continued for one month. Patients are asked to avoid moderate sport activities for one month though vigorous activities such as contact sports or professional exercises are best postponed for three months.

### 11.5. Important points

1. Diluted corticosteroids (triamcinolone) may be beneficial to control the edema and granulation tissues post-operatively.

2. Selective taping is an effective method to shape subtle deformities. In this method prominent edematous points such as supratip area may be pressed under tight taping while other points that are susceptible to slight depression are left without taping or covered with light taping
3. Any major revision is best postponed for 6 months to one year after the first operation while smaller revisions such as alar base surgeries may be done sooner according to specific conditions of patient after the first operation.

## Author details

Payam Varedi<sup>1,2\*</sup> and Behnam Bohluli<sup>2,3</sup>

\*Address all correspondence to: [payam.varedi@yahoo.com](mailto:payam.varedi@yahoo.com)

1 Department of Oral and Maxillofacial Surgery, Qazvin University of Medical Sciences, Qazvin, Iran

2 Department of Oral and Maxillofacial Surgery, Craniomaxillofacial Research Center, Shariati Hospital, Tehran University of Medical Sciences, Tehran, Iran

3 Department of Oral and Maxillofacial Surgery, Buali Hospital, Islamic Azad University of Medical Sciences, Tehran, Iran

## References

- [1] Swamy RS, Sykes JM, Most SP. Principles of photography in rhinoplasty for the digital photographer Clin Plast Surg. 2010 Apr;37(2):213-21.
- [2] Ziglinas P, Menger DJ, Georgalas C. The body dysmorphic disorder patient: to perform rhinoplasty or not? Eur Arch Otorhinolaryngol. 2014 Sep;271(9):2355-8.
- [3] Belli H, Belli S, Ural C. Psychopathological evaluation of patients requesting cosmetic rhinoplasty: a review. West Indian Med J. 2012 Mar;61(2):149-53.
- [4] Chauhan N, Warner J, Adamson PA. Aesthetic outcomes Plast Surg. 2010 Aug;34(4):510-6
- [5] Tan S, Rotenberg B. Functional outcomes after lateral crural J-flap repair of external nasal valve collapse. Ann Otol Rhinol Laryngol. 2012 Jan;121(1):16-20.
- [6] Saleh AM, Younes A, Friedman O. Cosmetics and function: quality-of-life changes after rhinoplasty surgery. Laryngoscope. 2012 Feb;122(2):254-9.



- [7] Zoumalan RA, Larrabee WF Jr, Murakami CS. Intraoperative suction-assisted evaluation of the nasal valve in rhinoplasty. *Arch Facial Plast Surg*. 2012 Jan-Feb;14(1):34-8.
- [8] Fung E, Hong P, Moore C, Taylor SM. The effectiveness of modified cottle maneuver in predicting outcomes in functional rhinoplasty.
- [9] Duron JB, Nguyen PS, Jallut Y, Bardot J, Aiach G. Middle third of the nose and internal valve. Alar wall and external valve. *Ann Chir Plast Esthet*. 2014 Jul 30. pii: S0294-1260(14)00105-8.
- [10] Riechelmann H, Karow E, DiDio D, Kral F. External nasal valve collapse - a case-control and interventional study employing a novel internal nasal dilator (Nasanita). *Rhinology*. 2010 Jun; 48(2):183-8.
- [11] Bohluli B, Varedi P, Nazari S, Bagheri SC. Lateral crural suspension flap: a novel technique to modify and stabilize the nasolabial angle. *J Oral Maxillofac Surg*. 2013 Sep;71(9):1572-6.
- [12] Xavier R. Nasal tip plasty: the delivery approach revisited. *Aesthetic Plast Surg*. 2013 Feb; 37(1):16-21.
- [13] Gruber RP, Chang E, Buchanan E. Suture techniques in rhinoplasty. *Clin Plast Surg*. 2010 Apr; 37(2):231-43.
- [14] Gruber RP, Weintraub J, Pomerantz J. Suture techniques for the nasal tip. *Aesthet Surg J*. 2008 Jan-Feb; 28(1):92-100.
- [15] Lee KC, Kwon YS, Park JM, Kim SK, Park SH, Kim JH. Nasal tip plasty using various techniques in rhinoplasty. *Aesthetic Plast Surg*. 2004 Nov-Dec; 28(6):445-55.
- [16] Atighechi S, Sajadinejad BS, Baradaranfar MH, Dadgarnia MH, Shahbazian H. Caudal extension graft versus columellar strut with plumping graft for acute nasolabial angle correction in rhinoplasty surgery. *Eur Arch Otorhinolaryngol*. 2014 Aug 18.
- [17] McCollough EG, Mangat D. Systematic approach to correction of the nasal tip in rhinoplasty. *Arch Otolaryngol* 07:12, 1981.
- [18] Daniel RK. Rhinoplasty: creating an aesthetic tip. *Plast Reconstr Surg* 80:775, 1987.
- [19] Xavier R. Nasal tip plasty: the delivery approach revisited. *Aesthetic Plast Surg*. 2013 Feb;37(1):16-21.
- [20] Lee KC, Kwon YS, Park JM, Kim SK, Park SH, Kim JH. Nasal tip plasty using various techniques in rhinoplasty. *Aesthetic Plast Surg*. 2004 Nov-Dec;28(6):445-55. Epub 2004 Dec 2.
- [21] Hwang K, Hwang JH, Park JH, Kim DJ, Shin YH. J Experimental study of autologous cartilage, acellular cadaveric dermis, lyophilized bovine pericardium, and irradiated bovine tendon: applicability to nasal tip plasty. *Craniofac Surg*. 2007 May;18(3):551-8.

- [22] Antohi N, Isac C, Stan V, Ionescu R. Dorsal nasal augmentation with "open sandwich" graft consisting of conchal cartilage and retroauricular fascia. *Aesthet Surg J*. 2012 Sep;32(7):833-45.
- [23] Temiz G, Yeşiloğlu N, Sarici M, Filinte GT. Congenital isolated aplasia of lower lateral cartilage and reconstruction using dorsal hump material. *J Craniofac Surg*. 2014 Sep;25(5):e411-3.
- [24] Rohrich RJ, Muzaffar AR, Janis JE. Component dorsal hump reduction: the importance of maintaining dorsal aesthetic lines in rhinoplasty. *Plast Reconstr Surg*. 2004 Oct;114(5):1298-308; discussion 1309-12.
- [25] Varedi P, Bohluli B, Bayat M, Mohammadi F. Spreader graft placement: A simplified technique for young surgeons. *Int J Oral Maxillofac Surg*. 2014 Oct;43(10):1216-7.
- [26] Kucuker I, Ozmen S. Extended spreader graft placement before lateral nasal osteotomy. *Aesthetic Plast Surg*. 2013 Aug;37(4):684-91.
- [27] Grigoryants V, Baroni A. The use of short spreader grafts in rhinoplasty for patients with thick nasal skin. *Aesthetic Plast Surg*. 2013 Jun;37(3):516-20.
- [28] Varedi P, Shirani G, Bohluli B, Besharati R, Keyhan SO. A simplified approach to the external lateral nasal osteotomy: a technical note. *J Oral Maxillofac Surg*. 2013 Aug;71(8):1435-8.
- [29] Rootman D, DeAngelis D, Tucker N, Wu A, Hurwitz J. Cadaveric anatomical comparison of the lateral nasal wall after external and endonasal dacryocystorhinostomy. *Ophthal Plast Reconstr Surg*. 2012 Mar-Apr;28(2):149-53.
- [30] Bohluli B, Moharamnejad N, Bayat M. Dorsal hump surgery and lateral osteotomy. *Oral Maxillofac Surg Clin North Am*. 2012 Feb;24(1):75-86.
- [31] Levie P, Horoi M, Claes J, Monnoye JP, Verheyden PJ, Monnoye V, Lefebvre J, Millet B, Darteville D, Lemaire FX, Hatert AS, de Burbure C. External or internal lateral osteotomy: why I choose the external percutaneous approach. *B-ENT*. 2010;6Suppl 15:49-50.
- [32] Helal MZ, El-Tarabishi M, Magdy Sabry S, Yassin A, Rabie A, Lin SJ. Effects of rhinoplasty on the internal nasal valve: a comparison between internal continuous and external perforating osteotomy. *Ann Plast Surg*. 2010 May;64(5):649-57.
- [33] Yi CR, Kim YJ, Kim H, Nam SH, Choi YW. Comparison study of the use of absorbable and nonabsorbable materials as internal splints after closed reduction for nasal bone fracture. *Arch Plast Surg*. 2014 Jul;41(4):350-4.
- [34] Cayonu M, Acar A, Horasanlı E, Altundag A, Salihoglu M. Comparison of totally occlusive nasal pack, internal nasal splint, and transseptal suture technique after septoplasty in terms of immediate respiratory distress related to anesthesia and surgical complications. *Acta Otolaryngol*. 2014 Apr;134(4):390-4.

- [35] Drezner DA. Thermoplastic splint for use after nasal fracture. *Otolaryngol Head Neck Surg.* 1994 Jul;111(1):146-7

IntechOpen

IntechOpen