

We are IntechOpen, the world's leading publisher of Open Access books Built by scientists, for scientists

6,900

Open access books available

185,000

International authors and editors

200M

Downloads

Our authors are among the

154

Countries delivered to

TOP 1%

most cited scientists

12.2%

Contributors from top 500 universities



WEB OF SCIENCE™

Selection of our books indexed in the Book Citation Index
in Web of Science™ Core Collection (BKCI)

Interested in publishing with us?
Contact book.department@intechopen.com

Numbers displayed above are based on latest data collected.
For more information visit www.intechopen.com



Basics of Microvascular Reconstruction of Maxillomandibular Defects

Reza Tabrizi and Barbad Zamiri

Additional information is available at the end of the chapter

<http://dx.doi.org/10.5772/59303>

1. Introduction

Effective reconstruction following ablative surgery of maxillomandibular defects requires the provision for adequate oral lining, skin, and replacement of missing bone; in some situations, restitution of function of the temporomandibular joint also requires reconstruction-preferably achieved in one stage. Conventional replacement of bone defects usually involves the use of autogenous cancellous bone grafts from either the iliac crest or ribs after provision of adequate skin cover by pedicled axial-pattern skin flaps such as a pectoralis major flap.[1]

Early reconstructive efforts with nonvascularized bone grafts were plagued by a high incidence of postoperative complications and poor long-term outcomes. [2] Inadequate local blood supply due to poorly vascularized flaps or irradiation resulted in rapid resorption of the grafts. The advent of techniques in which composite flaps containing skin and bone together with their own independent blood supply transferred either as pedicled osteocutaneous flaps or free osteocutaneous flaps has revolutionized the concepts of head and neck reconstruction.[1] Early postoperative complications decreased even in the setting of postoperative radiation; and expectations for successful oral rehabilitation, including placement of osseointegrated implants, rose markedly.[2]

1.1. History

The first vascular anastomosis was introduced by J.B. Murphy in 1892; and Alexis Carrel made an end to end anastomosis by using a three-stay suture technique. [3] The first anastomosis in a dog was performed by Krizek. [4] Following him, the first free flap was published in 1971. [3]

2. Assessment of maxillomandibular defects

Each defect is individualized according to the missing component. In the maxillomandibular area the size of soft tissue as well as bone defect, the underlying etiology (cancer, trauma, and infection), anatomic location, aesthetic visibility, associated functional disabilities and the availability of a local and or distant donor site should be evaluated. [5] Compatibility of the donor tissue with the area being reconstructed should be considered with regard to skin color, texture, thickness of soft tissue, bone quantity and quality and also shape of the bone component to restore the mandible and maxilla; further restoration with dental implants can be done. It has been shown that any mandibular defect greater than 6.0 cm is prone to failure and thus free flaps in these defects are indicated.[6] Restoration of stable retentive dentition is a prerequisite to a successful functional oral rehabilitation. This is best achieved with endosseous implants, capable of supporting a stable dental prosthesis, placed directly into vascularized bone flaps at the time of mandibular reconstruction. The iliac crest is the most consistently implantable donor site, followed by the scapula, fibula, and radius (with 83%, 78%, 67%, and 21% of sections from each donor site satisfying the criteria for implantability respectively). Consistent regional differences in implantability were encountered at each donor site except the scapula. [7] In a cadaver study, the dimensions of bone available for implant placement from the iliac crest, scapula, fibula, and radius osseous flaps were measured. The iliac crest and fibula flaps had bone dimensions consistently adequate for implant placement. Bone availability for the safe placement of implants into the scapula flap was found in the majority of specimens. The radius flap group had the highest number of specimens that were inadequate for implant placement. [8] Another study demonstrated that nearly all of the iliac crests had adequate dimensions for the positioning of four 10 mm implants. In 63% of the scapulae, it

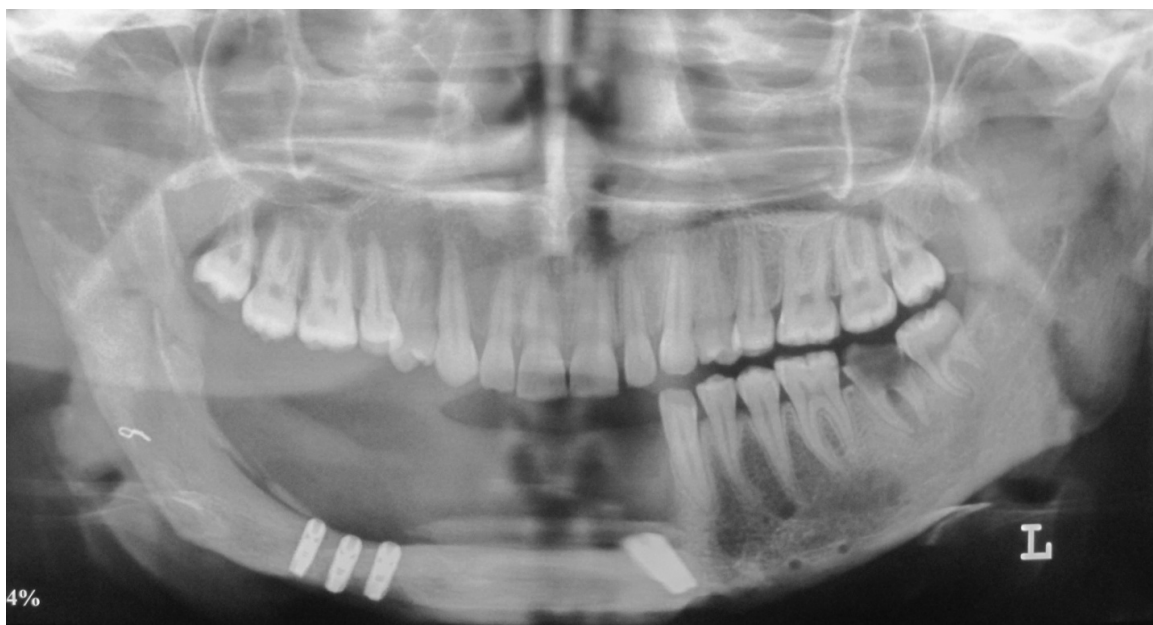

Figure 1. Four implants placed after a fibula flap graft.

was also possible to place four 10 mm implants. In the case of the scapula, half of the female subjects lacked enough available bone for the insertion of four 10 mm implants because of their inadequate width. Bone density and cortical thickness were found to be similar in the iliac crest and scapula. Age and side do not have an important influence on cortical bone dimensions and density. In contrast to the iliac crest, the lateral margin of the scapula astonishingly showed increasing values for bone density and increasing thickness of the cortex. Analogical advanced biological age works in conformity with the scapula flap (Figure 1). [9]

3. Microvascular composite tissue transplantation

In the maxillomandibular area, surgeons encounter soft and hard tissue defects due to ablation of cancer or severe destructive trauma. After introducing the ability to repair vessels less than 2 mm in diameter, microvascular transplantation found its place in reconstruction surgery. A microvascular composite transplantation was defined as a composite flap (soft and hard tissue with their associated blood supply) which is removed from a part of the body and anastomosed to the recipient site vessels. It has been shown that a reliable anastomosis can be achieved with an external lumen diameter of 0.5 to 2mm with a patency rate of 95%. [10]

The frequency of using various free flaps is different according to defect site, the surgeon's experience and condition of the patient. In a retrospective study, flap donor sites included radial forearm (n = 183), fibula (n = 145), rectus abdominis (n = 38), subscapular system (n = 28), iliac crest (n = 5), and a jejunal flap. Age, sex, diagnosis, comorbidities, tumor stage, defect site, primary vs. secondary reconstruction, and history of surgery, radiation therapy, or chemotherapy were considered for choosing a flap. [11]

4. Common microvascular flaps in the maxillomandibular region

Radical cancer ablative surgery and severe traumatic injury can result in complicated defects in the maxillomandibular area which need a complex reconstruction plane. In a small or simple defect, it may be appreciated that the defect is restored with a regional flap. However, microvascular reconstruction of large defects with hard and soft tissue deficiency is a standard approach. The primary use of the free muscle or musculocutaneous flap in the maxillomandibular area consist of provision of tissue bulk for a large defect, coverage of vital structures, provision of skin for the face and mucosa for intraoral lining.[12] Furthermore, a composite osteocutaneous flap provides a skeletal framework to restore function.[12]

5. Radial forearm flap

As the radial forearm flap was originally developed in China, it is often named the China flap. [13] Primarily this flap was introduced as a large flap incorporating most of the circumference

of the forearm and was applied as a free flap to cover burns contractures, mainly in the head and neck. [14] The radial forearm flap is a good flap for intraoral reconstruction, offering thin, pliable predominantly hairless skin to replace oral mucosa. The vascularity of the area allows considerable variation in the design of this fasciocutaneous flap and offers the possibility of including bone as an osteocutaneous flap. Furthermore, the vascular anatomy of the flap simplifies the technical aspects of free tissue transfer. Based on ten clinical cases the design of the flap is described and its versatility in differing clinical situations is illustrated. [15] The rich vascularity of the flap results in rapid healing and minimizes wound healing complications, and there is a potential for sensory reinnervation. The flap can be harvested at the same time of tumor surgery. [13]

The radial forearm flap has mostly been used to reconstruct the oral floor, tongue and the maxilla [16] (Figure 2). The osteocutaneous radial flap is robust, reliable, and relatively simple to harvest, which will ensure that it remains one of the established reconstructive options in most maxillofacial units. Many surgeons prefer to use a limited number of trusted flaps, and these qualities will ensure that in the intermediate future most surgical trainees will continue to be shown the fasciocutaneous radial flap as both the basic training flap and the established option for reconstruction. Evidence from observational clinical studies and one randomized clinical trial indicates that there is increasing support for the use of the evolutionary technique of suprafascial dissection to minimize morbidity at the donor site. The suprafascial donor site may be repaired with either a meshed or unmeshed partial-thickness skin graft, or a fenestrated full-thickness skin graft, with good rates of successful healing. The application of a negative pressure dressing to the wound seems to facilitate the healing of all types of skin grafts. The subfascial donor site, however, remains more prone to complications. It may be helpful to position the donor site of the flap more proximally, but this has not been proven. These refinements probably produce the best outcomes that can currently be achieved, given the inherent flaws of the radial donor site.[17] Evidence based on clinical observational studies and biomechanical studies supports the routine or selective use of prophylactic internal fixation to strengthen the radial osteocutaneous donor site. This allows safe harvesting of the maximum volume of available bone, up to half of the circumference, with minimal risk of fracture or long term complications. The incidence of fracture with the plate placed either anteriorly or posteriorly is equally low, but the anterior position is technically easier and probably less likely to cause additional morbidity. The introduction of prophylactic internal fixation consolidates the role of the osteocutaneous radial flap for repair of defects that require a relatively small volume of bone and an appreciable area of thin soft tissue, particularly when a long vascular pedicle is desirable. This includes low level defects of the maxilla, some defects of the mandible and niche reconstructions, such as the orbital rim. The radial forearm flap remains useful as a first choice when there is appreciable peripheral vascular disease, when there are other serious coexisting medical conditions, when it is the preferred choice of the patient for functional reasons such as mobility of the lower limb or hip or when it is a salvage flap used when other reconstructive options have been exhausted. [18]

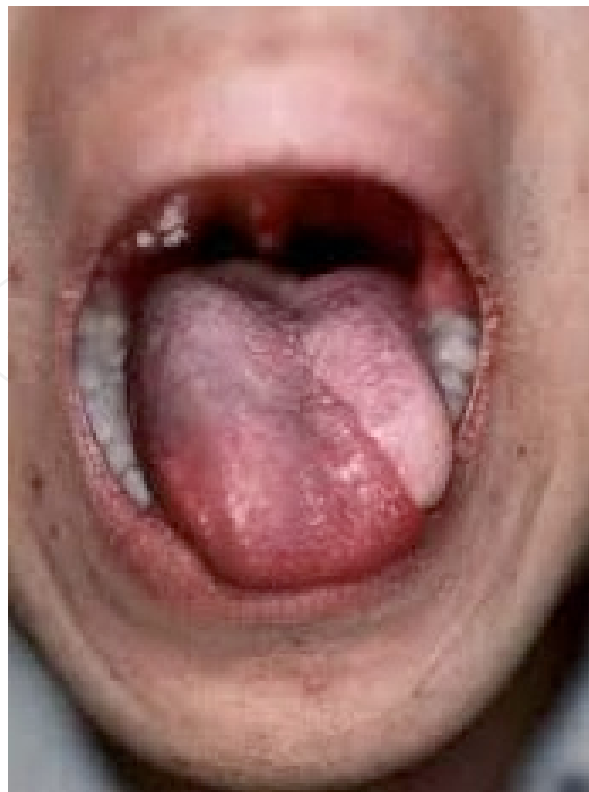

Figure 2. A radial forearm flap used to reconstruction of tongue after hemiglossectomy.

5.1. Flap anatomy

The radial artery branches from the brachial artery near the antecubital fossa and courses deep between the flexor carpi radialis and brachioradialis muscles in the proximal forearm. The artery emerges from this muscle approximately 7 cm cephalic to the wrist crease to enter the subcutaneous tissue.[19] Nine fasciocutaneous branches from the radial artery supply the skin of the forearm, four in the proximal forearm arising between the brachio-radialis and pronator teres muscles and nine in the distal forearm arising between the brachioradialis and flexor carpi radialis muscles.[14] Venous drainage is through either the venae comitantes that accompany the radial artery or the much larger superficial venous drainage system via the cephalic vein. The cephalic vein courses subcutaneously on the radial side of the wrist near the superficial radial nerve. The vein goes cephalically supramedially toward the antecubital fossa. Several branches of the superficial radial nerve are found cephalad to the anatomical snuffbox in intimate relation to the cephalic vein. Saving of this nerve is important to maintain sensation over the radial aspect and the index finger. [19]

5.2. Flap component

This is a true septocutaneous flap with a main vessel lying in the septum, giving perforators superficially to supply the fascia, fat and skin and deeper branches to supply underlying tendons, muscles, nerves and bone.[14] The Allen test is noninvasive and reliably detects

circulation problems by evaluation of arterial inflow in the presence of one functioning artery. Edgar V. Allen first introduced the test in 1929 as a non-invasive assessment of hand circulation in patients with thromboangiitis obliterans. The test was modified in the 1950s to assess the ulnar artery before cannulation of the radial artery. A similar method is used today to detect the ulnar artery inflow before harvesting the radial forearm flap. [19] The nondominant arm is usually selected for flap harvest. The design and position of the skin island in the volar forearm depend on several factors, including the desire to include the superficial venous drainage system and specific functional and cosmetic requirements at the recipient site. [19] It is usually projected over the course of the radial artery and one of the subcutaneous veins. The paddle is frequently outlined over the distal radius to obtain a vascular pedicle of greatest length (Figure 3). [13]

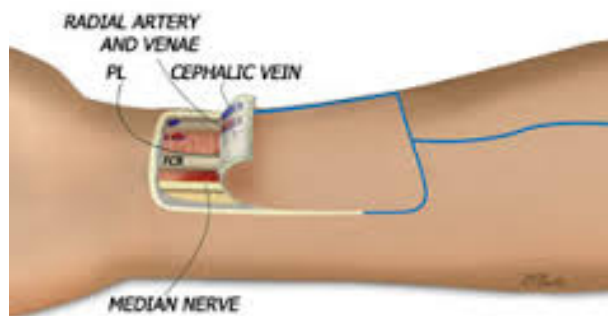


Figure 3. A radial forearm flap

5.3. Flap dimensions

The skin part of the flap commonly has 12 cm length (range 4-30 cm) and 5 cm width (range 4-15 cm) and 1 cm thickness (range 0.5-2cm). The bone part of the flap has 10 cm length (range 6-14 cm) and 1 cm width (range 0.7-1.5 cm) and 1 cm thickness (range 0.7-1.5 cm).[14]

5.4. A common radial forearm flap harvesting technique

A tourniquet is placed. The skin island is outlined over the distal forearm, including the radial artery and cephalic vein, and the flap edges are incised. The incision is extended deeply to include the deep fascia, except along the proximal edge, where the superficial veins and nerves are in the immediate subcutaneous tissue plane. The radial artery is exposed and temporarily closed to assess the adequacy of the circulation to the hand through the ulnar artery. The flap is raised from the ulnar and radial sides. It is necessary to include the deep fascia but saving the final peritenon. [19] Where bone is to be included in the lateral intermuscular septum, the periosteum of the radius must be preserved. Available bone extends from the insertion of the pronator teres to the distal styloid where there is no muscle attachment on the radial border. This provides a length of about 10-12 cm. Dissection can be performed as described, but, at the

radial border of palmaris longus, the plane is deepened to expose the flexor pollicis longus and pronator quadratus.

5.5. Complications

A major problem with radial forearm flap relates to its donor site and the effect on function and aesthetics (Figure 4). Injury to the superficial radial nerve results in numbness over the anatomic snuffbox and radial side of the thumb and index finger. A devastating complication is vascular problems of the hand because of inadequate blood supply by the ulnar artery. It has been shown that a significant functional forearm and wrist range-of-motion morbidity associated with the harvest of a radial forearm fasciocutaneous free flap may occur in the early postoperative period. [20]

The radial forearm free flap results in measurable quantitative changes in hand function and limited changes in patient perception. [21]

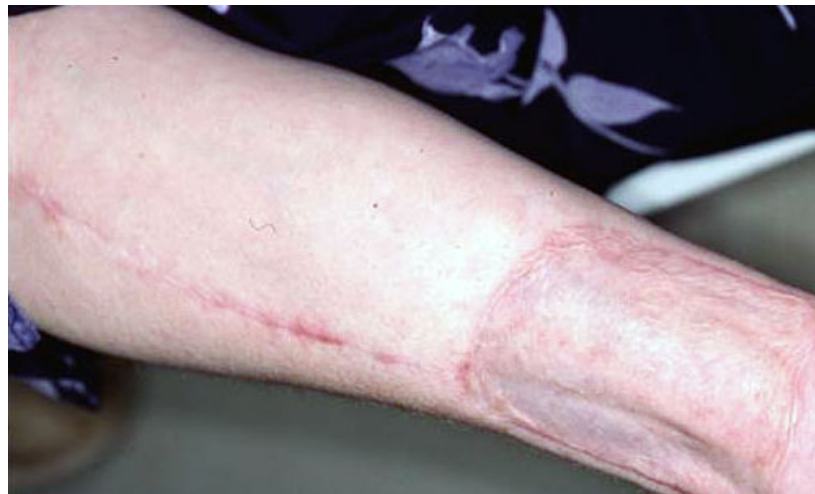

Figure 4. A severe scar of the donor site after a radial forearm flap

5.6. Radial forearm flap updates

The radial forearm flap has been used for reconstruction of palatal defects and for total lower lip reconstruction. [22, 23] It is suggested to use a full-thickness skin graft from the neck to cover the radial forearm free flap donor site in patients undergoing neck dissection and microvascular reconstruction for ablative head and neck oncologic surgery. The primary advantage is avoiding a third surgical site. Complications were comparable to those using Full-thickness Skin Grafting from other harvest sites. Importantly, cross-contamination from the head and neck with the forearm was not a problem. [24] The pre-operative application of topical tissue expansion tapes produces measurable changes in skin biomechanical properties. The location of this change on the dorsal forearm is consistent with the method of tape application. This increase in skin pliability may account for the improved rate of primary donor site closure reported using this technique. [25] AlloDerm with split-thickness skin graft has been used to

cover the donor site after radial forearm flaps. Results demonstrated thicker coverage of the forearm defect, with minimal donor site morbidity and superior cosmetic results. [26]

6. Fibula flap

The fibula bone is most commonly used in oral and maxillofacial reconstruction following benign or malignant jaw tumor ablation Hidalgo, in 1989, reported the first mandibular reconstruction using a vascularized fibula free flap. [27]. It has several advantages over other bones, including being the longest bone with lengths up to 25 cm, having bicortical structures that can support osseointegrated dental implants, having a large caliber and long vascular pedicles which provide easier anastomosis, and having thin and pliable skin paddles as well as available muscular cuffs around the fibula which can be used for reconstructing the various soft tissue defects (Figures 5 and 6). The morbidity at the donor site is also low and the operation time is reduced because of a two-team approach.

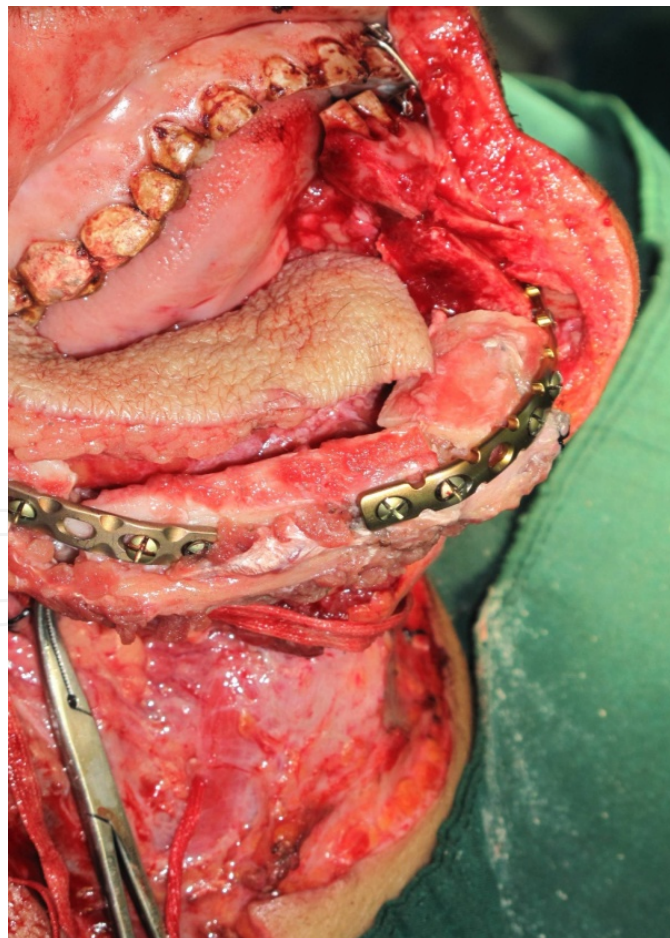


Figure 5. A composite fibula flap used to restore the hemimandible and the oral floor.

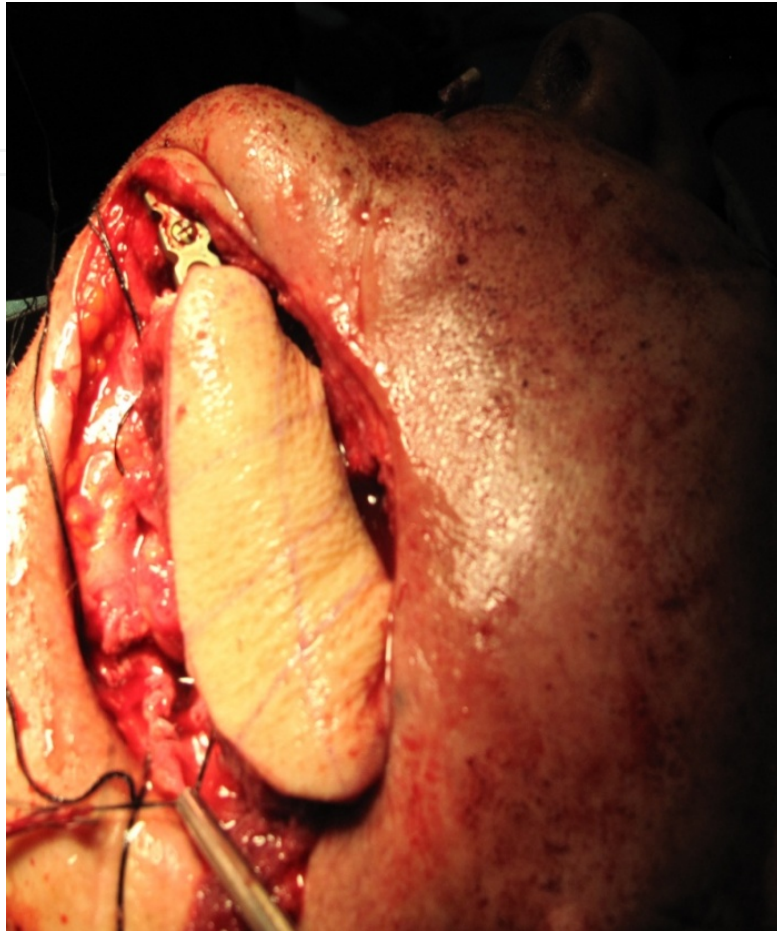


Figure 6. A composite fibula flap for reconstruction of the hemimandible and soft tissue defect on the face.

6.1. Flap anatomy

The arterial supply of the fibula flap is the peroneal artery. The peroneal artery branches from the posterior tibial artery just proximal to the head of the fibula. The external diameter of the peroneal artery is 1.5-2.5 mm. The pedicle length varies and may be quite long if a large segment of the proximal part of the bone is resected. The skin over the lateral leg is also nourished by the peroneal artery via septocutaneous vessels that course posterior to the fibula to enter the posterior crural intermuscular septum. [19] Venous drainage of the flap is primarily by venae comitantes (two) of the peroneal artery. The venae comitantes often merge to form a single large vein near the posterior tibial artery. Sensory innervation to the corresponding lateral leg skin is mostly supplied by the lateral sural nerve. It can be detected under microscopic view. It is possible to enclose the lateral sural nerve with the fibula flap to improve function of recipient site (Figure 7). [28]

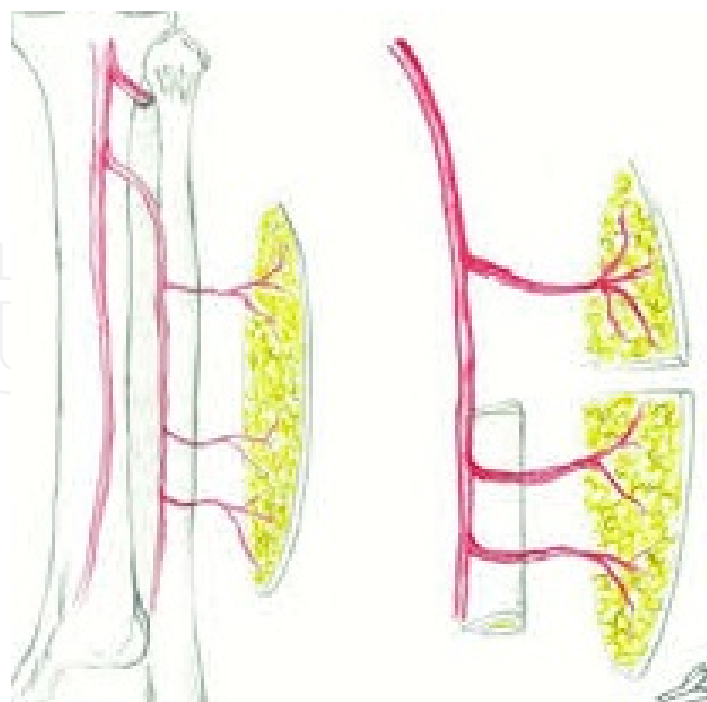


Figure 7. Anatomy of a free fibula flap

6.2. Flap component

The fibula flap is harvested as a bone flap and may consist of muscles (soleus or flexor hallucis longus), overlying fascia and/or skin (Figure 8). [28]

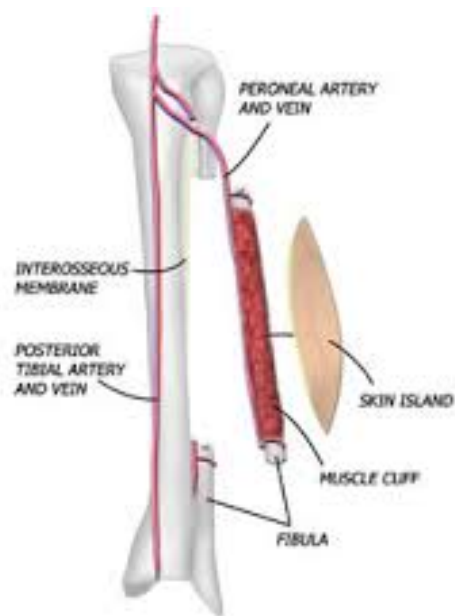


Figure 8. Components of a fibula flap

6.3. Flap dimensions

The skin paddle length can be 12 cm and its width can be 6 cm. The bony part length is 16 cm (range 6-26 cm) and its thickness 2 cm.

6.4. A common fibula flap harvesting technique

A tourniquet is placed on the thigh and the knee is partially flexed for access to the posterolateral leg. Firstly, the fibula bone outline and a skin paddle (if it is included in the flap) are marked on the skin. Then an incision is made on the anterior outline. Dissection proceeds anterior to the posterior intramuscular septum, through which fasciocutaneous perforators run. The common peroneal nerve which runs below the level of the head of the fibula is identified and preserved with the peroneal muscles of the anterior surface of the fibula, reflecting the peroneus longus and brevis muscles. The anterior intermuscular septum is incised to gain access to the anterior part. Dissection is extended through the extensor digitorum and extensor hallucis longus. After access to the fibula bone, the maximum length of the bone is included with proximal osteotomy 6 cm inferior to the fibular head and distal osteotomy 8 cm superior to the lateral malleolus (Figure 9).[28]

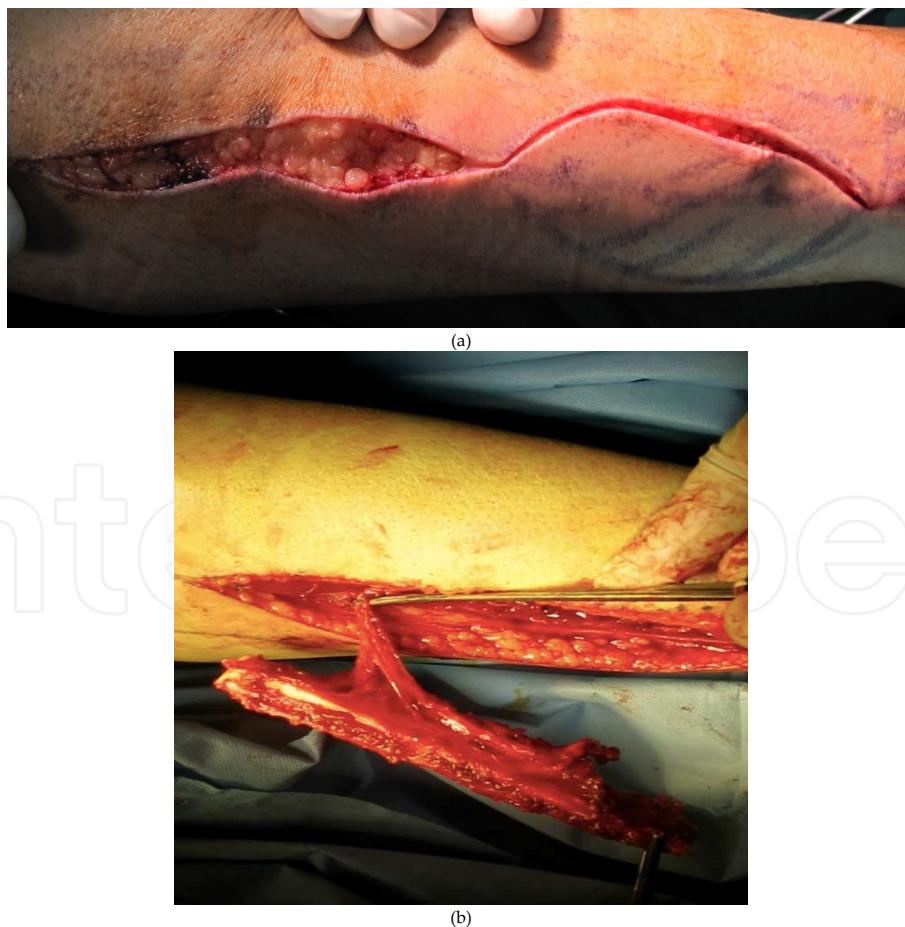

Figure 9. (a): The outline of a fibula flap with a skin paddle. (b): A fibula flap harvest. Note its vascular pedicle.

6.5. Complications

The most feared potential donor site complication in fibula flap transfer is foot ischemia secondary to the sacrifice of the peroneal artery. In the most common situation, terminal branches of the peroneal artery arise at the level of the ankle, and the blood supply to the foot is provided by the anterior and posterior tibia arteries. In patients with atherosclerosis of the anterior or posterior tibial vessels, collaterals from the peroneal artery may provide a significant contribution to pedal circulation. The majority of patients with peripheral vascular disease of the lower extremities are easily identified on the basis of history and physical examination. However, there is another group of patients with congenital vascular anomalies for whom the peroneal artery provides a significant contribution to the foot circulation. This subpopulation of patients present a unique difficulty when performing a preoperative evaluation in anticipation of performing a fibula free flap, because they may have a normal history and physical examination.[29] In general, the patient perception of donor-site morbidity is low. Complaints however, were frequently mentioned, including pain (60 percent), dysesthesia (50 percent), a feeling of ankle instability (30 percent), and inability to run (20 percent). Gait analyses revealed that patients walked at a lower preferred velocity, compared with control subjects. Furthermore, it was demonstrated that significant increases in the coefficients of variation of stride time during walking under visual and cognitive loads and during walking at a velocity higher than the preferred compared with normal walking.[30] Noticeable limitation and discomfort in ankle function and range of motion with aggressive physical activity may result after fibula harvest, particularly if tibiofibular fusion is performed.[28] Commonly the bone flap may tolerate venous thrombosis for up to 24 hours because of spontaneous bleeding from the medullary canal before the artery undergoes thrombosis, but venous drainage of the skin paddle must be managed by reoperation.[28]

6.6. Fibula flap updates

Proximal peroneal perforator in the dual-skin paddle configuration of fibula free flap has been used to reconstruct composite oral defects. The proximal peroneal perforator was found to be anatomically reliable and clinically useful in composite oral cavity reconstruction. [31] The free fibula flap has been reported to be an appropriate option for mandibular reconstruction in bisphosphonate-related osteonecrosis of the jaws. [32] The keys for gaining maximum success in a fibula flap include:

1. Harvesting the distal fibula when recipient vessels are distant
2. Flap selection based on the anatomy of perforators
3. Use of the skin paddle for postoperative flap monitoring
4. Protection of the flap's soft-tissue cuff
5. Preventing venous thrombosis which is essential to reduce flap complications
6. Aligning fibular struts and protecting the vascular pedicle when the double-barrel technique is used

7. Minimizing the gap between the double-barrel struts and implementing a long-term follow-up of dental implants
8. Selecting osteosynthesis materials
9. Mastering the learning curve and clinical competence in microvascular reconstruction. [33]

It has been shown that function can reliably be reestablished after segmental mandibulectomy and condylectomy reconstructed with a vascularized fibula flap whose distal end is not precisely contoured or actively seated in the glenoid fossa, as a valid alternative to condylar reconstruction. [34] Skin paddle harvesting is a factor that influences the operation time and patient satisfaction of fibula free flap surgery. An increase in body mass index is related to an increase in donor-site morbidity after fibula free flap transfer. [27]

7. Deep circumflex iliac artery flap

For large oromandibular defects such as subtotal glossectomy with anterior mandibulectomy the options for reconstruction are limited. The composite fibular flap will not easily provide the mass of soft tissue required or the mobility to set it in. A scapular free flap can supply the tissue needed in a chimerical fashion but without the quality or length of bone, and it requires the patient to be turned. Two free flaps can be used such as a fibular with an anterolateral thigh flap, but this lengthens the operating time, and increases morbidity and complications.

A deep circumflex iliac artery flap (**DCIA**) flap is a good single flap option in these circumstances. [35] DCIA flap, a composite osteomusculocutaneous flap of the iliac crest, abdominal wall musculature and overlying skin, has evolved significantly during the previous 30 years since its inception in the late 1970s. With an increasingly reported role for a range of facial, lower limb, and upper limb reconstructions, its most widespread utility has been for hemimandibular defect reconstruction. Furthermore, the iliac crest has long been used for these various bony reconstructions, its versatility as a composite flap has largely been limited by an understanding of the finer vascular anatomy of the region. Initial attempts to harvest the iliac crest flap using the superficial circumflex iliac artery as its vascular supply in 1978 met with less than ideal results. Although greater success was achieved with the DCIA pedicle flap after the landmark report by Taylor and Townsend in 1979, detailing the DCIA as the main blood supply to the iliac crest, a lack of familiarity with the DCIA perforators in these early studies limited the use of the DCIA flap as a composite flap. [36]

7.1. Flap anatomy

Vessel branches supplying the flap are the ascending branch, which supplies the internal oblique muscle, nutrient endosteal perforators, and periosteal contributions to the iliac crest, and musculocutaneous perforators which supply the overlying skin. The dominant blood supply to the iliac crest flap is provided by deep circumflex iliac (DCIA) artery (length=9 cm and diameter=2.8 mm). The DCIA generally arises deep to the inguinal ligament from the

femoral artery or the external iliac artery deep to the inguinal ligament or less frequently from the external iliac artery superior to the inguinal ligament. Venous drainage of the flap is to the deep circumflex iliac vein. This flap does not have a motor reinnervation. Sensory nerve comes from T12 (Figure 10). [37]

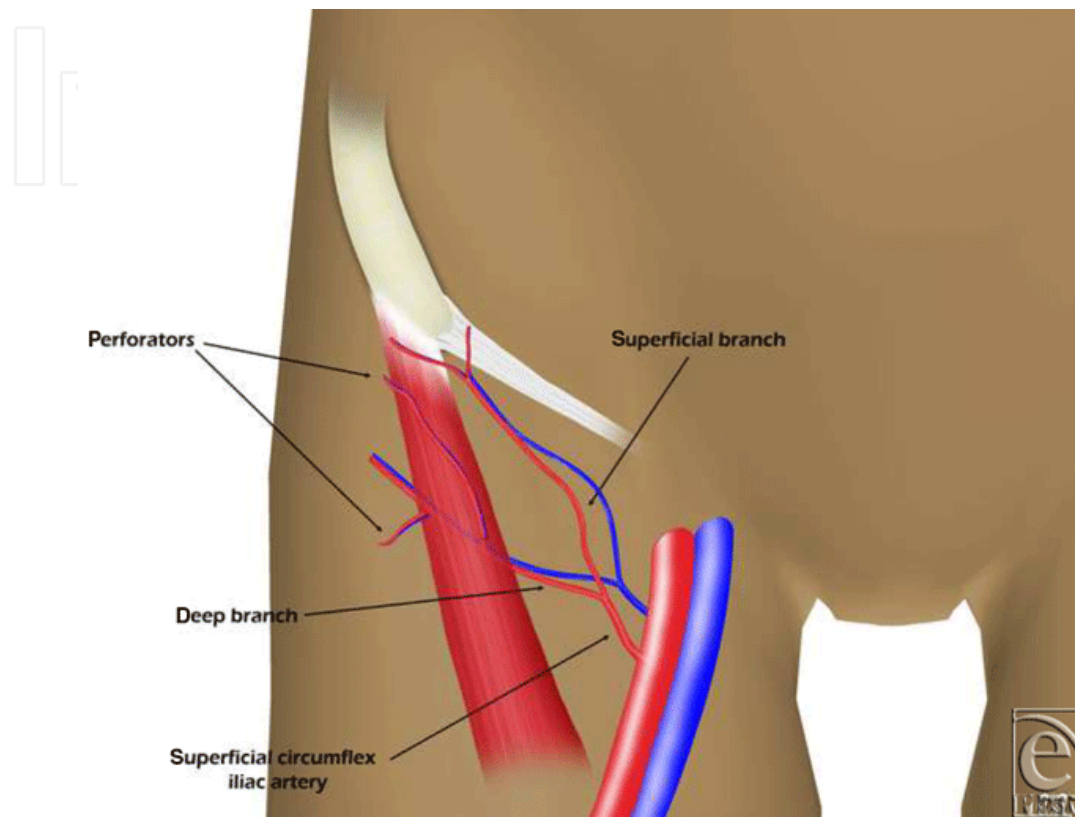


Figure 10. Anatomy of the DCIA flap

7.2. Flap components

The iliac crest flap provides for a great many options in flap composition. It may be harvested as a bone-only or a composite flap, which may include muscle, fascia, fat and skin.

7.3. Flap dimensions

Skin island length commonly is 15 cm and its width 8-10 cm with variable thicknesses. The bony part length is commonly 7 cm and its height 4 cm with 1 cm thickness.

7.4. A common deep circumflex iliac artery flap harvesting technique

An incision is first made 2 cm above the mid-point of the line between the anterior superior iliac spine and the pubic tubercle to identify the origin of the deep circumflex iliac artery; dissection is performed following the course of the deep circumflex artery. Around the anterior superior iliac spine, one can find the ascending branch arise to enter the abdominal muscula-

ture, which is dissected free as a backup vessel. The insertion of the abdominal musculature to the inner lip of the iliac bone is detached, with a small muscular cuff preserved between the deep circumflex artery and the iliac crest to protect the minute osteomusculocutaneous branches entering the inner cortex. After detachment of the abdominal musculature along the superior edge of the iliac crest is performed for about 6.5 cm, the deep circumflex artery can be found to sweep medially upward into the abdominal musculature, ending as a musculocutaneous perforator, nourishing the overlying skin. Meticulous dissection is performed to isolate the vascular pedicle from the abdominal musculature; the skin paddle is centered on the perforator with the previous incision along the iliac crest as the inferolateral margin of the cutaneous flap; finally the flap is harvested to the actual need. [38]

7.5. Complications

Bulky skin paddle may result in poor cosmetic or functional outcomes. A hernia or abdominal contour deformity can occur in 10% of patients. [37] Postoperative sequelae include injury to the lateral femoral cutaneous and ilioinguinal nerves, which can produce unpleasant dysesthesia or anesthesia. [13] The incidence of gait disturbance and chronic hip pain after the flap harvesting may be greatly decreased by preserving the anterior superior iliac spine and using unicortical bone flap.

7.6. Deep circumflex iliac artery flap updates

A free vascularized iliac bone flap based on superficial circumflex iliac perforators (SCIPs) has been introduced. Compared with a conventional iliac bone flap, which is based on deep circumflex iliac vessels, this flap is less invasive, less bulky and can include a reliable skin island. In addition, an SCIP-deep inferior epigastric perforator (DIEP) bipedicle soft-tissue flap has been developed, which can contribute to safe transfer of larger DIEP flaps.[39] An anatomical study described variations in DCIA flap. The origin of the DCIA was 5.30 ± 6.22 mm (mean \pm SD) superior to the inguinal ligament, and the DCIV was 4.75 ± 3.14 mm medial to the origin of the DCIA. The length of the DCIA from its origin to the level of the anterior superior iliac spine was 59.35 ± 9.06 mm, and the vertical distance between the anterior superior iliac spine and DCIA was 18.50 ± 3.82 mm. With regard to the branching pattern of the ascending branch, most cases ($n = 18, 90\%$) exhibited 1 origin and 2 branches, and the remaining 2 cases (10%) had 2 origins and 2 branches. The distance from the DCIA origin to the branch point in cases exhibiting 1 origin and 2 branches was 36.83 ± 16.10 mm. [40]

8. Scapular flap

The scapular region is an excellent source of cutaneous, fascial, muscular, osteomuscular-cutaneous free or pedicled flaps based on the subscapular artery and its branches. In 1978, the scapular free flap was introduced by Sajio. The flap was based on the circumflex scapular vessels. These vessels supply the vast thoracodorsal fascial network of the back, which provide an abundant tissue source beyond the flap margin. The scapular osteocutaneous free flap has

been used mostly in reconstruction of craniomaxillofacial defects, including the orbit, the maxilla and palatal defects. [13] Scapular bone provides thin bone for restoring orbital floor defects in conjunction with malar regions, orbital rim and alveolar defects.

8.1. Flap anatomy

The subscapular artery gives rise to the circumflex scapular artery supplying the scapular and parascapular skin. The superficial branch of the circumflex scapular artery reaches the subcutaneous tissue at the level of the triangular space. At this point it provides several branches. The main two branches are the horizontal and vertical ones. [41] Venae comitantes of the horizontal and vertical branches of the circumflex scapular vein are the venous drainages of the flap. The horizontal and vertical branches drain into the circumflex scapular vein, then the subscapular vein and finally the axillary vein. The third, fourth and fifth intercostal nerves through lateral and posterior branches provide sensory innervation of this region. There is no motor nerve involvement in this procedure (Figure 11).

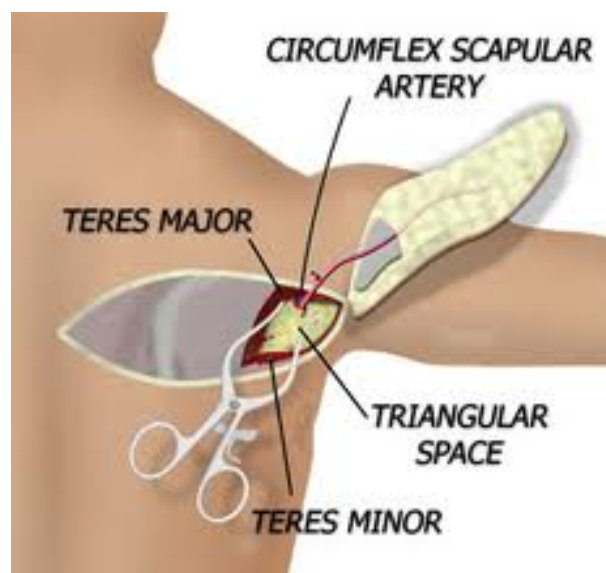


Figure 11. Anatomy of the scapular flap.

8.2. Flap components

This is a skin and subcutaneous flap which may include bone, fascia and muscle. These flaps are extremely reliable with a consistent vascular pedicle of good length and large caliber. The color of the back skin may provide a better match for head and neck reconstruction.

8.3. Flap dimensions

Skin island length is 18-20 cm with 7-8 cm width and 2 cm thickness. The bone length is about 10-14 cm with 2-3 cm width and 1.5-3 cm thickness.

8.4. A common scapular flap harvesting technique

The site of flap incision is infiltrated with lidocaine with 2% epinephrine. The outline of skin paddle is marked. It is important to mark the location of the flap on the patient's back relative to flap size, and to mark the orientation relative to the pedicle and its branches. An incision is made from the posterior border of the deltoid muscle 3 cm lateral and parallel to the lateral border of the scapula, ending approximately at the angle. The dissection of the cutaneous flap is extended medially in a plane just superficial to the deep muscular fascia of the infraspinatus muscle. The thoracodorsal fascia is preserved during dissection. The circumflex vessels arise sharply over the lateral edge of the scapula and are just superficial to the facial base of dissection. [13] The lateral scapular bone flap and the branches to the bone from the pedicle are carefully dissected and preserved in the triangular space. An incision is made 2 to 3 cm medial to the bone edge through the muscles on the scapula inferior to the bone. If a bipedicle bone flap is desired with 2 vascular sources on the same pedicle, in this situation the angular branch from thoracodorsal vessel should be included in the flap design. The donor site is closed primarily, with the use of appropriate drain placement and the patient is turned to the supine position (Figure 12).

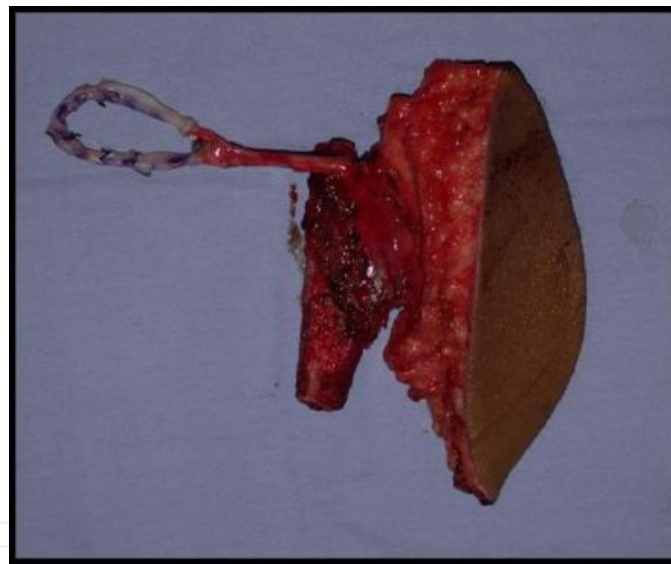


Figure 12. A skin paddle of the scapular flap.

8.5. Complications

Extended scapular flap loss is a major problem because a large area remains uncovered. Closure of the donor site under tension will result scar dehiscence and an unsightly result.

8.6. Scapular flap updates

The scapular tip free flap (STFF) has been used in reconstruction of mandibular defects. Low morbidity, early ambulation time, possibility of simultaneous harvesting with the tumor

resection and large musculocutaneous paddles in the chimerical version of the flap are advantages of the STFF. This makes it a good choice in elderly patients, when other bone containing free flaps are not indicated because of the related morbidity, when other flaps are not available or when wide composite defects are approached.[42] Fibular and scapular osseous free flaps for oromandibular reconstruction were compared based on a patient-centered approach to flap selection. Results demonstrated the free fibula flaps and subscapular flaps are complementary options for oromandibular reconstruction. The fibular free flaps are ideal for younger patients, extended defects, multiple osteotomies, and limited soft-tissue requirements. The subscapular system free flaps are excellent options for (1) elderly patients; (2) those with significant comorbidities, such as peripheral vascular disease; and (3) mandible defects associated with complex soft-tissue requirements.[43] For immediate mandibular reconstruction, a scapular flap provides short-term results equivalent to those with a fibular flap but with less donor-site morbidity. The major drawbacks of the fibular flap include prolonged healing of the donor site and the delayed mobilization of patients. Although our first choice of vascularized bone graft is the fibular flap, the scapular flap is an alternative for those patients, especially elderly patients, in whom fibula harvest can result in significant morbidity. [44] Minimally invasive harvesting techniques may reduce potential donor-site morbidity. A reverse-flow scapular osteocutaneous flap has been introduced for head and neck reconstruction. The distal end of the thoracodorsal artery and subscapular vein were used in this type of the flap. There has been no report on endoscopically assisted harvesting of the scapular adipofascial flap. [45, 46]

Author details

Reza Tabrizi^{1*} and Barbad Zamiri²

*Address all correspondence to: tabmed@gmail.com

1 Assistant Professor, Department of Oral and Maxillofacial Surgery, Shahid Beheshti University of Medical Sciences School of Dentistry, Shiraz, Iran

2 Associated Professor, Department of Oral and Maxillofacial Surgery, Shiraz University of Medical Sciences School of Dentistry, Shiraz, Iran

References

- [1] Jones, N.F. and B.C. Sommerlad, Reconstruction of the zygoma, temporo-mandibular joint and mandible using a compound pectoralis major osteo-muscular flap. *Br J Plast Surg*, 1983. 36(4): p. 491-7.

- [2] Hidalgo, D.A., A.L. Pusic, and F.-C. Wei, Free-flap mandibular reconstruction: a 10-year follow-up study. *Plastic and reconstructive surgery*, 2002. 110(2): p. 438-449.
- [3] Fu-Chan Wei, S.S., Principle and Techniques of microvascular surgery. Plastic surgery. Saunders-Elsevier 2006. 1: p. 507-538.
- [4] Krizek, T.J., et al., Experimental transplantation of composite grafts by microsurgical vascular anastomoses. *Plastic and reconstructive surgery*, 1965. 36(5): p. 538-546.
- [5] Jason A.Spector, J.P.L., cutaneous defects :Flaps,Grafts,and Expansion. *Current Therapy in plastic surgery*,Saunders,Elsevier, 2006: p. 11-21.
- [6] Nandra, B. The Maximum length of free bone grafts for Mandibular reconstruction- Are bone grafts greater than 6.0 cm more susceptible to infection and exposure? in 2014 Annual Meeting. 2014. Aaoms.
- [7] Moscoso, J.F., et al., Vascularized bone flaps in oromandibular reconstruction: a comparative anatomic study of bone stock from various donor sites to assess suitability for osseous dental implants. *Archives of Otolaryngology-Head & Neck Surgery*, 1994. 120(1): p. 36-43.
- [8] Frodel, J.L., et al., Osseointegrated implants: a comparative study of bone thickness in four vascularized bone flaps. *Plastic and reconstructive surgery*, 1993. 92(3): p. 449-455.
- [9] Beckers, A., et al., Comparative densitometric study of iliac crest and scapula bone in relation to osseous integrated dental implants in microvascular mandibular reconstruction. *Journal of Cranio-Maxillofacial Surgery*, 1998. 26(2): p. 75-83.
- [10] Disa, J.J., et al., Simplifying microvascular head and neck reconstruction: a rational approach to donor site selection. *Annals of plastic surgery*, 2001. 47(4): p. 385-389.
- [11] Suh, J.D., et al., Analysis of outcome and complications in 400 cases of microvascular head and neck reconstruction. *Archives of Otolaryngology-Head & Neck Surgery*, 2004. 130(8): p. 962-966.
- [12] Mathes JS, H.S., Flap classification and application. *Plastic surgery*. Saunders-Elsevier, 2006. 1: p. 365-481.
- [13] Quershy FA, P.M., Reconstruction of the maxillomandibular cancer patient. *Fonseca oral and maxillofacial surgery*,Saunders, 2000. 7: p. 361-444.
- [14] S.Souter, D., Radial forearm flap. *Flaps and reconstruction surgery*,Saunders-Elsevier, 2009(25): p. 321-338.
- [15] Soutar, D., et al., The radial forearm flap: a versatile method for intra-oral reconstruction. *British Journal of Plastic Surgery*, 1983. 36(1): p. 1-8.

- [16] Santamaria, E., M. Granados, and J.L. Barrera-Franco, Radial forearm free tissue transfer for head and neck reconstruction: versatility and reliability of a single donor site. *Microsurgery*, 2000. 20(4): p. 195-201.
- [17] Avery, C., Review of the radial free flap: is it still evolving, or is it facing extinction? Part one: soft-tissue radial flap. *British Journal of Oral and Maxillofacial Surgery*, 2010. 48(4): p. 245-252.
- [18] Avery, C., Review of the radial free flap: still evolving or facing extinction? Part two: osteocutaneous radial free flap. *British Journal of Oral and Maxillofacial Surgery*, 2010. 48(4): p. 253-260.
- [19] Dolan, R., *Microvascular surgery. Lore and Medina, An atlas of head and neck surgery*, Saunders-El, 2005: p. 1417-1470.
- [20] Skoner, J.M., et al., Short-Term Functional Donor Site Morbidity After Radial Forearm Fasciocutaneous Free Flap Harvest. *The Laryngoscope*, 2003. 113(12): p. 2091-2094.
- [21] Sardesai, M.G., et al., Donor-site morbidity following radial forearm free tissue transfer in head and neck surgery. *Journal of otolaryngology-head & neck surgery= Le Journal d'oto-rhino-laryngologie et de chirurgie cervico-faciale*, 2008. 37(3): p. 411-416.
- [22] Ahuja, R.B., P. Chatterjee, and P. Shrivastava, A novel route for placing free flap pedicle from a palatal defect. *Indian journal of plastic surgery: official publication of the Association of Plastic Surgeons of India*, 2014. 47(2): p. 249.
- [23] Silberstein, E., et al., Total Lip Reconstruction with Tendinofasciocutaneous Radial Forearm Flap. *The Scientific World Journal*, 2014. 2014.
- [24] Hanna, T.C., W.S. McKenzie, and J.D. Holmes, Full-Thickness Skin Graft from the Neck for Coverage of the Radial Forearm Free Flap Donor Site. *Journal of Oral and Maxillofacial Surgery*, 2014.
- [25] Chung, J., et al., The effect of topically applied tissue expanders on radial forearm skin pliability: a prospective self-controlled study. *Journal of Otolaryngology-Head & Neck Surgery*, 2014. 43(1): p. 8.
- [26] Wester, J.L., et al., AlloDerm with split-thickness skin graft for coverage of the forearm free flap donor site. *Otolaryngology--Head and Neck Surgery*, 2014. 150(1): p. 47-52.
- [27] Vittayakittipong, P., Donor-site morbidity after fibula free flap transfer: a comparison of subjective evaluation using a visual analogue scale and point evaluation system. *International journal of oral and maxillofacial surgery*, 2013. 42(8): p. 956-961.
- [28] Christopher J.Salgado, S.L.M., Samir Mardani, Fu-chan Wei, *Fibula flap*. 1th edition ed. 2009: Saunders, Elsevier 439-455.

- [29] Blackwell, K.E., Donor site evaluation for fibula free flap transfer. *American journal of otolaryngology*, 1998. 19(2): p. 89-95.
- [30] Bodde, E.W., et al., Donor-site morbidity after free vascularized autogenous fibular transfer: subjective and quantitative analyses. *Plastic and reconstructive surgery*, 2003. 111(7): p. 2237-2242.
- [31] Potter, J.K., et al., Proximal Peroneal Perforator in Dual-Skin Paddle Configuration of Fibula Free Flap for Composite Oral Reconstruction. *Plastic and reconstructive surgery*, 2014. 133(6): p. 1485-1492.
- [32] Spinelli, G., et al., Microsurgical Reconstruction After Bisphosphonate-Related Osteonecrosis of the Jaw: Our Experience With Fibula Free Flap. *Journal of Craniofacial Surgery*, 2014. 25(3): p. 788-792.
- [33] Pitak-Arnnop, P., et al., Fibular flap for mandibular reconstruction: Are there old tricks for an old dog? *Revue de stomatologie, de chirurgie maxillo-faciale et de chirurgie orale*, 2013. 114(1): p. 15-18.
- [34] Chao, J.W., et al., Oral Rehabilitation Outcomes After Free Fibula Reconstruction of the Mandible Without Condylar Restoration. *Journal of Craniofacial Surgery*, 2014. 25(2): p. 415-417.
- [35] Bisase, B., et al., The deep circumflex iliac artery perforator flap (DCIAP)—A reconstructive option for the large composite oro-mandibular cutaneous defect. *British Journal of Oral and Maxillofacial Surgery*, 2013. 51(8): p. 962-964.
- [36] Ting, J., et al., Developments in image-guided deep circumflex iliac artery flap harvest: a step-by-step guide and literature review. *Journal of oral and maxillofacial surgery*: 2014. 72(1): p. 186-197.
- [37] Elisabeth K.Beahm, M.M., Hanasono,Saleh Shenaq, *Flaps and reconstruction surgery,Iliac Flap*. 2009: Saunders,Elesiever 339-357.
- [38] Zheng, H.-P., et al., Modified deep iliac circumflex osteocutaneous flap for extremity reconstruction: Anatomical study and clinical application. *Journal of Plastic, Reconstructive & Aesthetic Surgery*, 2013. 66(9): p. 1256-1262.
- [39] Iida, T., et al., A free vascularized iliac bone flap based on superficial circumflex iliac perforators for head and neck reconstruction. *Journal of Plastic, Reconstructive & Aesthetic Surgery*, 2013. 66(11): p. 1596-1599.
- [40] Kim, H.-S., et al., Anatomical basis of the deep circumflex iliac artery flap. *Journal of Craniofacial Surgery*, 2013. 24(2): p. 605-609.
- [41] Claudio Angrigiani, J.P., Marcelo MackFarlane *Fapls and reconstruction surgery,Scapular and parascapular flap*. 2009: Saunders,Elsevier. 271-285.
- [42] Bianchi, B., et al., Reconstruction of mandibular defects using the scapular tip free flap. *Microsurgery*, 2014.

- [43] Dowthwaite, S.A., et al., Comparison of fibular and scapular osseous free flaps for oromandibular reconstruction: a patient-centered approach to flap selection. *JAMA Otolaryngology–Head & Neck Surgery*, 2013. 139(3): p. 285-292.
- [44] Fujiki, M., et al., A comparison of perioperative complications following transfer of fibular and scapular flaps for immediate mandibular reconstruction. *Journal of Plastic, Reconstructive & Aesthetic Surgery*, 2013. 66(3): p. 372-375.
- [45] Al-Benna, S., J.J. Kirkpatrick, and I. Taggart, Minimally Invasive Harvesting of Adipofascial Scapular Flaps. *Annals of plastic surgery*, 2014. 72: p. 666-669.
- [46] Zevallos, J.P. and M.L. Urken, Reverse-flow scapular osteocutaneous flap for head and neck reconstruction. *Head & neck*, 2013. 35(6): p. E171-E174.