

# We are IntechOpen, the world's leading publisher of Open Access books Built by scientists, for scientists

6,900

Open access books available

185,000

International authors and editors

200M

Downloads

Our authors are among the

154

Countries delivered to

TOP 1%

most cited scientists

12.2%

Contributors from top 500 universities



WEB OF SCIENCE™

Selection of our books indexed in the Book Citation Index  
in Web of Science™ Core Collection (BKCI)

Interested in publishing with us?  
Contact [book.department@intechopen.com](mailto:book.department@intechopen.com)

Numbers displayed above are based on latest data collected.  
For more information visit [www.intechopen.com](http://www.intechopen.com)



---

# Reconstruction of Facial Hair Bearing Areas in the Male Patient

---

Shahram Nazerani

Additional information is available at the end of the chapter

<http://dx.doi.org/10.5772/59191>

---

## 1. Introduction

Hair bearing regions of the face have been the hallmarks of Manhood through the ages and the defects of these regions are psychologically traumatizing and sometimes demeaning for the male patients in several cultures. The reconstruction of these areas is very difficult due to scarcity of donor areas and the available donors such as scalp have anatomically different hair morphology and the hair follicles' proximity is quite different from the face, on the other hand the facial skin thickness and texture is another matter of concern making a "look alike" reconstruction almost impossible. In this chapter we will try to address this difficult reconstruction challenge.

### 1.1. Terminology

In humans, usually only pubescent or adult males are able to grow beards. [1, 2]

**The Beard or Barba** is defined as:

1. The hair on a man's chins, cheeks, and throat.
2. A hairy or hair like growth such as that on or near the face of certain mammals.

**Moustache or Mustache** refers to:

1. The unshaved growth of hair above the upper lip and sometimes down the sides of the mouth, especially when grown and groomed.
2. Something similar to the grown and groomed hair above the human upper lip

## 1.2. Historical background [3]


Throughout the course of history, societal attitudes towards male beards have varied depending on factors such as prevailing cultural-religious traditions and the fashion trends. Some religions (such as Islam and Sikhism and Judaism) have always considered a full beard to be absolutely essential for all males able to grow one. [4]

### 1.2.1. Ancient Egypt [3]

The highest ranking Ancient Egyptians grew hair on their chins which was often dyed or hennaed (reddish brown) and sometimes plaited with interwoven gold thread. A metal false beard, or postiche, which was a sign of sovereignty, was worn by queens and kings. This was held in place by a ribbon tied over the head and attached to a gold chin strap, a fashion existing from about 3000 to 1580 BC. [5] Mesopotamian civilizations (Sumerian, Assyrians, Babylonians, Chaldeans and Medians) devoted great care to oiling and dressing their beards, using tongs and curling irons to create elaborate ringlets and tiered patterns.

### 1.2.2. Ancient Iran [3]

The Iranians (Persians) were fond of long beards (Figure 1), and almost all the Iranian kings had a beard. In *Travels* by Adam Olearius, a King of Iran commands his steward's head to be cut off, and on its being brought to him, remarks, "what a pity it was, that a man possessing such fine mustachios, should have been executed." Men in the Achaemenid era wore long beards, with warriors adorning theirs with jewelry. Men also commonly wore beards during the Safavid and Qajar eras. [6]



**Figure 1.** A 19<sup>th</sup> century painting of an Old Persian man after lunch, note the full beard.

### 1.2.3. Ancient Macedonia [3]

At the time of Alexander the Great the custom of smooth shaving was introduced. [7, 8] Reportedly, Alexander ordered his soldiers to be clean-shaven, fearing that their beards would serve as handles for their enemies to grab and to hold the soldier as he was killed. The practice of shaving spread from the Macedonians, whose kings are represented on coins, etc. with smooth faces, throughout the whole known world of the Macedonian Empire (Figure 2).



**Figure 2.** A coin depicting a cleanly shaven Alexander the Great.

Laws were passed against it, without effect, at Rhodes and Byzantium; and even Aristotle conformed to the new custom, unlike the other philosophers, who retained the beard as a badge of their profession. A man with a beard after the Macedonian period implied a philosopher, and there are many allusions to this custom of the later philosophers in such proverbs as: "The beard does not make the sage." [9]

### 1.2.4. Ancient Rome 3

Shaving seems to have not been known to the Romans during their early history (under the Kings of Rome and the early Republic). Pliny tells us that Ticinius was the first who brought a barber to Rome, which was in the 454th year from the founding of the city (that is, around 299 BC). Scipio Africanus was apparently the first among the Romans who shaved his beard. However, after that point, shaving seems to have caught on very quickly, and soon almost all Roman men were clean-shaven; being clean-shaven became a sign of being Roman and not Greek. Only in the later times of the Republic did the Roman youth begin shaving their beards only partially, trimming it into an ornamental form; prepubescent boys oiled their chins in hopes of forcing premature growth of a beard. [10]

### 1.2.5. *The middle ages [3]*

In the middle ages, the beard had still an important role, figure 3 depicts the picture of El Cid or “The Mister” in Arabic. (Figure 3). [11]



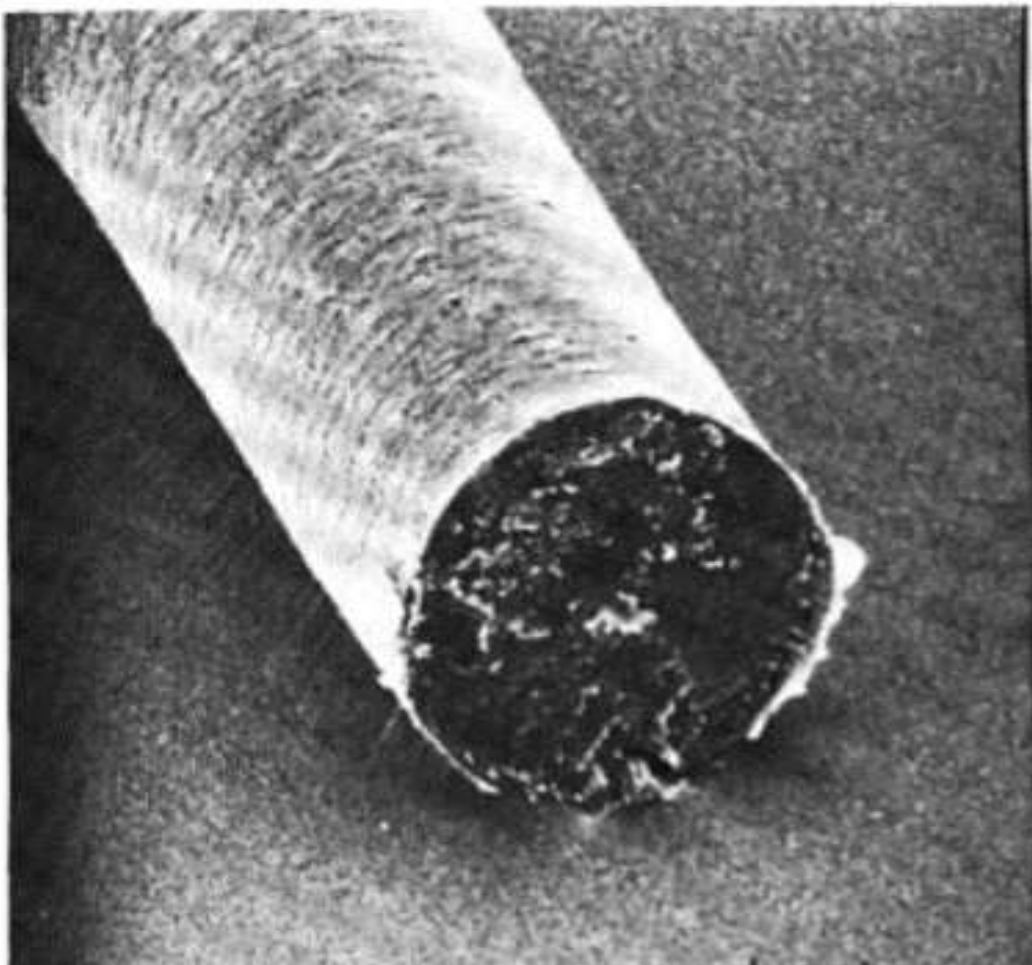
**Figure 3.** Charles IV, Holy Roman Emperor.

While most noblemen and knights were bearded, the Catholic clergy were generally required to be clean-shaven. This was understood as a symbol of their celibacy. By the early 20th century beards began a slow decline in popularity. Although retained by some prominent figures who were young men in the Victorian period (like Sigmund Freud), most men who retained facial hair during the 1920s and 1930s limited themselves to a moustache or a goatee (such as with Marcel Proust, Albert Einstein, Vladimir Lenin, Leon Trotsky, Adolf Hitler, and Joseph Stalin). In America, meanwhile, popular movies portrayed heroes with clean-shaven faces and "crew cuts". Concurrently, the psychological mass marketing of companies like Gillette popularize short hair and clean shaven faces as the only acceptable style for decades to come. Those who grow beards are frequently either old, Central Europeans, members of a religious sect that require it or those who are in academia.

### 1.3. **Modern prohibition of beards [3]**

Professional airline pilots are required to be clean shaven to facilitate a tight seal with auxiliary oxygen masks. Similarly, firefighters may also be prohibited from full beards to obtain a proper seal with equipment. This restriction is also fairly common in the oil and gas industry for the same reason in locations where hydrogen sulfide gas is a common danger. Other jobs may prohibit beards as necessary to wear masks or respirators. [12] Isezaki city in Gunma, Japan,





**Figure 4.** An Asian scalp hair, note the roundness of the hair, reprinted by permission of The Society of Cosmetic Chemists

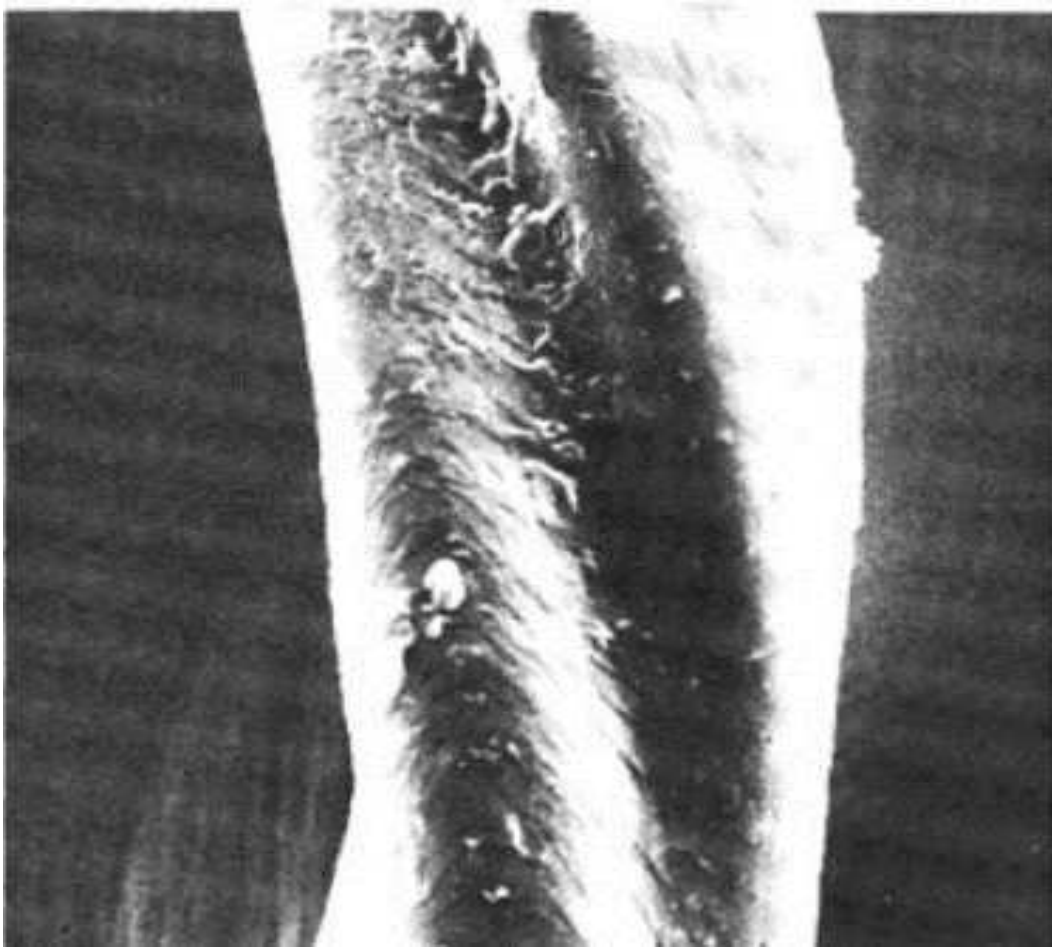
decided to ban beards for male municipal employees on May 19, 2010. [13] Brigham Young University generally requires its students and employees to be clean-shaven. However, Brigham Young himself was often seen with a beard. [14]

## **2. Anatomy and physiology of facial hair**

Human hair has been categorized into three ethnic groups according to distinguishable characteristics: Asian, Caucasian, and African hair. These ethnic groupings show distinct characteristics in hair density, diameter, shape, mechanical properties and composition. [15]

The hair follicle itself determines the appearance of the hair. The typical hair follicle of Asian hair is round (Figures 4 and 5), whereas those of Caucasians and Africans are ovoid and elliptical, respectively. [16]

The shape of the hair follicle is thus believed to contribute to the appearance and the geometry of the hair. Asian hair has a circular geometry, African hair has an elliptical shape, and hair of




**Figure 5.** Asian beard hair, note the different contour of the beard hair from scalp hair, reprinted by permission of The Society of Cosmetic Chemists

Caucasians is of an intermediate shape. The chemical and protein composition of hair does not vary across ethnic groups, and there is no difference in the keratin types. However, African hair generally has less tensile strength and breaks more easily.

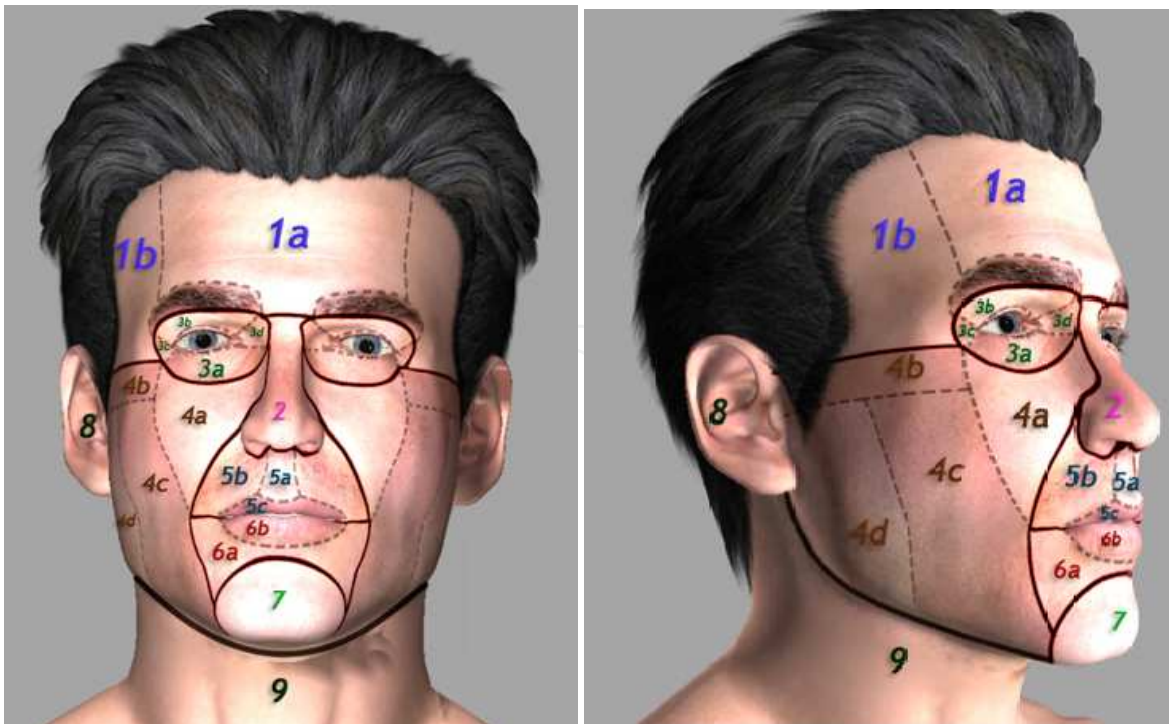
### 3. The units of the face

The face consists of 6 major aesthetic units comprised of: forehead, eye/eyebrow, nose, lips, chin, and cheek. These aesthetic units can be subdivided into additional anatomical subunits. For example, the nose can be divided into nasal tip, dorsum, columella, soft-tissue triangles, sidewalls, and nasal alar regions. Correct orientation of planned incisions next to these mobile functional and aesthetic facial structures is important to avoid distortion when closing wounds.

In this chapter we focus on the hair bearing units of the male face which are designated as the mustache and beard namely units 4c, d, 5a, b, 7 and some part of unit 9 in the neck (Figures 7 and 8).

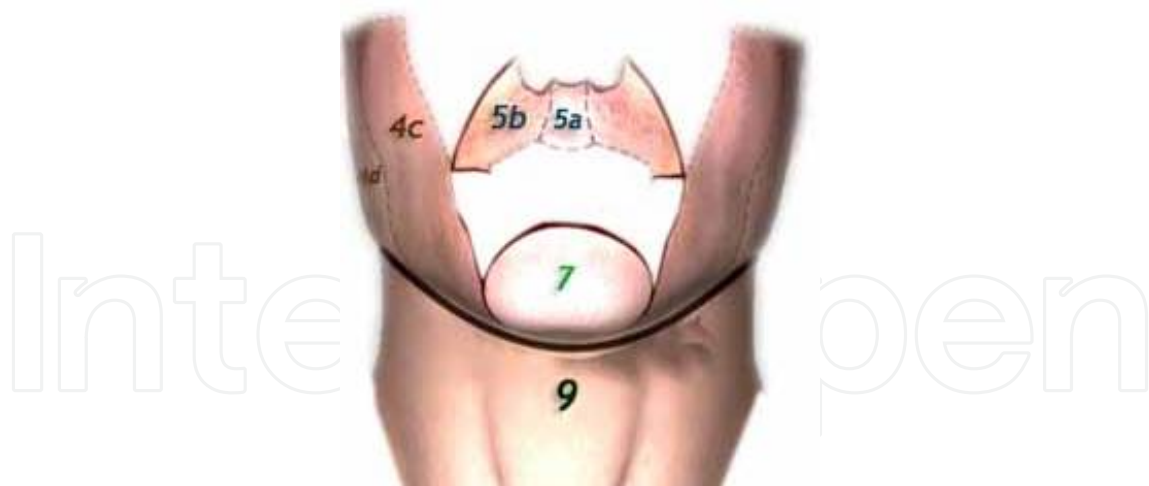


**Figure 6.** Comparison of the cuticular patterns of scalp and beard hair, reprinted by permission of The Society of Cosmetic Chemists



**Figure 7.** The human face units, used by permission of author Davide Brunelli M.D, [www.med-ars.it](http://www.med-ars.it)





**Figure 8.** The hair bearing units in the male face, used by permission of author Davide Brunelli M.D, [www.med-ars.it](http://www.med-ars.it)



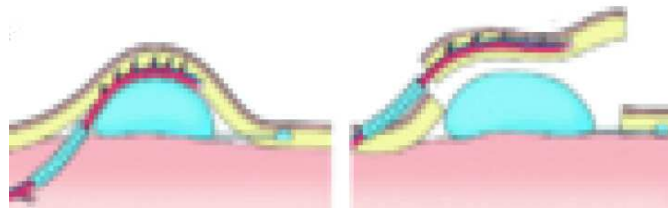
**Figure 9.** The mustache unit, used by permission of the author Davide Brunelli M.D, [www.med-ars.it](http://www.med-ars.it)

### 3.1. The Mustache

Loss of the mustache in the male patient causes cosmetic and psychological problems. The mustache also has the ability to cover the perioral scars and defects and is favored by the patients with scars around the mouth and upper lip such as cleft lip patients (Figure 9).

Full thickness defects of the units 5a and b or upper lip area in addition to esthetically unappealing elicit the functional problems such as drooling, speech disorders and poor oral hygiene, the partial thickness defects are more of an esthetic nature with asymmetrical structure.

The two potential sources of hair-bearing skin are the bearded face, neck and the scalp. The texture, hair bearing quality, and color match make local beard skin on the face a preferable donor site, but this is possible only for relatively small defects; otherwise, the resulting scar at the donor site is unacceptable. In these cases, local advancement or V-Y advancement flaps are



**Figure 10.** Flap prefabrication stages, vascular pedicle transferred under the skin paddle and the pedicle is wrapped by either Gore-Tex or silicone and a tissue expander is inserted for expansion, after proper expansion the flap is transferred as a free or island flap. The prelaminated flap can then be transferred to reconstruct the mustache or beard area. [23] Distant pedicled scalp flaps such as the extended midline forehead flap, transposition or island scalp flap, and bipedicle visor flap are other viable options.

used. Tissue expansion of this hair-bearing region to increase the surface area of the bearded face with Abbe and submental flaps have been described to bring hair-bearing tissue to the upper lip from the lower lip and bearded face and vice versa. [17] However, one must note the difference in hair distribution in the upper and lower lips when planning this flap.

The submental island flap reported by Martin et al is another source of hair bearing tissue with acceptable donor scar. [18]

The hair follicle match of the submental area is excellent and the follicle orientation is also correct, this flap can be transferred as a bipedicle type with limited arc of rotation and several other flap types reported by Tsur and Hyakusoku. [19]-[22]

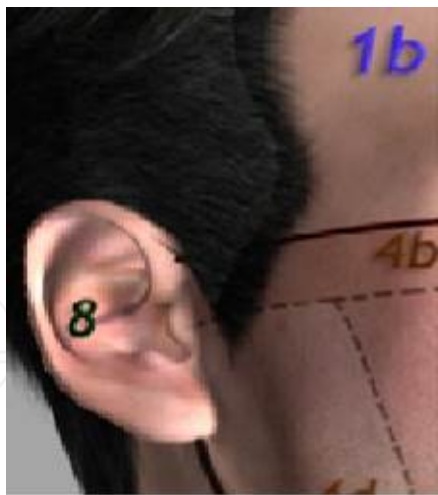
The main drawback of submental flap is the need for several revision procedures, which have the potential risk of Alopecia due to too much thinning of the flap or damaging the vascular supply of the flap. [17, 22]

The flap prelamination is another option, in this technique a vascular pedicle is transposed under a random pattern flap and after maturation this composite tissue is transferred, it has some drawbacks such as the need for microvascular expertise and the potential risk of peripheral flap failure. (Figure 10)

### 3.2. Beard and Sideburns

The male bearded region can be subdivided into a preauricular zone, which includes the sideburn and the buccomandibular zone (Figure 11).

The sideburn is an important anatomical structure determining the boundary between the head and the face and providing an aesthetic reference for balanced facial symmetry. The normal sideburn dimensions have been well described by Giraldo. [24] The sideburn shape is largely rectangular or trapezoidal. According to Juri, the most frequent causes for absence of the sideburn are trauma, burns, surgery, and infection. [25] Small defects within or involving the sideburn can be reconstructed with a single V-Y flap, opposing V-Y flaps, extended V-Y flaps, or double extended V-Y flaps. V-Y flaps are designed within hair-bearing regions and non-hair-bearing regions according to the characteristics of the tissue to be replaced. Additional options for sideburn reconstruction include a scalp transposition flap. Larger defects

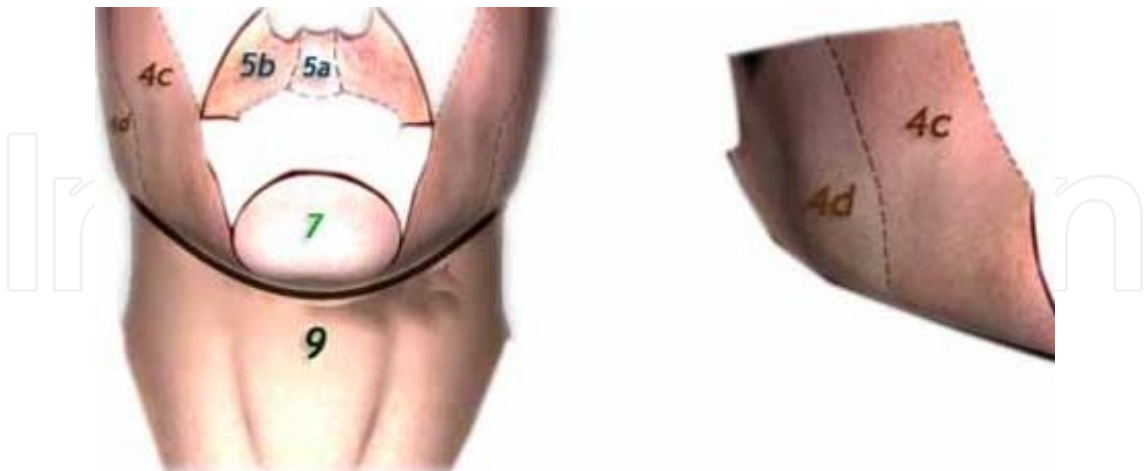


**Figure 11.** The side burn area, used by permission of author Davide Brunelli M.D, [www.med-ars.it](http://www.med-ars.it)

including the sideburn and adjacent cheek or beard region can be reconstructed with a combination of any of these three primary options: the scalp transposition flap, the cervicofacial advancement flap, or the pedicled submental flap.

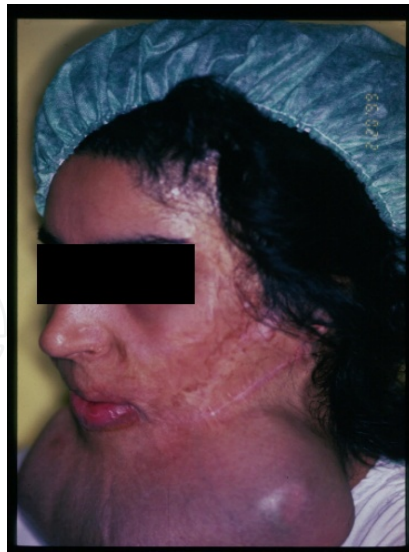**4. Cheek reconstruction**

The cheek provides abundant subcutaneous tissue, which is mobile and has a perfect color match. Because of the laxity of the cheek, adjacent undermining and primary closure can be used to reconstruct many defects. Flaps can be designed within this tissue with minimal distortion to surrounding facial features and minimal dead space (Figure 12).

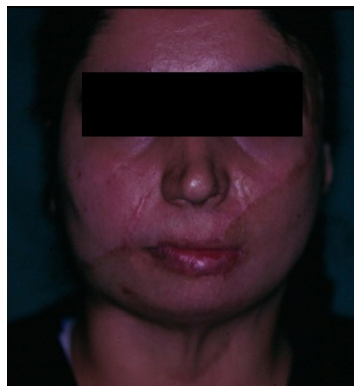


**Figure 12.** The cheek unit with subdivision of c and d, used by permission of author Davide Brunelli M.D, [www.med-ars.it](http://www.med-ars.it)

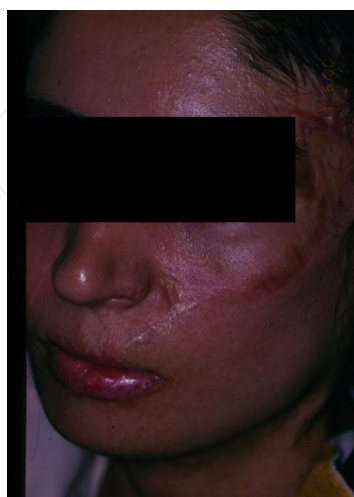In females the face has almost no hair so the reconstruction can begin at a younger age and more donor sites are available than the male patients. In the female neck skin can be expanded and be used to cover the chin and even cheek defects (Figure 13 - 15).



**Figure 13.** Bilateral cheek scars, expanded neck skin via tissue expander

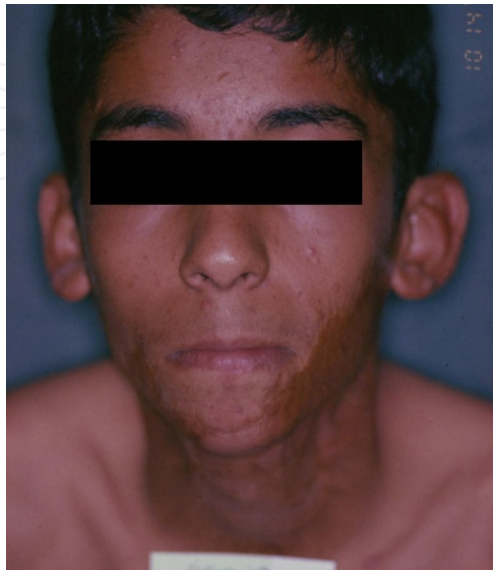


**Figure 14.** Frontal view of the scar after 5 years

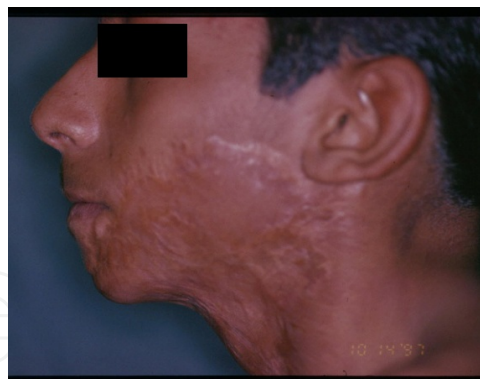

**Figure 15.** Result 8 years postoperatively

In the male child or adolescent, a facial skin defect reconstruction is completely different from females because transferring a hair bearing flap in a child is unsightly and the definite reconstruction of the facial hair bearing areas must be postponed until the patient has grown hair (Figures 16 and 17).



**Figure 16.** A 14-year-old male patient with a unit 4 scar



**Figure 17.** Lateral view of the same patient

## 5. Neck reconstruction

Zone 9 is the neck area contiguous with the chin and if the facial hair is present there is no need to reconstruct this area with hair bearing flaps, in these instances the patient can cover the neck scar with a beard.

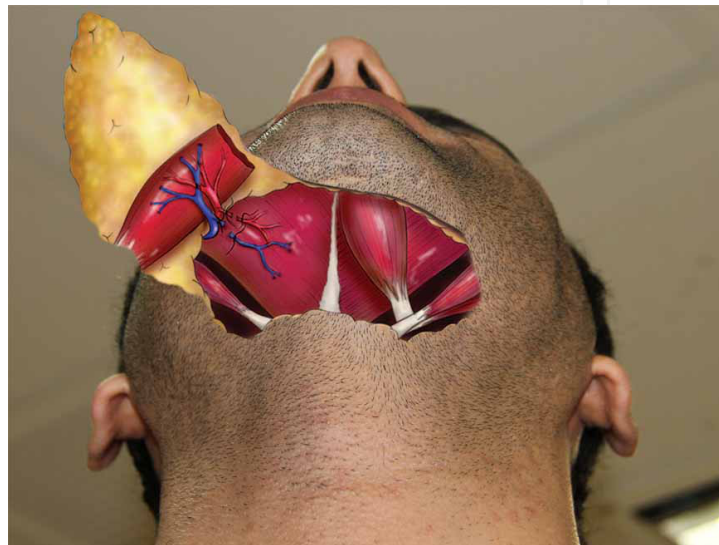


## 6. Available donor sites

### 6.1. Submental island flap

#### 6.1.1. Anatomy

The submental island flap is a fasciocutaneous flap that includes a rhomboid area of skin, subcutaneous tissue, and platysma located below the inferior border of the mandible (Figure 18). This flap was first reported by Martin et al. [26]



**Figure 18.** The submental flap raised on its vascular pedicle

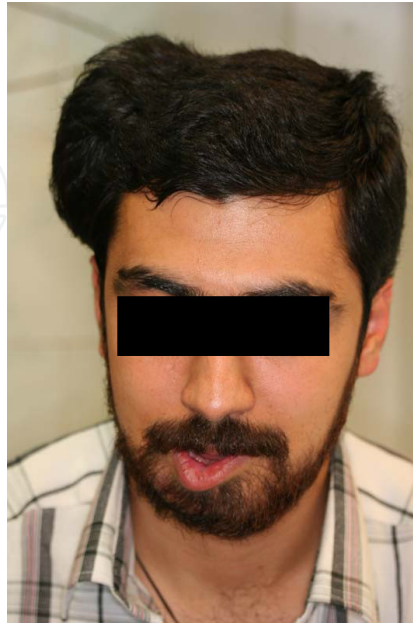Injection studies into the submental artery have found that it can supply a large skin paddle, as large as 10 \_ 16 cm, reaching from one angle of the mandible to the contralateral angle. [27] Although this horizontal dimension includes an area supplied by bilateral submental arteries, the entire flap can be perfused by one side. Practically speaking, the anteroposterior dimension of the skin flap that can be harvested is limited by the ability to achieve primary closure, which depends on the patient's skin laxity and age, which can be estimated by marking out the desired anteroposterior dimension of the flap and attempting to pinch the marks together with forceps.

The locations of the perforator vessels connecting the submental artery to the subdermal plexus (which perfuses the areas listed above) are variable. This flap has a shorter pedicle compared to scalp flaps, is rather thick and arch of rotation or pivot point is short; in the young the donor site scar becomes hypertrophic and in view.

### 6.2. Expanded scalp

The expanded scalp has two benefits namely thinning the density of the hair follicles and also a thinner skin brought in to the defect. These flaps can be transferred as pedicle flaps or free

flaps. [28, 29] The expanded flap can be covered by the scalp hair is not very noticeable until late in expansion (Figure 19).



**Figure 19.** The expander is in place; the patients usually grow hair on the opposite side of the expansion area to compensate.

### 6.3. Visor flap

The frontal visor flap first described by Leon Dufourmental in 1919 has stood the test of time; and with tissue expansion to overcome the donor site morbidity it is the only solution in bilateral facial defects in the male patient. [30] The scalp visor flap has an excellent blood supply, guaranteed by its double pedicle with the two superficial temporal arteries.

### 6.4. Adjacent skin reconstruction, expanded and non-expanded

In small defects it is possible to expand the adjacent skin and reconstruct the defect by the "same skin".

### 6.5. Hair transplantation

Another option for reconstruction of facial hair is Hair Transplantation; there are different techniques of hair transplantation, each with their inherent advantages and disadvantages. The most common and known hair transplantation method is the so-called 'strip' method. [31]

A strip of skin containing hair follicles is removed, cut into grafts and implanted in the recipient area. In the past years, new methods have developed of which the most promising is the follicle unit extraction (FUE). [32] With this method, whole follicle units are extracted one by one and

implanted one by one into the recipient area. Although the FUE method is more patient friendly and leaves only tiny scars compared with the strip method, which leaves visible linear scars at the donor area, the major disadvantage of both methods is that the extracted hair follicles are removed and the source of potential grafts will be consumed in time. The only way to preserve a significant part of the donor hair follicles could be partial FUE. This idea is not unrealistic and is supported by different experiments [33] Reynolds found that, although the dermal papillae of humans cannot induce new hair growth, the sheath of the lower part of the hair follicle can.

The main drawback of hair transplantation is the esthetic result; in a full thickness facial scar with depressed and discolored skin with poor vascularity the result might not be very satisfactory.

Hair transplantation can be very useful in small and patchy hair bearing area defects or as an adjunct operation in the remaining hairless scar.

## 7. Algorithm of treatment

In the female patient the final reconstruction can be done at any time but the male patient's reconstruction should be postponed until the facial hair has grown because a bearded face in a child is not socially acceptable and a non-hair bearing reconstruction of the face in these patients, although reported in the literature, might lead to dissatisfaction in later years.

Although at some point during the treatment of the patients we have combined all the treatment modalities such as covering a flap scar with hair transplantation or combining expansion with adjacent tissue VY or Z plasty I propose an algorithm of treatment based on the face units. There are generally four types of hair bearing area defects:

**Type 1** is a partial unit defect

**Type 2** is total unit defect

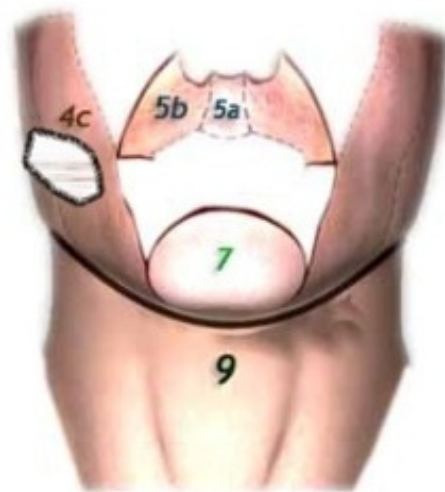
**Type 3** is bilateral or multiple unit defects with two subtypes type 3a: multiple unit and 3b: bilateral

**Type 4** is isolated unit 9 defect

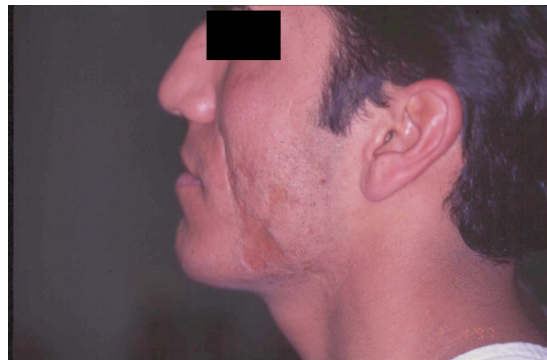### 7.1. Type 1 defect

For partial unit defects (Figures 20 to 22), the treatment modalities available are:

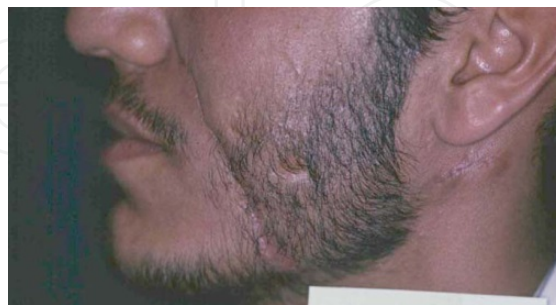1. Defect resection and primary repair
2. Local tissue expansion and reconstruction
3. Hair transplantation



**Figure 20.** A partial unit defect can be anywhere on the face, used by permission of author Davide Brunelli M.D, [www.med-ars.it](http://www.med-ars.it)



**Figure 21.** A type one defect of unit 4



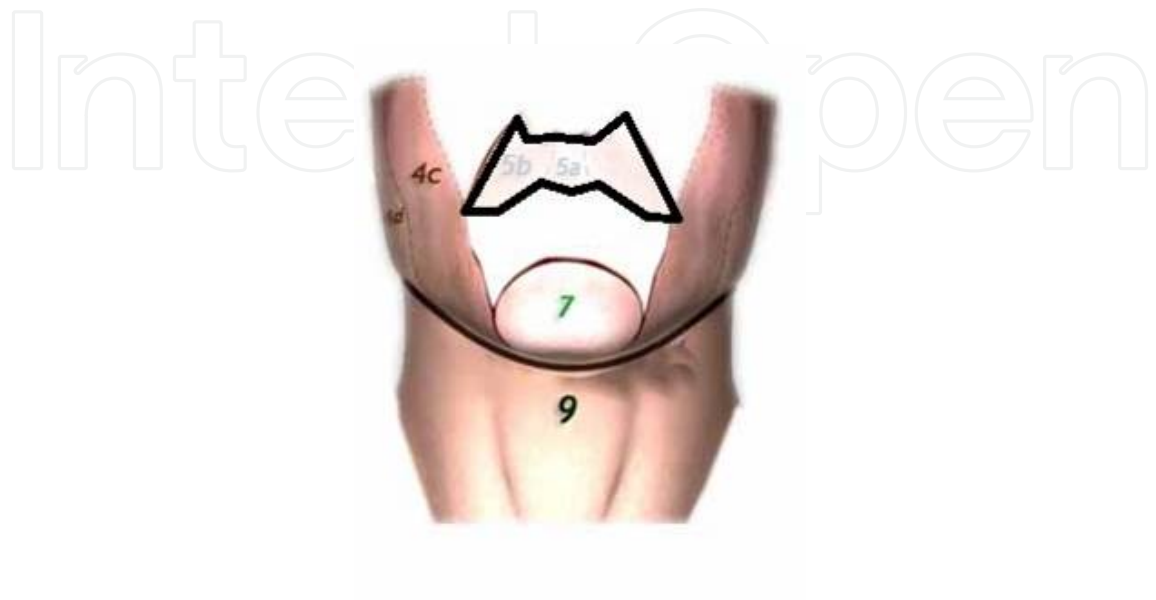
**Figure 22.** After resection and repair and one stage hair transplantation. Some areas need more transplantation

## 7.2. Type 2 defect

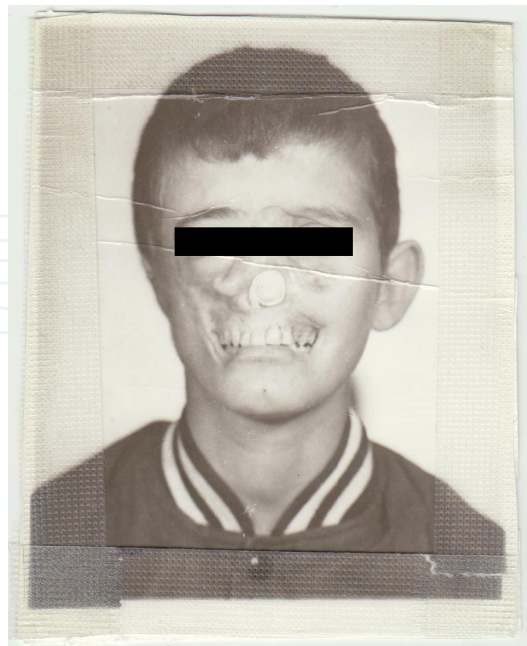
Total unit defects which can be either unit 4 or 5 (Figures 23 to 34).

The reconstruction options are :

1. Expanded scalp
2. Expanded submental flap

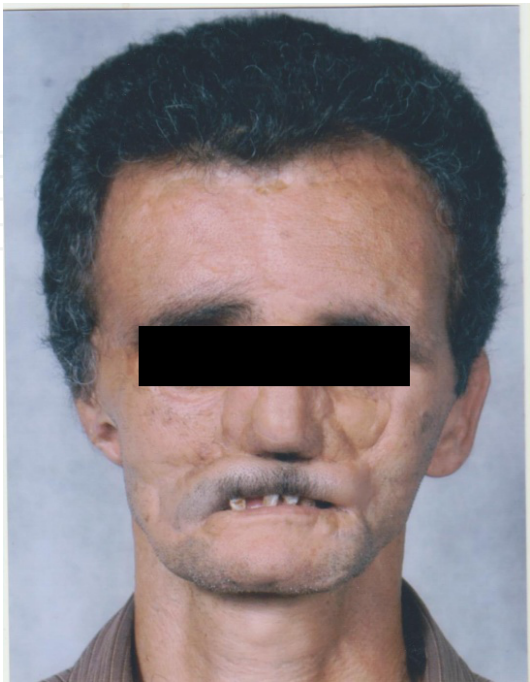


**Figure 23.** Unit 5 defects, used by permission of author Davide Brunelli M.D, [www.med-ars.it](http://www.med-ars.it)




**Figure 24.** A unit five defect 20 years after reconstruction by an expanded scalp visor flap

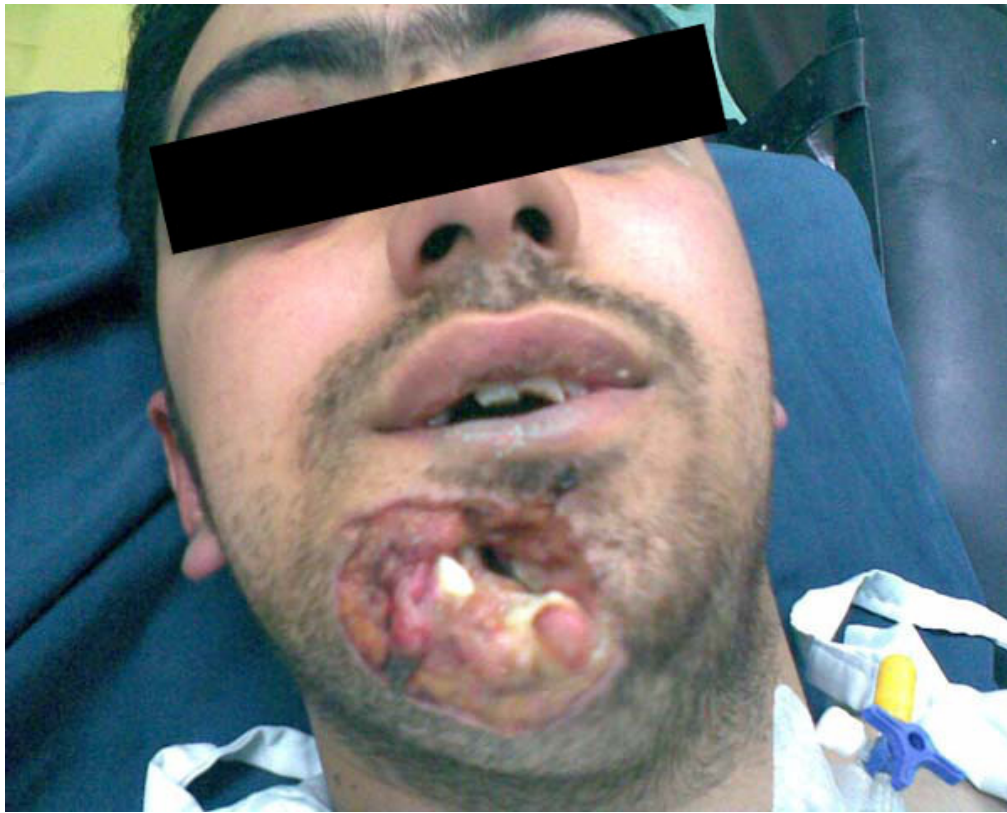



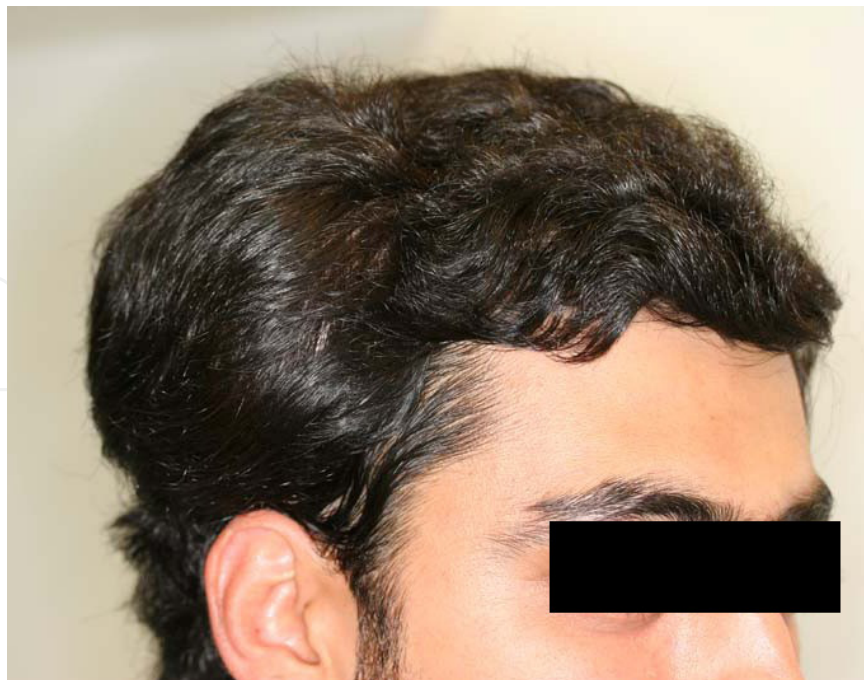**Figure 25.** A unit five defect 20 years after reconstruction by an expanded scalp visor flap



**Figure 26.** Unit 4 defect, used by permission of author Davide Brunelli M.D, [www.med-ars.it](http://www.med-ars.it)



**Figure 27.** Unit 7 full thickness defect



**Figure 28.** The expanded scalp flap

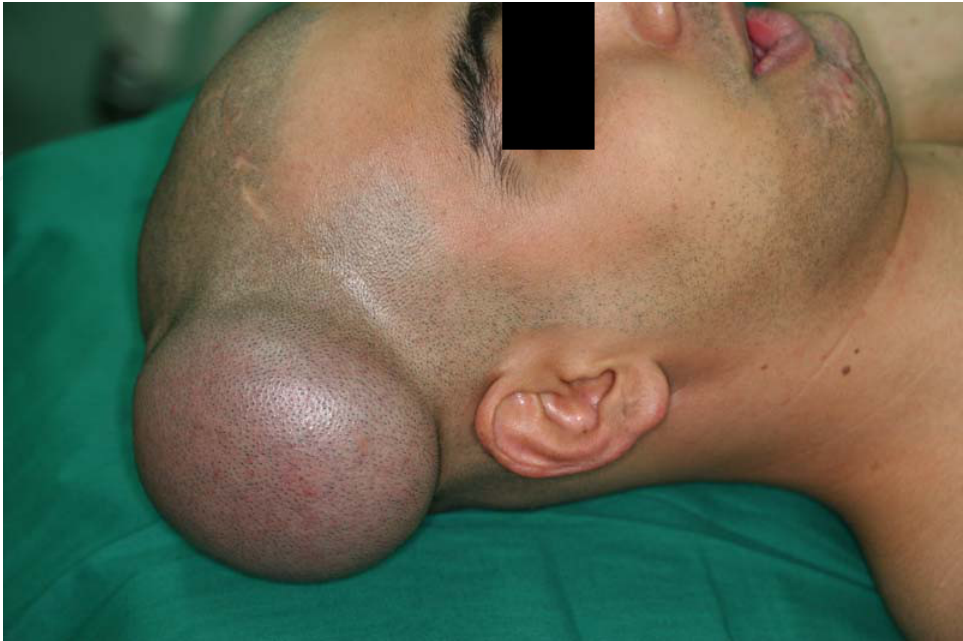

Figure 29. Expansion is complete.

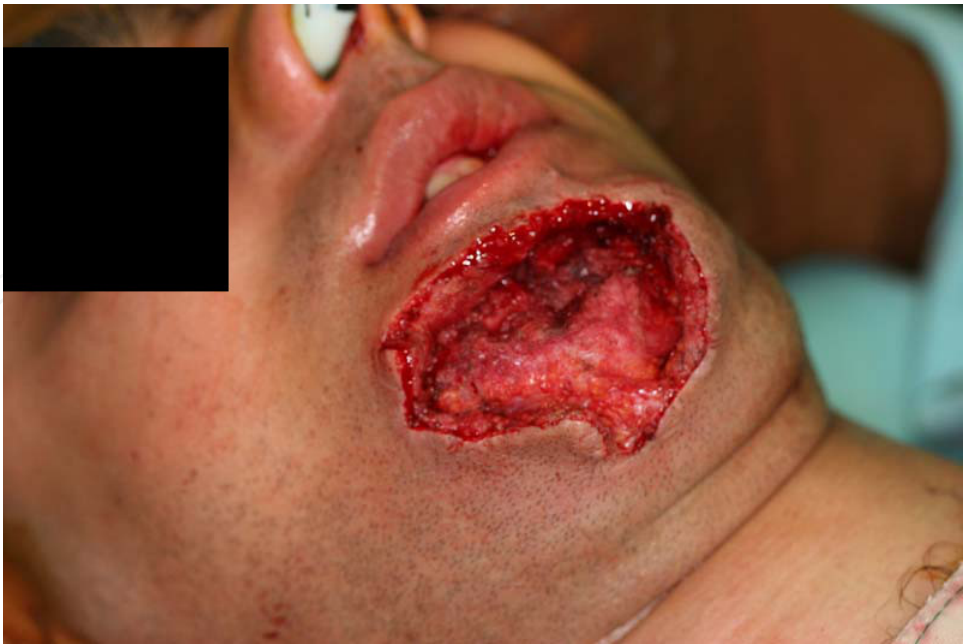
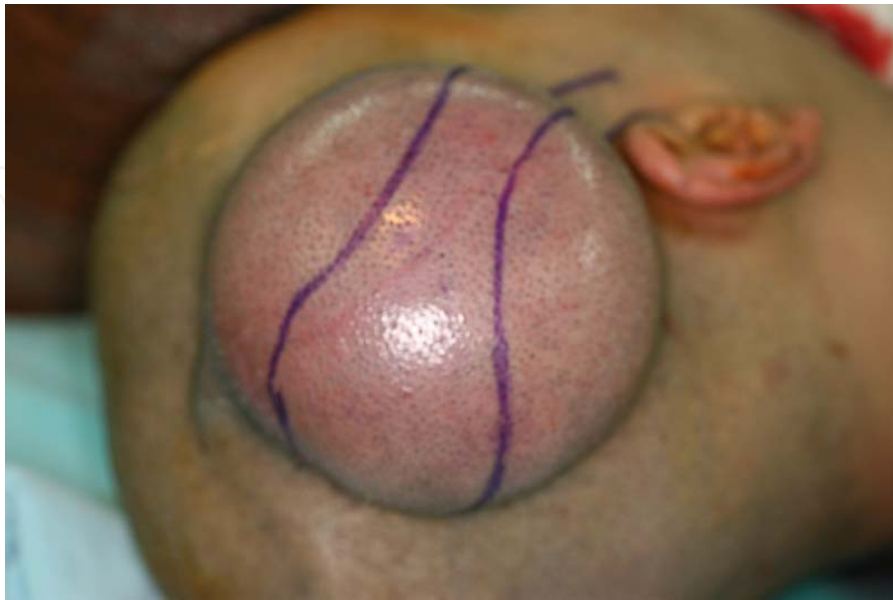
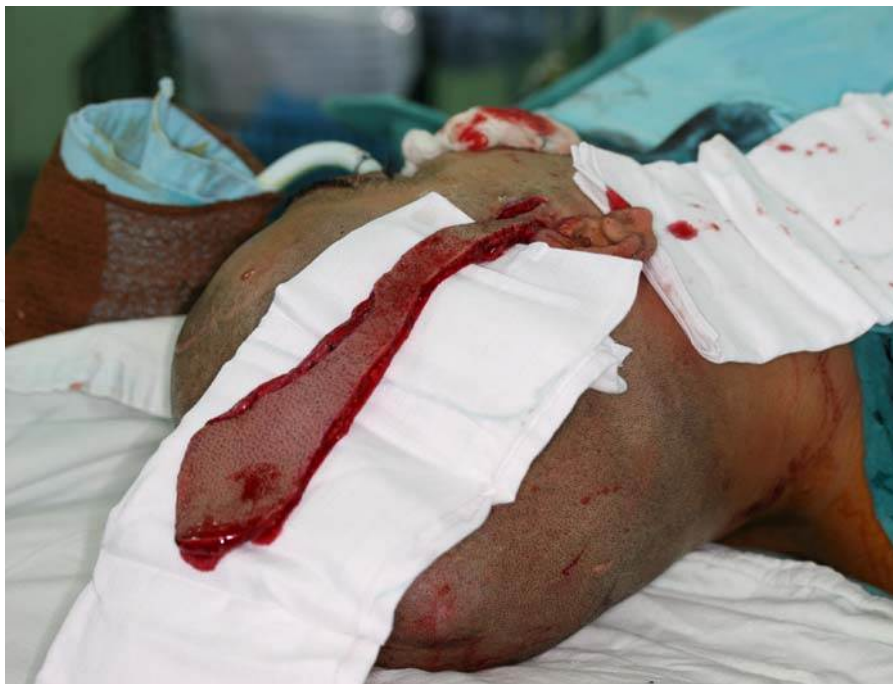Figure 30. The defect after resection of scar tissues

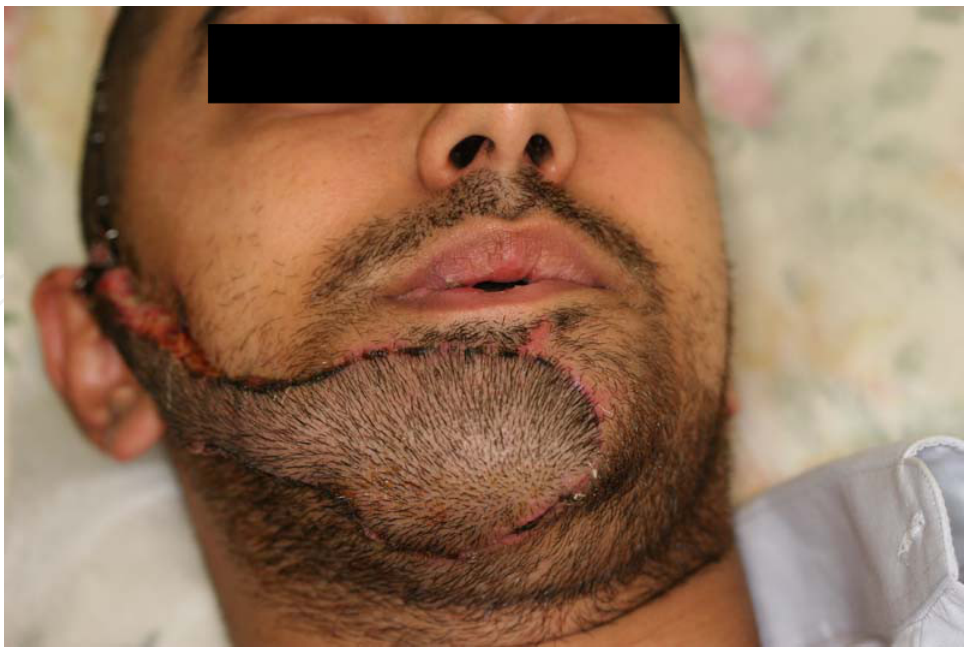



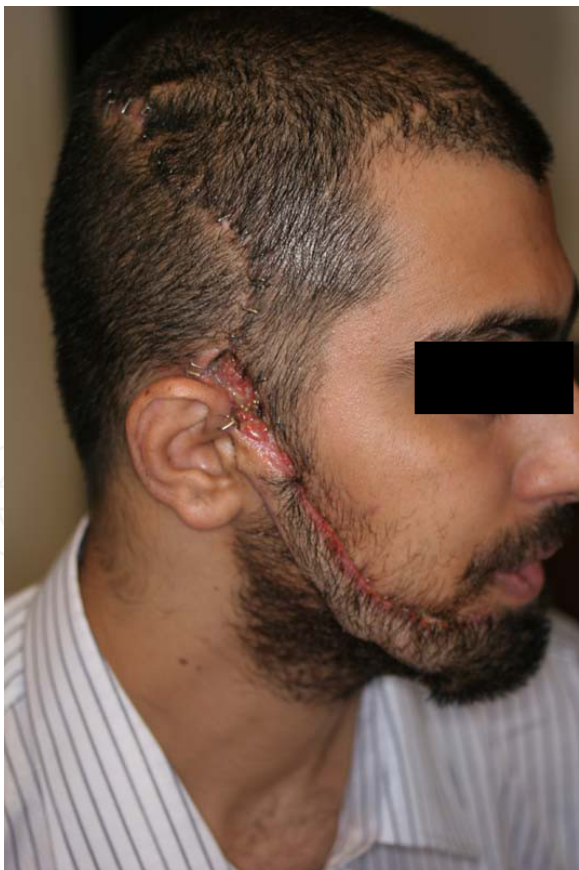**Figure 31.** Outline of the flap design is over the highest expanded area to bring a less dense follicle area to the recipient site.



**Figure 32.** The flap is elevated on the superficial temporal vessels as a pedicle flap

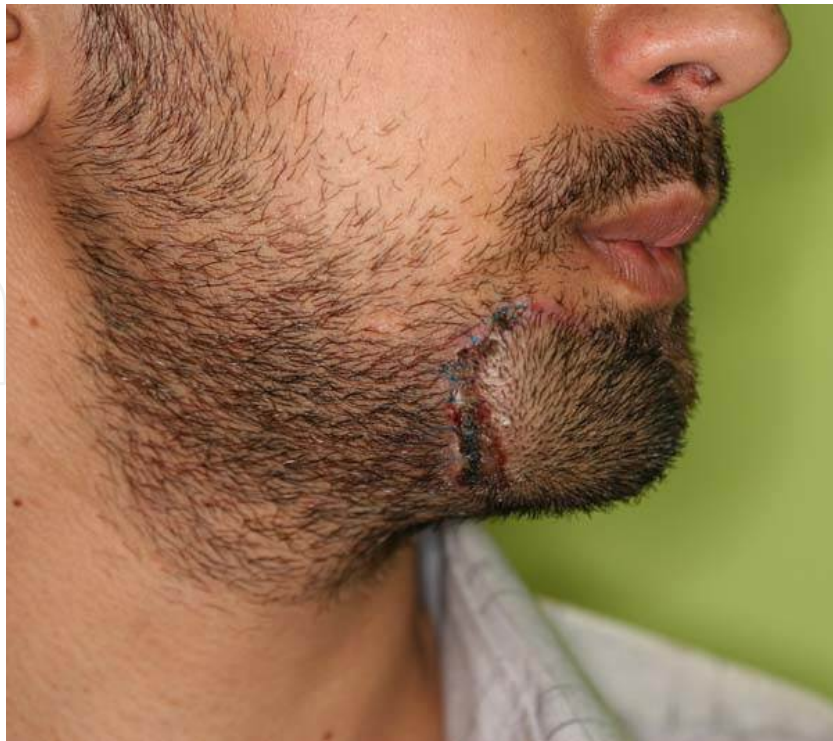

**Figure 33.** The flap covers the defect completely. Note the pedicle lying over the face.

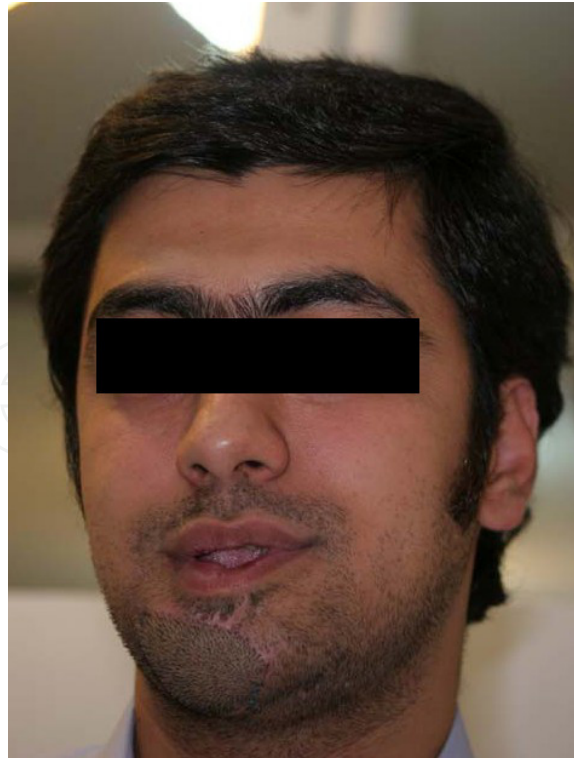

**Figure 34.** The flap pedicle ready to be severed and returned to its original place.





**Figure 35.** The flap after severance

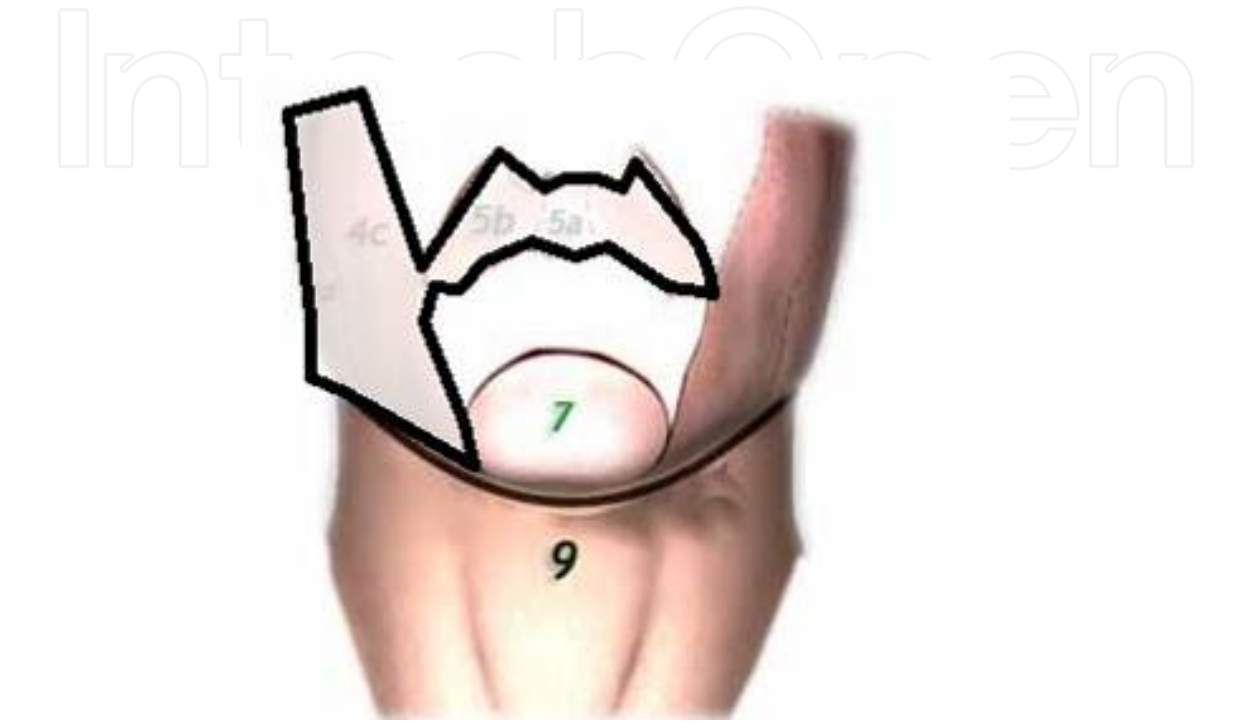


**Figure 36.** The patient 5 years after the last operation.

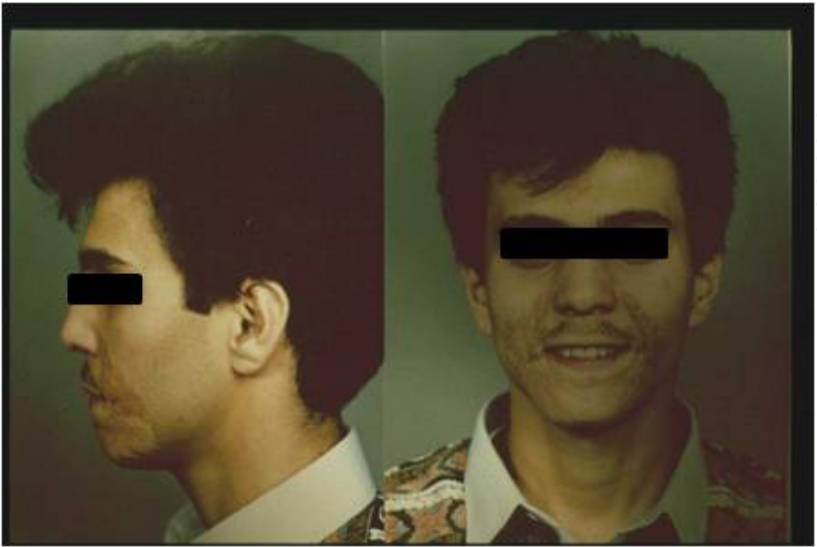7.3. Type 3 defect

Bilateral unit defects or multiple unit defects may be best treated via an expanded Visor flap (Figures 35 to 45).

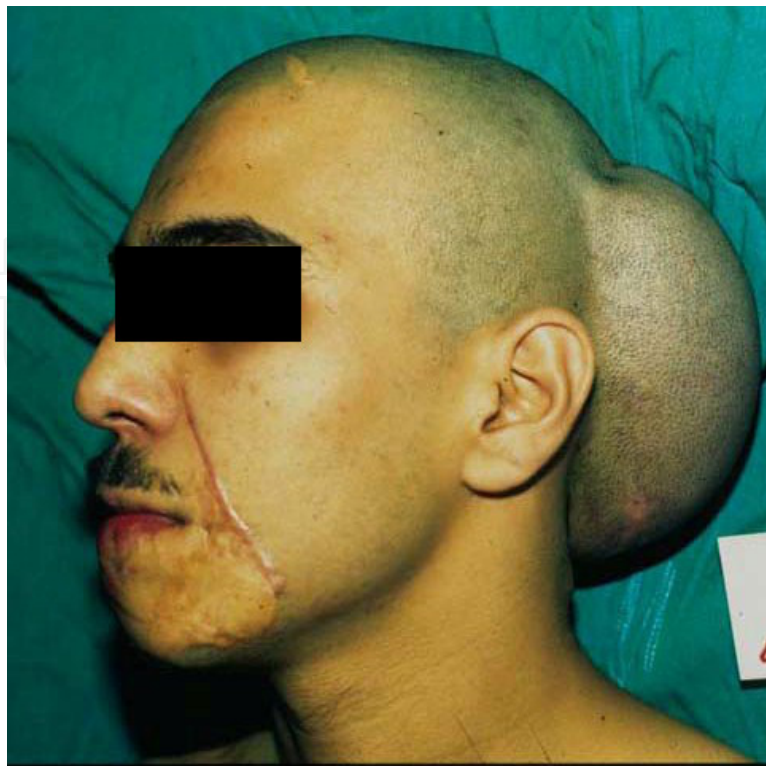Type 3a



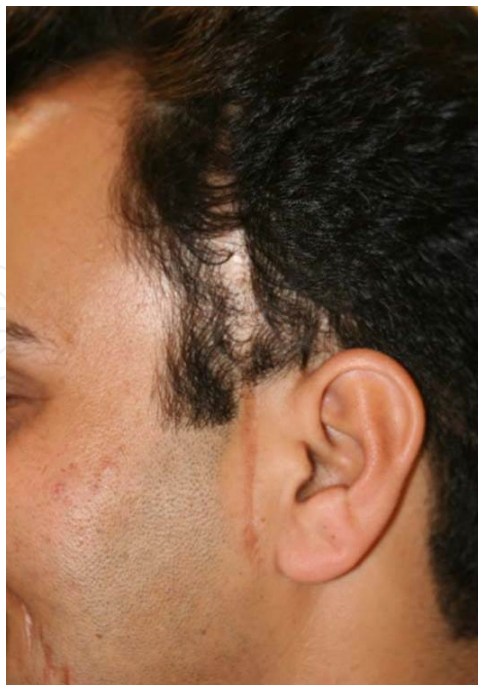**Figure 37.** Type 3a defect, bilateral involvement of units or combined units, used by permission of author Davide Brunelli M.D, [www.med-ars.it](http://www.med-ars.it)



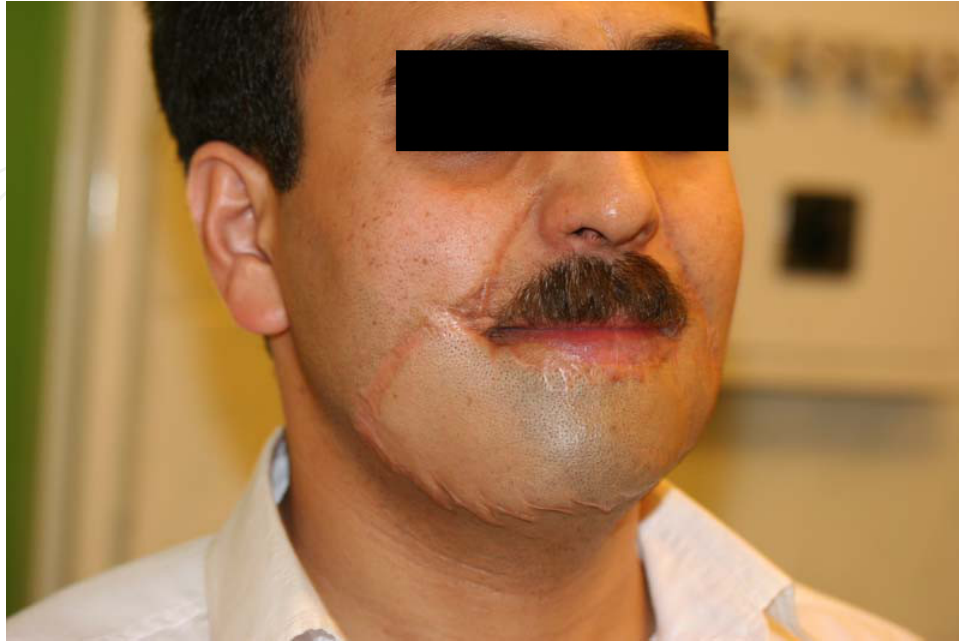**Figure 38.** A bilateral unit 4 and 7 defect



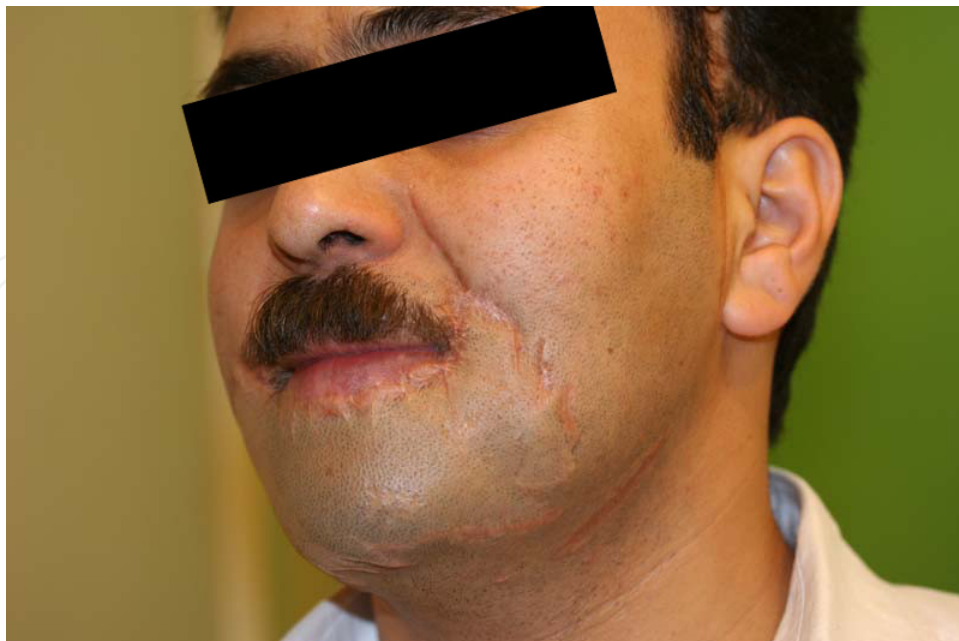**Figure 39.** The expanded occipital flap



**Figure 40.** The flap is transferred on the temporal pedicle

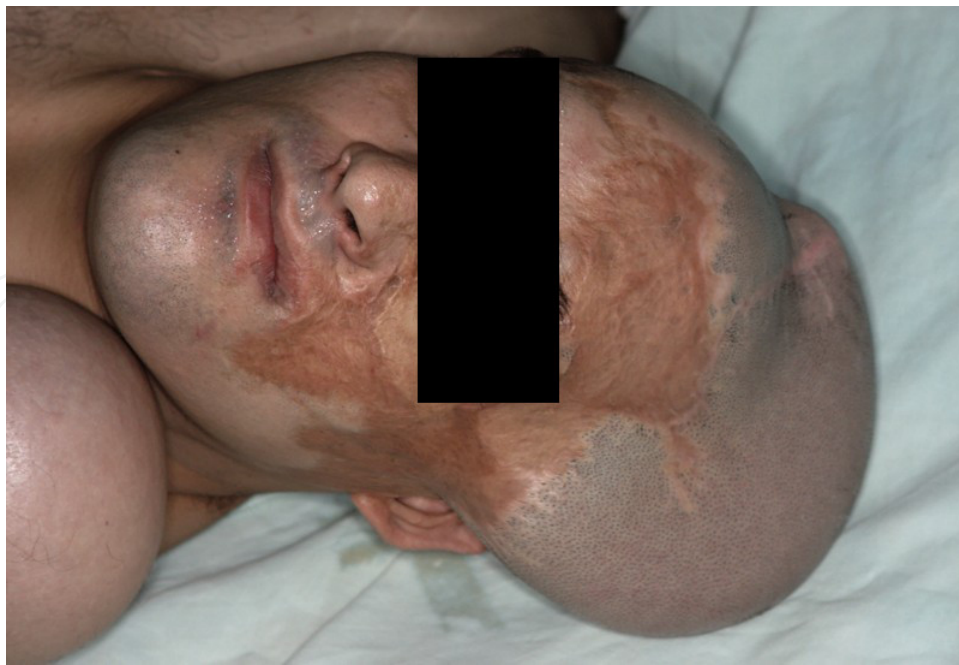

**Figure 41.** Ten years after the operation

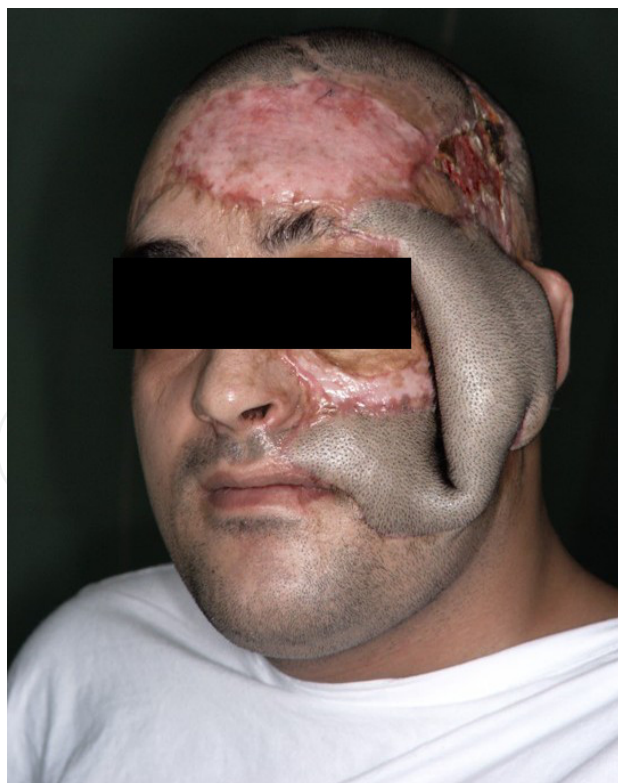

**Figure 42.** Another view with small Z- plasties to cover the scar



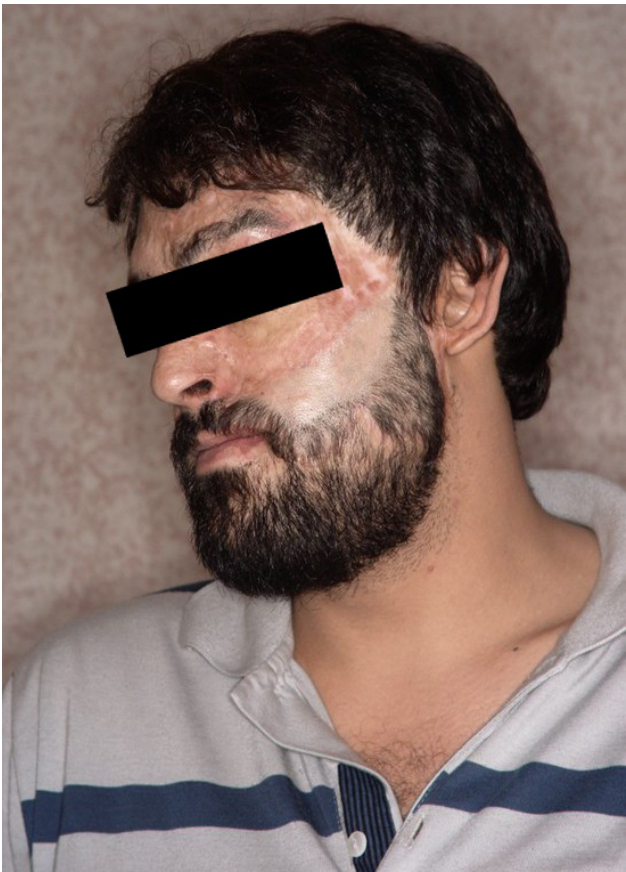

**Figure 43.** Type 3a : multiple unit with sideburn involvement; units 4 and 5 partial defects with expansion in place

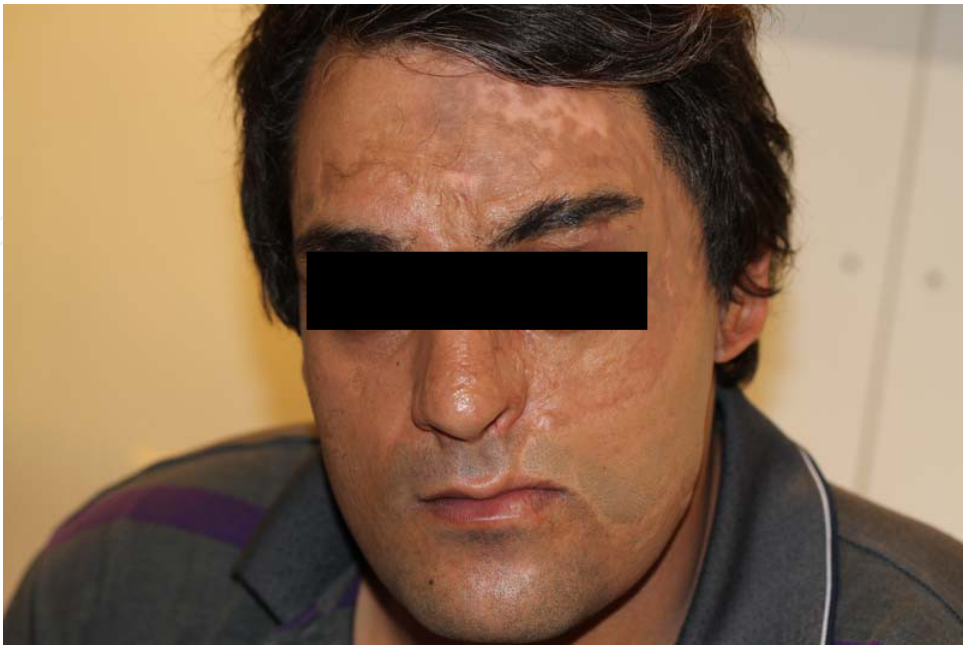

**Figure 44.** Expanded supraclavicular skin for forehead coverage and expanded scalp for reconstruction of multiple units.

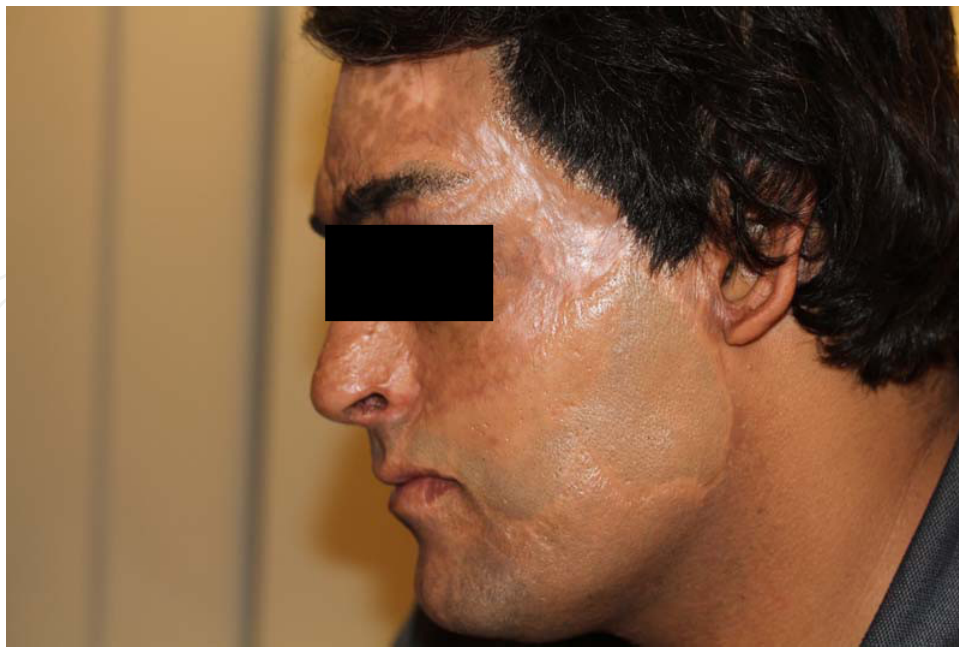



**Figure 45.** The result after two years



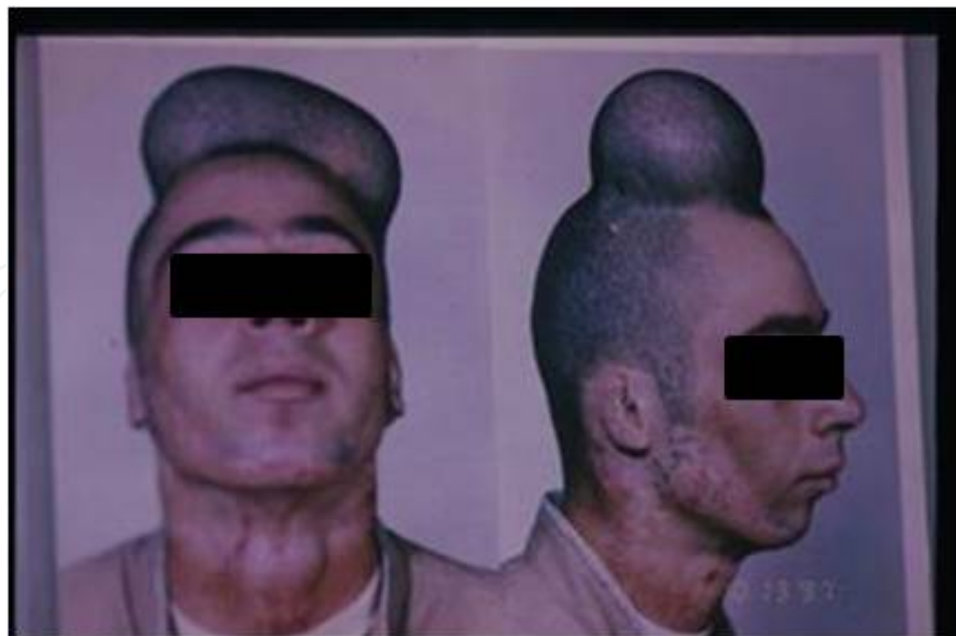**Figure 46.** Ten years after operation



**Figure 47.** Another view of the patient with Z- plasties to cover the scar

### **Type 3b**

Bilateral near total defects (Figures 46 to 49)



**Figure 48.** Bilateral unit 4 and 9 involvement with expansion in place.

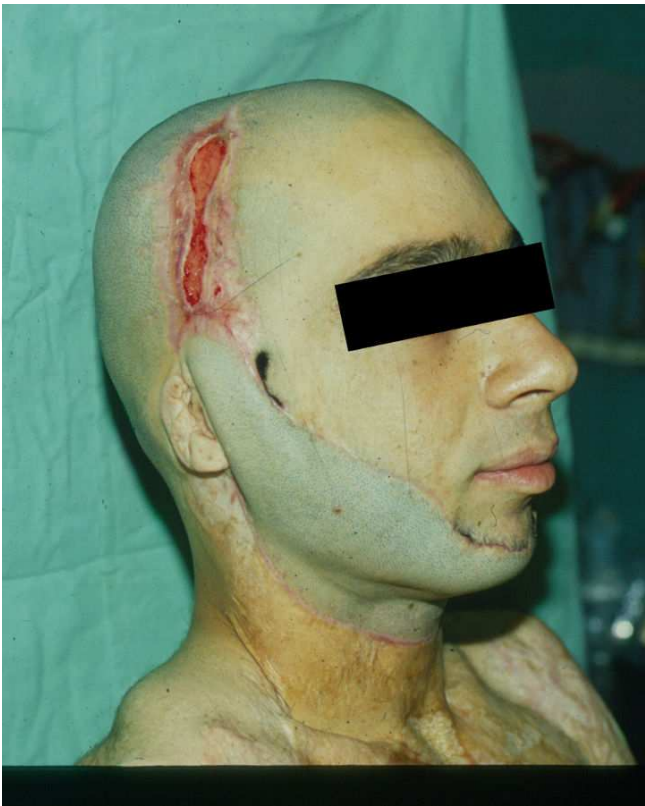

Figure 49. The flap in place

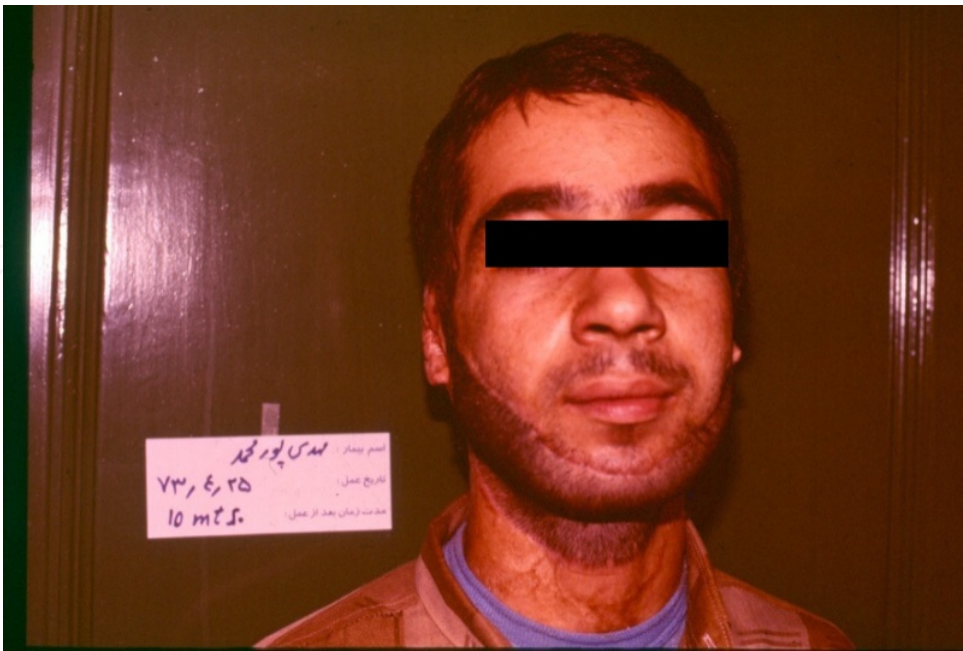
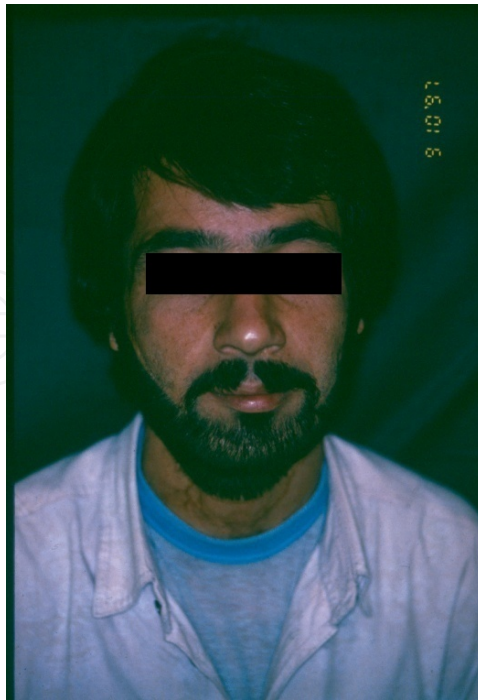

Figure 50. The result after two years.

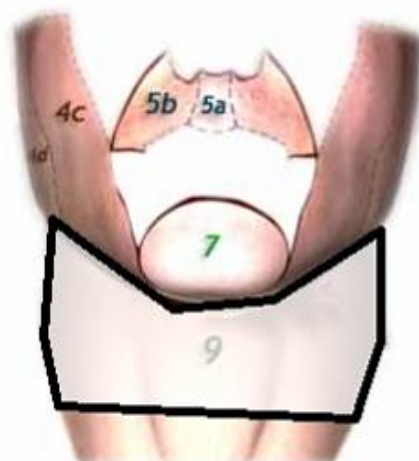


**Figure 51.** Ten years after the operation.

#### **7.4. Type 4 defect**

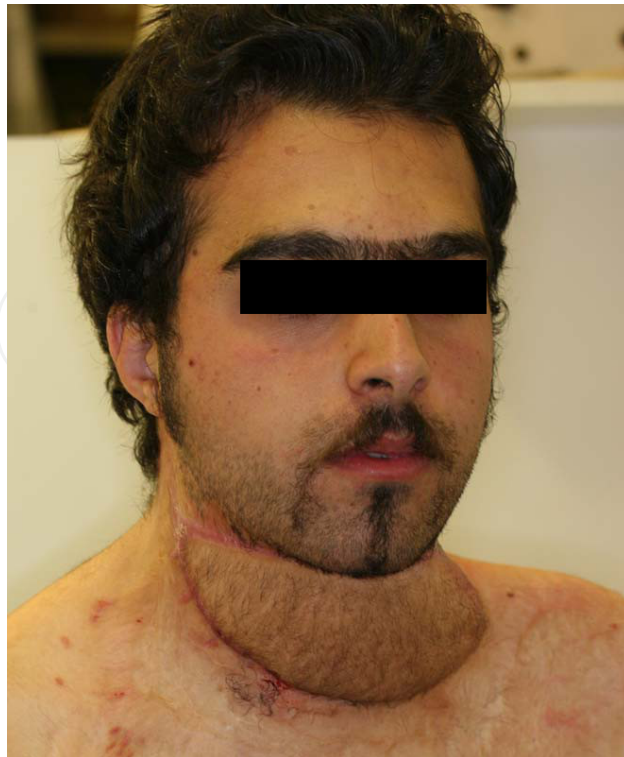##### *7.4.1. Isolated unit 9 defects*

These defects are unique in that although they bear hair they can be reconstructed with non-hair bearing flaps especially when unit 4 is intact. The beard will cover the scar of this area (Figures 52 - 55)

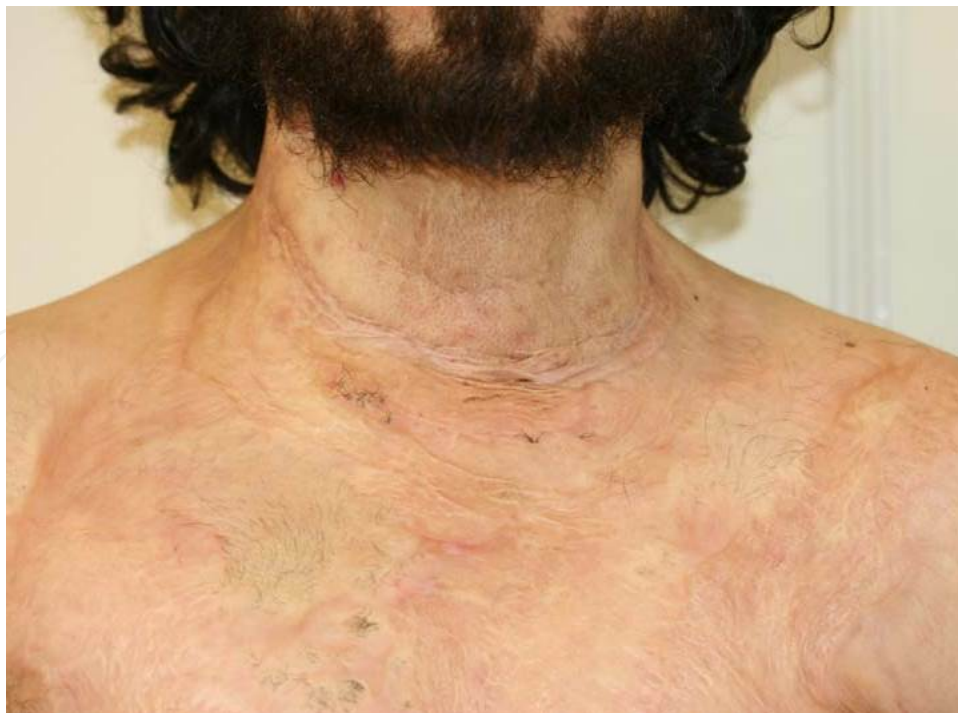

**Figure 52.** Isolated unit 9 defects can be reconstructed with non-hair bearing flaps



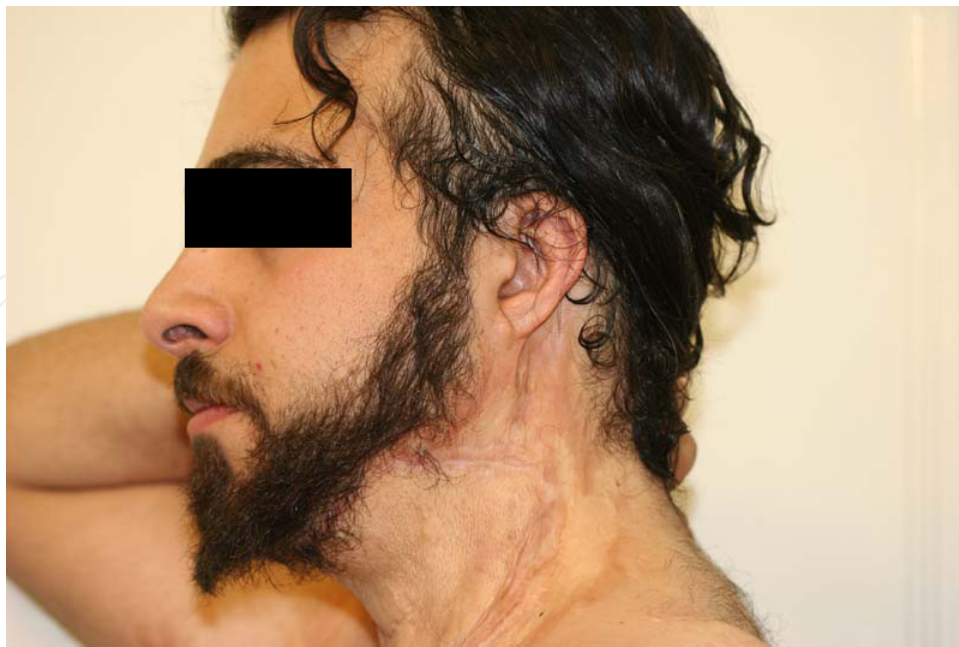

**Figure 53.** An isolated unit 9 defect reconstructed by an expanded trapezius flap, the anterior trunk was involved in the scar.



**Figure 54.** The flap after defatting, note the hair which was present before defatting has become very thin after defatting or transfer.





**Figure 55.** The end result after 7 years, the flap is hidden behind the beard.

## 8. Summary

Facial hair bearing area reconstruction is one of the most demanding reconstructive procedures and the options available are not an exact match. The facial region recognition and available donors are the prerequisites for the reconstructive surgeon treating these difficult conditions.

## Author details

Shahram Nazerani\*

Address all correspondence to: [Snazeranimd@gamil.com](mailto:Snazeranimd@gamil.com)

Dept. of Surgery, Firuzgar Medical Center, Iran University of Medical Sciences, Tehran, Iran

## References

- [1] Darwin, Charles (2004). *The Descent Of Man And Selection In Relation To Sex*. Kessinger Publishing. p. 554.
- [2] Randall VA (2008). "Androgens and hair growth". *Dermatol Ther* 21 (5): 314–28.

- [3] Sahih Bukhari, Book 72, Hadith #780 Allah's Apostle, salallahu aleihi wa sallam/ peace and blessings of Allah be upon him, said, "Cut the moustaches short and leave the beard (as it is)."
- [4] Zokon Yisrael KiHilchso, [http://holmininternational613.com/books/BEARD\\_JEWISH\\_LAW-E.pdf](http://holmininternational613.com/books/BEARD_JEWISH_LAW-E.pdf)
- [5] Sherrow, Victoria (2006). Encyclopedia of Hair: A Cultural History. Greenwood Publishing Group. p. 59.
- [6] The Oxford Handbook of Iranian History, PP300
- [7] Helen Bunkin, Randall Williams: Beards, Beards, Beards (Hunter & Cyr, 2000)
- [8] Chrysippus ap. Athen. xiii. 565 a
- [9] Ancient Greek: πωγωνοτροφία φιλόσοφον οὐ ποιεῖ. De Is. et Osir. 3 (cited by Peck)
- [10] Petron. 75, 10 (cited by Peck)
- [11] Corpus Christianorum, Continuatio Mediaevalis LXII, Apologiae duae: Gozechini epistola ad Walcherum; Burchardi, ut videtur, Abbatis Bellevallis Apologia de Barbis. Edited by R.B.C. Huygens, with an introduction on beards in the Middle Ages by Giles Constable. Turnholti 1985
- [12] Citing Lucian's Demonax 13, Cynicus 1 - John Sellars (1988). The art of living: the Stoics on the nature and function of philosophy. Burlington, VT: Ashgate Publishing Limited
- [13] "Gunma bureaucrats get beard ban | The Japan Times Online". Search.japan-times.co.jp. 2010-05-20. Retrieved 2011-11-24.
- [14] Job Bulletin". Agency.governmentjobs.com. 2013-03-22. Retrieved 2014-02-26
- [15] Franbourg A, Hallegot P, Baltenneck F, et al. Current research on ethnic hair. J Am Acad Dermatol 2003; 48(6):S115–9
- [16] Tolgyesi E, Coble F., Fang S., Kairinen E.O., A comparative study of beard and scalp hair. J Soc Cosmet Chemists, 1982; 34, 361-382
- [17] Zhang B, Wang JG, Chen WL, et al. Reverse facialsubmental artery island flap for reconstruction of oropharyngeal defects following middle and advanced-stage carcinoma ablation. Br J Oral Maxillofac Surg 2011;49:194–7
- [18] Koshima I, Inagawa K, Urushibara K, et al. Combined submental flap with toe web for reconstruction of the lip with oral commissure. Br J Plast Surg 2000; 53:616–9
- [19] Yilmaz M, Menderes A, Barutcu A. Submental artery island flap for reconstruction of the lower and mid face. Ann Plast Surg 1997;39:30–5.

- [20] Zhang B, Wang JG, Chen WL, et al. Reverse facialsubmental artery island flap for reconstruction of oropharyngeal defects following middle and advanced-stage carcinoma ablation. *Br J Oral Maxillofac Surg* 2011;49:194–7.
- [21] Wang WH, Hwang TZ, Chang CH, et al. Reconstruction of pharyngeal defects with a submental island flap after hypopharyngeal carcinoma ablation. *ORL J Otorhinolaryngol Relat Spec* 2012;74:304–9.
- [22] Abboud O, Shedid D, Ayad T. Reconstruction of the prevertebral space with a submental flap: a novel application. *J Plast Reconstr Aesthet Surg* 2013; 66(12):1763–5.
- [23] a textbook of advanced Oral and Maxillofacial surgery, chapter 18, p. 516
- [24] Giraldo F1, González C, Garnica I, Ferrón M, Rus JA. A Sideburn reconstruction with an expanded supraauricular trapezoidal flap, *Plast Reconstr Surg*. 1997 Jul;100(1):257-61.
- [25] Juri J, Juri C, Colnago A. The surgical treatment of temporal and sideburn alopecia. *Br J Plast Surg*. 1981 Apr;34(2):186-93
- [26] Martin D, Baudet J, Mondie JM, et al. The submental island skin flap. A surgical protocol. Prospects of use. *Ann Chir Plast Esthet* 1990;35:480–4
- [27] Faltaous AA, Yetman RJ. The submental artery flap: an anatomic study. *Plast Reconstr Surg* 1996; 97:56–60 [discussion: 61–2
- [28] Expanded tubed flap in scalp reconstruction: a modern option in an old technique. Caleffi E, Fasano D, Bocchi A, Papadia F. *Plast Reconstr Surg*. 1988 Dec;82(6):1075-8  
Microvascular transplantation of expanded free scalp flaps between identical twins.
- [29] Valauri FA, Buncke HJ, Alpert BS, Lineaweaver WC, Argenta LC. *Plast Reconstr Surg*. 1990 Mar;85(3):432-6
- [30] Dufourmentael L. Essai de reconstruction totale u massif maxillaire inferieur. *Reconstr Maxillofacial* 1919;3:141-156
- [31] Bisaccia E, Scarborough D. Hair transplant by incisional strip harvesting. *J Dermatol Surg Oncol* 1994;20(7):443–8
- [32] Rassman WR, Bernstein RM, McClellan R, Jones R, Worton E, Uyttendaele H. Follicular unit extraction: minimally invasive surgery for hair transplantation. *Dermatol Surg* 2002;28((August) 8):720–8
- [33] Gurlek A, Alaybeyoglu N, Demir CY, Aydogan H, Bilen BT, Ozturk A. Aesthetic reconstruction of large scalp defects by sequential tissue expansion without interval. *Aesthetic Plast Surg* 2004;28((July–August) 4):245–50
- [34] Kim JC, Choi YC. Regrowth of grafted human scalp hair after removal of the bulb. *Dermatol Surg* 1995;21(4):312–3.

