

# We are IntechOpen, the world's leading publisher of Open Access books Built by scientists, for scientists

6,900

Open access books available

185,000

International authors and editors

200M

Downloads

Our authors are among the

154

Countries delivered to

TOP 1%

most cited scientists

12.2%

Contributors from top 500 universities



WEB OF SCIENCE™

Selection of our books indexed in the Book Citation Index  
in Web of Science™ Core Collection (BKCI)

Interested in publishing with us?  
Contact [book.department@intechopen.com](mailto:book.department@intechopen.com)

Numbers displayed above are based on latest data collected.  
For more information visit [www.intechopen.com](http://www.intechopen.com)



---

# **Combined Surgical and Orthodontic Management of Maxillofacial Deformities**

---

Sana Alami, Hakima Aghoutan, Samir Diouny,  
Farid El Quars and Farid Bourzgui

Additional information is available at the end of the chapter

<http://dx.doi.org/10.5772/59164>

---

## **1. Introduction**

The development of orthognathic surgery techniques and materials has allowed surgeons and orthodontists to standardize treatment of maxillomandibular deformities. Multidisciplinary treatment of skeletal deformities by orthognathic surgery in addition to orthodontics has become a routine strategy believed to result in functional and esthetic outcomes in adult patients.

When malocclusion is caused by severe skeletal discrepancies, the orthodontist can propose dentofacial orthopedics in growing children, dental compensation for skeletal deformity or orthognathic surgery combined with orthodontic treatment (when the major growth potential of the patient has been completed). The decision is based on clinical examination and cephalometric analysis, both of which aim to assess the amount of three dimensional discrepancy. Patients with functional and esthetic issues require a multidisciplinary approach involving orthodontic and orthognathic surgery to reposition the maxilla and/or the mandible in three dimensions. Such a therapeutic approach is considered as the best treatment; it corrects dentofacial deformities which cannot be treated by orthodontics alone [1].

The stability of results in addition to the functional well-being and aesthetic appearance approach the level of excellence. The issue of skeletal, dento-alveolar and soft tissue relapse is a matter of discussion, debate and controversy in the orthodontic literature. The aim of this chapter is to define the criteria for stability that must be complied during both preparatory orthodontic and surgery phases in orthognathic surgery, without over-timing the postoperative orthodontic phase.

### 1.1. Stability criteria of ortho-surgical treatment

The management of dento-skeletal dysmorphism requires a team of specialists that mainly include orthodontists and maxillofacial surgeons. The ultimate aim of orthodontists is both to meet the patients' expectations, and make effective sustainable interventions. Three treatment objectives, which form the basis in treating patients with dento-facial deformities, are fundamental in orthognathic surgery namely function, esthetics, and stability. Skeletal relapse is the most common complication following orthognathic surgery. Optimal treatment planning for maxillofacial surgery requires an understanding of postoperative skeletal stability, dento-alveolar position and the soft tissue response to skeletal movement. Accurate treatment planning and careful orthodontic and surgical protocols are essential to the achievement of treatment objectives; these have to be planned with collaborating partners upon initial consultation (Figure 1). [1]

## Influencing Factors

- Preoperative age
- Soft tissue and muscles
- Presurgical skeletal pattern
- Dental decompensation
- Coordination of dental arcss
- Direction and amount of surgical movement
- Type and material of fixation

Figure 1. Factors influencing stability in orthognathic surgery treatment.[1]

## Figure 1 : Factors influencing stability in orthognathic surgery treatment.[1]

### 2. Preliminary patient evaluation

#### Preliminary patient evaluation

A systematic examination is necessary to adequately evaluate and treat patients with dento-facial deformities. Treatment planning should start only when the orthodontist and surgeon have agreed on a final treatment plan. It is mandatory that the patient be well informed about the treatment plan and related possible disadvantages. Indeed, efficacy is guaranteed when there is clear and effective communication between the orthodontist and surgeon have agreed on a final treatment plan. It is mandatory that the patient be well informed about the treatment plan and related possible disadvantages. Routine evaluation includes [1]:

Indeed, efficacy is guaranteed when there is clear and effective communication between the orthodontist and the maxillofacial surgeon from the outset.

Routine evaluation includes [1]:

- Evaluation of patient's medical history
- Socio-psychological assessment of the patient's motives and expectations
- Aesthetic facial evaluation involving frontal and profile analysis
- Dental and occlusal oral function evaluation
- Cephalometric radiographic evaluation which forms an important part of the database for orthognathic surgical treatment planning. Soft tissue, skeletal and dental analysis are helpful diagnostic guides.
- Occlusion and study cast evaluation which includes examination for intra and inter- arch relationships.

The initial consultation aims to discuss the possible need for surgical procedure as part of the treatment to achieve optimal results. However, before treatment, it is important to put emphasis on those elements that are directly related to stability; some of these include operative age, the soft tissue and muscles, and mandibular inclination. [2, 3]

### **2.1. Preoperative age**

Growth following surgery may result in relapse; surgical osteotomy and osteosynthesis have little influence on the mandibular jaw growth. The initial growth of the patient's face and continuous remodeling processes may lead to an advantageous or disadvantageous change of position of the mandible after sagittal split osteotomy. [3] The inability to predict the potential growth of the mandible can lead to failure or recurrence when the surgical indication is established before the end of growth. This leads practitioners to adopt a cautious attitude. To minimize the risks of relapse due to continuous growth, surgery should only be recommended to patients when growth is complete.

### **2.2. Soft tissue and muscles**

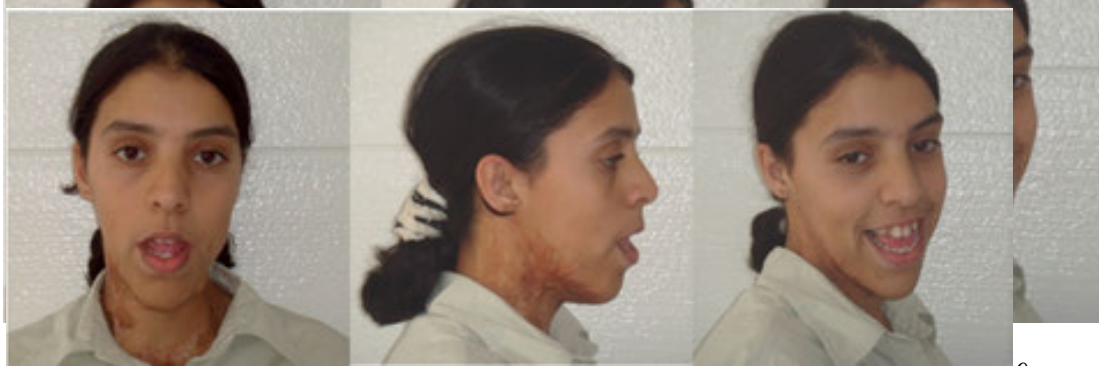Although long-term studies of surgical orthodontic stability are sparse, many authors predict the importance of active and /or passive contractions exerted by muscles and/or post surgical skeletal recurrences due to soft tissue. [2] An examination of cervical soft tissues and orofacial muscles (in particular the tongue) at rest and during function requires due attention. This is illustrated in case 1 which was a 19-year-old female admitted for burn injuries following a home accident at the age of 6 yrs. Aesthetic imbalance and significant dento-skeletal deformity is due to post-burn contractures of the neck (Figures 2 and 3). Facial appearance is the patient's main concern. Radiographic evaluation and cephalometric analysis showed the patient presented high values for mandibular length and plane angle (FMA= 38°). The Wits appraisal indicated a large anteroposterior discrepancy between the maxilla and mandible (AO-BO=-6.5mm) (Figure 4). Only surgery can improve the aesthetics. The expected dental and soft tissue changes to be affected by the preoperative orthodontic treatment are illustrates by cephalometric tracing. The surgical plan consisted of two-jaw surgery (Figure 5).



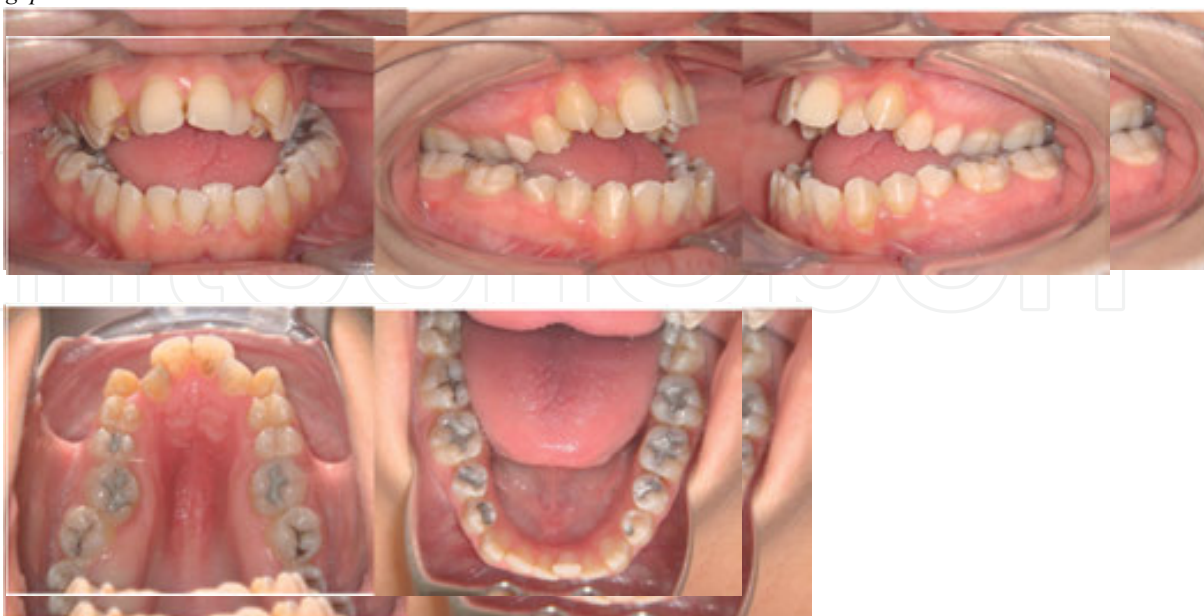- Lefort I maxillary osteotomy is used to perform advancement and expansion of the maxilla and a slight superiorly repositioning is needed to allow the mandible to auto-rotate and close the openbite.
- Bilateral sagittal split osteotomy for setback of the mandible.

Preoperative orthodontic treatment planning included teeth alignment without extraction and provision of good arch form assisted by maxillary expansion (Figure 6).

réparatrice des tissus cutanés du cou, seule garante d'une stabilité après chirurgie orthognathique. La frenectomie linguale But the project initially conceived can only succeed after surgical repair of cervical skin tissue, the only guarantee of stability for tongue position during swallowing are modalities that help prompt stability. But the project initially conceived can only succeed after surgical repair of cervical skin tissue, the only guarantee of stability after orthognathic surgery. Lingual Frenectomy, re-education of the tongue as well as swallowing are modalities that help prompt stability.



**Figure 2:** Frontal view, profile and smile of the patient before treatment: Female, 19 years of age, characteristics long face pattern, with prognathism, and vertical growth pattern, scare contracture due to neck burn and increased interlabial gap.



**Figure 3:** Pre-treatment intra-oral photographs: frontal lateral occlusion shows severe open bite and maxillary anteroposterior and transverse deficiency. Constricted maxillary arch explains the crowding in the anterior maxilla. There is serious open bite. So, maxillary anteroposterior and transverse deficiency (maxillary arch –shaped lyre) explains crowding in the anterior maxillary arch

Figure 3: Pre-treatment intra-oral photographs: frontal lateral occlusion shows severe pre-treatment intra-oral photographs: frontal and lateral occlusion shows severe overbite with anplaxillary anteroposterior and transverse deficiency. Constricted maxillary arch explain the crowding in the anterior Maxilla

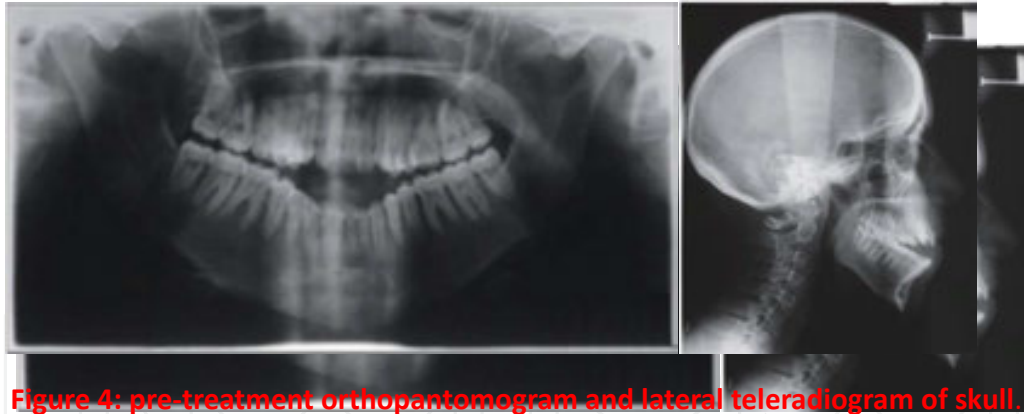

Figure 4. Pre-treatment orthopantomogram and lateral teleradiogram of skull.

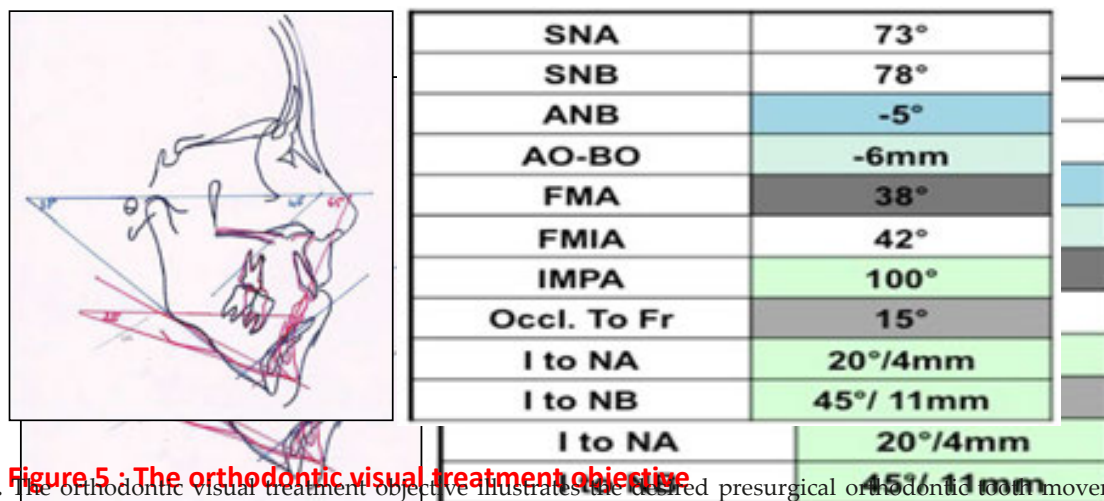


Figure 5. The orthodontic visual treatment objective illustrates the desired presurgical orthodontic tooth movement and predicts the surgical repositioning of the jaws with subsequent soft tissue changes. It has a key role in choosing dental extractions, if needed.

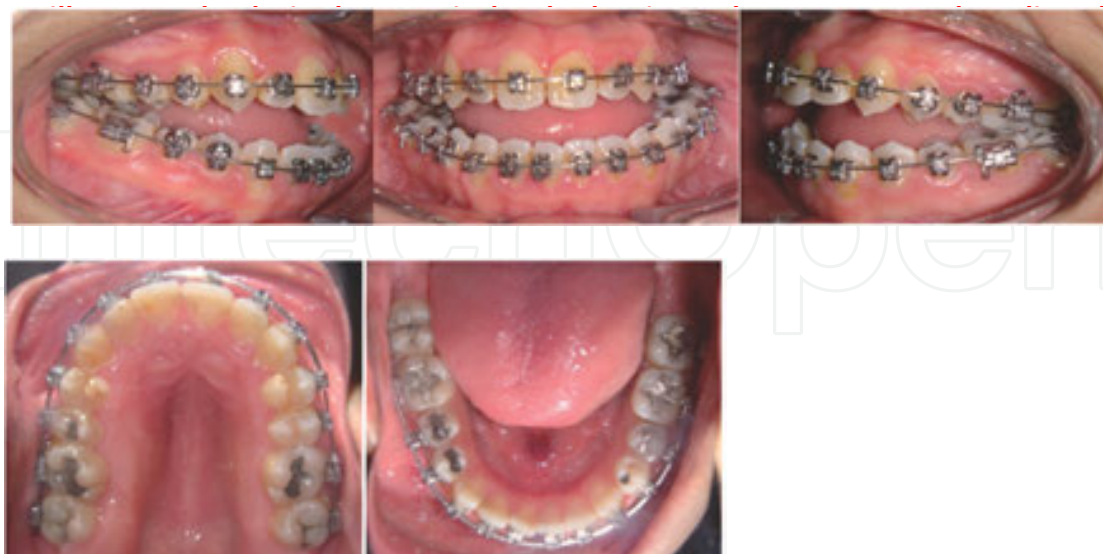

Figure 6. Immediate preoperative intraoral photographs. Treatment does not need dental teeth extraction and the aim of preparatory orthodontic stage was to establish a good arch form in the maxillary and mandibular arches.

### 1.3- Presurgical skeletal pattern

The influence of the mandibular plane angle on horizontal and vertical skeletal stability has been shown in several studies. [3, 4] High angle patients have a greater risk of relapse after receiving bilateral sagittal split ramus osteotomy than low and normal-angle patients. Patients with a low mandibular plane angle, compared to high and normal angle patients, appear to have a more predictable procedure. Then, patients with a low mandibular plane angle have increased vertical relapse when advancement surgery is indicated; whereas patients with a high mandibular plane angle have more horizontal relapse. [3] Because the muscles of mastication are lengthened in the ramus area, they tend to return to their original positions, rotate the mandible in a clockwise movement, open the bite, and cause relapse. To minimize the risk of relapse, patients should be selected carefully ; isolated mandibular advancement or setback should not be performed for patients with high mandibular plane angles. [3]

### 2. Defining treatment objectives

### 2.3. Presurgical skeletal pattern

The influence of the mandibular plane angle on horizontal and vertical skeletal stability has been shown in several studies. [3, 4] High angle patients have a greater risk of relapse after receiving bilateral sagittal split ramus osteotomy than low and normal-angle patients. Patients with a low mandibular plane angle, compared to high and normal angle patients, appear to have a more predictable procedure. Then, patients with a low mandibular plane angle have increased vertical relapse when advancement surgery is indicated; whereas patients with a high mandibular plane angle have more horizontal relapse. [3] Because the muscles of mastication are lengthened in the ramus area, they tend to return to their original positions, rotate the mandible in a clockwise movement, open the bite, and cause relapse. To minimize the risk of relapse, patients should be selected carefully; isolated mandibular advancement or setback should not be performed for patients with high mandibular plane angles. [3]

## 3. Defining treatment objectives

Therapy planning should be clear and precise and the objectives need to be defined with collaborative partners before a final treatment planning decision:

- Focus of the objective of surgery should center on osteotomy choice and its site;
- Orthodontic objective conditioned by the surgical objective, will consist of determining the necessary strategies to reduce preliminary occlusal obstacles and the rebalancing of the dentoalveolar system.

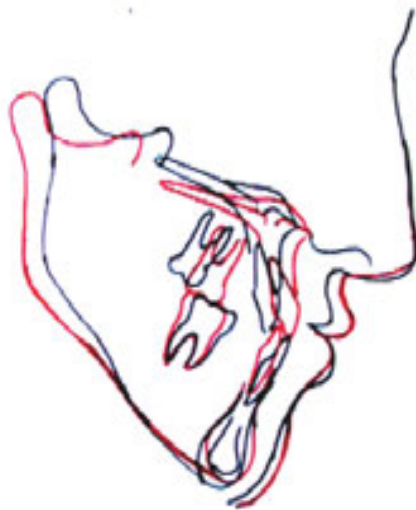Starting cases orthodontically and then, if unsuccessful, referring them for surgery often produces compromised results. [5] It is, therefore, important to prioritize problems and think of potential solutions; this way one can define the objectives of each treatment step. The initial treatment plan must be established following a discussion between the different parties responsible for the smooth implementation of the various steps of the treatment plan. In fact, cephalometric and occlusal simulation setup permits the practitioner to project the occlusal dental and facial skeletal result, to ascertain and determine a suitable orthodontic surgical protocol. Those set-up demonstrates the general reharmonization of the teeth, the jaw and the face. It can then be used as a reference instrument in discussions with the surgeon and patient, and can be modified at all times according to the particular needs. The set-up is, and remains, an estimation which supplies simple quantitative proportional and comparative data. We can record all the data in it (Figure 7). [6]

The use of information technology in dental studies and orthodontics in particular, has contributed to the use of set-up scanning. A 3D simulation system has been developed for orthognathic surgery ; it helps integrate the shape data of the teeth, jawbone and face into the same coordinate system on a computer. The movement of bone associated with mandibular osteotomy and the subsequent changes in the facial form can thus be estimated preoperatively. [7]

The three-dimensional setups allow orthognathic surgery simulation through:



- Integration of the dental arch using a three-dimensional digital model and accurate face scan of the patient.
- Simulation of different possible osteotomies (Lefort, Obwegeser genioplasty), and removal of bone fragments.
- Visualization of contact points.
- Realization of a morphing orthognathic surgery



**Figure 7. Surgical visual treatment prediction** The presurgical setup can assist surgical diagnosis accurate prediction of the postoperative skeletal, dental and facial profile and has become an essential part of the diagnostic and treatment planning procedure of combined surgical-orthodontic therapy.

#### 4. Surgical treatment

The treatment protocol includes three distinct, but successive steps: Orthodontic phases of preparation are enacted prior to surgical treatment. Generally speaking, the stability of expected results depends on both meeting pre-defined objectives for each step as well as on the smooth and proper course of treatment. Otherwise, it could also be compromised by incomplete orthodontic treatment and yield unfavorable outcomes in orthognathic surgery or functional occlusal imbalance following treatment (Figure 8). [8]

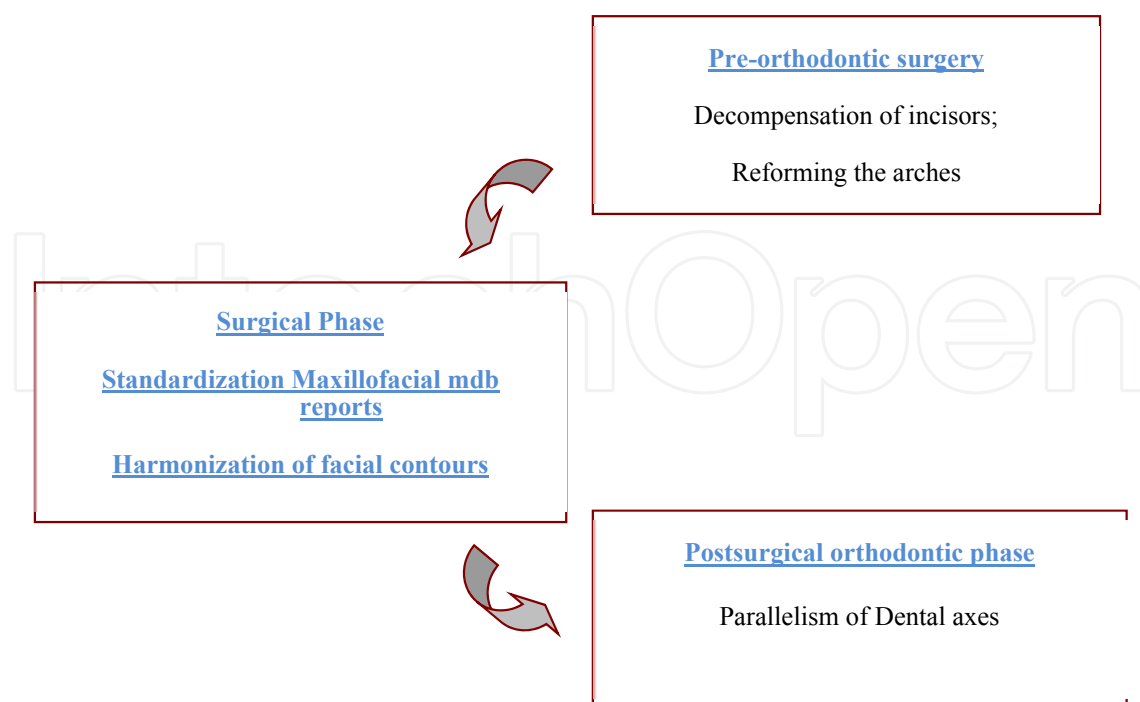
Successful surgical correction of dentoskeletal cases is determined by both pre- surgical-orthodontic treatment (which eliminates dental compensation), correct surgical planning, and postoperative orthodontic therapy applied to refine the patient's occlusion. Fixed appliances are normally used in both of these orthodontic stages.



### 3- Surgical treatment

140

The treatment protocol includes three distinct, but successive steps: Orthodontic phases of preparation are enacted prior to surgical treatment. Generally speaking, the stability of expected results depends on both meeting pre-defined objectives for each step as well as on the smooth and proper course of treatment. It could also be compromised by incomplete orthodontic treatment ; Unfavorable outcomes in orthognathic surgery or functional occlusal imbalance following treatment [8]. (Figure 8)



**Figure 8.** The aim of surgical correction is to achieve the right occlusal and skeletal relationships and correct esthetics simultaneously.

#### 4.1. Preoperative / pre-surgical orthodontic phase

In orthognathic surgery cases, orthodontic treatment objectives are for the most part different from those used in conventional orthodontics. The purpose of pre-surgical orthodontics is to position the teeth to the most desirable position in preparation for surgery, to restore the anteroposterior and vertical positions in addition to coordinating incisors. Two main elements must prevail during this first phase: Incisors decompensation and transverse and dental arch coordination. [1, 9]

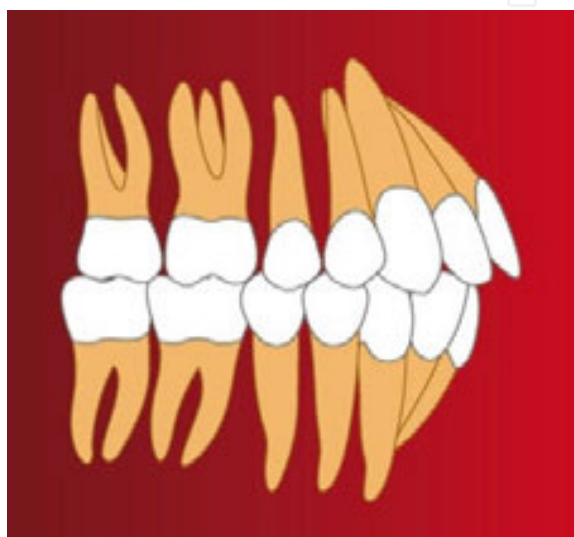##### 4.1.1. Anteroposterior dental decompensation

In the presence of a bone gap, teeth manage to maintain an occlusion with dental compensation in three dimensions.

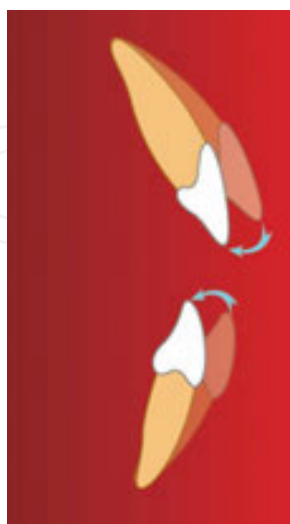
In the sagittal plane, overjet does not represent magnitudes of bone gap. However, during surgery, bone bases are mobilized to allow dental occlusion [10] in this context, it is clear that the relationship between anterior and posterior bases of incisors determines the magnitude of anterior-posterior relocation of the bone base. [11]

Presurgical orthodontic treatment aims to decompensate incisor inclination toward normal values. It is therefore necessary to define beforehand the objective of the "terminal incisor position". Therefore In the case of skeletal class II, the lower incisors are proclined while the upper incisors are lingual retroclined (Figure 9). In Class III, the reverse pattern is observed; upper incisors are proclined while the lower incisors are retroclined (Figure 13). Bone gap is

compensated for by teeth inclination [10] presurgical intra-arch objectives include positioning of the incisors in “ideal” positions, establishment of correct torque, and elimination of tooth-size discrepancies so as to permit the establishment of Class I canine and molar relationships after surgery. In orthognathic surgery cases, extraction patterns, and types of mechanics used are frequently the reverse of those used in conventional orthodontics. [11] Very often in skeletal Class II, the first premolars are extracted in order to cover mandibular incisors and obtain a Class I canine relationship. Extraction of the second premolars allows in recovery of the upper incisors and the mesial movement of upper molars. The ultimate goal is to achieve a Class I molar relationship (Figures 10- 12).



**Figure 9.** Dental compensation in skeletal Class II malocclusion



**Figure 10.** Direction of incisor decompensation in Class II malocclusion: the lingual inclination of the lower incisors is increased and in some cases (Class II.1 malocclusion), the upper incisors retroclined



This is achieved by using Class III elastics in Class II cases (and vice versa), thus allowing for modification of the underlying skeletal deformity.

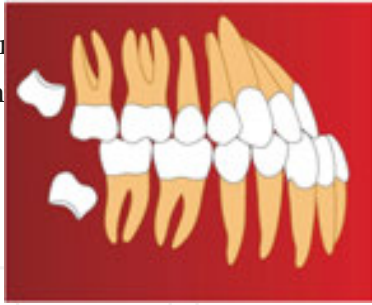

Figure 13: dental compensation in skeletal Class III malocclusion

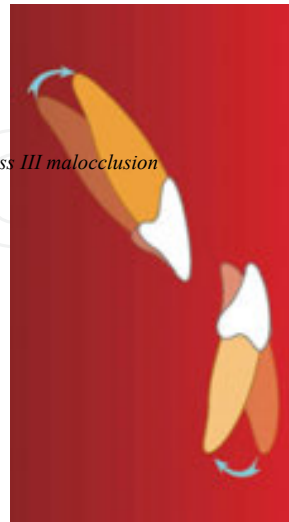

Figure 14: Direction of incisor decompensation in Class III malocclusion: the labial inclination of the lower incisors is increased and the upper incisors reduced

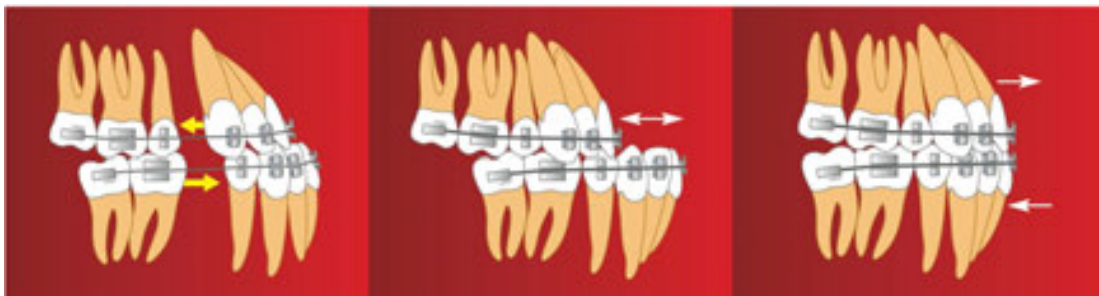

Figure 15: Classic pattern extraction of 14, 24, 35 and 45 in order to increase the negative overjet and presurgically decompensate the dental arches. Correct planning of the orthodontic tooth positioning before surgery will enhance the surgical potential and, hence, the esthetic result.

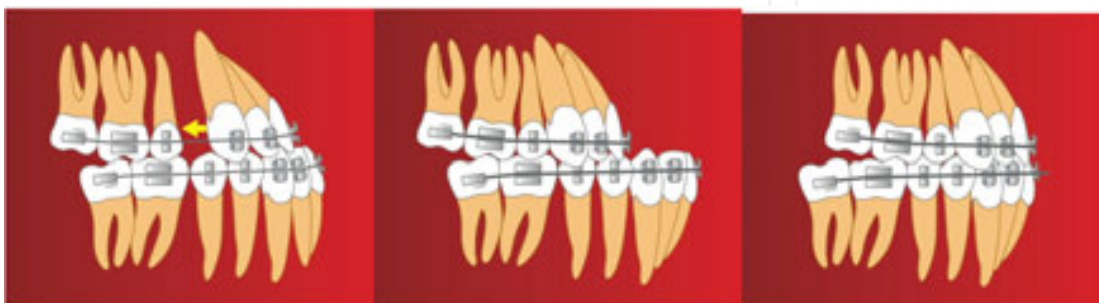


Figure 16: extraction of 14 and 24 is often sufficient and molar Class II acceptable.

#### Transverse arch Coordination

One goal of presurgical orthodontics is that maxillary and mandibular transverse diameters coincide for a reasonable intercuspitation after surgery. [10] It was clearly established that both vertical and horizontal recurrence correlates with dental arches incoordination and the persistence of occlusal interferences. The resulting occlusal imbalance is closely related to orthodontic preparation, sometimes without extraction [12] In the transverse plane, differentiation of skeletal from dental problems as well as identification of relative and absolute discrepancies should be carried out presurgically. Orthodontic or surgical expansion should be used, depending on individual circumstances. (Figure 17 ) [11]





#### 4.1.2. Transverse arch coordination

One goal of presurgical orthodontics is that maxillary and mandibular transverse diameters coincide for a reasonable intercuspation after surgery. [10] It is clearly established that both vertical and horizontal recurrence correlate with dental arches in coordination and the persistence of occlusal interferences. The resulting occlusal imbalance is closely related to orthodontic preparation, sometimes without extraction [12] in the transverse plane; differentiation of skeletal from dental problems as well as identification of relative and absolute discrepancies should be carried out presurgically. Orthodontic or surgical expansion should be used depending on individual circumstance (Figure 17).

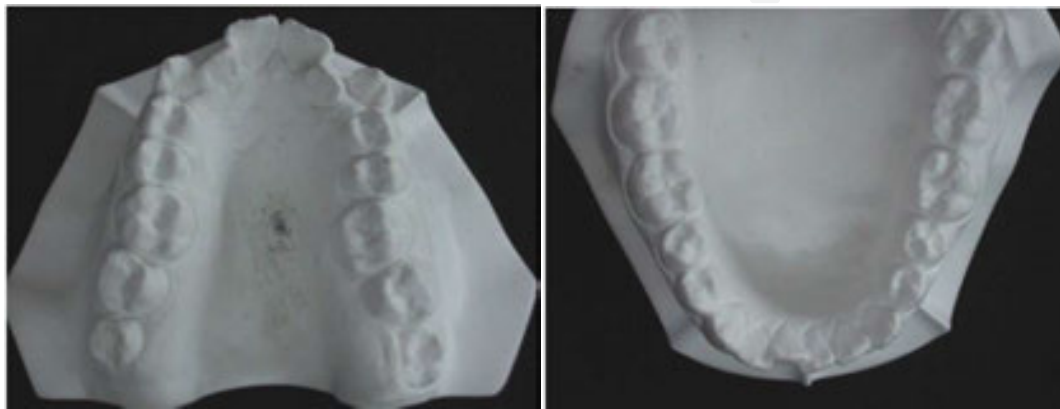

Figure 17: Dental arch width must be assessed preoperatively by measuring and comparing the distance between the mesiolingual cusps of the maxillary first molars versus the central fossae of the mandibular first molars. In this case, there are skeletal transverse deficiencies which must be corrected by surgical maxillary expansion.

In the absence of a major transverse problem, arch compatibility is generally achieved by coordination. [11] This is true for class II cases, where transverse shift goes unnoticed as revealed by the manipulation in the corrected position. This is a favorable orthodontic work so that both arches engage properly when the surgical mandibular advancement is performed.

Surgical disjunction or surgically assisted expansion can help to prevent transverse recurrence related to excessive teeth release. [10] Study casts carried out at the end of orthodontic preparation are essential; they allow rectifying any condition that may potentially lead to complications and thus affects the success and stability of the surgical procedure. [13]

#### 4.2. Surgical phase

The order of importance begins with the direction and amount of skeletal movement, the type of fixation used, and finally, the surgical technique. [3, 14] Other factors were also stated, namely, the maxillomandibular order or surgery-orthodontics [15- 17]

##### 4.2.1. Direction and amount of surgical movement

In a report on the hierarchy of stability in orthognathic surgery, Proffit ranked isolated maxillary advancement as the second most stable orthognathic surgical procedure after

### 3.2- Surgical phase

The order of importance begins with the direction and amount of skeletal movement, the type of fixation used, and finally, the surgical technique. [3, 14] Other factors were also stated, namely, the maxillomandibular order or surgery-orthodontics [15- 17]

maxillary upward positioning; the latter was performed more than maxillary advancement with or without mandibular setback. [13, 14]

#### *4.2.1.1. Maxillary upward*

Maxillary impaction is recommended in the case of patients with dolichofacial condition and vertical maxillary excess. Excellent skeletal stability is achieved in 90% of the cases, irrespective of the type of osteosynthesis used. [14] Such stability is due to the physiological occlusal adaptation related to mandible rotation. Interocclusal space is then maintained. [14, 18]

In asymmetry correction of the maxilla characterized by the inclination of the occlusal plane, surgery combines maxillary impaction and mandibular surgery. The maxillary component of this asymmetry correction is considered stable [19]

#### *4.2.1.2. Mandibular advancement*

Sagittal split ramus osteotomy (SSRO) is a well-established procedure for correcting mandibular retrognathism. [20] The literature contains a number of studies on postoperative changes after SSRO. At retention phase, relapse occurred due to the increase in mandibular plane and ANB angle, and an increase in overjet. [19, 21] The etiology of relapse is multifactorial, involving the proper seating of the condyles, the amount of advancement, the soft tissue and muscles, the mandibular plane angle, the remaining growth and the skill of the surgeon. [3, 8, 21] It is believed that orthosurgical treatment for the correction of Class II with mandibular advancement could be stable, provided the amount of skeletal movements and the circumjacent soft tissues are respected. Advancements over 10mm lead to horizontal relapse. [14, 21, 22] In systematic review that evaluate horizontal relapse in bilateral sagittal split advancement osteotomy, it was shown that advancements in the range of 6 to 7 mm or more predispose to horizontal relapse. [3]

#### *4.2.1.3. Maxillary advancement*

Maxillary advancement could be stable, provided that skeletal movements, as recommended by some others, were under 6, 8 or 10mm. In fact, the use of rigid fixation and bone grafting for good stability of maxillary advancement up to 6 mm showed no recurrence. [14, 19, 23-25] For a maxillary advancement of less than 8mm, it was suggested that the maxillary maintain its horizontal postsurgical position (less than 2 mm) in 80% of the cases; a risk of recurrence between from 2 and 4 mm can be seen in 20% of the cases. [25]

#### *4.2.1.4. Mandibular setback*

The sagittal split ramus osteotomy (SSRO) and the intraoral vertical ramus osteotomy (IVRO) are well-established procedures for correcting mandibular prognathism. Both techniques have advantages and disadvantages; include bony contact between the distal and mesial segments and application for both advancement and retraction and the duration of intermaxillary fixation (IMF). Orthognathic surgeons must weigh up these advantages and disadvantages when deciding which surgical treatment to use in cases of mandibular prognathism. Another

important factor for surgeons to consider is postoperative stability. While the literature contains a number of studies on postoperative changes after SSRO, a few reports concern postoperative stability after IVRO.

IVRO is a relatively simple technique, which is applicable for only retraction of the mandible. The postoperative changes and stability tend to be influenced by the surgical techniques employed and the skills of the surgeons. In the short term after IVRO, clockwise rotation was observed due a less bony contact between the proximal and distal segments during surgery. After this period of adaptive rotation, the mandible showed a slight tendency to relapse with forward movement up to 2 years after IVRO. [20] With bilateral sagittal split osteotomy setback (BSSO), the relapse is more frequent than vertical osteotomy. However, it is an effective treatment of skeletal class III and a stable procedure in the short and long term. Analyzing the different relapse rates in systematic review showed that main relapse mostly takes place immediate after surgery and in the short term. [2, 14] From the reviewed literature, it was conclude that skeletal relapse is very frequent and was influenced by the magnitude of surgical correction and the inclination of the ramus after surgery. But, compared with mandibular advancement BSSO, the amount of setback was correlated less frequently with the amount of relapse. Opinions differ and generally speaking, the father the distal segment is set back (more than 10mm), the greater the tendency for the proximal segment to rotate. Furthermore, maintaining the initial inclination of the ramus could therefore reduce the tendency to relapse. [2, 14, 22, 26] Other research suggested that post-operative relapse in mandibular setback surgery may relate to the pre-surgical skeletal pattern of each patient and the perimandibular connective tissue action. Additionally, some vertical mandibular relapse after setback surgery may be affected by the postural changes of the tongue and hyoid bone [26] However, it was reported that the role of suprahyoid muscles is less important after a mandibular setback than after advancement or a closing gap.[26,27] Correcting the open bite by orthognathic surgery directed only at the mandible has a high risk of relapse because of mandibular up-repositioning in a counter-clockwise rotation. A mandibular backward repositioning is equally performed to prevent open bite relapse. [28]

#### *4.2.1.5. Maxillary advancement combined with mandibular setback*

The mandibular setback is frequently combined with Le Fort I osteotomy for maxillary advancement when there is a greater discrepancy between the maxilla and mandible and greater labial projection. Surgical correction of Class III malocclusion after combined maxillary and mandibular procedures appears to be a fairly stable procedure for maxillary advancements up to 5 mm, independent of the type of fixation used to stabilize the mandible. Likewise, no statistically significant differences have been observed between the procedures conducted on both jaws versus the lower jaw only. [21, 29- 31] Over the past few years, the number of patients with mandibular prognathism as a component of a skeletal Class III problem who were treated with mandibular setback alone decreased remarkably, compared with outcomes in patients with two- jaw surgery. A number of reasons to explain such a tendency are listed below: [32, 33]

- Restricting the amount of mandibular setback by simultaneously advancing the maxilla contributes to stability.

- Facial appearance was better if simultaneous maxillary advancement allowed a smaller mandibular setback;
- Large setbacks lead to airway reduction
- The outcomes of isolated mandibular setback surgery were shown to be less predictable and less stable than desired.
- The better control of the ramus position when 2-jaw surgery is performed

#### 4.2.1.6. Maxillary expansion

Transverse maxillomandibular discrepancies are a major component of several malocclusions. The correction of skeletal transverse deficiency of the maxilla may be achieved surgically. [34]

The segmental maxillary osteotomy (SMO) is recommended when a moderate transverse defect of the maxillary bone in the amount of 5 to 6mm require correction. To increase the transverse diameter of the maxilla, maxillary expansion is simultaneously performed with Lefort I planned to correct all maxilla-mandibular discrepancies (vertical and sagittal repositioning). It consists at least to two osteotomy lines, one on either side of the palatine raphe, performed after orthodontic preparatory stage. [34, 35] Maxillary expansion is relatively simple, but treatment stability remains a common problem. Overcorrection and rigid osteosynthesis are recommended. In addition, the corrected maxilla should be reinforced with intraoral retention provided by a preformed palatal bar or splint. [14, 35]

The Surgically assisted rapid palatal expansion (SARPE) is used in cases of severe deficit estimated at more than 6 to 7mm; surgically-assisted maxillary expansion, which depends on osseous distraction osteogenesis the separating of segments of bone to create new bone and the movement of whole groups of teeth and their periodontium. This technique works by release of the maxilla bone resistances and assures excellent stability.

#### 4.2.1.7. Genioplasty

The chin is subject to morphological anomalies in the sagittal (retrogenia or progenia), vertical (excess or insufficient height), or transversal (laterogenia) axes. Genioplasty, used alone or in conjunction with other maxillomandibular osteotomies, is an important and reliable technique for the esthetic treatment of the lower facial skeleton. It can be a powerful procedure to improve the facial profile by modifying the position of the chin bones in three planes. Genioplasty is a stable surgical procedure when used in conjunction with rigid internal fixation. So there is no significant relapse after genioplasty and bilateral sagittal split osteotomy or genioplasty alone after 12 months. In fact, the changes are minimal and hard to detect clinically. [36]

#### 4.2.2. Osteotomy fixation (type and materials)

Osteotomy fixation technique is one of the factors that determine the horizontal and vertical postsurgical relapse potential. The short- and long-term outcomes of different fixation techniques are a topic of interest in the orthodontic literature. [37] In earlier years, maxillary



osteotomies were stabilized using intraosseous wires. In the 1980s, rigid internal fixation of osteotomy segments using miniplates and/or screws were introduced in an attempt to decrease postsurgical relapse and to allow earlier mobilization of the mandible. In fact, miniplates were introduced for fixation in BSSO, and have several advantages compared with bicortical screw osteosynthesis, because of the stretching of the musculature and paramandibular tissues, the bilateral compound joints, the masticatory forces, and occlusion. [27, 37] A number of studies that addressed the value of rigid internal fixation reported that 50% of the total forward relapse of mandible occurred during the 6 weeks after surgery. In contrast, with wire fixation and maxillomandibular fixation, the mandible maintained its position or moved posteriorly during MMF fixation. [33] On the other hand, in study which investigates biomechanical stability of RIF, the relationship between screw placement configurations and stability was demonstrated. It was concluded that bi-cortical screws with a 2.3-mm diameter and triangular configuration were considered as a sufficient fixation tool for BSSO than the linear configuration. [38] However, there is a trend toward increase in relapse from short-term to long-term studies when bicortical screws are used. [3] Bicortical screws of titanium, stainless steel, or bioresorbable material show little difference regarding skeletal stability compared with miniplates in the short term. A greater number of studies with larger skeletal long-term relapse rates were evident in patients treated with bicortical screws instead of miniplates. [3] The use of bicortical screws or monocortical screws, together with plates, is the most demanding fixation procedure of the craniofacial skeleton when used in mandibular advancement patients. [8] It was also shown that the use of BSSO of the mandible with or without counterclockwise rotation of the occlusal plane for anterior open bite correction, increases stability in the vertical direction. [39] Thus, some of the limitations of metal plates and screws used for the fixation of bones have led to the development of plates made from titanium. Such a technique has been in use in orthognathic surgery for about two decades, because of their high biocompatibility and resistance to corrosion. In addition, titanium fixation produces stability for the osteotomy site and allows patients to use their masticatory system functionally immediately after surgery. [40] The development of bioresorbable osteosynthesis devices made it possible to avoid second surgery to remove titanium plates linked sometimes to palpability, infectious complications or allergies; although they are rare. However, concerns remain about the stability which was related to the movements in orthognathic surgery. [26, 40] The systematic reviews of bioresorbable versus titanium fixation for orthognathic surgery, have shown that bioresorbable fixation systems produce reliable skeletal stability. [40] However, it suggested no statistically significant difference for plate and screw fixation using either titanium or resorbable materials. There are a few studies about the stability of biodegradable devices osteosynthesis and it was recommended that these materials should be used with caution for bony movements of greater magnitude until their usefulness is evaluated in studies with large maxillary advancements. [30]

### 4.3. Postsurgical orthodontics

Postsurgical orthodontic treatment involves finalization of the occlusion and retention. Working wire and light up and down elastics or slightly Class II or Class III elastics ensures

the refinement of the occlusion. This final stage is equally important to ensure stable results. It is not enough to place orthodontic retainers at the end of treatment. It is appropriate to finalize and fine-tune the occlusion with a view to achieve stability, function, and facial balance. [1, 41]

#### *4.3.1. Functional balance conditions*

Neutralizing the functional matrix at the end of treatment contributes significantly to stability of results. It is important to note that mastery of the neuromuscular environment is an important element of skeletal and dentoalveolar modeling of each patient. The stability of the result after treatment is therefore based on the diagnosis of muscle behavior, and functional rehabilitation.

This final phase of treatment is the best time to prescribe exercises for normalizing orofacial muscles and harmonizing skeletal relationships making rehabilitation more effective.

#### *4.3.2. Occlusion balance conditions*

The finishing and detailing phase, the last stage of active orthognathic surgery treatment, makes it possible to improve the occlusion, by adopting a number of criteria as defined by various authors; the ultimate goal is to improve the esthetic result, on the condition that treatment objectives during the pre-planning phase have been met.

Dental balance should be considered both statically and dynamically. Indeed, intra-arch condition inter-arch relationships, and balance provides functional comfort and lasting results.

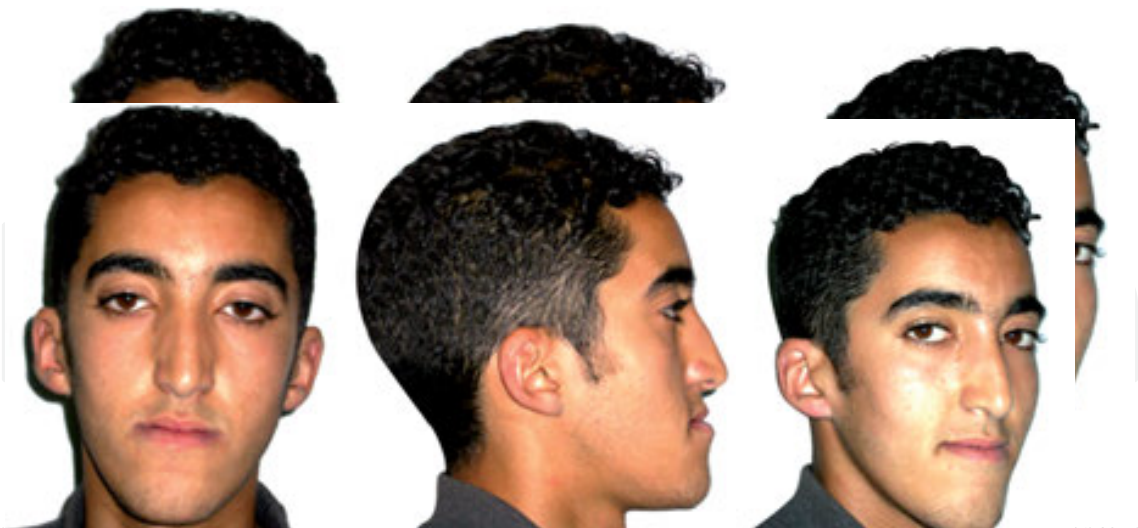Treatment stability depends in part on obtaining a "functional occlusion" consistent with the physiology of TMA. The quality of finishing for some researchers (Tweed) is sufficient as a natural retainer tool.

##### *4.3.2.1. The sequence of ortho-surgical treatment*

The sequence of steps of ortho-surgical treatment is illustrated through a clinical case: A 16-year-old patient reported aesthetic and psychological discomfort related to severe skeletofacial discrepancy. The patient also complained of functional difficulty during mastication and expressed concern at his inability to bite using the anterior sector of the dentition. In face and profile views, skeletal class III due to underdevelopment of the upper jaw and to mandibular deformity in frontal, vertical and sagittal dimension was noticed (Figure 18).

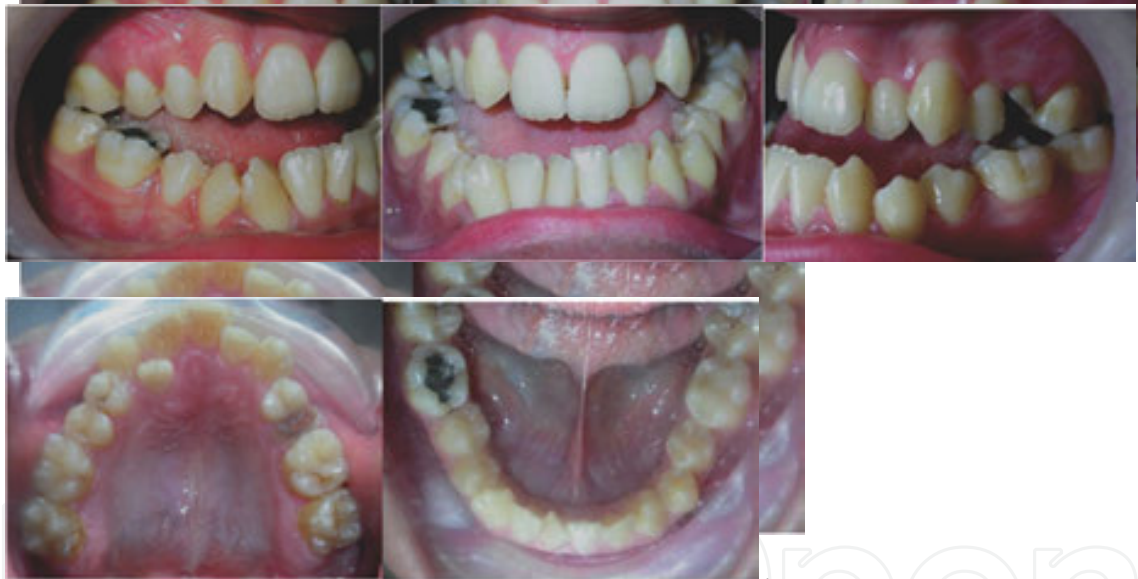Intraoral examination showed severe molar and canine Class III, the absence of overbite and the marked negative overjet. The crowding of the superior incisors was confirmed in occlusal view. The position of the incisors had evidently compensated for the skeletal malocclusion (Figure 19).

The lateral telerradiogram and relative cephalometric values confirmed the diagnosis of serious skeletal Class III (Figure 20).



**Figure 18:** A patient H. presented long and narrow face, concave profile, lack of upper lip support, with maxillary anteroposterior deficiency and mandibular anteroposterior excess. Clinically significant asymmetry of mandible to the right is present.

A patient H. presented long and narrow face, concave profile, lack of upper lip support, with maxillary anteroposterior deficiency and mandibular anteroposterior excess. Clinically significant asymmetry of mandible to the right is present.

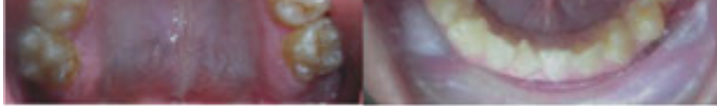

**Figure 19:** Pretreatment intraoral photographs: frontal, lateral and occlusion. The Class III malocclusion is characterized by an anterior and posterior crossbites. Crowding is present in both arches (palate-position of maxillary lateral incisors) due to narrow maxillary dental arch and compensated mandibular incisors.

Given the severe skeletal disharmony, the treatment plan suggested was orthognathic surgery to improve both esthetic and functional problems. The surgery was followed by presurgical preparation of dentition. The treatment plan consisted of extraction of the first maxillary premolars to align the anterior arch, eliminate compensations and to establish ideal incisor, and second mandibular premolars position (Figure 21). The outcome of this preparation is evident in the postorthodontic pretreatment intraoral and profile photographs and composite cephalometric tracing. The patient's facial profile was getting worse (Figures 22, 23).

	SNA	70°	
SNA	70°		
SNB	77°		
ANB	13°		
U1 to BO	118mm		
FMA	33°		
EMIA	73°		
IMPA	74°		
Occl. To SN	27°		
I to NA	33°/8mm		m
I to NB	15°/2mm		m





Combined Surgical and Orthodontic Management of Maxillofacial Deformities 151  
 Figure 19 : Pretreatment intraoral photographs: frontal, lateral and occlusion  
 The Class III malocclusion is characterized by an anterior and posterior crossbites . Crowding is present in both arches (palate-  
<http://dx.doi.org/10.5772/59164>  
 position of maxillary lateral incisors) due to narrow maxillary dental arch and compensated mandibular incisors

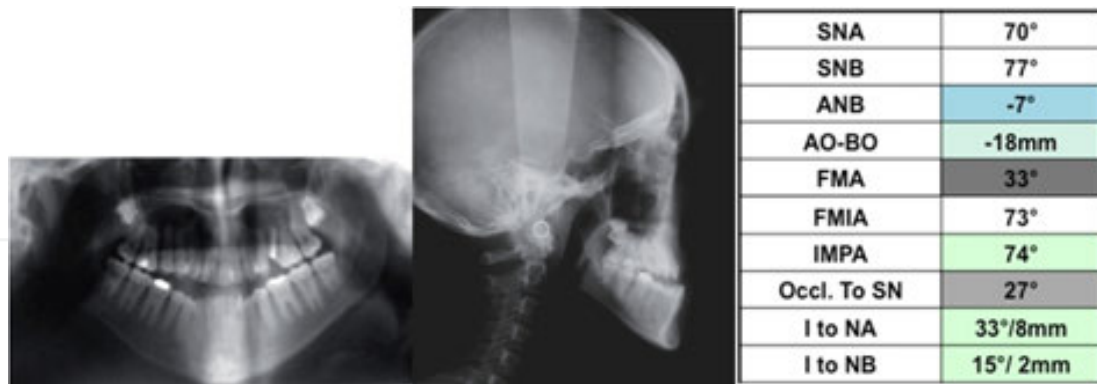

Figure 20. Pretreatment cephalometric radiograph and lateral cephalogram. The cephalometric radiograph shows mandibular disharmony and lingual inclination of mandibular incisors and protrusion of maxillary incisors. The surgery was followed by presurgical preparation of dentition. The treatment plan consisted of extraction of first maxillary premolars to align the anterior arch, eliminate compensations and to establish ideal incisor position, and second maxillary premolars. (Figure 21) The outcome of this preparation is evident in the postorthodontic presurgical intraoral and profile photographs.

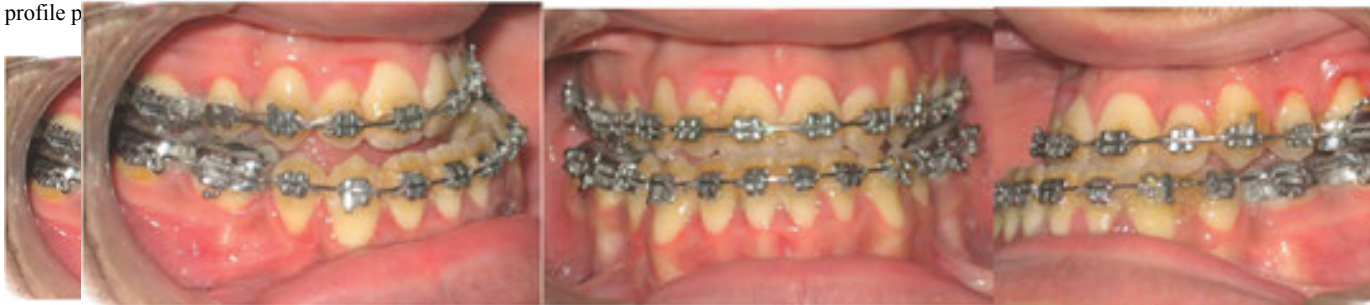

Figure 21: intraoral views after presurgical orthodontic preparation: immediate preoperative views and radiograph of patient. The objective of presurgical orthodontic preparation is to create a harmonious form of the maxillary and mandibular dental arches independently. The use of class III elastics is necessary to increase the labial inclination of the lower incisors and the negative overjet and presurgically decompensate for the malocclusion.

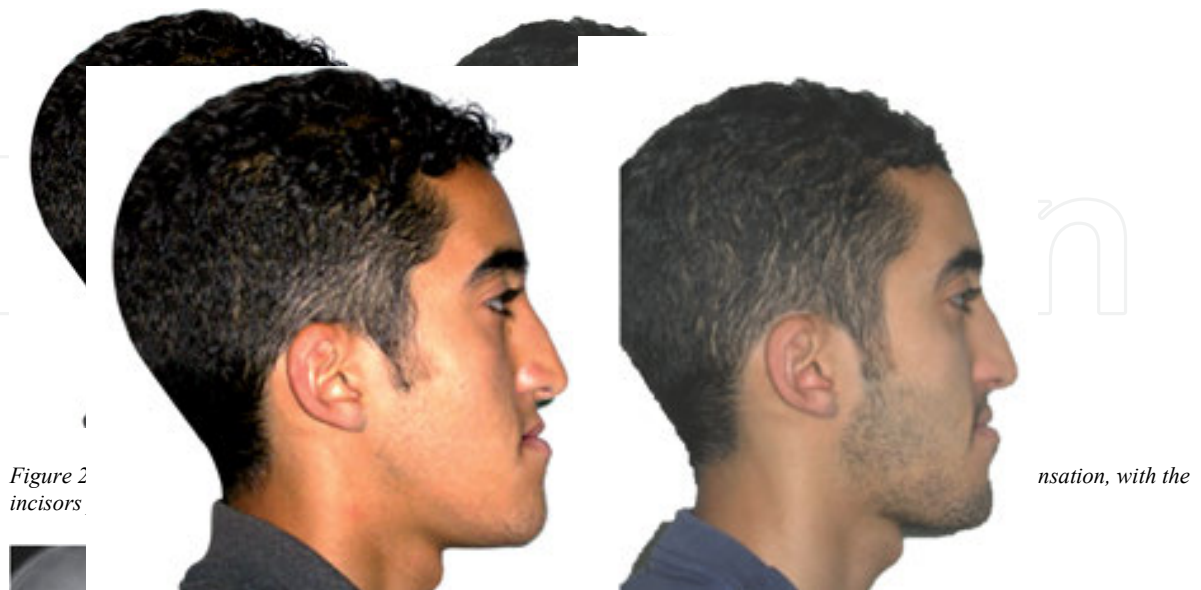
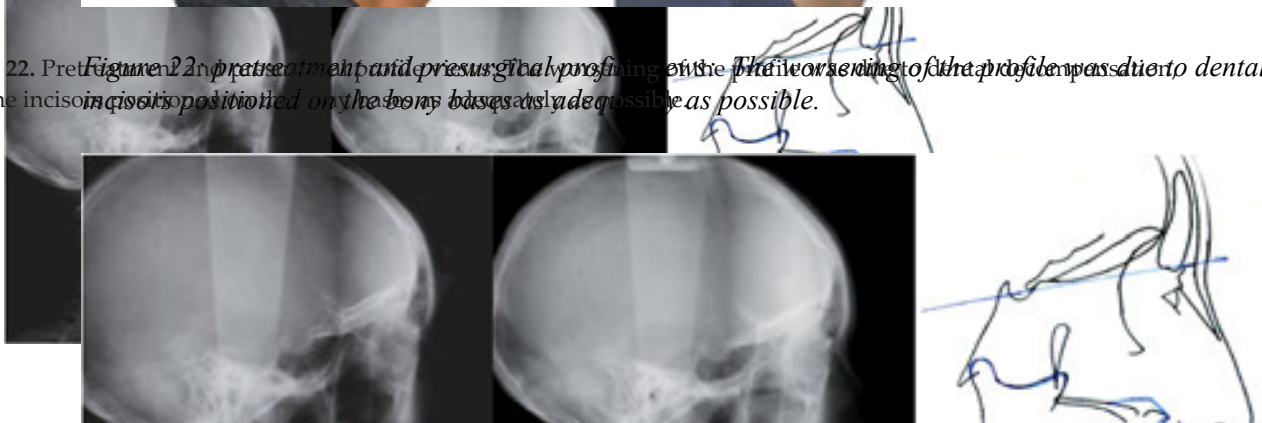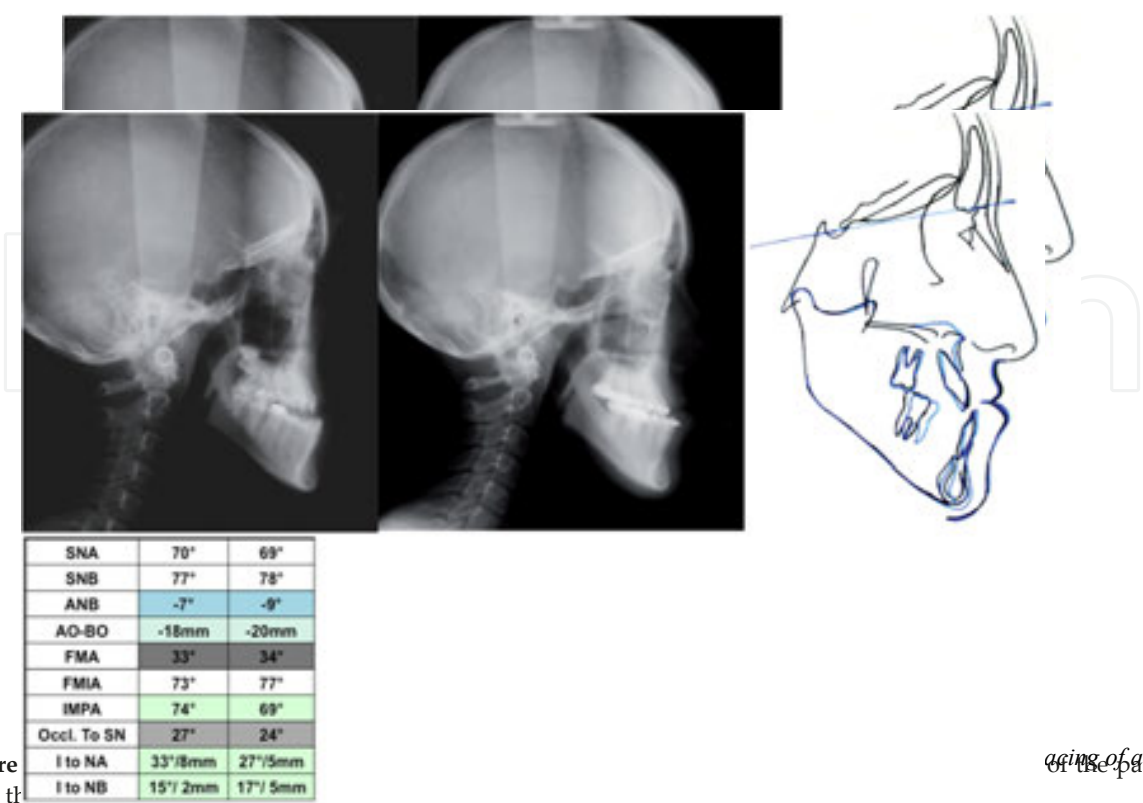


Figure 22. Pretreatment and presurgical profile photographs of the patient. The worsening of the profile was due to dental decompensation, with the incisors positioned on the bony bases as a decompensation, with the

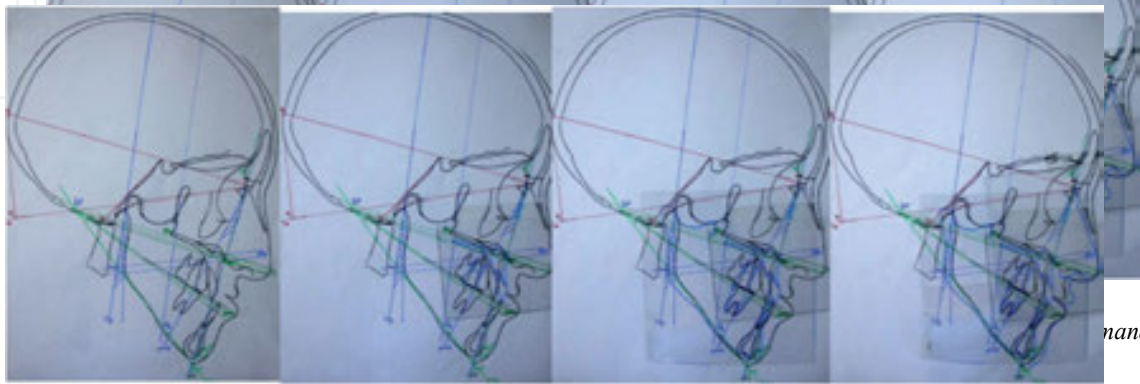




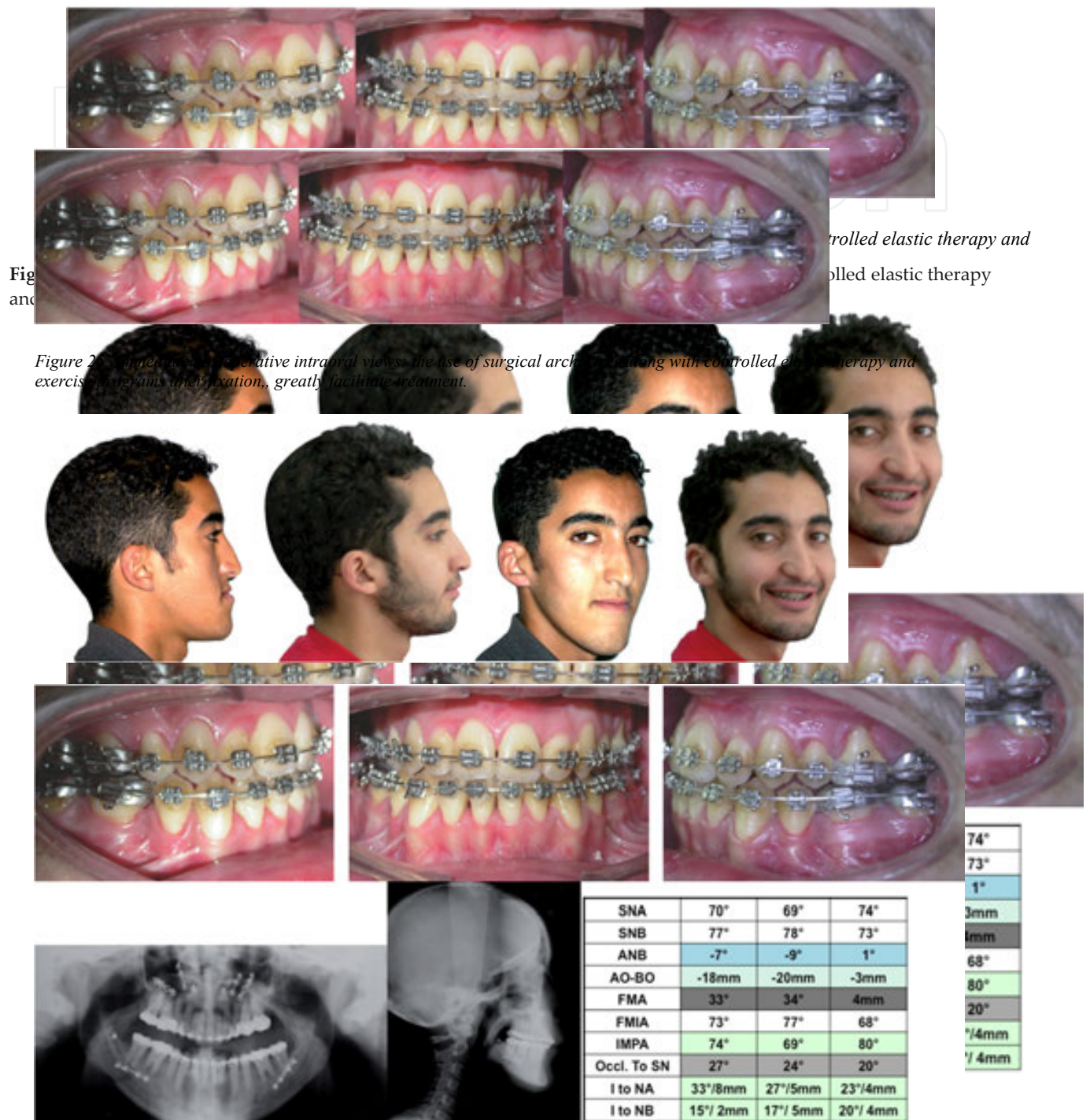


**Figure 24:** Preoperative and postoperative lateral teleradiographs and composite cephalometric tracings of a patient. Note the surgical advancement and mandible setback with counterclockwise rotation by means of LeFort I maxillary and sagittal split osteotomies.

Surgical visual treatment objectives are shown in figure 24. Two-jaw surgery was performed in this case. The maxilla was advanced and mandible setback with counterclockwise rotation by means of LeFort I maxillary and sagittal split osteotomies. The postoperative views show the resolution of the main issues, the establishment of a bilateral molar and canine Class I relationship and correct overjet and overbite. The satisfactory aesthetic result in terms of profile appearance and smile line is evident from the extraoral photographs, which also show correct upper incisor exposure and normalization of the position of the bony bases. The curve in the contour line is more harmonious after surgical advancement of the maxilla and mandibular setback. (Figures 25- 27)

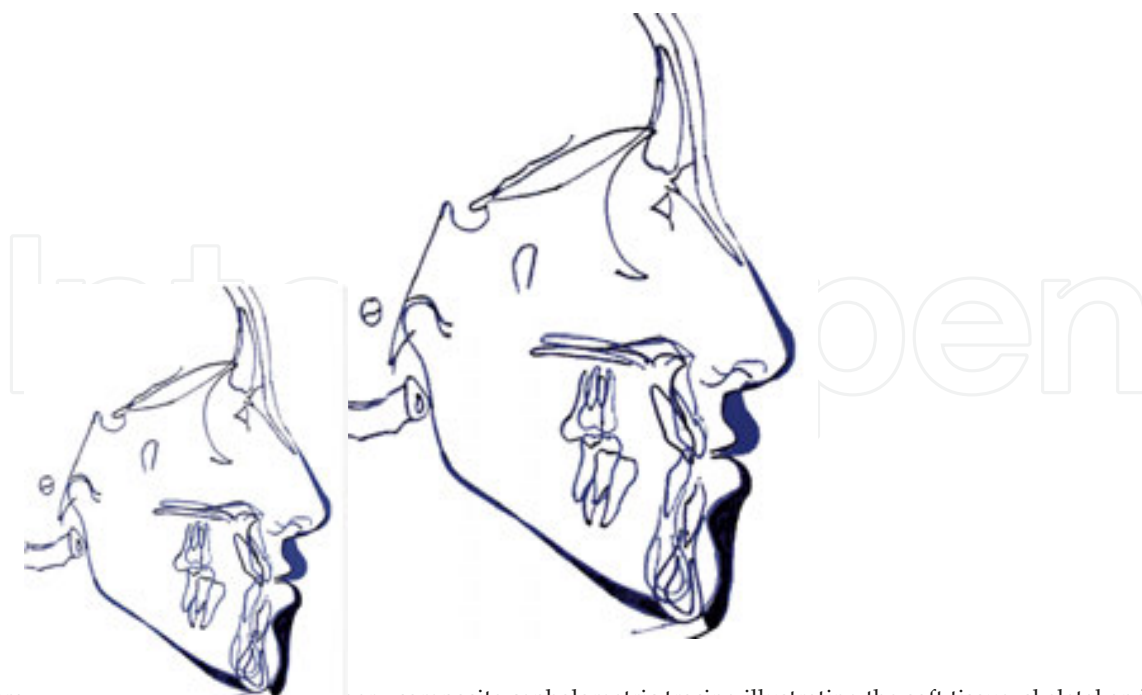


**Figure 25:** Lefort maxillary osteotomy to superiorly reposition and advance the maxilla to allow the mandible to autorotate and close the openbite.



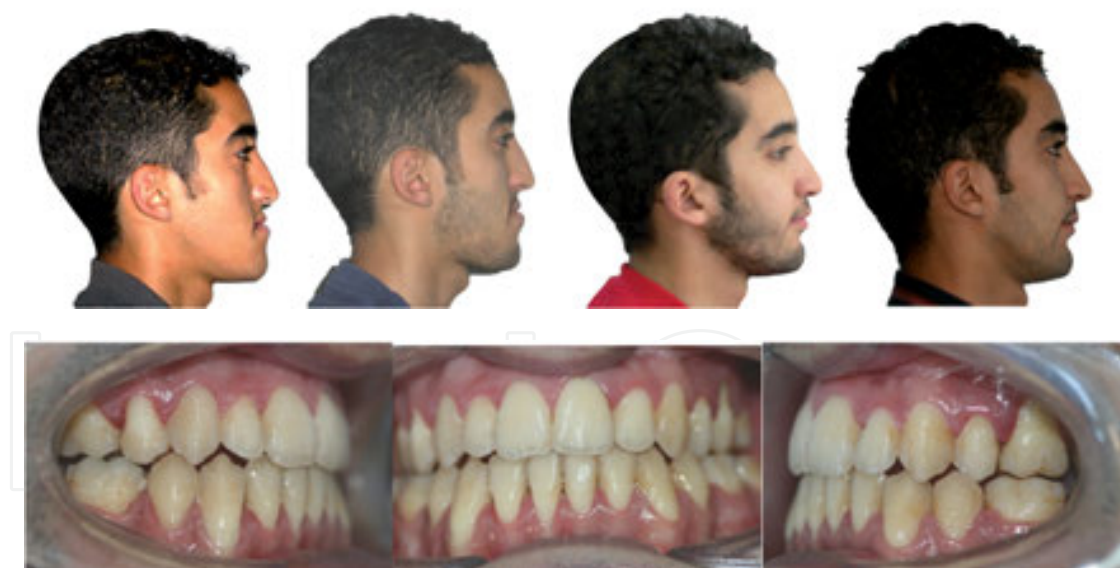*We can note the immediate postoperative changes and the osteosynthesis of the maxilla and the mandible with titanium miniplates and screws. So the Witts and the ANB values illustrate the re-equilibration of maxillomandibular relationship. .*  
*We can note the immediate postoperative changes and the osteosynthesis of the maxilla and the mandible with titanium miniplates and screws. The Witts and the ANB values illustrate the re-harmonization of the maxillomandibular relationship..*





**Figure 27:** Pretreatment and post-surgery composite cephalometric tracing illustrating the soft tissue, skeletal and dental changes.

The end results of treatment were gratifying (Figure 28). View the end results of treatment (Figure 28), we can conclude that benefit of repositioning incisive via Class II elastics, surgical expansion and genioplasty would allow to much better occlusal relationships and aesthetic results.



**Figure 28:** The changing profile during treatment and intraoral views after debonding

## 5. Conclusion

Stability of results depends on overall treatment plan. Successful treatment depends on a rigorous diagnosis and a treatment plan, a close collaboration between all the different actors involved; all of which are deal within predefined objetices using a highly rigorous diagnosis and a treatment plan. Successful treatment depends on a close collaboration between all the different members Moderate to severe skeletal deformities often requires a combined orthodontic and surgical approach for optimal function and best aesthetic results. Indeed, given the development of orthodontic and surgery techniques, this approach becomes a fully-fledged form of treatment which belongs, quite naturally, in the arsenal of treatment we can offer our adult patients.

Orthognatic surgery has created new and exciting oppotunities in the treatment of patients with dentofacial deformities and has relieved the orthodontist of having only compromised treatment to offer patients with skeletal disharmony.

involved; all of which deal within predefined objectives using a highly personalized approach. Moderate to severe skeletal deformities often require a combined orthodontic and surgical approach for optimal function and best esthetic results. Indeed, given the development of orthodontic and surgery techniques, this approach becomes a fully-fledged form of treatment which belongs, quite naturally, in the arsenal of treatment we can offer our adult patients. Orthognathic surgery has created new and exciting opportunities in the treatment of patients with dentofacial deformities and has relieved the orthodontist of having only compromised treatment to offer patients with skeletal disharmony.

One needs to be fully convinced that ortho-surgical treatments should be in no way viewed as a game of chance. The main focus of orthodontic treatment should be on obtaining and maintaining long-term clinically satisfactory stability results. Without stability, the achievement of good function and satisfactory aesthetics is obviously not successful.

## Author details

Sana Alami<sup>1</sup>, Hakima Aghoutan<sup>1</sup>, Samir Diouny<sup>2</sup>, Farid El Quars<sup>1</sup> and Farid Bourzgui<sup>1\*</sup>

\*Address all correspondence to: [faridbourzgui@gmail.com](mailto:faridbourzgui@gmail.com)

1 Department of Dento-facial Orthopedics, Faculty of Dental Medicine, Hassan II Ain Chok University in Casablanca, Morocco

2 Chouaib Doukkali University, Faculty of Letters & Human Sciences, El Jadida, Morocco

## References

- [1] Reyneke J P. Essentials of orthognathic surgery. China: Quintessence Publishing Co, Inc; 2003
- [2] Jos CU, Vassalli IM. Stability after bilateral sagittal split osteotomy setback surgery with rigid internal fixation: a systematic review. J Oral maxillofac Surg. 2008; 66; 1634-43
- [3] Jos CU, Vassalli IM, Stability After Bilateral Sagittal Split Osteotomy Advancement Surgery With Rigid Internal Fixation: A Systematic Review. J Oral Maxillofac Surg. 2009; 67; 301-13
- [4] Guglielmi M1, Schneider KM, Iannetti G, Feng C, Martinez AY. Orthognathic surgery for correction of patients with mandibular excess: don't forget to assess the gonial angle. J Oral Maxillofac Surg. 2013; 71 (6) 1063-72.



- [5] Jacobs JD, Sinclair PM. Principles of orthodontic mechanics in orthognathic surgery cases. *American Journal of Orthodontics*. 1983, 84 (5) 399-407
- [6] Brunel JM, Garcia C. Orthodontic – surgical synergy. *International Orthodontics*. 2006; 4; 155-97
- [7] Noguchi N, Tsuji M, Shigematsu M, Goto V. An orthognathic simulation system integrating teeth, jaw and face data using 3D cephalometry. *Int. J. Oral Maxillofac. Surg.* 2007; 36: 640–45.
- [8] Costa F, Robioni M, Polti M. Stability of sagittal split ramus osteotomy used to correct class III malocclusion : review of literature. *Int J Adult Orthod Orthognath Surg* 2001;16 (2) 121-29.
- [9] Kim CS, Lee SC, Kyung HM, Park HS, Kwon TG. Stability of mandibular setback surgery with and without presurgical orthodontics. *J Oral Maxillofac Surg.* 2014; 72 (4) 779-87
- [10] Sabri R. Objectifs orthodontiques en chirurgie orthognathique. *Rev Orthop Dento Faciale* 1995;29; 319-35.
- [11] Proffit WR, White RP. combined surgical orthodontic treatment: who does, what, when?. *Surgical orthodontic treatment*: Mosby; 1991.
- [12] Nam-Ki Lee, Young-Kyun Kim Jrba. Evaluation of post-surgical relapse after mandibular setback surgery with minimal orthodontic preparation, *Journal of Cranio-Maxillo-Facial Surgery*. 2013; 41 (1) 47- 51
- [13] Ariane Hohoff A, Meier N, Stamm T, Ehmer U, JoosU. Optimizing presurgical orthodontic planning by means of the transverse coordinate simulation system (TCSS). *Journal of Cranio-Maxillofacial Surgery*. 2002; 30; 75–86.
- [14] 56- Proffit WR, Turvey TA, Phillips C. Orthognathic surgery: a hierarchy of stability. *International Journal of Adult Orthodontics and Orthognathic Surgery*. 1996;11; 191-204.
- [15] Béziat JL, Babic B, Ferreira S, Gleizal A. Justification for the mandibular-maxillary order in bimaxillary osteotomy. *Rev Stomatol Chir Maxillofac*. 2009;110; 323-326.
- [16] Kim JY. Postoperative stability for surgery-first approach using intraoral vertical ramus osteotomy: 12 month follow-up. *Br J Oral Maxillofac Surg*. 2014: 1-6 <http://dx.doi.org/10.1016/j.bjoms.2014.03.011>
- [17] Liou EJW, Wang YC, Huang CS. Surgery-first accelerated orthognathic surgery: post-operative rapid orthodontic tooth movement. *J Oral Maxillofac Surg*. 2011; 69; 781-85.
- [18] Proffit WR, Phillips C, Turvey TA. Stability following superior repositioning of the maxilla by LeFort I osteotomy. *American Journal of Orthodontics and Dentofacial Orthopedics*. 1987; 92: 151-61.

- [19] Bailey LTJ, Cevidanes LHS, Proffit WR: Stability and predictability of orthognathic surgery. *Am J Orthod Dentofacial Orthop.* 2004; 126: 274-77.
- [20] Nihara J, Takeyama M, Takayama Y, Mutoh Y, Saito I. Postoperative changes in mandibular prognathism surgically treated by intraoral vertical ramus osteotomy. *Int. J. Oral Maxillofac. Surg.* 2013; 42: 62–70.
- [21] De Lir ALS, de Moura W L, Ruellas A C O, Souza MMG, Nojima LI. Long-term skeletal and profile stability after surgical-orthodontic treatment of Class II and Class III malocclusion. *Journal of Cranio-Maxillo-Facial Surgery.* 2013; 41; 296- 302.
- [22] Eggensperger N. Skeletal relapse after mandibular advancement and setback in single jaw surgery. *J oral maxillofac surg.* 2004; 62 pages
- [23] Bailey LT, Proffit WR, White RP. Trends in surgical treatment of Class III skeletal relationships. *International Journal of Adult Orthodontics and Orthognathic Surgery.* 1995; 10: 108-18.
- [24] Arpornmaeklong P, Heggie AA, Shand JM. A comparison of the stability of single-piece and segmental Le Fort I maxillary advancements. *Journal of Craniofacial Surgery.* 2003; 14: 3-9.
- [25] Proffit WR, Phillips C, Prewitt JW, Turvey TA. Stability after surgical-orthodontic correction of skeletal Class III malocclusion. 2. Maxillary advancement. *International Journal of Adult Orthodontics and Orthognathic Surgery.* 1991; 6: 71-80
- [26] Kim YK, Kim YJ, Yun PY, Kim JW. Evaluation of skeletal and surgical factors related to relapse of mandibular setback surgery using the bioabsorbable plate. *Journal of Cranio-Maxillofacial Surgery.* 2009; 37: 63-68.
- [27] Kraft T, Bouletreau P, Raberin M, Etienne C, Breton P, Freidel M. Severe class III skeletons: long-term stability. Retrospective analysis of 12 cases. *Rev Stomatol Chir Maxillofac,* 2004 ; 105 (3) 153-59.
- [28] Ito G, Koh M, Fujita T, Shirakura M, Ueda H, Tanne K. Factors related to stability following the surgical correction of skeletal open bite. *Aust Orthod J.* 2014; 30 (1) 61-6.
- [29] De Haan IF, Ciesielski R, Nitsche T, Koos B. Evaluation of relapse after orthodontic therapy combined with orthognathic surgery in the treatment of skeletal class III. *J Orofac Orthop.* 2013; 74: 362-369.
- [30] Costa F, Robiony M, Zorzan E, Zerman N, Politi M. Stability of skeletal Class III malocclusion after combined maxillary and mandibular procedures: titanium versus resorbable plates and screws for maxillary fixation. *J Oral Maxillofac Surg.* 2006; 64 (4) 642-51.
- [31] Politi M, Costa F, Cian R, Polini F, Robiony M. Stability of skeletal class III malocclusion after combined maxillary and mandibular procedures: rigid internal fixation

- versus wire osteosynthesis of the mandible. *J Oral Maxillofac Surg.* 2004; 62 (2) 169-81
- [32] Proffit WR, Phillips C, Turvey TA. Stability after mandibular setback: mandible-only versus 2-jaw surgery. *J Oral Maxillofac Surg.* 2012, 70: 408-14.
- [33] Proffit WR, Phillips C, Dann Ct, Turvey TA. Stability after surgical-orthodontic correction of skeletal Class III malocclusion. I. Mandibular setback. *International Journal of Adult Orthodontics and Orthognathic Surgery.* 1991; 6 :7-18.
- [34] Suri L, Taneja P. Surgically assisted rapid palatal expansion: A literature review. *Am J Orthod Dentofacial Orthop.* 2008; 133: 290-302.
- [35] Bouletreau P, Paulus C. Surgical correction of transverse skeletal abnormalities in the maxilla and mandible. *International Orthodontics.* 2012 ; 10 : 261-73.
- [36] Talebzadeh N., Pogrel MA. Long-term hard and soft tissue relapse rate after genioplasty. *Oral Surg Oral Med Oral Pathol Oral Radiol Endod.* 2001; 91(2) 153-6.
- [37] Solano-Hernández B, Stylianos Antonarakis G, Scolozzi P, Kiliaridis S. Skeletal Anterior Open-Bite Malocclusion: A Systematic Review on Vertical Stability. *J Oral Maxillofac Surg.* 2013; 71: 98-109.
- [38] Ming-Yih L, Chun-Li L, Wen-Da T, Lun-Jou L. Biomechanical stability analysis of rigid intraoral fixation for bilateral sagittal split osteotomy. *Journal of Plastic Reconstructive & Aesthetic Surgery.* 2010; 63: 451-55
- [39] Nieblerova J, Foltá R, Hanzelka T, Pavlíková G, Vik M, Klíma K, Samsonyan L. Stability of the miniplate osteosynthesis used for sagittal split osteotomy for closing an anterior open bite: an experimental study in mini-pigs. *Int. J. Oral Maxillofac. Surg.* 2012; 41; 482–88.
- [40] Yang L, Xu M, Jin X, Xu J, Lu J, Zhang C, Li S, Teng L. Skeletal stability of bioresorbable fixation in orthognathic surgery: A systemic review. *Journal of Cranio-Maxillo-Facial Surgery.* 2013, 1- 6
- [41] Fourquet L, Göttle M, Bounoure G. Finishing and detailing, stability and harmony. *Orthod Fr.* 2014 ; 85 (1) 93-125.