

We are IntechOpen, the world's leading publisher of Open Access books Built by scientists, for scientists

6,900

Open access books available

186,000

International authors and editors

200M

Downloads

Our authors are among the

154

Countries delivered to

TOP 1%

most cited scientists

12.2%

Contributors from top 500 universities



WEB OF SCIENCE™

Selection of our books indexed in the Book Citation Index
in Web of Science™ Core Collection (BKCI)

Interested in publishing with us?
Contact book.department@intechopen.com

Numbers displayed above are based on latest data collected.
For more information visit www.intechopen.com



Advanced Techniques in Rhinoplasty

Behnam Bohluli and Payam Varedi

Additional information is available at the end of the chapter

<http://dx.doi.org/10.5772/59745>

1. Introduction

Basic techniques of rhinoplasty are known to experienced aesthetic surgeons; however, post-traumatic nasal deformities, secondary cases and ethnic demands require advanced techniques. These modern techniques are generally aimed to provide a more normal looking nose while a great attempt is made to preserve or return the normal function of the nose while improving some existing functional shortcomings during the surgery. This chapter presents a problem-based approach to some complex nasal deformities. Current solutions to each deformity are presented and advantages and limitations of each technique are discussed.

2. Nasal tip deformities

2.1. Under-projected tip

Many techniques are known to increase tip projection all of which may be effectively used according to patient's special needs and indications:

1. **Tip sutures:** A tip spanning suture is a mattress suture that is used on each dome area to refine the angle between lateral crura and medial crura cartilages (Figure 1). This suture has been shown to increase tip projection.
2. **Cap graft:** Cap graft is a small piece of cartilage that is precisely formed and trimmed and fixed over the cartilaginous tip (Figure 2). The main indication of this graft is necessity to form and refine the tip; though this graft slightly increases tip projection in this technique.
3. **Shield graft (Sheen graft):** The shield graft is the only technique that may arbitrarily add to tip projection. A usual approach is to prepare and fix a bigger piece of cartilage. This

oversized graft is incrementally trimmed and tailored until the ideal tip projection and contour is achieved (Figure 3).[1,8]

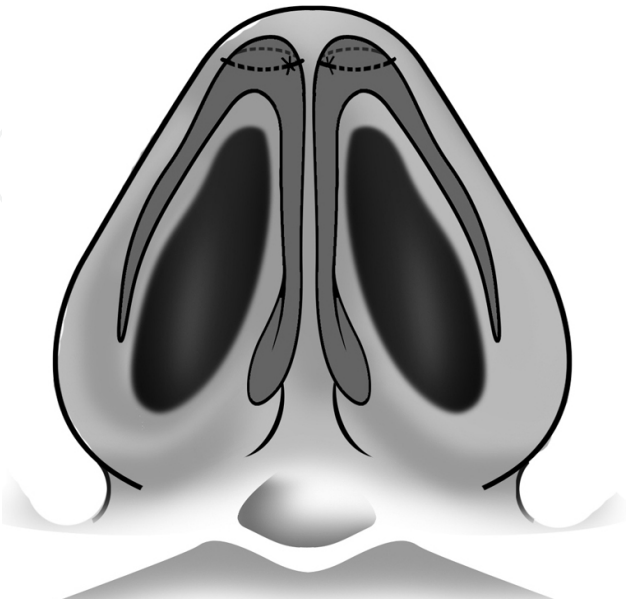


Figure 1. Tip spanning suture

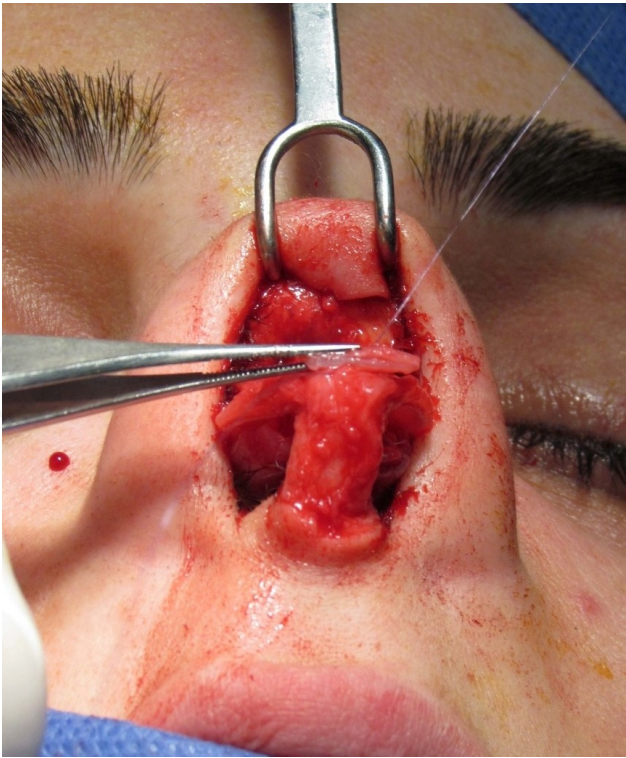


Figure 2. Cap graft

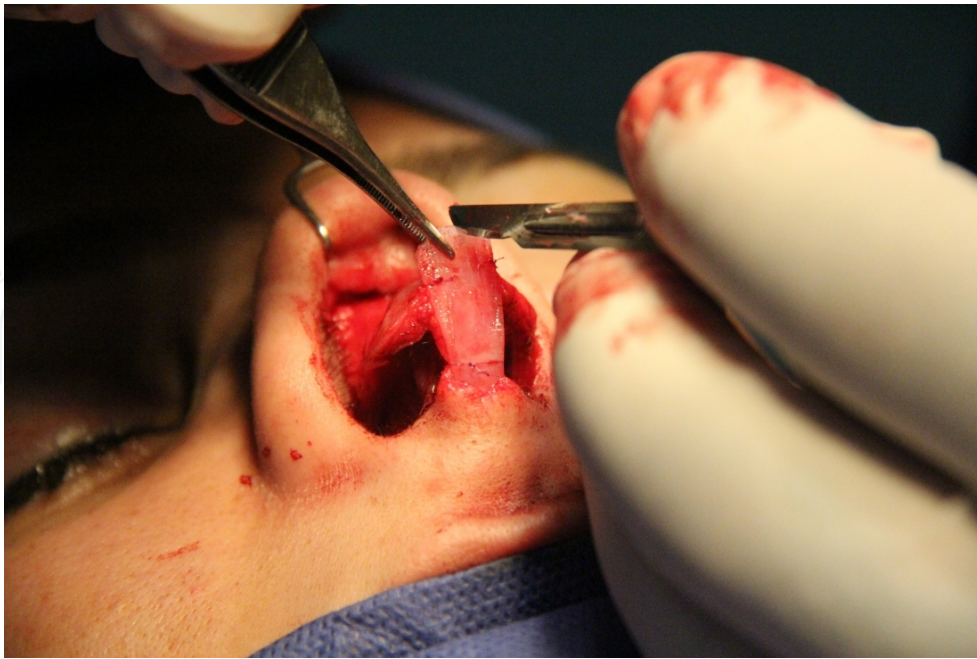


Figure 3. Shield graft (Sheen graft)

2.2. Over-projected tip

An over-projected nasal tip is a common finding that must be detected in preoperative assessments. Two general groups of techniques are applied to decrease the projection for all over-projected noses. In the first group it is tried to sever normal tip support mechanisms that will result in small decrease in tip projection. In the second group lower lateral cartilages are interrupted in some parts. A few millimeters of cartilage are resected and a new tripod with smaller limbs is formed.

1. Transfixion incision: All the resective techniques that are done on lower lateral cartilages may decrease the projection; although, the transfixion incision is the only one that is specifically done to decrease projection of the nose. This incision may decrease projection up to 3 mm (Figure 4).
2. Dome splitting: In this technique lower lateral cartilages are divided in dome area, then a few millimeter of excessive cartilage is resected and a new dome is formed by precise suturing. A small piece of crushed or morselized cartilage may be placed over dome area to cover the sutures and sharp edges of cartilages^[9,13]

2.3. Drooping tip

There are many modalities to correct the drooping tip or acute nasolabial angle.

1. **A wedge is sometimes resected** from the caudal part of the septum to provide enough space for tip rotation (Figure 5).

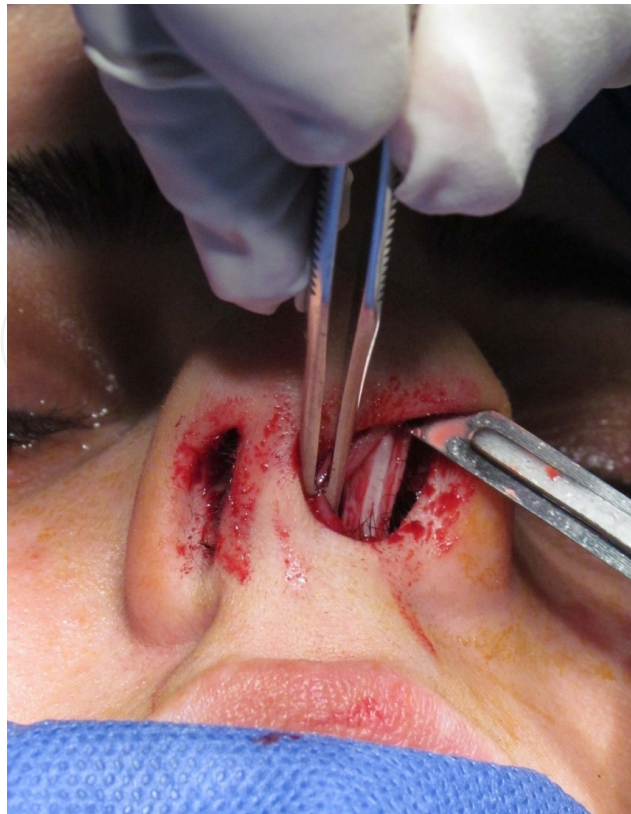

Figure 4. Transfixion incision

2. Cephalic trimming of lower lateral cartilages and

3. Collumellar strut insertion

These are other modalities that are basically done to increase nasolabial angle. In case basic techniques fail to provide the ideal result, the following techniques may be effectively applied [14,16]

4. Tip rotating suture

This is an effective method to increase and hold the nasolabial angle. In this technique a mattress suture is used to anchor lower lateral cartilages to the nasal septum, by incremental tightening of the suture, ideal nasolabial angle is achieved, then with several subsequent ties this nasolabial angle is fixed and stabilized.

2.4. Important points

Tip rotating suture easily changes the tip position, though it is clear that a single suture suspension may lose its effect gradually and will not lead to permanent results; to achieve stable results, tip support mechanisms should be improved (i.e. application of collumellar strut) and appropriate space be provided for new tip position (i.e. conservative cephalic trimming and caudal resection of septum) [17,18]

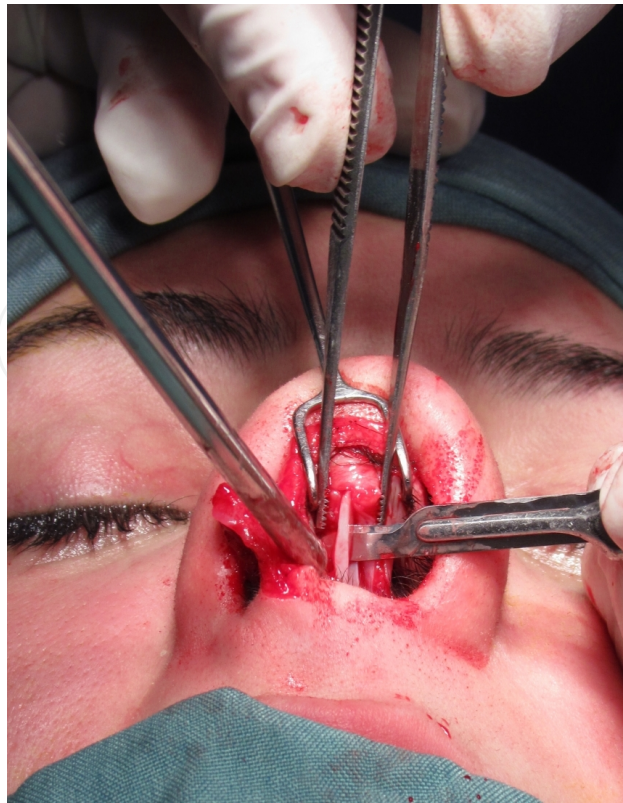

Figure 5. A wedge is resected from caudal part of the septum to provide enough space for tip rotation.

3. Tongue in groove

In this technique two medial crura cartilages are completely separated from each other. Then upper lateral cartilages are stripped off the nasal septum. Medial crural cartilages are pushed back in a way that each medial cru covers the nasal septum on one side. A delicate needle is used to temporarily fix the medial crura cartilages to the septum. Skin flap is turned back to its original position for several times. When the ideal nasolabial angle is achieved, medial crura are fixed to the septum with several PDS sutures. In this method the lower lateral cartilages (nasal tip) are permanently fixed to the nasal septum. [19]

4. Lateral crural anchorage flap

In this technique, excessive parts of the lateral crural cartilages that are routinely excised and resected in tip plasty are marked on both sides. Cartilage incisions are made and excessive cartilage is separated from its underlying skin in a way that its medial attachments remain intact. Excessive cartilages are easily omitted while two cartilage flaps with a strong attachment to medial crural cartilage are available. These two flaps are used to rotate the nasal tip. Cartilage flaps are fixed with a needle to the nasal septum. The maneuver may be done for several times to find the ideal tip position. Then the flaps are precisely fixed with sutures to the nasal septum. [17]

4.1. Important points

This technique is based on two cartilage flaps that are in fact excessive parts of the lower lateral cartilages. These cartilages are supposed to be trimmed and resected in normal rhinoplasty. It is clear that in weak cartilage, or in case a small strip of cartilage is to be trimmed this approach will not be possible.

4.2. Weak lower lateral cartilages and pinch deformity

Strength and consistency of lower lateral cartilages play an important role in shape and function of the lower one third of the nose. Many techniques have been proposed to reinforce and reshape the lower lateral cartilages; all may be used in specific indications:

1. **Batten grafts:** a batten graft is a thin oval piece of cartilage that is used over deficient or weak cartilaginous part of the nose to reshape and reinforce the nose. This graft is frequently fabricated from septal cartilage or chonchal cartilage. It may be used on one side or bilaterally according to specific needs and indications. [20,22]
2. **Lateral crural strut graft:** Unlike batten grafts the lateral crural strut graft is placed beneath the lower lateral cartilages, so after adequate injection of local anesthetic under the lower lateral cartilages, the lateral crura is precisely stripped off from its underlying skin and a quadrangular piece of cartilage is fixed under the lateral crura.

This technique:

- a. Restores pinch deformities
- b. Reinforces external nasal valve
- c. Corrects moderate to severe cephalic positioning of lower lateral cartilages [23,24]
- d. **Alar contouring grafts:** Alar contour or alar rim grafts are quite simple and effective techniques frequently used for several aesthetic and functional indications. These grafts are narrow strips of cartilage placed in a pocket anterior to the lower lateral cartilages. This graft is made from septal or chonchal cartilage.

Indications:

- a. To reinforce external nasal valve
- b. To correct minor cephalic positioning of lower lateral cartilages
- c. To provide a pleasant nostril borders [25]
- d. **Lateral crural transposition flap:** In this technique excessive parts of lower lateral cartilages that are usually trimmed and discarded in rhinoplasty, are folded inside, in this way, wide lateral crural cartilages are reshaped while excessive cartilage is used to reinforce the lateral crural cartilage. [26]

5. Dorsal problems

5.1. Shallow radix

In some patients pre-operative evaluations show that radix augmentation will help gain a pleasant aesthetic appearance. A complete familiarity with common autografts, their potentials and limitations will help the surgeon to select a predictable and stable graft with acceptable results in each specific indication. [27,28]

5.2. Low dorsum

Augmentation of a low dorsum is an important task in current concepts of rhinoplasty. Many modalities and techniques are proposed, though all of them have their own advantages and disadvantages and no one technique seems to cover all the indications for dorsal augmentation. Proper case selection and familiarity with characteristics of each technique are prerequisites for a successful dorsal augmentation.

5.3. 1-rib graft

Rib grafts are extensively used in reconstructive nasal surgery. Considerable amounts of cartilage and bone, acceptable mechanical properties such as strength and load bearing as well as its resistance to resorption has made it the gold standard for massive cartilaginous augmentations and reconstructions. Availability of other autografts, potential drawbacks of rib cartilage and patient compliance has limited its use to severe deformities and the need for excessive amount of graft material.

5.4. Important points

Graft distortion (warping) is a common complication in rib cartilage grafting. Many modalities have been proposed to control this unwanted effect. Some authors drill the core of the graft with a long delicate orthopedic bur and insert a strong Krishna wire to control any possible distortion. Sometimes it is thought that core of the graft has the least potential for warping so it is suggested to trim the periphery of the graft and to use the core of rib cartilage as the graft material.[29,31]

6. Temporalis fascia

Temporalis fascia is a well-established augmentation material in rhinoplasty. To harvest temporalis fascia, after proper application of local anesthesia, a 5 cm incision is done in posterior neck hair line with anterior and upward dissections adequate access is gained to the superficial layer of the deep temporalis fascia. Adequate amount of fascial tissue is harvested and the donor site is precisely sutured after complete control of bleeding. Temporalis fascia provides a soft and smooth layer that may cover dorsal irregularities. It may be used for

minimal dorsal augmentations and for greater amounts of augmentation it should be combined with other grafting techniques otherwise alternatives may be selected. [32,33]

6.1. Postauricular fascia

Postauricular and mastoid fascia provide a thick fascial tissue that is easily harvested with a 4cm curvilinear incision exactly behind the ears; incision lines are completely concealed behind the ears in normal skin creases and the risk of complications comparing to donor sites in the temporalis fascia is quiet low. This fascial tissue may be used in moderate dorsal augmentations (Figure 6). [34]

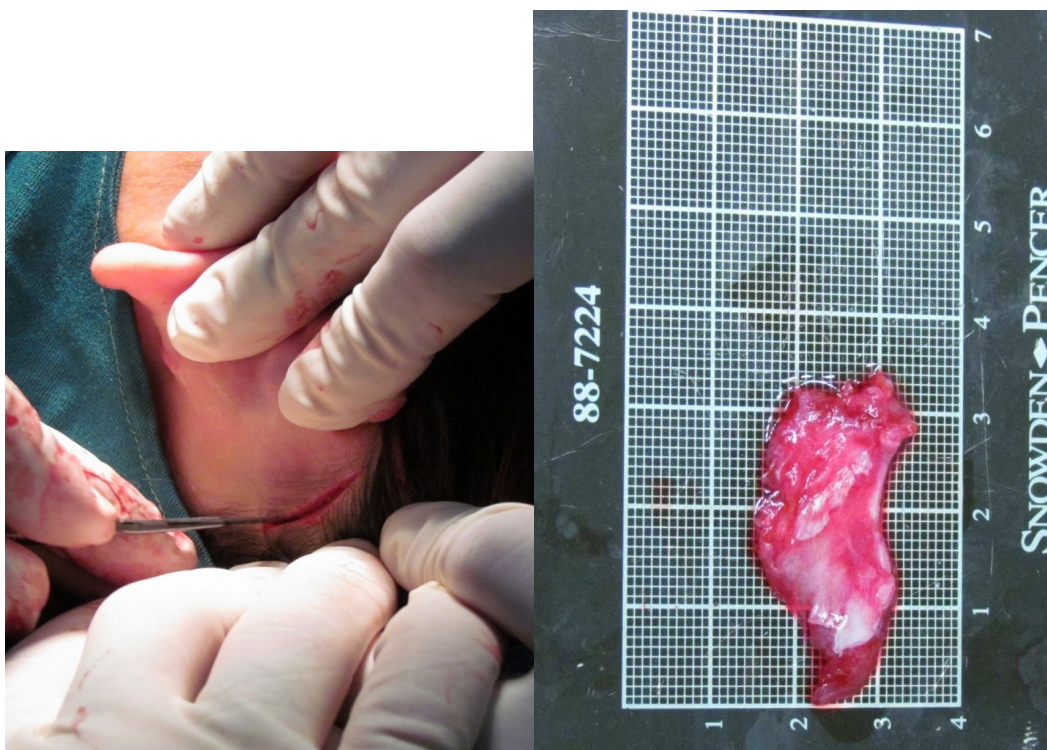


Figure 6. Post-auricular fascia harvesting

6.2. Turkish delight

Turkish delight is an efficient technique that was originally designed by Erol in 2000. This technique was aimed to solve essential problems that were frequently encountered in the use of cartilage blocks from the nasal septum or ribs. In Erol's original report rib cartilage was delicately diced into small particles, then soaked in blood and wrapped in Surgicel. Daniel wrapped the diced cartilages in temporalis fascia to omit the unpredictable behavior of Surgicel (oxidized cellulose) coverage. Diced cartilage wrapped in fascia is now commonly utilized in augmentation rhinoplasty and is reported to have acceptable results (Figure 7). [35,36]

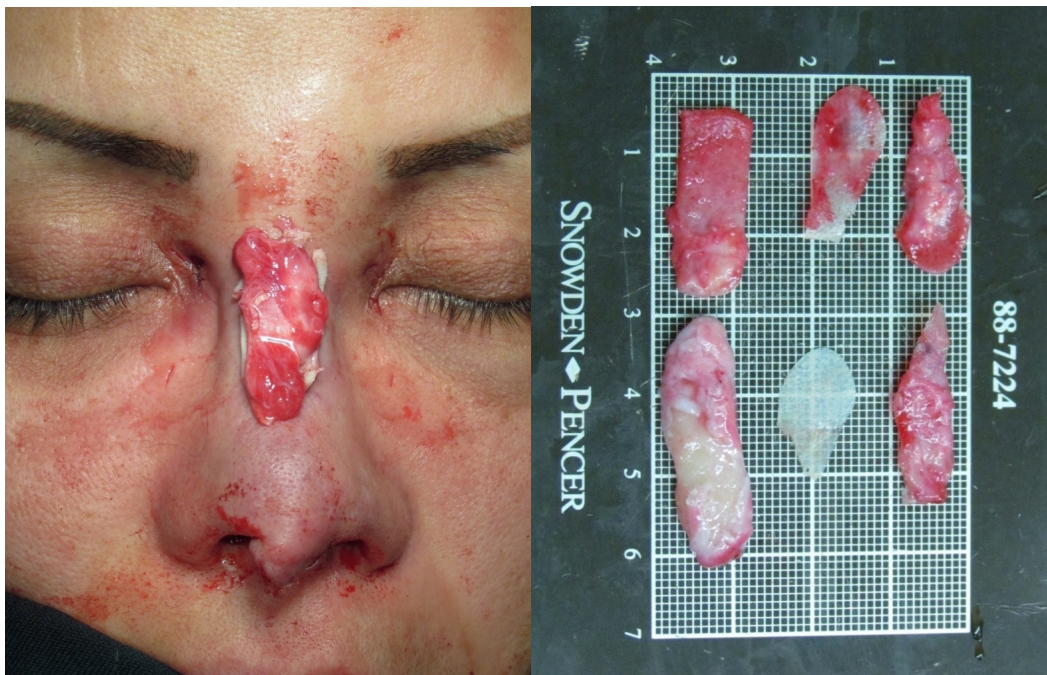

Figure 7. Turkish delight

6.3. Fascia-cartilage sandwich technique

Fascia-cartilage sandwich is reasonable alternative to rib grafts. In this technique temporalis or mastoid tissue is harvested, cartilage block from nasal septum or chonchal tissue is trimmed and formed in its ideal contour, and then it is covered with fascia. In fact cartilage provides the bulk of augmentation material and fascia covers the possible irregularities and shadows of a cartilage block graft [37]

6.4. Internal nasal valve incompetency

Sometimes pre-operative evaluations show that one or both internal nasal valves are incompetent and do not work well. On the other hand in major hump resections (more than 3mm); nasal valve reconstruction will be necessary. For this reason, internal nasal valve reinforcement is commonly indicated and may be indicated in most cases. The followings are some of effective valve reinforcement techniques:

1. **Spreader graft:** Spreader grafts were first introduced in 1981 by Jack Sheen and are now considered the gold standard in internal nasal valve reinforcements. A spreader graft is a piece of quadrangular cartilage that is placed between upper lateral cartilage and septum. Spreader grafts are usually used on both sides though due to some specific needs such as asymmetries unilateral spreaders may be utilized. [39]
2. **Autospreader:** In this technique, after incremental trimming of the nasal septum, the upper lateral cartilages are folded inside. It is thought that this technique prevents unnecessary graft harvesting and will provide the same effects as spreader grafts though

the main advantage of this technique is its reversibility and when an ideal result is not obtained intra-operatively, the sutures can be removed. Upper lateral cartilages are conservatively trimmed and other standard valve reconstruction techniques such as spreader grafts may be applied (Figure 8).[40-42]

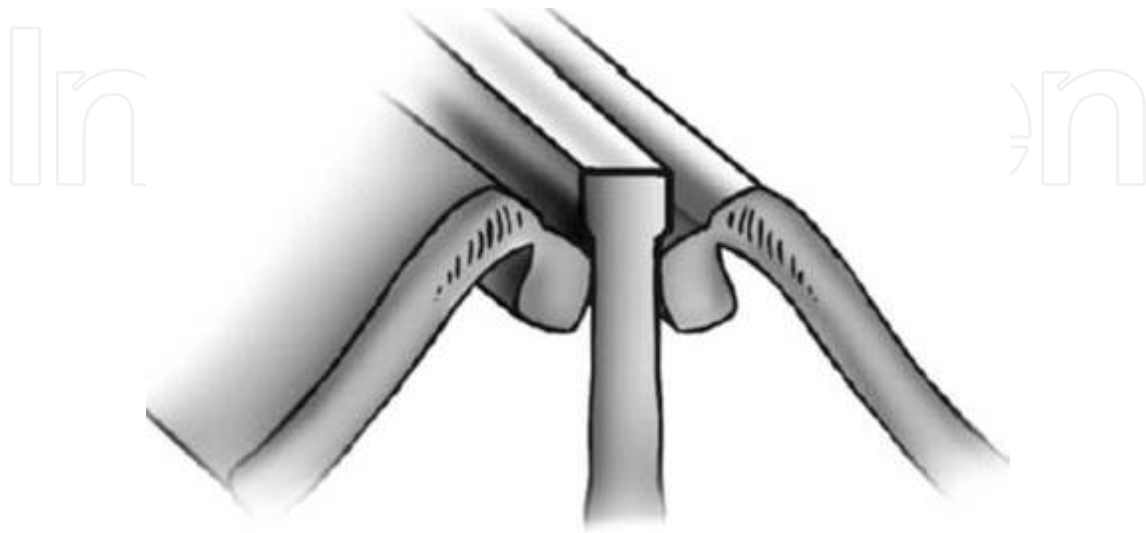


Figure 8. Autospreader

3. **Docile splay graft:** The docile splay graft is a piece of septal cartilage that is gently crushed and is placed over the nasal septum in a way that it covers the nasal septum and the two upper lateral cartilages are located laterally to the graft. It is believed that this simple graft will prevent upper lateral cartilages from functional movements and collapse [43]

6.5. Important points

1. Spreader grafts may be indicated to straighten a curved nasal dorsum that is not corrected in normal septoplasty techniques [39]
2. Internal nasal valve reconstruction prevents and corrects inverted V deformities and plays a substantial role in providing aesthetic brow lines.

7. Septal deformities

In most cases basic techniques will result in a straight functional nasal airway though in complicated cases more aggressive approaches may be necessary.

7.1. Complicated septal deformities

Sometimes the nasal septum is deviated in several different planes, and insisting on basic septoplasty techniques does not solve the problem and may lead to septal perforation and

many other complications. Extracorporeal septoplasty is a known modality that may be applied by experienced surgeons. In this technique, after an open approach skeletonization, the upper lateral cartilages are completely stripped off from nasal septum and then septal cartilage is precisely detached from all its anatomic connections and is taken out completely. The deformed nasal septum, which is now on the surgical table, is completely re-evaluated. Broken and deformed parts are excised and omitted in a way that a heavy strong L strut remains or is reconstructed. This newly formed septum is placed back inside the nose and tightly fixed to the bony vault and upper lateral cartilages [44-47]

7.2. Inadequate osteotomy

Sometimes intraoperative evaluations show that in spite of clear lateral osteotomy lines, medialization of bony segments is not achieved; in these cases medial osteotomy (in internal continuous osteotomy) and lateral oblique osteotomy (in external perforating osteotomy) may be indicated.

7.3. Medial osteotomy

In most rhinoplasty cases, lateral osteotomy will fulfill all the aims of osteotomy and there are limited indications for medial osteotomy; in indicated cases medial osteotomy may resolve some potential complications and will complete the bony vault surgery such as:

1. **Extremely wide noses:** Sometimes in wide noses lateral osteotomy will not appropriately medialize the bony segments and medial osteotomy will result in passive movements of bony segments.
2. **When hump reduction is not performed** or has not resulted in an open roof of the bony vault; medial osteotomy will allow the osteotomy to be completed; otherwise excessive pressure if applied may lead to uncontrolled fractures.
3. **Deviated bony pyramid:** In this case complete reformation of the bony pyramid is necessary thus, total release of bony segments and repositioning may be necessary. [48-50]

7.4. Rocker deformity

Rocker deformity is a relatively common sequel of lateral osteotomy. In this complication a large bony spicule is seen and palpated after lateral osteotomy over nasal radix. Like many other complications the best is to avoid this deformity by limiting osteotomy line maximum up to lateral canthus and not to extend it in thicker bony compartments. In case rocker deformity is seen, sharp bony spicules may be gently trimmed and sometime crushed cartilages or fascia can be used to camouflage the deformity. [51]

7.5. Crooked bony vault

In some post-traumatic nasal deformities a conventional lateral osteotomy does not result in an ideal symmetric bony vault; a double layer osteotomy may solve the problem in most cases. In this technique a deep low or low lateral osteotomy is performed in the traditional way; the

second line of osteotomy is started in a higher plane and then with light finger pressure the bony vault is molded. In case adequate results are not achieved a third line may be designed on one side or both sides of the nose. [52]

7.6. Important points

1. Internal continuous osteotomy may dislodge the fractured bony segments in two layer osteotomies, thus external perforating osteotomy is usually preferred in these deformities. As a predictable alternative, first deep osteotomy may be done by the internal method and the second line which is used to mold the segment may be added via the external approach.
2. Crushed cartilage may help the surgeon camouflage residual irregularities and asymmetries. In this technique a small part of crushed cartilage is gently placed on deficient parts, and then is molded until the ideal symmetric result is achieved.

Author details

Behnam Bohluli¹ and Payam Varedi^{2*}

*Address all correspondence to: payam.varedi@yahoo.com

1 Department of Oral and Maxillofacial Surgery, Buali Hospital, Islamic Azad University of Medical Sciences, Tehran, Iran, and Craniomaxillofacial Research Center, Shariati Hospital, Tehran University of Medical Sciences, Tehran, Iran

2 Department of Oral and Maxillofacial Surgery, Qazvin University of Medical Sciences, Qazvin, Iran, and Researcher, Department of Oral and Maxillofacial Surgery, Craniomaxillofacial Research Center, Shariati Hospital, Tehran University of Medical Sciences, Tehran, Iran

References

- [1] Tebbetts JB. Shaping and positioning the nasal tip without structural disruption: a new systematic approach. *PlastReconstrSurg* 94:61, 1994.
- [2] McColloughEG,Mangat D. Systematic approach to correction of the nasal tip in rhinoplasty. *Arch Otolaryngoll* 07:12, 1981.
- [3] Rich IS, Friedman WH, Pearlman SJ. The effects of lower lateral cartilage excision on nasal tip projection. *Arch Otolaryngol Head Neck Surg* 117:56, 1991.

- [4] Gunter JP. The merits of the open approach in rhinoplasty. *Plast Reconstr Surg* 99:863, 1997.
- [5] Tebbetts JB. The next dimension: rethinking the logic, sequence, and techniques of rhinoplasty. In Gunter JP, Rohrich RJ, Adams WP, eds. *Dallas Rhinoplasty: Nasal Surgery by the Masters*. St Louis: Quality Medical Publishing, 2002, p 219.
- [6] Tardy ME Jr, Cheng E. Transdomal suture refinement of the nasal tip. *Facial Plast Surg* 4:317, 1987.
- [7] Daniel RK. Rhinoplasty: creating an aesthetic tip. *Plast Reconstr Surg* 80:775, 1987.
- [8] Daniel RK. Rhinoplasty: a simplified, three-stitch, open tip suture technique. Part I: primary rhinoplasty. *Plast Reconstr Surg* 103:1491, 1999.
- [9] Petroff MA, McCollough EG, Horn D, et al. Nasal tip projection: quantitative changes following rhinoplasty. *Arch Otolaryngol Head Neck Surg* 117:783, 1991.
- [10] Janekel B, Wright WK. Studies on the support of the nasal tip. *Arch Otolaryngol* 94:458, 1971.
- [11] Johnson CM Jr, Godin MS. The tension nose: open structure rhinoplasty approach. *Plast Reconstr Surg* 95:43, 1995.
- [12] Tardy ME Jr, Walter MA, Patt BS. The overprojecting nose: anatomic component analysis and repair. *Facial Plast Surg* 9:306, 1993.
- [13] Wise JB, Becker SS, Sparano A, et al. Intermediate crural overlay in rhinoplasty: a deprojection technique that shortens the medial leg of the tripod without lengthening the nose. *Arch Facial Plast Surg* 8:240, 2006.
- [14] Sajjadian A, Guyuron B. An algorithm for treatment of the drooping nose. *Aesthet Surg J*. 2009 May-Jun;29(3):199-206.
- [15] Konior RJ. The droopy nasal tip. *Facial Plast Surg Clin North Am*. 2006 Nov;14(4):291-9, v. Review.
- [16] Pedroza F. A 20-year review of the "new domes" technique for refining the drooping nasal tip. *Arch Facial Plast Surg*. 2002 Jul-Sep;4(3):157-63. Review.
- [17] Bohluli B, Varedi P, Nazari S, Bagheri SC. Lateral crural suspension flap: a novel technique to modify and stabilize the nasolabial angle. *J Oral Maxillofac Surg*. 2013 Sep;71(9):1572-6.
- [18] Tasman AJ, Lohuis PJ. Control of tip rotation. *Facial Plast Surg*. 2012 Apr;28(2):243-50.
- [19] Ponsky DC, Harvey DJ, Khan SW, Guyuron B. Nose elongation: a review and description of the septal extension tongue-and-groove technique.
- [20] Chua DY, Park SS. Alar batten grafts. *JAMA Facial Plast Surg*. 2014 Sep 1;16(5):377-8.

- [21] Bewick JC, Buchanan MA, Frosh AC. Internal nasal valve incompetence is effectively treated using batten graft functional rhinoplasty. *Int J Otolaryngol*. 2013;2013:734795.
- [22] Sufyan AS, Hrisomalos E, Kokoska MS, Shipchandler TZ. The effects of alar batten grafts on nasal airway obstruction and nasal steroid use in patients with nasal valve collapse and nasal allergic symptoms: a prospective study. *JAMA Facial Plast Surg*. 2013 May;15(3):182-6.
- [23] Kuran I, Oreroğlu AR. The sandwiched lateral crural reinforcement graft: a novel technique for lateral crus reinforcement in rhinoplasty. *Aesthet Surg J*. 2014 Mar;34(3):383-93.
- [24] Gunter JP, Friedman RM. Lateral crural strut graft: technique and clinical applications in rhinoplasty. *Plast Reconstr Surg*. 1997 Apr;99(4):943-52; discussion 953-5.
- [25] Toriumi DM, Checcone MA. New concepts in nasal tip contouring. *Facial Plast Surg Clin North Am*. 2009 Feb;17(1):55-90, vi. doi: 10.1016/j.fsc.2008.10.001. Review.
- [26] Ashtiani AK, Bohluli B, Bateni H, Fatemi MJ, Sadr-Eshkevari P, Rashad A. Lateral crural transposition flap in tip correction: Tehran retrospective rhinoplasty experience. *Ann Plast Surg*. 2013 Jul;71(1):50-3. doi: 10.1097/SAP.0b013e318248b7f1. Erratum in: *Ann Plast Surg*. 2013 Aug;71(2):246
- [27] Cohen JC, Pearlman SJ. Radix grafts in cosmetic rhinoplasty: lessons from an 8-year review. *Arch Facial Plast Surg*. 2012 Nov;14(6):456-61
- [28] Besharatizadeh R, Ozkan BT, Tabrizi R. Complete or a partial sheet of deep temporal fascial graft as a radix graft for radix augmentation. *Eur Arch Otorhinolaryngol*. 2011 Oct;268(10):1449-53
- [29] Baser B, Kothari S, Thakur M. Diced cartilage: an effective graft for post-traumatic and revision rhinoplasty. *Indian J Otolaryngol Head Neck Surg*. 2013 Aug;65(Suppl 2):356-9. doi: 10.1007/s12070-012-0525-6. Epub 2012 Feb 25.
- [30] Moretti A, Sciuto S. Rib grafts in septorhinoplasty. *Acta Otorhinolaryngol Ital*. 2013 Jun;33(3):190-5.
- [31] Christophel JJ, Hilger PA. Osseocartilaginous rib graft rhinoplasty: a stable, predictable technique for major dorsal reconstruction. *Arch Facial Plast Surg*. 2011 Mar-Apr;13(2):78-83.
- [32] Bussi M, Palonta F, Toma S. Grafting in revision rhinoplasty. *Acta Otorhinolaryngol Ital*. 2013 Jun; 33(3):183-9.
- [33] Baker TM, Courtiss EH. Temporalis fascia grafts in open secondary rhinoplasty. *Plast Reconstr Surg*. 1994 Apr;93(4):802-10.
- [34] Cho JM, Jeong JH, Woo KV, Lee YH. Versatility of retroauricular mastoid donor site: a convenient valuable warehouse of various free graft tissues in cosmetic and reconstructive surgery. *J Craniofac Surg*. 2013; 24(5):e486-90.

- [35] Nazari S, Bohluli B, Besharatizadeh R, Sadr-Eshkevari P, Rashad A. Neck hairline incision for simultaneous harvesting of temporal and mastoid fasciae: a technical note. *J Oral Maxillofac Surg.* 2013 Sep;71(9):1598-600.
- [36] Erol OO. The Turkish delight: a pliable graft for rhinoplasty. *Plast Reconstr Surg.* 2000 May;105(6):2229-41; discussion 2242-3.
- [37] Gerbault O, Aiach G. Diced cartilage wrapped in deep temporal aponeurosis (DC-F): A new technique in augmentation rhinoplasty. *Ann Chir Plast Esthet.* 2009 Oct; 54(5): 477-85.
- [38] Antohi N, Isac C, Stan V, Ionescu R. Dorsal nasal augmentation with "open sandwich" graft consisting of conchal cartilage and retroauricular fascia. *Aesthet Surg J.* 2012 Sep;32(7):833-45.
- [39] Varedi P, Bohluli B, Bayat M, Mohammadi F. Spreader graft placement: A simplified technique for young surgeons. *Int J Oral Maxillofac Surg.* 2014 Oct;43(10):1216-7.
- [40] Hussein WK, Elwany S, Montaser M. Modified autospreader flap for nasal valve support: utilizing the spring effect of the upper lateral cartilage. *Eur Arch Otorhinolaryngol.* 2014 Sep 30
- [41] Pepper JP, Baker SR. The autospreader flap in reduction rhinoplasty. *Arch Facial Plast Surg.* 2011 May-Jun;13(3):172.
- [42] Moharamnejad N, Bohluli B. Docile splay graft for middle vault reconstruction. *Br J Oral Maxillofac Surg.* 2013 Dec;51(8):e307-9.
- [43] Aaronson NL, Vining EM. Correction of the deviated septum: from ancient Egypt to the endoscopic era. *Int Forum Allergy Rhinol.* 2014 Aug 18
- [44] Bohluli B, Motamedi MH, Varedi P, Malekzadeh M, Ghassemi A, Bagheri SC. Management of perforations of the nasal septum: can extracorporeal septoplasty be an effective option? *J Oral Maxillofac Surg.* 2014 Feb;72(2):391-5.
- [45] Nazari S, Bohluli B, Varedi P, Besharatizade R. Carpentering in septorhinoplasty: a novel technique to straighten the deviated nasal septum. *J Oral Maxillofac Surg.* 2014 Jan;72(1):157-63.
- [46] Karameşe M, Akdağ O, Akatekin A, Koplay TG, Koplay M, Tosun Z. Extracorporeal Septoplasty Combined With Valve Surgery in Rhinoplasty Patients. *Ann Plast Surg.* 2014 Oct 2.
- [47] Ghassemi A, Ayoub A, Modabber A, Bohluli B, Prescher A. Lateral nasal osteotomy: a comparative study between the use of osteotome and a diamond surgical burr - a cadaver study. *Head Face Med.* 2013 Dec 19;9:41.
- [48] Varedi P, Shirani G, Bohluli B, Besharati R, Keyhan SO. A simplified approach to the external lateral nasal osteotomy: a technical note. *J Oral Maxillofac Surg.* 2013 Aug; 71(8):1435-8.

- [49] Bohluli B, Moharamnejad N, Bayat M. Dorsal hump surgery and lateral osteotomy. *Oral Maxillofac Surg Clin North Am.* 2012 Feb;24(1):75-86.
- [50] Harshbarger RJ, Sullivan PK. The optimal medial osteotomy: a study of nasal bone thickness and fracture patterns. *Plast Reconstr Surg.* 2001 Dec;108(7):2114-9; discussion 2120-1.
- [51] Cerkes N. The crooked nose: principles of treatment. *Aesthet Surg J.* 2011 Feb;31(2):241-57.
- [52] Levie P, Horoi M, Claes J, Monnoye JP, Verheyden PJ, Monnoye V, Lefebvre J, Millet B, Darteville D, Lemaire FX, Hatert AS, de Burbure C. External or internal lateral osteotomy: why I choose the external percutaneous approach. *B-ENT.* 2010;6 Suppl 15:49-50.
- [53] Helal MZ, El-Tarabishi M, Magdy Sabry S, Yassin A, Rabie A, Lin SJ. Effects of rhinoplasty on the internal nasal valve: a comparison between internal continuous and external perforating osteotomy. *Ann Plast Surg.* 2010 May;64(5):649-57.
- [54] Sinha V, Gupta D, More Y, Prajapati B, Kedia BK, Singh SN. External vs. internal osteotomy in rhinoplasty. *Indian J Otolaryngol Head Neck Surg.* 2007 Mar;59(1):9-12.
- [55] Rohrich RJ, Janis JE, Adams WP, Krueger JK. An update on the lateral nasal osteotomy in rhinoplasty: an anatomic endoscopic comparison of the external versus the internal approach. *Plast Reconstr Surg.* 2003 Jun; 111(7):2461-2; discussion 2463.