

We are IntechOpen, the world's leading publisher of Open Access books Built by scientists, for scientists

6,900

Open access books available

185,000

International authors and editors

200M

Downloads

Our authors are among the

154

Countries delivered to

TOP 1%

most cited scientists

12.2%

Contributors from top 500 universities



WEB OF SCIENCE™

Selection of our books indexed in the Book Citation Index
in Web of Science™ Core Collection (BKCI)

Interested in publishing with us?
Contact book.department@intechopen.com

Numbers displayed above are based on latest data collected.
For more information visit www.intechopen.com



Aspects of Renal Disease Affecting Dental Management — Surgery in Patients Receiving Hemodialysis

M. Dencheva, E. Deliverska, A. Krasteva,
J. Galabov and A. Kisselova

Additional information is available at the end of the chapter

<http://dx.doi.org/10.5772/59930>

1. Introduction

Kidneys play several roles in helping maintain physiologic balance; they are therefore important for continuing or regaining homeostasis during and after surgery and anesthesia. The renal system is necessary to support the processes of fluid, electrolyte, and acid-based balance, drug metabolism and elimination, blood pressure control through the renin-angiotensin system, red blood cell production through erythropoietin production, and vitamin D hydroxylation.

2. Main issues regarding the oral health in patients on hemodialysis and those with kidney transplant

The primary role of the dental doctor consists of the early diagnosis or referral of the patient to the right specialist, as the most frequent renal disease a dentist may encounter is the chronic kidney disease [18, 39, 114].

The symptoms that may lead us to the conclusion of constrained renal function vary depending on the extent of the damage and the reaction to the suggested treatment, and are characterized with systemic as well as intraoral findings.

3. Common symptoms at CKD (Chronic Kidney Disease)

Disease	Symptoms
Gastrointestinal	– nausea, vomiting, anorexia, metal taste, malodor, oesophagitis, gastritis, gastrointestinal bleeding
Neuromuscular	– headache, peripheral neuropathy, paralysis, sleep disturbances, numbness of limbs, convulsions correlating with level of the azotemia
Hematoimmunologic	– normocytic and normochrome anemia, coagulopathy, low resistance to infections, low production of erythropoietin, lymphocytopenia
Endocrine metabolic	– renal osteodystrophy (osteomalacia, osteosclerosis, fibrous cysts), secondary hyperparathyroidism, disturbed growth, decreased libido, amenorrhea, thyroid dysfunction
Cardio vascular	– cardiomyopathy, arrhythmia, pericarditis, high blood pressure, difficulty in breathing, congestive heart failure
Dermatologic	– paleness, itching, signs of scratching because of the itch, increased photosensitive pigmentation, uremic white spots, brown coloring of the nails- Fig.1, signs of water retention, limb heaviness, edema of the ankles
Respiratory	– Kussmaul breathing because of acidosis, pulmonary edema, dyspnea

Table 1. Symptoms at CKD [18, 125]

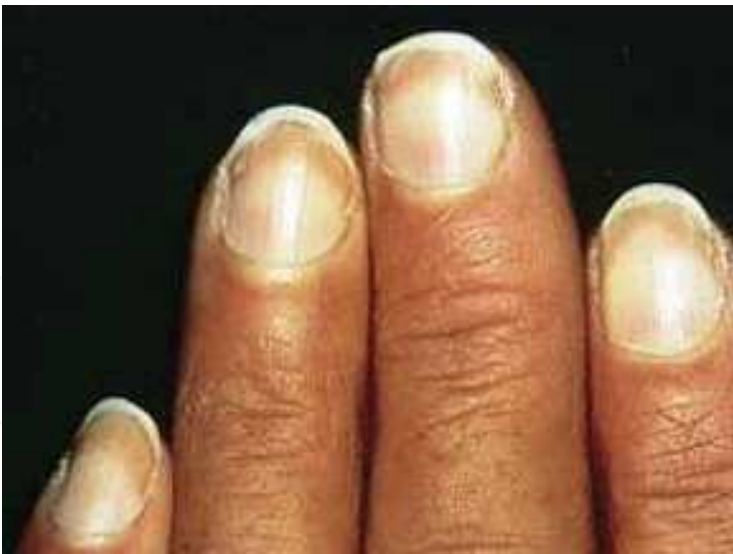

Figure 1. Brown coloring of nails

Renal osteodystrophy or renal bone disease is one of the most prominent signs of CKD and may occur in one or several combined forms. As a result of the increase of the level of phosphates in blood plasma, the decrease of calcium in blood plasma and the failure of processing of 25-hydroxycholecalciferol into the active and necessary 1.25 dihydroxycholecalciferol, an

increase of the parathormone (PTH) occurs. This leads to secondary hyperparathyroidism. Because of the increase of the non-mineralized bone matrix progressive bone changes may be observed - osteomalacia, lytic lesions followed by bone fibrosis. Renal osteodystrophy in kids leads to a delay in skeletal growth and a tendency for spontaneous fractures.

Most frequent orofacial signs of renal osteodystrophy are bone demineralization, lower trabeculation, lower density of the cortical bone, calcifications in soft tissues, radiolucent fibrocystic lesions, and complicated bone healing following extraction. Regarding the teeth and parodontal tissues we may observe delayed eruption, enamel hypoplasia (fig.2), loss of lamina dura, widening of the periodontal space, severe periodontal destruction, tooth mobility, denticles, obliteration of pulp chamber, and giant-cell lesions of the type "brown tumors"[78, 85].

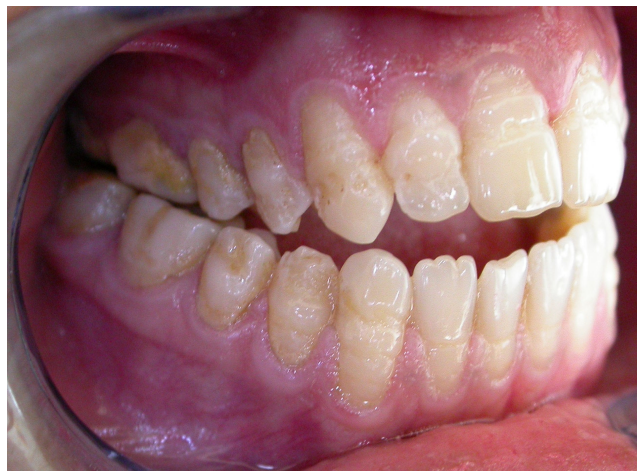

Figure 2. Hypoplasia and open bite in a female patient on hemodialysis

Nephrotic syndrome is observed in patients with glomerular diseases. It includes proteinuria (over 3.5 gr), hypoalbuminemia, hyperlipidemia, lipiduria, and edema. Causes may vary: sugar diabetes, chronic lupus erythematosus, or membrane glomerulonephritis. Increased level of blood coagulation factor VIII may lead to hypercoagulation and increased risk of thrombosis. Such patients may suffer catabolic processes, bacterial, fungal and viral infections [53, 66].

It should be noted that a significant part of the patients with renal disorders may also suffer from diabetes [14]. It is less probable for a dentist to diagnose diabetes, but patients whose dental status alters unexpectedly as rapidly as in progressive parodontitis, fungal eczemas, abscesses, high fluid intake, rapid weight loss, mouth dryness and halitosis [28, 29] may be suspicious. Those symptoms impose the appointment of definite examinations, which may help to set the latter diagnosis.

Renal disorders almost invariably cause anemia as a result of the kidneys' inability to produce erythropoietin. Fibrosis of marrow and the increased loss of erythrocytes are additional factors which increase the development of the disease. Anemia leads to fatigue, loss of concentration,

tissue hypoxia, and paleness of the oral mucosa. In patients with advanced and untreated uremia, yellow-brownish coloring of the skin and mucosa because of the accumulation of carotene-like substances [4, 125] may be observed.

4. Intraoral findings typical for patients on hemodialysis and patients with kidney transplant

- Almost mandatory findings for each patient on hemodialysis are uremic breath and altered taste in the oral cavity. They occur as a result of the increased concentration of urea in saliva and its following transformation to ammonia [18, 60, 113, 121]. It is possible, however, for similar complaints to be registered in patients with normal values for blood and urine, for example after transplantation, and this is caused by the higher corrosion potential, combined with insufficient and personal and professional oral hygiene [90].
- Xerostomia could be explained with lowered fluid intake, as a side effect of antihypertensive or other medicaments, possible alterations in the salivary glands due to autoimmune or age-related changes [25, 26, 27, 28, 41, 47, 52, 73, 91, 92]. The study of Bots et al. [12] proves that in patients on hemodialysis the saliva quantity (stimulated and non-stimulated) is temporarily lowered but after transplantation and recovery of the renal function it is restored to normal values. With the same patients they register drop in pH from 7.36 to 6.74 probably because of the lower concentration of urea in saliva and the following decrease of hydrolysis and by the transformation of oral flora to ammonia [16].
- Oral mucosa findings, reported in patients with CKD, with the exception of uremic stomatitis (fig.3), are unusual and vary, as a result of the main disease, as well as the intake of drugs: white plaques, macules, nodules, erythematous plaques, fibro-epithelial polypus, ulceration, geographic tongue (fig.4), lichen planus, red fibrous tongue, fiber leukoplakia, and papilloma [21, 38, 76]. We may notice pale oral mucosa because of anemia, but also red-orange coloring of the skin following the deposition of carotene-like substances [71, 92, 110].

Cervero et al. [18] described 4 types of uremic stomatitis (erythematous, ulcerative, haemorrhagic and hyperkeratotic). The lesions are painful, situated on the ventral surface of the tongue, on the floor of the oral cavity and the buccal mucosa. Most frequently the cause is untreated CKD. It emerges because of inflammation and the chemical influence of ammonia or ammonia components, formed by the hydrolysis of the urea (over 30mmol/L intraoral) [95] in the saliva by urease. Kellet [58] reports about four patients with chronic renal insufficiency suffering white painless plaques. They are not subject to treatment, and they disappear in up to 2 or 3 weeks after regulating the level of blood urea. Long [71] defines two types of uremic stomatitis: I type - generalized or localized erythema with grey-white pseudomembrane coating the removal of which doesn't lead to bleeding or ulceration, and type II- after removing the coating of the surface is ulcerating [3, 27, 58, 71].

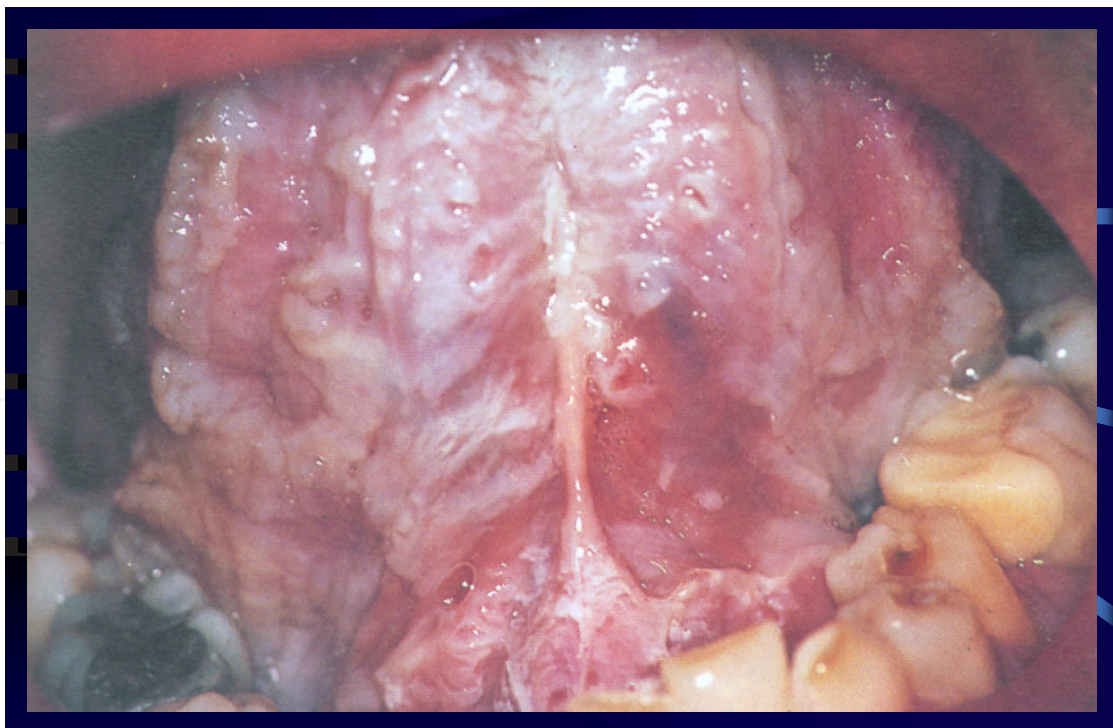


Figure 3. Uremic stomatitis

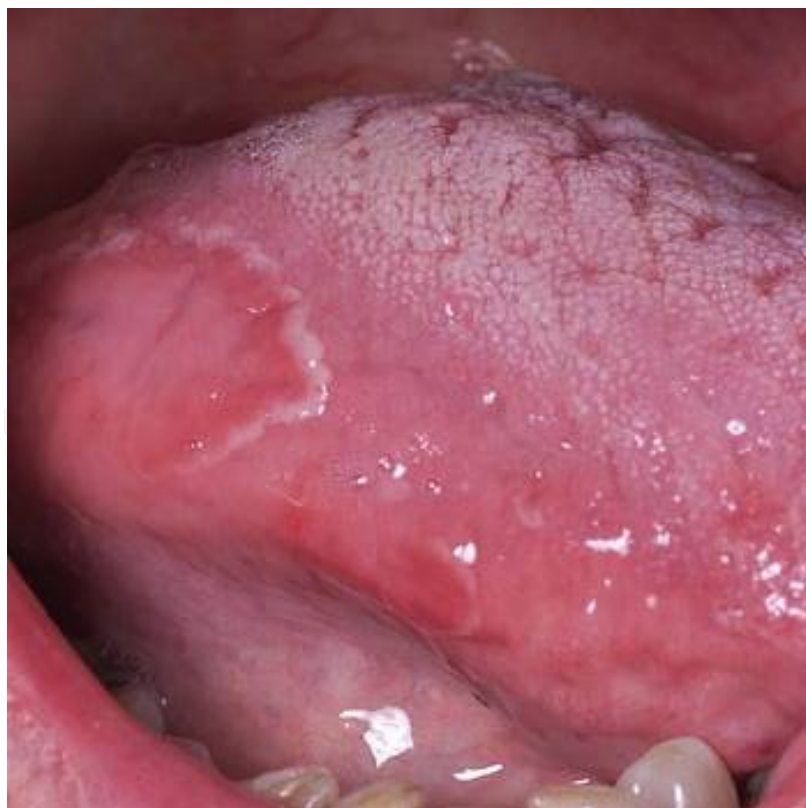

Figure 4. Geographic tongue

- Mac-Donald [74], Peneva et al. [87] found delay in the eruption of the permanent teeth with statistically significant difference in children born with the disease and lasting for life in comparison to healthy children.

Peneva et al. [85] explored the incidence of tooth decay among 30 children on hemodialysis and defined that children on dialysis suffer less frequently from decay compared to healthy children. They also found that, decay resistance is higher at children with earlier beginning of the disease and longer duration.

Shu et al. [105] explored the correlation between decay and urease activity of the tooth plaque in 25 caries-free participants and 8 participants with decays. They found that in the caries-free subjects urease activity of the dental plaque is significantly higher than this in patients with caries. They suggested that the loss of alkalizing potential of the tooth biofilm is in positive correlation with the incidence of tooth decay. Meanwhile they didn't establish statistically significant difference in the salivary urease activity.

- Takeuchi et al. [111] researched the oral microbial flora in patients with renal disease and its influence on caries and parodontal pathology. They discovered significantly higher count of parodontal and decay pathogens in patients with renal disease. This fact in turn defines the higher risk of tooth decay and parodontal disease compared to healthy samples.

Most researches regarding the oral status of patients with CKD, on hemodialysis or transplanted, are made with a control group consisting of healthy patients. For the first time a long-term, two- year research by Bots et al. [13] compares xerostomia, the sense of thirst, saliva secretion and the general oral health of patients with renal failure to those of a group of transplanted patients. Using DMFT, DMFS- indexes they find that the teeth affected by decay don't differ statistically in the group of patients on hemodialysis from those of the control group with transplanted patients. In this research, the scholars expressly note the increased necessity of examining the oral status of patients expecting transplantation.

Gavalda et al. [41] examined 105 patients on hemodialysis. They diagnosed mucosal, salivary, dental and periodontal findings in the oral cavity. They didn't find significant difference between the value of the index referring to the decay incidence in patients on hemodialysis and healthy samples, but they established such at indexes reflecting the amount of calculus and tooth plaque.

Bayraktar et al. [8] found elevated incidence of tooth caries in their control healthy group compared to group of patients on hemodialysis, but that rise is not statistically significant. Rustemeyer et al. [97] didn't find statistically significant difference of the dental health of the groups in their research either, but they noted the tendency for higher value of DMFT in the groups expecting renal transplantation (=14,9), liver transplantation (=14,5), valve transplantation (=15,2) and the control group (=13,8).

In the scientific literature, the issue of prevention and early dental intervention in patients on dialysis has become extremely pertinent, with a marked emphasis on the requirement for an interdisciplinary approach towards these patient groups [11, 30, 61].

Hypoplasia- there are cases where ESRD evolved in childhood. Pulp obliteration is due to violations in calcium and phosphoric exchange [60, 74, 81, 86, 90].

1. It's been proven that **parodontitis** may contribute to the development of common inflammation processes and systemic diseases such as atherosclerosis and cardiovascular diseases [22, 109]. Gingival pathogens may damage system circulation in the body by one of two connected mechanisms:
2. They provoke liver enzyme activity, influencing IL-6 and C-reactive protein, which in its turn activates the system of the complement and cause the deposition of calcium connections and aggregation of LDL and very LDL cholesterol.
3. *P. gingivalis* damages human endothelial cells and helps the formation of atheromatous plaques [11, 22, 60, 65, 84, 112].

Fisher [37] in his research defines parodontal disease as an “unconventional risk factor for the development of chronic renal disease”. Pejic et al. [84] took part into the discussion about the role of periodontitis as a risk factor for general diseases. Authors such as Klassen and Krassko [62] and Al Wahadni and Al Omari [2] report prevalence of gingival and parodontal diseases in patients on hemodialysis. There are authors who don't find increase in parodontal indexes with such patients [13, 55, 81]. Kshisageret et al. [68] note the significance of parodontal health in end-stage renal failure. They carried out a retrospective cohort research and followed the correlation between parodontal diseases and the mortality rate of patients with severe cardiovascular disease, such as patients with CKD. They established define that the mortality rate in the group of the patients with medium to severe periodontitis and cardiovascular disease is five times higher for the 18- month period of the research.

Using parodontal diagnostics, that includes CPITN, PI, PBI (papillary bleeding index), CAL (clinical attachment level), Borawski et al. examine patients on hemodialysis, patients on peritoneal dialysis, patients in the pre-dialysis stage, patients with advanced periodontitis and average patients (randomly selected). The research shows a much higher incidence of parodontitis development in patients with renal disease in comparison to average patients. Periodontal disease is practically most severe in patients on hemodialysis, less severe in patients on peritoneal dialysis and moderate in patients in the pre-dialysis stage.

Relatively little is known about the **long term** effect of dialysis treatment on oral health. A research carried out by a group of Turkish scientists, Bayraktar et al. [8], proves the necessity of sanitation, because of the negative results that occur with time onto oral health of this patient group. The publications of Graig [44], Donald [31], and Davidovich [23, 24] testify to the two-way relation between end-stage CKD and the severity of parodontal inflammation, which can be proved by examining the levels of C-reactive protein. Bayraktar et al. [8], led by the fact that problems with oral health may have a negative influence over patients in end-stage CKD, launched a survey comparing the parodontal and dental status of patients with renal failure and a healthy control group. They established that there isn't a statistically significant difference between the measured pocket depths (PPD) of the two groups, but the values of the plaque index (PI), the calculus index (CSI), and the gingival index (GI) show significant statistical

difference. A positive correlation was established between the duration of dialysis procedures more than 3 years and missing teeth, the gingival index and pocket depth.

The research of Davidovich [24] shows for the first time the relation between the duration of dialysis and parodontal diseases in children. The results present a significant loss of epithelial attachment in patients with end-stage CKD compared to healthy patients. A positive correlation was established between the severity of parodontal status and bad oral hygiene, the uremic status, and the duration of the kidney disease.

- Regarding the cause of commonly reported gingival inflammation in patients with CKD, controversial data in literature exists. Nunn et al. [81], Tollefsen & Jonasen [118, 119], and Ertugrul et al. [36] report reduction in gingivitis because of immunosuppressants and uremia. Naugle et al. [79] reveal conflicting data. Furthermore, Kitsou et al. [62] reproduce experimental gingivitis following the protocol of Löe. Oral hygiene is discontinued for 28 days. The authors report they haven't found differences in the gingival indexes between the group of 6 patients on hemodialysis and one of 6 patients without renal problems and conclude that chronic uremia doesn't contribute to the defensive mechanisms of parodontal tissue against tooth plaque. Davidovich et al. [24] report a statistically significant difference comparing the duration of the dialysis and CKD and gingival and parodontal changes. They report that uremia and immunosuppression reduce but don't eliminate an inflammation response of the gingiva and periodontium against tooth plaque. Another condition accompanying end-stage renal failure is diabetes. Chuang et al. [21] compared the oral health of 45 patients suffering from diabetes and undergoing hemodialysis treatment to that of 83 patients without diabetes but on hemodialysis. They reported lower saliva secretion and lower pH connected with higher caries levels in the diabetes group, but they didn't observe differences in gingival inflammation and the presence of parodontitis. In the research of Borawski et al. [11] the need is noted of treatment through CPITN for patients on hemodialysis and transplanted renal patients.

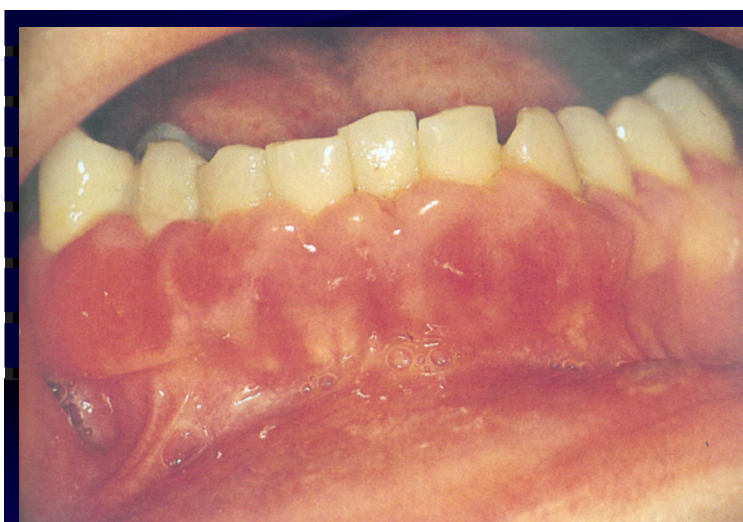

Figure 5. Cyclosporine induced gingival hyperplasia

- Another finding in patients with end-stage liver failure, is drug-induced **gingival hyperplasia (DIGH)** (fig.5). Its mechanism of occurrence is multifactorial and has not yet been fully explained. The intake of antihypertensive and immunosuppressive drugs gives evidence in the oral cavity [42, 50, 104, 115]. Such overgrowth is usually observed in the early posttransplantation period (4 m) and in combination with insufficient oral hygiene or previously damaged periodontium [1, 30, 89, 112]. The sole influence of cyclosporine remains controversial in the specialized literature. Data varies from 25 to 81% depending on methods used [104]. R. A. Seymour [103] compares the influence of azathioprine on gingiva to that of cyclosporine and finds that azathioprine has no damaging effect on the gingiva. J. A. James [57] reports the absence of gingival changes when using tacrolimus (6,4%) and cyclosporine (17,9%) on the third month after immunosuppression, excluding patients with accompanying antihypertensive therapy. Their study shows that tacrolimus also induces gingival hyperplasia, but to a lesser extent [3]. James [56] takes into consideration 4 cases of swapping cyclosporine with tacrolimus, combined with professional care of periodontist. In only one case a full regression of the gingival overgrowth occurs. J. A. James [57] compares gingival hyperplasia among 25 patients taking tacrolimus, and 26 control group patients and doesn't find a statistically significant difference. This gives him the grounds to distinguish tacrolimus as an alternative to cyclosporine A, when a severe case of gingival hyperplasia is present.

Researches made by Davidovich [24] and Thorp et al. [116] confirmed the findings of Nunn et al. [81] about gingival overgrowth in transplanted patients on immunosuppression with cyclosporine A and less frequently occurring one in patients taking tacrolimus.

Radwan- Oczko et al. [94] sought a connection between gingival hyperplasia, immunosuppressive drugs and the growth factor $\beta 1$ (TGF $\beta 1$), which is considered a key cytokine in fibrogenesis. They didn't prove any statistically significant relation between gene expression of TGF $\beta 1$, gingival hyperplasia and treatment with cyclosporine A and tacrolimus.

Djemileva [30] and Gera [42] believe that shared responsibility in maintaining oral health in the long process of treatment of these patients is a crucial factor as well as the possible switch of immunosuppressants. The studies of Somacarrera et al. [108], Ellis et al. [34], and J. Smith et al. [106] are taken as evidence corroborating the supposition that maintaining sufficient oral hygiene leads to a decrease of gingival hyperplasia.

- **Malignancy.** The suppression of the immune system in transplanted patients may predispose the formation of malignant entities. Two types of malignant formations that prevail in patients with kidney transplantation have been reported: cancer of the cervix and squamous cancer of the skin [10, 17, 66, 88, 100]. Malignancy may also include Kaposi's sarcoma, renal cancer, and lymphomas.
- **Candidiasis** is particularly specific for the early post-transplantation period: from 0 to 6 months. It is caused first by the immunosuppressive action of the drugs and the impact on oral homeostasis and second by the decrease of saliva secretion- medications for hypertension, and dialysis procedures [32, 49, 78, 99].

4.1. A dental treatment approach to patients on hemodialysis and transplanted

Assuming susceptibility of the patients on hemodialysis and those with a renal transplant to infections, it proves necessary to pick the right antibiotics for each dental procedure, that may cause longer bacteraemia [97, 120]. A number of studies prove the need of antibiotic protection at risky dental manipulations, even though according to Lockhart et al. [70], washing one’s teeth is comparable to tooth extraction as a possible cause for bacteraemia [122, 123]. It’s necessary to have in mind the possibility of contamination of parodontal tissues through various means of personal oral hygiene [72, 93].

The American Heart Association in its recommendations for the prevention of bacterial endocarditis from 2007 [123] divides the dental procedures into such hazardous for bacteraemia: all procedures connected with manipulation of the gingival tissue and the periapical region of the teeth, or perforation of the oral mucosa, and these where antibiotic prophylaxis is not necessary: routine anesthesia through non-infected tissue, radiographs, and bleeding from trauma of the oral mucosa. In a similar way, D. Tong [119, 120] made a division of the dental procedures (table 2).

High risk category
Tooth extraction
Periodontal procedure that includes surgery, Ultrasound scaling
Root probing
Implant placing and tooth reimplantation
Endodontic instrumentation or surgery beyond root apex
Subgingival application of antibiotic fibers and bands
Initial placing of orthodontic rings but not brackets
Intraligamentary local anesthesia
Preventive cleaning of teeth or implants with expected bleeding
Procedures where prophylaxis is not needed
Dental restorations with or without a retraction cord
Local anesthesia (excluding intraligamentary)
Intracanal endodontic procedures after placing implants and build-ups
Rubber dam placing
Post-operative suture removal
Placement of orthodontic and prosthetic constructions
Taking of dental impressions
Teeth fluoridation
Radiographs
Adjustment of orthodontic constructions
Replacement of milk teeth

Table 2. Dental procedures with a compelling antibiotic prophylaxis in patients at risk

4.2. Dental treatment approaches in the pre- and post-operative periods

- i. Most authors are unanimous that in the pre-transplantation period preventive sanitation of all foci is necessary [5, 6, 11, 12, 27, 46, 64, 82, 84, 96, 97, 98]. To the initial dental diagnostics that includes standard dental examination and parodontal examination the methods of the complex oral and focal diagnostics could be added, which may define the dominant and latent foci that early in the pre-transplantation period so that a treatment plan for the post-transplantation period can be devised. Dental doctors should be aware of the degree of renal insufficiency and the current medical status of the patient. Consultation with the patient's general doctor should be made and lab tests should be performed, especially before surgical dental interventions. The intake of systemic antibiotics in the pre-transplantation period is contraindicated [82], not counting life-threatening situations. Heavily damaged decayed teeth and such with radiograph changes and symptoms should be extracted. A mass teeth extraction procedure is to be performed on patients with bad oral hygiene and advanced periodontal disease, and on those unmotivated to maintain sufficient oral hygiene. Surgical sanitation is followed by prosthetic restoration [54].

It is necessary **to treat all newly emerged dental conditions** without waiting for the clinical symptoms to develop. Moreover, to fulfil the requirements for sufficient dental health, a patient should have a sufficient knowledge. Several studies take notice of the fact that patients suffering from CKD don't maintain sufficient oral hygiene and it should be improved [7, 43].

Infection control is a complex issue regarding patients with end-stage renal disease. If an invasive dental procedure is required, a consultation with the treatment doctor must be made. The current health status of the patients is consulted, as well as the possible need of antibiotic premedication, usage of local anesthetics and other drugs. Prescribing medicaments to patients with renal insufficiency should be approached with care and in full accordance with their current medical and renal condition [19, 20, 53, 67] (table 3).

Antibiotic	Normal renal function	Glomerular filtration 10–50 ml/min	Glomerular filtration <10 ml/min
<i>Amoxicillin</i>	8 h	8–12 h	12–18
<i>Ampicillin</i>	6 h	6–9 h	9–12
<i>Cephalexin</i>	6 h	6 h	6–12 h
<i>Clindamycin</i>	8 h	8 h	8 h
<i>Doxycycline</i>	12–24 h	12–24 h	12–24 h
<i>Erythromycin</i>	6 h	6 h	6 h
<i>Metronidazole</i>	8 h	8 h	12–16 h

Table 3. Antibiotic premedication for patients suffering from CKD, adap. J. W. Little, D. A. Falace et al [66]; J. A. Ship [105]

W. M. Bennett et al. [9] propose a change in dosage for patients on hemodialysis with emerged tooth infection:

- Penicillin 500 mg p. o. every 6 hours after dialysis;
- Amoxicillin 500 mg p. o. every 24 hours after hemodialysis;
- Ampicillin 250 mg – 1 g p. o. every 12-24 hours after hemodialysis;
- Erythromycin 250 mg p.o. every 6 hours optional only after dialysis;
- Clindamycin 300 mg p.o. every 6 hours optional only after dialysis.

According to data from Tong and Walker [120] in Australia and New Zealand, 53% of dental doctors follow the instructions of AHA for the prevention of bacterial endocarditis. One of the most frequently used patterns for premedication is taking a 2g Amoxicillin or 600 mg Clindamycin (in cases of Penicillin allergy) one hour before a dental procedure: for kids 50mg/kg oral intake 30-60 minutes before the procedure.

A survey in two Swedish provinces reveals that the most frequently prescribed antibiotics to kidney transplanted patients when performing scaling, tooth extraction and root canal treatment are Amoxicillin, Penicillin, Clindamycin [33].

The issue of antibiotic prevention of bacterial endocarditis has undergone considerable development in the past 10 years. In 2007 AHA published an amendment to the recommendations from 1997. AHA (2007) narrows significantly the diseases whose dental treatment is indicative for antibiotic prevention. In the recommendations patients with dialysis shunts are classified in class 3, level C on account of the possibility for the development of bacterial endocarditis during dental treatment. This means that there are indications, supported with evidence or general agreement, that the procedures/treatment are not necessary, ineffective and in some cases even damaging. The level of evidence is C, in other words the recommendations are based only on an established consensus of views of experts, on separate cases or on accepted standards of treatment. Despite this fact, these patients are defined as “unique” in view of the higher risk of infections of the venous shunt, because of their immunocompromised status and the increased count of *S. aureus* [5]. Around 22% of the arteriovenous shunts get infected, which leads to antibiotic intake or to changes in the intake plan. The pathogens linked with the infection occurring in the application of the vascular approach are 53% *S. aureus* and 20.3% coagulase-negative staphylococci. In the AHA guide [5] to non-valvular cardiovascular equipment a regime of antibiotic prophylaxis of patients with hemodialysis shunts and organ transplants is not mentioned. The same opinion is maintained by Pallsh [83]. Lockhart et al. [69] methodically examine the efficiency of antibiotic premedication in dental practice. They divide patients taking antibiotics in 8 groups. One of the groups consists of patients with hemo- and peritoneal dialysis: with kidney dialysis shunts (hemodialysis and peritoneal). The authors found little or no scientific evidence on issues relating to the usage of antibiotic prophylaxis before dental procedures in these 8 groups of patients.

Until now no clear evidence has been provided that during invasive dental treatment of patients with advanced renal, liver or heart condition antibiotic prevention is needed, but most

dental centers and authors follow the instructions of the AHA [123], pointing out two main reasons: shunt infection risk [101] or the possible development of infectious endocarditis [109] (table 4).

Condition	Antibiotic	Prescription	
<i>Standard prophylaxis</i>	Amoxicillin	Adults 2.0mg	Kids 50 mg/kg
<i>Inability for oral intake</i>	Ampicillin	2g i.m. or i.v.	50 mg/kg i.m. or i.v.
<i>Penicillin allergy</i>	Clindamycin	600mg	20 mg/kg
	Cephalexin* or cefadroxil	2 gr	50 mg/kg
	Azithromycin or Clarithromycin	500 mg	15 mg/kg
<i>Penicillin allergy and inability for oral intake</i>	Clindamycin	600 mg i.m. or i.v.	20 mg i.m. or i.v.
	Cefazolin	1 gr i.m. or i.v.	50 mg/kg i.m. or i.v.

* Or other first or second generation cephalosporins in equivalent doses for adults and children

Table 4. Antibiotic premedication according to AHA's recommendations

Patients awaiting transplantation undergo antibiotic premedication from the moment they are moved into the operation theater. The duration of the antibiotic treatment is usually with a duration of up to 3 days. In the best case scenario the antibiotic intake should be determined on the basis of the bacterial flora present, the kind of transplantation and patient-specific features [107]. For example a kidney transplanted patient may be prescribed Cefazolin and Ampicillin-sulbactam to cope with the uropathogens and staphylococci. In patients with chronic dental infections, frequent or continuous bacteraemia may occur, which in its turn may trigger acute or chronic inflammation in other organs [61].

De Rossi and Glick [27] systematize a few guidelines for a recommended dental approach to patients on hemodialysis. They also follow AHA's recommendations, but they think that the antibiotic of choice should be Vancomycin, which must be flowed on the day of the dialysis before an invasive dental procedure, since its action on the organism lasts for the next 7 days. What follows is a radical approach with the extraction of the tooth.

With better medical care, the expectations of the patients for better and longer life are justified.

Hemostatic agents

Standard tests for suspected coagulopathy include [45]:

1. Bleeding time (BT).
2. Prothrombin time (PT).
3. Partial thromboplastin time (PTT).

- 4. Platelet count (table 8).
- 5. INR (International Normalised Ratio).

Lockhart et al. [68] define several points which need to be considered before invasive dental procedure is initiated on patients with CKD. The first issue to consider is the analysis of what is described above, as well as the influence of the platelet count on the expected post-operative bleeding (table 5).

Platelet count (на μ l)	Diagnose	Effect
150 000–450 000	Normal	Rare but possible operative bleeding
100 000–150 000	Mild thrombocytopenia	
50 000–100 000	Moderate thrombocytopenia	Increased possibility for bleeding during dental manipulation but unusual.
25 000–50 000	Severe thrombocytopenia	Expected problematic bleeding Spontaneous bleeding at <10 000
<25 000	Life-threatening condition	Invasive procedures only at emergency and blood transfusion

Table 5. Platelet count and its effect on post-operative bleeding

They define hemostasis in the oral cavity as a multifactorial process, which is not well studied yet. To a greater extent the insufficient use of lab tests may confound the appointed anticoagulation therapy and the risk for the patient could be greater than post-operative bleeding.

Meechan and Greenwood [76] propose that in cases of platelet count lower than $50 \cdot 10^9/L$ an urgent invasive procedure is needed. The latter could be performed after substitute platelet transfusion 30 minutes before operation. In practice this approach is used quite rarely because of the risk of immune sensitization. Patients on hemodialysis undergo heparinisation 3 times a week before procedures, but heparin has a short half-life (around 5 hours), that’s why as a precaution it’s accepted that it is best for any dental procedures to be performed on the day after dialysis [30, 59]. On the other hand, the longer the time since the last dialysis, the greater the chance for prolonged bleeding during invasive dental procedures because of uremia.

As a result of thrombocytic dysfunction, even with relatively good blood indicators, profuse bleeding could be expected during invasive dental procedures [53, 80]. The treatment of these patients requires a preventive strategy for oral and parodontal surgery that includes:

- the ability and the knowledge to perform atraumatic surgery;
- the use of sutures, compression bandages and local or systemic hemostatic agents. Assuming different reference books that propose different patterns for hemostasis and according to Bulgarian experience in this direction, most frequently used medicaments are as follow:

EAK, amp. 40% 20 ml	I.v. very slow 1 amp.
Pamba, amp. 1% 5 ml	I.m., I.v. 1–2 amp./24 h.
Vit. K, amp. 1% 1ml	I.m, I.v.
Metadiol	5–10 mg oral/24 hours
Phytonadione	5–10 mg oral/24 hours
Tranexamic acid	10–12,5 mg/kg 2 times a day, p.o.
Desmopressin	03 mg/kg i.v. for 30 min single dose
Conjugated estrogen	0,6 mg/kg i.v. or 2,5–25 mg p.o. for 5 days

Cryoprecipitates are less frequently used because of the risk of disease transmission [40, 67, 80].

6. Post transplantation period (fig. 6)

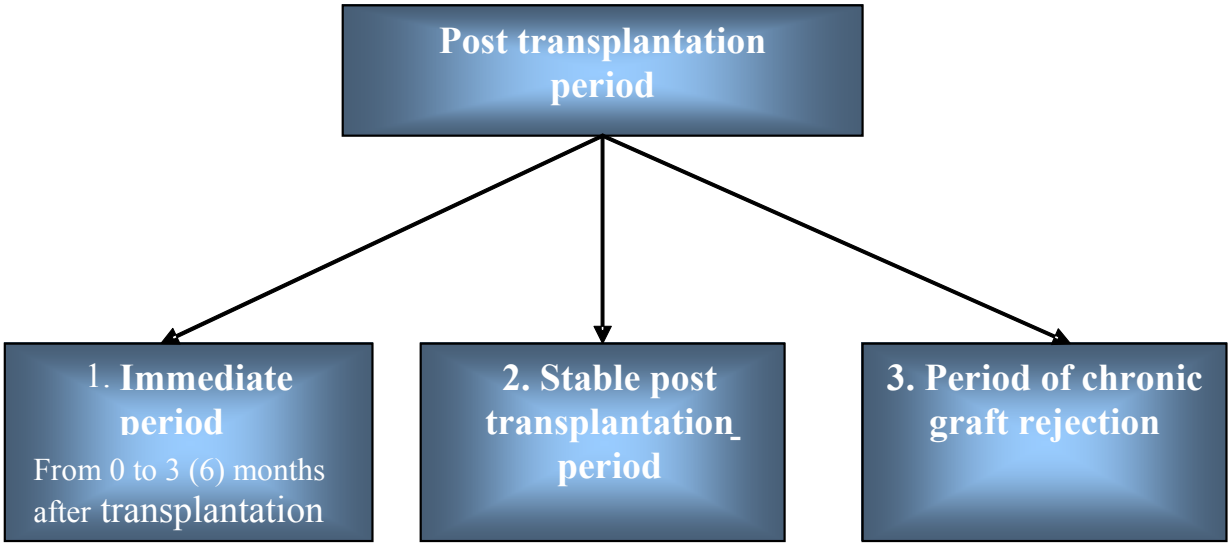


Figure 6. Schematic depiction of the post transplantation period

Dental treatment after transplantation can be differentiated in 3 periods - **immediately** after transplantation to the 3rd month after transplantation, **stable** post-transplantation period, and the period of **chronic graft rejection** [45, 67]. Diaz [54] defines the immediate after transplantation period till the 6th month following the operation.

Through the immediate period the possibility for post-operative complications, dominating opportunistic virus and fungal infections, the risk of acute graft rejection is greater. Therefore dental interference is not advisable, excluding any emergencies [53, 67, 82, 117].

Muzyka et al. [78] and J. B. Epstein [35] find that the most used antifungal agent in the initial treatment plan of surface forms of oral candidiasis is Nystatin, applied locally as well as

clotrimazole. Parenteral administration of Amphotericin B is associated with increased nephrotoxicity, especially in combination with cyclosporin or aminoglycoside antibiotics. A diluted parenteral solution of Amphotericin B for mouth rinse is successfully used in USA [15]. Ketoconazole is part of the imidazole group, but in combination with cyclosporine it may lead to increased level of Cyclosporin A [32, 49, 99, 124].

The recommendations for dental treatment in the immediate after-transplantation period are the following:

- Avoiding routine dental treatment, and if such is needed, conservative treatment methods should be used;
- Meticulous oral hygiene that includes mouth rinse solutions containing chlorhexidine. Djemileva [30] points out that the simultaneous use of toothpastes containing sodium laurylsulfate may inactivate the chlorhexidine which is part of some mouth rinse solutions and gels.

Dental rehabilitation of patients on hemodialysis and transplanted patients would be more successful, if the methods of complex focal diagnostics and treatments are applied. They are non-invasive and provide atraumatic and aseptic work techniques, combining thermal diagnostics and a laser treatment approach.

Author details

M. Dencheva², E. Deliverska^{1*}, A. Krasteva², J. Galabov² and A. Kisselova²

*Address all correspondence to: elitsadeliverska@yahoo.com

1 Department of Oral and Maxillofacial Surgery, Faculty of Dental Medicine, Medical University, Sofia, Turkey

2 Department of imaging and oral Diagnostics, Faculty of Dental Medicine, Medical University, Sofia, Turkey

References

- [1] Al Nowaiser, A., V. S. Lucas, M. Wilson, G. L. Roberts, R. S. Trompeter. Oral health and caries related microflora in children during the first three months following renal transplantation. *Int J Pediatr Dent*, 2004, 14, 2: 118–126 (9).
- [2] Al Wahadni, A., M. A. Al Omari. Dental diseases in a Jordanian population on renal dialysis. *Quintessence Int*, 2003; 34: 343–347.

- [3] Asante-Korang, A., G. J. Boyle, S. A. Webber, S. A. Miller, F. J. Fricker. Experience of FK506 immune suppression in pediatric heart transplantation: a study of long-term adverse effects. *J Heart Lung Transplant*, 1996;15: 415–22.
- [4] Azmanova, V., L. Brankova, I. Ivanov, L. Videnov, P. Karaboicheva. Atlas of oral diseases. Medicine, C., 1992.
- [5] Baddour, L., M. Bettmann, A. Bolger, A. Epstein, P. Ferriere et al. Nonvalvular cardiovascular device-related infections. *Circulation*, 2003; 108: 2015–2031.
- [6] Barnett, M. The oral-systemic disease connection. An update for the practicing dentist. *JADA*, 2006, vol. 137, 5S–6S.
- [7] Bayraktar, G., C. Kurtulus, R. Kazancioglu et al. Effect of educational level on oral health in peritoneal and hemodialysis patients. *International Journal of Dentistry* (2009) Article ID 159767, 5 pages
- [8] Bayraktar, G., I. Kurtulus, A. Duraduryan et al. Dental and periodontal findings in hemodialysis patients. *Oral Dis*, 2007; 13: 393–7.
- [9] Bennett, W. M. et al. Drug prescribing in renal failure, 1999, 2nd ed. Philadelphia, American College of Physicians.
- [10] Birkeland, S. A. et al. Cancer risk after renal transplantation in the Nordic countries, 1964–1986. *Int J Cancer*, 1995; 60: 183–189.
- [11] Borawski, J., M. Wilczynska-Borawska, W. Stokowska, M. Mysliwiec. The periodontal status of pre – dialysis chronic kidney disease and maintenance dialysis patients. *Nephrol Dial Transplant*, 2007; 22: 457–464.
- [12] Bots, C. P., H. S. Brand, H. G. Poorterman. Oral and salivary changes in patients with end stage renal disease (ESRD): a two year follow – up study. *British dental Journal*, 2007; 10; 10–38.
- [13] Bots, C., J. Poorterman, H. Brand, H. Kalsbeek, B. Amerongen, E. Veerman, A. Nieuw Amerongen. The oral health status of dentate patients with chronic renal failure undergoing dialysis therapy. *Oral Dis*, 2006; 12: 176–180.
- [14] Brancati, F. et al. Risk of end-stage renal disease in diabetes mellitus. A prospective cohort study of men screened for MRFIT. *JAMA*, 1997, 278: 2069–2074.
- [15] Brandell, R., S. L. Chase, J. R. Cohn. Treatment of oral candidiasis with amphotericin B solution. *Clin Pharm*, 1988; 7: 70–2.
- [16] Burne, R. A., R. E. Marquis. Alkalai production by oral bacteria and protection against dental caries. *FEMS Microbiol Lett*, 2000; 193: 1–6.
- [17] Caillard, S., L.Y. Agodoa, E.M. Bohen, K.C. Abbott. Myeloma, Hodgkin disease, and lymphoid leukemia after renal transplantation: characteristics, risk factors and prognosis. *Transplantation*, 2006, 27; 81 (6): 888–95.

- [18] Cervero, A. J., J. V. Bagan, Y. J. Soriano, R. P. Roda. Dental management in renal failure: Patients on dialysis. *Med Oral Patol Oral Cir Bucal*, 2008 Jul 1; 13 (7): E 419–27.
- [19] Chainani-Wu, N., T. Wu. Immunosuppressants. *CDA Journal*, 2006, vol. 36, 10, 775–779.
- [20] Chavez, E. Systematic review of the medication list: A resource for risk assessment and dental management. *CDA Journal*, October 2008, vol. 36; 10: 739–745.
- [21] Chuang, S. F., J. M. Sung, S. C. Kuo, J. J. Huang, S. Y. Lee. Oral and dental manifestations in diabetic and nondiabetic uremic patients receiving hemodialysis. *OOOOE*, 2005, 99: 6; 689–695.
- [22] Craig, R. G. Interactions between chronic renal disease and periodontal disease. *Oral Dis*, 2008 Jan; 14 (1): 1–7.
- [23] Davidovich, E., M. Davidovits, E. Eidelman, Z. Schwarz, E. Bimstein. Pathophysiology, therapy, and oral implications of renal failure in children and adolescents: an update. *Pediatr Dent*, 2005 Mar–Apr; 27 (2): 98–106.
- [24] Davidovich, E., Z. Schwarz, M. Davidovitch, E. Eidelman, E. Bimstein. Oral findings and periodontal status in children, adolescents and young adults suffering from renal failure. *J Clin Periodontol*, 2005; 32: 1076–1082.
- [25] Davies, A., K. Broadley, D. Beighton. Xerostomia in patients with advanced cancer. *Journal of pain and symptom management*, 2001 October, vol. 22; 4: 820–825.
- [26] De la Rosa Garcia, E. et al. Oral mucosa symptoms, signs and lesions, in end stage renal disease and non end – stage renal disease diabetic patients. *Med Oral Patol Oral Cir Bucal*, 2006 Nov 1; 11 (6): E 467–73, Synder, S., B. Pendrgraph. Detection and evaluation of chronic kidney disease. *Am Fam Physician*, 2005 Nov 1; 72 (9): 1723–32.
- [27] De Rossi, S., M. Glick. Dental considerations for the patient with renal disease receiving hemodialysis. *JADA*, vol. 127, 1996, 211–219.
- [28] Djemileva, T. Xerostomia (dryness in mouth). *Publ., ALIEP*, 1998.
- [29] Djemileva, T. Parodontal diseases. *Publ. „ALIEP”, C.*, 1999, 367.
- [30] Djamileva, T., Bolqrova, T. Gingival hyperplasia during system intake of calcium antagonists, immunosuppressants and hydantoins. *Publ. „ALIEP”, C.*, 2007, 118.
- [31] Donald, G. Vidt. Inflammation in renal disease. *Am J Cardiol*, 2006; 97 [supp]: 20A–27A.
- [32] Dongari-Bogtzoglou, A. et al. Oral Candida infection and colonization in solid organ transplant recipients. *Oral Microbiol Immunol*, 2009 Juni; 24 (3): 249–254.
- [33] Ellervall, E., F. Bjorklund, M. Rohlin, E. Vinge, K. Knutsson. Antibiotic prophylaxis in oral health care: administration strategies of general dental practitioners. *Acta Odontologica Scandinavica*, 2005; 63: 321–329.

- [34] Ellis, J. S., R. A. Seymour, J. J. Taylor, J. M. Thomason. Prevalence of gingival overgrowth in transplant patients immunosuppressed with tacrolimus. *J Clin Periodontol*, 2004, 31: 126–131.
- [35] Epstein, J. B. Antifungal therapy in oropharyngeal mycotic infections. *Oral Surg Oral Med Oral Pathol*, 1990; 69: 32–41.
- [36] Ertugrul, F., C. Elbek-Cubukcu, E. Sabah, S. Mir. The oral health status of children undergoing hemodialysis treatment. *Turk J Pediatr*, 2003; 45: 108–113.
- [37] Fisher, M., G. Taylor. A prediction model for chronic kidney disease includes periodontal disease. *J Periodontol*, 2009, 1, 80, 16–23.
- [38] Franca, C. M., M. Domingues-Martins, A. Volpe et al. Severe oral manifestations of chronic graft-vs.-host disease. *JADA*, Vol. 132, August 2001.
- [39] Friedlander, A. et al. Restless legs syndrome. *JADA*, June 2006, vol. 137, 755–761.
- [40] Gacina, P., D. Carzavec, V. Stancic, V. Pejisa. Dental procedures in patients receiving oral anticoagulant therapy. *Acta clin Croat*, 2006, 45 (2): 101–104.
- [41] Gavalda, C., J. Bagan, C. Scully, F. Silvestre, M. Milian, Y. Jimenez. Renal haemodialysis patients: oral, salivary, dental and periodontal findings in 105 adult cases. *Oral Dis*, 1999; 5: 299–302.
- [42] Gera, I., T. Keglevich. A case history of a kidney transplant patient with ciclosporin – induced gingival overgrowth combined with chronic periodontitis. *Perio*, 2007; 12: 287–293.
- [43] Gheith, O. A., S. Ali-El Saadany et al. Compliance with recommended life style behaviours in kidney transplant recipients. Does it matter in living donor kidney transplant? *IJKD*, 2006; 2: 216–26.
- [44] Graig, R., P. Kotanko, A. Kamer, N. Levin. Periodontal diseases – a modifiable source of systemic inflammation for the end-stage renal disease patient on haemodialysis Therapy. *Nephrol Dial Transplant*, 2007, 22: 312–315.
- [45] Gudapati, A., P. Aahmed, R. Rada. Dental management of patients with renal failure. *Gen Dent.*, 2002 Nov-Dec; 50 (6): 508–10.
- [46] Guggenheimer, J., D. Mayher, B. Eghtesad. A survey of dental care protocols among US organ transplant centers. *Clinical Transplantation*, 2005; 19: 15–8.
- [47] Guggenheimer, J., P. Moore. Xerostomia. Etiology, recognition and treatment. *JADA*, vol. 134, 2003.
- [48] Gurkan, A., T. Kose, Gul. Atilla. Oral health status and oral hygiene habits of an adult Turkish population on dialysis. *Oral Health Prev Dent*, 2008, 6, 1:37–43.

- [49] Hamid, M., C. Dummer, L. Pinto. Systemic conditions, oral findings and dental management of chronic renal failure patients: general considerations and case report. *Braz Dent J*, 2006, 17 (2): 166–170.
- [50] Hassell, T. M., A. F. Hefti. Drug-induced gingival overgrowth: old problem, new problem. *Crit Rev Oral Biol Med*, 1991; 2: 103–37.
- [51] Heeger, P. Frontiers in nephrology: Tolerance. *J Am Soc Nephrol*, 2007, 18: 2240–2241.
- [52] Helenius, L., J. Meurman, I. Helenius, K. Kari, J. Hietanen, R. Suuronen et al. Oral and salivary parameters in patients with rheumatic diseases. *Acta Odontologica Scandinavica*, 2005; 63: 284–293.
- [53] Herr, R., R. Cydulka. Emergency care of the compromised patient. 1994, 808.
- [54] <http://www.usc.edu/hsc/dental/dhnet/papers/coral149.html>
- [55] Jaffe, E. C., G. J. Roberts, C. Chantler, J. E. Carter. Dental findings in chronic renal failure. *Br Dent J*, 1986; 160: 18–20.
- [56] James, J., S. Boomer, A. Maxwell, P. Hull, C. Short et al. Reduction in gingival overgrowth associated with conversion from cyclosporine A to tacrolimus. *J Clin Periodontol*, 2000; 27: 144–148.
- [57] James, J., S. Jamal, P. Hull, T. Macfariane, B. Campbell et al. Tacrolimus is not associated with gingival overgrowth in renal transplant patients. *J Clin Periodontol*, 2001; 28: 848–852.
- [58] Kellett, M. Oral white plaques in uraemic patients. *B Dent J*, 1983; 154: 366.
- [59] Kerr, A. R. Update on renal disease for the dental practitioner. *Oral Surg Oral Med Oral Pathol*, 2001; 92: 9–16.
- [60] Kho, H. S., S. W. Lee, S. C. Chung, Y. K. Kim. Oral manifestations and salivary flow rate, pH, and buffer capacity in patients with end-stage renal disease undergoing hemodialysis. *Oral Surg Oral Med Oral Pathol Oral Radiol Endod*, 1999, 88: 316–319.
- [61] Kiselova-Yaneva, A. Dental allergology and focal diagnostics. Gutenberg, C., 2001, 327 c.
- [62] Kitsou, V. K., A. Konstantinidis & K. C. Siamopoulos. Chronic renal failure and periodontal disease. *Renal failure*, 2000, 22; 307–318.
- [63] Kozarov, E. V., B. R. Dorn, C. E. Shelburne et al. Human atherosclerotic plaque contains viable invasive *Actinobacillus actinomicetemcomitans* and *Porphyromonas gingivalis*. *Arterioscler Thromb Vasc Biol*, 2005; 25: e17–e18.
- [64] Krennmair, G., J. Auer et al. Odontogenic infection sources in patients scheduled for cardiac valve replacement. *Oral Health Prev Dent*, 2007; 2: 153–159.

- [65] Kshirsager, A. et al. Periodontal disease adversely affects the survival of patients with end-stage renal disease. *Kidney International*, 2009, 75, 746–751.
- [66] Little, J. W., D. A. Falace et al. *Dental management of the medically compromised patient*, seventh ed., St. Louis, Mo., Mosby Elsevier, 2008.
- [67] Little, J., D. Falace, G. Miller, N. Rhodus. *Dental Management of the Medically Compromised Patient*. Sixth edition, Chapter 9, 2002, 617.
- [68] Lockhart, P. B., J. Gibson, S. H. Pond, J. Leitch. Dental management considerations for the patient with an acquired coagulopathy. Part 1: Coagulopathies from systemic disease. *British Dental Journal*, 2003; 195: 439–445.
- [69] Lockhart, P., B. Loven, M. Brennan, Ph. Fox. The evidence base for the efficacy of antibiotic prophylaxis in dental practice. *J Am Dent Assoc*, 2007, 4, 458–474.
- [70] Lockhart, P., M. Brennan, H. Sasser P. Fox et al. Bacteremia associated with toothbrushing and dental extraction. *Circulation*, 2008; 117; 3118–3125.
- [71] Long, R., L. Hlousek, J. Doyle. Oral manifestations of systemic diseases. *Dermatol Clin*, 1998, 65: 309–315.
- [72] Malmberg, E., D. Birkhed et al. Microorganisms on toothbrushes at day – care centers. *Acta Odontol Scand*, 1994; 52: 93–98.
- [73] Marton, K., M. Madlena, J. Banoczy, G. Varga et al. Unstimulated whole saliva flow rate in relation to sicca symptoms in Hungary. *Oral Diseases*, 2008, 14, 472–477.
- [74] Mc Donald, P., Avery, D. *Стоматология детей и подростков*. Пер. с англ. М., Медицинское информационное агентство, 2003. 766 с.
- [75] McCartan, B. E., C. E. McCreary. Oral lichenoid drug eruptions. *Oral Dis*, 1997; 3: 58–63.
- [76] Meechan, J. G., M. Greenwood. General medicine and surgery for dental practitioners Part 9: Haematology and patients with bleeding problems. *BDJ*, 2003 September, vol. 195; 305–310.
- [77] Mihailova, Hr., Nikolov, V. Maxillofacial changes during hemodialysis and secondary hyperparathyroidism. *Dental management, C.*, 1999–2000, issue XXVII, 59–64.
- [78] Muzyka, B., M. Glick. A review of oral fungal infections and appropriate therapy. *JADA*, 1995, vol. 126.
- [79] Naugle, K., M. L. Darby, D. B. Bauman, L. T. Lineberger, R. Powers. The oral health status of individuals on renal dialysis. *Ann Periodontol*, 1998, 3: 197–205.
- [80] Nishide, N., T. Nishikawa, N. Kanamura. Extensive bleeding during surgical treatment for gingival overgrowth in patient on haemodialysis. A case report and review of the literature. *Australian dental journal*, 2005; 50: 4.

- [81] Nunn, J. H., J. Sharp, H. J. Lambert, N. D. Plant, M. G. Coulthard. Oral health in children with renal disease. *Pediatr Nephrol*, 2000; 14: 997–1001.
- [82] Otten, J. E. Zahnsanierung vor und nach Organtransplantation. Wissenschaftliche Stellungnahme der DGZMK, 1998.
- [83] Pallasch, Th. Perspectives on the 2007 AHA endocarditis prevention guidelines. *CDA Journal*, July 2007, vol. 35; 7: 50–513.
- [84] Pejicic, A., S. Pesevska, I. Grigorov, M. Bojovic. Periodontitis as a risk factor for general disorders. *Acta Fac Med Naiss*, 2006; 23 (2): 59–63.
- [85] Peneva, M., Anadolska, A., Apostolova, D. Tooth decay in children suffering CKD. *Dentistry, C.*, 3, 1989, 6–9.
- [86] Peneva, M., Anadolska, A., Apostolova, D. Oral status in children with CKD. *Dentistry, C.*, 3, 1988, 72–76.
- [87] Peneva, M., Anadolska, A., Apostolova, D. Eruption of permanent teeth in children with CKD. *Dentistry, C.*, 2, 1989, 8–11.
- [88] Penn, I. Occurrence of cancers in immunosuppressed organ transplant recipients. *Clin Transpl*, 1998: 147–157.
- [89] Pernu, H. E., L. M. Pernu, K. R. Huttunen, P. A. Nieminen, M. L. Knuuttila. Gingival overgrowth among renal transplant recipients related to immunosuppressive medication and possible local background factors. *J Periodontol.*, 1992; 63: 548–53.
- [90] Petrunov, B., Dimitrov, V., Kiselova-Yaneva, A. Clinical immunology, allergology, dental clinical allergology. *C., Apco*, 2009, 276.
- [91] Porter, S. R., A. Hegarty, C. Scully. An update of the etiology and management of xerostomia. *Oral Surg Oral Med Oral Pathol Oral Radiol Endod*, 2004, 97: 28–46.
- [92] Proctor, R., N. Kumar, A. Stein, D. Moles, S. Porter. Oral and dental aspects of chronic renal failure. *J Dent Res.*, 2005 Mar; 84 (3): 199–208.
- [93] Quirynen, M., M. De Soete, M. Pauwels et al. Bacterial survival rate on tooth – and interdental brushes in relation to the use of toothpaste. *J Clin Periodontol*, 2001: 28: 1160–1114.
- [94] Radwan-Oczko, M., M. Boratynska, M. Zietec, T. Dobosz. Transforming growth factor – β 1 gene expression and cyclosporine A – induced gingival overgrowth: a pilot study. *J Clin Periodontol*, 2008; 35: 371–378.
- [95] Ross, W. F., P. L. Salisbury. Uremic stomatitis associated with undiagnosed renal failure. *Gen Dent*, 1994; 9/10: 410–412.
- [96] Rustemeyer, J., A. Bremerich. Necessity of surgical dental foci treatment prior to organ transplantation and heart valve replacement. *Clin Oral Invest*, 2007, 11: 171–174.

- [97] Rustemeyer, J., M. Black, A. Bremerich. Stellenwert der dentalen und parodontalen Fokussanierung vor Organtransplantationen und Herzklappenersatz. *Transplantationsmedizin*, 2006; 18: 24.
- [98] Sarachev, E. Connection between some joint diseases and foci of odontogenic origin. *Journal of IMAB – Annual Proceeding (Scientific papers)*, 2006, book 2.
- [99] Segal, B., G. Nikolaus et al. Prevention and early treatment of invasive fungal infection in patients with cancer and neutropenia and in stem cell transplant recipients in the era of newer broad-spectrum antifungal agents and diagnostic adjuncts. *Clinical Infectious Diseases*, 2007; 44: 402–9.
- [100] Seymour, R. A., J. M. Thomason, A. Nolan. Oral lesions in organ transplant patients. *J Oral Path Oral Med*, 1997; 26: 297–304.
- [101] Seymour, R. A., J. M. Whitworth. Antibiotic prophylaxis for endocarditis, prosthetic joints, and surgery. *Dent Clin North Am*, 2002; 46 (4): 635–51.
- [102] Seymour, R., D. Smith, S. Rogers. The comparative effects of azathioprine and cyclosporine on some gingival health parameters of renal transplant patients. *J. Clin Periodontol*, 1987; 14: 610–613.
- [103] Seymour, R., D.J. Jacobs. Cyclosporin A and the gingival tissues. *Journal of clinical periodontology*, 1992; 19: 1–11.
- [104] Seymour, R., M. Rudralingam. Oral and dental adverse in drug reactions. *Periodontology*, 2000, vol. 46, 2008, 9–26.
- [105] Shu, M., E. Morou-Bermudez et al. The relationship between dental caries status and dental plaque urease activity. *Oral microbiology and Immunology*, 2007, 22: 1: 61–66.
- [106] Smith, J., G. Wong et al. Sonic tooth brushing reduces gingival overgrowth in renal transplant recipients. *Pediatr Nephrol*, 2006, 21: 1753–1759.
- [107] Soave, R. Prophylaxis strategies for solid-organ transplantation. *Clinical Infectious Diseases*, 2001; 33 (suppl 1): S26–31.
- [108] Somacarrera, M. L., G. Hernandez, J. Acero, B. S. Moskow. Factors related to the incidence and severity of cyclosporine – induced gingival overgrowth in transplant patients. A longitudinal study. *J Periodontol*, 1994; 65: 671–5.
- [109] Sowell, Sb. Dental care for patients with renal failure and renal transplantation. *J am dent assoc*, 1982; 104 (2): 171–7.
- [110] Summers, S. A., W. M. Tilakaratne, F. Fortune, N. Ashman. Renal disease and the mouth. *Am J Med*, 2007; 120 (7): 568–73.
- [111] Takeuchi, Y., H. Ishikawa, M. Inda, O. Shinozuka, M. Umeda, Ts. Yamazaki. Study of the oral microbial flora in patients with renal disease. *Nephrology*, 2007; 12 (2), 182–190.

- [112] Taylor, B. A. Management of drug – induced gingival enlargement. *Australien Prescriber*, 2003, vol. 26, 1.
- [113] Temnqlov, N. Urea-pharmacology, clinics and therapeutic aspects. *Grafik OOD, Varna*, 2004, 78.
- [114] Terasaki, P. I., J. M. Cecka, D. W. Gertson, S. Takemoto. High survival rates of kidney transplants from spousal and living unrelated donors. *N Engl J Med*, 1995; 10: 333–6.
- [115] Thomason, J. M., R. A. Seymour. The prevalence and severity of cyclosporin and nifedipine – induced gingival overgrowth. *J Clin Periodontol*, 1993; 20: 37–40.
- [116] Thorp, M., A. DeMattos, W. Bennett, J. Barry, D. Norman. The effect of conversion from cyclosporine to tacrolimus on gingival hyperplasia, hirsutism and cholesterol. *Transplantation*, 2000, 69 (6): 1218–20.
- [117] Toivonen, H. J. Anaesthesia for patients with a transplanted organ. *Acta Anaesthesiologica Scandinavica*, 2000; 44: 812–833.
- [118] Tollefsen, T. & R. Johansen. Periodontal status of prospective and renal transplant patients. Comparison with systemically healthy subjects. *Journal of periodontal research*, 1985 a), 20, 220–226.
- [119] Tong, D., B. Rothwell. Antibiotic prophylaxis in dentistry: A review and practice recommendations. *JADA* March 2000, vol. 131: 366–374.
- [120] Tong, D., R. Walker. Antibiotic prophylaxis in dialysis patients undergoing invasive dental treatment. *Nephrology*, 2004; 3: 167–170.
- [121] Vanholder, R., E. Shepers, N. Meert, N. Lameire. What is uremia? Retention versus oxidation. *Blood Purif*, 2006; 24: 33–38.
- [122] Villaciaran, J., C. Paya. Prevention of infections in solid organ transplant recipients. *Transplant Infectious Disease*, 1999; 1: 50–64.
- [123] Wilson, W., K. Taubert, M. Gewitz et al. Prevention of infective endocarditis. Guidelines from American Heart Association. *Circulation*, 2007; 115; &NA.
- [124] Zaiton, H. End stage renal disease: The oral component. *BDJ*, 2006, 201, 180.
- [125] Zlatkov, N., Andreev, N. Skin manifestations of internal diseases. *Wolkohim, C.*, 1994, 263.