

We are IntechOpen, the world's leading publisher of Open Access books Built by scientists, for scientists

6,900

Open access books available

186,000

International authors and editors

200M

Downloads

Our authors are among the

154

Countries delivered to

TOP 1%

most cited scientists

12.2%

Contributors from top 500 universities



WEB OF SCIENCE™

Selection of our books indexed in the Book Citation Index
in Web of Science™ Core Collection (BKCI)

Interested in publishing with us?
Contact book.department@intechopen.com

Numbers displayed above are based on latest data collected.
For more information visit www.intechopen.com



Toxicities of New Drugs for Melanoma Treatment and their Management

Paola Savoia and Paolo Fava

Additional information is available at the end of the chapter

<http://dx.doi.org/10.5772/59860>

1. Introduction

Advanced melanoma is a highly aggressive tumor with a low response rate to the majority of pharmacological agents.

Among conventional cytotoxic chemotherapies, dacarbazine (DTIC) is the only FDA-approved alkylating agent, at present; its clinical efficacy is pretty low with 5–10% responsiveness, which is generally short-lived. Carmustine, temozolomide and other chemotherapeutic agents (taxanes and platinum-analogs) showed similar efficacy in metastatic settings [1, 2].

Adjuvant immunotherapy for stage III melanoma is mainly based on interferon- α 2b (IFN- α 2b) even if its efficacy is quite limited. In fact, only about the 20% of patients showed an improvement in relapse-free survival as demonstrated in randomized observation-controlled trials without a clear effect on overall survival [3]. FDA approved high-dose interleukin-2 (IL-2) for the treatment of advanced stage melanoma, on the basis of its ability to elicit durable responses in a small percentage of patients [4, 5]. However, the durable response rate is only 10-20% and toxicities associated with IL-2 are quite severe.

Recently, molecular targeted therapies have radically changed the management of metastatic melanoma. Anti-CTLA-4 monoclonal antibodies (Ipilimumab) and B-Raf inhibitors are the first examples of this new kind of drugs, the firsts approved with both overall survival and progression-free survival benefits in respect of the standard chemotherapeutic agent dacarbazine [6-10].

Ipilimumab targets the anti-cytotoxic T-lymphocyte antigen-4, a key immune-checkpoint molecule that down-regulates some pathways of T-cell activation. Ipilimumab inactivating the CTLA-4 inhibitory signal, enhance the immune system response against melanoma cells. Several randomized phases II and III trials demonstrated a statistically significant improvement in overall survival in patients with metastatic melanoma treated with Ipilimumab alone

or in combination with dacarbazine. The efficacy of Ipilimumab was confirmed both in treated and untreated metastatic melanoma patients [6, 9, 11]. Furthermore, re-treatment with Ipilimumab can re-establish disease control in a percentage of patients who progress after achieving an objective response or stable disease after the first treatment course [6, 9, 11-13].

As a consequence of this peculiar mechanism of action, Ipilimumab may determine the development of autoimmune conditions and exacerbate a series of immune-related adverse events, which will be described in the next section of this review.

Vemurafenib is a low molecular weight molecule (489.9 Da), orally available, which belongs to the new generation inhibitors of B-Raf as well as of other members of the RAF kinase family (including the products of ARAF, BRAF and CRAF genes). The BRAF protein is a part of the RAS/RAF/MEK/ERK signaling pathway, which is a key regulator of melanoma cell growth. In cells expressing the pro-oncogenic BRAF-V600E, BRAF-V600D and BRAF-V600R genes, Vemurafenib inhibits both phosphorylated ERK (pERK) and pMEK in a dose-dependent manner, resulting in a reduction of tumour growth and even in tumour regression in in vitro studies and xenograft transplant models. Several clinical trials have confirmed and extended these preclinical observations and, to date, RAF inhibitors represent the emerging standard of care for metastatic melanoma harboring the BRAF-V600E mutation, with clinical responsiveness in more than 90% of these patients [1, 14]. In particular, results from a phase III clinical trial of patients expressing the BRAF-V600E mutated isoform affected by unresectable or metastatic melanoma showed a median overall survival significantly higher for Vemurafenib-treated patients, in comparison to those treated with dacarbazine (13.2 vs 9.9 months, respectively).

Even if the toxicity of this treatment is normally considered to be acceptable, Vemurafenib triggers the onset of a wide spectrum of systemic and cutaneous toxicities which can impact patient's quality of life in a significant way [15-17]. The adverse effects, which will be detailed later, are dose-dependent and related to the alteration of the cell-signaling pathway in response to B-Raf inhibition in cells expressing the wild-type BRAF gene [18].

2. Ipilimumab toxicities

The onset of immune-related adverse events (irAEs) during the treatment with Ipilimumab is consequent to action on the immune system. Actually, CTLA-4 blockage removes CTLA4-mediated downregulation of the immune response, leading thus to a large spectrum of autoimmune-inflammatory side effects with a dose-dependent mechanism [19]. These irAEs are described both at the currently approved 3mg/kg dose and at the investigational 10mg/kg dose and may affect a number of organs and systems, including the eye, the skin, the gut and the endocrine system.

In a retrospective analysis of phase I-III Ipilimumab trials on patients with advanced melanomas, the occurrence of irAEs of any grade was a quite common phenomenon, regarding about 60% of the patients [20]. Nevertheless, Ipilimumab can be considered a safe drug: irAEs-related deaths occurred only in about 1% of treated patients [20]. In these trials, the most common immune side effects were represented by enterocolitis, dermatitis, hepatitis, hypo-

physitis, and uveitis, usually with an early onset. More recent data obtained on an Italian multi-centric expanded-access cohort reported an occurrence of irAEs of any grade in 33% of treated patients, with a median time of onset of 5 weeks. Most irAEs were low grade, whereas grade 3/4 irAEs were described in 6% of the cases and were most commonly represented by diarrhea, liver toxicity and fatigue/asthenia [21].

IrAE	Grade 1	Grade 2	Grade 3	Grade 4
Skin Toxicity	Mild to moderate localized rash or pruritus; papules/pustules covering <10%–30% of the body surface	Non localized rash (diffuse, ≥50% of skin surface)	Intense and widespread (>30% of body surface) skin rash; skin sloughing of <10%–30% of the body surface; epidermal or mucus membrane detachment	Stevens–Johnson syndrome, toxic epidermal necrolysis, or rash complicated by full-thickness dermal ulceration, or necrotic, bullous, or hemorrhagic manifestations
Diarrhea	Increase of <4 stools per day over baseline; mild increase in ostomy output compared with baseline	Increase of 4–6 stools per day over baseline; Intra venous fluids indicated <24 hours; moderate increase in ostomy output compared to baseline; not interfering with activities of daily living	Increase of ≥7 stools per day over baseline; incontinence; Intra venous fluids >24hours; hospitalization; severe increase in ostomy output compared with baseline; interfering with activities of daily living	Life-threatening diarrhea, causing severe hemodynamic alterations and even collapse
Liver toxicity	Asymptomatic or mild symptoms; clinical or diagnostic observations only; intervention not indicated	AST or ALT >2.5 to ≤5.0 × ULN and/or total bilirubin >1.5 to ≤3.0× ULN	AST or ALT >5× ULN and/or total bilirubin >3.0× ULN	Moderate to severe encephalopathy with abnormal plasma levels of ammonia, bilirubin, lactic dehydrogenase, and alkaline phosphatase
Endocrine toxicity	Asymptomatic; clinical or diagnostic observations only; intervention not indicated	Moderate symptoms; medical intervention indicated	Severe symptoms; hospitalization indicated	Adrenal crisis: severe dehydration, hypotension, or shock. Life-threatening consequences

Modified from Weber J, et al. J Clin Oncol 30 (21), 2012: 2691-2697[23].

Table 1. Most common Immunorelated Edverse events and their grade:

IrAE	Grade 1	Grade 2	Grade 3	Grade 4
Skin Toxicity	Antihistamines and topical corticosteroids; if no response, consider oral corticosteroids	Antihistamines and topical corticosteroids if no response, consider oral corticosteroids	High-dose systemic corticosteroid therapy	High-dose systemic corticosteroid therapy; antibiotics if indicated and definitive discontinuation of Ipilimumab
Diarrhea	Anti-diarrhea drugs, loperamide and diphenoxylate Patient hydration	Anti-diarrhea drugs Loperamide and diphenoxylate. Patient hydration	Hospitalization, patients hydration and systemic corticosteroids	Hospitalization, patient hydration, and systemic corticosteroids. Definitive discontinuation of Ipilimumab
Liver toxicity	Monitoring of LFTs	Withhold Ipilimumab dose and check LFTs every day for 3 consecutive days; if LFT improvement to grade 1, resume routine monitoring of LFTs and continue Ipilimumab If no improvement in the LFTs, administer corticosteroid treatment and skip the next Ipilimumab dose until event resolves	Withhold Ipilimumab dose and check LFTs every day for 3 consecutive days; if LFT improvement to grade 1, resume routine monitoring of LFTs and continue Ipilimumab If no improvement in LFTs, administer corticosteroid treatment and skip the next Ipilimumab dose until event resolves	High dose of intravenous corticosteroids Definitive discontinuation of Ipilimumab
Endocrine toxicity	Abnormal endocrine workup, grade 1 or 2 endocrine toxicity without adrenal crisis May resolve spontaneously If no spontaneous resolution, consider low-moderate dose Of systemic corticosteroids Consider temporary Ipilimumab suspension	Symptoms suggestive of hypophysitis require prompt corticosteroid therapy. Temporary Ipilimumab suspension	Intravenous corticosteroids Hormone replacement Hydration Electrolyte replacement Temporary Ipilimumab suspension	Intravenous corticosteroids Hormone replacement Hydration Electrolyte replacement Definitive discontinuation of Ipilimumab

Modified from Weber J, et al. J Clin Oncol 30 (21), 2012: 2691-2697 [23].

Table 2. Most common immunorelated adverse events and their management:

In phase I-III studies, irAE resolution time varied from 4.3 to 7.7 weeks, whereas in patients included in the expanded-access projects ranged from 0.1 to 11.1 weeks (median 1.7 weeks). When grade 3/4 irAE were separately analyzed the median resolution time was 1.1 weeks (range, 0.1–3.4 weeks) [20, 21]. Despite some early findings, no relationship seems to exist between clinical benefit and irAEs onset in treated patients.

Grade 1/2 events take advantage from symptomatic treatments and the use of topical steroids, whereas early administration of high-dose systemic corticosteroids is mandatory for the right management of grade 3/4 irAEs. Specific guidelines to manage irAEs are available [19, 22]. In literature are available guidelines to manage Ipilimumab side effects (see Table 1 and 2) [23].

3. Cutaneous side effects from Ipilimumab

Systemic side effects from Ipilimumab are usually dose-related. However, the incidence and severity of pruritus or skin reactions appear independent of Ipilimumab dosage, as demonstrated by a meta-analysis of the studies in which Ipilimumab was administered as monotherapy at different doses (3 mg/kg vs 10 mg/kg),

Commonly used targeted anticancer agents (e.g. erlotinib, cetuximab, panitumumab, vandetanib, pertuzumab) usually induce a characteristic papulopustular (acneiform) rash in 68% to 75% of treated patients. Conversely, Ipilimumab-induced maculo-papular rash are more similar to those commonly seen with traditional drugs (ie, antibiotics, non steroidal anti-inflammatory drugs) or shows clinical characteristics mimicking atopic dermatitis [22].

From a recent meta-analysis performed on 19 studies from 1998-2011, which included several trials testing Ipilimumab (as monotherapy or in combination at various doses in randomized multi-arm and single-arm studies) [24], emerged that the overall incidence of all-grade rash was 24.3%. The overall incidence of high-grade rash was 2.4%, with a relative risk ranging from 0.7% to 11.8%. Interestingly, among 320 patients receiving 3 mg/kg and 440 receiving 10 mg/kg, there was no significant difference in terms of incidence of all-grade or high-grade rash between doses [24]. Skin irAEs have a shorter time of onset than those affecting other sites and usually develop 3-4 weeks after Ipilimumab initiation.

In our series of 57 patients treated with Ipilimumab, the incidence of cutaneous side effects was 10% (any grade). Ipilimumab-related skin lesion were erythematous, edematous or maculo-papular, often located on the trunk and extremities (Figure 1); vasculitic and purpuric lesions were also observed. Pruritus was present in almost half of the patients who showed skin reactions [unpublished data]. Some literature reports suggest that rash can coincide with the regression of subcutaneous disease and may be especially pronounced around nevi, suggesting the presence of an underlying inflammatory response against melanocytes [25-27]. The onset of vitiligo-like lesions during Ipilimumab treatment is also a finding related to an immune activation status of the host, and was a relatively common event in our experience [personal unpublished data], as well as in other case reports [28].

From a histological point of view, skin biopsies of Ipilimumab-related skin lesions showed a perivascular inflammatory infiltrate in the superficial dermis that extend to the epidermis with CD4+ and CD8+ T cells that are CD3+. Eosinophils may also be present [24-27].

4. Vemurafenib toxicities

Even if Vemurafenib is generally a safe and well-tolerated drug, a wide spectrum of toxic effects has been described [14-18, 29, 30]. The most common one is represented by arthralgia, which occurs in about 60% of patients. Most cases are mild to moderate, but about 5% of patients treated with Vemurafenib experienced a grade 3 arthralgia [14, 29]. These latter cases can be managed conservatively with non-steroidal anti-inflammatory drugs and acetaminophen; however, severe cases may require a short course of steroid treatment [31]

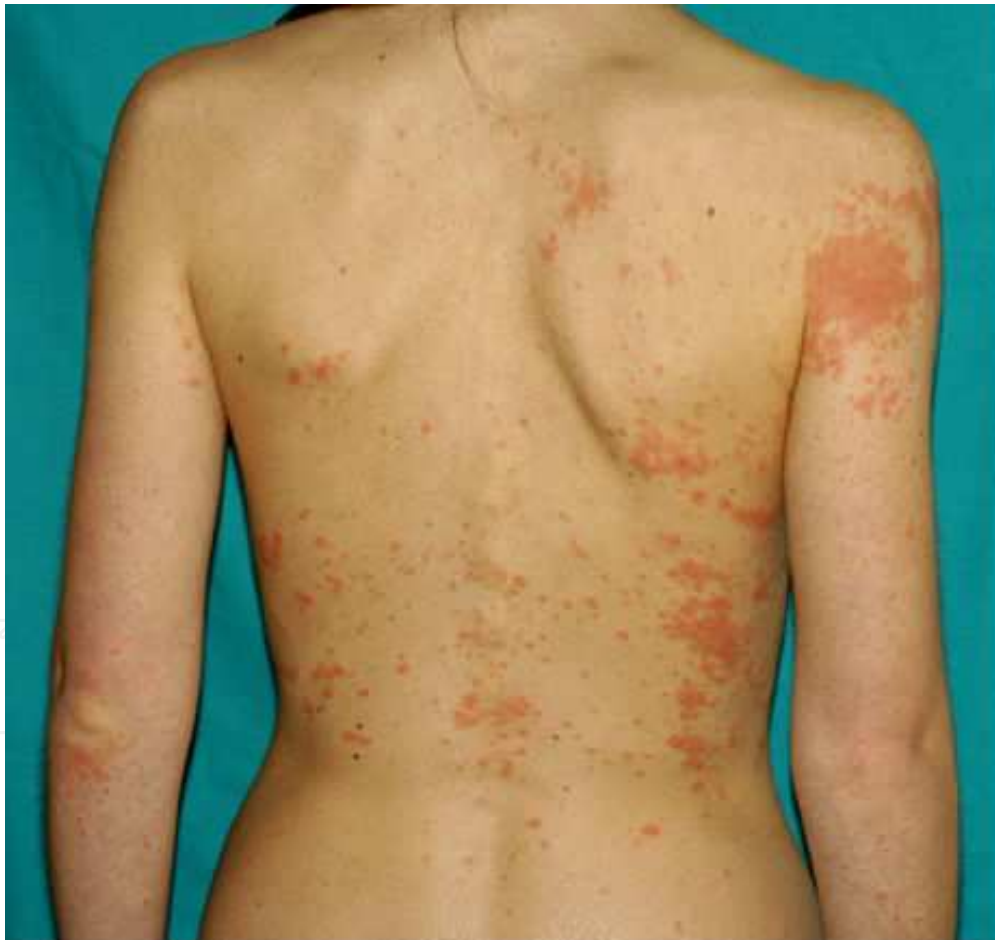

Figure 1. Erythematous-edematous rash in a patient treated with Ipilimumab

Liver enzymes should be monitored, since elevated liver enzymes have been documented in about 20% of treated patients; usually resolving with a treatment suspension [14, 29, 31].

Only a relatively small percentage of patients (approximately 20%) experience nausea, which is normally responsive to oral antiemetics [31].

Quite unusual but potentially life-threatening side effects are related to alterations of the cardiac rhythm, including the prolongation of cardiac repolarization and arrhythmia, which occurs in about 8% of patients. Hence, the monitoring of cardiac activity is mandatory in all Vemurafenib-treated patients; however, the occurrence of absolute QTc values >500 ms [29, 31, 32] that require prompt clinical management is quite rare.

5. Cutaneous side effects from Vemurafenib

Cutaneous reactions are the most common side effects described during Vemurafenib treatment and impact significantly on patient's quality of life [15-17, 29]. As expected from the experience collected with other molecular targeted therapies, skin toxicity is related to the alteration of the wild-type BRAF signaling [18].

The cutaneous adverse reactions affect a percentage of treated patients from 75 to 90%, without difference of age and sex and can be classified according to the reaction pattern and time of appearance as follows:

5.1. Rash

Literature data report the onset of a maculo-papular eruption in about 50% of treated patients [14, 16, 18, 29]. Also in our experience, rash was the earliest and most frequent cutaneous side effect during Vemurafenib treatment (48% of treated patients of our series). From a clinical point of view, this rash could be similar to other drug-related exanthemas and it is characterized by the onset of maculae and follicular papules mainly distributed on the trunk and limbs (Figure 2); the head region is generally spared. Rash appears after a median time of 11 days (range 7-55 days), it is generally self-limiting and spontaneously resolve after a median of 18 days from the onset (range 2-95). In the majority of cases, it is asymptomatic, even if some patients reported pruritus [personal unpublished data].

Cases that underwent skin biopsy show an inflammatory lympho-histiocytic lichenoid infiltrate, even if keratinocytes activation should be observed [18]. The origin of this maculo-papular eruption is still unclear; however these features can explain the usefulness of topical steroids, as well as the anecdotic finding that rash did not occurred in patients receiving concomitant steroids for medical treatments related to other diseases.

Because of the self-limiting nature of this side effect, we recommend the routinely use of topical emollients; steroids should be limited to symptomatic cases. Patients also have to be informed about the frequency and benignity of this rash; however, persistent or clinically atypical exanthemas should be referred to an experienced dermatologist to avoid the risk of Steven-Johnson Syndrome /Toxic Epidermal Necrolysis (SJS/TEN) [33, 34].

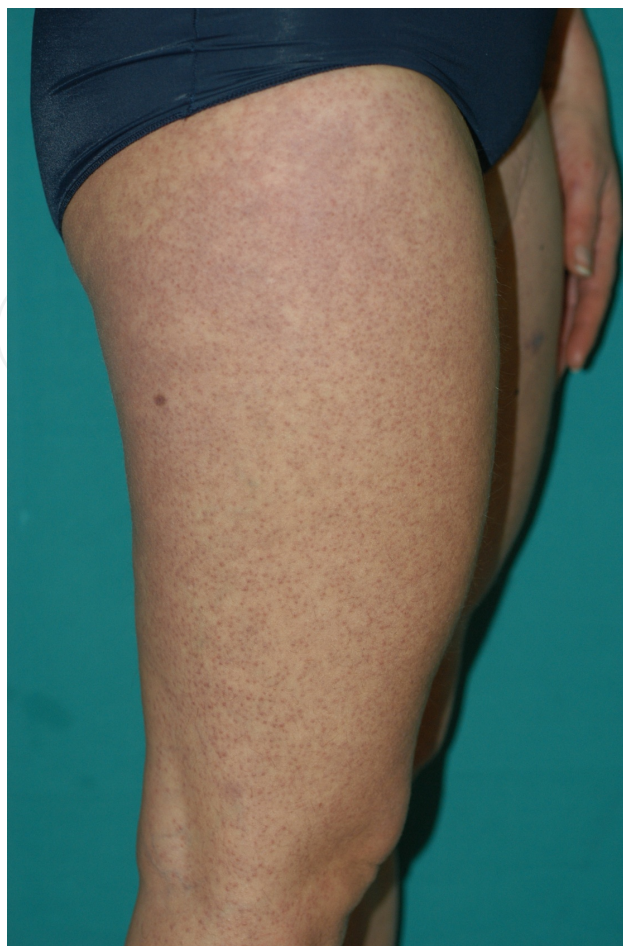

Figure 2. Maculae and follicular papules distributed on limbs in a patients treated with Vemurafenib

5.2. Warts

Viral warts represent the second most frequent cutaneous side effect of Vemurafenib [15-17] which affects about 41% of patients in our experience; median time of onset is 50 days from the initiation of treatment. Warts affect mainly the regions of the head and neck, less frequently the trunk and limbs (Figure 3). In our casistics, viral warts were the first cutaneous side effect in 13.7% of patients [unpublished data].

Histologically, Vemurafenib-dependent warts were indistinguishable from common viral warts [15, 19]; standard wart treatments (e.g. cryosurgery, keratolytic solutions, and diathermic coagulation) usually are very effective.

5.3. Hyperkeratosis

In a percentage of Vemurafenib-treated patients, the induction of a keratinocytic hyperproliferation without signs of apoptosis results in an increased epidermal thickness [28]. Plantar hyperkeratosis occurs mainly in areas under physical pressure, whereas diffuse hyperkeratotic follicular papules are observed mainly in the lower limbs and forearms (Figure 4). In our

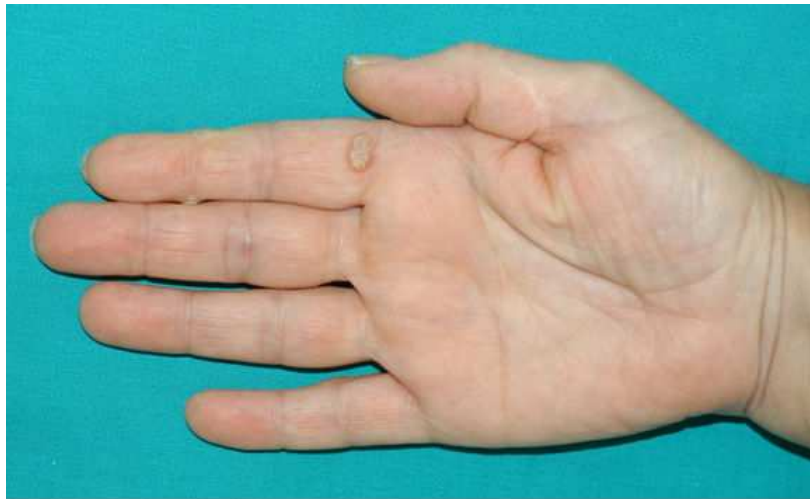


Figure 3. Disseminated viral warts in a patient treated with Vemurafenib

experience, the median onset time of localized and diffuse hyperkeratosis is 44 and 31 days, respectively.

Topical keratolytic and emollient treatment can reduce hyperkeratosis, even if a complete resolution of this side effect was observed only after Vemurafenib discontinuation.

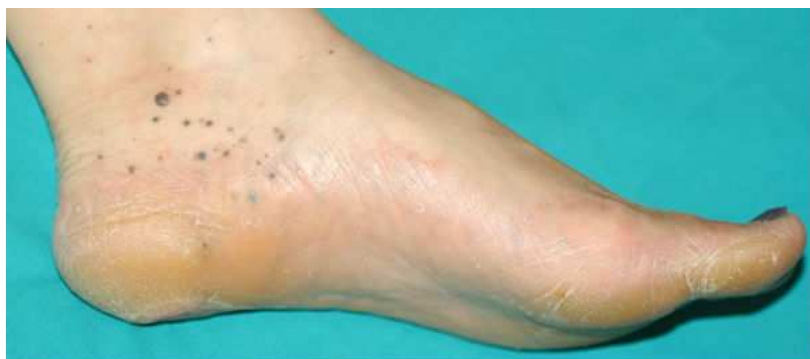

Figure 4. Plantar hyperkeratosis occurred in areas under physical pressure during Vemurafenib treatment

5.4. Photosensitivity

Photosensitivity is another common phenomenon in Vemurafenib-treated patients. Even if this side effect does not represent a life-threatening condition, it can impact on patients' quality of life and could be difficult to manage [14, 17, 29, 30]. Painful sunburns are an early phenomenon and may occur after few minutes of sun exposure; UVA seems to play a more prominent role than UVB. In our experience, sunburns were observed in 14% of patients, also after a few days of treatment (Figure 5). Patient phototype and intensity of sun exposure can concur in the onset of this phenomenon. In our series, all patients who developed sunburns during Vemurafenib treatment showed a photo type II [personal unpublished data].

Sun protection is mandatory in Vemurafenib-treated patients, and should be started together with BRAF inhibitor.

Actinic conjunctivitis is also described as an early as well as a very late side effect.

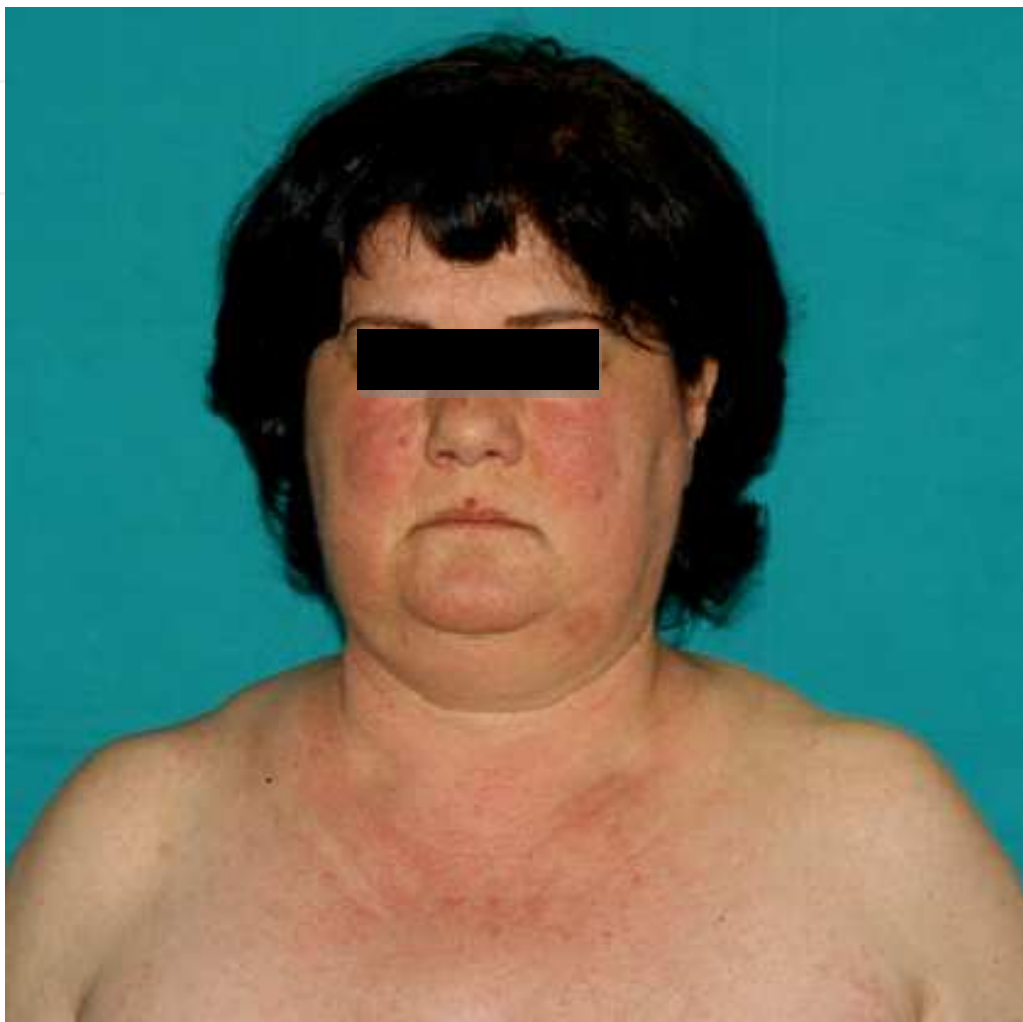

Figure 5. Painful sunburns developed after a few days of Vemurafenib treatment

5.5. Effluvium and hair changes

In our experience, effluvium occurs in 17% of patients, after a median time of 88 days, usually without complete hair loss. Moreover, some patients experience a curling and ticking of the hair. Hair changes belong to the late onset side effects. All these phenomena could be explained by a paradoxical up-regulation of MAPK signaling [35-37].

5.6. Hands oedema and urticaria

A less frequent skin toxicity is represented by localized hand oedema, that developed in a few patients as an early side effect, usually within a month from the beginning of the treatment, in

the absence of other signs of localized or diffuse oedema. In these patients, laboratory tests did not show renal toxicity or hypoalbuminemia. Moreover, cases of urticarial episodes during the Vemurafenib treatment are described, particularly in patients with a personal history of atopia; normally, these episodes spontaneously resolve without drug suspension, and, hence, the relationship between Vemurafenib and urticaria remains to be ascertained [15-17, 29].

5.7. Skin cancer

The first reports of skin toxicity obtained from phase I-III clinical trials and expanded access studies showed the onset of squamous cell carcinomas (SCCs) in up to 31% of Vemurafenib-treated patients [30]. However, a pathology review of all lesions excised in phase II study revealed that 90% of reported SCCs were keratoacanthomas and the remaining 10%, well-differentiated squamous cell carcinomas. More recent reports stated that incidence of SCCs and keratoacanthomas is about 14-18%, respectively [18].

Literature data hypothesize that keratoacanthomas and SCCs develop as a consequence of pre-existing precancerous RAS mutations in keratinocytes of sun-exposed areas that are then activated by Vemurafenib through a paradoxical up-regulation of MAPK signaling [30, 35]. This mechanism could explain the keratinocytes proliferation that leads to keratosis pilaris-like lesions, palmo-plantar hyperkeratosis and hair changes in Vemurafenib-treated patients; notably, the same side effects are also observed during treatment with sorafenib and MEK inhibitors. Along this line, chemoprevention of cutaneous SCCs by the subadministration of systemic retinoids has been reported to be successful in Vemurafenib-treated [28]. In our experience, also topical retinoid can significantly reduce the hyperkeratosis, with lower side effects (unpublished data).

6. Toxicity profiles of emerging BRAF inhibitors

The second-generation BRAFV600 inhibitor Dabrafenib has an acceptable safety profile. The percentage of patients that experience treatment-related side toxicities is lower respect to Vemurafenib and drug-related adverse events of grade ≥ 2 occur in about 5% of patients.

Clinical trials with Dabrafenib and Vemurafenib show several differences in type, grade and frequencies of toxicities [15-18, 38, 39]. Cutaneous toxicities such as rash, hyperkeratosis and the development of non-melanoma skin cancers are less frequent in Dabrafenib-treated patients than in those treated with Vemurafenib. In particular, skin carcinomas occur in 19% of patients treated with Vemurafenib as opposed to 5% during treatment with dabrafenib. Patients included in the phase I and II trials with Dabrafenib do not experienced photosensitivity, which could therefore be considered a Vemurafenib-specific toxicity.

Non-cutaneous toxicities such as arthralgia and fatigue also occur at an increased rate and grade for patients treated with Vemurafenib, whereas pyrexia is a specific toxicity seen with dabrafenib. The mechanisms underlying Dabrafenib-associated pyrexia are poorly understood and require further investigation. However, this condition can be successfully treated

with steroids. No patient included in clinical trials with Dabrafenib experience liver toxicity [38, 39].

The increased incidence of high class toxicities scored with Vemurafenib than with Dabrafenib is likely to be explained by a number of factors, including differences in drug dosage (the administered dose for Dabrafenib is lower than for Vemurafenib), RAF inhibitor potency, histopathologic assessment of cutaneous lesions, classification and reporting of toxicity. Moreover, the differences in phototype and exposure to exogenous risk factors for skin carcinomas of the different geographic populations enrolled in these studies could also play an important role.

7. Conclusions

The efficacy of new drugs for the treatment of metastatic melanoma is accompanied by a new spectrum of toxicities, very different from those caused by conventional chemotherapy, but not less important. Therefore, it is crucial that clinicians develop the necessary skills for the early detection and management of these toxicities, in order to limit the need of interruption or suspension of these treatment and to offer the best chance of disease control.

Author details

Paola Savoia* and Paolo Fava

*Address all correspondence to: paola.savoia@unito.it

Department of Medical Science, University of Turin, Italy

References

- [1] Chapman, P.B., Einhorn, L.H., Meyers, M.L., Saxman, S., Destro, A.N., Panageas, K.S., Begg, C.B., Agarwala, S.S., Schuchter, L.M., Ernstoff, M.S., Houghton, A.N., Kirkwood, J.M. Phase III multicenter randomized trial of the Dartmouth regimen versus dacarbazine in patients with metastatic melanoma. *J. Clin. Oncol.* 1999; 17, 2745–51.
- [2] Tarhini, A.A., Agarwala, S.S. Cutaneous melanoma: available therapy for metastatic disease. *Dermatol. Ther.* 2006; 19: 19–25
- [3] Kirkwood JM, Manola J, Ibrahim J. Eastern cooperative oncology group. A pooled analysis of eastern cooperative oncology group and intergroup trials of adjuvant high-dose interferon for melanoma. *Clin. Cancer Res.* 1999; 10, 1670–7.

- [4] Atkins, M.B., Lotze, M.T., Dutcher, et al. High-dose recombinant interleukin 2 therapy for patients with metastatic melanoma: analysis of 270 patients treated between 1985 and 1993. *J Clin. Oncol* 1999; 17: 2105-16.
- [5] Atkins, M.B., Kunkel, L., Sznol, M., Rosenberg, S.A. High-dose recombinant interleukin-2 therapy in patients with metastatic melanoma: long-term survival update. *Cancer J Sci.Am* 2000; 6 (Suppl. 1), S11-4.
- [6] Hodi FS, O'Day SJ, McDermott DF et al. Improved survival with Ipilimumab in patients with metastatic melanoma. *N Engl J Med* 2010; 363:711-23.
- [7] Liu W, Kelly JW, Trivett M, et al. Distinct clinical and pathological features are associated with the BRAF(T1799A(V600E)) mutation in primary melanoma. *J Invest Dermatol* 2007; 127: 900-5.
- [8] Long GV, Menzies AM, Nagrial AM, et al. Prognostic and clinicopathologic associations of oncogenic BRAF in metastatic melanoma. *J Clin Oncol* 2011; 29: 1239-46.
- [9] Robert C, Thomas L, Bondarenko I et al. Ipilimumab plus dacarbazine for previously untreated metastatic melanoma. *N Engl J Med* 2011; 364:2517-26.
- [10] Viros A, Fridlyand J, Bauer J, et al. Improving melanoma classification by integrating genetic and morphologic features. *PLoS Med* 2008; 5: e120.
- [11] Hoos A, Ibrahim R, Korman A et al. Development of Ipilimumab: contribution to a new paradigm for cancer immunotherapy. *Semin Oncol* 2010;37: 533-46.
- [12] Weber J, Thompson JA, Hamid O et al. A randomized, double-blind, placebo-controlled, phase II study comparing the tolerability and efficacy of Ipilimumab administered with or without prophylactic budesonide in patients with unresectable stage III or IV melanoma. *Clin Cancer Res* 2009;15:5591-8.
- [13] Wolchok JD, Weber JS, Maio M et al. Four-year survival rates for patients with metastatic melanoma who received Ipilimumab in phase 2 trials [abstract P-20]. Presented at: Perspectives in Melanoma XV; September 16-17, 2011; New York, NY.
- [14] Sosman JA, Kim KB, Schuchter L, et al. Survival in BRAF V600-mutant advanced melanoma treated with Vemurafenib. *N Engl J Med* 2012; 366: 707-14.
- [15] Boyd KP, Vincent B, Andea A, et al. Nonmalignant cutaneous findings associated with Vemurafenib use in patients with metastatic melanoma. *J Am Acad Dermatol* 2012; 6:1375-79.
- [16] Boussemart L, Routier E, Mateus C, et al. Prospective study of cutaneous side-effects associated with the BRAF inhibitor Vemurafenib: a study of 42 patients. *Ann Oncol*. 2013; 24:1691-97.
- [17] Sinha R, Edmonds K, Newton-Bishop JA, et al. Cutaneous adverse events associated with Vemurafenib in patients with metastatic melanoma: practical advice on diagno-

sis, prevention and management of the main treatment-related skin toxicities. *Br J Dermatol* 2012; 167:987-94.

- [18] Rinderknecht JD, Goldinger SM, Rozati S, et al. RASopathia skin eruptions during Vemurafenib therapy. *PLoS One*. 2013; 8:e58721
- [19] Della Vittoria Scarpati G, Fusciello C, Perri F et al. 2014 Ipilimumab in the treatment of metastatic melanoma: management of adverse events. *Onco Targets Ther*. 2014 19;7:203-9
- [20] Ibrahim R, Berman D, De Pril V, et al. Ipilimumab safety profile: summary of findings from completed trials in advanced melanoma. *J Clin Oncol*. 2011;29(Suppl):Abstract 8583.
- [21] Ascierto P, Simeone E, Chiarion Sileni V et al. Clinical experience with Ipilimumab 3 mg/kg: real-world efficacy and safety data from an expanded access programme cohort. *Journal of Translational Medicine* 2014; 12:116.
- [22] Lacouture, M, Wolchok J, Yosipovitch G, et al. Ipilimumab in patients with cancer and the management of dermatologic adverse events. *J Am Acad Dermatol* 2014; dx.doi.org/10.1016/j.jaad.2014.02.035.
- [23] Weber J, et al. Management of immune-related adverse events and kinetics of response with Ipilimumab. *J Clin Oncol* 30 (21), 2012: 2691-2697.
- [24] Attia P, Phan GQ, Maker AJ, et al. Autoimmunity correlates with tumor regression in patients with metastatic melanoma treated with anti-cytotoxic T-lymphocyte antigen-4. *J Clin Oncol* 2005; 25:6043-53.
- [25] Minkis K, Garden BC, Wu S, Pulitzer MP, Lacouture ME. The risk of skin rash associated with Ipilimumab in patients with cancer: a systematic review of literature and meta-analysis. *J Am Acad Dermatol* 2013;69:e121-8
- [26] Klein O, Ebert LM, Nicholaou T, et al. Melan-A-specific cytotoxic T cells are associated with tumor regression and autoimmunity following treatment with anti-CTLA-4. *Clin Cancer Res* 2009;15:2507-13.
- [27] Phan GQ, Yang JC, Sherry RM, et al. Cancer regression and autoimmunity induced by cytotoxic T lymphocyte-associated antigen 4 blockade in patients with metastatic melanoma. *Proc Natl Acad Sci U S A* 2003;100:8372-7.
- [28] Choi JN. Dermatologic adverse events to chemotherapeutic agents, Part 2: BRAF inhibitors, MEK inhibitors, and Ipilimumab. *Semin Cutan Med Surg*. 2014; 33:40-8.
- [29] Chapman PB, Hauschild A, Robert C et al. Improved survival with Vemurafenib in melanoma with BRAF V600E mutation. *N Engl J Med* 2011; 364:2507–16.
- [30] Anforth R, Fernandez-Peñas P, Long GV. Cutaneous toxicities of RAF inhibitors. *Lancet Oncol*. 2013;14 :e11-8.

- [31] Lemech C, Arkenau HT. Novel treatments for metastatic cutaneous melanoma and the management of emergent toxicities. *Clin Med Insights Oncol.* 2012;6:53-66
- [32] Tsai KY, Nowroozi S, Kim KB. Drug safety evaluation of Vemurafenib in the treatment of melanoma. *Expert Opin Drug Saf.* 2013;12:767-75.
- [33] Wantz M, Spanoudi-Kitrimi I, Lasek A, Lebas D, Quinchon JF, Modiano P Vemurafenib-induced toxic epidermal necrolysis]. *Ann Dermatol Venereol.* 2014;141:215-8
- [34] Minor DR, Rodvien R, Kashani-Sabet M. Successful desensitization in a case of Stevens-Johnson syndrome due to Vemurafenib. *Melanoma Res.* 2012;22:410-1.
- [35] Hatzivassiliou G, Song K, Yen I, et al. RAF inhibitors prime wildtype RAF to activate the MAPK pathway and enhance growth. *Nature* 2010; 464:431–35.
- [36] Poulikakos PI, Zhang C, Bollag G, et al. RAF inhibitors transactivate RAF dimers and ERK signalling in cells with wild-type BRAF. *Nature* 2010; 464:427–30
- [37] Su F, Viros A, Milagre C, et al. RAS mutations in cutaneous squamous- cell carcinomas in patients treated with BRAF. *N Engl J Med* 2012; 366:207–15
- [38] Long GV, Trefzer U, Davies MA, et al. Dabrafenib in patients with Val600Glu or Val600Lys BRAF-mutant melanoma metastatic to the brain (BREAK-MB): a multicentre, open-label, phase 2 trial. *Lancet Oncol.* 2012; 13:1087-95.
- [39] Ascierto PA, Minor D, Ribas A, et al. Phase II trial (BREAK-2) of the BRAF inhibitor dabrafenib (GSK2118436) in patients with metastatic melanoma. *J Clin Oncol.* 2013; 31: 3205-11.

