

We are IntechOpen, the world's leading publisher of Open Access books Built by scientists, for scientists

6,900

Open access books available

186,000

International authors and editors

200M

Downloads

Our authors are among the

154

Countries delivered to

TOP 1%

most cited scientists

12.2%

Contributors from top 500 universities



WEB OF SCIENCE™

Selection of our books indexed in the Book Citation Index
in Web of Science™ Core Collection (BKCI)

Interested in publishing with us?
Contact book.department@intechopen.com

Numbers displayed above are based on latest data collected.
For more information visit www.intechopen.com



Treatment Approaches for Odontogenic Cysts of the Maxillary Sinus

Hasan Garip, Sertac Aktop, Onur Gonul and
Kamil Göker

Additional information is available at the end of the chapter

<http://dx.doi.org/10.5772/59087>

1. Introduction

Cysts of the maxillary sinus are detected primarily as incidental findings on radiographs. These cysts often appear as rounded, dome-shaped, soft tissue masses, which are usually located on the floor of the maxillary sinus. Ectopic teeth in the maxillary sinus are readily diagnosed radiographically because they are radiopaque. Water's view, panoramic radiography and plain skull radiography are simple and inexpensive methods that can be used in daily practice. The shape and extent of the cysts can vary widely, and the position of ectopic teeth may be found very close to the eye; in such situations, conventional radiographs may not be sufficient for determining their dimensions or relationship with anatomical structures. Thus, computed tomography (CT) should be used, and patient observation should be initiated using a multidisciplinary team that includes specialists from radiology, dentistry, and surgery departments.

Multidisciplinary treatment planning is an important key component in the long-term success and quality of treatment. In some cases, endodontic treatment should be performed by a dentist or endodontist before the operation, and the vitality of the teeth should be observed closely after the operation. Generally, treatment includes enucleation of the cyst and/or surgical excision, including endoscopic observation in some cases. Long-term multidisciplinary postoperative patient observation should be performed, especially in cases with high recurrence. The aim of this section is to shed new light on treatment approaches for cysts localized in the maxillary sinus.

2. Anatomy of the maxilla

The maxillae are the largest bones of the face, after the mandible. Each assists in forming the boundaries of three cavities: the roof of the mouth, the floor and lateral wall of the nose, and the floor of the orbit. They also enter into the formation of the fossae infratemporal and fossae pterygopalatine, and two fissures, the inferior orbital and pterygomaxillary. [1] The body of the maxilla is somewhat pyramidal in shape, and contains a large cavity, the maxillary sinus (antrum of Highmore). [1]

2.1. Blood supply and venous drainage of the maxillary teeth

The arteria (a.) maxillaris arises from the a. carotis externa, which supplies the maxillary teeth. The maxillary arch is supplied by a plexus of three arterial branches: the a. alveolares superiores anteriores, a. alveolares superiores medialis, and a. alveolares superiores posteriores. The a. alveolares superiores posteriores arises from the third division of the a. maxillaris before the a. maxillaris enters the fossa pterygopalatine (Figure 1). It continues on and enters the infratemporal surface of the maxilla to supply the maxillary sinus, the premolars, and the molars (Figure 1).

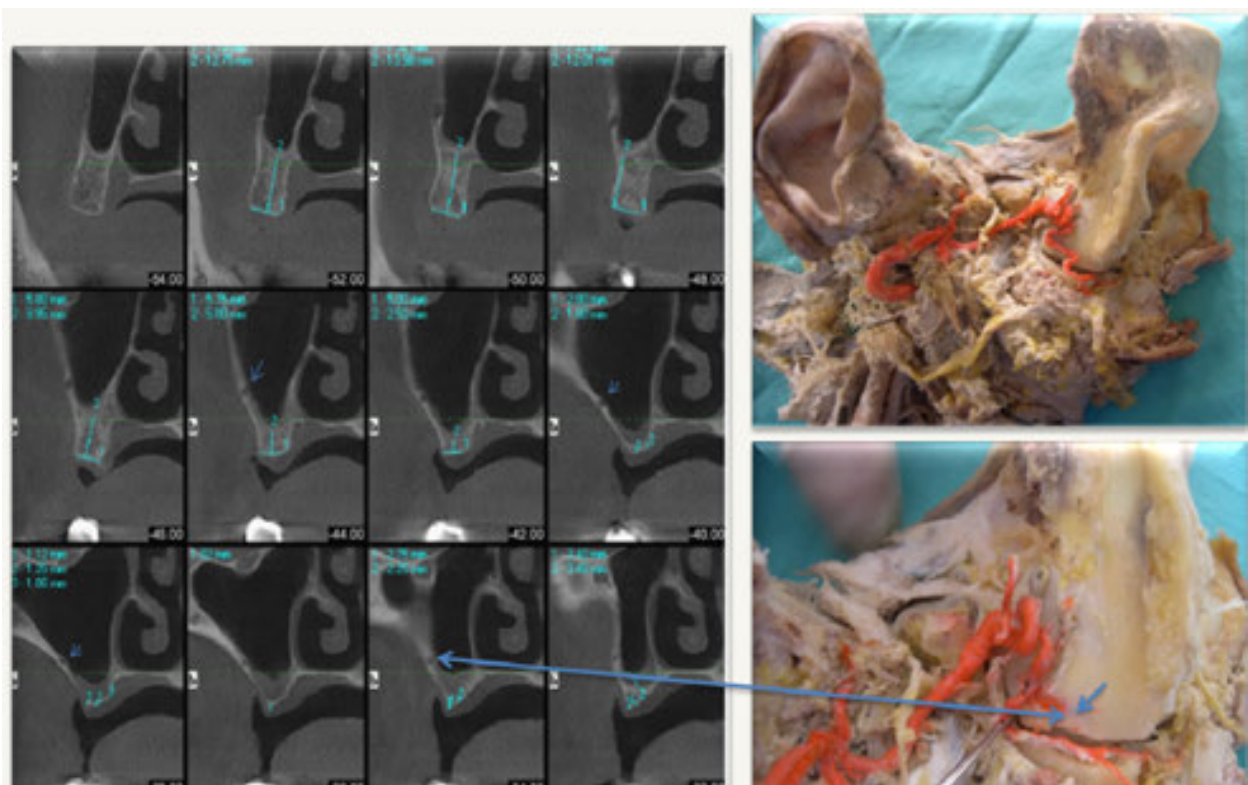


Figure 1. A. maxillaries and a. alveolares superiores posteriores.

During operations performed in this area there may be spontaneous bleeding from these vessels during surgery and sometimes serious bleeding in the postoperative period after local

anesthetics lose activity. This situation may put the patient in a dangerous situation at two time points: immediately after the operation, because of bleeding, and later, after the operation, because of infection of formed clots. Careful CT examinations before the operation and appropriate surgical management will help to avoid all intraoperative and post-operative bleeding complications.

The a. alveolares superiores medialis arises from the a. infraorbitalis as does the a. alveolares superiores anteriores. It arises within the infraorbital canal where it descends to supply the maxillary sinus and plexus at the level of the canine. The a. alveolares superiores anteriores also arises at the level of the middle superior alveolar artery and runs with it to supply the anterior portion of the maxillary arch, maxillary sinus, and anterior teeth.

The venous (v.) drainage of v. alveolares superiores posteriores, v. alveolares superiores medialis, and v. alveolares superiores anteriores drain into the plexus venosus pterygoideus.

[3] Some of the most important points during operations in the maxillary part of the body are first, during the design of the flap, to protect the plexus venosus pterygoideus and lymphatic drainage and, second, to be gentle during the retraction of soft tissues.

2.2. Innervation of the maxilla and of the maxillary teeth

The nervus trigeminus (the fifth cranial nerve) is a mixed nerve (n.) responsible for sensation in the face and certain motor functions, such as biting and chewing. It has three major branches: the n. ophthalmicus, n. maxillaris, and the n. mandibularis. The n. ophthalmicus and n. maxillaris are purely sensory. The n. mandibularis has both sensory and motor functions (Figure 2). [1]

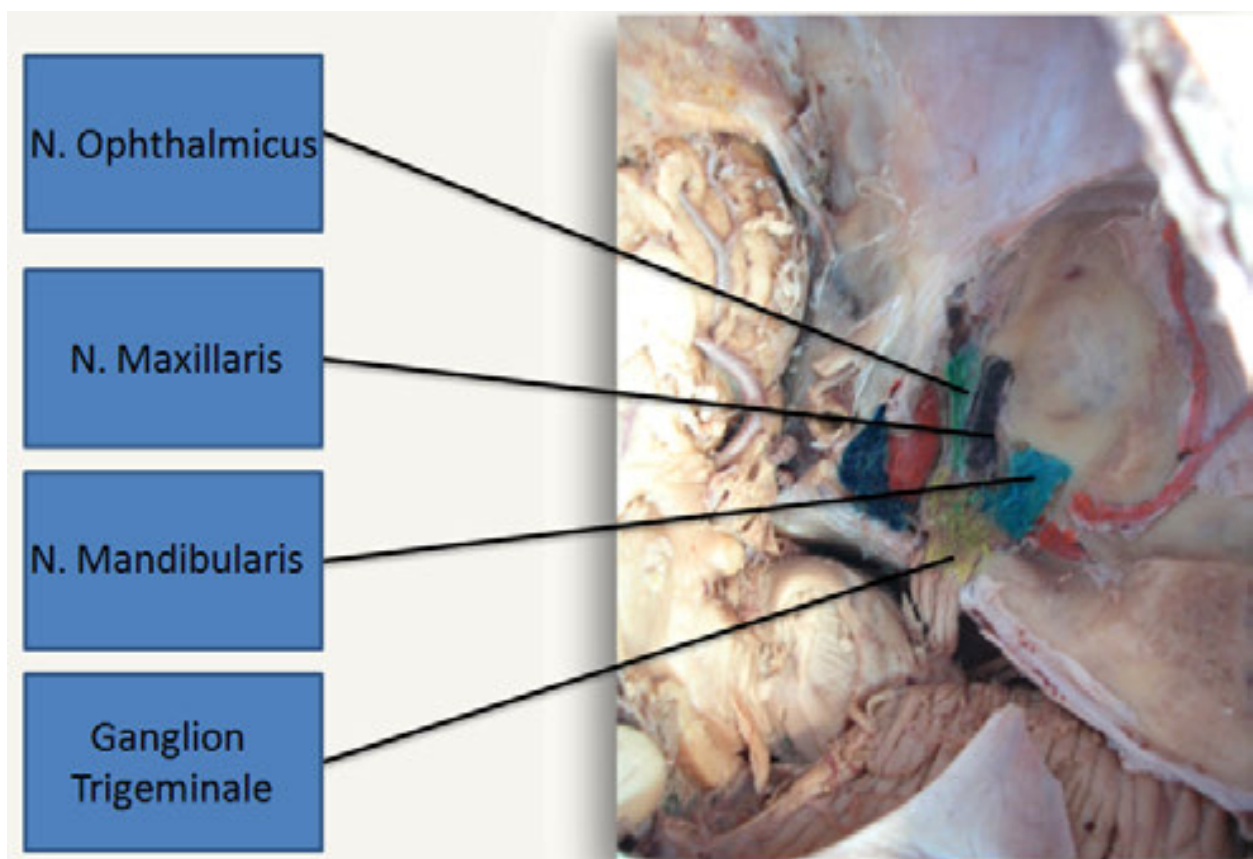


Figure 2. The nervus trigeminus

- The n. ophthalmicus carries sensory information from the scalp and forehead, the upper eyelid, the conjunctiva and cornea of the eye, the nose, the nasal mucosa, the frontal sinuses, and parts of the meninges.
- The n. maxillaris carries sensory information from the lower eyelid and cheek, the nares and upper lip, the upper teeth and gums, the nasal mucosa, the palate and the roof of the pharynx, the maxillary, ethmoid and sphenoid sinuses, and parts of the meninges. It leaves the ganglion trigeminale between the n. ophthalmicus and the n. mandibularis lateral to the sinus cavernosus. The nerve leaves the cranium forward, through the foramen rotundum and enters the fossa pterygopalatina where it divides into three main branches: the n. zygomaticus, n. infraorbitalis, and truncus pterygopalatinus.
- The n. infraorbitalis is a direct extension of the n. maxillaris. It leaves the fossa pterygopalatina and enters the orbit through the fissura orbitalis inferior, together with a. infraorbitalis. The nerve runs forward on the floor of the orbita in one fulcrum, which turns anteriorly to the canalis infraorbitalis. Going forward it leaves the maxilla through the foramen infraorbitale (Figure 3), positioned on the anterior wall of the maxilla under the sutura zygomaticomaxillaris, and gives rise to terminal branches.

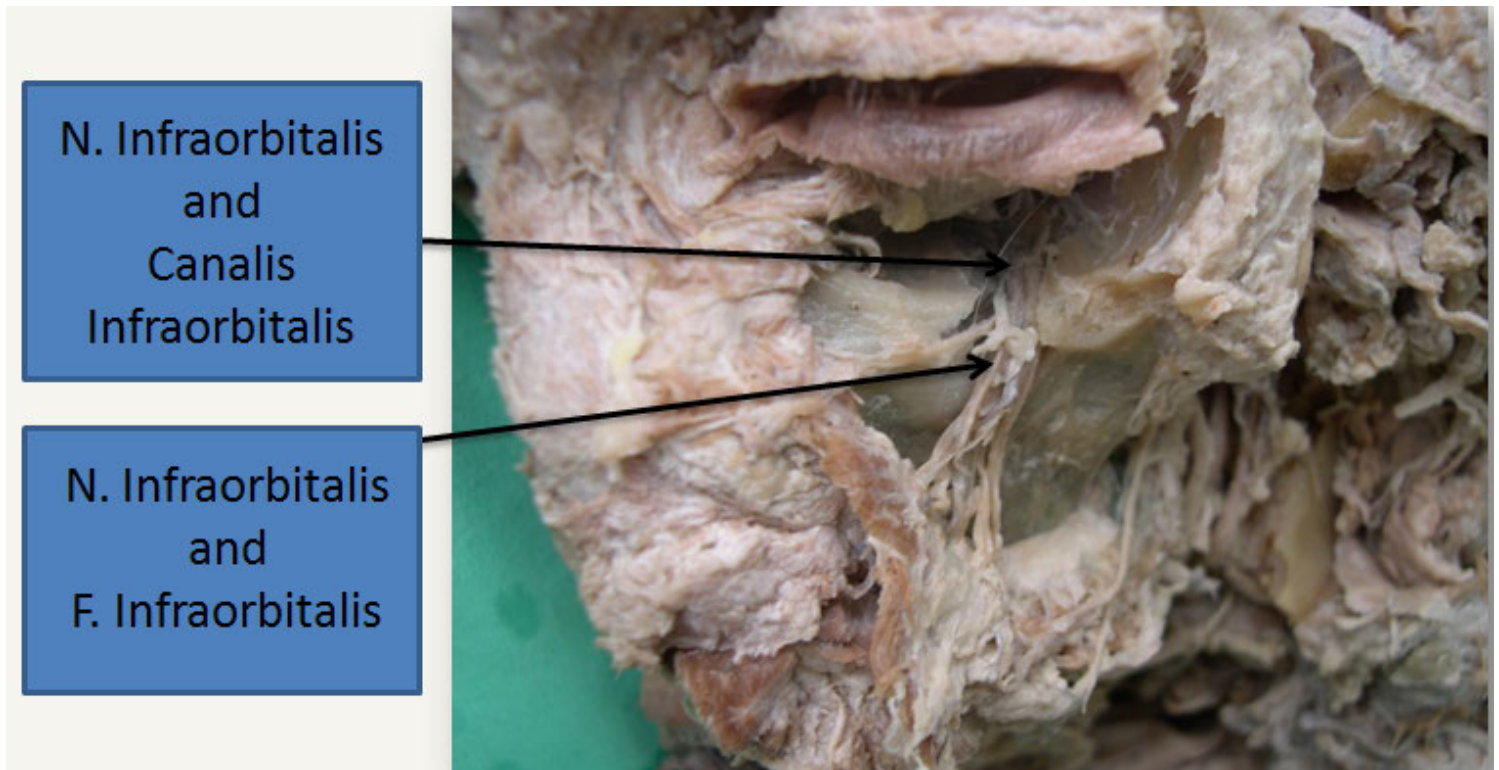


Figure 3. N.infraorbitalis, c. infraorbitalis and f.infraorbitalis

The n. alveolares superiores arises from the n. maxillaris in the fossa pterygopalatina just before n. infraorbitalis enters the orbita or arises from the n. infraorbitalis in the sulcus infraorbitalis. The upper alveolar nerves are divided in three groups: the n. alveolaris superior posterior, the n. alveolaris superior medius, and the n. alveolaris superior anterior. [4] Working 5 mm above the roots of the teeth in the maxilla will avoid damage to the neurovascular plexus. [5] This is one of the most important points during surgical procedures performed in the maxillary sinuses when the teeth are vital (Figure 4). A second important point is to avoid damage to the n. infraorbitalis, which is commonly damaged during elevation and retraction of mucoperiosteal flaps.

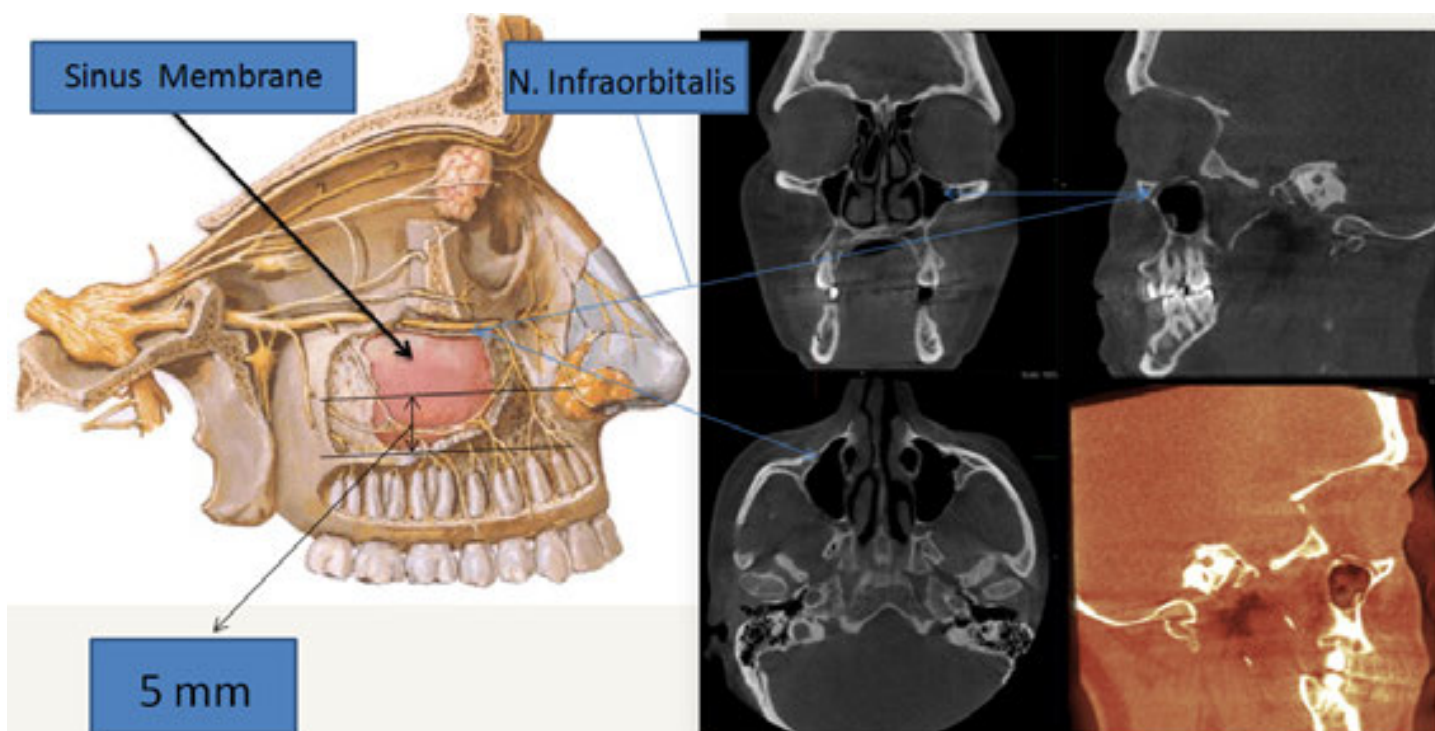


Figure 4. N. infraorbitalis, c. infraorbitalis and f. infraorbitalis (part of figure adapted from Netter).

The n. mandibularis carries sensory information from the lower lip, the lower teeth and gums, the chin and jaw, parts of the external ear, and parts of the meninges. The mandibular nerve carries touch/position and pain/temperature sensation from the mouth. It does not carry the taste sensation; the chorda tympani is responsible for taste. However, one of its branches, the lingual nerve, carries somatic sensation from the tongue.

3. History and anatomy of the maxillary sinus

The maxillary sinus was first discovered and illustrated by Leonardo da Vinci (1452-1519), but the earliest scientific description is attributed to the British surgeon Nathaniel Highmore (1613-1685). [2] The sinus maxillaris is located behind the anterior wall of the os. maxillaris, under the orbital cavities and above the alveolar bone of the teeth. It has the shape of a pyramid, with a volume of ~15 cc, inferosuperior length of 33 mm, a mediolateral length of 23 mm, and anteroposterior length of 34 mm (Figure 5). The deepest point of the maxillary sinus is normally located in the area of the molar roots; the next deepest area is at the premolar roots. Thus, the risk of exposing the maxillary sinus intraoperatively is greatest when molar teeth are extracted (Figure 6). [6-10]

Kiliç et al. [8] evaluated the maxillary sinus regions from 92 patients, using dental cone-beam CT. This study showed that ~10.5% of molar roots were located in the maxillary sinus. Jung

and Cho [9] in their study showed that 28.1% of molar roots were located in the maxillary sinus. Hirata et al. [10] investigated 1337 patients after 2038 molar extractions and found 3.8% maxillary sinus perforations. In addition to the relationship between the roots and the maxillary sinus floor, exposing the maxillary sinus intraoperatively when molar teeth are extracted depends on the shape and distance of the roots from each other, extraction technique, skill and experience. Knowledge of the anatomical shape of the maxillary sinus and the relationship between the sinus floor and tooth apices, careful planning, and good extraction technique will avoid maxillary sinus perforations.

The paranasal sinuses and the majority of the nasal cavity itself are lined with pseudostratified columnar ciliated epithelium (respiratory type). The cilia suspend a mucous blanket, which is secreted by goblet cells in the mucous membrane. [11] The sinus maxillaris has an opening for drainage, the ostium, located on the medial wall into the hiatus semilunaris. The position of the ostium does not help draining of sinus contents when the head is in an upright position. Before operation, this opening should be checked in CT scans for any obstruction. Ordinarily, it has a diameter of 5-7 mm and a length of 1-2 mm.

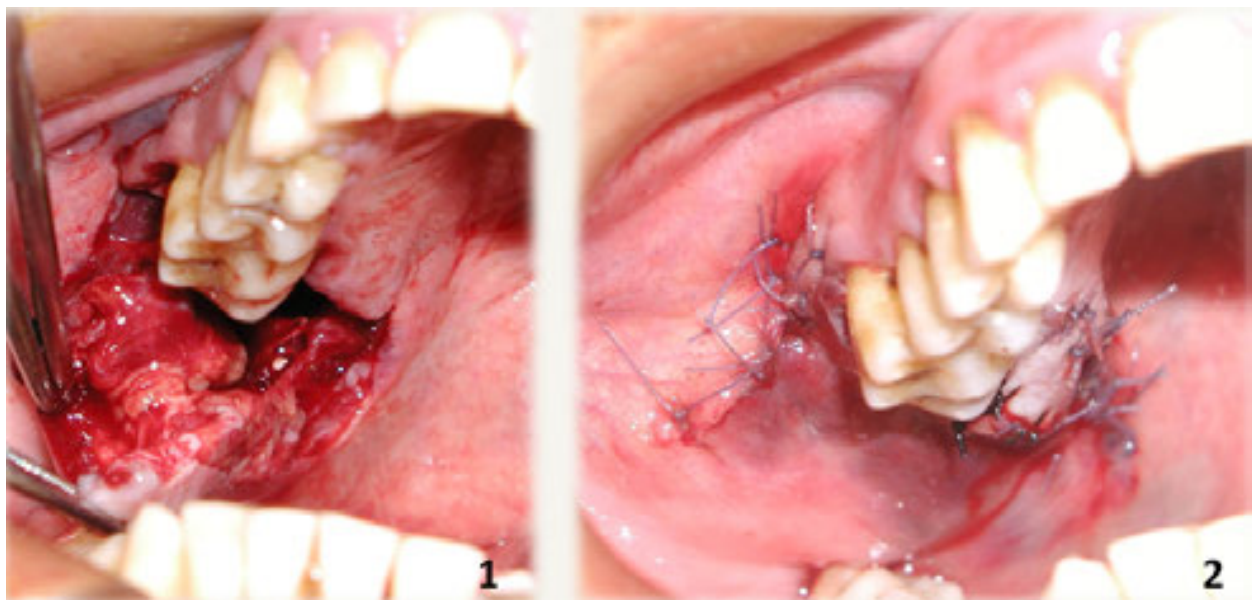


Figure 6. Maxillary sinus exposed after second molar tooth extraction.

Janner et al. [12] reported that the thickness of the Schneiderian membrane showed a wide range, with a minimum value of 0.16 mm and a maximum value of 3.461 mm. The highest mean values, ranging from 2.16 to 3.11 mm, were found for the mucosa located in the mid-sagittal regions of the maxillary sinus. Dagassan-Berndt et al. [13] stated that in the molar regions with periodontal destruction, Schneiderian membrane thickening occurred, particularly in combination with small bone layers above the root tips or periapical lesions.

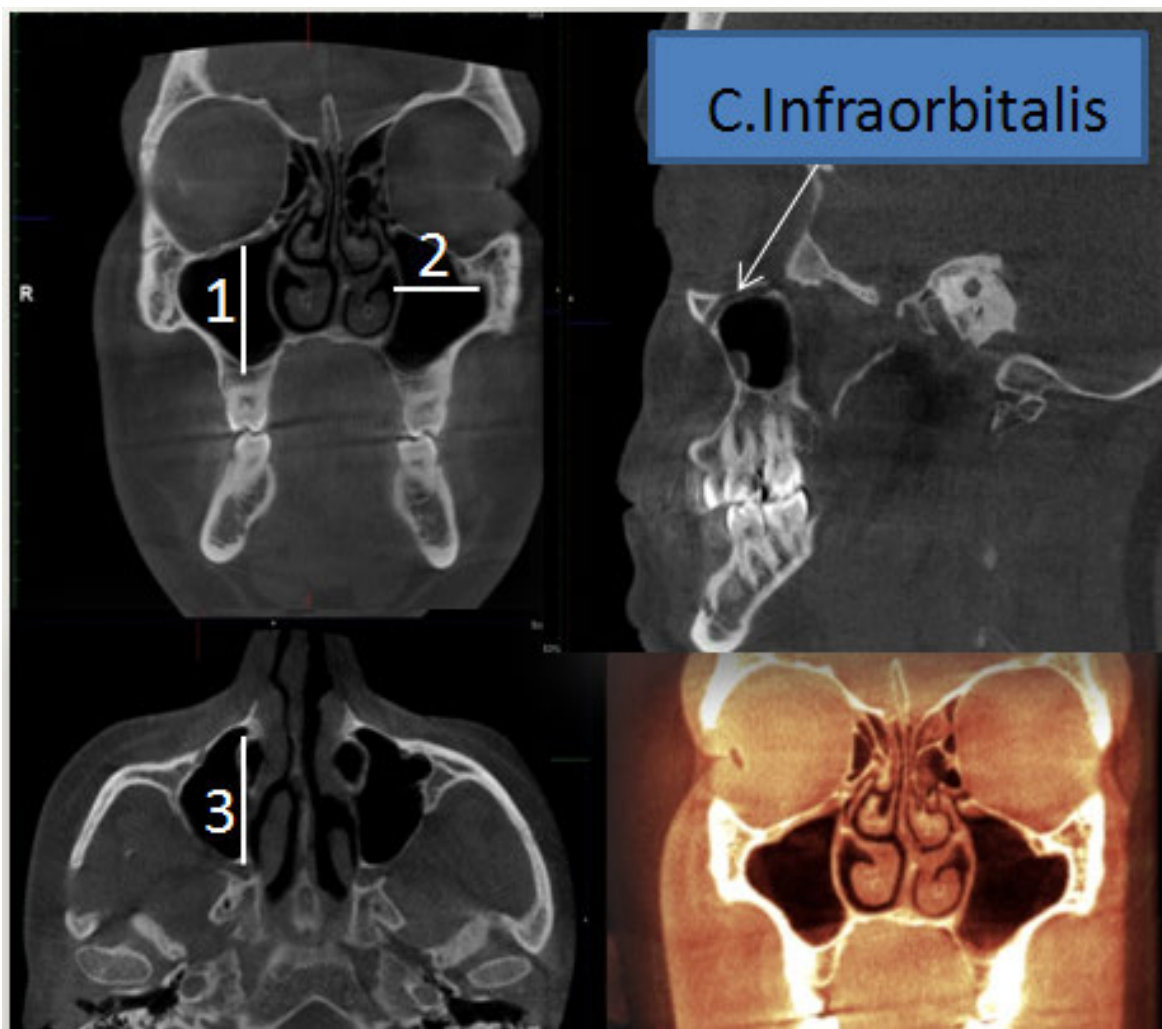


Figure 5. The sinus maxillaries. Volume ~15 cc and pyramidal shape. 1. inferosuperior length 33 mm, 2. Mediolateral length 23 mm, 3. Anteroposterior length 34 mm.

4. Etiology of cysts localized in the maxillary sinus

A cyst is a lesion consisting of an epithelial sac, filled with fluid or semisolid material, and is surrounded by a connective tissue capsule. Cysts are more commonly seen in the maxilla than the mandible. The most common causes of cysts localized in the maxillary sinus are chronic infection, allergic sinonasal disease, trauma, previous surgery, obstruction of the sinus ostium, accumulations of secretions, ectopic teeth, foreign bodies (e.g., dental implant, tooth roots, graft materials), dental infections, incomplete sealing of all communications between the root canal system and periradicular tissues during endodontic treatment, mechanical obstruction of mucociliary flow, defects in ciliary capabilities to propel the mucous blanket and genetic factors. Pathologically, a cyst can develop and grow in the sinus until it reaches a large size with no serious complaint by the patient because of the anatomy of the sinus. [14-16]

5. Cyst treatment options

Marsupialization (Partsch I) procedure is a technique for making a surgical incision in the cyst capsule, minimizing intracystic pressure, and evacuating its contents, then suturing the edges of the cyst to the healthy surface of the oral mucosa to establish a large permanent opening (Figure 7).[17]

Decompression is a technique that relieves the pressure within the cyst by making a small opening in the cyst and keeping it open. This can be achieved with a drain or obturator. Each day the obturator should be removed and the cyst cavity should be irrigated. The cyst size will decrease and any damage to important structures upon enucleation will be diminished (Figures 8, 9). [18]

The decompression and marsupialization of cysts were first suggested by Partsch in the German literature in the late 19th century. [18] Indications for such marsupialization and decompression are large cysts with thin bony walls that may cause spontaneous fracture, cysts that are very close to structures such as the n. alveolaris inferior or nasal floor, and infected cysts. [17, 18, 19]

Enucleation (Partsch II procedure) is a procedure in which all pathological tissue is removed and wound edges are closed (Figure 10). [18]

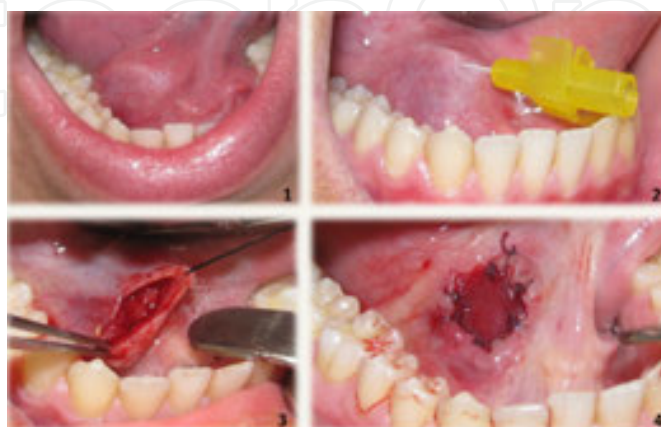

Figure 7. Marsupialization (Partsch I) procedure of a ranula.

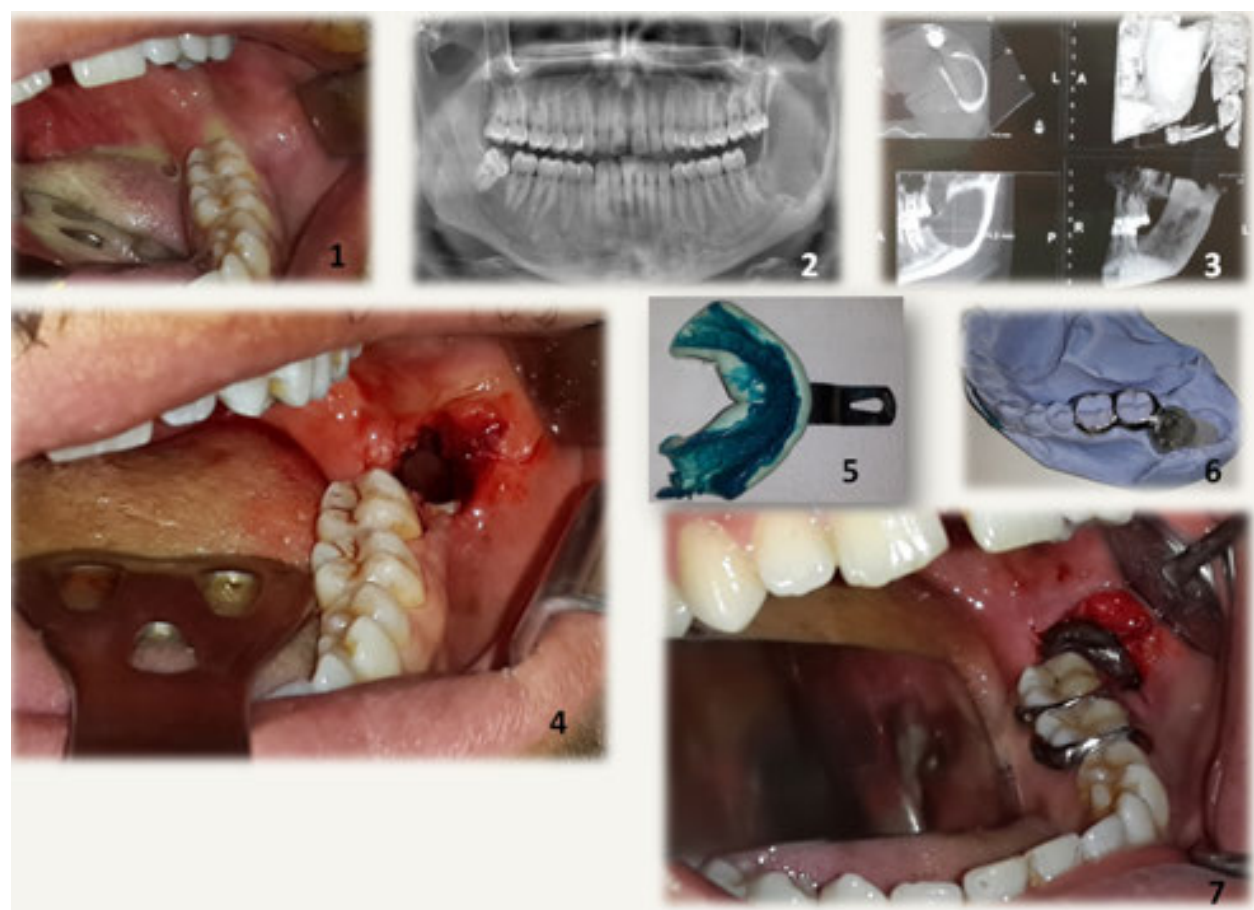


Figure 8. Decompression technique for a dentigerous cyst.

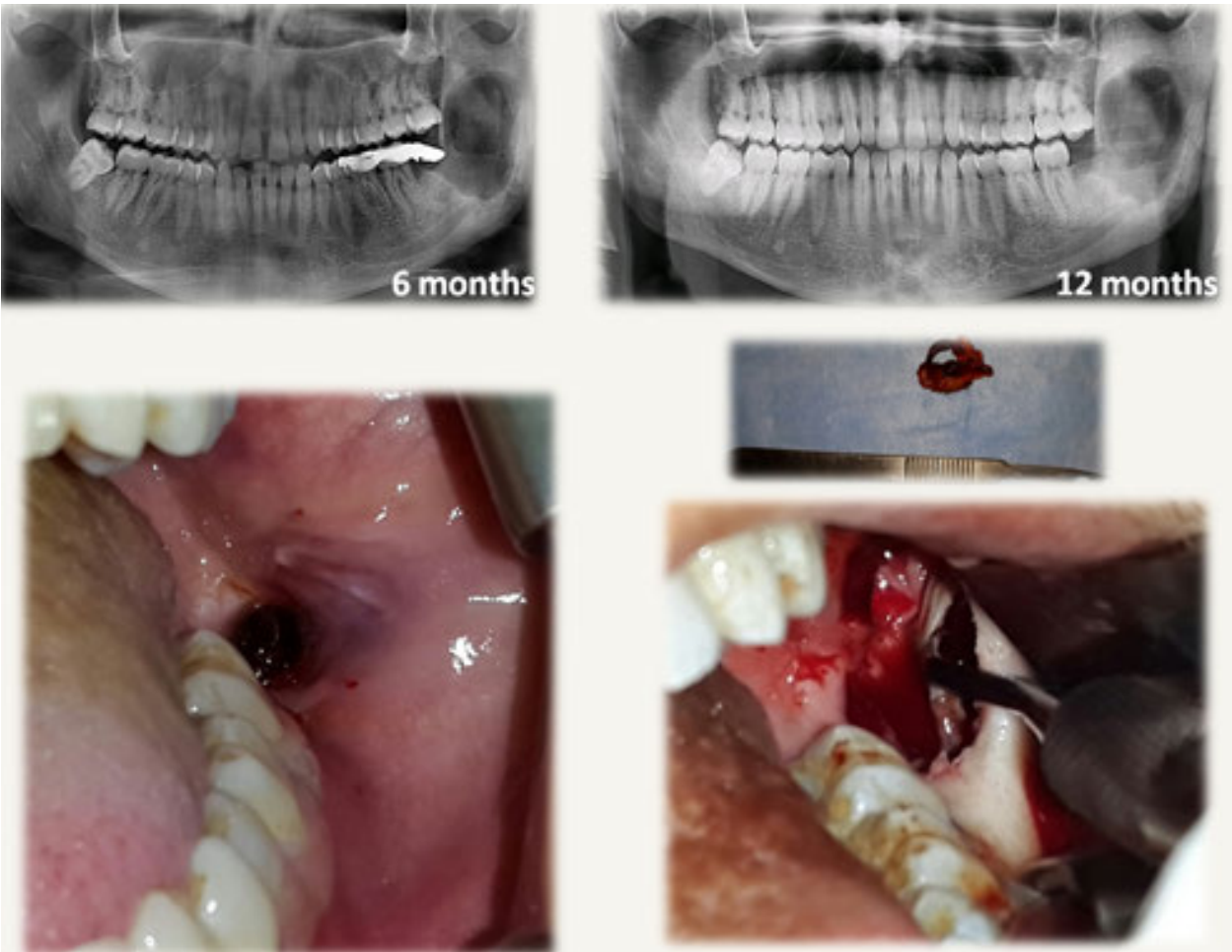


Figure 9. Enucleation after 12 months of decompression.

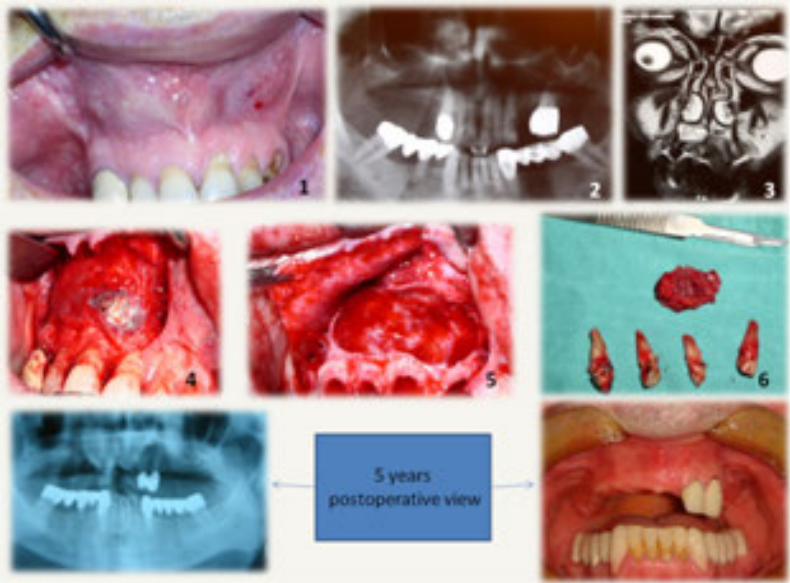


Figure 10. Enucleation (Partsch II procedure) of an odontogenic keratocyst.

6. Cases


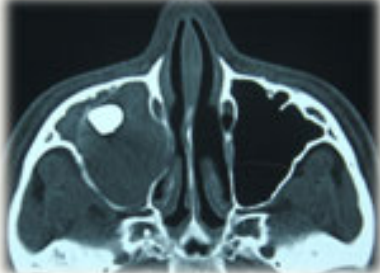
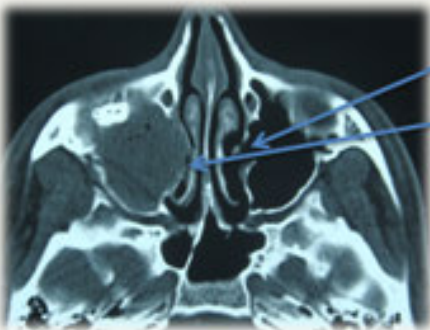

6.1. Case 1

A 19-year-old male was referred to our department of oral and maxillofacial surgery with a 3-week history of swelling on the right side of the face. There was no history of trauma, pain, paresis, paresthesia, or lymphadenopathy. There was slight but obvious facial asymmetry caused by the swelling over the right maxillary region. The mass was firm and non-tender on palpation and not adherent to the overlying skin. Intra-oral examination showed little expansion of the upper right third molar region.

A panoramic radiograph and CT showed a well-defined unilocular radiolucency involving the right maxillary sinus along with the impacted third molar in the top part of the maxillary sinus in conjunction with the orbital floor. A vitality test was performed; all the teeth were vital.

MAKSİLLER SİNÜSTE LOKALİZE OLAN ODONTOJENİK KİSTLERİN TEDAVİ YAKLAŞIMLARI

Doç.Dr.Hasan GARİP

| ANATOMİ | KİST SIVISI VE İÇERİĞİ | TEDAVİ YÖNTEMLERİ | ENDODONTİNİN ÖNEMİ | VAKALAR |
|---|------------------------|-------------------|--------------------|---|
|  | | | |  |
|  | | | |  |

Sinus Ostium

???

Figure 11. Panoramic radiograph and CT views.

In cases like this, careful examination is important. Points that should be checked include possible obstruction of the sinus ostium (Figures 11, 12), the need for an antrostomy procedure, the route of the canalis nasolacrimalis, resorption of the posterior bony wall of the sinus, continuity of the orbital floor, and eye examinations before and after the operation. In such operations where visualization is a problem, an endoscopic-assisted approach is mandatory.

[20] Endoscopic sinus surgery has been performed for various indications in maxillofacial surgical practice. It has been used for the assessment of antral pathologies, removal of foreign bodies, orthognathic procedures, and the treatment of facial fractures. [21, 22] Especially after finishing the removal of a cyst and tooth in operations like this using endoscopy, the surgeon should check any remaining pathology of the cyst, continuity of the orbital floor, to assess the possibility of a blow-out fracture [23], root tips of the teeth and any possible damage, check the aperture of sulcus nasolacrimalis, and perform an antrostomy using endoscopic assistance as needed. [24]

The operation was performed under general anesthesia, combined with local anesthesia. A mucoperiosteal flap was opened in two layers (Figure 13). Through a modified Caldwell-Luc approach, the cyst was exposed (Figure 14). At this stage in the operation, saving teeth vitality is the most important point, so it is important to work at least 5 mm away from the teeth apices. After the pus was removed from the cyst, the tooth was carefully extracted under endoscopic assistance and the remaining part of the cyst was then enucleated (Figure 15, 16). Using endoscopy, the cavity was checked (Figure 17) and packing of the sinus (Figure 18) was performed; this was removed 3 days later. Vitality of the teeth were checked for the last time at 3 months after the operation and all teeth were vital.

MAKSİLLER SİNÜSTE LOKALİZE OLAN ODONTOJENİK KİSTLERİN TEDAVİ YAKLAŞIMLARI

Doç.Dr.Hasan GARİP

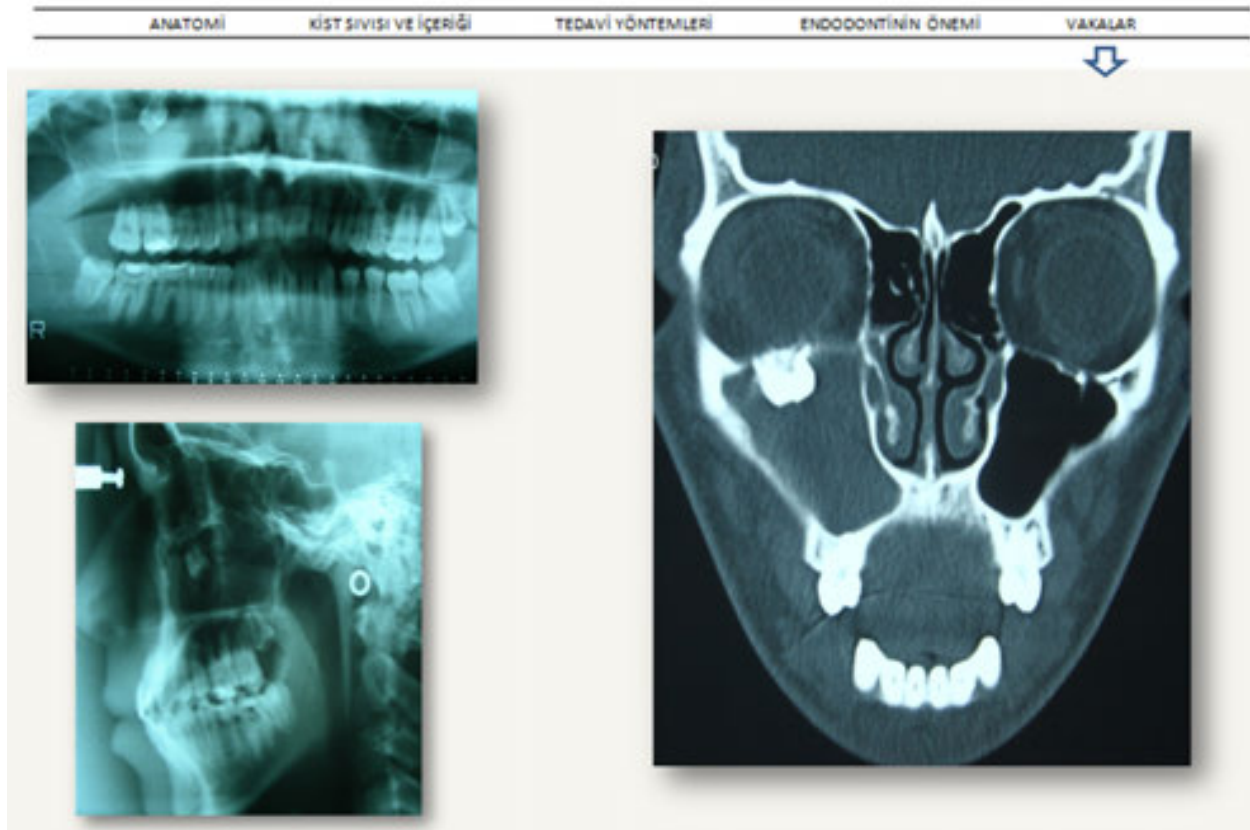


Figure 12. Panoramic radiograph, lateral cephalometric and CT views showing tooth in the right maxillary sinus.

IntechOpen

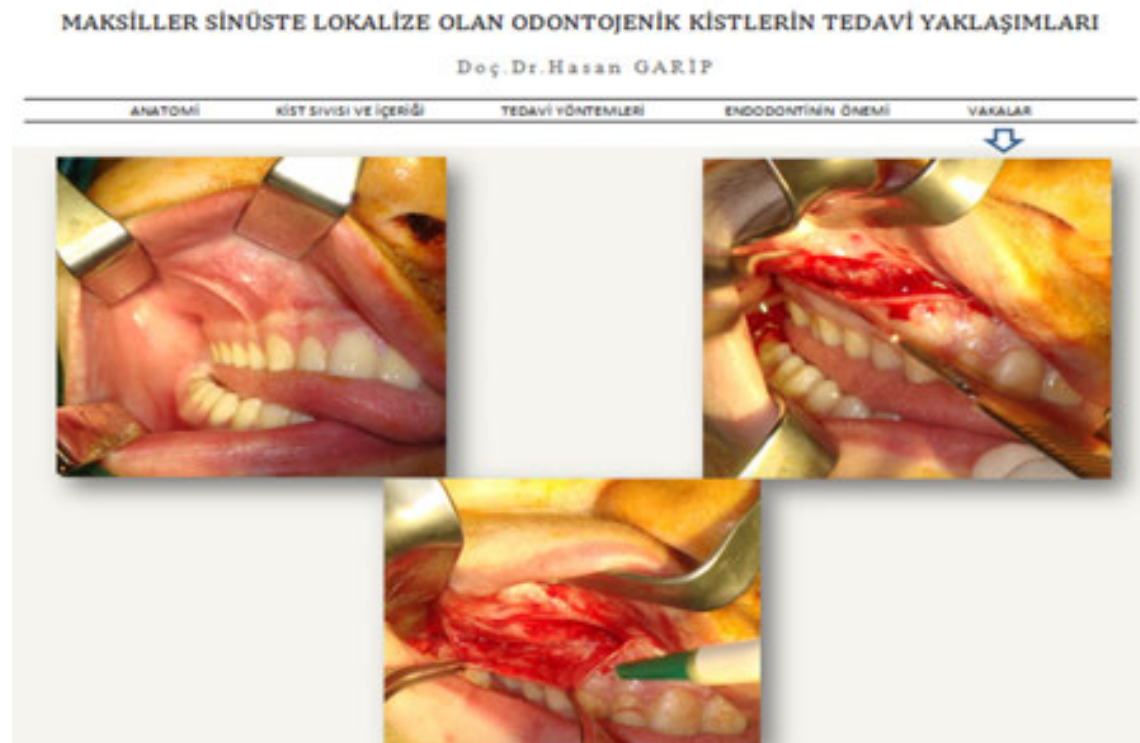

Figure 13. Mucoperiosteal flap preparation.

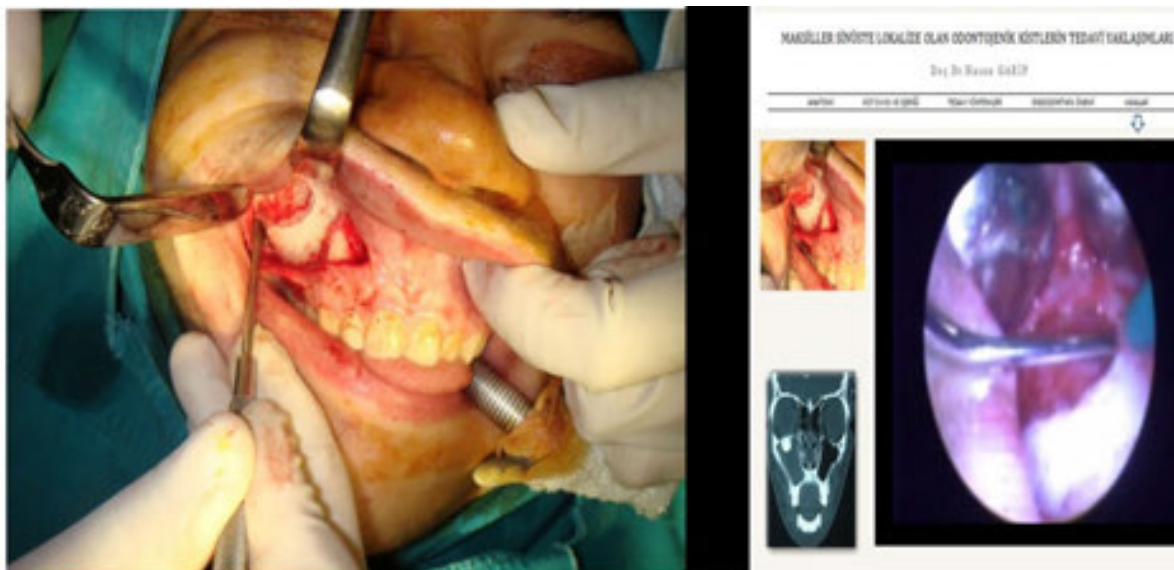

Figure 14. Exposure of the cyst. Endoscopic view (right).

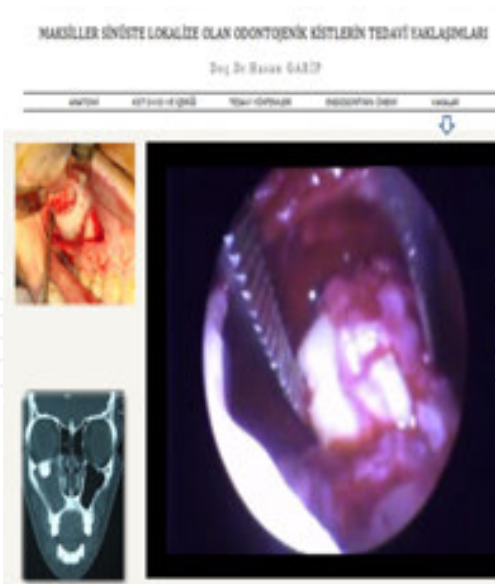

Figure 15. Enucleation of the cyst.

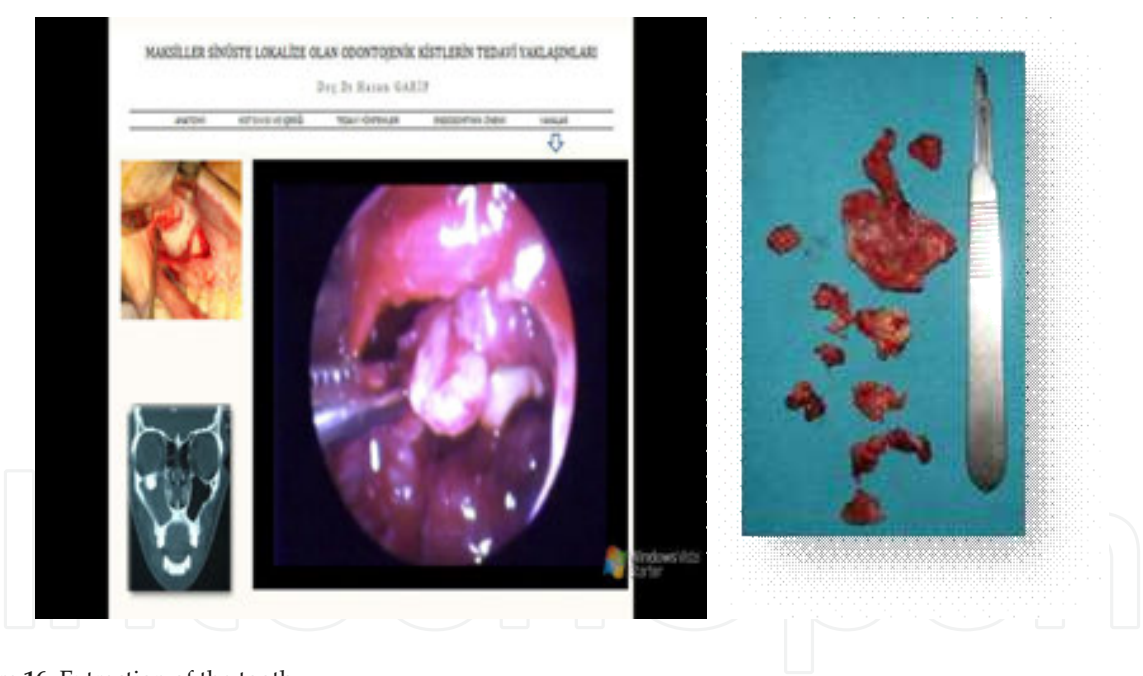


Figure 16. Extraction of the tooth.

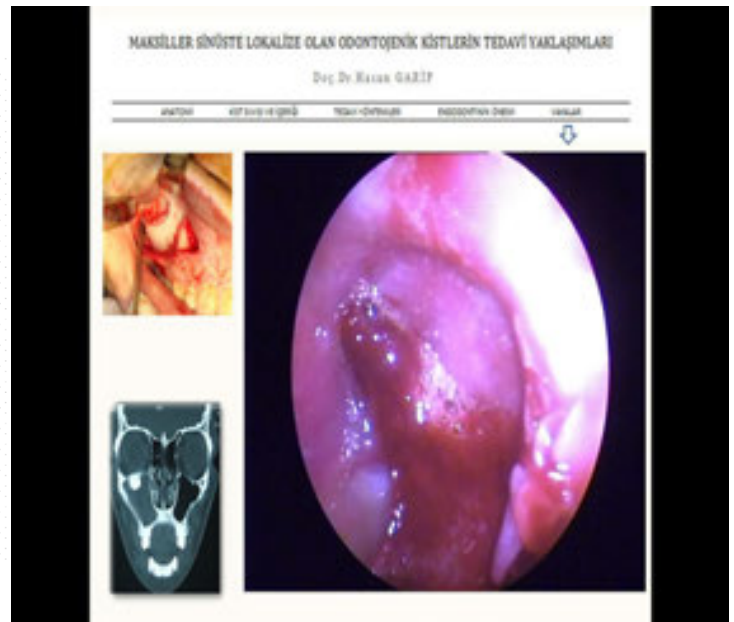
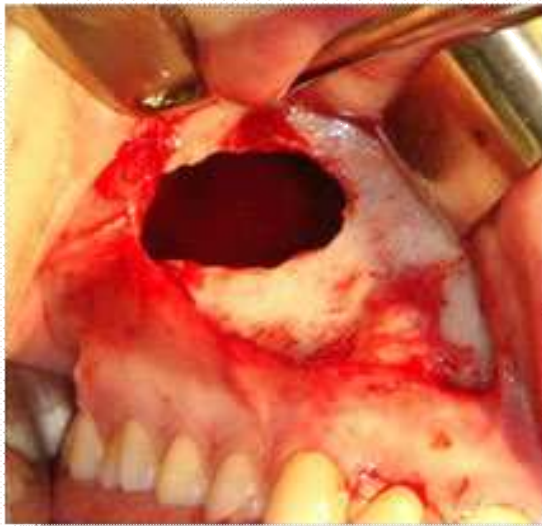
Figure 17. Postoperative cavity checking.

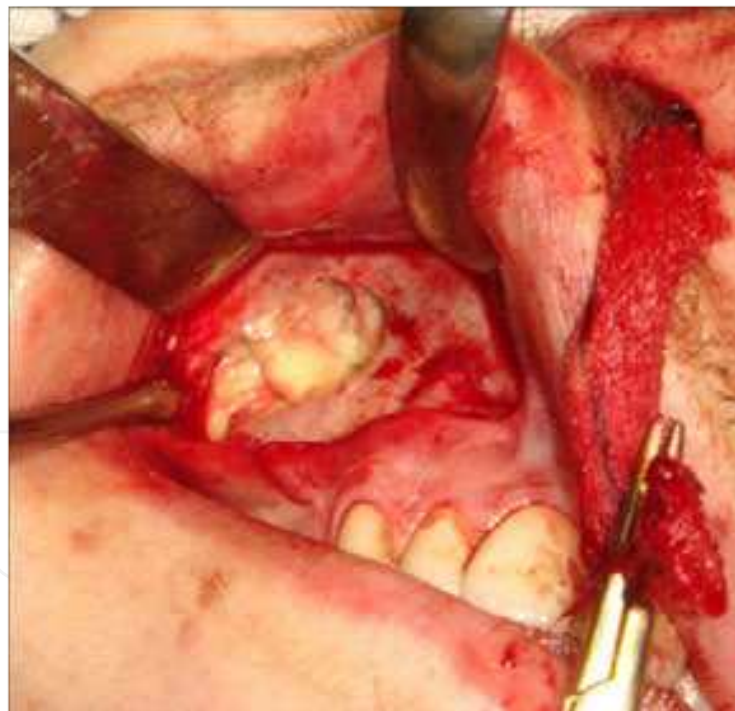

Figure 18. Packing of the sinus after antrostomy.

6.1.1. Intranasal inferior meatal antrostomy technique

An intranasal inferior meatal antrostomy is a process of making an opening in the nasoantral wall of the inferior meatus by an intranasal route. The nasoantral wall of the inferior meatus

is perforated with a curved hemostat and then this opening is enlarged. The opening should be 1.5-2 cm in diameter and as close to the floor of nose as possible (Figure 19). Intrasinus pus/debris should be removed by suction. Packing into the sinus is achieved from the posterior, packing layer-by-layer upwards and forwards (to facilitate removal through the antrostomy) and nose packing may also be required if there is severe bleeding (Figure 20). [25]

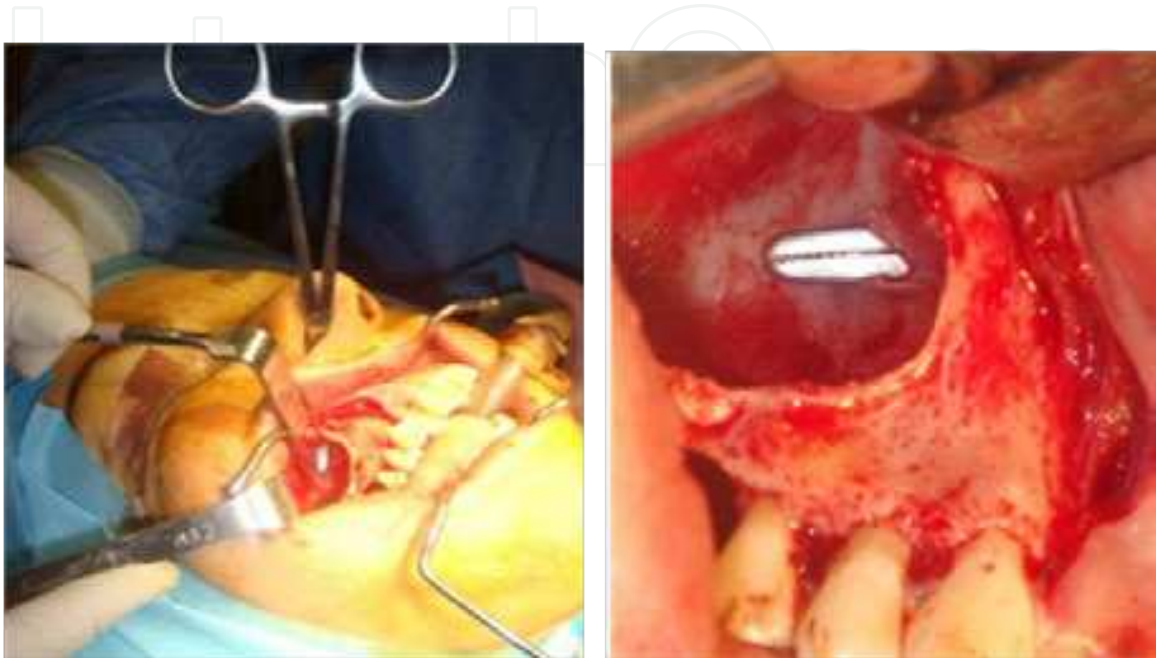

Figure 19. Intranasal inferior meatal antrostomy technique.

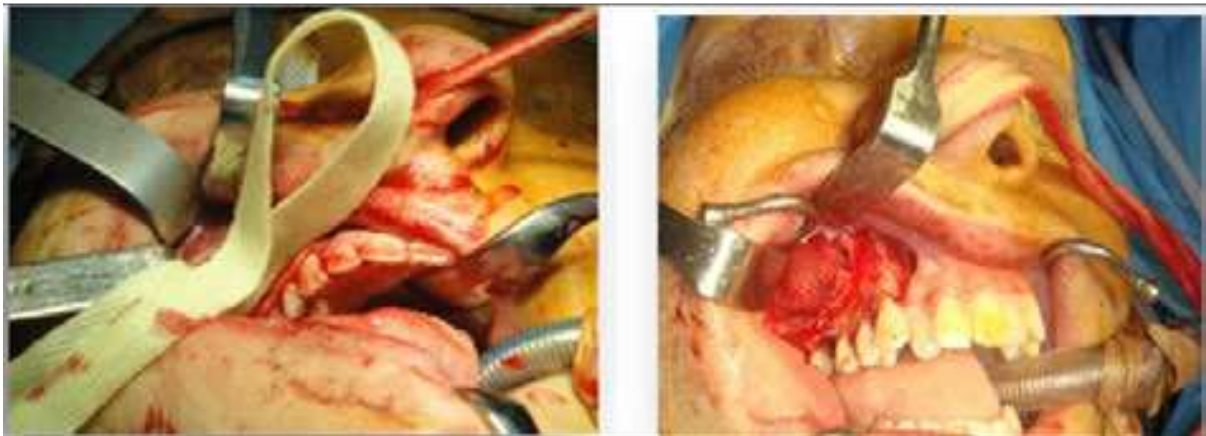


Figure 20. Packing of the sinus maxillaris.

6.2. Case 2

During an incidental radiological exam (orthopantomograph, OPG, Figure 21 at our department of radiology, a 51-year-old male with no complaints and no history of any trauma, pain,

paresis, paresthesia, or lymphadenopathy, was discovered to have an ectopic tooth in the right maxillary antrum. A CT scan (Figure 21) was performed and all important points were checked. An operation was performed under general anesthesia with combined local anesthesia. Using a crestal incision, a trapezoid mucoperiosteal flap was designed and carefully elevated. The tooth was extracted under endoscopic assistance (Figures 22, 23) and a dentigerous cyst was enucleated (Figure 24). Using endoscopy, all cavities were checked and packing of the sinus was performed; this was then removed 3 days later.

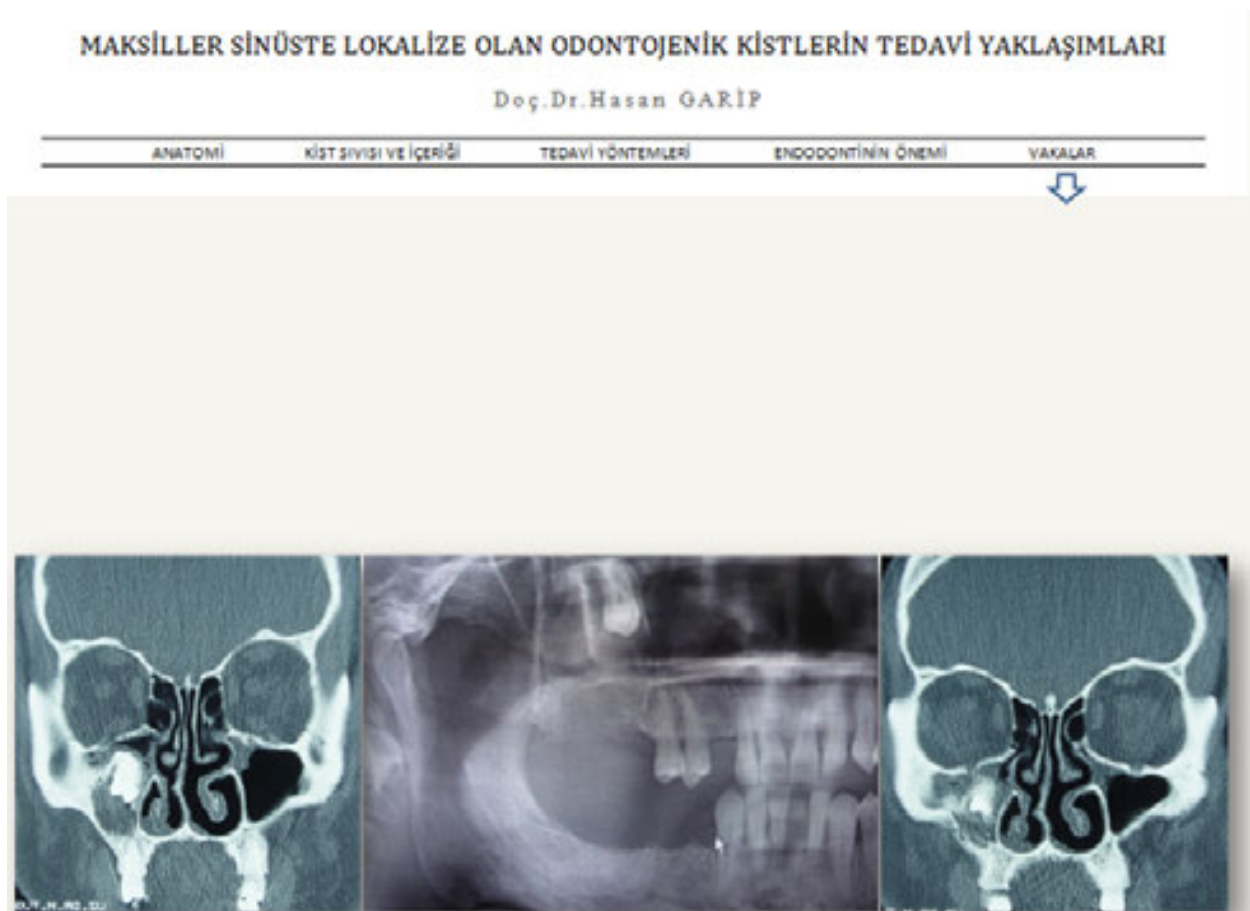

Figure 21. OPG and CT views.

MAKSİLLER SİNÜSTE LOKALİZE OLAN ODONTOJENİK KİSTLERİN TEDAVİ YAKLAŞIMLARI

Doç.Dr.Hasan GARİP

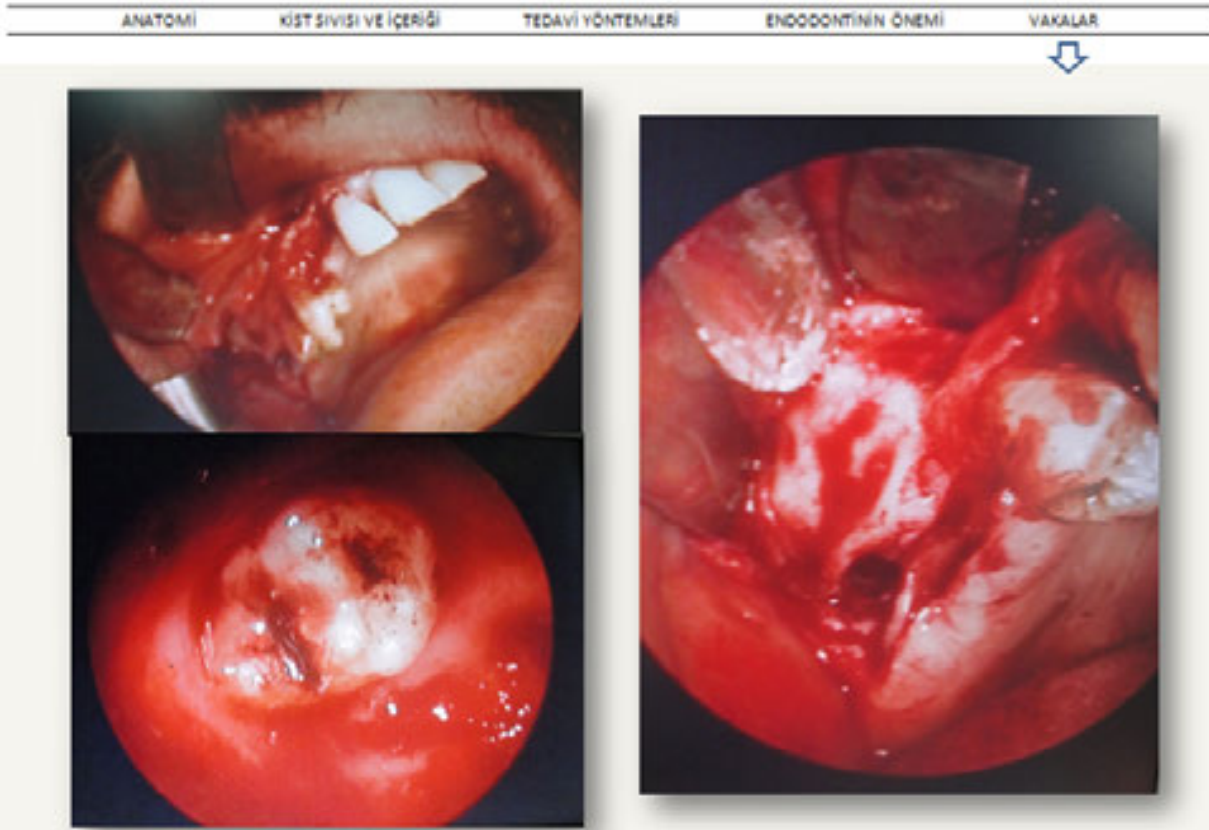


Figure 22. Extraction under endoscopic assistance.

MAKSİLLER SİNÜSTE LOKALİZE OLAN ODONTOJENİK KİSTLERİN TEDAVİ YAKLAŞIMLARI

Doç.Dr.Hasan GARİP

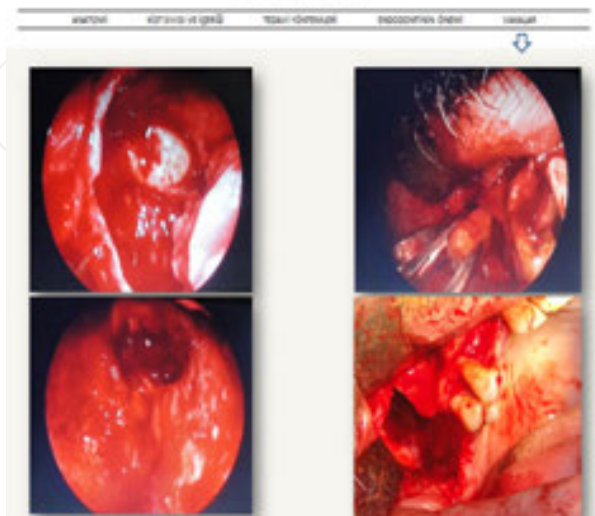


Figure 23. Extraction under endoscopic assistance.

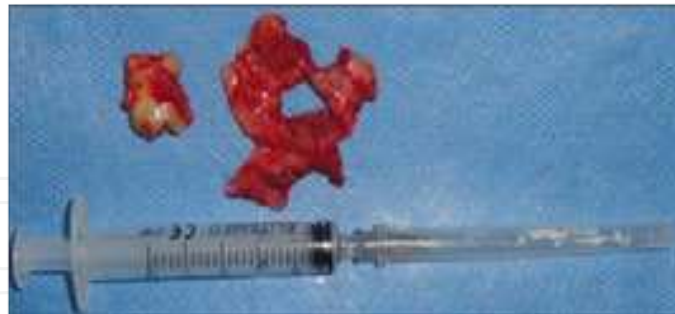

Figure 24. Enucleated dentigerous cyst.

6.3. Case 3

A 23-year-old female was referred to our department of oral and maxillofacial surgery with headache, fatigue, and difficulty in nasal breathing. After a radiological examination (figure 25), it was seen that there was an ectopic third molar in the left sinus and a wisdom lower left third molar in conjunction with a cyst. A CT scan (Figure 26) was performed and all important points were checked and it was seen that the third molar in the maxillary sinus was associated with a cyst that had occupied over two-thirds of the left maxillary sinus.

An operation was performed under general anesthesia with combined local anesthesia. A trapezoid mucoperiosteal flap was designed and carefully elevated (Figure 27). The tooth was extracted (Figure 28) and the cyst was enucleated (Figure 29). An intranasal inferior meatal antrostomy was performed with packing of the sinus (Figure 30); this was removed 3 days later. After the operation, all symptoms of headache, fatigue, and difficulty in nasal breathing resolved. Pathological specimens were sent for examination and the report showed that the cyst was an orthokeratotic odontogenic cyst.

During the operation, using envelope incision, the lower-left-third molar was also extracted and its cyst was enucleated (Figure 31). The pathological report for the lower cyst showed it to be dentigerous. The patient remains under observation (Figure 32).

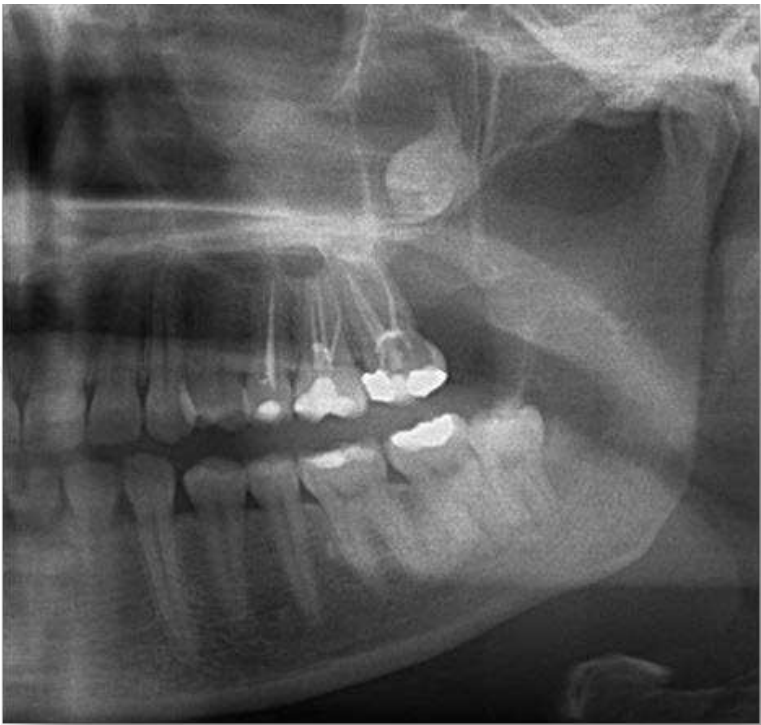

Figure 25. OPG view.

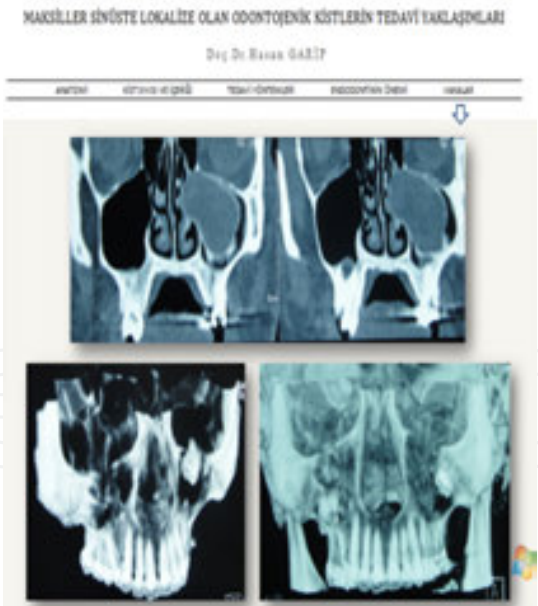


Figure 26. CT views.

MAKSİLLER SİNÜSTE LOKALİZE OLAN ODONTOJENİK KİSTLERİN TEDAVİ YAKLAŞIMLARI

Doç.Dr.Hasan GARİP

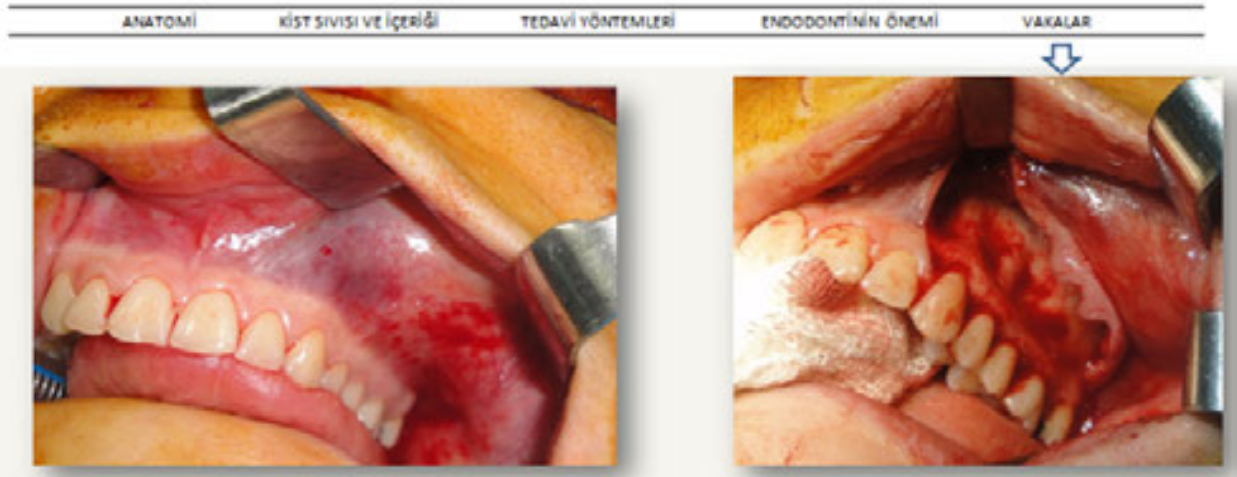


Figure 27. Mucoperiosteal flap preparation.

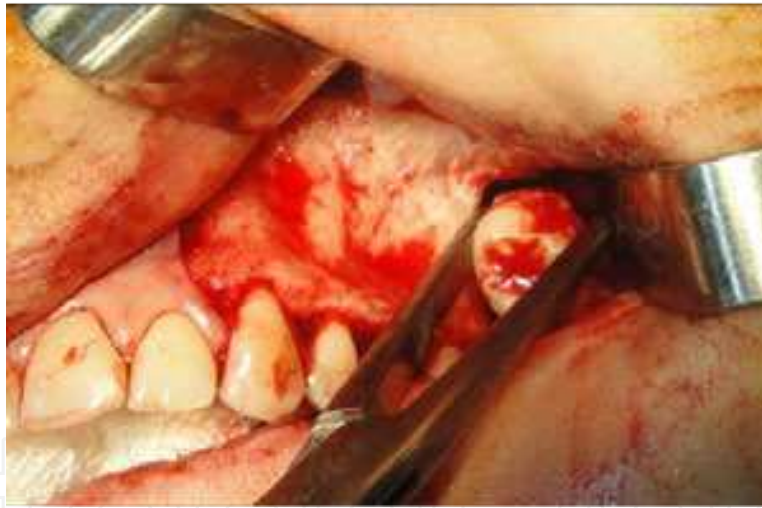

Figure 28. Tooth extraction.

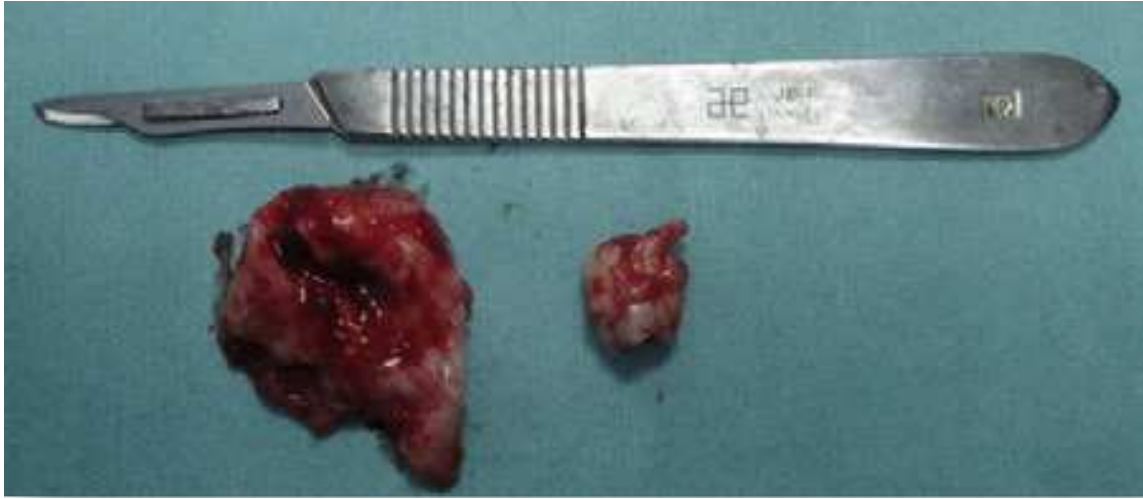


Figure 29. Enucleated cyst and extracted tooth.

MAKSİLLER SİNÜSTE LOKALİZE OLAN ODONTOJENİK KİSTLERİN TEDAVİ YAKLAŞIMLARI

Doç.Dr.Hasan GARİP

ANATOMİ

KİST SIVISI VE İÇERİĞİ

TEDAVİ YÖNTEMLERİ

ENDODONTİNİN ÖNEMİ

VAKALAR

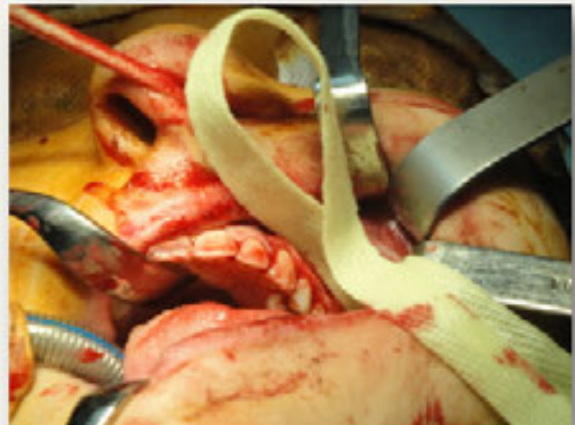
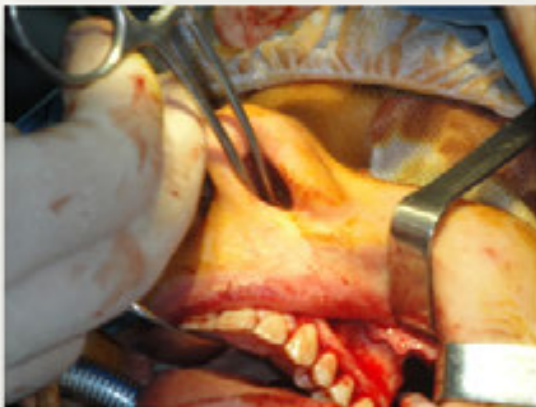
Figure 30. Intranasal inferior meatal antrostomy and packing of the sinus maxillaris.

MAKSİLLER SİNÜSTE LOKALİZE OLAN ODONTOJENİK KİSTLERİN TEDAVİ YAKLAŞIMLARI

Doç.Dr.Hasan GARİP

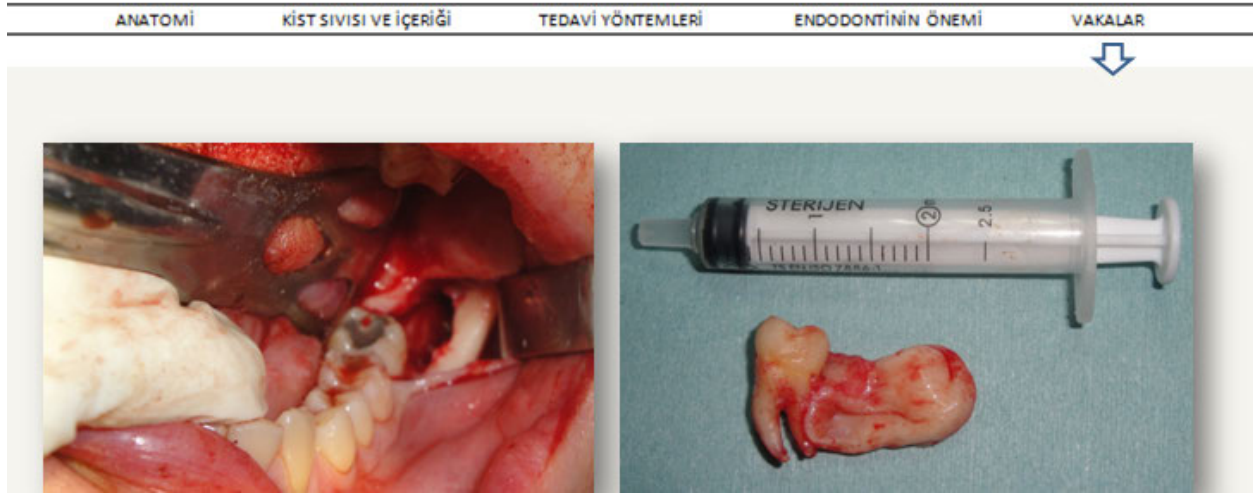


Figure 31. Extracted lower tooth.

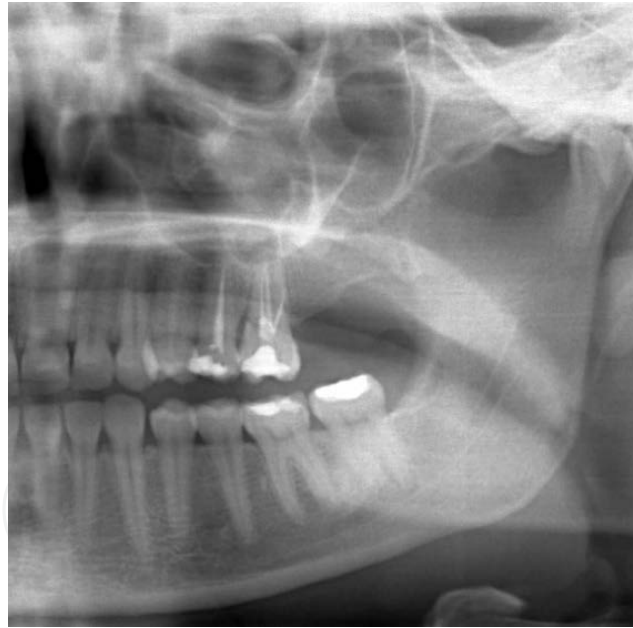

Figure 32. 5 year postoperative OPG.

6.4. Case 4

A 26-year-old female was referred to our department with severe headache, fatigue, difficulty in nasal breathing, halitosis, and a slowly growing facial deformity on the right site of the face. After radiological assessment (OPG and CT) and clinical examination (Figure 33), it was seen

that there was a cyst that almost completely filled the right maxillary sinus and there was slight, but obvious, facial asymmetry caused by the swelling over the right maxillary region. The mass was firm and non-tender on palpation and not adherent to the overlying skin. Intra-oral examination showed expansion of the upper right molar region.

Endodontic treatment was performed for the upper right first and second premolars and for the second molar tooth. It was decided that the first molar roots and third molars would be extracted. All important anatomical points were carefully checked on CT scans.

An operation was performed under general anesthesia, with combined local anesthesia. A trapezoid mucoperiosteal flap was designed and carefully elevated (Figure 34). The teeth were extracted and the cyst was enucleated (Figure 35); and apical resection was performed (Figure 36). An intranasal inferior meatal antrostomy was performed as was packing of the sinus (Figures 37, 38); this was removed 3 days later. Endoscopic assistance was not used because of good visualization. Pathological specimens were sent for examination and report confirmed a radicular cyst (Figure 39).

MAKSİLLER SİNÜSTE LOKALİZE OLAN ODONTOJENİK KİSTLERİN TEDAVİ YAKLAŞIMLARI
 Doç. Dr. Hasan GARİP

| ANATOMİ | KİST SIVISI VE İÇERİĞİ | TEDAVİ YAKLAŞIMLARI | ENDODONTİK ÇEVRE | VAKALAR |
|--|------------------------|---------------------|------------------|---------|
| <p>3. SORU <u>Anamnez</u></p> <p>Yaşı: 27 Cinsiyet: K Sistemik Şikayetler : Yok Kullandığı İlaçlar : Yok Şikayeti : 1. Ağız kokusu 2. Yüzünün Sağ Yarısında Şişliğin Yavaş Artması</p> <p>Teghis:???</p> <p>Tedavi:???</p> | | | | |
|  | | | | |

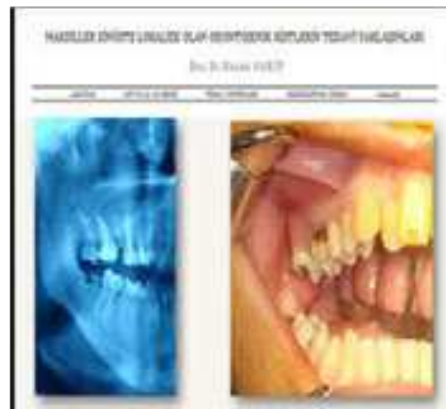

Figure 33. Radiological (OPG and CT) and intraoral clinical views.

MAKSİLLER SİNÜSTE LOKALİZE OLAN ODONTOJENİK KİSTLERİN TEDAVİ YAKLAŞIMLARI

Doç.Dr.Hasan GARİP

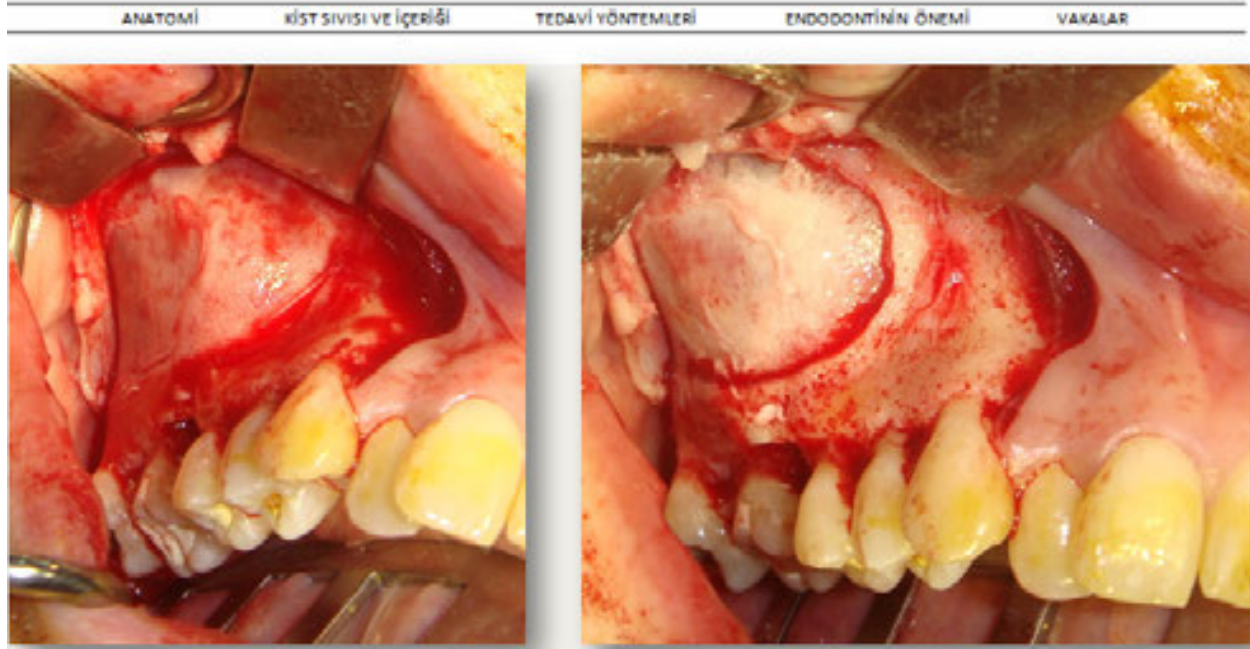


Figure 34. Mucoperiosteal elevation and cyst exposure.

IntechOpen

MAKSİLLER SİNÜSTE LOKALİZE OLAN ODONTOJENİK KİSTLERİN TEDAVİ YAKLAŞIMLARI

Doç.Dr.Hasan GARİP

| ANATOMİ | KİST SIVISI VE İÇERİĞİ | TEDAVİ YÖNTEMLERİ | ENDODONTİNİN ÖNEMİ | VAKALAR |
|---------|------------------------|-------------------|--------------------|---------|
|---------|------------------------|-------------------|--------------------|---------|

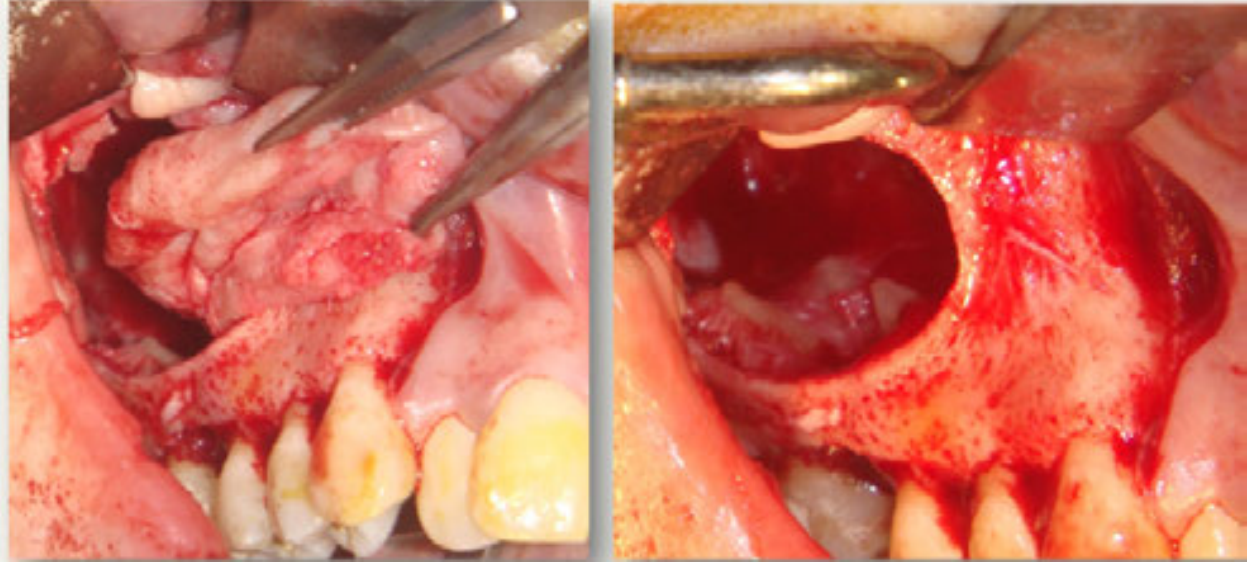


Figure 35. Cyst enucleation.

IntechOpen

MAKSİLLER SİNÜSTE LOKALİZE OLAN ODONTOJENİK KİSTLERİN TEDAVİ YAKLAŞIMLARI

Doç. Dr. Hasan GARİP

ANATOMİ

KİST SIVISI VE İÇERİĞİ

TEDAVİ YÖNTEMLERİ

ENDODONTİNİN ÖNEMİ

VAKALAR

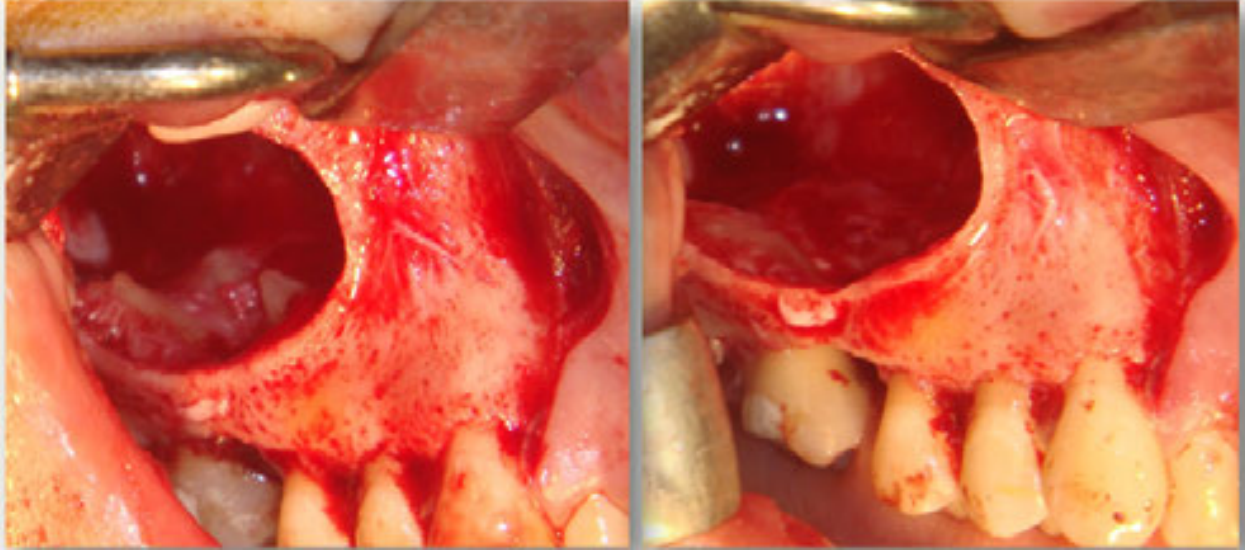


Figure 36. Apical resection.

MAKSİLLER SİNÜSTE LOKALİZE OLAN ODONTOJENİK KİSTLERİN TEDAVİ YAKLAŞIMLARI

Doç. Dr. Hasan GARİP

ANATOMİ

KİST SIVISI VE İÇERİĞİ

TEDAVİ YÖNTEMLERİ

ENDODONTİNİN ÖNEMİ

VAKALAR

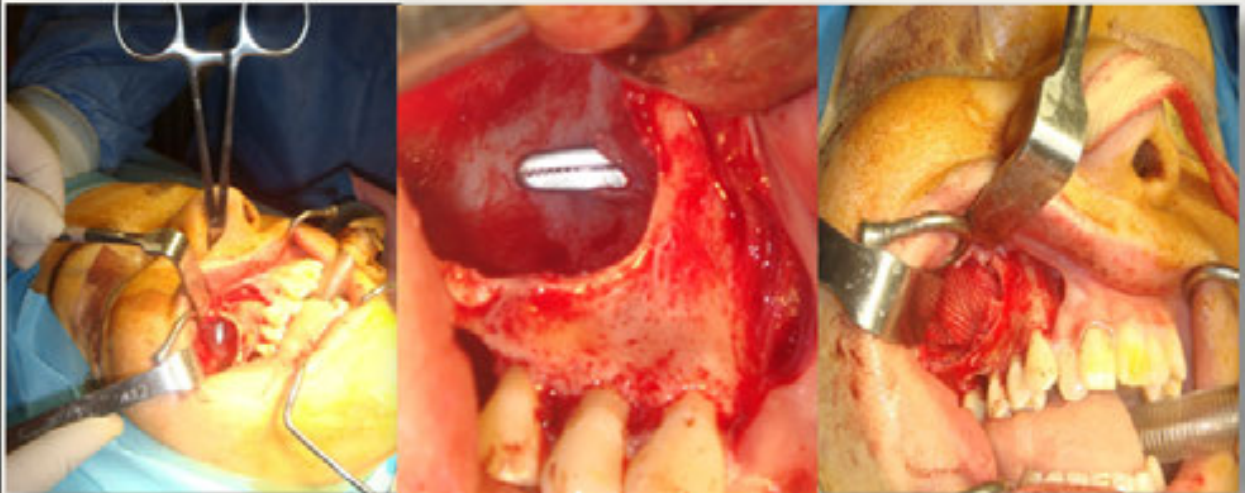

Figure 37. Intranasal inferior meatal antrostomy and packing of the sinus maxillaris.

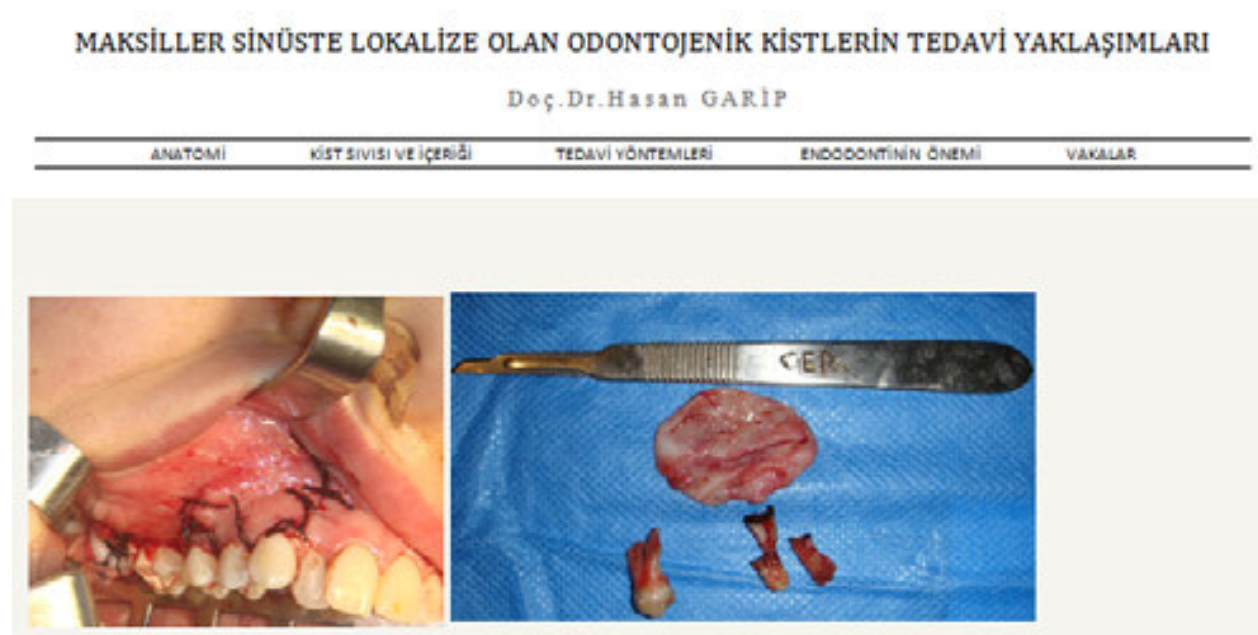

Figure 38. Closed mucoperiosteal flap and enucleated cyst.

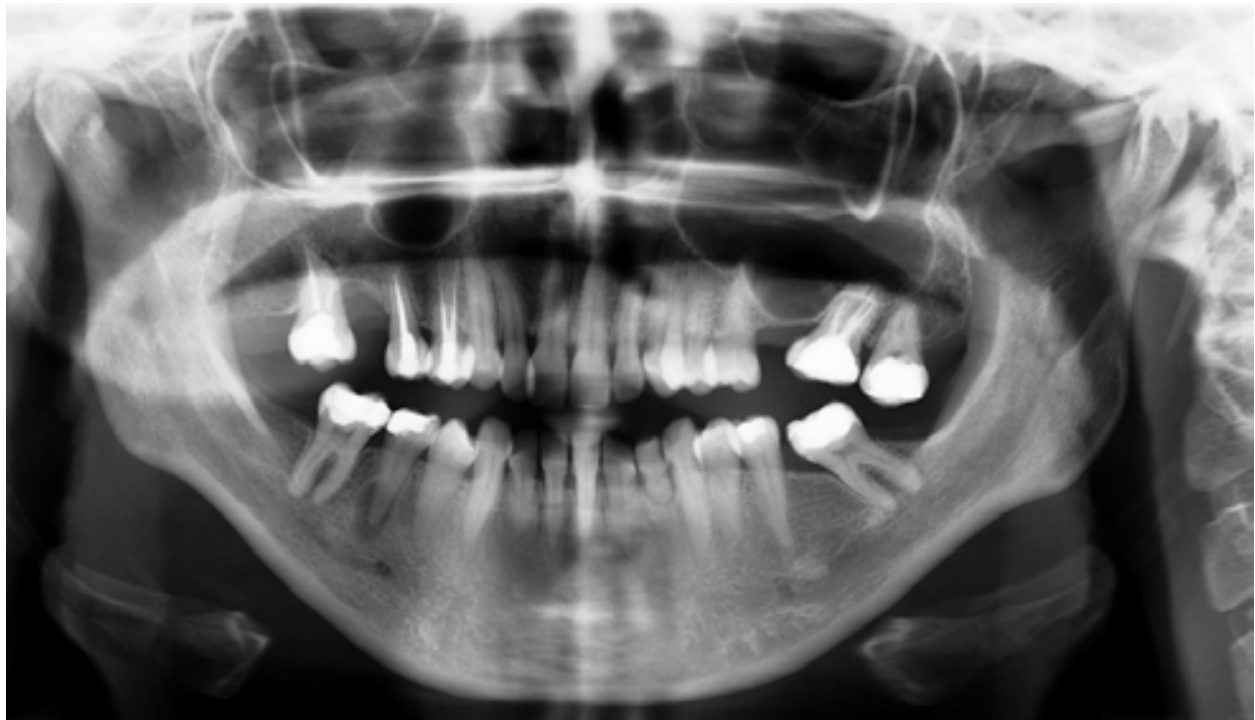


Figure 39. 5 year postoperative OPG

6.5. Case 5

A 33-year-old male was referred to our department with difficulty in nasal breathing, halitosis, and a slowly growing facial deformity on the left side of the face. From radiological (OPG and CT) and clinical examinations (Figure 42), it was seen that there was a cyst, which was related to the left maxillary teeth and nasal floor, uplifting the sinus floor, although it did not obliterate the sinus ostium and the sinus mucosa was not infected. This information was important for the decision as to whether to perform an intranasal inferior meatal antrostomy or not. In this case, because the parameters for maxillary sinus ventilation were ideal, we did not perform an antrostomy. Before the operation all teeth on the left site underwent endodontic treatment (Figure 41).

An operation was performed under general anesthesia combined with local anesthesia. A trapezoid mucoperiosteal flap was designed and carefully elevated (Figure 42). The buccal cortex was decorticated using a round bur without damaging the cyst wall (Figure 43). Intracystic liquid was aspirated with a 20-cc syringe (Figure 44). During aspiration, cholesterol crystals were observed clearly in the cyst fluid. After enucleation of cyst (Figure 45), apical resection plus MTA retrograde filling was performed and the mucoperiosteal flap was sutured. Pathological specimens were sent for examination and the report was a radicular cyst.

Endodontic surgery involves a combination of curettage of infected tissue and removal of an infected or damaged root apex. Among the causes of failure in endodontic surgery, the most frequent is the incomplete sealing of all communications between the root canal system and periradicular tissues. Many studies have shown that bacteria that remain in the root canal system have access to the periradicular tissues after resection [26, 27] The main purpose of the root-end filling material is to provide an apical seal that prevents the movement of bacteria from the root canal system into the periapical tissues. Recently, an experimental substance, MTA, was suggested as a potential root-end filling material. In a series of *in vitro* studies, the sealing ability of MTA was evaluated, compared with commonly used root-end-filling materials. It was shown that MTA had significantly less dye and bacterial leakage. [26, 28, 29] Some studies have shown that when the root canal is confined hermetically and an adequate retrograde cavity depth is prepared, then variation in the root-end cutting angle does not necessarily cause any difference in microleakage. [26]

MAKSİLLER SİNÜSTE LOKALİZE OLAN ODONTOJENİK KİSTLERİN TEDAVİ YAKLAŞIMLARI
Doç. Dr. Hasan GARİP

| ANATOMİ | KİST SİVİSİ VE ÇERÇİSİ | TEDAVİ YAKLAŞIMLARI | ENDODONTİKALİ TEDAVİ | VEZİKÜLER |
|---------|------------------------|---------------------|----------------------|-----------|
|---------|------------------------|---------------------|----------------------|-----------|

2. SORU
Anamnez

Yaşı: 33
Cinsiyet: E
Sistemik Şikayetler:
Kullandığı İlaçlar : Yok
Şikayeti: 1. Ağız kokusu ve ara sıra ağızına irin gelmesi
2. Tek Taraflı Burun Tıkanıklığı
3. Yüzünün Sol Yarisında Şişlik
Teşhis:???
Tedavi:???

MAKSİLLER SİNÜSTE LOKALİZE OLAN ODONTOJENİK KİSTLERİN TEDAVİ YAKLAŞIMLARI
Doç. Dr. Hasan GARİP

| ANATOMİ | KİST SİVİSİ VE ÇERÇİSİ | TEDAVİ YAKLAŞIMLARI | ENDODONTİKALİ TEDAVİ | VEZİKÜLER |
|---------|------------------------|---------------------|----------------------|-----------|
|---------|------------------------|---------------------|----------------------|-----------|

Tedavi

Not: Kanal tedavisi esnasında 24 numaralı diğin eksudası kesilemediğinden dolayı kanal dolgusu ameliyattan hemen önce tamamlanıp, ameliyat esnasında MTA ile retrograd dolgu yapılmıştır.

Figure 40. Radiological (OPG and CT) examination.

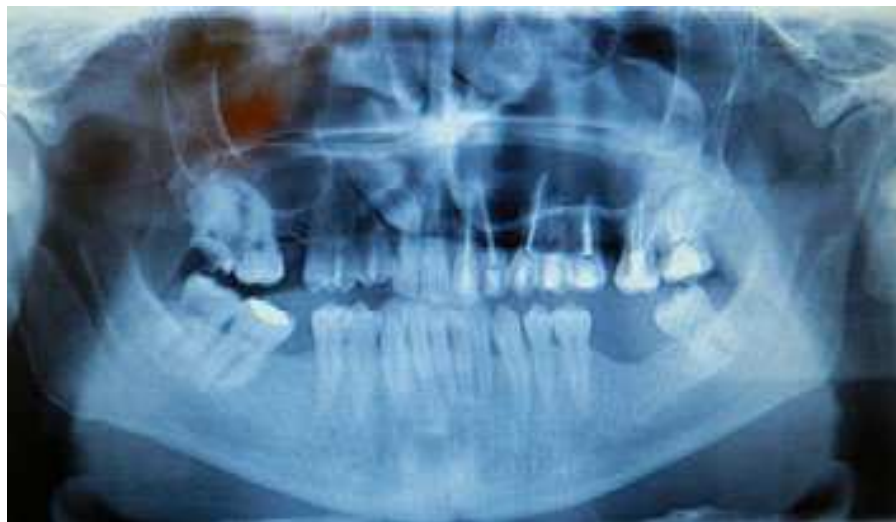

Figure 41. Endodontic treatment of the teeth.

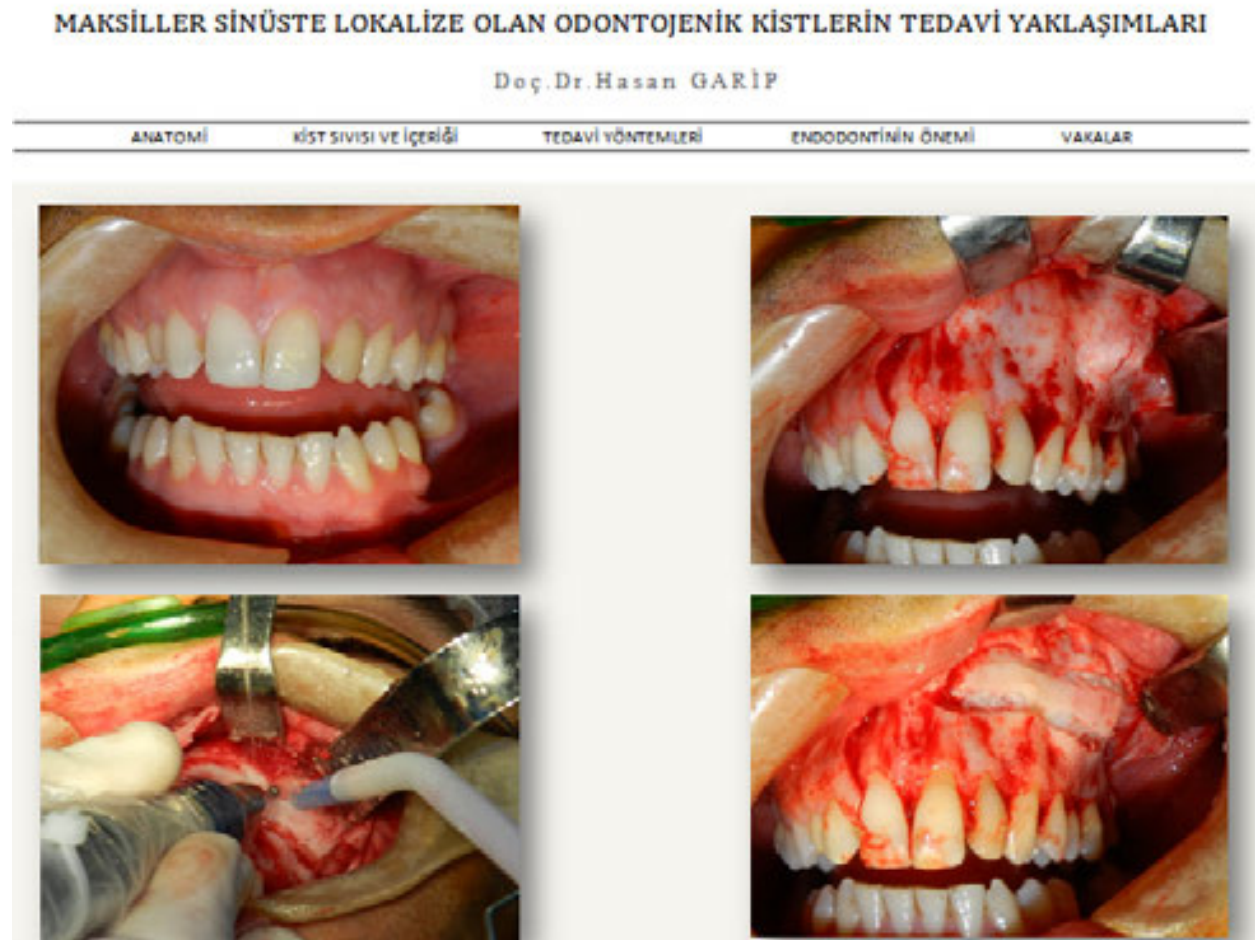

Figure 42. Preparation and elevation of the mucoperiosteal flap.

IntechOpen

MAKSİLLER SİNÜSTE LOKALİZE OLAN ODONTOJENİK KİSTLERİN TEDAVİ YAKLAŞIMLARI

Doç.Dr.Hasan GARİP

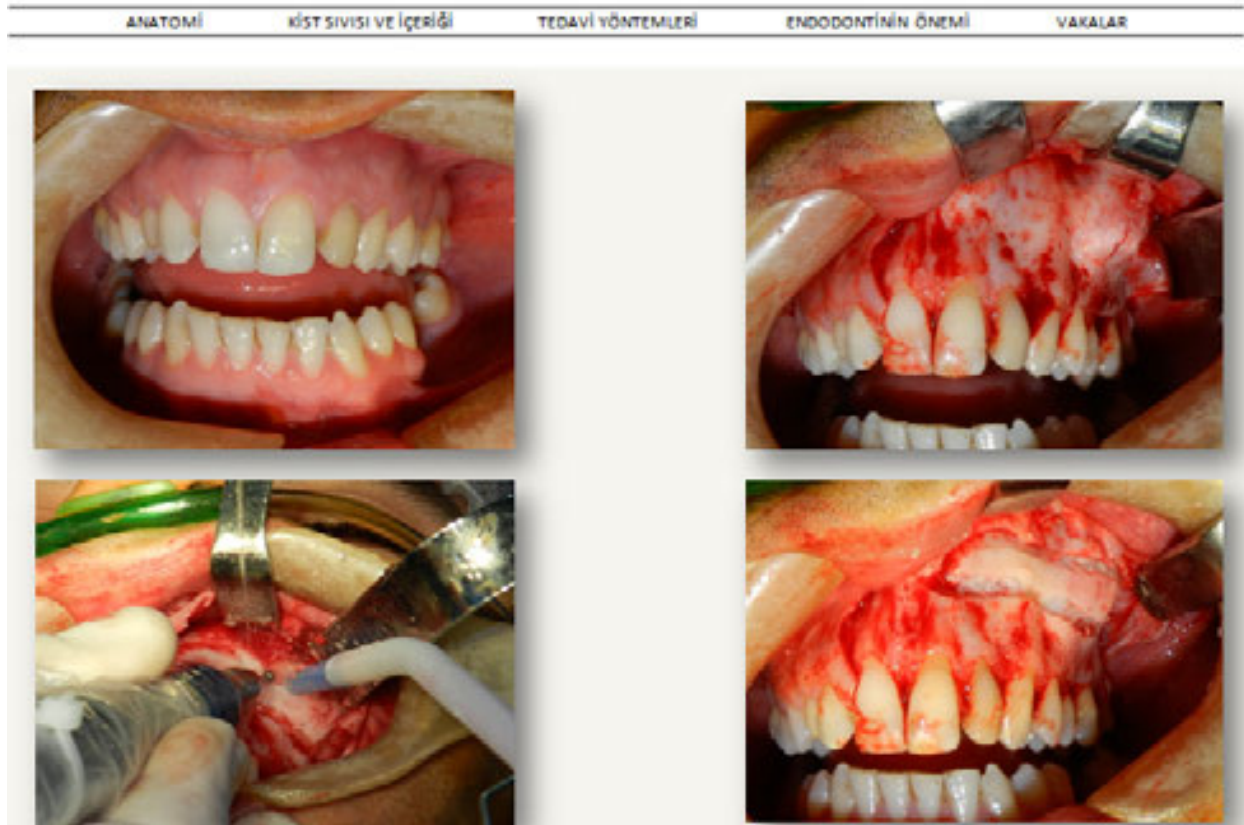


Figure 43. Buccal cortex decortication.

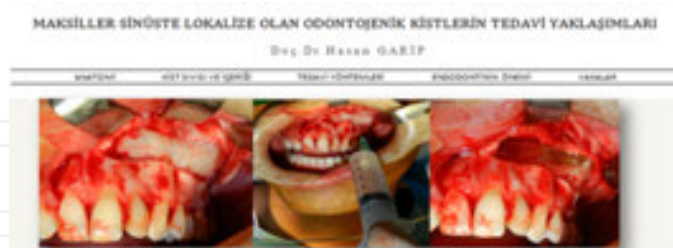

Figure 44. Intracystic liquid aspiration with a 20-cc syringe and view of cholesterol crystals.

MAKSİLLER SİNÜSTE LOKALİZE OLAN ODONTOJENİK KİSTLERİN TEDAVİ YAKLAŞIMLARI

Doç.Dr.Hasan GARİP

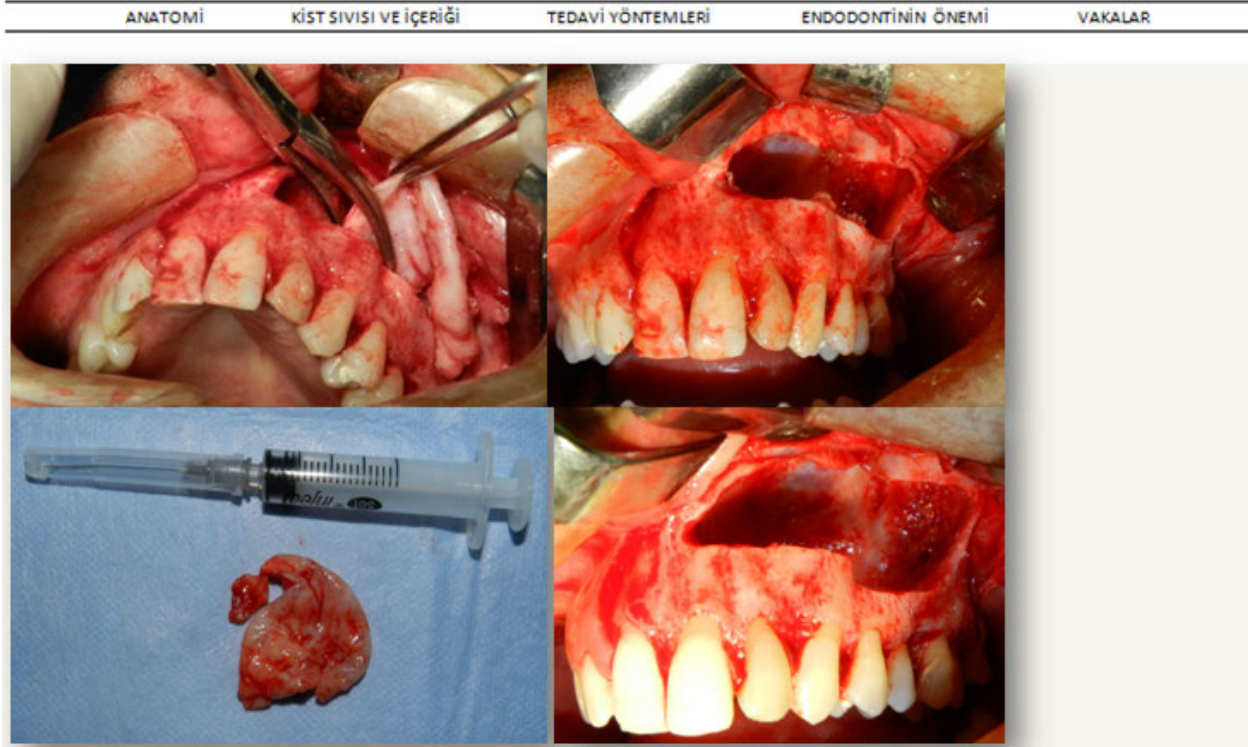


Figure 45. Enucleation of the cyst.

7. Conclusions

Because of the anatomy of the maxillary sinus, pathological structures that develop and grow in the sinus can reach a large size without any serious complaint by the patient, making early diagnosis unlikely and treatment is important to address morbidity.

OPG and CT scans aid in the diagnosis of cysts localized in the sinus and CT scans are indispensable in surgical strategy planning. Good visualization during the operation provides a better opportunity for good cleaning of pathologies, better bleeding control, and minimal trauma. For better visualization, the use of endoscopy during the operation can simplify and enhance the procedure. Also, close observation of patients in the early postoperative period and regular follow-up in the later postoperative period are important.

Author details

Hasan Garip*, Sertac Aktop, Onur Gonul and Kamil Göker

*Address all correspondence to: hasangarip@yahoo.com

Dear Authors, Add Your Respected Institutions, Town, Country

References

- [1] Gray's anatomy.
- [2] http://en.wikipedia.org/wiki/Maxillary_sinus
- [3] www.kenhub.com/en/library/anatomy/innervation-and-blood-supply-of-the-teeth
- [4] Sarachev E, Uzunov H. *Klinichna I Topographska Anatomoya na Litsevo-Chelusnata Oblast*. ISBN 9549806-14-6, 2001 Plovdiv, 449-495.
- [5] Miloro M. Peterson's Principle of Oral and Maxillofacial Surgery. Second Edition.. In Miloro M., Ghali G. E., Larsen P. E., Waite P. Editors. BC Decker Inc. 2004 p. 1179-1205
- [6] Aydinlioğlu A, Diyarbakirli S, Şakul U B, Keleş P, Arslan H, Kiriş M. Surgical Anatomy Of The Paranasal Sinuses: Cadaver And Ct Study I-Sinus Maxillaris And Frontalis. *Turkiye Klinikleri J Dental Sci* 1997;3(1):6-11
- [7] Jensen, Ole T. *The Sinus Bone Graft*, Quintessence Publishing Co, Inc, 1999 p. 31-48
- [8] Kılıc C, Kamburoğlu K, Yüksel SP, Özen T. An Assessment of the Relationship between the Maxillary Sinus Floor and the Maxillary Posterior Teeth Root Tips Using Dental Cone-beam Computerized. Tomography. *Eur J Dent*. 2010 Oct;4(4):462-7.
- [9] Jung YH, Cho BH. Assessment of the relationship between the maxillary molars and adjacent structures using cone beam computed tomography. *Imaging Sci Dent*. 2012 Dec;42(4):219-24.
- [10] Hirata Y, Kino K, Nagaoka S, Miyamoto R, Yoshimasu H, Amagasa T. A clinical investigation of oro-maxillary sinus-perforation due to tooth extraction. *Kokubyo Gak-kai Zasshi*. 2001 Sep;68(3):249-53
- [11] Miloro M. Peterson's Principle of Oral and Maxillofacial Surgery. Second Edition.. In Miloro M., Ghali G. E., Larsen P. E., Waite P. Editors. BC Decker Inc. 2004 p.295-312
- [12] Janner SF, Caversaccio MD, Dubach P, Sendi P, Buser D, Bornstein MM. Characteristics and dimensions of the Schneiderian membrane: a radiographic analysis using cone beam computed tomography in patients referred for dental implant surgery in the posterior maxilla. *Clin Oral Implants Res*. 2011 Dec;22(12):1446-53.
- [13] Dagassan-Berndt DC, Zitzmann NU, Lambrecht JT, Weiger R, Walter C. Is the Schneiderian membrane thickness affected by periodontal disease? A cone beam computed tomography-based extended case series. *J Int Acad Periodontol*. 2013 Jul; 15(3):75-82.
- [14] Han MH, Chang KH, Lee CH, Na DG, Yeon KM, Han MC. Cystic expansile masses of the maxilla: differential diagnosis with CT and MR. *AJNR Am J Neuroradiol*. 1995 Feb;16(2):333-8.

- [15] Caylakli F, Yavuz H, Cagici AC, Ozluoglu LN. Endoscopic sinus surgery for maxillary sinus mucocoeles. *Head Face Med*. 2006 Sep 6;2:29.
- [16] Buyukkurt MC, Omezli MM, Miloglu O. Dentigerous cyst associated with an ectopic tooth in the maxillary sinus: a report of 3 cases and review of the literature. *Oral Surg Oral Med Oral Pathol Oral Radiol Endod*. 2010 Jan;109(1):67-71.
- [17] Scott A. Martin. Conventional Endodontic Therapy of Upper Central Incisor Combined with Cyst Decompression: A Case Report. *JOE* 33(6), 2007, 753-757
- [18] Pogrel M A. Treatment of Keratocysts: The Case for Decompression and Marsupialization. *J Oral Maxillofac Surg* 63:1667-1673, 2005
- [19] Miloro M. Peterson's Principle of Oral and Maxillofacial Surgery. Second Edition.. In Miloro M., Ghali G. E., Larsen P. E., Waite P. Editors. BC Decker Inc. 2004 p.575-596
- [20] Bello SA, Oketade IO, Osunde OD. Ectopic 3rd molar tooth in the maxillary antrum. *Case Rep Dent*. 2014;2014:620741.
- [21] Varol A, Türker N, Göker K, Basa S. Endoscopic retrieval of dental implants from the maxillary sinus. *Int J Oral Maxillofac Implants*. 2006 ;21(5):801-4
- [22] Kim JW, Lee CH, Kwon TK, Kim DK. Endoscopic removal of a dental implant through a middle meatal antrostomy. *Br J Oral Maxillofac Surg*. 2007, 45(5):408-9.
- [23] Chen CT, Chen YR. Endoscopically assisted repair of orbital floor fractures. *Plast Reconstr Surg*. 2001 Dec;108(7):2011-8
- [24] Nour YA. Variable extent of nasoantral window for resection of antrochoanal polyp: selection of the optimum endoscopic approach. *Eur Arch Otorhinolaryngol*. 2014 Jul 11.
- [25] Dhingra PL, Dhingra S. Diseases of Ear, Nose and Throat. Chapter 82 5th edition, Elsevier 2010
- [26] Garip H, Garip Y, Oruçoğlu H, Hatipoğlu S. Effect of the angle of apical resection on apical leakage, measured with a computerized fluid filtration device. *Oral Surg Oral Med Oral Pathol Oral Radiol Endod*. 2011 Mar;111(3):e50-5.
- [27] Lin LM, Pascon EA, Skribner J, Langleland K. Clinical, radiographic, and histologic study of endodontic treatment failures. *Oral Surg Oral Med Oral Pathol* 1991;71:603-11.
- [28] Torabinejad M, Watson TF, Pitt FTR. Sealing ability of a mineral trioxide aggregate when used as a root end filling material. *J Endod* 1993;19:591-5.
- [29] Torabinejad M, Higa RK, McKendry DJ, Pitt FTR. Dye leakage of four root end filling materials: effects of blood contamination. *J Endod* 1994;20:159-63.