

We are IntechOpen, the world's leading publisher of Open Access books Built by scientists, for scientists

6,900

Open access books available

186,000

International authors and editors

200M

Downloads

Our authors are among the

154

Countries delivered to

TOP 1%

most cited scientists

12.2%

Contributors from top 500 universities



WEB OF SCIENCE™

Selection of our books indexed in the Book Citation Index
in Web of Science™ Core Collection (BKCI)

Interested in publishing with us?
Contact book.department@intechopen.com

Numbers displayed above are based on latest data collected.
For more information visit www.intechopen.com



Advanced Adjunct Orthosurgical Esthetic Procedure

Seied Omid Keyhan, Seifollah Hemmat,
Peiman Mehriar, Arash Khojasteh and
Mohammad Ali Asayesh

Additional information is available at the end of the chapter

<http://dx.doi.org/10.5772/59088>

1. Introduction

Changes in the esthetic appearance of the face is highly depended on the bony structures of the facial skeleton, including the malar-midface region, nose, and chin. Alterations of soft tissue and skin alone will not satisfy all of our aesthetic demands. Multiple factors such as skin (texture, color, thickness and...), soft tissue (symmetry, composition, location and...) and facial bony contours (size, shape, location, symmetry and...) contributes to creating esthetically appealing appearance of the face.

Since many years ago numerous surgical and office based techniques have been introduce to augment, reduce or refine the most projected points of the face such as cheek, chin, nose, Para-nasal area, angle of the jaw..According to the literature the techniques can be classified to: 1) Office based or non-invasive techniques; such as fillers injection, facial lipostructure or facial liposuction which modified the soft tissue coverage of the facial skeleton.2) Facial prosthesis. 3) Maxillofacial osteotomies. Based on our knowledge the first and second group have been considered more in the literatures and text book of the Oral and Maxillofacial Surgery (OMFS) or Plastic Surgery, it is perhaps related to the more complications of the osteotomy techniques or easiness of the office –based one. OMFS are familiar with orthognatic surgeries and their skill in this field can help them to plan the third one,especially in cases whom the long term results should be considered. In current chapter we reviewed the esthetic osteotomy techniques of the facial skeleton and introduce a surgical techniques for management of the most projected points of the face namely:

- **Chin modification**

Reduction genioplasty

- **Paranasal modification**

Piriform augmentation osteotomies

- **Mandibular Angle modification**

Angle augmentation osteotomies

Angle reduction osteotomies

- **Malar modification**

Malar augmentation osteotomies

Malar reduction osteotomies

- **Forehead modification**

Frontal Bossing reduction techniques

2. Chin modification

The creation or restoration of an esthetically pleasing facial contour can encompass many surgical approaches. Several surgical techniques are available for correcting and giving harmony to the lower third of the face.[1] In this respect, some well-known techniques seek to correct the shape and size of the chin using different kinds of chin implants or osteotomies in an effort to move it and change its spatial location, thus determining a new facial contour.

2.1. Augmentation genioplasty

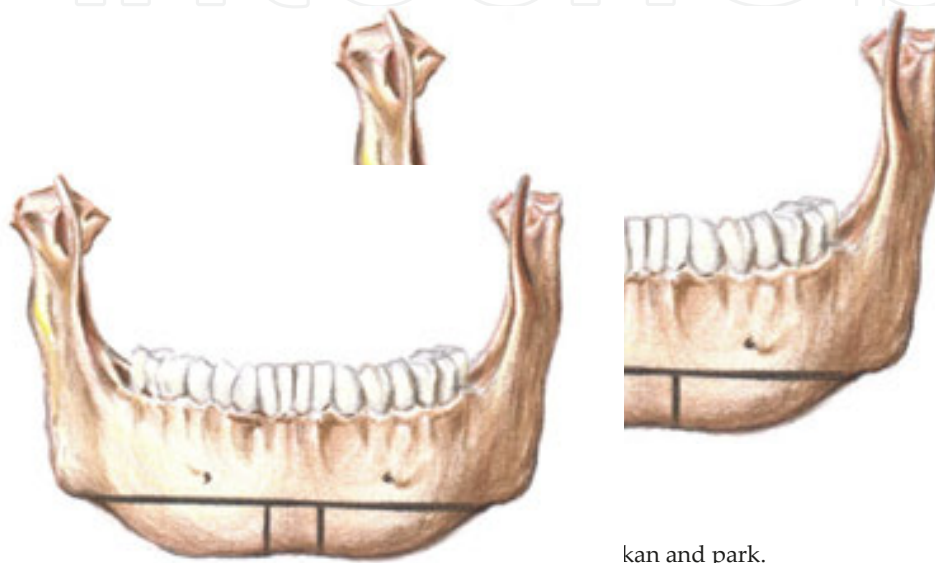
Genioplasty (anterior horizontal mandibular osteotomy) means a plastic procedure on the chin that involves both bony components (ie, anterior portion of the base of the mandible) and the soft tissue component. The procedure can be performed either alone or as an adjunct to other orthognathic and facial plastic surgeries. Either direct osteoplasty and soft tissue correction or implantation of an alloplastic material/cartilage/bone has been recommended for genioplasty. Since 1942, with first sliding advancement genioplasty that was described by Hofer, various genioplasty techniques with various indications, advantages, and disadvantages have been developed for correction of microgenia and macrogenia. In recent chapter we did not focused on augmentation genioplasty techniques. The readers can update their knowledge by reviewing the other chapters or books.

2.2. Reduction genioplasty

In the event of anterior mandibular bony excess different surgical approaches can be used. Each have their own limitations and disadvantages. For instance simple burring down removal of bony excess from anterior mandible through an intraoperative approach will usually result in an abnormal appearance and is not the best choice of treatment.

Reduction genioplasty surgical procedure results in narrowing or shortening of the chin. However, the literature lacks data about the best technique, indications, complications, and long-term results. The soft tissue envelope of the chin area usually follows the genial osseous movement approximately 90% or more, but the predictability ratio of horizontal reduction

Reduction genioplasty surgical procedure results in narrowing or shortening of the chin. However, the literature lacks data about the best technique, indications, complications, and long-term results. The soft tissue envelope of the chin area usually follows the genial osseous movement approximately 90% or more, but the predictability ratio of horizontal reduction genioplasty is limited; it follows approximately 50% to 60%.¹



kan and park.

Figure 1. reduction genioplasty technique described by Ukan and park.

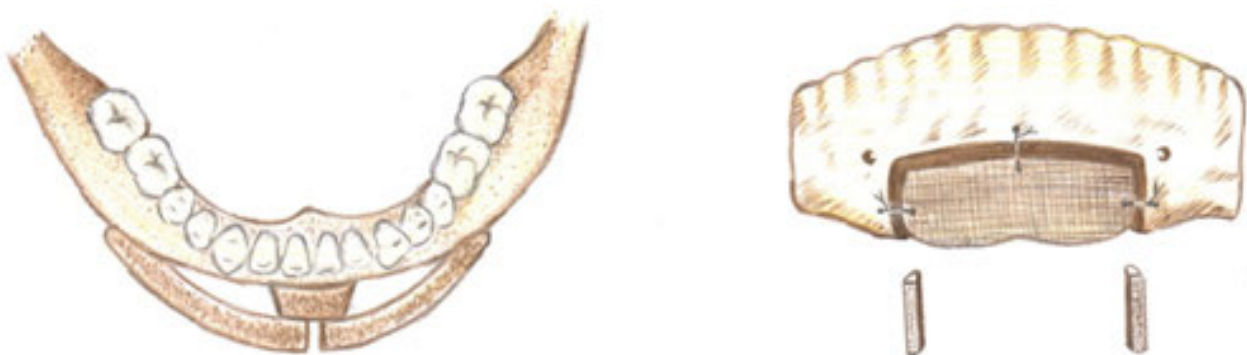


Figure 2. Horizontal T genioplasty and modified reduction genioplasty techniques.

Figure 2. Horizontal T genioplasty and modified reduction genioplasty techniques.

To date, only 2 articles have been published about the narrowing of the chin by use of this technique. Minor step-off at the chin-mandible junction and mild transient numbness of the lower lip, jowls, and bunching of the chin were reported as the most common complications of this technique. Because the lingual muscle is released, there is a risk of avascular necrosis of the distal segments, and the chin prominence should be minimally degloved to prevent this complication. Furthermore, because the mid-symphysis area is removed, the chance of asymmetry or unesthetic results could be increased(fig.1).¹ another techniques such as horizontal T osteotomy were also described but is not used widely(fig.2).^{10,46} In 2013 we described^{1,47} a novel technique to reduce the prominent chin 3-dimensionally(fig.3).This new genioplasty (Zigzag genioplasty) makes it possible to decrease the vertical and transverse dimension of the chin alone or simultaneously, symmetrically or asymmetrically. This genioplasty alsomakesit

of the distal segments, and the chin prominence should be minimally degloved to prevent this complication. Furthermore, because the mid-symphysis area is removed, the chance of asymmetry or unesthetic results could be increased(fig.1).[1] another techniques such as horizontal T osteotomy were also described but is not used widely(fig.2).[10, 46]In 2013 we described[1, 47] a novel technique to reduce the prominent chin 3-dimensionally(fig.3).This new genioplasty (Zigzag genioplasty) makes it possible to decrease the vertical and transverse dimension of the chin alone or simultaneously, symmetrically or asymmetrically. This genioplasty alsomakesit possible to decrease the mental sagittal projection,if indicated, and simultaneously reduce the mandibular body height. Zigzag genioplasty allows one to properly correct excess of the chin(3-dimensionally), avoiding the need for muscular repositioning (except sometimes in types III and IV)(fig.4).A simple geometric calculation allows one to mobilize the chin in a vertical, horizontal, and sagittal direction,according to the needs of each patient. Furthermore, this design preserves the suprahyoid muscle attachmentsand the most important anatomic portion of symphysis area; narrowing the wide chin by this technique provides an esthetic and natural facial look.[1, 47]

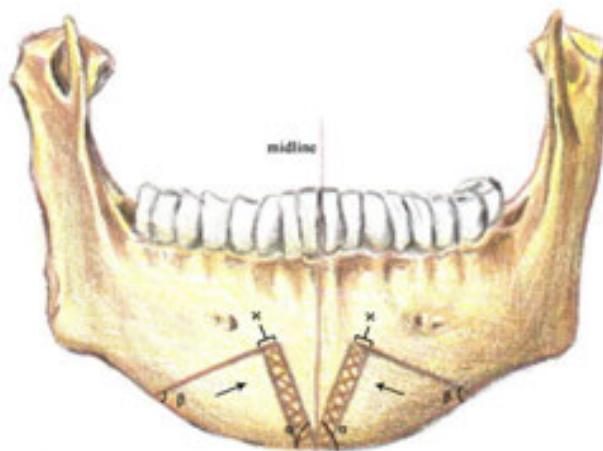


Figure 3. Zigzag osteotomy design is based on the displacement of 2 bone fragments on the slopes of an inclined plane with a superior-medial direction. The degree of inclination for these slopes (the α and β - angles) will be estimated pre-surgically according to ; the extent of the vertical and transverse displacement wanted for a given case, mandibular symphysis height and width, the size of remained bone fragments after ostectomy, the need for conventional or extended (to the mandibular body) reduction, the position of anterior mandibular teeth apices, the position of mental foramina and symmetrical or asymmetrical reduction.The posterior edges of the osteotomy, either could be finished just beneath the mental foramina (obtuse degree of inclination) or extended to the Anti-Gonial notch(acute degree of inclination),especially in such cases that, simultaneous reduction of inferior mandibular body osteotomy must be done, also. The amount of β -angle must be equal bilaterally except in asymmetrical cases.The anterior edge of the osteotomy which is extended medially from canine root apices (with a distance of 5 mm) to the mid-symphysis area, either could be extended above the inferior border(especially; in such cases which simultaneous advancement or set back should be done) or beyond it.As the same manner to posterior edge, the degree of inclination in the anterior part (the α -angle) could be determined pre-surgically,and must be equal in both sides except in asymmetrical cases.[from Keyhan et al. Zigzag genioplasty: a new technique for 3-dimensional reduction genioplasty. *Br J Oral Maxillofac Surg*.2013]

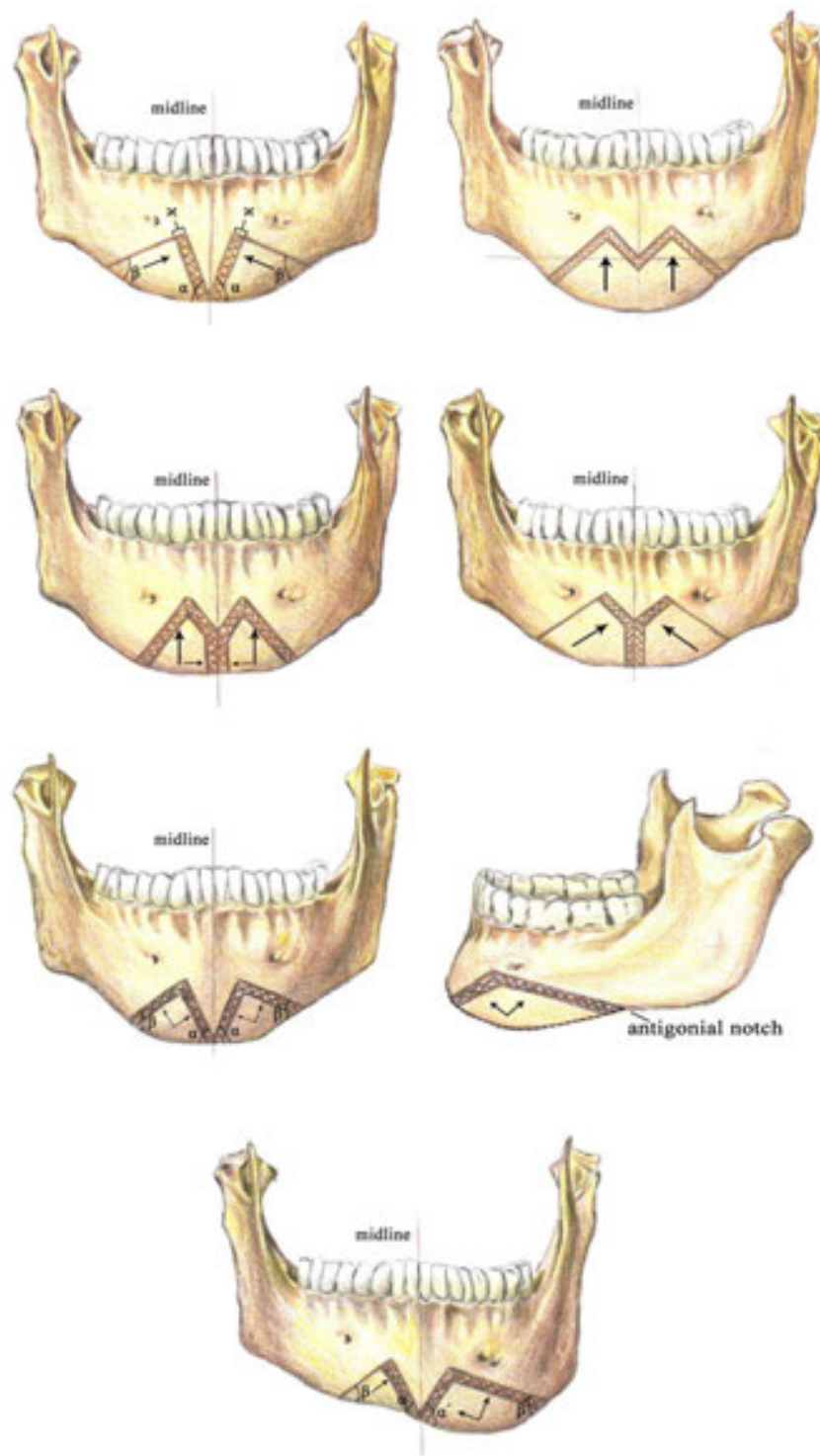


Figure 4. Schematic views of osteotomy design modifications of zigzag genioplasty technique (type I-VII). The anterior edge of the osteotomy could either be extended above the inferior border or beyond it. The posterior edges of the osteotomy, could either be finished just beneath the mental foramina or extended up to the Anti-Gonial notch. For pure chin narrowing with minimal reduction in vertical dimension, bone removal just near the strut of bone in the middle should be done, and if vertical reduction is planned as well, bone strips should be removed above both posterior and anterior slob. [from keyhan et.al. Zigzag genioplasty; patients evaluation, technique modifications and review of the literature. Br J oral amxillofac surg.2013] Figure reprinted with permission from The Br J oral amxillofac surg.

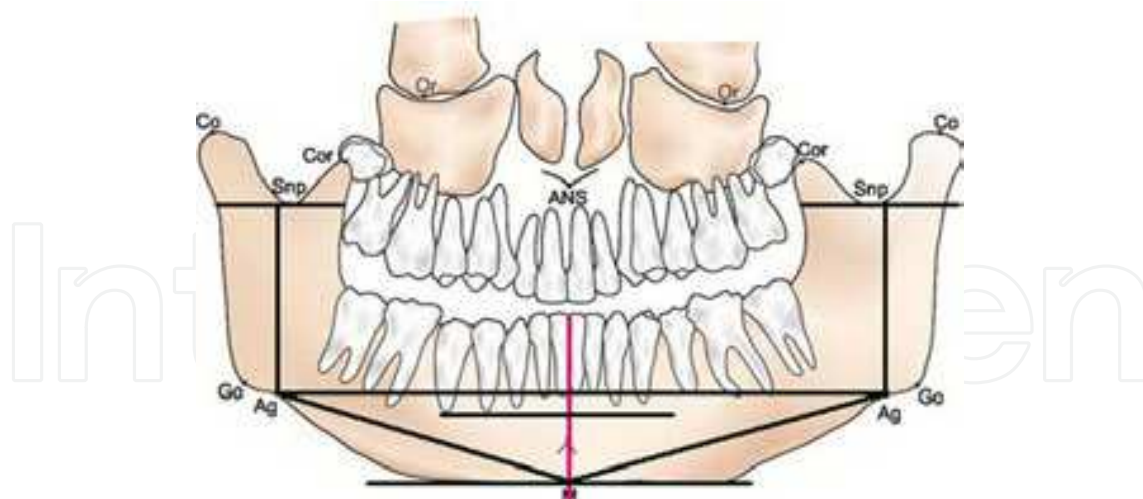


Figure 5. A simple geometric calculation allows one to mobilize the chin in a vertical, horizontal and sagittal direction, according to the needs of each patient the design of the planned osteotomy can be traced on the tracing paper and a surgical guide can be made simply.

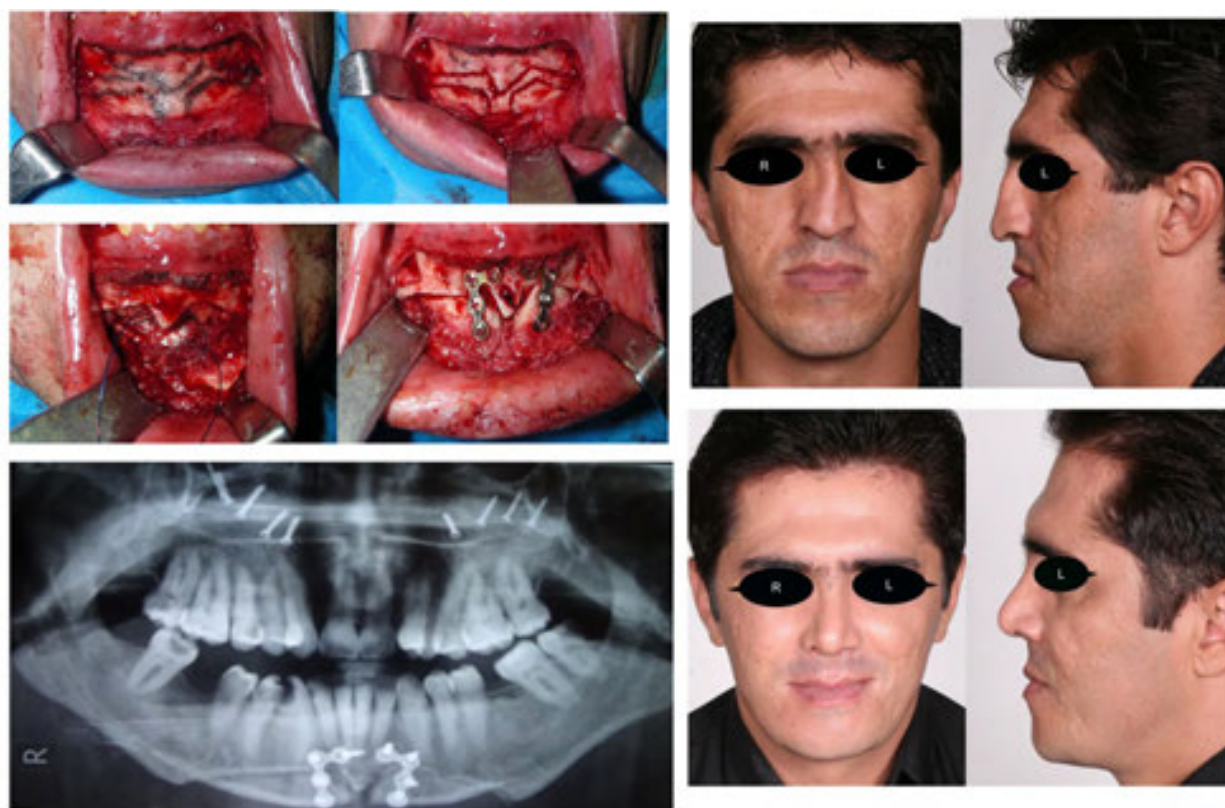

Figure 6. A 29 years old man who underwent zigzag genioplasty (type III) in combination with rhinoplasty, buccal fat pad lifting [48], malar prosthesis and paranasal augmentation. a, b, c, d) Incision of the oral mucosa was performed 5 to 7 mm labial to the depth of the vestibule and directed horizontally. Then, the muco-periosteal flap was released, and the mental nerve was exposed. The chin prominence was degloved, and the lingual muscle attachments were maintained for blood supply. The osteotomy sites (type III) were marked with a surgical marker and the osteotomy was done with reciprocal saw and fissure bur. In the next step, bone strips were removed bilaterally and the osteotomy was continued.

bilaterally, after down-fracturing, the interferences were removed, with high accuracy in maintain lingual pedicle tissues, detached supra-hyoids muscles was secured to the bone strut and medial and superior displacement was performed with the traction of two 10 centimeter wires. e) 2 L-shape miniplates were used for fixation. Any bone irregularity could be removed with round bur although, most often they could be remodeled post operatively. Vestibular incision was closed with 3-0 vicryl sutures. f, g) pre-operative views. h, i) post-operative views, simultaneous rhinoplasty and malar and para-nasal augmentation were performed also. [from keyhan et.al. Zigzag genioplasty ;patients evaluation, technique modifications and review of the literature. Am J Cosmetic surg, 2013]. **Figure reprinted with permission from The American Journal of Cosmetic Surgery.**

3. Paranasal modification

Clinical evaluation: There is no specific soft tissue or skeletal cephalometric landmark(s) or values to quantify the “fullness” of this region, so deficiency assessment of para-alar region is mainly based on qualitative profile judgment. [64]

Surgical technique: After general anesthésia and flap incision and elevation the osteotomy is done 2cm above the nasal floor from one side to another side To allow adequate mobilization the junction between septum and bony segment should be cut this can be done by a osteotomy.

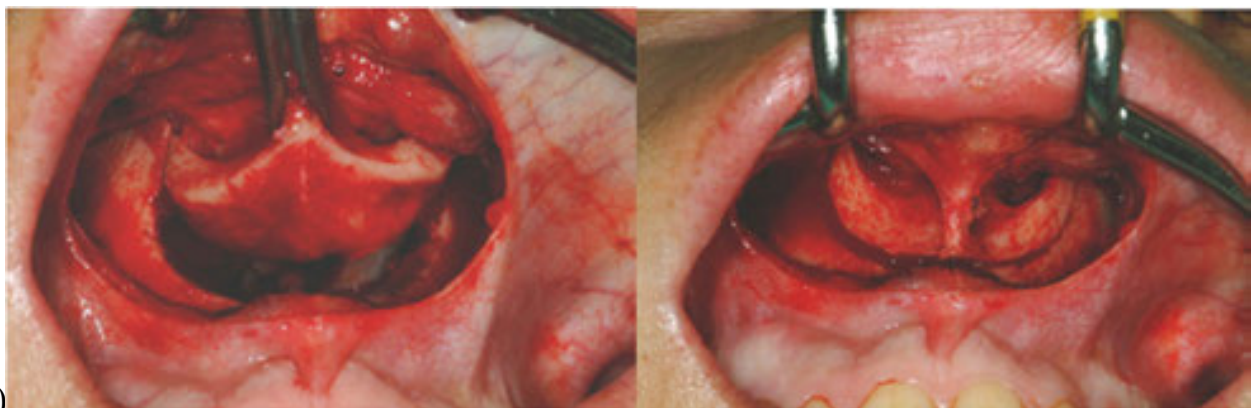


Figure 7: U-shaped osteotomy of piriform aperture. [from Herná'ndez Alfaro F, García E, Martí C, Porta A. U-shaped osteotomy in management of paranasal deficiency. Int. J. Oral Maxillofac. Surg. 2006]

4. Angle modification

Caucasians consider a prominent mandibular angle to be unappealing in their populations, and mandibular angle ostectomy has been popular since Baek et al. introduced it in 1989. [66] Standard procedure to correct prominent mandibular angles is mandibular angle ostectomy

4. ANGLE MODIFICATION
with an oscillating saw through the intraoral approach, although a number of modifications and improvements in operative techniques have been reported in the last two decades. [68, 69] Kim et al. [70] classified all the patients with prominent mandibular angle according to mandibular angle shape into four classes (I, II, III, and IV). [70]
Caucasians consider a prominent mandibular angle to be unappealing in their populations, and mandibular angle ostectomy has been popular since Baek et al. introduced it in 1989. [66] Standard procedure to correct prominent mandibular angles is mandibular angle ostectomy with an oscillating saw through the intraoral approach, although a number of modifications and improvements in operative techniques have been reported in the last two decades. [68, 69] Kim et al. [70] classified all the patients with prominent mandibular angle according to mandibular angle shape into four classes (I, II, III, and IV). [70]

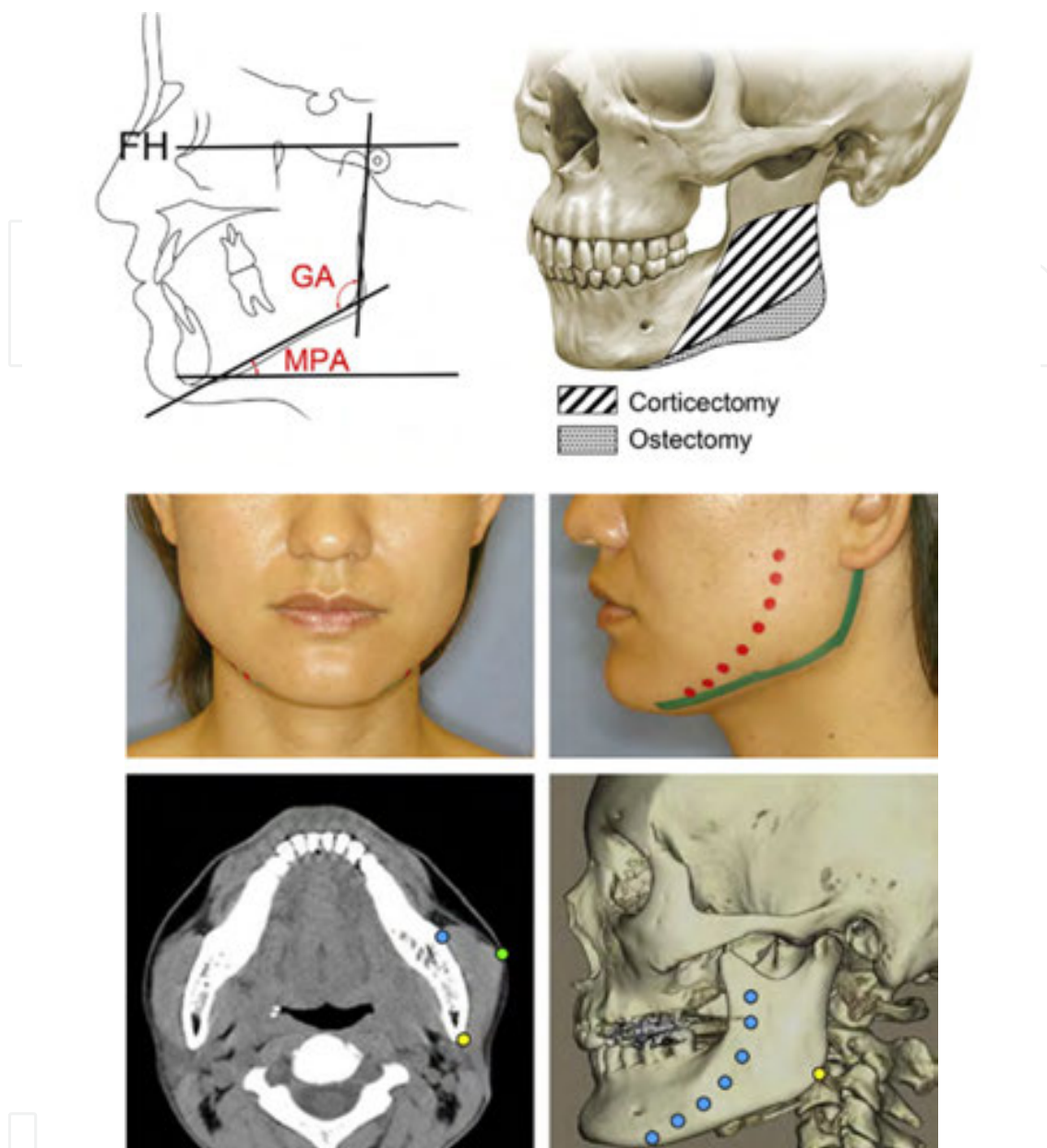


Figure 8: Preoperative evaluation and planning for mandibular angle reshaping. [from Hirohi et al. Lower face reduction with full-thickness marginal osteotomy of mandibular corpus-angle followed by corticectomy. J Plast Reconstr Aesth Surg. 2010.]

Clinical evaluation: It is important to consider the plans for correcting the lateral and frontal appearances of the lower face separately, because the ideal correction requires two surgical techniques. **Surgical technique:** Firstly, the osteotomy of the marginal part of the mandibular corpus-angle was performed, then corticectomy after evaluating the thickness of the resected bone fragment. Mandibular corticectomy was performed to improve the frontal appearance. After designing the osteotomy line with a pencil, a groove was hollowed out on the lateral cortex using a round burr. [66]

Surgical technique: Firstly, the osteotomy of the marginal part of the mandibular corpus-angle was performed, then corticectomy after evaluating the thickness of the resected bone fragment. Mandibular corticectomy was performed to improve the frontal appearance.[66] After designing the osteotomy line with a pencil, a groove was hollowed out on the lateral cortex using a round burr. [66]

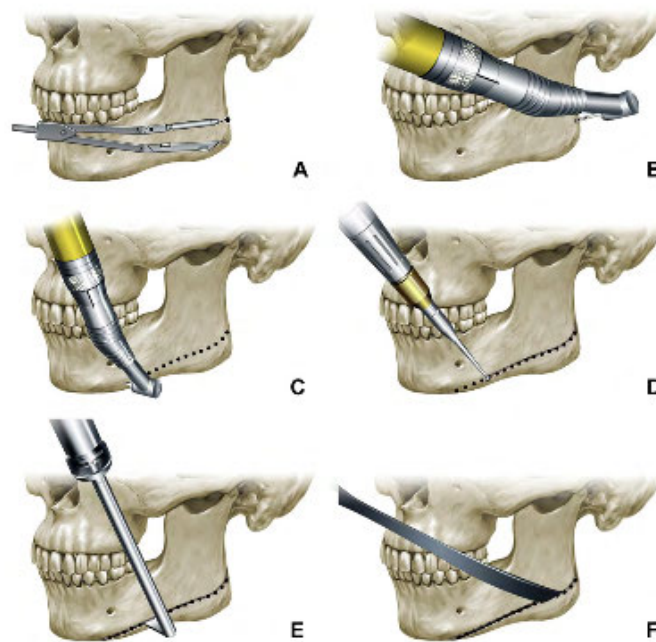


Figure 9. Operative procedures for en-bloc mandibular corpus-angle osteotomy (MCAO) with a contra-angle hand-piece. [from Hirohi et al. Lower face reduction with full-thickness marginalostectomy of mandibular corpus-angle followed by corticectomy. J Plast Reconstr Aesth Surg. 2010.]

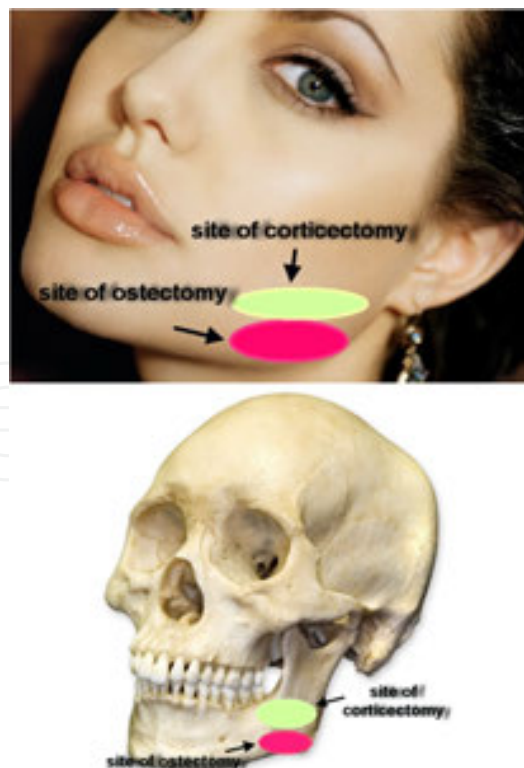


Figure 10: schematic view of sites of corticectomy and osteotomy.

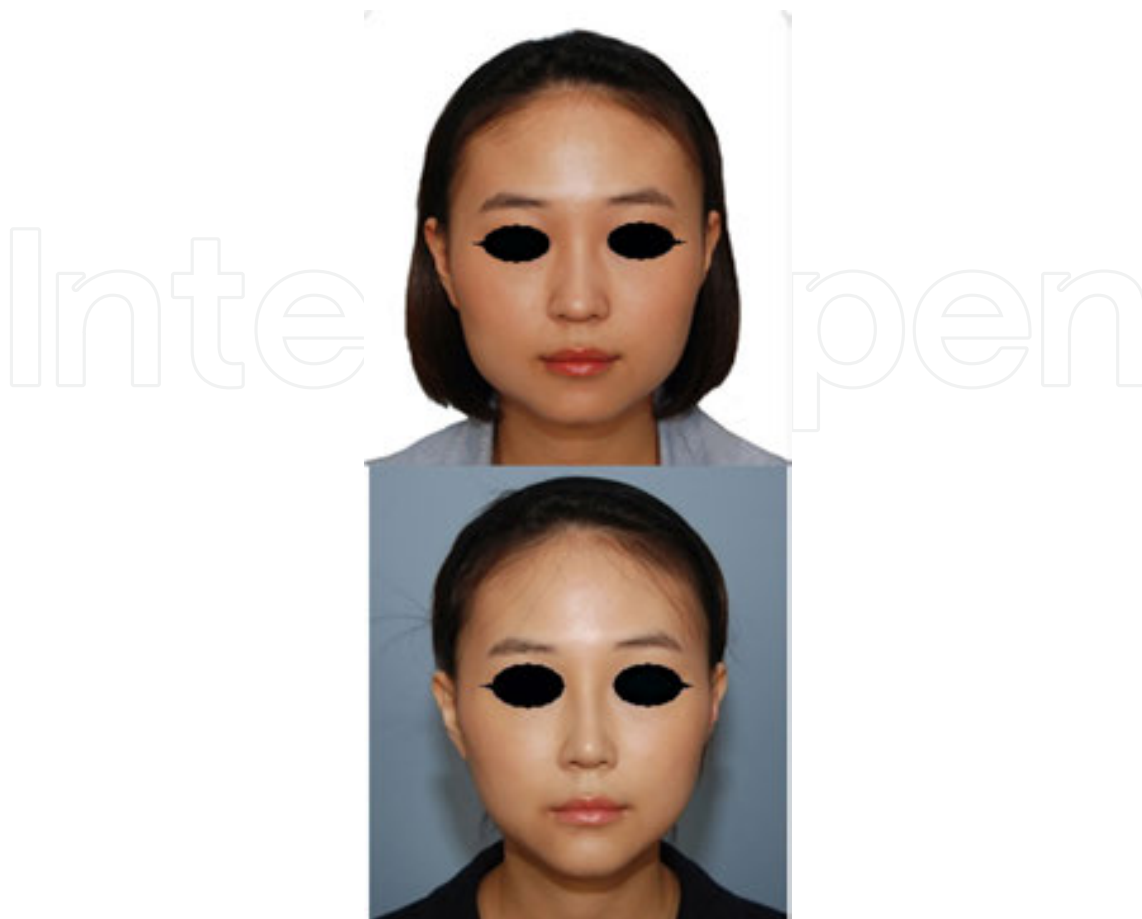

Figure 11: A 28 year-old woman with a muscular and square face desired mandibular reshaping and underwent mandibular corpus-angle osteotomy and corticectomy. The postoperative frontal view shows that the width of his lower face was greatly reduced by osteotomy and corticectomy.

4-1-Reduction malarplasty

4.1. Reduction malarplasty Reduction body and arch malarplasty (RBAM) is suited for patient with a hyperplastic anterior and posterior midface which will soften their square and wide facial appearance.^{90,94,95}

Reduction body malarplasty (RBM) can be done for patients with a hyperplastic anterior mid-face. Reduction body and arch malarplasty (RBAM) is suited for patient with a hyperplastic anterior and posterior midface which will soften their square and wide facial appearance.[90, 94, 95]

Surgical techniques: since many years ago numerous surgical technique have been introduced to reduce the prominent malar, which some of these techniques are discussed here.

Zygoma shaving procedure: After intra oral flap elevation the entire zygomatic body and arch is exposed and subperiosteal dissection is carried out. [89] The most prominent portion of the zygoma, including part of the zygomatic arch, is shaved using a broad chisel or a bone bur. [89]

I-shaped osteotomy: Using a reciprocating saw, 2 parallel cuts are made on the zygomatic body from inner cortex toward the outer cortex resembling an I shape. [89] Then, the zygoma and the zygomatic arch complex are displaced antero-medially.

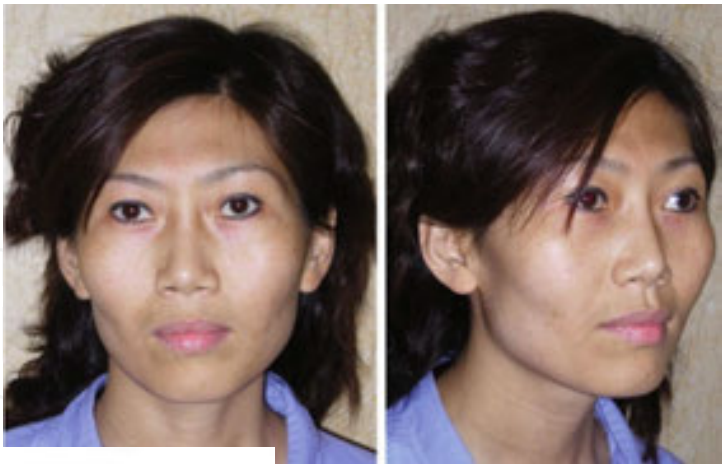

Figure 12. / considered 1 malarplasty

ere malar prominence. wide faces due to a prominent zygoma are ht) views.[from Zou C, et al. midface contour change after reduction surgical outcomes study. Aesthetic plast surg.2014]

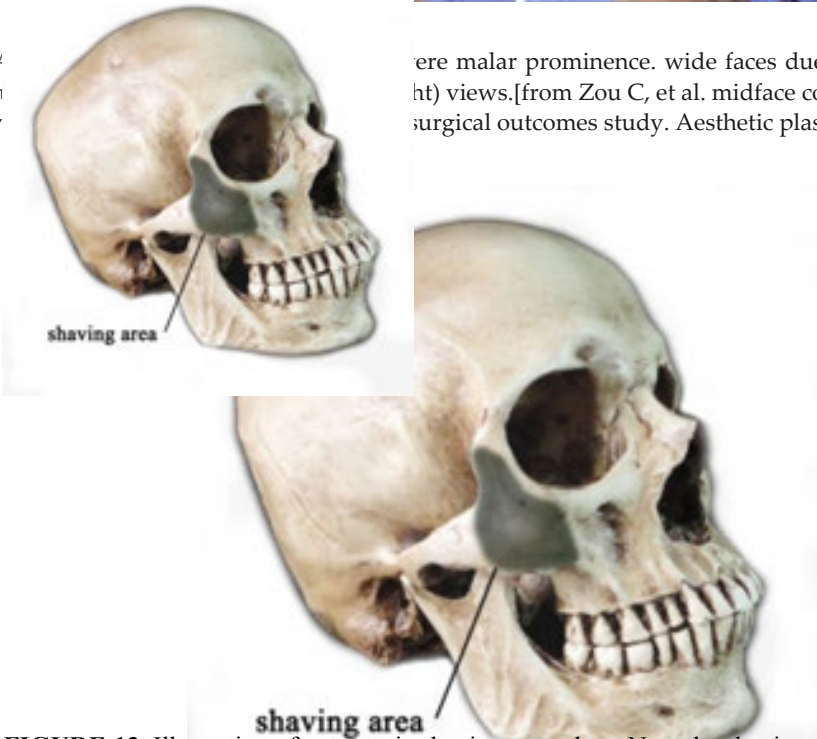

FIGURE 13. Illustration of zygomatic shaving procedure. Note the shaving area involved the zygoma and the anterior part of zygomatic arch.

Figure 13. **I-shaped osteotomy:** Using a reciprocating saw, the parallel cuts are made on the zygomatic body from the anterior part of zygomatic body from inner cortex toward the outer cortex resembling an I shape. Then, the zygoma and the zygomatic arch complex are displaced antero-medially .

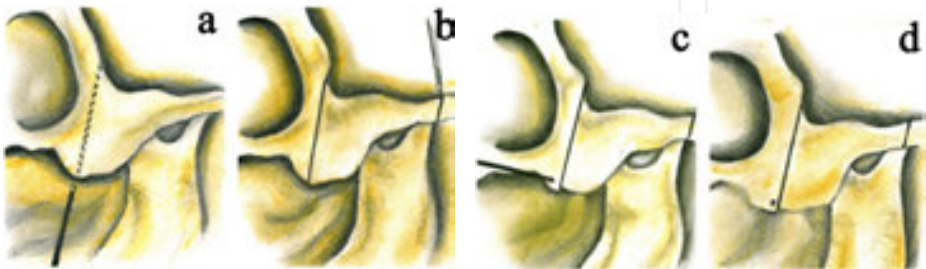


FIGURE 14. Illustration of I-shaped osteotomy.
Figure 14. Illustration of I-shaped osteotomy.

L-shaped osteotomy: This technique is similar to I-shaped osteotomy which can be considered in special cases.

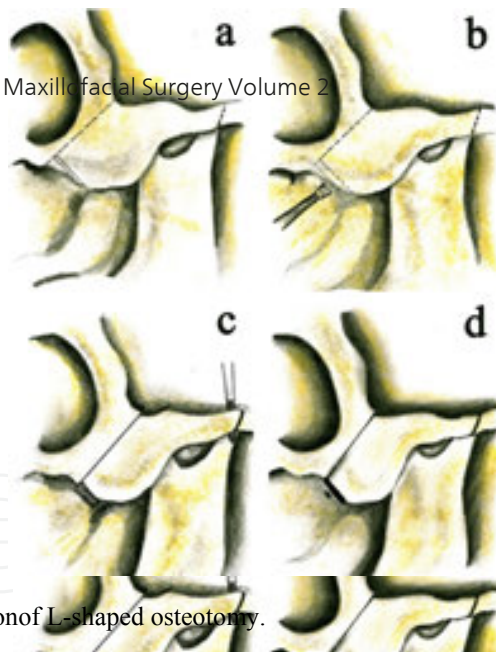


FIGURE 15. Illustration of L-shaped osteotomy.

C-shaped osteotomy The main difference of this technique with L-shaped osteotomy is in the oblique part of the osteotomy line; the oblique line is moved more toward the external orbital rims in comparison with the L-shaped osteotomy and consists of 2 parallel lines unlike L-shaped osteotomy in which we have only 1 line of osteotomy. [89]

FIGURE 15. Illustration of L-shaped osteotomy.
Figure 15. Illustration of L-shaped osteotomy.

C-shaped osteotomy The main difference of this technique with L-shaped osteotomy is in the oblique part of the osteotomy line; the oblique line is moved more toward the external orbital rims in comparison with the L-shaped osteotomy in which we have only 1 line of osteotomy. [89]

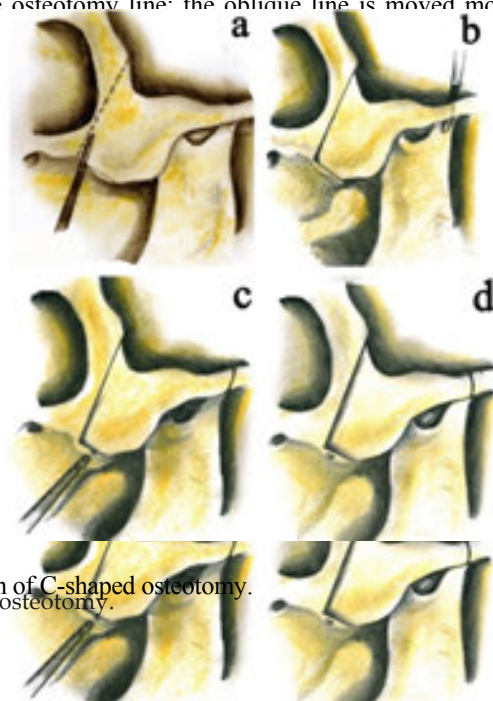


FIGURE 16. Illustration of C-shaped osteotomy.
Figure 16. Illustration of C-shaped osteotomy.

L-shaped osteotomy: This technique is used in special cases where the maxilla is shifted forward and upward, which can be considered in special cases.

FIGURE 16. Illustration of C-shaped osteotomy.

C-shaped osteotomy The main difference of this technique with L-shaped osteotomy is in the oblique part of the osteotomy line; the oblique line is moved more toward the external orbital rims in comparison with the L-shaped osteotomy and consists of 2 parallel lines unlike L-shaped osteotomy in which we have only 1 line of osteotomy. [89]

Modified L-shaped Osteotomy: The modified L-shaped osteotomy differed from the original method mainly in that the two parallel osteotomy lines are made vertically so that the zygomatic body and arch can be shifted (Fig. 17).

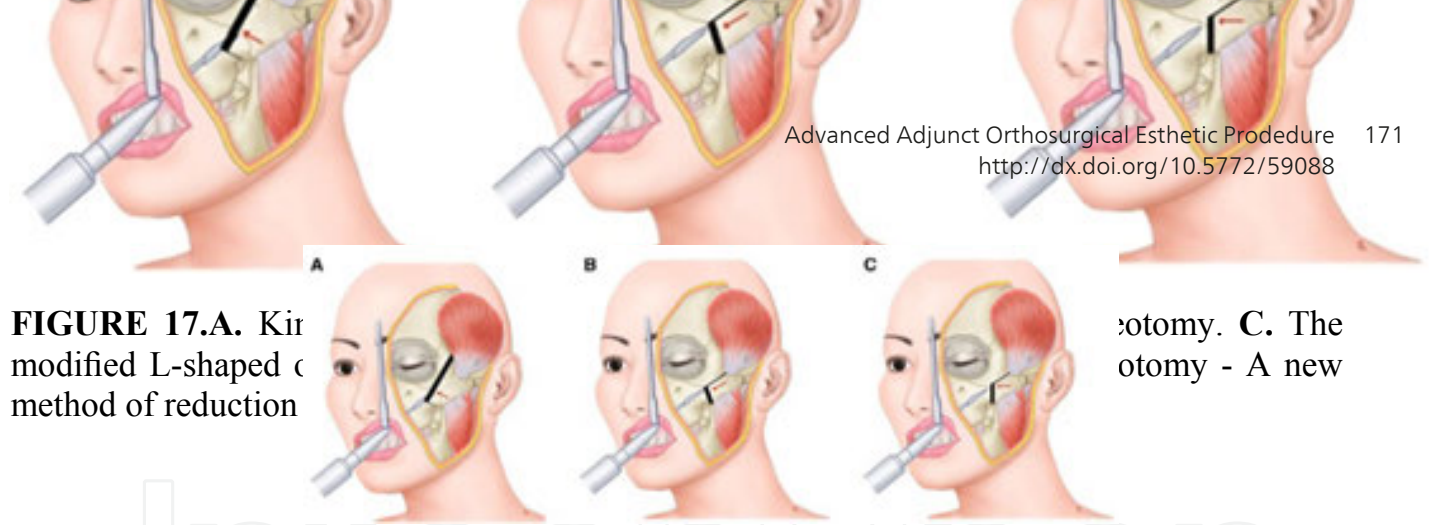


FIGURE 17.A. Kim's modified L-shaped osteotomy. B. The original L-shaped osteotomy. C. The new method of reduction malarplasty.

ototomy. C. The
 otomy - A new

Figure 17. A. Kim's L-shaped osteotomy. B. The original L-shaped osteotomy. C. The modified L-shaped osteotomy. [from Nakanishi Y, et al. The boomerang osteotomy - A new method of reduction malarplasty. 2012]

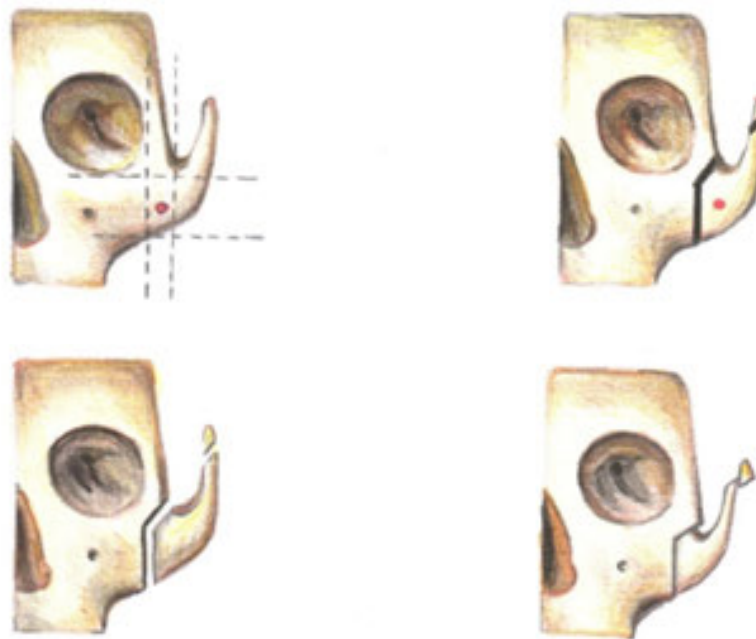


Figure 18. (Left Above) Location of the most prominent part of the zygoma body (red point) (Right Above) Incision of the Boomerang Osteotomy (Left Below) Mobilization of the bone (Right Below) The complex of the zygoma body and zygomatic arch is shifted medially.

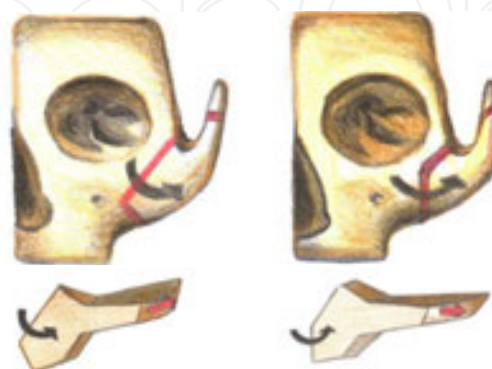
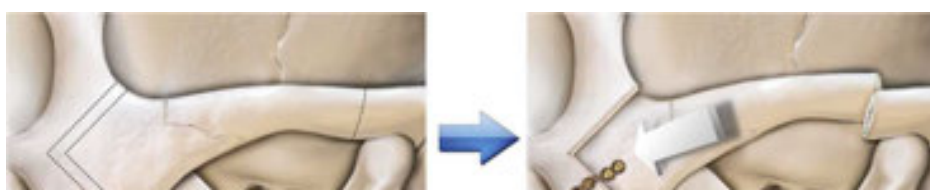

Figure 19. With Kim's method, the zygomatic arch shifts upward as the rotation for subtle adjustment. The vertical height of the zygomatic arch presents no change with boomerang method. **Figure 19.** With Kim's method, the zygomatic arch shifts upward as the rotation for subtle adjustment. The vertical height of the zygomatic arch presents no change with boomerang method.

Horizontal v-shaped osteotomy : this technique is similar to L-shaped osteotomy .



Horizontal v-shaped osteotomy : this technique is similar to L-shaped osteotomy.

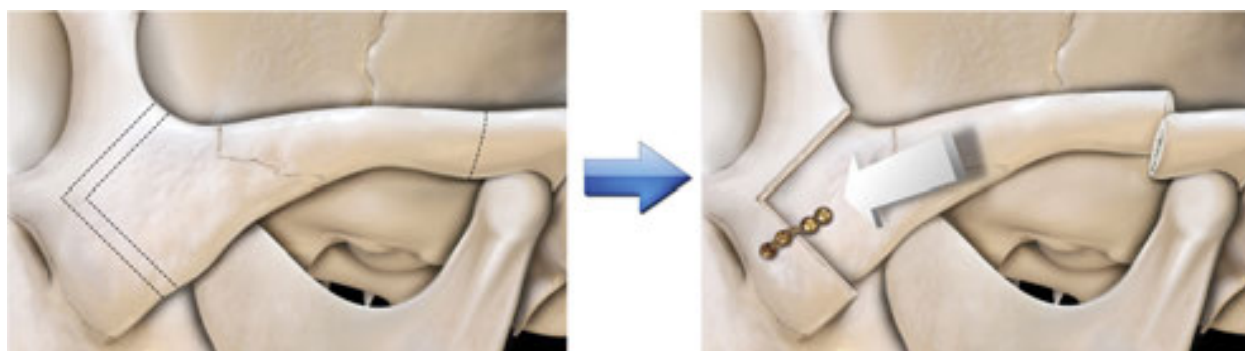


Figure 20. Horizontal V-shaped osteotomy used to correct protrusion of the zygoma and zygomatic arch. Not that the free part of the root of the zygomatic arch was locked into the gap between the rigid part and the temporal bone as a mortice and tenon structure.[fromTang K, et al. New horizontal v-shaped osteotomy for correction of protrusion of the zygoma and the zygomatic arch in East Asiansindication and results. Br J Oral Maxillofac Surg. 2014]

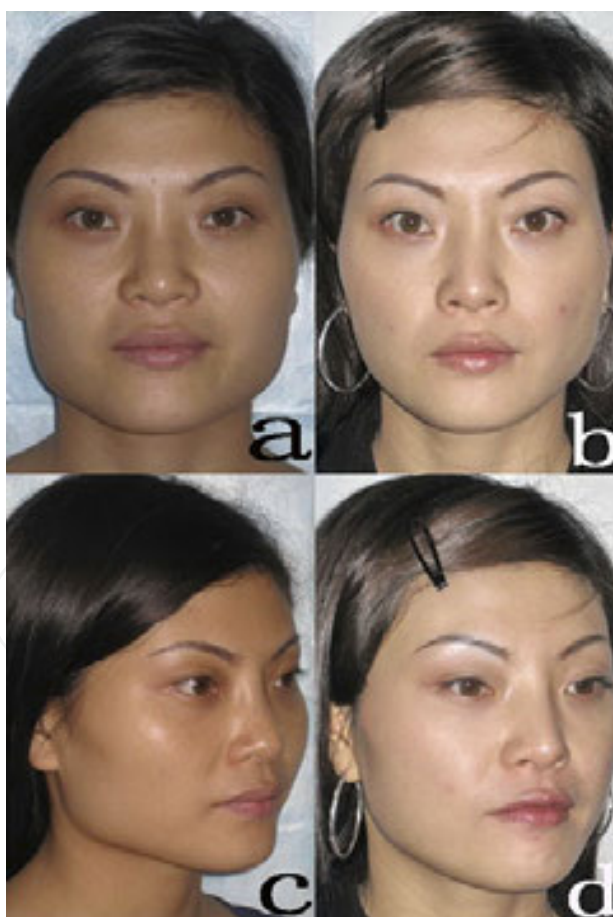

Figure 21. Preoperative views of the same patient (a, c). Postoperative views after an L-shaped malar osteotomy and repositioning and mandibular reduction (b, d).[fromChen T, et al. correction of zygoma and zygomatic arch protrusion in east Asian individuals. Oral Surg Oral Med Oral Pathol Oral Radiol Endod.2011].

4.2. Aumentation malarplasty

Clinical evaluation: Oval shaped face with the key component of malar prominence is considered to be a sign of beauty and youth in Caucasians. [73] Many tricks using artificial highlighting and darkening are developed by makeup artists to accentuate the malar prominence. [73] Flattened cheeks and narrow face makes people look sad and prematurely aged. [73] This transverse midface deficiency can be addressed by widening the bimalar width.[73]

Hinderer ^[100]	From the frontal view, draw a line from the lateral commissure of the lip to the lateral canthus of the ipsilateral eye and another line from the tragus to the inferior edge of the nasal ala. The area posterior and superior to the junction of these two projections should be the most prominent area of the malar eminence. (Fig. 12a) ^[100]
Powell et al ^[77]	Draw a vertical line through the middle of the face, then bisect the segment between the nasion and the nasal tip with a line that curves gently upward to the tragus on both sides. Draw a line from the inferior ala to the lateral canthus and another one, parallel to this one, from the lateral oral commissure toward the ear. The intersection of the curvilinear horizontal line and the line from the oral commissure marks the point where the malar area should be most prominent. (Fig. 12b) ^[77]
Silver and Guilden ^[101]	If the malar prominence in the true lateral projection is >5 mm posterior to the nasolabial groove, then a deficiency in the malar area exists. Silver describes the malar prominence triangle. ^[101] To create this triangle, draw a Frankfort horizontal line across the face in frontal projection and a parallel line that bisects the upper lip. Then draw a perpendicular line through both of these lines and through the lateral canthus. The intersection of the vertical line and the line through the upper lip defines point A. ^[101] Create a line from point A though the medial canthus and then a second line from point A toward the temporal area-but at the same angle from the vertical that was created by the projection from point A through the medial canthus. This creates the malar prominence triangle with the base being the Frankfort horizontal and the apex being point A. Silver advises that the implant should be placed several millimeters below the Frankfort line. (Fig. 12c) ^[101]
Wilkinson ^[102]	The ideal high points as he has suggested is at or just lateral to the outer canthus of the eye on a point a distant of approximately one-third from the lateral canthus to the inferior border of the mandible. (Fig.12d) ^[102]
Schoenrock ^[103]	On an oblique view (27 to 35 degrees of rotation from the frontal view) in natural head position,A line from themost lateral point of the malar complex intersected at 90° the commissure-canthus line at 66% of its lengthand The length of thisline was 17% the length of the commissure-canthus line. (Fig. 13) ^[103]

Table 1. Analyses of malar projection

Malar recontouring involves not only the zygomatic region, but also the infraorbital,paranasal, and buccal regions. Furthermore, imperfections of other facial areas may reflect negatively on the malar region. The buccal region should be slightly concave or flat in adults,within the

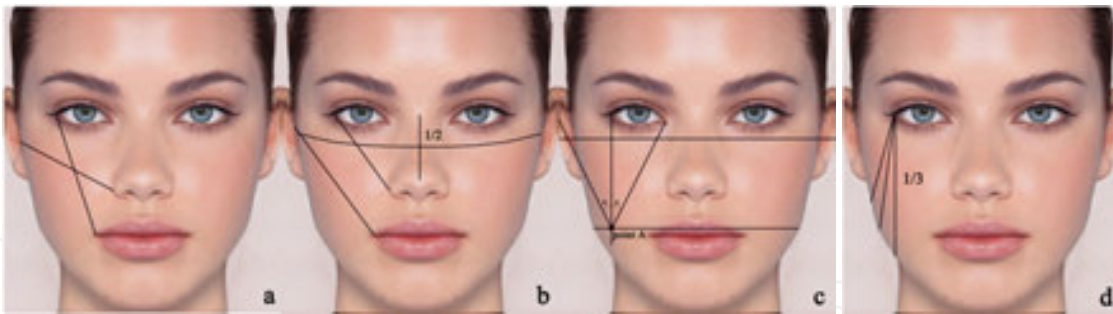


Figure 22. analyses of malar projection. a, hinderer analysis. b, pwell et al analysis. c, Silver and Guilden. d, Wilkinson analysis.

Malar recontouring involves not only the zygomatic region, but also the infraorbital, paranasal, and buccal regions. Furthermore, imperfections of other facial areas may reflect negatively on the malar region. The buccal region should be slightly concave or flat in adults within the confines of a tangent from the cheekbone to the mandibular angle. Fullness in the buccal area can give the illusion of a poorly developed malar eminence. In these patients, partial excision of the buccal fat pad may be indicated.^[104] Shadowing in the concavity of the buccal area highlights the malar eminence, giving it a sculptured, well-defined look. Caucasian women tend to accentuate this effect by using makeup, whereas Asians prefer much softer contours. But excessive buccal hollowness results in an emaciated, gaunt appearance with exaggerated malar definition. Excessive width and prominence of the mandibular angle and masseter muscles make the malar eminence look small and give the face a square or triangular shape. Reduction of the mandibular angle and masseter muscles might be more adequate than malar augmentation. The malar eminence and its relative position to the peri-orbital region of the face is important. A high and prominent angle and masseter muscles might appear adequate, but the malar eminence is also examined relative to the peri-orbital region. A high and prominent (Fig. 21) malar eminence enhances the appearance of the beautiful eye. Fullness of the area 10 mm lateral and 15–20 mm inferior to the lateral canthus should be obvious. (Fig. 21)¹⁰⁵

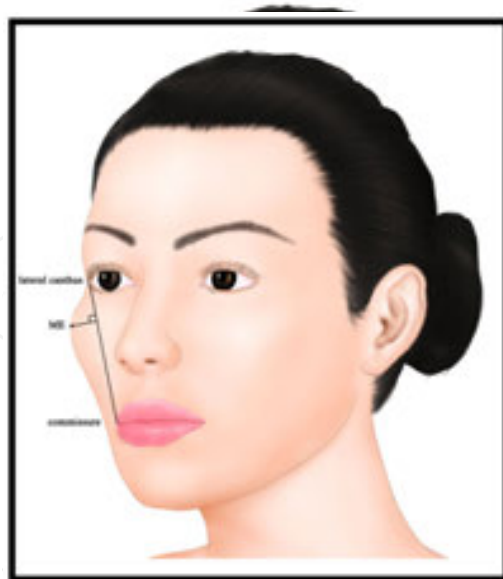


Figure 23. Schoenrock analysis

minence.

Surgical techniques:

Zygomatic arch osteotomy: A subperiosteal flap is raised to expose the ascending malar buttress and the zygomaticomaxillary suture. The position of an oblique sagittal cut is selected

by deciding whether augmentation should include any of the anterior buttress or whether it should be totally lateral to zygomaticomaxillary suture line. The cut is then made with a sagittal reciprocating saw starting from the inferior portion of the zygomaticomaxillary suture to the notch of both lateral orbital rim and malar zygomatic process. A previously selected graft may now be placed between the two segments. The result is an increase in interarch width (zygion-zygion).(Fig 22)

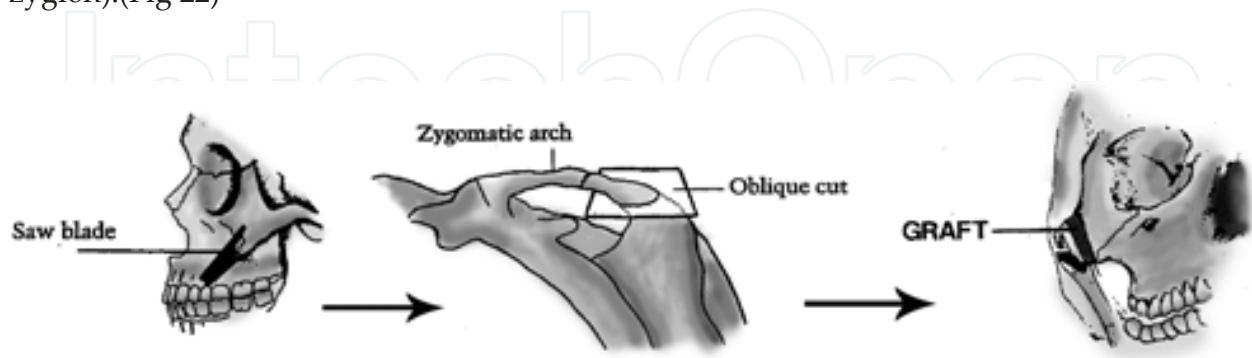


Figure 24. Surgical steps of zygomaticarch osteotomy.

Zygomatic sandwich osteotomy (ZSO): To solve some problems, modifications of zygomatic arch osteotomy technique have been presented. Mommaerts et al [81]modified Powell's technique by connecting a vertical with a semihorizontal osteotomy which both transect the maxillary sinus, thereby maximizing anterior as well as lateral augmentation.

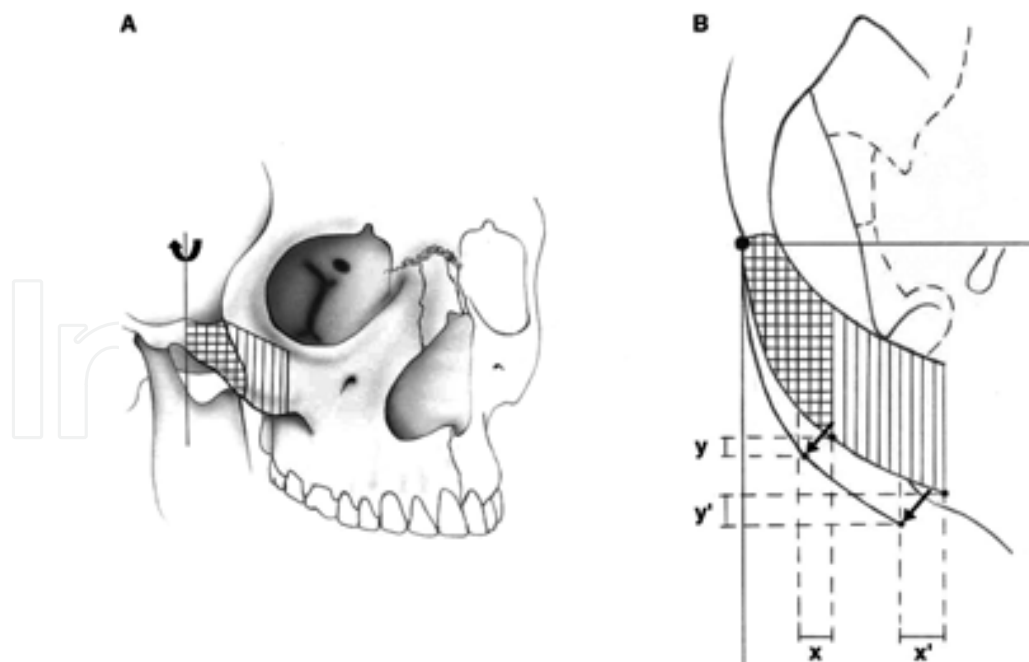


Figure 25. Comparison of zygomatic arch osteotomy (Powell et al) and zygomatic sandwich osteotomy (Mommaerts et al). (A) difference in design (zygomatic arch osteotomy [ZAO] = horizontal lines; zygomatic sandwich osteotomy [ZSO] = vertical lines). (B) amount of augmentation, caudal view (x = lateral displacement with ZAO; x' = lateral displacement with ZSO; y = anterior displacement with ZAO; y' = anterior displacement with ZSO).

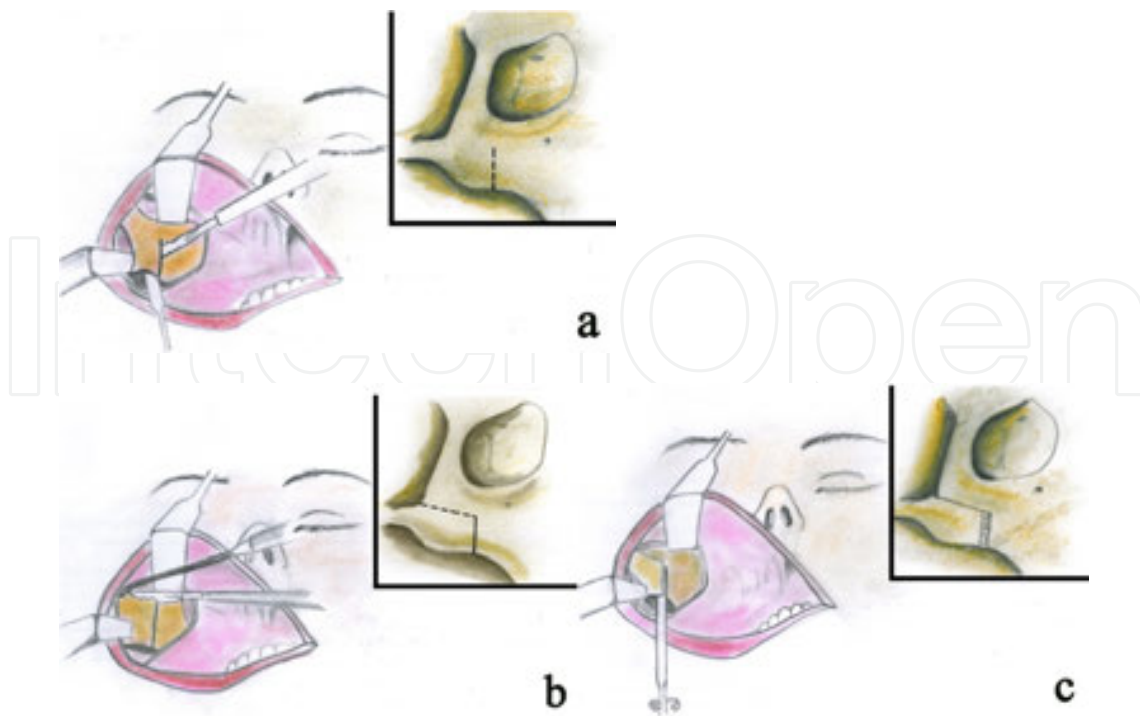


FIGURE 24. a. vertical osteotomy, b. semihorizontal osteotomy, c. Opening of the vertical osteotomy and insertion of spacer material.

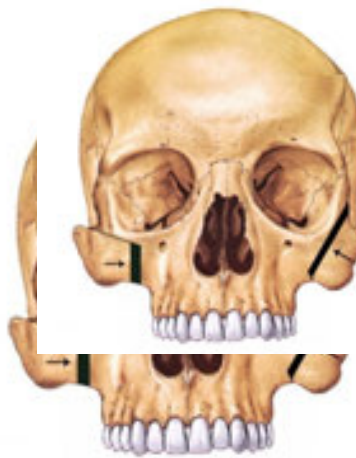

Figure 27. Malar augmentation, differences in osteotomy design: Mommaerts et al (left) compared with Kim and Seul (right).

Zygomatic Sagittal Split Osteotomy (ZSSO): in this technique the zygomatic arch is isolated from its temporal origin to its zygomatic insertion both on its lateral and medial surfaces. Using a waver sewer, a sagittal full thickness osteotomy of the zygomatic arch is performed (Fig. 26). Later, 2 separate partial thickness osteotomies: one on the arch's osteotomies are connected with the previously released sagittal osteotomy. After correction of the zygomatic arch according to presurgical programs. Stabilization is achieved using bicortical titanium screws (Fig. 26).

Zygomatic Sagittal Split Osteotomy (ZSSO): in this technique the zygomatic arch is isolated from its temporal origin to its zygomatic insertion both on its lateral and medial surfaces. Using a waver sewer, a sagittal full thickness osteotomy of the zygomatic arch is performed (Fig. 26). Later, 2 separate partial thickness osteotomies, one on the arch's osteotomies are connected with the previously released sagittal osteotomy. After correction of the zygomatic arch according to presurgical programs. Stabilization is achieved using bicortical titanium screws (Fig. 26).

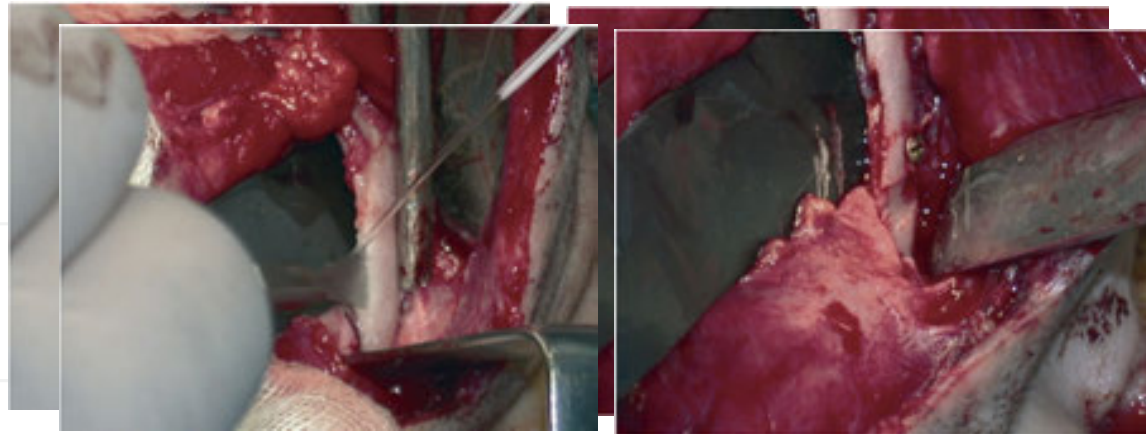


FIGURE 26. Two vertical partial-thickness osteotomies are performed: one on the posterolateral surface of the zygomatic arch and the other on its anteromedial surface. (left) Sagittal full-thickness osteotomy of the zygomatic arch performed with a waver sewer. (right) Stabilization of the osteotomy with bicortical titanium screws. From Gasparini G et al. Zygomatic Sagittal Split Osteotomy: A Novel and Simple Surgical Technique for Use in Midface Corrections. J Craniofac Surg. 2010; Surg. 2010]

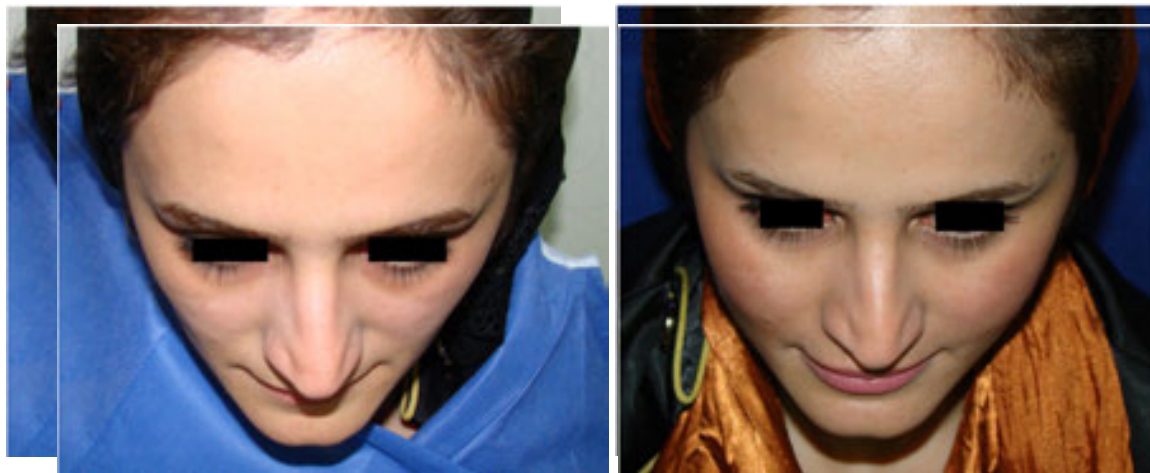

Figure 29. A 32 years woman with malar deficiency, No orthognathic surgery was performed in this case. The patient desired definition of the cheekbones with zygomatic sandwich osteotomy (ZSO) (left) preoperative view, note the triangular shape of she's face; (right) 18 month postoperative view.

5. Frontal modification

Frontal bossing reduction: Frontal Bossing known as a prominent supraorbital region and considers as a masculine characteristic. Generally men have more prominent frontal bossing than women which tends to have a smooth transition from brow area into a forehead. Frontal Bossing patients range from those with craniofacial anomaly such as thalassemias, Crouzon/

apert syndrome, Hurler syndrome to those without any underlying medical problem (figure 28,29). [112]

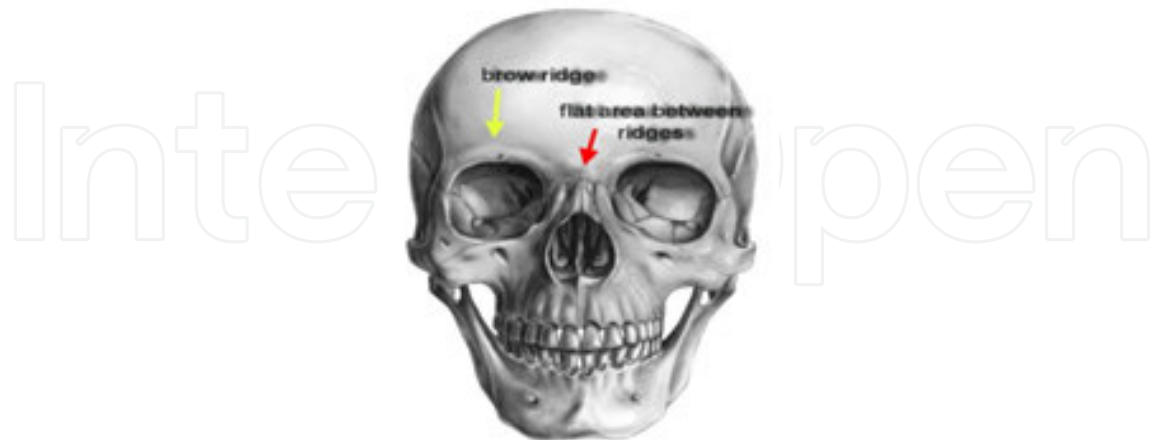


Figure 30. The main difference between male and female foreheads is that males often have a ridge of bone around the upper edge of the eye sockets called the "brow ridge" or "brow bossing". Female foreheads tend to have little or no bossing. Between the ridges of the two eye sockets a flat area can be visible. As women don't have the ridges, also the flat area between them is not present. [from facialfeminization.eu]

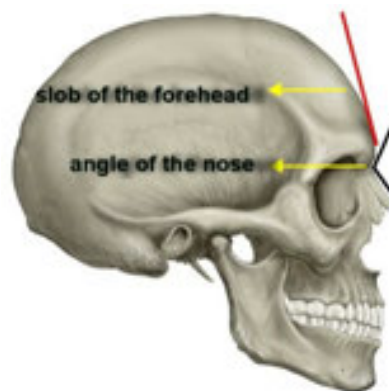


Figure 31. Schematic view of the slob of the forehead. Because of the brow ridge the general angle of the forehead in males (below-right) is steeper and the angle between the forehead and nose is sharper in lateral view. Women, (below-left) because they don't have the brow ridge, have a more vertical appearance of the forehead in lateral view. The angle between nose and forehead is more open. [from facialfeminization.eu]

The most common method of brow bone reduction is an open approach using a bi-coronal flap with either a burring reduction, an infracture technique or osteotomies and reshaping. Simple burring can be effective if the outer table of the brow bone is thick enough.

In the course of normal skull growth, satisfactory reduction of anterior bossing without direct surgical correction of the shape of the forehead can be achieved through sagittal suturectomy along with biparietal barrel stave cuts [113]. More correction of biparietal width and the occipital deformity, on the other hand, may also result in a gradual correction of the frontal

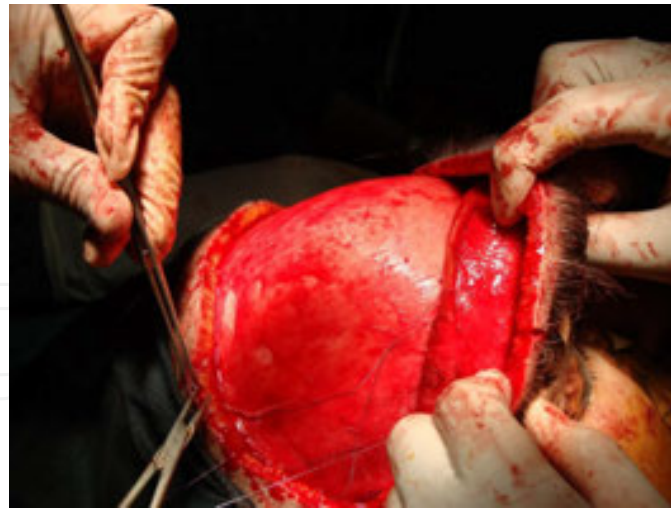

Figure 32. bi-coronal flap.

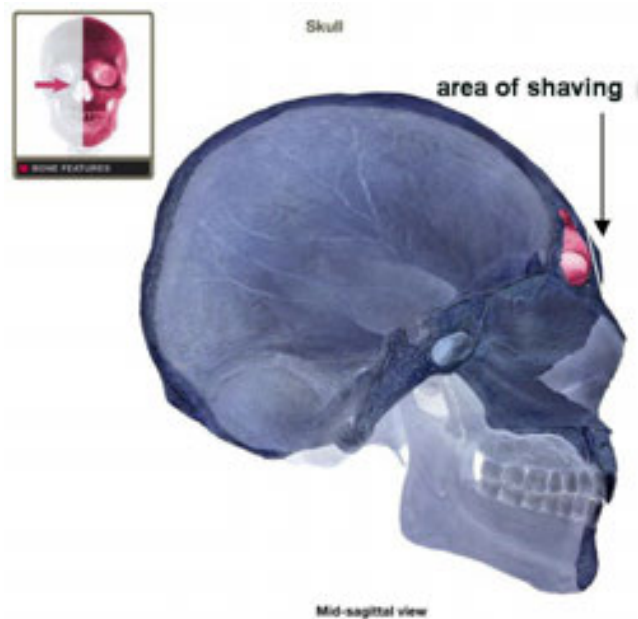


Figure 33. Frontal bossing re-shaping. With the thick bone, the surgeon only has to grind down the bone to the desired level and there will still be plenty of bone left to cover the frontal sinus as you can see. With the thin bone surgeons can't grind it down to the ideal line or very much at all without breaking through into the sinus. In this case, most FFS surgeons will perform a forehead reconstruction so after grinding down what they can, they actually take the wall of bone apart, re-shape it and move it backwards to the desired position. [from www.virtualffs.co.uk]

deformity to satisfactory. In severe cases, however, the natural development of the calvarial shape with physiological skull growth following the described technique will not suffice as a cosmetically compromising frontal bossing will be most likely to persist. In such cases, a direct surgical correction, including radial osteotomies, rotation of bone flaps, "frontal to occipital switch", π -procedure, morcellation, use of distraction or contraction devices, total cranial vault reconstruction, and other techniques have been suggested in the craniofacial literature.[114] The general approach in these techniques includes excision, remodeling, transposition, and

re-insertion of free bone flaps. The direct approach will then require complex bone fixations using wires or plates and screws. More advanced modifications of these techniques to avoid free bone flaps have been discussed where the shortened and re-approximated bone tongues stay attached at their normal calvarial position at the base or the apex of the calvaria. For example, in the technique described by Wagner and Wiewrodt[113] in 2008, following sagittal suturectomy and parietalbarrel stave incisions, four or five lanceolate pieces of the frontal bone are excised resulting in three or four vertical bone bridges. These osteotomies are designed to extend radially from the cranial base towards the fontanel. Small strips rectangular to the apico-basal axis are then cut out from these bridges, leaving basal and apical bone tongues. [113] The tabula externa at the base of the basal tongues is drilled off and the tongues are bent inward to correct the inferior aspect of the frontal bossing. [113]

Corresponding basal and apical bone tongues are then re-approached and fixated with sutures.

The gold standard procedure for correction of severe frontal bossing is still open approach with osteotomy of the anterior table of the frontal sinus which provides excellent outcome. Complications such as long coronal scars, alopecia, blood loss, forehead paresthesia, neuromas and traction palsy of the facial nerve makes this operation invasive, with increased chance of morbidity and less desirable for mild to moderate frontal bossing correction. [112]

Despite the widespread use of endoscopic frontal bone operations such as remodeling of bony defects and removal of osteomas of the frontal bone, only recently has “endoscopic frontal bossing correction” been introduced.[112] This emerging method seems to have rendered frontal bossing correction much simpler, significantly safer, and minimally invasive.

Moreover, the introduction of the endoscope revolutionized the surgical approach to the forehead, as it allowed for smaller incisions, magnified visualization, decreased risk of bleeding, faster recovery, and decreased chance of neuropathy by preserving cutaneous nerves. Endoscopic contouring of the forehead was first described by Song et al. on a Korean woman with frontal bone deformities.[115] Since then, most published endoscopic manipulation of the frontal bone and supraorbital ridge has involved osteoma mass excision or frontal sinus fracture repair. Retrospective reviews of patients receiving endoscopic correction of frontal bossing have shown promising aesthetic results with minimal postoperative morbidity. This method of improving forehead contour, however, should be carried out on properly selected groups of patients. Mild deformities of frontal bossing and adequate bone thickness over the frontal sinus makes patients a great choice for endoscopic frontal bossing correction. [112] Some complications such as neurosensory damage, vascular injury, and extended operative time. [112]. Similarities like incision line and dissection planes for this technique with standard endoscopic forehead lift allows easy access to the frontal bone for contouring in patients with frontal bossing and undergoing concurrent forehead rejuvenation.[112]

6. Summary

The major architectural promontories of the facial skeleton, including the malar-midface region, nose, chin, angle of the mandible and frontal buttress provide the base upon which the

soft tissues of the face drape. By altering these promontories, dramatic changes can be made in the esthetic appearance of the face—much more so than by changing soft tissue and skin alone. Since many years ago numerous surgical and office based techniques have been introduced to augment, reduce or refine the most projected points of the face such as cheek, chin, nose, Para-nasal area, angle of the jaw. When reduction of these esthetic points is planned not only we don't have multiple choices but also without using these methods the precise and predictable correction is almost impossible. In case of augmentation although we have the more options such as soft tissue office based procedures or facial prostheses [110, 111] a precise pre-surgical evaluation in according to patient complaints, social and economic conditions, soft or hard tissue deficiency, amount of augmentation, the past similar procedure, etc. should be considered and the best method for each patient should be selected. Aesthetic adjunct facial osteotomy techniques have proved to be expedient techniques, with low morbidity, producing a controllable and predictable increase or decrease of the facial prominences and stable short and long-term morphological results. The most common complication of esthetic adjunct osteotomy techniques are under-correction and over-correction; pre-surgical evaluation and precise estimation of amount of excess or deficiency is a best method to reduce these complications the relation between hard and soft tissue change is also important, for example the hard tissue to soft tissue ratio in case of advancement genioplasty is almost 1:1 but in case of reduction genioplasty or chin narrowing is almost 1:0.5. Another complication is bad split; although it is a rare complication and often is simple to manage but in cases in whom correction is impossible the best way is internal fixation, close the incision and set another appointment with patient. Other complications such as nerve injury, relapse or severe bleeding is very rare. The more surgeon experience the less incidence of complications.

Acknowledgements

Special thanks to MS. Shahrzad Zojaji and Marjan Golpasha for illustrations.

Author details

Seied Omid Keyhan^{1,2*}, Seifollah Hemmat³, Peiman Mehriar⁴, Arash Khojasteh⁵ and Mohammad Ali Asayesh⁵

*Address all correspondence to: keyhanomid@gmail.com

1 Department of Oral and Maxillofacial Surgery, Shahid Sadooghi University of Medical Sciences, Yazd, Iran

2 Department of Oral and Maxillofacial Surgery, Isfahan University of Medical Sciences, Isfahan, Iran

3 Department of Oral and Maxillofacial Surgery, Bandar Abbas University of Medical Sciences, Bandar Abbas, Iran

4 Department of Advanced Periodontology, University of Southern California, Los Angeles, USA

5 Department of Oral and Maxillofacial Surgery, Shahid Beheshti University of Medical Sciences, Tehran, Iran

References

- [1] Keyhan SO, Khiabani K, Raeisian SH et al. Zigzag genioplasty: patients evaluation, technique modifications and review of the literature. *Am J Cosmetic surg*, 2013; 30(2):80-88.
- [2] Chang E, Lam S, Karen M, Donlevy JL. Sliding genioplasty for correction of chin abnormalities. *ArchFacial Plast Surg*. 2001;3:8-15.
- [3] Troulis MJ, Kearns GJ, Perrott DH, Kaban LB. Extended genioplasty: long-term cephalometric, morphometric and sensory results. *Int J Oral Maxillofac Surg*. 2000;29:167-175.
- [4] Farija R, Valladares S, Aguilar L, Pastrian J, Rojas F. M-shaped genioplasty: a new surgical technique for sagittal and vertical chin augmentation: three case reports. *J Oral Maxillofac Surg*. 2012;70:1177-118
- [5] Satoh K, Onizuka T. A new osteotomy for genioplasty—stepped osteotomy: preliminary report. *Ann Plast Surg*. 1993;31:186-190.
- [6] Thomson ER. Sagittal genioplasty: a new technique of genioplasty. *Br J Plast Surg*. 1985;38:70-74.
- [7] Wang J, Gui L, Xu Q, Cai J. The sagittal curving osteotomy: a modified technique for advancement genioplasty. *J Plast Reconstr Aesthet Surg*. 2007;60:119-124.
- [8] Celik M, Tuncer S, Buyukcayir I. Splitting advancement genioplasty: a new genioplasty technique. *Ann Plast Surg*. 1999;43:148-153.
- [9] Triaca A, Minoretti R, Merz B. Treatment of mandibular retrusion by distraction osteogenesis: a new technique. *Br J Oral Maxillofac Surg*. 2004;42:89-95.
- [10] Grime PD, Blenkinsopp PT. Horizontal T genioplasty: a modified technique for the broad or asymmetrical chin. *Br J Oral Maxillofac Surg*. 1990;28:215-221.
- [11] Li KK, Riley RW, Powell NB, Troell RJ. Obstructive sleep apnea surgery: genioglossus advancement revisited. *J Oral Maxillofac Surg*. 2001;59:1181-118

- [12] Zide BM, Mccarthy J. The mentalis muscle: an essential component of chin and lower lip position. *Plast Reconstr Surg* 1989; 83: 413-20.
- [13] Danahey DG, Dayan SH, Benson AG, et al: Importance of chin evaluation and treatment to optimizing neck rejuvenation surgery. *Facial Plast Surg*,2001;17:91-97,
- [14] Frodel JL: Evaluation and treatment of deformities of the chin. *Facial Plast Surg Clin North Am*,2005; 13:73-84,
- [15] Frodel JL, Sykes JM, Jones JL: Evaluation and treatment of vertical microgenia. *Arch Facial Plast Surg*,2004; 6:111-119,
- [16] Hofer O. Operation der Prognathic und Mikrogenie. *Dtsch Zahn Mund Kieferheilkd* 1942; 9: 81.
- [17] Gillies HD, Millard DR. The principles and art of plastic surgery. Boston: Little Brown, 1957.
- [18] Trauner R, Obwegeser H. The surgical correction of mandibular prognathism and retrognathia with consideration of genioplasty. Part I. Surgical procedures to correct mandibular prognathism and reshaping of the chin. *Oral Surg* 1957; 10: 677-89.
- [19] Hinds EC, Kent JN. Genioplasty: the versatility of horizontal osteotomy. *J Oral Surg* 1969; 27: 690-700.
- [20] Schendel SA. Genioplasty: a physiological approach. *Ann Plast Surg* 1985; 14: 506-14.
- [21] Bell WH, Gallagher DM. The versatility of genioplasty using a broad pedicle. *J Oral Maxillofac Surg* 1983; 41: 763-9.
- [22] Wolfe S. Chin advancement as an aid in correction of deformities of the mental and submental regions. *Plast Reconstr Surg* 1981; 6: 624-9.
- [23] Tessier E Chin advancement as an aid in correction of deformities of the mental and submental regions: discussion. *Plast Reconstr Surg* 1981; 67: 630.
- [24] Behrman S J, Complications associated with orthognathic surgery. In: IRBY WB, ed.: *Current advances in oral surgery*. St Louis: CV Mosby, 1974: 137.
- [25] Mercuri LG, Laskin DM. Avascular necrosis after anterior horizontal augmentation genioplasty. *J Oral Surg* 1977; 35: 296-8.
- [26] Ellis E, Dechow PC, Mcnamara JA,etal. Advancement genioplasty with and without soft tissue pedicle. *J Oral Maxillofac Surg* 1984; 42: 637-45.
- [27] Storum KA, Bell WH, Nagura H. Microangiographic and histologic evaluation of revascularization and healing after genioplasty by osteotomy of the inferior border of the mandible. *J Oral Maxillofac Surg* 1988; 48: 210-6.

- [28] Posnick JC, Al-qattan MM, Sterner NM. Alteration in facial sensibility in adolescents following sagittal split and chin osteotomies of the mandible. *Plast Reconstr Surg* 1996; 97: 920-7.
- [29] Spear SL, Kassan M. Genioplasty. *Clin Plast Surg* 1989; 16:695-706.
- [30] Lindquist CC, Obeid G. Complications of genioplasty done alone or in combination with sagittal split ramus osteotomy. *Oral Surg* 1988; 6: 13-6.
- [31] Conworse JM, Wood-Smith D. Horizontal osteotomy of the mandible. *Hast Reconstr Surg* 1964; 34: 464-71.
- [32] Precious DS. A retrospective study of advancement genioplasty using a special bone plate: discussion. *J Oral Maxillofac Surg* 1992; 50: 347.
- [33] Trimble LD, West RA. Steinman pin stabilization after horizontal mandibular osteotomy. *J Oral Maxillofac Surg* 1982; 40: 461-3.
- [34] Turvey AT, Childers DA, Ntynn DR. Kirshner wire stabilization of the horizontal osteotomy of the inferior border of the mandible. *Oral Surg* 1982; 54: 513-6.
- [35] Schow SR, Stein aM, Cardenas L. Intraoperative control and stabilization of the distal osseous segment in genioplasty. *J Oral Maxillofac Surg* 1995; 53: 481-2.
- [36] Defreitas CE, Ellis E, Sindde A. retrospective study of advancement genioplasty using a special bone plate. *J Oral Maxillofac Surg* 1992; 50: 340-6.
- [37] Polido WN, Declairfont RL, Bell WH. Bone resorption, stability and soft tissue changes following large chin advancements. *J Oral Maxillofac Surg* 1991; 49: 251-6.
- [38] Precious DS, Armstrong JE, Morals D. Anatomic placement of fixation devices in genioplasty. *Oral Surg* 1992; 73: 2-8.
- [39] Edwards RC, Kiely KD, Eppley BL: Resorbable fixation techniques for genioplasty. *J Oral Maxillofac Surg* 58:269-272, 2000
- [40] Dolce C, Hatch JP, Van Sickels JE, et al: Five-year outcome and predictability of soft tissue profiles when wire or rigid fixation is used in mandibular advancement surgery. *Am J Orthod Dentofacial Orthop* 124:249-256, 2003
- [41] Proffit WR, Turvey T, Moriarty J. Augmentation genioplasty as an adjunct to conservative orthodontic treatment. *Am J Orthod* 1991; 79: 473-91.
- [42] Wider TM, Spiro SA, Wolfe SA. Simultaneous osseous genioplasty and melo plasty. *Plast Reconstr Surg* 1997; 99: 1274-81.
- [43] Wolford LM, Bates JD. Surgical modification for the correction of chin deformities. *Oral Surg*.1988; 66: 279-86.

- [44] Uckan S, Soydan S, Veziroglu F, Arman A. Transverse reduction genioplasty to reduce width of the chin: indications, technique, and results. *J Oral Maxillofac Surg.* 2010;68:1432–1437.
- [45] Park S, Noh JH. Importance of the chin in lower facial contour: narrowing genioplasty to achieve a feminine and slim lower face. *Plast Reconstr Surg.* 2008;122:261
- [46] Putnam J, Donovan M. modified reduction genioplasty. *J Oral Maxillofac Surg.* 1989;47:203–205
- [47] Keyhan SO, Khiabani K, Hemmat S, Varedi P. Zigzag genioplasty: a new technique for 3-dimensional reduction genioplasty. *Br J Oral Maxillofac Surg.* 2013;51(8):e317–e318
- [48] Khiabani KH, Keyhan SO et al. Buccal fat pad lifting; an alternative open technique for malar augmentation. *J Oral Maxillofac Surg.* 2014;72(2):e1–e15
- [49] Badri AA, Keyhan SO, Surgical correction of facial skeletal deformity of patients with thalassemia. *Am J Cosmetic surg.* 2014;31(2):107–115
- [50] Herná'ndez-Alfaro F, García E, Martí C, Porta A. U-shaped osteotomy in management of paranasal deficiency. *Int. J. Oral Maxillofac. Surg.* 2006; 35: 1145–1148
- [51] Epker BN. Correction of the skeletal nasal base in rhinoplasty. *J Oral Maxillofac Surg* 1991; 49: 938–946.
- [52] Reyneke JP, Widgerow AD. Nasomaxillary osteotomy for the correction of Binder's syndrome. *Int J Adult Orthodon Orthognath Surg* 1996; 11: 117–126
- [53] Adams JR, Kawamoto HK. Late infection following aesthetic malar augmentation with proplast implants. *Plast Reconstr Surg* 1995; 95: 382–384.
- [54] Berghaus A. Porous polyethylene in reconstructive head and neck surgery. *Arch Otolaryngol* 1985; 11: 154–160.
- [55] Bikhazi HB, Van Antwerp R. The use of Medpor in cosmetic and reconstructive surgery: Experimental and clinical evidence. In: Stucker FJ, ed: *Plastic and Reconstructive Surgery of the Head and Neck*. St. Louis: Mosby 1990: 271–273
- [56] Cohen SR, Kawamoto HK. Infection of proplast malar implants following dental injections. *Plast Reconstr Surg* 1992; 89: 1148–1151.
- [57] Constantino PD, Friedman CD, Lane A. Synthetic biomaterials in facial plastic and reconstructive surgery. *Facial Plast Surg* 1993; 9: 1–15.
- [58] Davis PKB, Jones SM. The complications of silastic implants: Experience with 137 consecutive cases. *Br J Oral Maxillofac Surg* 1971; 24: 405–411
- [59] Frodel JL, Lee S. The use of high density polyethylene implants in facial deformities. *Arch Otolaryngol Head Neck Surg* 1998; 124: 1219–1223

- [60] Morehead JM, Holt GR. Soft tissue response to synthetic biomaterials. *Otolaryngol Clin North Am* 1994; 27: 195–201
- [61] Rubin JP, Yaremchuk MJ. Complications and toxicity of implantable materials used in facial reconstructive and aesthetic surgery: A comprehensive review of the literature. *Plast Reconstr Surg* 1997; 100: 1336–1353.
- [62] Whear NM, Cousley RR, Liew G, Henderson D. Postoperative infection of proplast facial implants. *Br J Oral Maxillofac Surg* 1993; 31: 292–295.
- [63] Yaremchuk MJ, Israeli D. Paranasal implants for correction of midface concavity. *Plast Reconstr Surg* 1998; 102: 1676–1684
- [64] Chow TK, Yu CN, Fung SC. Pyriform rim sandwich osteotomy: A new regional osteotomy for correction of para-alar deficiency. *J Oral Maxillofac Surg* 2004; 62: 256–260
- [65] Haffner CL, Pessa JE, Zadoo VP, et al: A technique for three-dimensional cephalometric analysis as an aid in evaluating changes in the craniofacial skeleton. *Angle Orthod* 1999; 69: 345,
- [66] Hirohi T, Yoshimura K. Lower face reduction with full-thickness marginal osteotomy of mandibular corpus-angle followed by corticectomy. *J Plast Reconstr Aesth Surg*. 2010; 63, 1251-1259
- [67] Baek SM, Kim SS, Bindiger A. The prominent mandibular angle: Preoperative management, operative technique, and results in 42 patients. *Plast Reconstr Surg* 1989; 83: 272-8
- [68] Yang DB, Park CG. Mandibular contouring surgery for purely aesthetic reasons. *Aesthetic Plast Surg*. 1991; 15: 53-6
- [69] Honda T, Sasaki K, Takeuchi M, et al. Endoscope-assisted intraoral approach for masseteric hypertrophy. *Ann Plast Surg* 1997; 38: 9-14
- [70] Kim SK, Han JJ, Kim JT. Classification and Treatment of Prominent Mandibular Angle. *Aesth. Plast. Surg*. 2001; 25: 382–387
- [71] Han K, Kim J. Reduction mandibuloplasty: osteotomy of the lateral cortex around the mandibular angle. *J Craniofac Surg* 2001; 12: 314-25
- [72] Yamanouchi S, Ishihara K, Shirato Y, et al. Facial pattern of the present day Japanese associated with normal occlusion. *J Jpn Orthod Soc* 1995; 54: 93-101
- [73] Layoun W, Guyot L, Richard O, Gola R. Augmentation of cheek bone contour using malar osteotomy. *Aesthetic Plast Surg*. 2003; 27(4): 269-74.
- [74] Choi JY, Lee SH, Baek SH: Effects of facial hard tissue surgery on facial aesthetics: Changes in facial content and frames. *J Craniofac Surg*. 2012; 23: 1683.

- [75] Jones RH, Ching M. Intraoral zygomatic osteotomy for correction of malar deficiency. *J Oral Maxillofac Surg.* 1995 Apr;53(4):483-5.
- [76] Powell NB, Riley RW: Cranial bone grafting in facial aesthetics and reconstructive contouring. *Arch Otolaryngol Head Neck Surg.* 1987; 113:713.
- [77] Powell N, Riley RW, Laub DR: A new approach to evaluation of the malar complex. *Ann Plast Surg.* 1988;30:206.
- [78] Donovan MG: Augmentation of the malar prominence by sagittal osteotomy of the zygoma and interpositional bone grafting, in Bell WH (ed): *Modern Practice in Orthognathic and Reconstructive Surgery*, vol 3. Philadelphia, PA, Saunders, 1992, pp 2298-2304.
- [79] Walji S: Letter to the Editor: Mommaerts MY, Abeloos JVS, De Clercq CAS, et al: The sandwich zygomatic osteotomy. *J Craniomaxillofac Surg.* 1996;24:131.
- [80] Gimenez EJ: Osteotomia de1 hueso malar. *Revista Assoc Odont Argent.* 1973;61:303.
- [81] Mommaerts MY, Abeloos JVS, De Clercq CAS, et al: The “sandwich” zygomatic osteotomy: Technique, indications and clinical results. *J Craniomaxillofac Surg.* 1995;23:12.
- [82] Onizuka T, Watanabe K, Takasu K, et al. Reduction malarplasty. *Aesthetic Plast Surg* 1983;7:121–125.
- [83] Baek SM, Chung YD, Kim SS. Reduction malarplasty. *Plast Reconstr Surg* 1991;88:53–61.
- [84] Sumiya N, Kondo S, Ito Y, Ozumi K, Otani K, Wako M. Reduction malarplasty. *Plast Reconstr Surg* 1997;100:461–7.
- [85] Baek RM, Kim J, Lee SW. Revision reduction malarplasty with coronal approach. *J Plast Reconstr Aesthet Surg* 2010;63:2018–24.
- [86] Kim YH, Seul JH. Reduction malarplasty through an intraoral incision:a new method. *Plast Reconstr Surg* 2000;106:1514–9.
- [87] Lee JG, Park YW. Intraoral approach for reduction malarplasty: a simple method. *Plast Reconstr Surg* 2003;111:453–60.
- [88] Zou C, Niu F, Liu J, Chen Y, Wang M, Su R, et al. midface contour change after reduction malarplasty with modified L-shaped osteotomy: a surgical outcomes study. *Aesthetic plast surg.* 2014;38(1):177-83.
- [89] Chen T, Hsu Y, Li J, Hu J, Khadka A, Wang Q, et al. correction of zygoma and zygomatic arch protrusion in east Asian individuals. *Oral Surg Oral Med Oral Pathol Oral Radiol Endod.* 2011;112(3):307-14.
- [90] Tang K, Hsu Y, Hu J, Zhao Y, Wang Q, Li J. New horizontal v-shaped osteotomy for correction of protrusion of the zygoma and the zygomatic arch in East Asians: indica-

- tion and results. *Br J Oral Maxillofac Surg*. 2014; <http://dx.doi.org/10.1016/j.bjoms.2014.04.016>.
- [91] Nakanishi Y, Nagasao T, Shimizu Y, Miyamoto j, kishi K, Fukuta K. The boomerang osteotomy - A new method of reduction malarplasty *J Plast Reconstr Aesthet Surg* 2012;65(5):111-20.
 - [92] Song WC, Choi HG, Kim SH, et al. Topographic anatomy of the zygomatic arch and temporal fossa: a cadaveric study. *J Plast Reconstr Aesthet Surg* 2009;62:1375-8.
 - [93] Uhm KI, Lew JM. Prominent zygoma in Orientals: classification and treatment. *Ann Plast Surg* 1991;26:164-70.
 - [94] Hwang YJ, Jeon JY, Lee MS. A simple method of reduction malarplasty. *Plast Reconstr Surg* 1997;99:348-55.
 - [95] Kim T, Baek SH, Choi JY. Reduction Malarplasty According to Esthetic Facial Unit Analysis: Retrospective Clinical Study of 23 Cases. *J Oral Maxillofac Surg*. 2014;72(8): 1565-78.
 - [96] Jung H, Lee Y, Doo JH, et al. Prevention of complication and management of unfavorable results in reduction malarplasty. *J Korean Soc Plast Reconstr Surg*. 2008;35:465–470.
 - [97] Hong SE, Liu SY, Kim JT, Lee JH. Intraoral Zygoma Reduction Using L-shaped Osteotomy. *J Craniofac Surg*. 2014;25(3):758-61.
 - [98] Morris DE, Moaveni Z, Lo LJ. Aesthetic facial skeletal contouring in the Asian patient. *Clin Plast Surg* 2007;34:547-56.
 - [99] Whitaker LA. Temporal and malar-zygomatic reduction and augmentation. *Clin Plast Surg* 1991;18:1-4.
 - [100] Hinderer UT. Malar implants for improvement of facial appearance. *Plast Reconstr Surg*.1975;56(2):157-65.
 - [101] Blyer SM. Facial ilants in cosmetic surgery. In: Fonseca RJ, Turvey TA (editors). *Oral and maxillofacial surgery*. Second ed. Missouri: ELSEVIER SAUNDERS;2009.690.
 - [102] Wilkinson TS. Complications in esthetic malar augmentation. *Plast Reconstr Surg*. 1983;71:643.
 - [103] Prendergast M, Shoenrock LD. Malar augmentation. Patient classification and placement. *Arch Otolaryngol Head Neck Surg*. 1989;115(8):964-9.
 - [104] Stuzin JM, Wagstrom L, Kawamoto HK, et al. The anatomy and clinical applications of the buccal fatpad. *Plast Reconstr Surg* 1990;85(1):29– 37.
 - [105] Bettens RMA, Mommaerts MY, Sykes JM. Aesthetic malar recontouring: the zygomatic sandwich osteotomy. *Facial Plast Surg Clin N Am*. 2002;10: 265–277.

- [106] Li KK. Discussion, six years' experience with the zygomatic "sandwich" osteotomy for correction of malar deficiency. *J Oral Maxillofac Surg.* 1999;57:14 – 5.
- [107] Lorenz HP, Schendel SA. Facial bone sculpturing. In: Ward-Booth P, Hausamen JE, Schendel SA, editors. *Maxillofacial surgery*, vol 2. London: Churchill Livingstone; 1999. pp. 1441– 56.
- [108] Mommaerts MY, Nadjmi N, Abeloos JVS, et al. Six years experience with the zygomatic sandwich osteotomy for correction of malar deficiency. *J Oral Maxillofac Surg.* 1999;57:8–13.
- [109] Gasparini G, Saponaro G, Moro A, Boniello R, Cervelli D, Pelo S. Zygomatic Sagittal Split Osteotomy: A Novel and Simple Surgical Technique for Use in Midface Corrections. *J Craniofac Surg.* 2010;21(6):1872-5.
- [110] Keyhan SO, Badri AA, Hemmat S ET AL. Use of platelet-rich fibrin and platelet-rich plasma in combination with fat graft: which is more effective during facial liposuction? *J Oral Maxillofac Surg.* 2013;71 (3), 610-621
- [111] Khiabani K, Keyhan SO, Hemmat S. Buccal Fat Pad Lifting: An Alternative Open Technique for Malar Augmentation. *J Oral Maxillofac Surg.* 2014;72 (2), 403. e1-403. e15
- [112] Guyuron B, Lee M, Larson K, Amirlak B. Endoscopic correction of frontal bossing. *Plastic and reconstructive surgery.* 2013 Mar;131(3):388e-93e.
- [113] Wagner W, Wiewrodt D. A simple technique for the correction of frontal bossing in synostotic scaphocephaly. *Child's nervous system : ChNS : official journal of the International Society for Pediatric Neurosurgery.* 2008 Mar;24(3):373-7.
- [114] Alvarez-Garijo JA, Cavadas PC, Vila MM, Alvarez-Llanas A. Sagittal synostosis: results of surgical treatment in 210 patients. *Child's nervous system : ChNS : official journal of the International Society for Pediatric Neurosurgery.* 2001 Jan;17(1-2):64-8.
- [115] Song IC, Pozner JN, Sadeh AE, Shin MS. Endoscopic-assisted recontouring of the facial skeleton: the forehead. *Annals of plastic surgery.* 1995 Mar;34(3):323-5

