

We are IntechOpen, the world's leading publisher of Open Access books Built by scientists, for scientists

6,900

Open access books available

186,000

International authors and editors

200M

Downloads

Our authors are among the

154

Countries delivered to

TOP 1%

most cited scientists

12.2%

Contributors from top 500 universities



WEB OF SCIENCE™

Selection of our books indexed in the Book Citation Index
in Web of Science™ Core Collection (BKCI)

Interested in publishing with us?
Contact book.department@intechopen.com

Numbers displayed above are based on latest data collected.
For more information visit www.intechopen.com



Endoscopic Explanation of Unexplained Infertility

Atef M. Darwish

Additional information is available at the end of the chapter

<http://dx.doi.org/10.5772/59948>

1. Introduction

1.1. Dilemma of definition of Unexplained Infertility (UI)

Infertility is a continuous challenge for all gynecologists worldwide. Unexplained infertility (UI) is infertility in which the cause of the fertility impairment cannot be detected by use of standard diagnostic measures like semen analysis, tests for ovulation and tubal patency. It remains a clinical and scientific challenge [1]. Unexplained infertility is a source of anxiety for couples desiring pregnancy. It can be diagnosed after a complete evaluation [2]. The Practice Committee of the American Society for Reproductive Medicine (ASRM) has published guidelines for a standard infertility evaluation [3]. UI does not mean there is no physical explanation for the infertility, but that is just, medical tests have not identified any specific problems [4, 5]. A quarter of infertility range (25%) cannot be explained because of current tests are not perfect in finding all problems., the problem preventing pregnancy is not covered by the usual range of tests for assessing infertility, or causes which are not yet understood by scientists [4]. In the past decades, tremendous advancement in the field of infertility has been made. The development of better methods of diagnosis due to better understanding of physiology of ovulation, advent of ultrasound, endoscopy and other modern equipments have changed the whole approach to this problem. [6]. Possible Etiologies for UI may include hostile cervical mucus [7], subtle ovulatory dysfunction [8], luteal-Phase Defect [9], impaired fertilizing ability of oocytes specially when associated with raised LH levels, hyperprolactinemia [10], sperm dysfunction and antisperm Antibodies (151endometrial Steroid receptor defects [12], some genetic [13], psychological [14] or immunological Causes [15]. Prospective studies appear to have clearly demonstrated the substantial importance of even minimal endometriosis, which has been shown to be associated with impaired fertilization ability of oocyte and presumably impaired follicular function. Changes in the intraperitoneal environment leading to an inflammatory process in the absence of visible abnormalities have been suggested as

being causal in some cases of unexplained infertility [11]. Scientific curiosity must take second place to a more pragmatic approach, which takes into account the clinical and financial costs of making a more accurate diagnosis [5]. Laparoscopy is generally accepted as a good standard for diagnosing tubal pathology or other pelvic reproductive diseases, such as adhesions and endometriosis. Once identified, appropriate surgical treatment can be given, enhancing the chance of spontaneous conception. Furthermore, in cases with poor prognosis, laparoscopy could accelerate the commencement of (IVF), bypassing unnecessary cycles of ovulatory stimulation with or without intrauterine insemination [16].

1.2. Is it logic to omit laparoscopy and hysteroscopy from the definition of UI?

There is a general consensus among gynecologists that tubal patency at HSG is quite assuring about tubal factor and they proceed to investigate other factors or advise patients to try assisted reproduction. On reviewing literature, Kahyaogla [17] found that laparoscopy can be omitted if there is no risk factor for pelvic pathology while it is recommended if suspected endometriosis or tubal pathology. Likewise, Bonneau et al. [16] examined 114 cases with UI by laparoscopy and detected abnormalities in 83.4% (n=95) of patients. More and more studies in addition to our day practice experience prefer to include laparoscopy and hysteroscopy in the evaluation of cases with UI. We believe that diagnostic laparoscopy is an integral step of the diagnostic work-up of any infertile couple before saying the term “unexplained”. Laparoscopy can demonstrate previously undetected stage I or II endometriosis or periovarian or peritubal adhesions in a substantial proportion of women. Detection of these abnormalities may result in alternative treatment plans, such as surgery for endometriosis or direct referral to an IVF program if there are peritubal adhesions. The following factors would affect implication of laparoscopy as a routine test in all cases of UI including the availability of resources, the risk associated with laparoscopy, the knowledge that laparoscopy demonstrates abnormalities not otherwise detected by other infertility tests, and laparoscopic treatment of minimal and mild endometriosis enhances fecundity.

1.3. When to perform endoscopy?

Timing of performing combined laparoscopy and hysteroscopy for cases of UI is a controversial issue as well. In one study, they recommended that transvaginal hydrolaparoscopy and minihysteroscopy can be performed after a waiting period of 6-12 months in older women and particularly in women experienced infertility awareness methods [18]. In our practice, timing is a matter of individualization. If you have a patient with a persistent TVS abnormality that requires Endoscopic assessment, it is a waste of time to defer the decision. This decision is of high importance particularly if all other possible causes were excluded.

1.4. Current role of gynecologic endoscopy in UI

Including laparoscopy and hysteroscopy as a basic investigation for cases of UI would be expected to detect the following:

- Missed fallopian tubal causes.

- Hidden intrauterine infections.
- Missed ovarian causes.
- Missed intrauterine causes.
- Exploration of the fertilization site.
- Exploration of the implantation site.

2. Missed Fallopian tube abnormalities

Tubal factor infertility accounts for nearly one-quarter of all cases of infertility [19]. The fallopian tubes may be abnormal in structure or function. Structural disorders can block the fallopian tubes. They include tubal scarring or blockage most commonly from pelvic infections, prior abdominal surgeries and endometriosis. Practically, many gynecologists are reluctant when reporting on diagnostic laparoscopy. Some perform a single puncture intraumbilical procedure that neglects an auxillary portal for proper grasping of the adnexa and thorough evaluation of the ovarian fossa. Most of them comment on tubal patency only and neglect tubal morphology, size, length and proximity to the pouch of Douglas. Rarely, they comment on the mesosalpinx and Wolffian duct remnants.

2.1. What is the normal fallopian tube? It is a complex organ that should be

- Open with intact endosalpinx.: a patent tube per se is not a grantee that the tube is OK.
- Adequate length to reach the pelvic floor.
- Mobile to reach the site of released egg and to create a negative pressure in itself.
- Fimbria should be normal and freely mobile to direct the egg towards the tubal ostium.

3. Role of Hydatid of Morgagni in UI

The recommendations of all societies define UI after a free tubal patency test. They didn't define which test. One of the great advantages of diagnostic laparoscopy is proper visualization of the genital organs and the pelvis. Some Wollfian duct vestigial remnants could be easily seen by laparoscopy like Hydatif of Morgagni and paratubal cysts and of course are not visible by HSG.

Hydatid of Morgagni is commonly underestimated finding even by expert laparoscopists. Tubal heaviness, possible fimbrial occlusion and restricted tubal mobility hindering ovum pick-up from the pouch of Douglas are possible mechanisms of infertility. Whether they are definite cause of infertility or not was studied in a randomized study [20]. They recruited a total 455 patients. The 240 of them were pregnant to whom planned cesarean section (C/S) and

the other 215 were infertile one who have undergone diagnostic laparoscopy. Fertile Group (Group 1) consisted of women whom have become spontaneously pregnant without any kind of infertility management. These are planned to undergo C/S with different indications. Infertile group (Group 2) consisted of women diagnosed as unexplained infertility and planned to undergo diagnostic laparoscopy according to ASRM 2006 guidelines. The frequency, number, and the bilaterality of the MH were evaluated during the C/S in fertile group and diagnostic laparoscopy in infertile group. SPSS was used for statistical analyses. The Morgagni hydatids (MH) frequency was higher in Group 2 than Group 1 ($P < 0.05$). The bilaterality of MHs was significantly higher in Group 2 than Group 1 ($P < 0.05$). The number of the MHs was significantly higher in Group 2 than Group 1 ($P < 0.05$). They concluded that these findings suggest a possible effect of MH on fertility. The theory of MH disturbing tubal motility with respect to the pick-up and transport of ovum appears logical in this aspect.

Another non-randomized study [21] was conducted on two hundred and thirteen patients with unexplained infertility and hydatid of Morgagni diagnosed at laparoscopy were included. The laterality (bilateral vs unilateral), location (fimbrial vs juxta-fimbrial), number (single vs multiple) and diameter of the hydatids of Morgagni were recorded. Patients were allocated to a study group ($n=127$) who underwent laparoscopic excision of hydatid of Morgagni and a control group ($n=86$) who underwent no intervention. Patients were followed for six months without any infertility or hormonal treatment to detect spontaneous pregnancy. Patients missed during the follow-up or who received infertility treatment was excluded. Statistical analysis was done using Chi-square test and Student's t-test. To find the most important character of hydatid of Morgagni which impedes pregnancy, logistic regression analysis of the dependent variable (no pregnancy) and independent variables (different characters of hydatid of Morgagni) was carried out in the control group. Hydatid of Morgagni was detected in 52.1% of patients with unexplained infertility compared to 25.6% of those with explained infertility ($p < 0.001$). The pregnancy rate was higher in the study group than the control group (58.7% vs 20.6%, $p < 0.001$). The pregnancy rate was significantly higher in the study group than the control group if the hydatid cyst was bilateral (85.7% vs 5.3%, $p < 0.001$), fimbrial (85.6% and 9.1%, $p < 0.001$), single (57.6% and 30.3%, $p < 0.001$) or 1-2 cm in diameter (58.1% and 25.5%, $p < 0.001$). Logistic analysis showed that the bilaterality and fimbrial location of the hydatid of Morgagni were the most significant characteristics impeding pregnancy (odds ratio=7.27 and 3.67 respectively). They concluded that Hydatid of Morgagni is a possible underestimated cause of unexplained infertility. Laparoscopic removal of hydatid of Morgagni in patients with unexplained infertility was followed with a high spontaneous pregnancy rate. This is particularly obvious with bilateral and fimbrial hydatid of Morgagni.

4. Undescended tubes

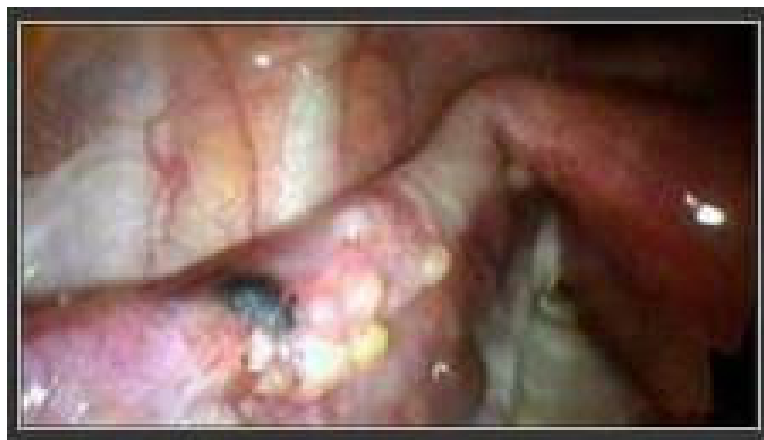Sometimes during laparoscopy you may notice that the tubes are congenitally nearer to the lateral pelvic wall or even adherent to it. By this way, the tubes are expected to be out of function due to the wide distance between the fimbria and the pouch of Douglas. It is commonly seen with some Mullerian duct anomalies.

4.1. Subtle tubal endometriosis

These lesions are only seen by laparoscopy which may include: tubal sacculations. Diverticulae [22], convolutions, phimosis, fimbrial agglutination or other subtle lesions (red, white or vesicular lesions).

4.2. Typical tubal endometriosis

Black or blue lesions could be seen on the surface of the fallopian tube. It may affect tubal motility, may cause tubal constriction or even occlusion. Generally, there is low fecundability rate in such cases. Laparoscopic coagulation would lead to fibrosis and subsequent constriction. No clear publication on this point found in literature so far.



4.3. Role of tubal functions in UI

To achieve pregnancy, in addition to patency, two paradoxical types of peristaltic movements occur in the tubes. Muscular contractions of the distal part of tube and the cilia of its inner lining move the egg toward the interstitial segment of the tube which acts like a muscle sphincter and prevents the egg from being released into the uterus until it is ready for implantation. On the other hand, the proximal part of the tube expresses peristalsis to attract sperms to the site of implantation [23,24]. To date, tubal perstalsis and antiperstalsis are not well understood. Some invitro 3D studies were recently published but did not fully explain these complicated tubal phenomena [25]. Office hysteroscopy (OH) is a modern diagnostic tool with expanding popularity all over the world [26]. Adding vaginoscopic approach to office hysteroscopy is an extra simplification of the procedure with elimination of pain during examination [27].

4.4. New horizons for tubal patency detection

Since a long time, HSG is the classic tubal patency test. Lipiodol HSG has been shown to increase pregnancy rate which may be attributed to tubal patency or endometrial stimulation with possible enhanced receptivity of the endometrium to embryo implantation even in

women with history of endometriosis [28,29]. Nevertheless, due to its well known drawbacks and complications (mainly pain), many women are afraid of doing HSG. Trials to improve its performance were described as elimination of traction on the cervix by tenaculum or usage of a pediatric Foley's catheter instead of the standard metal cannula [30] but still low patient acceptability of this invasive procedure is encountered. Saline infusion sonography (SIS) is an attractive alternative to HSG as it is a methodologically simple, cost effective, and time efficient comprehensive evaluation [31]. In 1999, we described a simplified technique of SIS utilizing a simple Nelaton catheter and 0.09% saline [32]. Despite its wide spread usage in many clinics, the main drawbacks of SIS are failure to localize the side of tubal patency and failure to properly visualize the tubes. Trials to improve results of SIS included the use of gel foam instead of saline [33], use of B-flow ultrasonography [34], 3D ultrasonography [35] or even sophisticated automated ultrasonography [36]. In the era of evidence-based medicine, Rubin perturbation tubal patency test is no longer implemented in modern practice [37] because it is very subjective and non-specific.

Definitely, hysteroscopy is the star of gynecologic endoscopy in recent years due to extended indications in modern practice. This position can be attributed to many factors including more technical refinement of instrumentation with better illumination and magnification, increased IVF/ICSI cycles practice and failures, increased interest in studying uterine factor of recurrent pregnancy loss (RPL), office usage with smaller caliber endoscopes omitting hospital admission, and increased product promotion. Most important, vaginoscopic approach with elimination of speculum insertion and traction on the cervix with a tenaculum had made hysteroscopy as simple as vaginal examination with high patient acceptability as shown in this study. OH saves money, omits stress for the patient, and improves health care services for the community at large. We believe that this attractive tool is not designed just to explore the endometrial cavity. The hysteroscopist should systematically examine the vagina, ectocervix, endocervical canal, endometrial cavity as well as the tubal ostia. Many tubal causes of infertility can be easily detected from the endometrial cavity like polyps, fine adhesions or occlusion. These advantages are offered to the patient with minimal costs unlike other sophisticated and expensive approaches. For instance, MRI guided HSG was proved to be an effective patency test [38] but the costs and complicity of the technique are against the office principles.

Interest in hysteroscopic testing of tubal patency testing is not new. Hysteroscopic perturbation utilizing a fine catheter inserted into the tubal ostia followed by injection of methylene blue dye had been described [39]. If no reflux was seen, this means that the ostium was patent.

Unfortunately, they changed a simple office procedure into a complicated operation. They used a 5.5 mm operative bridge that would definitely increase pain. They used fine catheters and evaluated patency in a very subjective way without laparoscopic or even sonographic confirmation. Non-reflux of the dye doesn't necessarily mean patency. Intravasation or false passage due to unintentional perforation could be the cause. In short, their approach is similar to hysteroscopic tubal cannulation but in a blind manner without laparoscopic or sonographic monitoring.

On the other hand, hysteroscopic bubble suction test addressed in this study is a unique additional rapid costless step which could be done in every OH. What's new is to direct the attention of the hysteroscopist to its value. Not only did this study prove tubal patency, but it also clearly demonstrated an important tubal function which is tubal suction of sperms to the ampulla for fertilization which is mostly attributed to peristalsis of the proximal tube. This comes in accordance with recent interest in studying tubal function rather than just patency [40]. It should be mentioned that we didn't inject air into the tubal ostia but just observed tubal suction of the bubbles by the proximal part of the tube. Performing the procedure postmenstrual (with less vascular completely healed endometrium) together with the generation of minimal bubbles (that could pass through tubal ostia) and when needed slow injection of less than 2 ml of air (inside the bulb of the infusion device and not the tube) almost eliminate any risk of air embolism [41].

Two important issues that would compromise this test should be highlighted. The effect of increased intrauterine pressure was not responsible for positive bubble suction as we observed bubble suction after a while following uterine distension in a periodic manner despite keeping the same intrauterine pressure all the time and no suction occurred in some cases despite increased pressure up to 200 mmHg. The second issue is the possible effect of negative intrauterine pressure which is again excluded by observing bubble suction after a while of uterine cavity distension.

In this study, tubal block (even after increasing pressure into 200 mmHg) was suspected in 11.5% of women examined by OH (out of 76 women). Tubal block in the same set of women was found in 7.2% when examined through laparoscopy. There was some overestimation towards OH that may be attributed to subjective errors or tubal spasm. OH reports thick adhesions related to the proximal tubal end in 6 women (3.9%). Regarding other tubal abnormalities, normal laparoscopy was found to yield no abnormalities in HSG in 97% of cases while abnormal laparoscopy is found to meet with only 54.5% of abnormal HSG.

When OH is combined with HSG, diagnostic indices for tubal block were lowered rather than improved. This can be explained by that both OH and HSG diagnosed all the cases of tubal block with 100% sensitivity, adding both methods to each other didn't add to the strength of the detection. Contrarily, the false positive rates of the 2 methods add to each other and slightly decrease the diagnostic accuracy. The degree of agreement between OH and laparoscopy in evaluation of tubal patency was also quite interesting. Small sample size is a clear drawback of this study. From this study, it is concluded that hysteroscopic bubble suction test is a costless, feasible and tolerable provisional test for tubal patency that should be attempted in every OH done for infertile women. Observation of movement of the peritubal bulge during bubble suction suggesting tubal peristalsis is interesting but requires more confirmatory studies.

5. Missed mesosalpingeal lesions

Mesosalpingeal lesions are perfectly seen by laparoscopy particularly if the lesion is small. They may include:

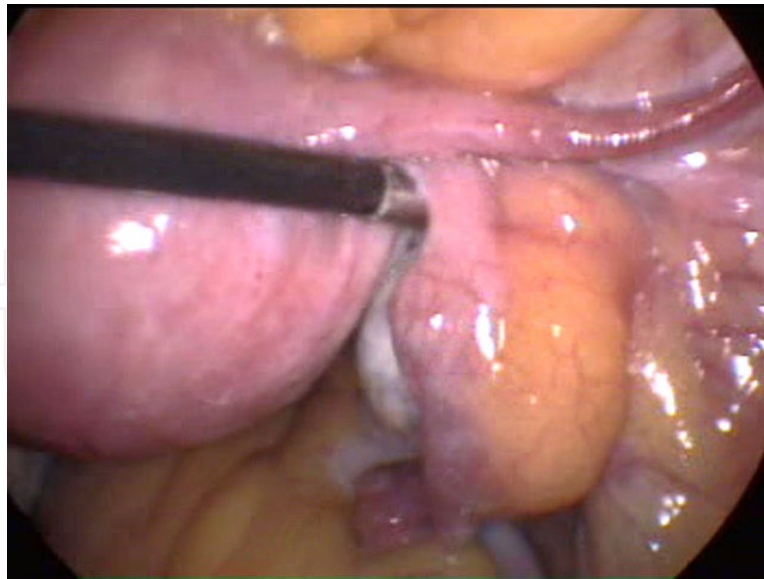
5.1. Paratubal cyst (Darwish et al., 2005) [42]

We constructed a study to define the proportion, methods of diagnosis and a simplified laparoscopic technique for treating paratubal and paraovarian cysts in a prospective cross-sectional study done at the Gynecologic Endoscopy Unit, Assiut University Hospital, Assiut, Egypt. It comprised a total of 1853 patients submitted to video-assisted laparoscopy. Transvaginal ultrasonography (TVS) was done in all cases to detect a paratubal or paraovarian cyst. Tubal shape and patency were evaluated using hysterosalpingography (HSG) in the infertile group. Diagnostic laparoscopy was done to confirm the diagnosis of paratubal or paraovarian cyst. Small cysts were punctured and coagulated, while larger cysts required cystectomy and extraction of the cysts using bipolar electrosurgery. Cystectomy was preceded by endocystic visualization in all cases. Laparoscopically, only 118 patients (15.7%) were proved to have paratubal or paraovarian cysts. Preoperatively, TVS was able to diagnose paratubal or paraovarian cysts in 52 cases (44%) of them. Cysts less than 3 cm in size (34 cases) were treated with simple puncture and bipolar coagulation of the cyst wall whereas larger cysts (84 cases) were treated by cystectomy. Endocystic visualization using the 4-mm rigid hysteroscope was done in 84 cases (71%) with big cysts. There was statistically significant improvement of tubal patency after laparoscopic management. We concluded that sonographic diagnosis of the not uncommon paratubal and paraovarian cysts is not always feasible and requires more awareness and accuracy. The characteristic laparoscopic differentiation from ovarian cysts is the crossing of vessels over it. Endocystic endoscopic visualization is a valuable simple step prior to cystectomy. Bipolar coagulation or extraction of these cysts diagnosed at laparoscopy is easy and not time consuming and should be routinely done in all cases following the microsurgical laparoscopic principles. The significant effect of paratubal cystectomy on tubal patency and mobility supports the concept of routine removal of any paratubal or paraovarian cyst discovered at laparoscopy. Additional value of removal of these cysts detected at laparoscopy is exclusion of the rare possibility of malignancy (2-3%) and obtaining sufficient tissues for histopathologic evaluation. Lastly, its extraction is relatively easy and less time consuming unlike ovarian cystectomy.

5.2. Lipomesosalpnix

The classic tubal factors include post-inflammatory peritubal adhesions, prominal or distal tubal occlusion [43] which can be easily diagnosed by most gynecologists based on HSG. Other rare tubal diseases are seldom investigated. For instance, salpingitis isthmica nodosa which is a nodular swelling of the isthmus segment of the fallopian tube are rarely reported [44]. Anatomically, mesosalpnix is defined as the part of the broad ligament enclosing a fallopian tube forming its mesentery. Histologically, it is formed of a thin layer of squamous epithelium and a small amount of loose areolar connective tissue [45,46]. It contains sympathetic ganglia and plexuses [47]. Laparoscopically, mesosalpnix is a thin vascular layer without evident fat in most cases.

With time interest to discover minute lesions that may affect fertility increased at our institution [42]. In practice, we observe some fatty tissue condensation in the mesosalpnix in some cases that deserved studying why it is present in some women. To make this study valuable,



we considered mesosalpngeal adipose tissue significant if its caliber was at least similar or exceeds the caliber of the ampulla of the ipsilateral fallopian tube regardless the appearance of its borders.

We constructed a study to estimate the proportion of a significant mesosalpngeal adipose tissue condensation (lipomesosalpnix, at least of a caliber similar to the ampulla of the ipsilateral tube regardless with well-defined or poorly defined margins) among infertile women subjected to diagnostic laparoscopy. It was a cross sectional study done at a specialized endoscopic center. It comprised all infertile women scheduled for diagnostic/therapeutic laparoscopy during the period between July 1994 and December 2012 were included in this study. Preoperative hysterosalpingography (HSG), transvaginal ultrasonography (TVS) as well as body mass index (BMI) for all cases. Laparoscopic documentation of a significant mesosalpingeal condensation of adipose tissue. Histopathologic assessment of the adipose tissues in some cases. Main outcome measures included number of cases with unilateral or bilateral lipomesosalpnix. Significant lipomesosalpnix was diagnosed in 145 cases (5.7%) out of 2563 cases examined by laparoscopy. In all but 7 cases, lipomesosalpnix was seen bilaterally (99.7%). There was insignificant correlation between those cases and high BMI when compared to the rest of cases. Infertility was unexplained by laparoscopy in 621 cases (24.3%) while laparoscopy diagnosed etiologic factors in 1942 (75.7%) cases. Lipomesosalpnix was seen in 46 (7.4 %) and 79 (3.9%) of the unexplained cases and explained cases respectively without a statistically significant difference ($P=0.48$). We concluded that despite being a rare laparoscopic finding, significant lipomesosalpnix should be reported and documented as a possible missed tubal factor of infertility. Whether to treat lipomesosalpnix or not, bilaterally or unilaterally and by which means require further studies with proper second look laparoscopy.

This study directs attention towards more concentration on some factors that would affect tubal motility and commonly missed by gynecologists. Previously, some authors reported on Hydatis of Morgagni as a cause of UI [21]. Likewise, an old study [48] diagnosed fimbrial agglutinations (25%), accessory tubes (13%), accessory ostia (10%), phimoses (13%), and

sacculations (7%) more in the infertile women. Tubal abnormalities would affect the prognosis of natural pregnancy as well as assisted reproduction [49, 50]. At our institution, we consider tubal sacculations, diverticulae, convolutions, phimosis or fimbrial agglutination as laparoscopic criteria of subtle tubal endometriosis specially if seen with other typical or atypical endometriotic tubal or peritoneal lesions. Proper endoscopic training would eliminate all these mistakes that would affect diagnosis as well as therapy.

Mesosalpingeal lesions include paratubal cyst [42], leiomyosarcoma of the broad ligament [51], Choristoma of Heterotopic Adrenal Tissue [52], primary Fallopian Tube Carcinoma [53] or lipoma of the Broad Ligament [54]. Precisely, among 1853 cases subjected to laparoscopy, we succeeded to diagnose a paratubal or paraovarian cyst in 118 patients (15.7%) [42]. Fat condensation in the mesosalpinx is not described in text books on histology, pathology or even endoscopic surgery as far as I know. Due to our interest in missed factors of infertility we tried to study the clinical significance of lipomesosalpinx. To be practical, we excluded cases with small amount of adipose tissue that wouldn't expect to affect tubal motility. In this study, preoperative TVS failed to diagnose lipomesosalpinx in all cases. Fallopian tubes are not usually visualized on a routine transvaginal sonographic examination unless outlined by fluid. However, the interstitial segment may be identified on TVS as an echogenic line arising from the endometrial canal and extending through the uterine wall. When surrounded by intra-peritoneal fluid, the remaining segments of the fallopian tubes are commonly seen as tubular structures extending between the uterus and the ovaries. Fallopian tubes are best visualized on sonography when thickened or fluid-filled as a result of pelvic inflammatory disease, torsion, ectopic pregnancy, or tumors [55]. Nevertheless, we still recommend performing TVS routinely prior to laparoscopy to detect important findings like paraovarian cysts [42] and more importantly intrauterine lesions that would make concomitant hysteroscopy a mandatory step.

Despite similarity of the histopathologic appearance of lipomesosalpinx to any adipose tissue in the body, failure to prove any correlation between lipomesosalpinx and obesity would support screening for lipomesosalpinx in all infertile women.

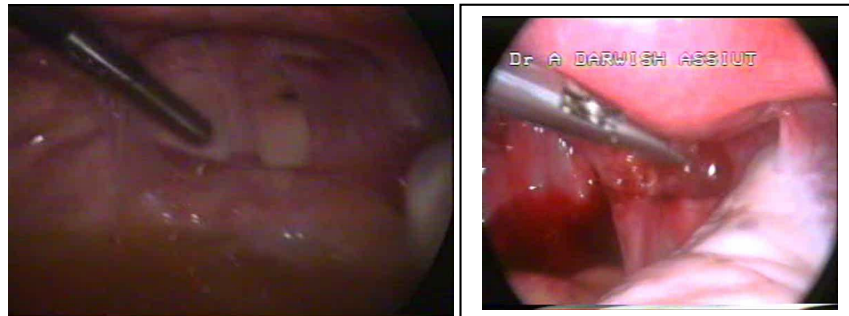
To date, there is no uniform definition for unexplained infertility (UI) [56]. With the marvelous advancement in illumination and magnification, endoscopy would add a lot for the diagnostic work-up for cases with UI. The findings of this and our previous [42] studies would support the central role of dual endoscopy (combined laparoscopy and hysteroscopy) in all cases of infertility despite not being clearly stated by most of the infertility-interested societies when defining UI. One of the promising and attractive options for evaluation of subtle tubal and mesosalpingeal lesions is hydrolaparoscopy which offers a comparable accuracy to laparoscopy in 96.1% of cases [55].

Despite being described since a long time [57], the impact of fatty condensation of the mesosalpinx on fertility is not yet studied so far and this is the first study in English literature to address this point and to report it in 5.7% of infertile women. Lipomesosalpinx would theoretically affect tubal motility and more importantly leads to failure to reach the pouch of Douglas for ovum pick up despite being a patent tube. Nevertheless, the results of this study failed to prove a positive correlation between lipomesosalpinx and unexplained infertility.

This calls for a more large sample sized multicentric study. The main value of this study is to direct attention to mesosalpneal lesions that would affect fertility.

6. Hidden Douglas pouch abnormalities

Douglas pouch is the site of ovum pick-up by the healthy fimbria. Sometimes, hidden factors contributing to infertility are seen in it. One of the best examples is subtle endometriosis which leads to changing environment and may hinder fimbrial pick up. One of the interesting laparoscopic findings is to see and cut fine adhesions that definitely affect ovum pick up. Such fine tiny lesions couldn't be seen by HSG. Practically, proper access to the pouch of Douglas can be aided by using a uterine manipulator with extreme anteversion of the uterus.



7. Uterovesical pouch abnormalities

Not uncommonly in post-cesarean section patients, we notice a thick central band between the uterus and the anterior abdominal wall attracting the uterus anteriorly causing severe anteversion. By this way infertility may occur due to relative shortening of the tubes as they will be far from the pouch of Douglas despite being completely healthy. The job of the laparoscopist in such cases is to cut this band to allow the tubes for proper function. One of the practical tricks, to know proper lysis is to test the level of the cervix by vaginal examination. Easy traction of the cervix is a good parameter of success. Moreover, the laparoscopist should look at the fimbrial relation to the pouch of Douglas. Care should be exerted to avoid bladder injury which can be easily induced particularly if a broad band with dense sealing is seen.

8. Role of Bacterial Vaginosis (BV) and the implementation of laparoscopy in these cases

We believe that occult infections are important explanation of UI particularly in patients who are unable to clearly give a history to explain a source for their tubal adhesions. BV infection

was reported as a significant association with infertility and its proper treatment had lead to pregnancy, emphasizing the value and clinical implication of its screening and treatment [58]. It is hypothesized that immunity to infection might be correlated to sperm rejection in women with positive BV, leading to infertility [59]. On the other hand, low prevalence of BV (4.2%) was reported in a population of women undergoing in-vitro fertilization/embryo transfer (IVF-ET) where 331 infertile women were selected [60]. Variable results of many studies on the prevalence of BV among infertile women particularly UI were one of the main indications to construct a prospective study. Its aim was to estimate the prevalence of bacterial vaginosis (BV) among women with unexplained infertility (UI) and to describe laparoscopic appearances in positive cases. It was a prospective cross sectional comparative observational study done in a tertiary care referral facility and University hospital. It comprised one hundred and fifty women divided into UI study group (120 cases) and a control group (30 cases). Vaginal and cervical swabs form two subgroups of the UI group (60 cases each) and vaginal swabs from control group (30 cases). All swabs were tested using Amsel's criteria then cultured. Thereafter, UI group (60 cases) was subjected to diagnostic laparoscopy. Main outcome measures were the prevalence of BV among women with UI and laparoscopic findings among positive cases. In the study group, the number of positive cases of BV confirmed by culture was 51 cases (42.5 %) while it was diagnosed in only 3 cases (10%) in group B (p value 0.0001). BV was positive in 24 and 27 cases with periods of infertility less than and more than 3 years respectively and in 39 patients (32.5%) with recurrent vaginitis without statistical significance. There was an insignificant difference in diagnosis of BV whether the site of sample is vagina or cervix. Positive laparoscopic findings were reported in 77 patients (64.2 %). The most common laparoscopic abnormalities were hyperemic uterus and chronic salpingitis. In this study, we found that the prevalence of BV in women with UI is 42.5%, while the prevalence of BV in the fertile women (the control group) was 10% (P Value=0.0001). These results were similar to others who reported BV in 45.5% Vs 15.5% of the infertile and the control groups respectively [58]. On the other hand, BV was reported in only 18.9% of women with UI [61]. They reported rates of 12–15% in those with endometriosis and male factor infertility and 33–36% in those with anovulation and tubal infertility. Women with tubal factor were two to three times more likely to have BV than women with other types of infertility [62]. These findings highlight the importance of searching for BV in cases with tubal factor of infertility. This study reported no significant difference in the results of samples taken from the posterior fornix of vagina and those taken from the endometrial cavity (P Value=0.853). However, detection of clue cells in the endometrial cavity of women with UI demonstrates the possibility of ascending route of BV to the upper genital tract.

Regarding the role of culture for diagnosis of BV, we reported in 45.8% and 42.5% in culture and using Amsel's criteria respectively without any significant difference. In this study, culture was a sensitive but not a specific method for diagnosing of BV compared to Amsel's criteria which is demonstrated by ROC curve. Likewise, culture was unhelpful for the diagnosis of BV due to an imbalance of the normal organisms, without any pathogens necessarily being present [63].

The sensitivity and specificity of vaginal cultures for anaerobic bacteria (*Bacteroides* and *Peptostreptococcus*) and *Mycoplasma hominis* were reported in one study. They found that the presence of these organisms was a more specific indicator of BV than the presence of *G. vaginalis* but their detection had inadequate sensitivity [64]. Another group of anaerobic

bacteria, *Mobiluncus* species, which is highly associated with BV, was very difficult to recover with culture methods [65].

In a previous study, 114 women with UI were examined laparoscopically. Laparoscopy revealed pelvic pathology in 95 patients. Endometriosis, pelvic adhesions and tubal disease were observed and treated in 72, 46 and 24 patients, respectively. They could treat 72 patients of them, and 35 of them conceived using their own tubes. However they concluded that diagnostic laparoscopy should be strongly considered in UI work-up, and tubal efficacy should not be underestimated [66]. In this study, positive laparoscopic findings were reported in 77 patients (64.2 %). We found that laparoscopy can reveal upper genital tract pathology in 50% of positive cases with BV and it was negative in 35% of negative cases with BV (P Value=0.0001). There was a significant correlation between the positive cases of BV and the pathological lesions diagnosed by laparoscopy especially hyperemic uterus, chronic salpingitis and massive adhesions (P Value=0.0001) as shown in the following table.

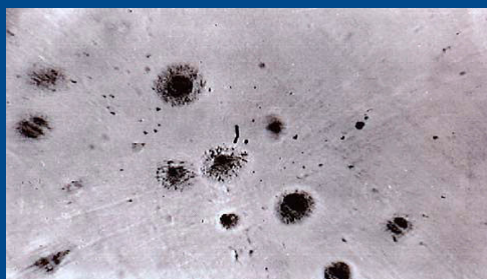
9. Relation between positive cases of bacterial vaginosis and laparoscopic findings

Subsequently, we recommend meticulous screening of women with these abnormal laparoscopic findings for possibility of hidden intrauterine infections. From this study, BV is strongly implicated in female infertility and it is probably an underestimated cause of UI. There is no extra benefit from using culture instead of Amsel's criteria for the diagnosis of BV. No difference in the site of sample taking in diagnosis of BV from posterior vaginal fornix or endometrial cavity. Laparoscopy is very beneficial in explaining the effect of BV on the upper genital tract. Further studies are required to test the impact of proper treating BV on subsequent fertility in case of UI.

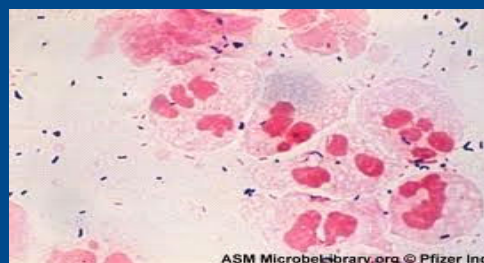diagnosis of bacterial vaginosis (Amsel's criteria)	chronic salpingitis	endometriosis	fine adhesions	hyperemic uterus	massive adhesions	normal	Total	P Value
+ve	Count 13 % of Total 10.8%	Count 3 % of Total 2.5%	Count 8 % of Total 6.7%	Count 14 % of Total 11.7%	Count 12 % of Total 10.0%	Count 1 % of Total 0.8%	Count 51 % of Total 42.5%	0.0001 (sig)
-ve	Count 7 % of Total 5.8%	Count 5 % of Total 4.2%	Count 5 % of Total 4.2%	Count 8 % of Total 6.7%	Count 2 % of Total 1.7%	Count 42 % of Total 35.0%	Count 69 % of Total 57.5%	
Total	Count 20 % of Total 16.7%	Count 8 % of Total 6.7%	Count 13 % of Total 10.8%	Count 22 % of Total 18.3%	Count 14 % of Total 11.7%	Count 43 % of Total 35.8%	Count 120 % of Total 100%	

10. Role of hidden intrauterine infections and the value of laparoscopy in these cases

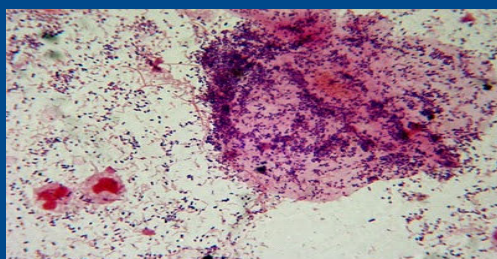
Existing definitions of infertility lack uniformity, rendering comparisons in prevalence between countries or over time problematic. The absence of an agreed definition also compromises clinical management and undermines the impact of research findings [66]. Unexplained infertility is infertility that is idiopathic in the sense that its cause remains unknown even after basic infertility work-up, usually including semen analysis in the man and assessment of ovulation and fallopian tubes in the woman. The available diagnostic tools for intrauterine causes of infertility include transvaginal ultrasonography, hysterosalpingography (HSG) or sonohysterography [67]. Manifest uterine causes may include clinically symptomatizing uterine infections, intrauterine adhesions, polypi or uterine cavity malformations. Hidden uterine factors may include thin endometrium, poor endometrial receptivity, and immunological incompatibility which have received the most attention in recent years [68]. In literature, little attention was directed towards asymptomatic hidden intrauterine infections like *Mycoplasma*, *Ureaplasma*, *Klebsiella* and *Chlamydia trachomatis* particularly among infertile women [69].



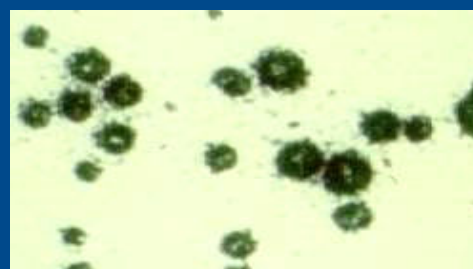
Mycoplasma colonies with fried egg appearance



Chlamydia trachomatis



BV (gram stain)



ureaplasma urealyticum

Subclinical infection can be a possible cause of unexplained infertility [70]. Changes in the intraperitoneal environment leading to an inflammatory process in the absence of visible abnormalities have been suggested as being causal in some cases of UI [71]. We believe that occult infections are important explanation of UI particularly in patients who are unable to clearly give a history to explain a source for their tubal adhesions.

We constructed a prospective study aimed to estimate the prevalence of hidden (asymptomatic) intrauterine infections among women with unexplained infertility in comparison to fertile women and to describe laparoscopic appearances in positive cases. It was a prospective cross sectional comparative observational study done at a tertiary care referral facility and University hospital. It comprised 50 women with unexplained infertility (study group A) and 50 fertile women (control group B) who came for contraceptive advice. Endouterine swab for bacteriologic study from all cases. Diagnostic laparoscopy for group A. Main outcome measures included prevalence of infections among both groups and to correlate laparoscopic findings to bacteriologic study in group A. There was statistically insignificant difference between both groups regarding the age and residence (p value >0.05) and it was highly significant regarding parity (p value <0.001). Hidden intrauterine infections were diagnosed by culture in 42 cases (84%) and 10 cases (20%) out of both groups respectively (P=0.001). The most common organisms detected in the study group were Mycoplasma (24%), klebsiella (20%), Chlamydia (18%) and Proteus (10%). In group A, positive laparoscopic findings were reported in 33 patients (66 %). There was a significant correlation between the positive cases of hidden intrauterine infections and abnormal laparoscopic findings (P Value=0.0001). The most common laparoscopic abnormalities were hyperemic uterus, peritubal adhesions and chronic salpingitis which were reported in 10 (20%), 6 (12%) and 4 (8%) cases respectively.

11. Hidden intrauterine microorganisms detected in both groups

Control group (B)		study group (A)		Organism
Percent	No (50)	Percent	No (50)	
2%	1	24%	12	<i>Mycoplasma</i>
8%	4	20%	10	<i>Klebsiella</i>
6%	3	18%	9	<i>Chlamydia</i>
0%	0	10%	5	<i>Proteus</i>
0%	0	6%	3	<i>Legionella</i>
2%	1	4%	2	<i>Ureaplasma</i>
0%	0	2%	1	<i>Staph.</i>
2%	1	0%	0	<i>Pseudomonous</i>
80%	40	16%	8	<i>Negative*</i>

		chronic salpingitis	Endometriosis	fine peritubal adhesions	hyperemic uterus	Tubal block (uni/bi)	Fimbrial agglutination	Normal (17)	Total (50)
	% of Total	0	4%	0	2%	0	0	10%	16%
Total (50)	No.	4	9	6	11	1	2	17	50
	% of Total	8%	18%	12%	22%	2%	4%	34%	100%

In this study, we found that the prevalence of hidden intrauterine infections proved by culture of endouterine discharge in women with UI was 84% while the prevalence in the fertile women (the control group) was 20% (P Value=0.0001). Based on our results, we recommend that before starting a lengthy and costly list of sophisticated level II investigations of both partners, focusing attention to hidden uterine infections is very important basic step in UI. These results were similar to others who reported high prevalence of different types of infections [72]. It has been found that women with tubal factor were two to three times more likely to have genital tract infections than women with other types of infertility [73]. Likewise, our findings highlight the importance of searching for genital tract infections in cases with tubal factor of infertility. In this study we used culture of the intrauterine discharge as a diagnostic test for different infections. Biochemical confirmation was also performed. Others used more sophisticated tests like ELIZA and PCR [72,73]. We think that culture should be accepted as a basic screening tool due to availability and feasibility in many hospitals. Screening test should not be expensive or complicated to be extended to all hospitals particularly in low resource countries like ours.

This study demonstrated a high prevalence of Mycoplasma (24%), klebsiella (20%), Chlamydia (18%) and Proteus (10%) among women with UI. These results of high prevalence compared to fertile women would call for more attention to screening protocols in all infertility units dealing with UI ideally prior to laparoscopic intervention. Due to high prevalence of Chlamydia in infertile women in one previous study, screening for Chlamydia was recommended for cases with UI [72]. We reported Mycoplasma in about one quarter of positive cases. Likewise, mycoplasma was reported in 32% of infertile cases with a statistically significant difference from fertile group [77]. In this study, we cultured proteus infection in 10% of infected cases. This particular organism is commonly noticed in the urinary system. Reporting it in the genital tract would requires more studies to define its role in infertility. Unlike others, we reported low prevalence of Ureaplasma in only 4% of cases despite its previous reports of up to 32% infertile cases [72]. This wide difference may demonstrate the variability of frequency of hidden intrauterine infections in different populations and highlights detection of prevalence in each community.

The role of laparoscopy in the evaluation of infertility is crucial [78]. In this study we reported 33 case (66%) of abnormal laparoscopic findings in the infertile group. In a previous study [79], abnormal laparoscopic findings were reported in about 53 % of infertile women. Pelvic adhesions were the most frequent finding in their study. Others [80] reported a higher

prevalence of abnormal laparoscopic findings in UI up to 87.2% who described endometriosis lesions, peritubal adhesions and tubal obstruction. In a previous study, 114 women with UI were examined laparoscopically. Laparoscopy revealed pelvic pathology in 95 patients. Endometriosis, peritubal adhesions and tubal disease were observed and treated in 72, 46 and 24 patients, respectively. They could treat 72 patients of them, and 35 of them conceived using their own tubes. However they concluded that diagnostic laparoscopy should be strongly considered in UI work-up, and tubal efficacy should not be underestimated [65]. In this study, positive laparoscopic findings were reported in 33 patients (66 %). We found that laparoscopy can reveal upper genital tract pathology in 30 cases (71.4%) of positive cases with hidden infections (42 cases) and it was negative in 3 cases (37.5%) of negative cases with hidden intrauterine infections (P Value=0.0001). We reported a significant correlation between the positive cases of intrauterine infections and the pathological lesions diagnosed by laparoscopy especially hyperemic uterus, chronic salpingitis and peritubal adhesions (P Value=0.0001). Subsequently, we recommend meticulous screening of women with these abnormal laparoscopic findings for possibility of hidden intrauterine infections. Small sample size of individual types of hidden intrauterine infections and lack of precise description of a particular abnormal laparoscopic finding for each organism are clear limitations of this study. Diagnostic accuracy for Chlamydia detection would be better if we used Nucleic Acid Amplification (NAAT) instead of the only available direct immunofluorescence assay (IFA). From this study, we conclude that despite being an underestimated cause of female infertility, hidden intrauterine infections are frequent and strongly implicated in UI. Laparoscopy is very beneficial in explaining the effect of hidden intrauterine infections on the upper genital tract. We recommend postoperative screening for hidden intrauterine infections in UI cases with abnormal laparoscopic findings. Further studies are required to test the impact of proper treating these infections in cases of UI.

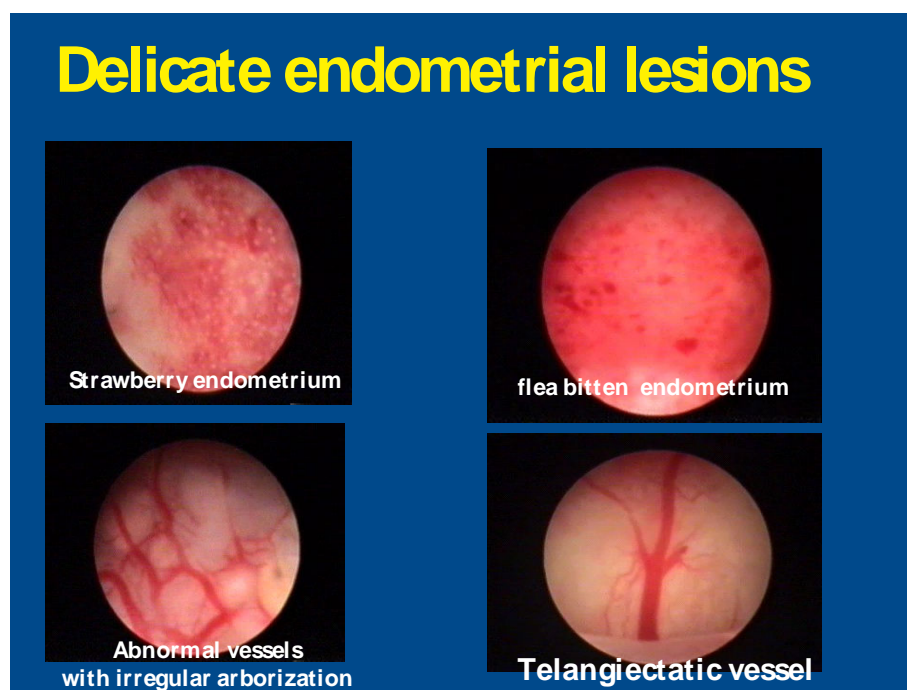
14. Hidden ovarian factors of infertility

The ovaries are easily and clearly seen by transvaginal ultrasonography. Intraovarian and capsular abnormalities can be detected in most of the cases. Despite properly confirmed ovulation in an otherwise normal couple, pregnancy could not be achieved. On doing diagnostic laparoscopy in those cases some tiny ovarian abnormalities could be diagnosed. Subtle surface ovarian endometriosis could be only diagnosed by laparoscopy. In such cases surface coagulation of red, white or vesicular lesions is easy. Moreover, typical black or blue lesions can be only seen and treated by laparoscopy. In some cases, we notice fine periovarian adhesions hindering rupture of the growing follicles and preventing pick-up of the oocytes. In such cases, fine microsurgical adhesiolysis without capsular injuring using a delicate fine scissors is feasible by laparoscopy. We may see some dense ovarian adhesions to the lateral or anterior abdominal wall that clearly affect fertility. In such cases, microsurgical adhesiolysis will regain the normal anatomy. Lastly, we may notice fine or dense adhesions between the ovary and the back of the uterus or the fallopian tubes. All these mechanical factors will not

be seen by HSG and highlight the importance of implication of dual laparoscopy and hysteroscopy in all cases of infertility particularly women with previous pelvic or uterine surgery.

15. Uterine causes of UI

Uterine factors account about 20% of all cases of infertility. Manifest uterine causes may include intrauterine adhesions, polypi or uterine cavity malformations. Hidden uterine factors may include thin endometrium, poor endometrial receptivity, and immunological incompatibility which have received the most attention in recent years. Some delicate endometrial lesions could be diagnosed by hysteroscopy as shown in this figure.



We constructed a study [81] aiming to estimate the safety, efficacy and patient acceptability of adding vaginoscopic office hysteroscopy (VOH) to the infertility diagnostic work-up prior to laparoscopy. It was a prospective comparative diagnostic trial done at a tertiary care referral facility and University hospital. A total of 156 infertile patients scheduled for laparoscopy. Seventy eight patients had VOH on one stop bases in addition to the usual infertility work-up were assigned as group B while a similar number was examined by the usual diagnostic work-up and assigned as group A. Main outcome measures included the diagnostic accuracy of VOH in diagnosing intrauterine abnormalities and tubal patency in comparison to hysterosalpingography (HSG) and diagnostic laparoscopy (DL). Combined VOH and HSG or DL assessment for diagnostic accuracy.

There was insignificant difference between both groups regarding sociodemographic and HSG data. Abnormal DL findings were more significant in group A. VOH detected 50% abnormal

endometrial cavity in group B with a significant superiority over HSG. Blocked tubes were diagnosed in 9% and 11.5%, 5.1% and 6.4% and 3.8% and 5.1% using VOH, HSG and DL on right and left sides respectively. There was a high percentage of agreement in the diagnosis of uterine abnormalities between HSG and VOH (96%, $k=0.394$). On the other hand, the percentage of agreement between VOH and HSG is less (86%, $k=0.214$) and is much less between VOH and laparoscopy (82%, $k=0.148$) regarding tubal patency testing. Generally, VOH was an acceptable procedure with mild pain and feasible in most cases.

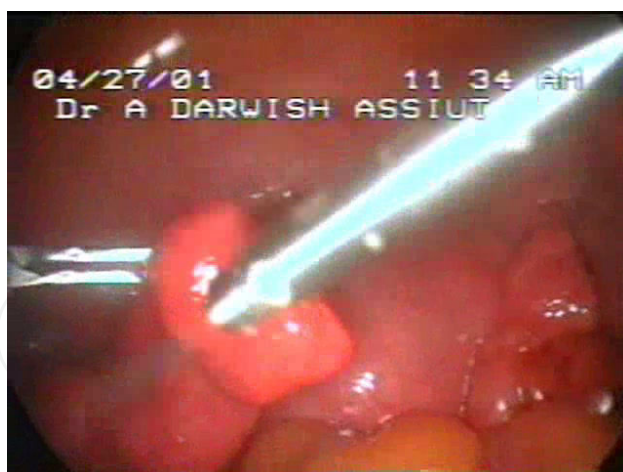
We concluded that VOH seems feasible, safe, simple, tolerable and quick out-patient procedure. It can diagnose intrauterine abnormalities in 23.7% of infertile women with normal HSG. VOH achieves marvelous agreement with HSG in diagnosing uterine abnormalities (96%), excellent agreement with HSG (86%) for tubal patency testing and very good agreement with DL (82%) regarding tubal patency. Diagnostic indices including accuracy of either HSG or DL would increase if combined with VOH. We recommend adding VOH to the routine diagnostic work-up of infertile couples prior to laparoscopy. Nevertheless, whether its use would increase pregnancy rate among infertile women requires a further longitudinal comparative study.

16. Diagnostic accuracy of combined tests for assessment of uterine and tubal factors

	VOH + HSG (for assessment of uterine factor)	VOH + HSG (for assessment of tubal patency)	VOH+ laparoscopy (for assessment of tubal patency)
Sensitivity	97.4%	50%	94%
Specificity	56.2%	16.6%	33.3%
Positive predictive value	80.9%	76.2%	94%
Negative predictive value	90%	5.9%	33.3%
Accuracy	59.2%	44.7%	89.5%

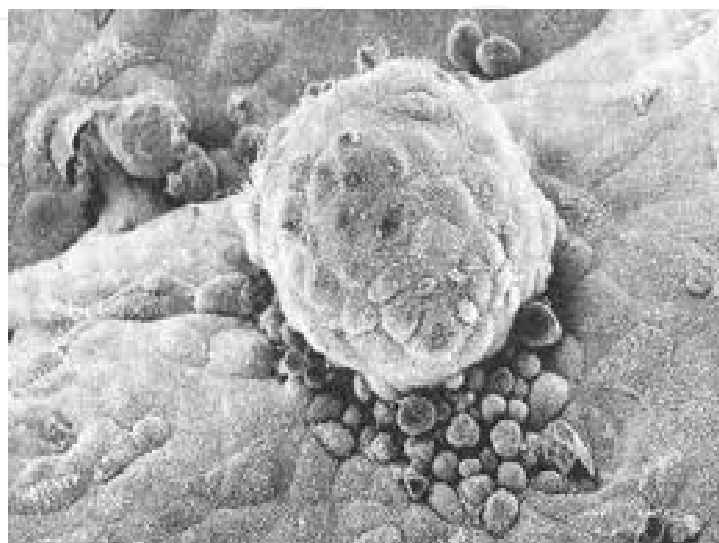
17. Endoscopic exploration of the fertilization site

Sometimes the fallopian tubes appear normal at HSG and even laparoscopy but pregnancy doesnot occur due to some hidden intratubal fine lesions at the fertilization site (ampulla). Intratubal examination can only be done using fallopscopy (from the cervical side) or salpingoscopy (from the fimbrial side). Going inside the tube allows proper exploration of the endosalpnix. Lost or destroyed major or minor folds may explain infertility. Detection of fine adhesions or tiny polypi is feasible by salpingoscopy.



18. Exploration of the implantation site

Implantation site is located on the posterior endometrium at midline 10-15 mm from the fundus. Hysteroscopy can detect tiny lesions at the implantation site like fine adhesions, polypi or small septum. Implantation failure may be caused by abnormal cytokine expression by embryos and endometrium. As proved in many studies, endometrial injury would induce release of cytokines that may increase implantation. Practically, site-specific endometrial injury in the follicular phase with the edge of the office hysteroscopy lens would enhance implantation in cases with unexplained infertility. Nevertheless, the real implementation of this procedure requires more randomized studies.



19. Keynote points

Unexplained infertility remains a clinical and scientific challenge.

Dual endoscopy (combined DL & DH) can explain a good percentage of cases with UI.

Nothing called UI without prior endoscopic assessment.

Office hysteroscopy (OH) is recommended even if HSG is normal.

Don't ignore hidden infections.

Try to explain UI but don't harm the patient. No need to perform unneeded procedure like overdoing of laparoscopic ovarian drilling that may invite adhesions and more importantly deleteriously affect ovarian reserve as shown in this figure.



Author details

Atef M. Darwish*

Address all correspondence to: atef_darwish@yahoo.com

Department of Obstetrics and Gynecology, Woman's Health University Hospital, Faculty of Medicine, Assiut University, Egypt

References

- [1] Siristatidis C, Bhattacharya S. Unexplained infertility: does it really exist? Does it matter? *Hum Reprod.* 2007;22(8):2084-7.
- [2] Smith S, Pfiefer SM, Collins J. Diagnosis and management of female infertility. *JAMA* 2003; 290, 17.
- [3] The Practice Committee of the American Society for Reproductive Medicine, authors. Optimal evaluation of the infertile female. *Fertil Steril* 2006; 86(5 suppl):S264–S267.
- [4] Cahill DJ and Wardle PG. Management of infertility. *British Medical Journal* 2002; 325:28-32.
- [5] Randolph JF. Unexplained infertility. *Clinical Obstetrics and Gynecology* 2000; 43:897-901.
- [6] Ray A, Shah A, Gudi A, Homburg R. Unexplained infertility: an update and review of practice. *Reproductive Biomedicine Online* 2012;24, 591-602.
- [7] Querlen D. Fertility after conization. *Rev Fr Gynecol and Obstet* 1991;15;86(2):81-82.
- [8] Paulson RJ. Unexplained infertility. *MishelFs Textbook if infertility, Contraception and Reproductive Endocrine.* 1997; Chapter (45): 743 – 753.
- [9] Speroff L, Glass RH and Kase NG. *Clinical gynecology Endocrine and infertility.* 5th ed. Williams &Wilkins Baltimore London. 2004;Vol. 11. p24.
- [10] Balasch J, Fabregues F, Creus M, Casamitjana R, Peurto B and Vanrell JA. Recombinant human follicular stimulating hormone for ovulation induction in polycystic ovary syndrome: a prospective, randomized trial of two starting doses in a chronic low dose step up protocol. *J Assist Reprod Genet* 2000; 17(10):561-565.
- [11] Cahill DJ, Wardle PG. Management of infertility. *British Medical Journal* 2002; 325:28-32.
- [12] Schild RL, Knobloch C, Dorn C, Fimmers R, Van derv en H, Hansmann M. Endometrial receptivity in an in vitro fertilization program as assessed by spiral artery blood flow, *Fertil Steril* 2001;75:361-366.
- [13] Li H, Chen S and Xing F. Expression of HOXA10 gene in human endometrium and its relationship with unexplained infertility. *Chinese Journal of OB/GYN* 2002; 37(1): 30-32.
- [14] Collins JA Burrows EA, Willam AR. The prognosis for live birth among untreated infertile couples. *Fertil Steril* 1995; 64:22-28.
- [15] Choudhury SR and Knapp LA. Human reproductive failure: Immunological factors. *Hum Reprod Update* 2001; 7(2):113-134.

- [16] Bonneau C, Chanelles O, Sifer C, Poncelet C. Use of laparoscopy in unexplained infertility. *European Journal of Obstetrics & Gynecology and Reproductive Biology* 2012; 58-60.
- [17] Kahyaoglu S. Does diagnostic laparoscopy have value in unexplained infertile couple? Review of the current literature. *J Minimally Invasive Surgery Science*. 2012 1;4: 124-128.
- [18] De Wilde RL, Brosens I. Rationale of first-line endoscopy-based fertility exploration using transvaginal hydrolaparoscopy and minihysteroscopy. *Hum Reprod*. 2012 Aug;27(8):2247-53.
- [19] Child T. Optimizing the management of patients with infertility. *Practitioner*. 2013;257(1759):19-22, 2-3.
- [20] Cebesoy FB¹, Kutlar I, Dikensoy E, Yazicioglu C, Kalayci H. Morgagni hydatids: a new factor in infertility? *Arch Gynecol Obstet*. 2010 Jun;281(6):1015-7.
- [21] Rasheed SM¹, Abdelmonem AM. Hydatid of Morgagni: a possible underestimated cause of unexplained infertility. *Eur J Obstet Gynecol Reprod Biol*. 2011 Sep;158(1): 62-6.
- [22] Han H, Guan J, Wang Y, Zhang Q, Shen H. Diagnosis and treatment of tubal diverticula: report of 13 cases. *J Minim Invasive Gynecol*. 2014 Jan-Feb;21(1):142-6.
- [23] Kunz G, Beil D, Deiniger H, Einspanier A, Mall G, Leyendecker G. The Uterine Peristaltic. The Fate of the Male Germ Cell. *Advances in Experimental Medicine and Biology* 1997; 424, 267-277.
- [24] Maia H, Coutinho EM. Peristalsis and antiperistalsis of the human fallopian tube during the menstrual cycle. *Biology of Reproduction*. 1970;2,305-314.
- [25] Aranda V, Cortez R, Fauci L. Stokesian peristaltic pumping in a three-dimensional tube with a phase-shifted asymmetry. *Physics of Fluids* 2011; 23, 081901.
- [26] Darwish AM, Sayed EH, Mohammad SA, Mohammad II, Hassan HI. Reliability of out-patient hysteroscopy in one-stop clinic for abnormal uterine bleeding. *Gynecologic Surgery* 2012;9, 3, 289-295.
- [27] Emanuel MH. New developments in hysteroscopy. *Best Pract Res Clin Obstet Gynaecol*. 2013 Feb 2. pii: S1521-6934(13)00005-9.
- [28] Johnson NP Review of lipiodol treatment for infertility-an innovative treatment for endometriosis-related infertility?. *Aust N Z J Obstet Gynaecol*. 2014 Feb;54(1):9-12.
- [29] Court KA, Dare AJ, Weston-Webb M, Hadden WE, Sim RG, Johnson NP. Establishment of lipiodol as a fertility treatment-Prospective study of the complete innovative treatment data set. *Aust N Z J Obstet Gynaecol*. 2014 Feb;54(1):13-19.

- [30] Petri E, Berlit S, Sütterlin M, Hornemann A. Chromopertubation--presentation of a modification of the standard technique. *Anticancer Res.* 2013 Apr;33(4):1591-4.
- [31] Saunders RD, Shwayder JM, Nakajima ST. Current methods of tubal patency assessment. *Fertil Steril.* 2011 Jun;95(7):2171-9.
- [32] Darwish AM, Youssef AA. Screening sonohysterography in infertility. *Gynecol Obstet Invest.* 1999;48(1):43-7.
- [33] Van Schoubroeck D, Van den Bosch T, Meuleman C, Tomassetti C, D'Hooghe T, Timmerman D. The use of a new gel foam for the evaluation of tubal patency. *Gynecol Obstet Invest.* 2013;75(3):152-6.
- [34] Sladkevicius P, Zannoni L, Valentin L. Use of B-flow ultrasound facilitates visualization of contrast media during hysterosalpingo-contrast sonography (HyCoSy). *Ultrasound Obstet Gynecol.* 2013 Dec 20. doi: 10.1002/uog.
- [35] Zhou L, Zhang X, Chen X, Liao L, Pan R, Zhou N, Di N. Value of three-dimensional hysterosalpingo-contrast sonography with SonoVue in the assessment of tubal patency. *Ultrasound Obstet Gynecol.* 2012 Jul;40(1):93-8.
- [36] Exacoustos C, Di Giovanni A, Szabolcs B, Romeo V, Romanini ME, Luciano D, Zupi E, Arduini D. Automated three-dimensional coded contrast imaging hysterosalpingo-contrast sonography: feasibility in office tubal patency testing. *Ultrasound Obstet Gynecol.* 2013 Mar;41(3):328-35.
- [37] Pavone ME, Hirshfeld-Cytron JE, Kazer RR. The progressive simplification of the infertility evaluation. *Obstet Gynecol Surv.* 2011 Jan;66(1):31-41.
- [38] Ma L, Wu G, Wang Y, Zhang Y, Wang J, Li L, Zhou W. Fallopian tubal patency diagnosed by magnetic resonance hysterosalpingography. *J Reprod Med.* 2012 Sep-Oct; 57(9-10):435-40.
- [39] Török P, Major T. Accuracy of assessment of tubal patency with selective pertubation at office hysteroscopy compared with laparoscopy in infertile women. *J Minim Invasive Gynecol.* 2012 Sep-Oct;19(5):627-30
- [40] Kajanová M, L D, S P, Miko M, Urban L, Bokor T, Varga I. The structural basis for transport through the Fallopian tube. *Ceska Gynekol.* 2012 Dec;77(6):566-71.
- [41] Groenman FA, Peters LW, Rademaker BM, Bakkum EA. Embolism of air and gas in hysteroscopic procedures: pathophysiology and implication for daily practice. *J Minim Invasive Gynecol.* 2008 Mar-Apr;15(2):241-7.
- [42] Darwish AM, Amin AM, Mohammad SA. Laparoscopic management of paratubal and paraovarian cysts. *Journal of the Society of Laparoendoscopic Surgeons* 2003;7,2 :101-6.
- [43] Gomel V, Taylor PJ, Yuzpe A, Roux J: *Laparoscopy and Hysteroscopy in Gynecologic Practice.* Chicago, Year Book, 1986.

- [44] Chawla N, Kudesia S, Azad S, Singhal M, Rai SM. Salpingitis isthmica nodosa. *Indian J Pathol Microbiol.* 2009;52(3):434-5.
- [45] Kessel R. *Medical histology.* Oxford University Press, London, P 486-1998
- [46] Gartner LP, Hiatt JL. *Color textbook of histology.* Third Edition. Saunders, Elsevier, New York, P 477-78.
- [47] Weiss L, Greep RO. *Histology.* Fourth Edition. McGraw-Hill Book Com, New York Page 920.
- [48] Yablonski M, Sarge T, Wild RA. Subtle variations in tubal anatomy in infertile women. *Fertil Steril.* 1990 Sep;54(3):455-8.
- [49] Hurst BS, Tucker KE, Awoniyi CA, Schlaff WD. Hydrosalpinx treated with extended doxycycline does not compromise the success of in vitro fertilization. *Fertil Steril.* 2001 May;75(5):1017-9.
- [50] Fakih H, Marshall J. Subtle tubal abnormalities adversely affect gamete intrafallopian transfer outcome in women with endometriosis. *Fertil Steril.* 1994 Oct;62(4):799-801
- [51] Kolusari A, Ugurluer G, Kosem M, Kurdoglu M, Yildizhan R, Adali E. Leiomyosarcoma of the broad ligament: a case report and review of the literature. *Eur J Gynaecol Oncol.* 2009;30(3):332-4.
- [52] Janovski NA. Choristoma of heterotopic adrenal tissue in mesosalpinx. *Obstet Gynecol.* 1966 ;28(3):380-2.
- [53] Huang WC, Yang SH, Yang JM. Ultrasonographic manifestations of fallopian tube carcinoma in the fimbriated end. *J Ultrasound Med.* 2005 ;24(8):1157-60; quiz 1161-2.
- [54] Benjaminov O, Atri M. Sonography of the abnormal fallopian tube. *AJR Am J Roentgenol.* 2004 Sep;183(3):737-42.
- [55] Ezedinma NA, Phelps JY. Transvaginal hydrolaparoscopy. *JSLs.* 2012;16(3):461-5.
- [56] Ray A, Shah A, Gudi A, Homburg R. Unexplained infertility: an update and review of practice. *Reprod Biomed Online.* 2012;24(6):591-602.
- [57] Lockyer C. Lipoma of the Broad Ligament. *Proc R Soc Med.* 1919;12(Obstet Gynaecol Sect):195-9.
- [58] Rasheed M. Salah, Abdelmonem M. Allam, Amin M. Magdy, Abeer Sh. Mohamed. Bacterial vaginosis and infertility: Cause or association ? *European journal of obstetrics & gynecology and reproductive biology* 2013; 167: 59-63.
- [59] Mania-Pramanik J, Kerkar SC, Salvi VS. Bacterial vaginosis: a cause of infertility?. *International Journal of STD & AIDS* 2009; 20: 778–781.

- [60] Spandorfer SD, Neuer A, Giraldo PC, Rosenwaks Z., Witkin SS. Relationship of abnormal vaginal flora, proinflammatory cytokines and idiopathic infertility in women undergoing IVF. *J Reprod Med* 2001; 46: 806-10.
- [61] Janet D. Wilson, Susan G. Ralph, Anthony J. Rutherford. Rates of bacterial vaginosis in women undergoing in vitro fertilization for different types of infertility. *BJOG: International journal of obstetrics and gynecology*. 2002;109:714-717.
- [62] Lamont RF. Bacterial vaginosis. *Year book of obstetric and gynecology*. 1998; 149:p154-158.
- [63] Krohn MA, Hiller SL. Comparison of methods for diagnosing bacterial vaginosis among pregnant women. *J. Clin. Microbiol*, 1989; 27:p1266-1271.
- [64] Hiller SL, Krohn MA, Nugent RP. Characteristics of the vaginal flora patterns assessment by gram stain among pregnant women. *Am. J. Obstet. Gynecol* 1992;166:p938-949.
- [65] Bonneau C, Chanelles O, Sifer C, Poncelet C. Use of laparoscopy in unexplained infertility. *European Journal of Obstetrics & Gynecology and Reproductive Biology* 2012; 58-60.
- [66] Boivin J, Bunting L, Collins JA, Nygren KG. International estimates of infertility prevalence and treatment-seeking: potential need and demand for infertility medical care. *Hum Reprod* 2007;22:1506–1512.
- [67] Darwish AM, Youssef AA. Screening sonohysterography in infertility. *Gynecol Obstet Invest*. 1999;48(1):43-7.
- [68] Choudhury SR, Knapp LA. Human reproductive failure: Immunological factors. *Hum Reprod Update* 2001; 7(2):113-134.
- [69] Cassell GH, Younger JB, Brown MB, Blackwell RE, Davis JK, Marriott P, Stagno S. Microbiologic study of infertile women at the time of diagnostic laparoscopy: Association of *Ureaplasma urealyticum* with a defined subpopulation. *N Engl J Med* 1983; 308: 502.
- [70] The Practice Committee of the American Society for Reproductive Medicine, authors. Optimal evaluation of the infertile female. *Fertil Steril* 2006; 86(5 suppl):S264–S267.
- [71] Siristatidis C, Bhattacharya S. Unexplained infertility: does it really exist? Does it matter? *Hum Reprod*. 2007;22(8):2084-7.
- [72] Gupta A, Gupta A, Gupta S, Mittal A, Chandra P, Gill AK. Correlation of mycoplasma with unexplained infertility. *Arch Gynecol Obstet* 2009 Dec; 280(6):981-5.
- [73] Cahill DJ, Wardle PG. Management of infertility. *British Medical Journal* 2002; 325:28-32.

- [74] Hossein Rashidi B, Chamani Tabriz L, Haghollahi F, Jeddi-Tehrani M, Naghizadeh MM, Shariat M, et al. Effects of Chlamydia trachomatis Infection on Fertility; A Case-Control Study. *J Reprod Infertil*. 2013;14(2):67-72.
- [75] Spandorfer SD, Neuer A, Giraldo PC, Rosenwaks Z., Witkin SS. Relationship of abnormal vaginal flora, proinflammatory cytokines and idiopathic infertility in women undergoing IVF. *J Reprod Med* 2001; 46: 806-10.
- [76] Siam EM, Hefzy EM. The relationship between antisperm antibodies prevalence and genital chlamydia trachomatis infection in women with unexplained infertility. *Afr J Reprod Health*. 2011 Sep;15(3):93-101.
- [77] Baczynska A, Friis Svenstrup H, Fedder J, Birkelund S, Christiansen G. The use of enzyme-linked immunosorbent assay for detection of Mycoplasma hominis antibodies in infertile women serum samples. *Hum Reprod*. 2005 May;20(5):1277-85.
- [78] Tsuji I, Ami K, Miyazaki A, Hujinami N, Hoshiai H. Benefit of diagnostic laparoscopy for patients with unexplained infertility and normal hysterosalpingography findings. *Tohoku J Exp Med*. 2009;219(1):39-42.
- [79] Gocmen, A. and T. Atak. "Diagnostic laparoscopy findings in unexplained infertility cases." *Clin Exp Obstet Gynecol* 2012;39(4): 452-453.
- [80] Nakagawa, K., S. Ohgi, T. Horikawa, R. Kojima, M. Ito and H. Saito. "Laparoscopy should be strongly considered for women with unexplained infertility." *J Obstet Gynaecol Res* 2007;33(5): 665-670.
- [81] Bonneau C, Chanelles O, Sifer C, Poncelet C. Use of laparoscopy in unexplained infertility. *European Journal of Obstetrics & Gynecology and Reproductive Biology* 2012; 58-60.
- [82] Atef M. Darwish, Ahmad I. Hassanin, Mahmoud A. Abdel Aleem, Ibraheem I. Mohammad, Islam H. Aboushama. Routine vaginoscopic office hysteroscopy in modern infertility work-up: A randomized controlled trial. *Gynecologic Surgery*. April 2014 online.