

We are IntechOpen, the world's leading publisher of Open Access books Built by scientists, for scientists

6,900

Open access books available

186,000

International authors and editors

200M

Downloads

Our authors are among the

154

Countries delivered to

TOP 1%

most cited scientists

12.2%

Contributors from top 500 universities



WEB OF SCIENCE™

Selection of our books indexed in the Book Citation Index
in Web of Science™ Core Collection (BKCI)

Interested in publishing with us?
Contact book.department@intechopen.com

Numbers displayed above are based on latest data collected.
For more information visit www.intechopen.com



Dental Implant Placement in Inadequate Posterior Maxilla

Umit Karacayli, Emre Dikicier and Sibel Dikicier

Additional information is available at the end of the chapter

<http://dx.doi.org/10.5772/59458>

1. Introduction

Hard tissue defects resulting from trauma, infection, or tooth loss often lead to an unfavorable anatomy of maxillary and mandibular alveolar processes. Dental implant placement in the edentulous posterior maxilla can present difficulties because of a horizontal or vertical alveolar ridge deficiency, unfavorable bone quality, or increased pneumatization of the maxillary sinus. The posterior maxilla has been known as the most difficult and problematic intraoral area for implant dentistry, requiring a maximum of attention for the achievement of successful surgery. Both anatomical structures and mastication dynamics contribute to the long term survival rates of endosseous dental implants in this region [1]. During the past 25 years, surgical procedures have been developed to increase the local bone volume, thus enabling the placement of implants [2]. The hard tissue augmentation techniques were separated into two anatomic sites, the maxillary sinus and alveolar ridge. Within the alveolar ridge augmentation procedures, different surgical approaches were developed and are currently used, including guided bone regeneration, onlay grafting, distraction osteogenesis, ridge splitting, free and vascularized autografts for discontinuity defects, and socket preservation. Among the variety of techniques have been described, the three that are the most widely used in maxilla are lateral approach, osteotome technique and ridge splitting [3].

2. Anatomy of the posterior maxilla

The maxillary sinus is a pyramid shaped cavity with an anterior wall corresponding to the facial surface of the maxilla. The size of the sinus is minimal until the eruption of permanent teeth. The average dimensions of the adult sinus are 2.5 to 3.5cm wide, 3.6 to 4.5 cm tall, and

3.8 to 4.5 cm deep. The size of the sinus will increase with age after extraction of the maxillary molar teeth. The extent of pneumatization varies from person to person and from side to side. The inner walls of the maxillary sinus is lined with the sinus membrane, also known as the Schneiderian membrane. This membrane consists of ciliated epithelium cells resting on the basement membrane. It is continuous with, and connects to, the nasal epithelium through the ostium in the middle meatus. The blood circulation to the maxillary sinus is primarily obtained from the posterior superior alveolar artery and the infraorbital artery, both being branches of the maxillary artery. Many anastomoses are occurred between these 2 arteries in the lateral antral wall. Among these arteries, the posterior superior alveolar artery and the infra-orbital artery also supply the buccal part of the maxillary sinus. However, because the blood supplies to the maxillary sinus are from terminal branches of peripheral vessels, to avoid bleeding complications, the branches of the maxillary artery should be taken into consideration. Nerve supply to the sinus is derived from the superior alveolar branch of the maxillary division of the trigeminal nerve [4].

The objective of sinus lift procedure is to compensate the bone loss by creating increased bone volume in the maxillary sinus and thus permitting the installation of implants in the posterior maxilla [4,5]. Membrane perforations and bleeding are procedure-related complications, seen in lateral wall sinus approach [6]. Therefore, the anatomy of the area should be carefully examined before surgical interventions.

3. Augmentation procedures

3.1. Vertical ridge augmentation

3.1.1. Sinus lifting procedure

Implant placement in the posterior maxilla is a challenging procedure when vertical deficiencies are occurred. Maxillary sinus elevation technique is a main surgical procedure which permits to augment the sufficient bone volume in posterior maxilla in order to place implants.

To increase the amount of bone in the posterior maxilla, the sinus lift procedure, or subantral augmentation, originally presented in 1977 and subsequently published in 1980 [4]. After modifications of the surgical procedure, access was accomplished through the lateral wall of the maxilla. It is preferable techniques to adjust the low residual bone height in the posterior maxilla performed in two ways: A lateral window technique and an osteotome sinus floor elevation technique and placing bone-graft material in the maxillary sinus to increase the height and width of the available bone. Autogenic bone graft is often used in this method. The bone usually seems to be harvested from the iliac crest, although several anatomic areas have been used.

When the ridge bone height is more than 6 mm, the osteotome technique can be performed. In that case, implant placement is usually carried out simultaneously with elevation of the sinus floor.

3.1.1.1. Lateral approach

Lateral approach is also known as lateral antrostomy which is a predictable technique to increase vertically available bone volume of the edentulous posterior maxilla giving the possibility to place osseointegrated implants. The sinus floor is elevated and it can be augmented with either autologous or xenogeneic bone grafts following an opening bone window prepared on the facial buccal wall of the sinus.

The 2-step antrostomy is the treatment of choice when the residual ridge bone height is less than 4 mm. As part of this approach, the implants are usually placed after a healing period of 6 to 18 months following sinus floor elevation [7]. The 1-step antrostomy is applied when the ridge bone height ranges from 4 to 6 mm. In this situation, implant placement is performed simultaneously with sinus floor elevation.

With respect to the grafting procedure, several grafting materials have successfully been used for elevating and stabilizing the sinus membrane: autogenous bone, allografts, xenografts and combination of these materials. Sinus floor elevation by lateral antrostomy has provided good implant survival rates, as reported in several studies. However, it is a demanding surgical procedure and is quite invasive. The 1-step antrostomy, in which implants are placed during the same surgical visit as elevation of sinus floor is performed, is similar to the 2-step technique with regard to advantages and disadvantages. The most important difference is that less time elapses before initiation of prosthetic therapy [7,8].

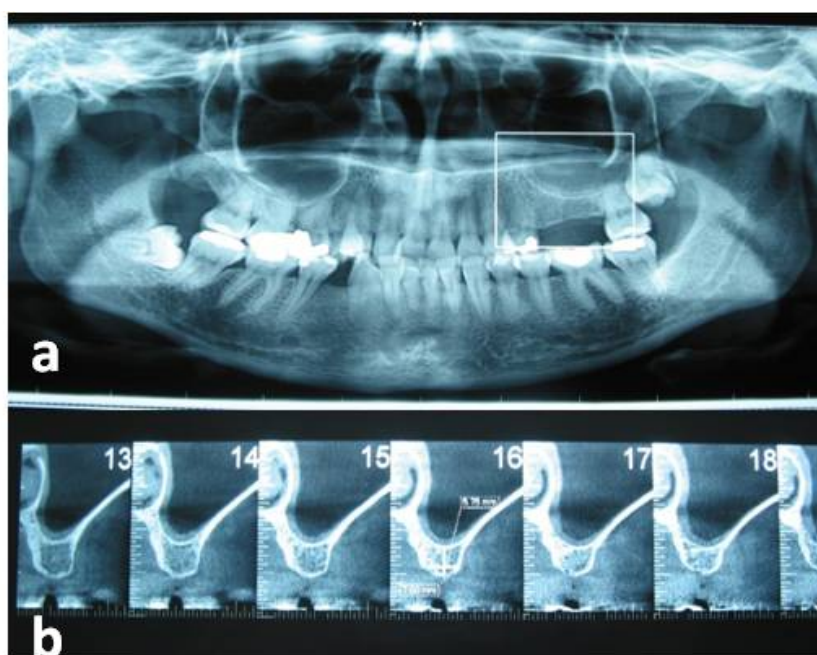


Figure 1. (a) Panoramic image before sinus augmentation procedure (b) Cone beam computerized image of the residual alveolar bone

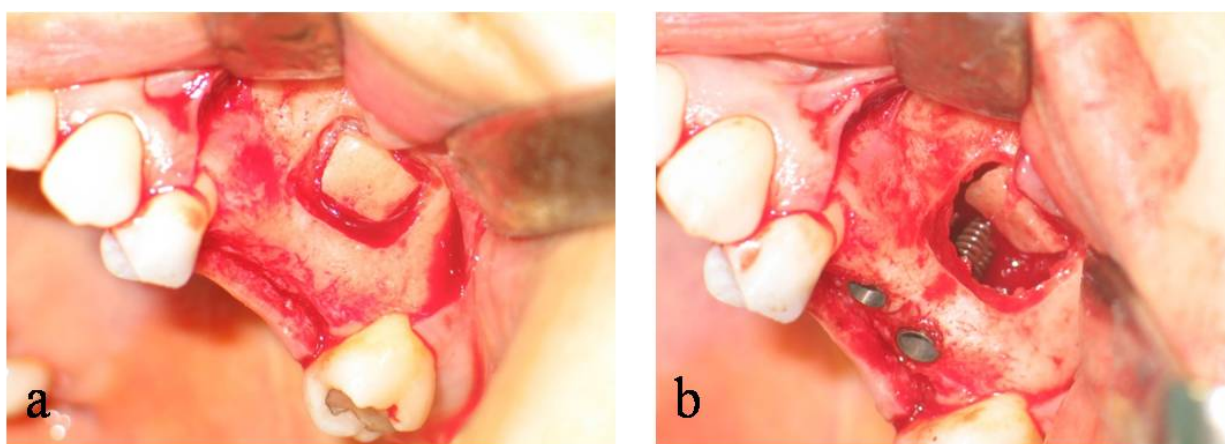


Figure 2. (a) Preparation of the bony window with a round bur (b) Medial rotation of the bone flap, elevation of the mucosa of the maxillary sinus and implant placement

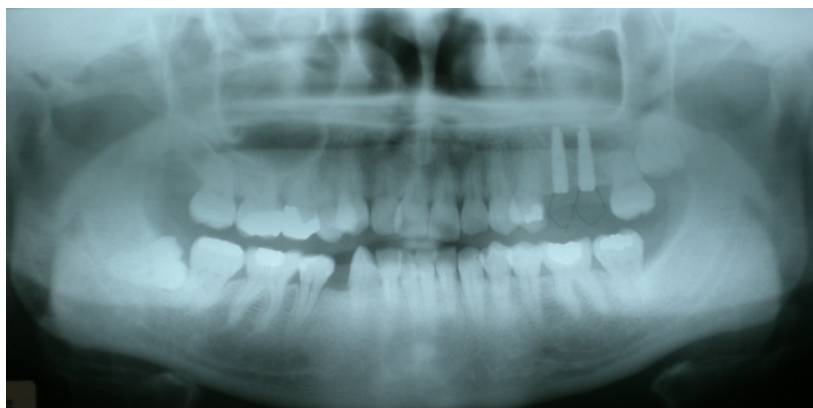

Figure 3. Postoperative radiographic view

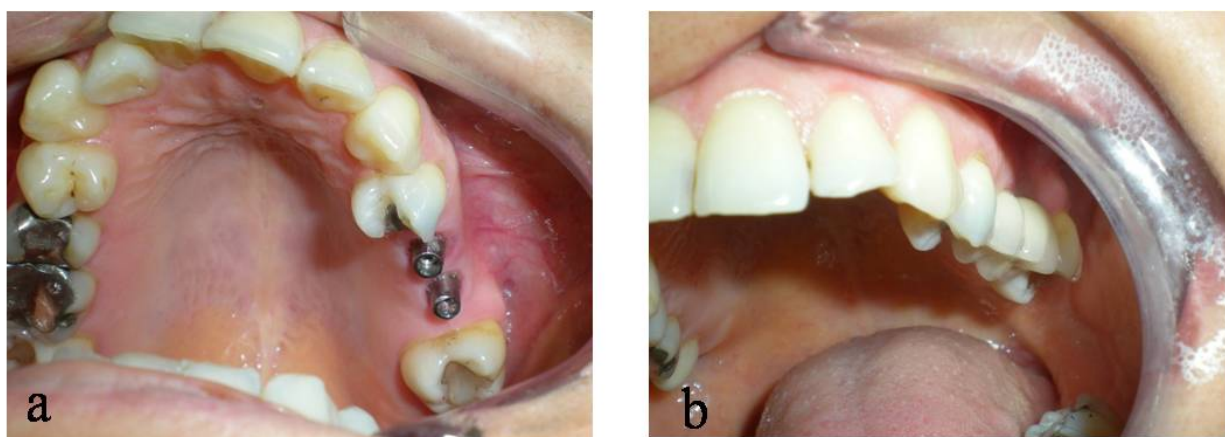


Figure 4. (a) Clinical view of the implants (b) Final prosthetic restoration

3.1.1.2. Osteotome sinus floor elevation technique

When the ridge bone height is more than 6 mm, the osteotome technique can be performed. In that case, implant placement is usually carried out simultaneously with elevation of the sinus floor. In the original approach, implants were placed after the controlled fracture of sinus floor and were submerged during the healing phase (Figure 5) [9].

Although the transcrestal approach is decided more conservative than the lateral approach, the main disadvantage is that the sinus lifting procedure must be performed blindly because of the impossibility to visualize the sinus floor [10]. In spite of this limitation, membrane perforation was reported to be less frequent in the osteotome-mediated procedure than in the lateral approach, for which such complication was occurred in 7-35% of cases [11].

Osteotome-mediated sinus lift surgery may be performed with or without using many type of bone graft material as allograft, autogenous bone, or xenogeneic bone material [12]. No significant differences in terms of implant survival and surgical success rates were reported comparing the two methods [13]. Also, the use of platelet derivatives without any bone substitute is described in literature with the aim of allowing a better control of forces during sinus floor elevation and reducing the incidence of complications [13].

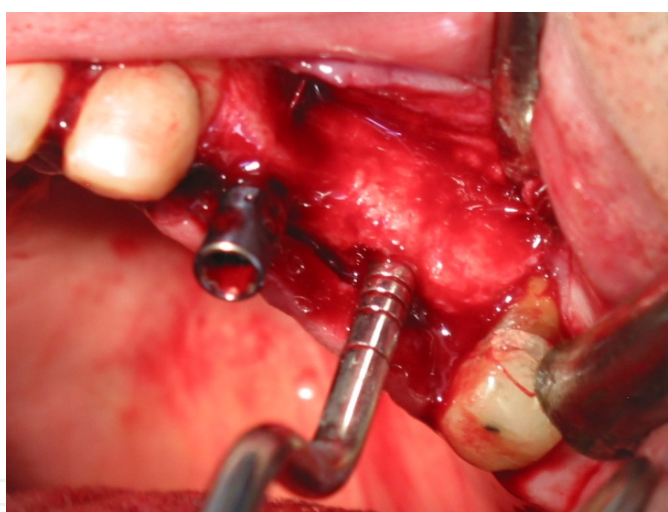


Figure 5. Osteotome sinus floor elevation technique

3.1.2. Titanium mesh

Natural hard and soft tissue contours allow both ideal implant placement and the emergence of a restoration. If there is large or small volume hard and soft tissue defects in these contours, these are prevent three-dimensional implant placement and aesthetic results [14]. Reconstructive efforts at aesthetic implant sites usually involve more than replacing missing hard and soft tissue. For reconstruction of these type of defects, the surgeon uses different techniques: (1) Distraction osteogenesis, which describes the surgical induction of a fracture and the subsequent gradual separation of the two bone ends to create spontaneous bone regeneration

between the two fragments; (2) Osteoinduction, which employs appropriate growth factors and/or stem/osteoprogenitor cells to encourage new bone formation [15, 16]; (3) Osteoconduction, in which a grafting material serves as a scaffold for new bone formation; and (4) Guided bone regeneration (GBR), which provides spaces using barrier membranes that are to be subsequently filled with new bone [17, 18]. Guided bone regeneration was introduced as a therapeutic modality to achieve bone regeneration, via the use of barrier membranes and titanium mesh. Titanium mesh has been used for a variety of clinical applications in reconstructive implant surgery and reported positive results. Titanium mesh has excellent mechanical properties for the stabilization of bone grafts beneath the membrane [19]. Its rigidity provides extensive space maintenance and prevents contour collapse; its elasticity prevents mucosal compression; its stability prevents graft displacement; and its plasticity permits bending, contouring, and adaptation to any unique bony defect [20]. The common feature of commercially available titanium mesh membranes is its macroporosity (in the millimeter range). This is thought to play a critical role in maintaining blood supply and is believed to enhance regeneration by improving wound stability through tissue integration and allowing diffusion of extracellular nutrients across the membrane [21]. The most important advantage of this macroporosity is related to the attachment of soft tissues, which may stabilize and restrict the migration of epithelial cells. However, this makes the material difficult to remove at the second surgery. These macro- and multi-porous characteristics also create sharp spots when the material is cut or bent, and may provide an easy pathway for microbial contamination into the healing site. Thus, the development of less porous and micropore-sized titanium mesh membrane could alleviate some of the current difficulties associated with titanium mesh in dental applications [22].

Although many relevant articles have reported good clinical results without using resorbable membrane over titanium mesh, it can be considered that the combination of titanium mesh and resorbable membrane can demonstrate satisfying results. Thus, it was achieved space creation by using titanium mesh and prevention of fibroblastic cell migration into the defect site by using resorbable membrane.

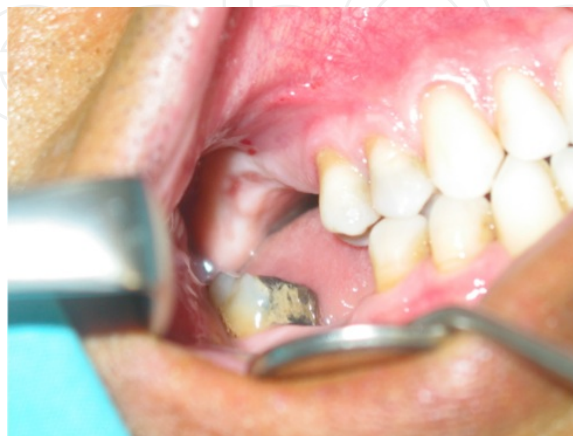

Figure 6. Pre-operative intraoral view

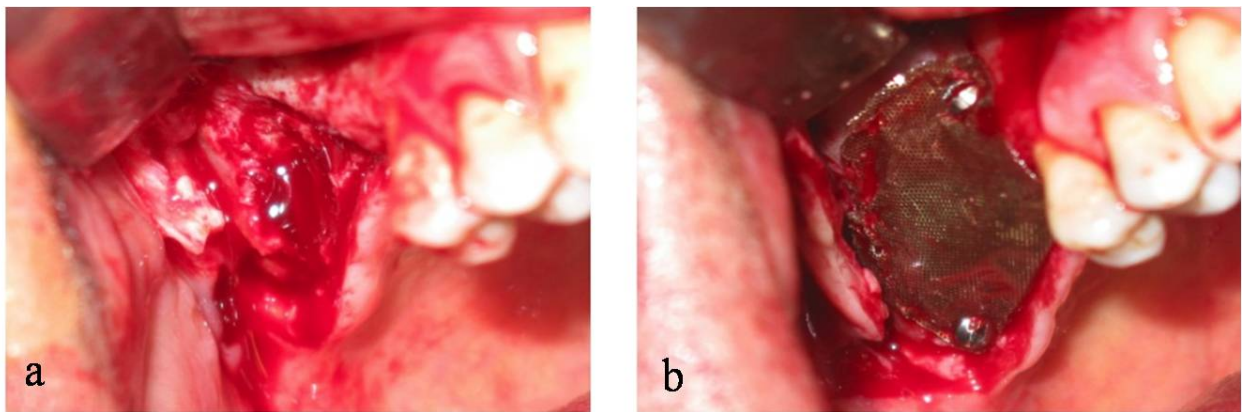


Figure 7. (a) Severe atrophy of right maxillar alveolar process (b) Titanium mesh

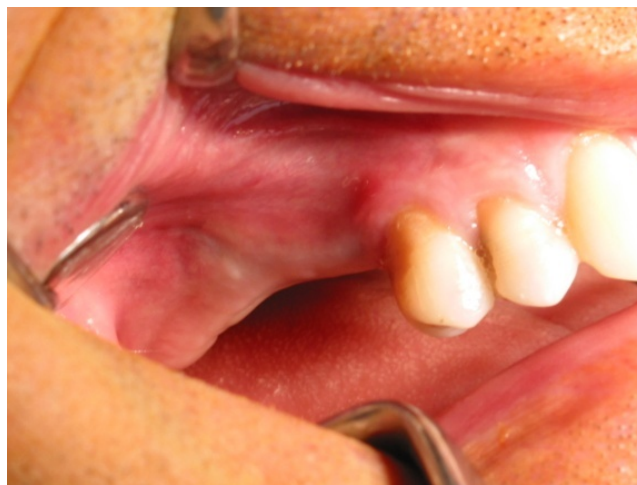

Figure 8. Post-operative 12 months intraoral view

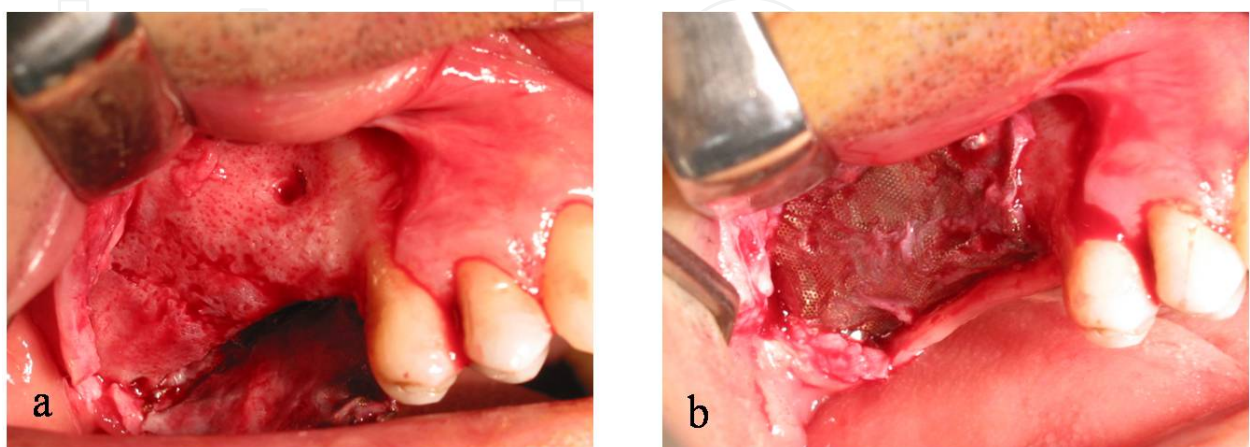


Figure 9. (a) Titanium mesh post-operative 12 months (b) Removal of titanium mesh.

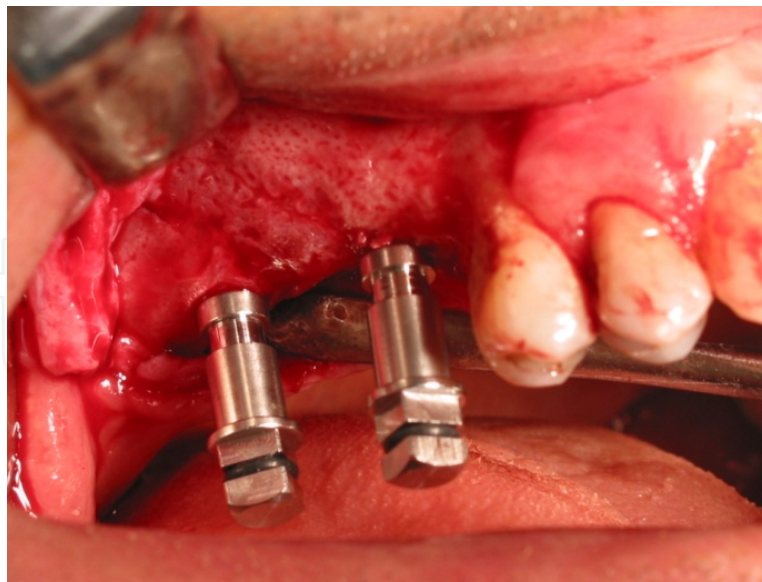


Figure 10. Implant placement

3.2. Lateral ridge augmentation

3.2.1. Ridge splitting

Alveolar bone splitting technique and immediate implant placement have been proposed for patients with narrow alveolar ridge in the horizontal dimension. When the alveolar ridge is narrower than the optimally planned implant diameter, onlays of bone grafting material or guided bone regeneration are indicated [23]. This technique provides a selective cutting, minimal operative invasion and provides an acceptable inter-cortical gap for the placement of particulate bone grafting [24]. The obvious advantage of this technique is the absence of donor site morbidity associated to autologous bone harvesting. Crestal split augmentation involved a surgical osteotomy that was followed by alveolar crest split and augmentation after buccolingual bony plate expansion, prior to implantation [25].

Specific disadvantages have also been reported for each technique: resorption, limited amount of bone, damaging soft tissues, such as sinus floor membrane, nerves and vessels in bone grafting; tissue dehiscence, membrane displacement and membrane collapse in guided bone regeneration; and insufficiency of the distraction line, bone resorption, deficiency of bone formation and increased healing time for implant placement, in alveolar distraction [26-28].

50-year-old male patient referred to our clinic with atrophy of the alveolar rim in the posterior maxilla, which had inadequate width and height for implant placement (Figure 11).

A pre-operative computerized tomographic (CT) scan revealed 2.5-3 mm. of bone weightand-height of themolarareawas 5.64 mm. between the alveolar crest and maxillary sinus (Figures. 12a,b, 13a). We planned segmental split osteotomy, socket lifting and three dental implant placement at the same section without using any graft materials.

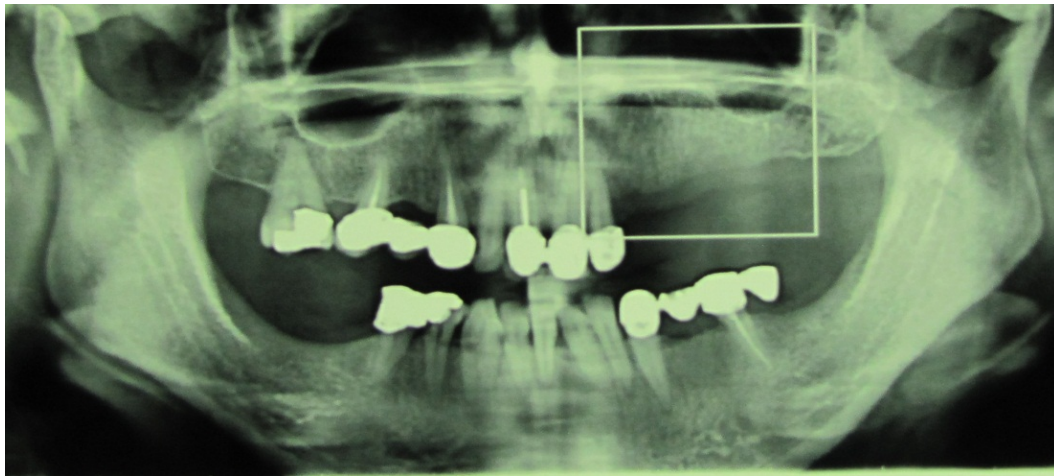


Figure 11. Pre-operative radiograph of the left posterior edentulous maxilla

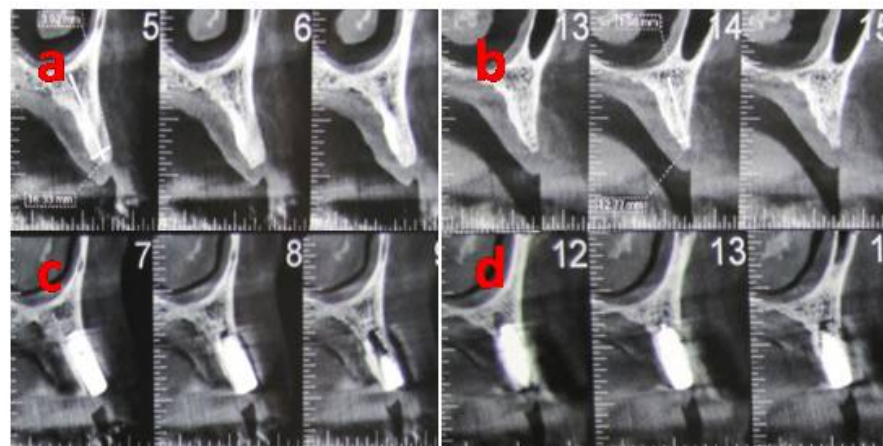


Figure 12. (a-b) Pre-operative CT scan (c-d) Post-operative CT scan

The surgical procedure was performed under local anesthesia. Full thickness muco-periosteal flap was elevated with vertical and crestal incisions. Ridge splitting was applied with osteotome 8 mm/Obwegeser (Ace Surgical Supply Co., Brockton, MA, USA), after the crest being prepared with surgical diamond disc in straight high speed handpiece (Figure 14-15). One centimeter penetration of the osteotome blade in ridge crest would automatically expand the ridge. Since osteotome thickness increases from tip toward shaft further the osteotome penetrates, more the ridge will expand. Slight bucco-lingual movement of the osteotome increases the expansion. 3.5x12 mm implants were placed in the canine and first premolar region into the ridge splitted crest (Figure 16-17). Muco-periosteal flap were sutured primerly by using 3.0 silk suture (Starmedix LLC, Miami, FL, USA).

The present study reports that the clinical results of narrow ridge splitting. Post-operative panoramic radiograph (Figure 8) and CT scan (Figure 13b) showed therewas not any compli-cations around the implants and maxillary sinus. Five months after surgery, final fixed prosthetic restorations were accomplished.

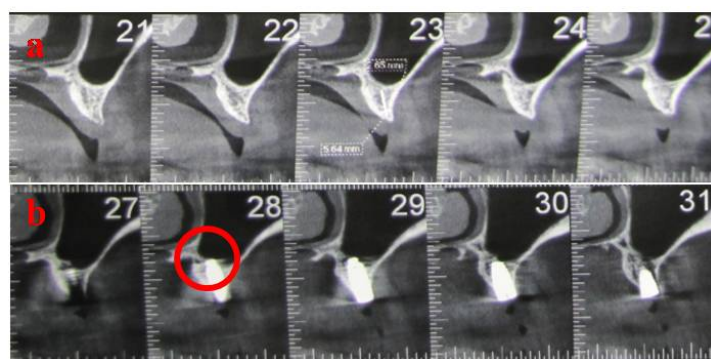


Figure 13. (a) Pre-operative CT scan (b) Post-operative CT scan

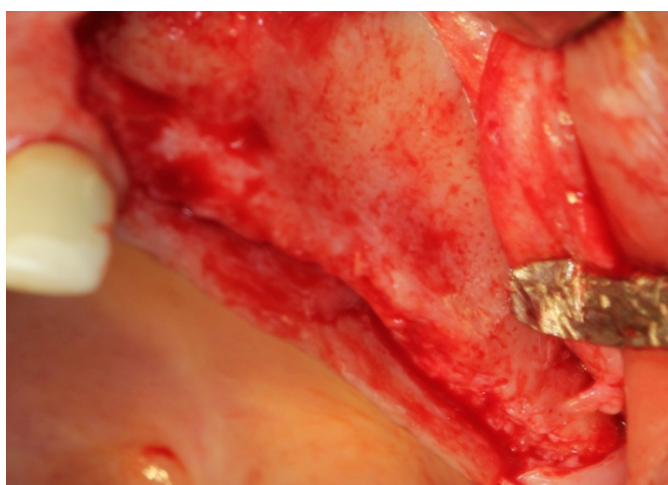


Figure 14. Pre-operative view of alveolar ridge

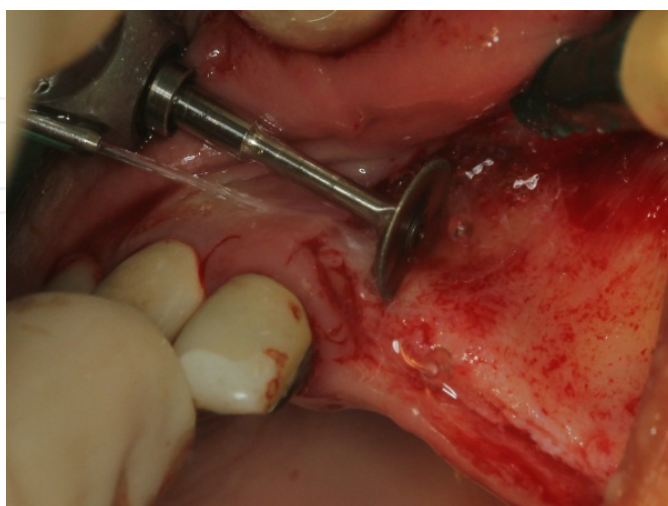

Figure 15. Ridge splitting procedure with diamond disc

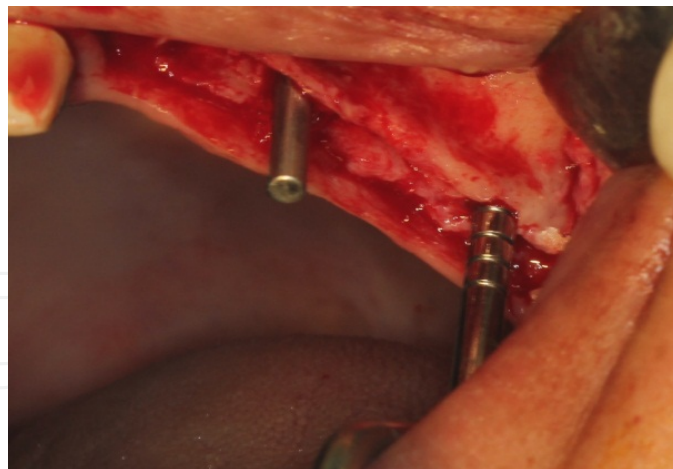


Figure 16. Implant placement

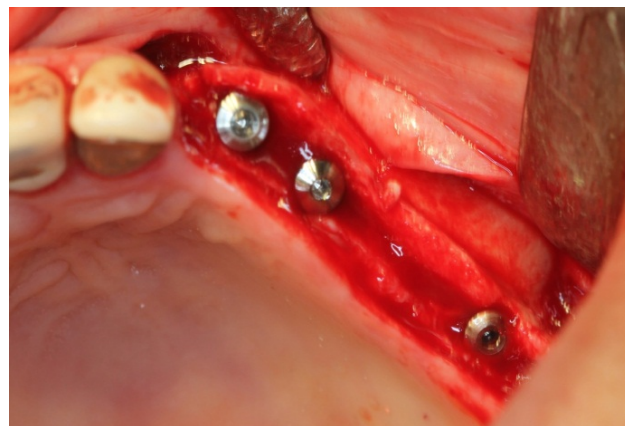


Figure 17. Post-operative view after implant placement

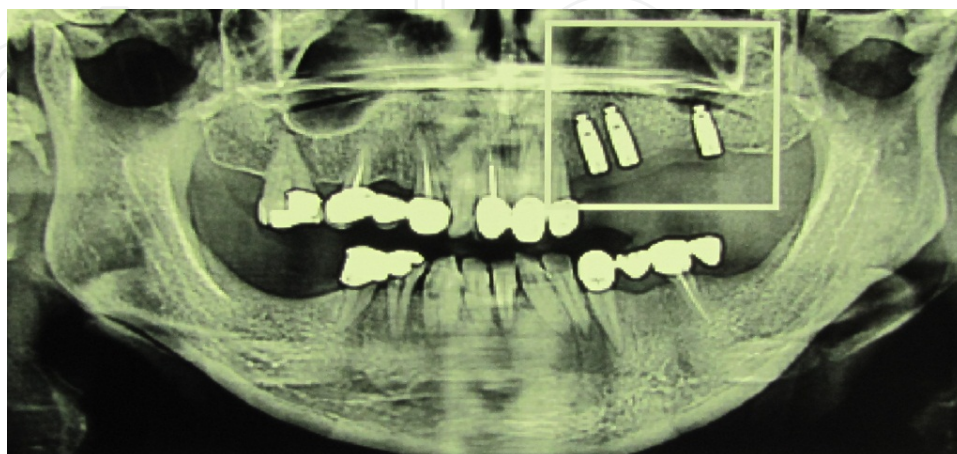


Figure 18. Post-operative panoramic radiograph

3.2.2. Autogenous block graft

Currently, various augmentation procedures have been introduced to rehabilitate atrophic maxillary ridges in literature [29-32]. The grafting procedure using autogenous bone block is considered ideal by many researchers, as it shows osteogenic capability and deformation resistance [33]. A wide range of bone grafts and synthetic bone graft materials have been used in the last two decades for augmentation of inadequate alveolar ridge to facilitate the placement of dental implants of partially and completely edentulous patients. Various bone graft types, including autogenous, allogeneic (human), xenogeneic (porcine, equine, or bovine, and synthetic calcium-based materials (calcium phosphates [β -tricalcium phosphate/ β -TCP, hydroxyapatite/HA], bioactive glasses), calcium sulfate, calcium hydroxide), and a combination of these with or without the use of membrane and screws have been employed for grafting procedure [34-37]. Although, allogeneic bone grafts do not have the drawbacks of autografts, the procedure is more delicate and less successful in clinical practice. They also display several other disadvantages: risk of disease transmission of the donor site, infection, difficulties in obtaining and processing, possible rapid resorption [38,39], and partial loss of mechanical strength after sterilization [40]. Xenogenic bone substitutes of porcine, bovine, or, more recently, equine origin are used because of their chemical and structural composition similarity when compared to human bone [32]. They represent an unlimited supply of available material and may reduce morbidity by eliminating the donor site [31]. Heat or other treatments are used to deproteinate bone particles and eliminate immunogenicity risks [40]. Synthetic calcium phosphate ceramics with their excellent biocompatibility are common alternatives to autogenous bone [41]. Autogenous bone grafts have been widely accepted as “gold standard” due to their compatibility and osteogenic potentials to form the new bone by processes of osteogenesis, osteoinduction, and osteoconduction. A particulate and block autogenous bone has been used to compensate of alveolar ridge deficiency [42]. Extraoral sites of autogenous block grafts are ilium, calvarium, tibia, rib, and others. The most widely used intraoral potential sites of autogenous block grafts include symphysis and retromolar-ramus areas. In the clinical practice, a maxillary tuberosity bone graft has been also used as a particulate graft for augmentation procedures in posterior maxilla prior to or simultaneously with implant insertion [43]. Some of advantages about the autogenous block graft procedure such as; intra- and extra-oral donor site morbidity, potential complications and risks associated with the harvesting procedures may have been reported [44].

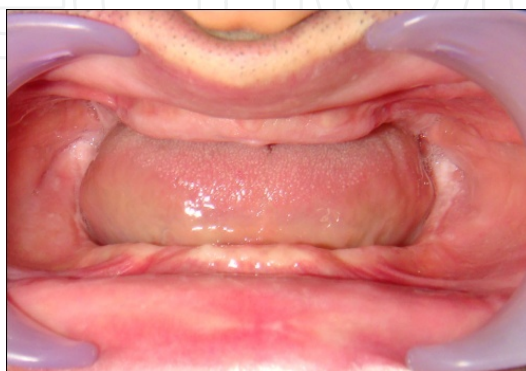

Figure 19. Pre-operative view

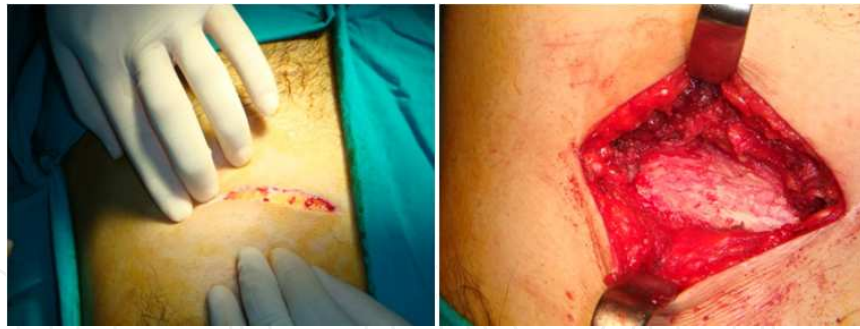

Figure 20. Operation site of the rib




Figure 21. Autogenous rib block graft

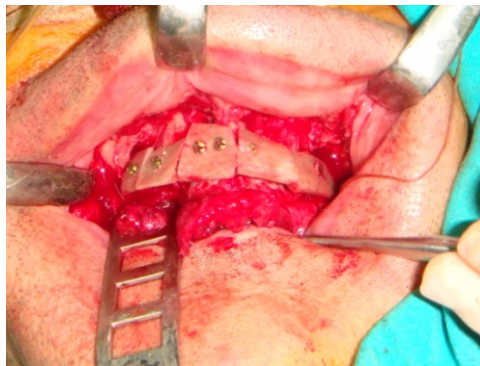


Figure 22. Lateral augmentation procedure of the maxilla with autogenous rib graft

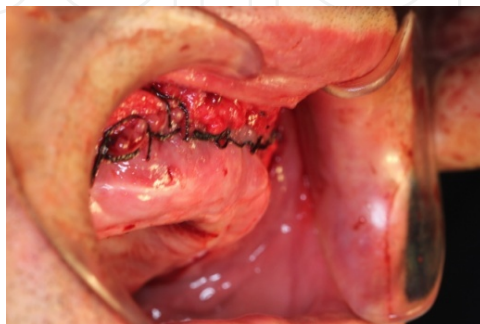


Figure 23. Post-operative intraoral view after rib grafting

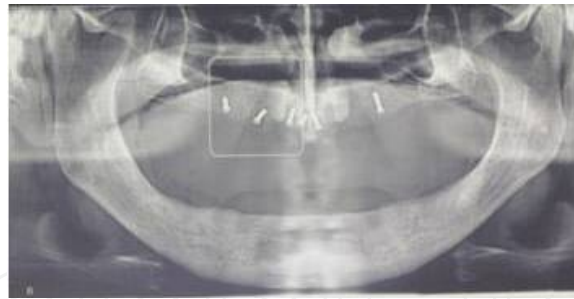


Figure 24. Post-operative panoramic radiograph of the graft

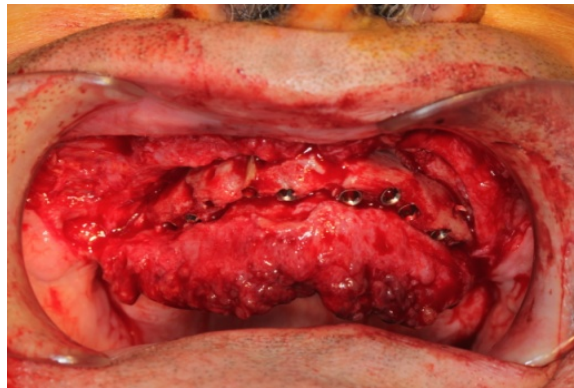


Figure 25. Implant placement four months after the augmentation procedure

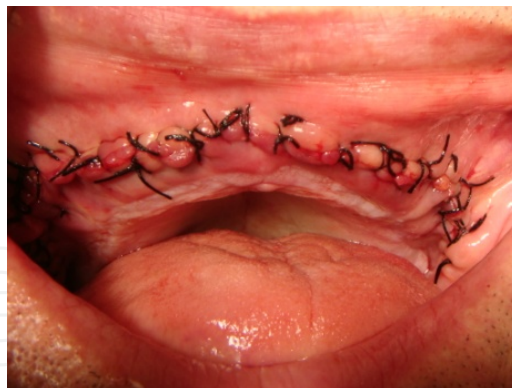

Figure 26. Post-operative intraoral view after implant surgery

4. Zygomatic implants

Maxillary posterior defects that occur after tumor resection or trauma are challenging to reconstruct and rehabilitate. The aim of rehabilitation is not only to provide a cosmetically acceptable appearance, but also to restore oral functions, such as deglutition, mastication, and

phonation [45]. The impossibility of placing conventional implants in posterior maxilla due to maxillectomy, maxillary sinus pneumatization or the lack of bone volume is currently the main indication for the usage of zygomatic implants [46].

Various reconstructive approaches, involving differing surgical procedures, graft materials and endosseous implant systems, have been described for reconstruction of patients with severe resorption of alveolar bone, and also patients who have undergone maxillary resection for neoplastic disease. Restorative techniques have been emphasized such as; microvascular free flaps, local flaps, and obturator prosthesis [47,48]. However, significant obturator retention and stability problems occur when extensive defects remain following a maxillectomy. Zygomatic implants are an effective treatment alternative to limit free or vascularized bone graft procedures, employing the zygomatic bone as anchorage. When determining zygomatic implant rehabilitation, the patient must present not only resorption of posterior maxilla preventing the placement of additional fixations for supporting the prosthesis, but also sufficient bone volume in the anterior maxilla -with a 10 mm in height and a 4 mm in width- to allow the placement of 2-4 conventional fixations [49].

Zygomatic implants were firstly introduced by Branemark in 1998 to rehabilitate the masticatory and aesthetic functions in severe atrophied maxilla caused by trauma, congenital conditions, tumour resection or increased sinus pneumatization. Given the high success rate reported for zygomatic implant placement, this surgical technique can be considered as a valid alternative therapeutic approach to bone grafting and invasive surgery to restore function and improve the esthetic results for patients with atrophic edentulous maxilla [50,51]. The surgical manipulation may lead to potential risk because of the drill way is close to critical anatomical vital structures, such as the maxillary sinus, the nasal cavity, and the eyes [52]. However the limited intraoperative visibility, especially given the anatomical intricacies of the curved zygomatic bone, makes this kind of surgery a demanding procedure. Traditional complications of this surgery are secondary infection, sinusitis, pain, periimplantitis and bone resorption related to implant function [46,53]. The surgical approach consists of using the frontal part of the zygomatic bone as an anchorage for zygomatic implant, with support from the maxillary palatal or alveolar bone, without any bone augmentation. This offers a more simplified treatment approach, a decrease in biological impact and a more comfortable post-surgical period for the patient thanks to a quicker recovery time [49].

5. Angulated implants

Angulated implant treatment of the maxilla requires presurgical prosthetic treatment planning for high smile line esthetics to be acceptable [54]. This requires bone removal in the vast majority of dentate or edentulous patients who undergo full arch treatment. The use of angulated implants for short-span bridges or even long-span reconstructions to avoid bone grafts has been used for 10 years, although many of these were not immediately loaded [55]. However, with the advent of the angulated implant immediate function, this became consistently possible using a graftless protocol [56]. Angulated implant concept consists that to avoid the anatomical structures in the posterior regions by using implants just anterior to the

maxillary sinus in the maxilla and anterior to mental foramen in the mandible by having them placed on a 30-45 degree angle. This concept solves the problem of insufficient bone and reduces the need for sinus and ridge augmentation.

Angulated implant treatment concept may not be considered or adopted as a conventional treatment modality by many clinicians. This treatment concept refers four implants to support a fixed prosthesis. However, long-term clinical results are inadequate on the effects of angulation on the development and distribution of the loading stress within the implant [57].

Author details

Umit Karacayli^{1*}, Emre Dikicier² and Sibel Dikicier³

*Address all correspondence to: ukaracayli@gmail.com

1 Department of Oral and Maxillofacial Surgery, Gulhane Military Medical Academy, Ankara, Turkey

2 Department of Oral and Maxillofacial Surgery, Corlu Military Hospital, Tekirdag, Turkey

3 Department of Prosthodontics, Corlu Military Hospital, Tekirdag, Turkey

References

- [1] Caudry, Landzberg M. Lateral window sinus elevation technique: Managing Challenges and complications. *Journal of Canadian Dental Association* 2013;79:d101. <http://www.jcda.ca/article/d101>
- [2] Khojasteh A, Soheilifar S, Mohajerani H, Nowzari H. The effectiveness of barrier membranes on bone regeneration in localized bony defects. A systematic review. *International Journal of Oral and Maxillofacial Implants* 2013;28(4):1076-89.
- [3] Rodoni LR, Glauser R, Feloutzis A, Hammerle CH. Implants in the posterior maxilla: a comparative clinical and radiologic study. *International Journal of Oral and Maxillofacial Implants* 2005;20(2):231-7.
- [4] Bell GW, Joshi BB, Macleod RI. Maxillary sinus disease: diagnosis and treatment. *Brazilian Dental Journal* 2011;210(3):113-8.
- [5] Troedhan A, Kurrek A, Wainwright M. Biological principles and physiology of bone regeneration under the schneiderian membrane after sinus lift surgery: A Radiological study in 14 patients treated with the transcrestal hydrodynamic ultrasonic cavitation sinus lift (Intralift). *International Journal of Dentistry* 2012; doi: 10.1155/2012/576238 [Epub ahead of print].

- [6] Bensaha T. Evaluation of the capability of a new water lift system to reduce the risk of schneiderian membrane perforation during sinus elevation. *International Journal of Oral and Maxillofacial Surgery* 2011;40(8):815-20.
- [7] Felice P, Pistilli R, Piattelli M, Soardi E, Barausse C, Esposito M. 1-stage versus 2-stage lateral sinus lift procedures: 1-year post-loading results of a multicentre randomised controlled trial. *European Journal of Oral Implantology* 2014;7(1):65-75.
- [8] Pariente L, Dada K, Daas M. Mini-lateral windows for minimally invasive maxillary sinus augmentation: case series of a new technique. *Implant Dentistry* 2014;23(4):371-7.
- [9] Simon BI, Greenfield JL. Alternative to the gold standard for sinus augmentation: osteotome sinus elevation. *Quintessence International* 2011;42(10):863-71.
- [10] Romero-Millan J, Martorell-Calatayud L, Penarrocha M, Garcia-Mira B. Indirect osteotome maxillary sinus floor elevation: an update. *Journal of Oral Implantology* 2012;38(6):799-804.
- [11] Wen SC, Chan HL, Wang HL. Classification and management of antral septa for maxillary sinus augmentation. *International Journal of Periodontics and Restorative Dentistry* 2013;33(4):509-17.
- [12] Calin C, Petre A, Drafta S. Osteotome-mediated sinus floor elevation: a systematic review and meta analysis. *International Journal of Oral and Maxillofacial Implants* 2014;29(3):558-76.
- [13] Urban IA, Nagursky H, Church C, Lozada JL. Incidence, diagnosis, and treatment of sinus graft infection after sinus floor elevation: a clinical study. *International Journal of Oral and Maxillofacial Implants* 2012;27(2):449-57.
- [14] Butura CC, Galindo DF. Implant placement in alveolar composite defects regenerated with rhBMP-2, anorganic bovine and titanium mesh: a report of eight reconstructed sites. *International Journal of Oral and Maxillofacial Implants* 2014;29(1):139-46.
- [15] Sjöström T, McNamara LE, Meek RM, Dalby MJ, Su B. 2D and 3D nanopatterning of titanium for enhancing osteoinduction of stem cells at implant surfaces. *Advanced Healthcare Materials* 2013;2(9):1285-93.
- [16] Egusa H, Sonoyama W, Nishimura M, Atsuta, Akiyama K. Stem cells in dentistry-Part II: Clinical applications. *Journal of Prosthodontic Research* 2012; 56(4):229-48.
- [17] Rakhmatia YD, Avukawa Y, Furuhashi A, Koyano K. Current barrier membranes: titanium mesh and other membranes for guided bone regeneration in dental applications. *Journal of Prosthodontic Research* 2013;57(1):3-14.
- [18] Miyamoto I, Funaki K, Yamauchi K, Kodama T, Takahashi T. Alveolar ridge reconstruction with titanium mesh and autogenous particulate bone graft: computed to-

- mography-based evaluations of augmented bone quality and quantity. *Clinical Implant Dentistry and Related Research* 2012;14(2):304-11.
- [19] Funato A, Ishikawa T, Kitajima H, Yamada M, Moroi H. A novel combined surgical approach to vertical alveolar ridge augmentation with titanium mesh, resorbable membrane, and rhPDGF-BB: a retrospective consecutive case series. *International Journal of Periodontics and Restorative Dentistry* 2013;33(4):437-45.
 - [20] Her S, Kang T, Fien MJ. Titanium mesh as an alternative to a membrane for ridge augmentation. *Journal of Oral and Maxillofacial Surgery* 2012;70(4):803-10.
 - [21] Moroi A, Ueki K, Okabe K, Marukawa K, Sotobori M, Mukozawa A, Miyazaki M. Comparison between unsintered hydroxyapatite/poly-L-lactic acid mesh and titanium mesh in bone regeneration of rabbit mandible. *Implant Dentistry* 2013;22(3):255-62.
 - [22] Hirota M, Ikeda T, Tabuchi M, Iwai T, Tohnai I, Ogawa T. Effect of ultraviolet-mediated photofunctionalization for bone formation around medical titanium mesh. *Journal of Oral and Maxillofacial Surgery* 2014;72(9):1691-702.
 - [23] Cawood JI, Stoelinga PWJ, Blackburn TK. The evolution of pre implant surgery from pre prosthetic surgery. *International Journal of Oral and Maxillofacial Surgery* 2007;36(5):377-85.
 - [24] Rahpeyma A, Khajehahmadi S, Hosseini VR. Lateral ridge split and immediate implant placement in moderately resorbed alveolar ridges: How much is the added width? *Dental Research Journal* 2013;10(5):602-08.
 - [25] Kelly A, Flanagan D. Ridge expansion and immediate placement with piezosurgery and screw expanders in atrophic maxillary sites: two case reports. *Journal of Oral Implantology* 2013;39(1):85-90.
 - [26] Zakhary IE, El-Mekkawi HA, Elsalanty ME. Alveolar ridge augmentation for implant fixation: status review. *Oral Surgery Oral Medicine Oral Pathology Oral Radiology and Endodontology* 2012;114(5):179-89.
 - [27] Khairnar MS, Khairnar D, Bakshi K. Modified ridge splitting and bone expansion osteotomy for placement of dental implant in esthetic zone. *Contemporary Clinical Dentistry* 2014;5(1):110-4.
 - [28] Funaki K, Takahashi T, Yamuchi K. Horizontal alveolar ridge augmentation using distraction osteogenesis: comparison with a bone-splitting method in a dog model. *Oral Surgery Oral Medicine Oral Pathology Oral Radiology and Endodontology* 2009;107(3):350-8.
 - [29] Di Stefano DA, Artese L, Iezzi G, Piatelli A, Pagnutti S, Piccirilli M, Perrotti V. Alveolar ridge regeneration with equine spongy bone: a clinical, histological, and immunohistochemical case series. *Clinical Implant Dentistry and Related Research* 2009;11(2):90-100.

- [30] Davidas JP. Looking for a new international standard for characterization, classification and identification of surfaces in implantable materials: the long march for the evaluation of dental implant surfaces has just began. *Periodontology, Oral Surgery, Esthetic & Implant Dentistry Open Journal* 2014;2(1):1-5. <http://www.poseido.info/publication/volume-2-2014/poseido-2014211-5-davidas.pdf>
- [31] Toeroek R, Ehrenfest DMD. The concept of Screw-Guided Bone Regeneration (S-GBR). Part 3: Fast Screw-Guided Bone Regeneration (FS-GBR) in the severely resorbed preimplant posterior mandible using allograft and Leukocyte-and Platelet-Rich Fibrin (L-PRF): a 4-year follow-up. *Periodontology, Oral Surgery, Esthetic & Implant Dentistry Open Journal* 2013;1(2):85-92. <http://www.poseido.info/publication/volume-1-2013/poseido-20131285-92-toeroek.pdf>
- [32] Traini T, Piatelli A, Caputi S, Degidi M, Mangano C, Scarano A, Perrotti V, Iezzi G. Regeneration of human bone using different bone substitute biomaterials. *Clinical Implant Dentistry and Related Research* 2013 doi: 10.1111/cid.12089 [Epub ahead of print]
- [33] Margonar R, dos Santos PL, Queiroz TP, Marcantonio E. Rehabilitation of atrophic maxilla using the combination of autogenous and allogeneic bone grafts followed by protocol-type prosthesis. *Journal of Craniofacial Surgery* 2010;21(6):1894-6.
- [34] Tadic D, Epple M. A thorough physicochemical characterization of 14 calcium phosphate-based bone substitution materials in comparison to natural bone. *Biomaterials* 2004;25(6):987-94.
- [35] Pietak AM, Reid JW, Stott MJ, Sayer M. Silicon substitution in the calcium phosphate bioceramics. *Biomaterials* 2007;28(28):4023-32.
- [36] Lee MJ, Sohn SK, Kim KT. Effect of hydroxyapatite on bone integration in a rabbit tibial defect model. *Clinics in Orthopedic Surgery* 2010;2(1):90-7.
- [37] Berberi A, Samarani A, Nader N, Noujeim Z, Dagher M, Kanj W, Mearawi R, Saleme Z, Badran B. Physicochemical characteristics of bone substitutes used in oral surgery in comparison to autogenous bone. *Biomedical Research International* 2014; doi: 10.1155/2014/320790 [Epub ahead of print]. <http://www.hindawi.com/journals/bmri/2014/320790/>
- [38] Gomes KU, Martins WD, Ribas Mde O. Horizontal and vertical maxillary osteotomy stability, in cleft lip and palate patients, using allogeneic bone graft. *Dental Press Journal of Orthodontics* 2013;18(5):84-90.
- [39] da Silva Filho OG, Ozawa TO, Bachega C, Bachega MA. Reconstruction of alveolar cleft with allogeneous bone graft: Clinical considerations. *Dental Press Journal of Orthodontics* 2013;18(6):138-47.
- [40] Glovacki J. A review of osteoinductive testing methods and sterilization processes for demineralized bone. *Cell and Tissue Banking* 2005;6(1):3-12.

- [41] Hing KA, Wilson LF, Buckland T. Comparative performance of three ceramic bone substitutes. *Spine Journal* 2007;7(4):475-90.
- [42] McAllister BS, Haghighat K. Bone Augmentation techniques. *Journal of Periodontology* 2007;78:377-96.
- [43] Tolstunov L. Maxillary tuberosity block bone graft: innovative technique and case report. *Journal of Oral and Maxillofacial Surgery* 2009;67(8):1723-9.
- [44] Sullivan JP. Implant placement in the aesthetic zone following an autogenous bone graft from an intraoral site: a case study. *Primary Dental Journal* 2013;2(4):49-55.
- [45] Sudhakar J, Ali SA, Karthikeyan S. Zygomatic implants – A Review. *Journal of Indian Academy of Dental Specialists* 2011;2(2):24-8.
- [46] Aparicio C, Manresa C, Francisco K, Ouazzani W, Claros P, Potau JM. The long-term use of zygomatic implants: a 10-year clinical and radiographic report. *Clinical Implant Dentistry Related Research* 2014;16(3):447-59.
- [47] Zwahlen RA, Gratz KW, Oechslin CK, Studer SP. Survival rate of zygomatic implants in atrophic or partially resected maxillae prior to functional loading: a retrospective clinical report. *International Journal of Oral and Maxillofacial Implants* 2006;21(3):413-20.
- [48] Pi Urgell J, Revilla Gutierrez V, Gay Escoda CG. Rehabilitation of atrophic maxilla: a review of 101 zygomatic implants. *Medicina Oral Patologia Oral y Cirugia Bucal* 2008;13(6):363-70.
- [49] Sorni M, Guarinos J, Peñarrocha M. Implants in anatomical buttresses of the upper jaw. *Medicina Oral Patologia Oral y Cirugia Bucal* 2005;10(2):163-8.
- [50] Stievenart M, Malevez C. Rehabilitation of totally atrophied maxilla by means of four zygomatic implants and fixed prosthesis: a 6-40 months follow-up. *International Journal of Oral and Maxillofacial Surgery* 2010;39(4):358–63.
- [51] Aparicio C, Ouazzani W, Hatano N. The use of zygomatic implants for prosthetic rehabilitation of the severely resorbed maxilla. *Periodontology* 2000 2008;47:162-71.
- [52] Becktor JP, Isaksson S, Abrahamsson P, Sennerby L. Evaluation of 31 zygomatic implants and 74 regular dental implants used in 16 patients for prosthetic reconstruction of the atrophic maxilla with cross-arch fixed bridges. *Clinical Implant Dentistry Related Research* 2005;7(3):159–65.
- [53] Branemark PI, Gröndahl K, Öhrnell LO, Nilsson P, Petruson B, Svensson B, Engstrand P, Nannmark U. Zygoma fixture in the management of advanced atrophy of the maxilla: technique and long-term results. *Scandinavian Journal of Plastic and Reconstructive Surgery and Hand Surgery* 2004;38(2):70-85.
- [54] Jivraj S, Chee W. Treatment planning of implants in the aesthetic zone. *Brazilian Dental Journal* 2006;201(2):77-89.

- [55] Jensen OT, Adams MW, Cottam JR, Parel SM, Phillips WR. The All-on-4 Shelf: Maxilla. *Journal of Oral and Maxillofacial Surgery* 2010;68(10):2520-7.
- [56] Khatami AH, Smith CR. All-on-four immediate function concept and clinical report of treatment of an edentulous mandible with a fixed complete denture and milled titanium framework. *Journal of Prosthodontics* 2008;17(1):47-51.
- [57] Agliard E, Panigatti S, Clerico M, Vila C, Malo P. Immediate rehabilitation of the edentulous jaws with full fixed prostheses supported by four implants: interim results of a single cohort prospective study. *Clinical Oral Implants Research* 2010;21(5):459-65.

