

We are IntechOpen, the world's leading publisher of Open Access books Built by scientists, for scientists

6,900

Open access books available

185,000

International authors and editors

200M

Downloads

Our authors are among the

154

Countries delivered to

TOP 1%

most cited scientists

12.2%

Contributors from top 500 universities



WEB OF SCIENCE™

Selection of our books indexed in the Book Citation Index
in Web of Science™ Core Collection (BKCI)

Interested in publishing with us?
Contact book.department@intechopen.com

Numbers displayed above are based on latest data collected.
For more information visit www.intechopen.com



Ultrasound Axillary Imaging

Nastasia Serban

Additional information is available at the end of the chapter

<http://dx.doi.org/10.5772/59730>

1. Introduction

The most significant prognostic factors in breast cancer are the tumoral diameter, tumor grading and the status of the axillary lymph nodes. The presence of nodal metastases decreases 5-year survival by approximately 40% compared to node-negative patients, in reference [1]. Lymph node status is of particular value in choosing further therapy. Lymph node metastatic disease is an indication for skipping sentinel node biopsy (SLNB) (and proceeding to complete axillary dissection) and/or for adjuvant systemic chemotherapy, which may be of benefit if administered as preoperative treatment.

2. The anatomy of the axillary lymph node

The anatomy of the axillary lymph node includes the cortex and the medulla. The high-frequency probes allow the differentiation of the central echogenic hilum and the peripheral hypoechoic cortex. The cortex, which includes the marginal sinus and the lymphoid follicles is hypoechoic and thin, and has a fusiform shape with smooth edge. The hilum is the hyperechoic, its echogenicity being attributable to multiple reflective interfaces of blood vessels, fat, and the central sinus, in reference [2,3].

Carcinoma from the breast enters the lymph node via the afferent lymphatics, penetrates the capsule, and enters the subcapsular sinus, in reference [4]. Metastatic cells firstly stop in the periphery (cortex) of the nodes, causing cortical enlargement. Then generalized cortical enlargement and destruction of the nodal architecture occurs, with compression and, eventually, loss of the hilum, in reference [2].

3. Assessment of axillary lymph nodes status

Grossly involvement of axillary lymph nodes can be detected by clinical examination, ultrasound or axilla MRI. However, introduction of screening mammography led to earlier diagnosis of breast cancer, in which axillary involvement is frequently absent. The challenge of imaging technique is to differentiate the normal lymph nodes from the nodes with minimal metastatic disease, which do not change the size and shape of the lymph node, in patients with small primary breast tumors.

The “golden standard” for axillary lymph node status is pathological examination of lymph nodes. There are three possibilities to obtain information regarding the axillary lymph nodes status: complete axillary lymph node dissection, biopsy of the sentinel lymph node (SLN) and pretreatment imaging of the axillary lymph nodes, associated or not with fine-needle aspiration cytology or core biopsy of the suspicious nodes.

Complete lymph node dissection represents the classic approach that allows pathological examination of all the lymph nodes in the axilla. However, complete axillary lymph node dissection is accompanied by complications like seroma formation, numbness, limitation of shoulder movement, and lymphedema, in reference [5].

SLN biopsy (SLNB) represents the biopsy of that lymph node, which first collects the lymph from the breast. It is a surgical procedure, requiring preoperative administration of a dye and/or radionuclide tracer.

Pretreatment imaging of the axillary lymph nodes must closely match the pathological findings in order to have any value for clinical decision making. Many studies suggest that patients with axillary involvement may benefit from preoperative systemic treatment. Imaging techniques for axilla include ultrasound, MRI enhanced or nonenhanced, FDG-PET scan, ^{99m}Tc -sestamibi scintigraphy.

4. Ultrasound evaluation of axilla

The most available imaging technique for axilla is ultrasound. Ultrasound has two roles in visualizing the axilla: a) to characterize the abnormal lymph nodes, either identified by US or by clinical examination or other imaging technique and b) to help axillar SLN identification. In both circumstances, ultrasound helps the biopsy of the nodes.

Afferent lymphatic channels enter a node through the periphery of the cortex, so the malignant cells travelling the lymphatic vessel will first stop in the cortical region of the lymph node. Most of the US signs of lymph nodes metastasis will refer to the abnormalities of the cortex. Subtle abnormalities of the cortex can indicate early metastatic involvement.

For the assessment of a lymph node by US, quantitative or qualitative methods have been used.

4.1. The qualitative features of a metastatic lymph node on US

The qualitative features of a metastatic lymph node on US include shape (round morphology), morphology (asymmetric cortical thickening (Figure 1), loss of central hilum, loss of compression of the medullary region (Figure 2), relationship with neighbouring lymph nodes, left-to-right asymmetry and increased peripheral blood flow. Even more, lymph nodes can exhibit hyperechoic medullary region (Figure 2), relationship with neighbouring lymph nodes, left-to-right asymmetry and increased peripheral blood flow. Even more, lymph nodes can exhibit ultrasound malignancy signs characteristic to the primary breast tumor, such as angular margins, taller than wide (Figure 3) or they appear intensely vascularised on Doppler ultrasound. Reactive changes associated with inflammation produce an increase of blood flux in the pre-existing blood vessels, but do not generate new vessel formation or vessels that can penetrate the capsule. Metastatic disease stimulates new vessel formation, but does not generate new vessel formation or vessels that can penetrate the capsule. Metastatic disease stimulates new lymph node and blood vessel formation. Doppler signals inside the lymph node signal vessel penetration of the capsule.

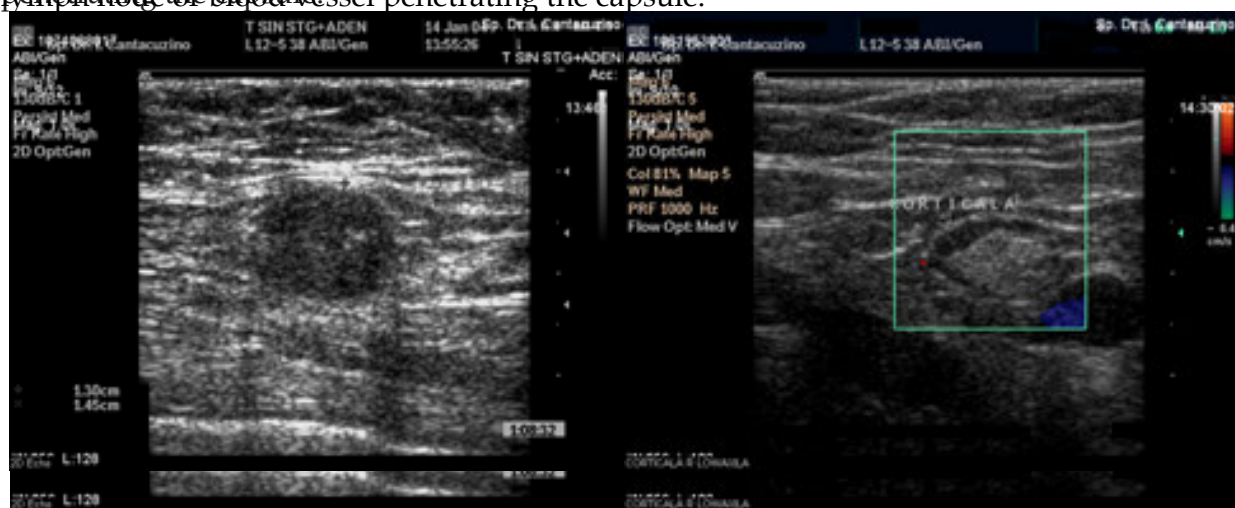

Figure 1. Left: Metastatic lymph node, with a round shape. Invasive ductal carcinoma

Primary tumor of 1.8 cm, three SLNs identified, all of them metastatic and complete axillary dissection. Right: asymmetric cortical thickening (ratio of 1.4 in a metastatic axillary lymph node (with normal the cortex-hilum area ratio)).

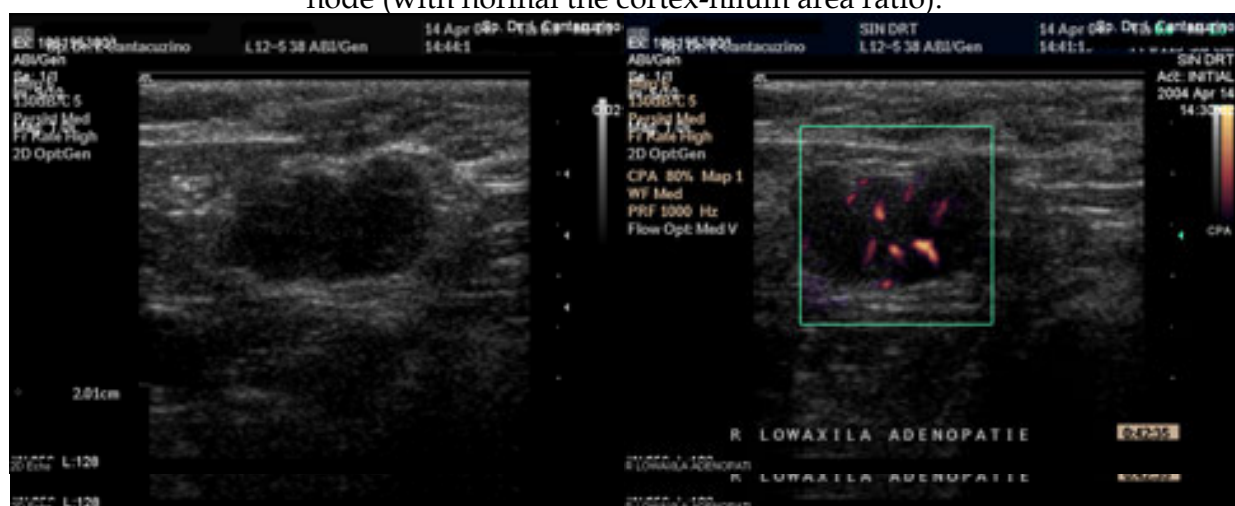


Figure 2. Metastatic lymph node. Left: loss of the hyperechoic medullary region. Right: on power Doppler examination, this node is displaying both central and peripheral blood flow.

lymphadenopathy with increased vascularisation and intact capsule.

4.2 The quantitative indicators of a metastatic lymph node on US

A small study of the author, in reference [8], evaluating 21 consecutive breast cancer patients, in which the SLNB was performed [8], evaluating at ultrasound size of lymph nodes correlates with invasion, of SLNs (Figure 4, left) and size > 1 cm of lymph nodes correlates with invasion of SLN (Figure 4, left).

Song SE et al, in reference [7], evaluated the diagnostic performance for their own positive criteria for lymph node metastasis, such as CH area ratio >2 (Figure 5), LT axis ratio <2 or peripheral type of vascularity on power Doppler imaging. They found that the sensitivity of the CH area ratio was superior to that of the LT axis ratio (94.1% vs. 82.3%, $p=0.031$) and to that of the peripheral blood flow pattern (94.1% vs. 29.4%, $p=0.009$) (Figure 6). For specificity, all three parameters had the same high values (89.1-95.6%; NS).

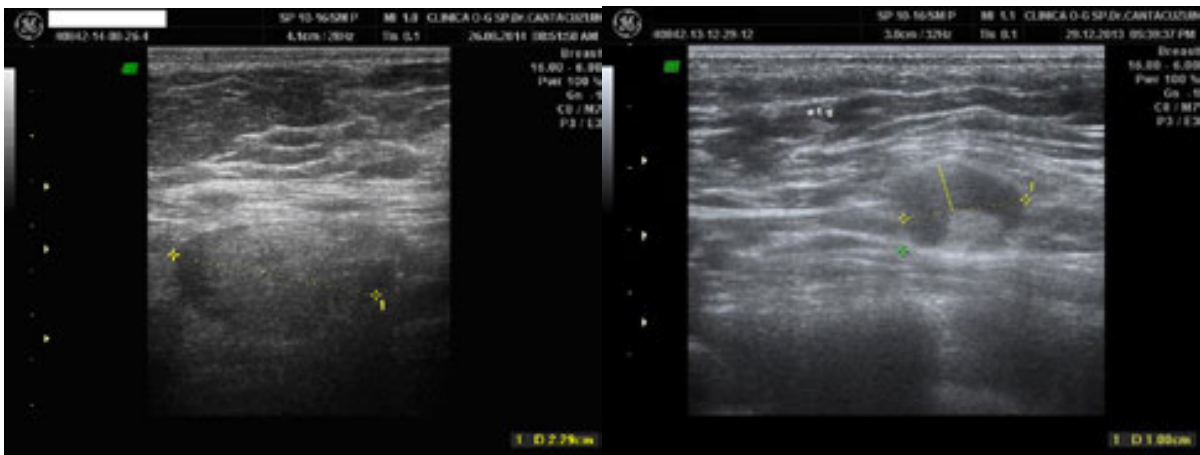


Figure 4. Left: metastatic lymph node, showing increased size (longest dimension of 2,29 cm) in a case of advanced invasive ductal carcinoma. Core biopsy of this node showed invasive ductal carcinoma. Right: maximum thickness of the cortex of 4 mm in a metastatic lymph node (invasive ductal carcinoma).

Cortical region evaluation of absolute cortical thickness and cortical thickness measurement in metastasis (Choi N et al, 2004) is a method that is more accurate than size. The absolute cortical thickness measurement (Figure 4, right), as well as lymph node

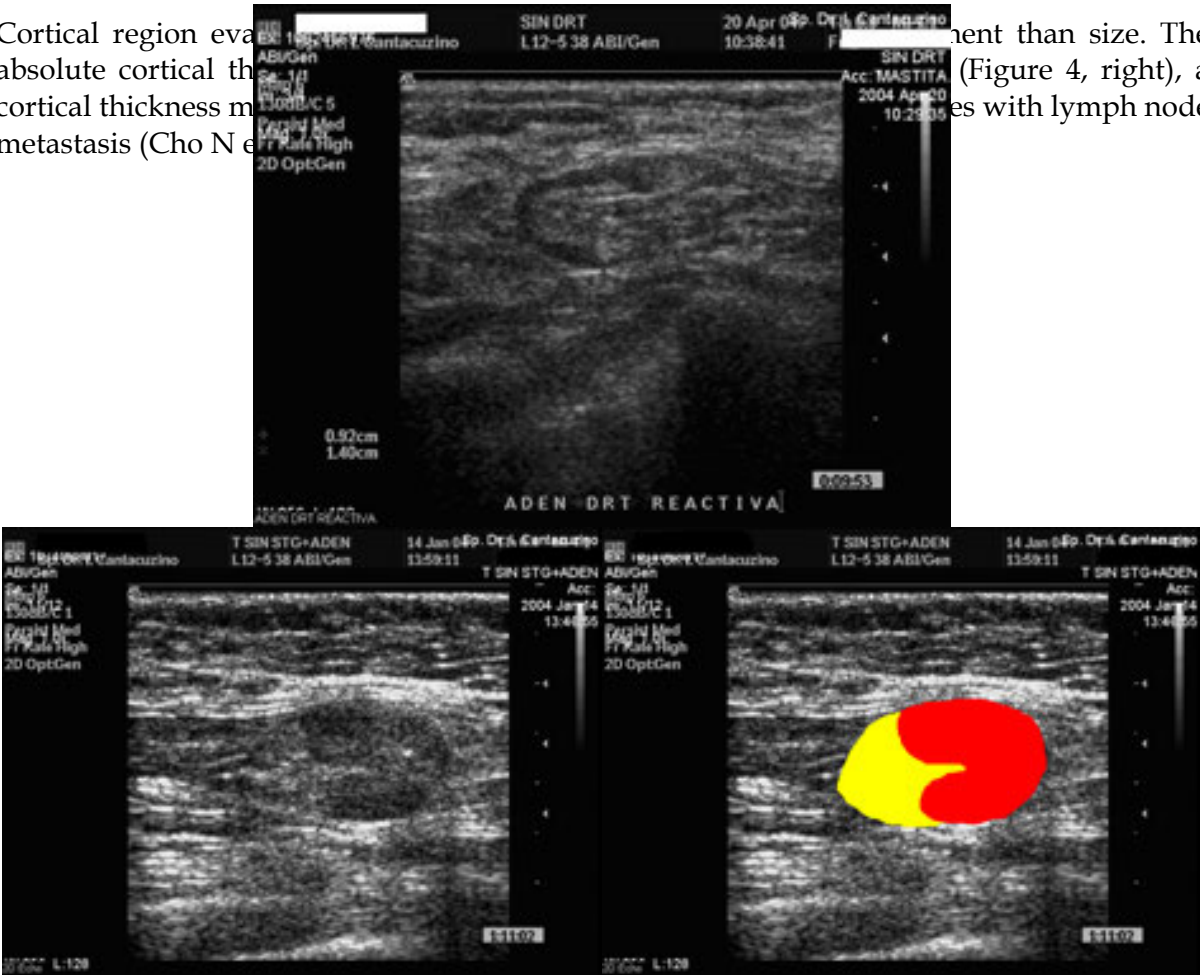


Figure 5. Above: reactive lymphadenopathy in patient with postpartum mastitis. There is moderate and symmetrical increase of cortical thickness, but normal cortical/medullary index. Below: metastatic axillary lymph node with cortical/medullary index of 1.82 and an absolute increase of cortical thickness > 2.5 mm.

Song SE et al, in reference [7], evaluated the diagnostic performance for their own positive criteria for lymph node metastasis, such as CH area ratio >2 (Figure 5), LT axis ratio <2 or peripheral type of vascularisation on power Doppler imaging. They found that the sensitivity of the CH area ratio was superior to that of the LT axis ratio (94.1% vs. 82.3%, p=0.031) and to that of the peripheral blood flow pattern (94.1% vs. 29.4%, p=0.009) (Figure 6). For specificity, all three parameters had the same high values (89.1-95.6%; NS).

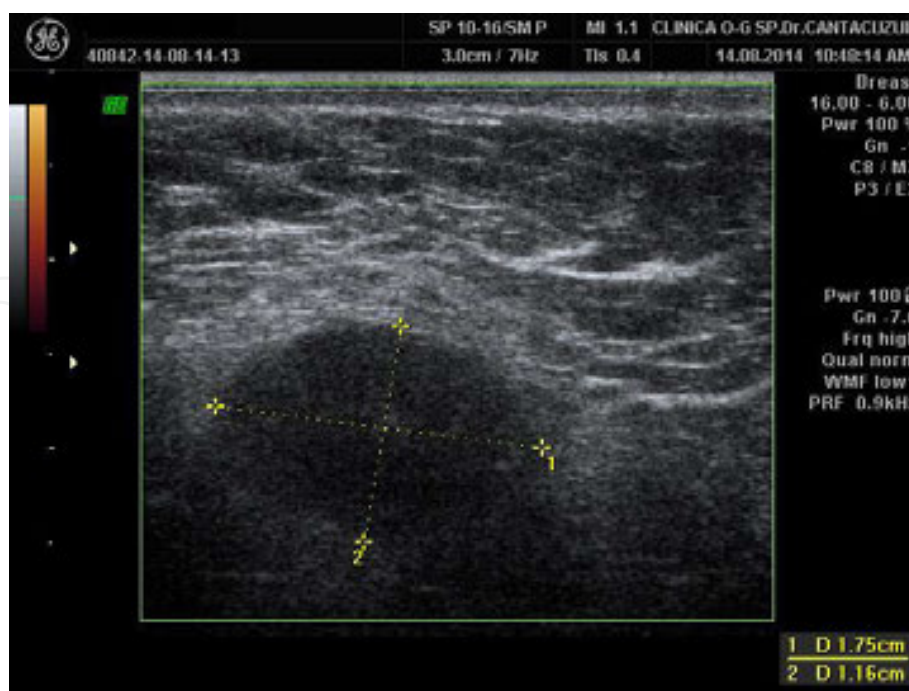

Figure 6. Metastatic axillary lymph node with LT axis ratio of 1.50; blood flow was absent on power Doppler.

4.3. Sonoelastography

Sonoelastography can be added to axillary lymph nodes ultrasound evaluation for further increase the precision of identification of metastatic lymph nodes. At present, there are not many studies trying to establish the place of sonoelastography in evaluation of axillary lymph nodes status. Choi (2011, 64 patients, in reference [9]), Taylor (2011, 50 patients, in reference [10]), Wojcinski (2012, 180 patients, in reference [11]) found that sonoelastography is capable of detecting elasticity differences between the cortex and medulla, and between metastatic and healthy LNs.

Wojcinski et al (2012) found that the highest sensibility (73.3%) is obtained when cortex >3mm in B-mode OR blue cortex in the elastogram, while, when these two features are found together (cortex >3mm in B-mode AND blue cortex in the elastogram (Figure 7)), the highest specificity is obtained (99.3%).

4.4. The role of ultrasound in sentinel lymph node identification and biopsy

Ultrasound has a role in sentinel lymph node identification. With introduction of indocyanine green for sentinel lymph node biopsy (SLNB), Tagaya et al (2010) were able to visualize the fluorescence of lymphatic vessels on the skin. The authors performed firstly intraoperative ultrasonography to identify a SLN as the first lymph node recognized during ultrasonography scanning from the edge of the breast gland in the direction of the axilla and they marked its position on the axillary skin. After indocyanine green dye injection, lymphatic ducts were visualized towards the axilla and the fluorescence stream disappeared approximately 1 cm

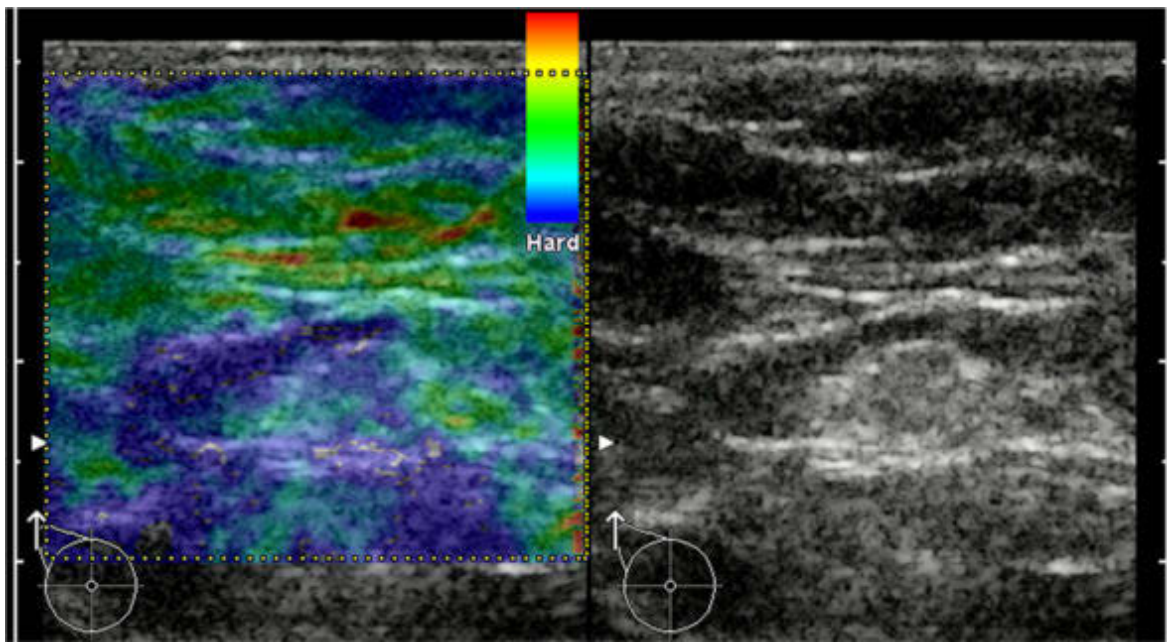


Figure 7. Wojcinski et al, 2012, in reference [11]. Open Access. Example for B-mode ultrasound and elastogram of a metastatic LN. In B-mode ultrasound, the cortex of the LN is slightly enlarged (maximum ~3.5mm). The predominant color of the medulla is turquoise (to green) and the cortex is mainly blue. Meeting both criteria of cortex >3mm in B-mode AND blue cortex in the elastogram, this case would be a true-positive.

before the line marked on the skin for ultrasound SLN location. In this study, the sites of skin incision for SLNB were also identical with the LN that had been demonstrated by ultrasonography in all patients.

Ultrasound signs of SLN involvement could be very subtle, with only a minimal focal cortical thickness increase.

By recognizing the first lymph node during scanning towards axilla (Figure 8), ultrasound may help SLN identification and decrease the operation time, an important fact because as the identification time increase, more SLNs are found.

However, in case of axillary metastases, identification of SLN may be impaired (Esen G, Gurses B, 2005, in [12]).

4.5. The role of ultrasound in imagistic staging of breast cancer

Ultrasound could have a role in imagistic staging of breast cancer. Knowledge of axillary lymph node involvement before surgery may allow for individualization of multimodal treatment. This may include preoperative chemotherapy, intraoperative breast radiotherapy or plastic surgery for immediate reconstruction.

The future protocols of breast cancer treatment will probably include ultrasound as a step in preoperative sentinel node mapping. Ultrasound may reveal abnormalities of axillary lymph nodes and guide biopsy of these nodes.

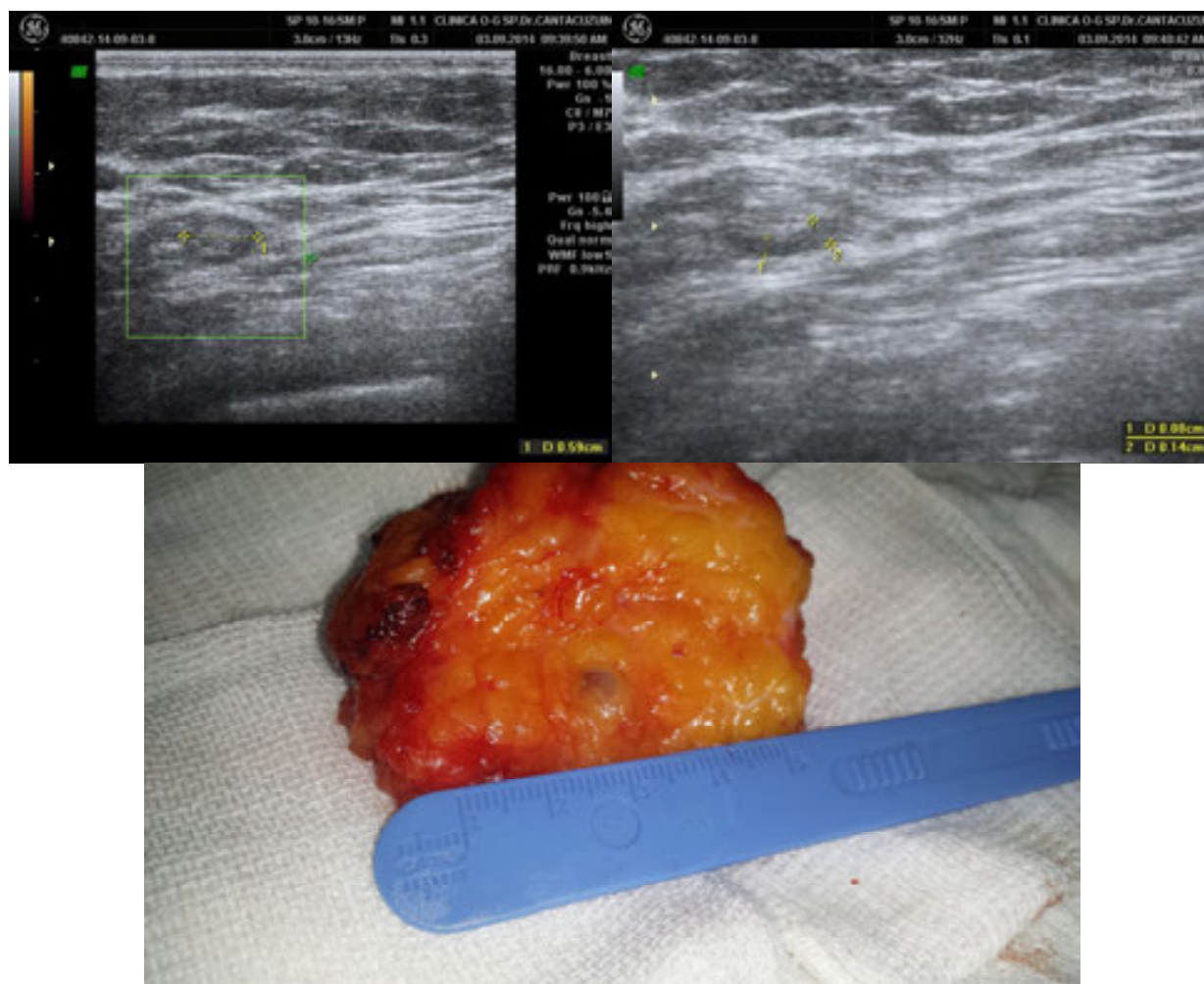


Figure 8: Above: preoperative assessment of axilla in a breast cancer patient with preoperative chemotherapy. The first lymph node during scanning towards axilla: sentinel lymph node with normal size (longest dimension 5.9 mm) and shape, but with small focal cortical thickness. Below: intraoperative identification of SLN. After complete axillary dissection, the sentinel lymph and all the other nodes were negative.

Patients with either normal or abnormal ultrasound exams, but negative cytology, underwent sentinel node mapping. Patients with abnormal ultrasound and positive cytology proceeded by recognizing the first lymph node during scanning towards axilla (Figure 8); ultrasound may help SLN identification and decrease the operation time, an important fact because as the identification time increase, more SLNs are found. There are studies trying to assess the tumoral burden in patient with positive nodes. The study of Moore A et al, in [13], indicates that abnormalities limited to the lymph node cortex (Figure 9) were indicative of N1 disease.

4.5 The role of ultrasound in imaging staging of breast cancer combined with results of cytology or biopsy, could modify the surgical approach to the axilla, eliminating the need for sentinel node mapping in a significant proportion of patients, in reference [13]. Knowledge of axillary lymph node involvement before surgery may allow for individualization of multimodal treatment. This may include preoperative chemotherapy, intraoperative breast and axillary or plastic surgery for immediate reconstruction. Blood flow are predictive of N2–3 disease, in reference [13] (Figure 10).

The future protocols of breast cancer treatment will probably include ultrasound and axillary staging in preoperative sentinel node mapping. Ultrasound may reveal abnormalities of axillary lymph nodes and guide biopsy of these nodes. 31

Patients with either normal or abnormal ultrasound exams, but negative cytology, underwent sentinel node mapping. Patients with abnormal ultrasound and positive cytology proceeded to complete axillary dissection, in reference [13]. There are studies trying to assess the tumoral burden in patient with positive nodes. The study of Moore A et al, in [13], indicates that abnormalities limited to the lymph node cortex (Figure 9) were indicative of N1 disease.

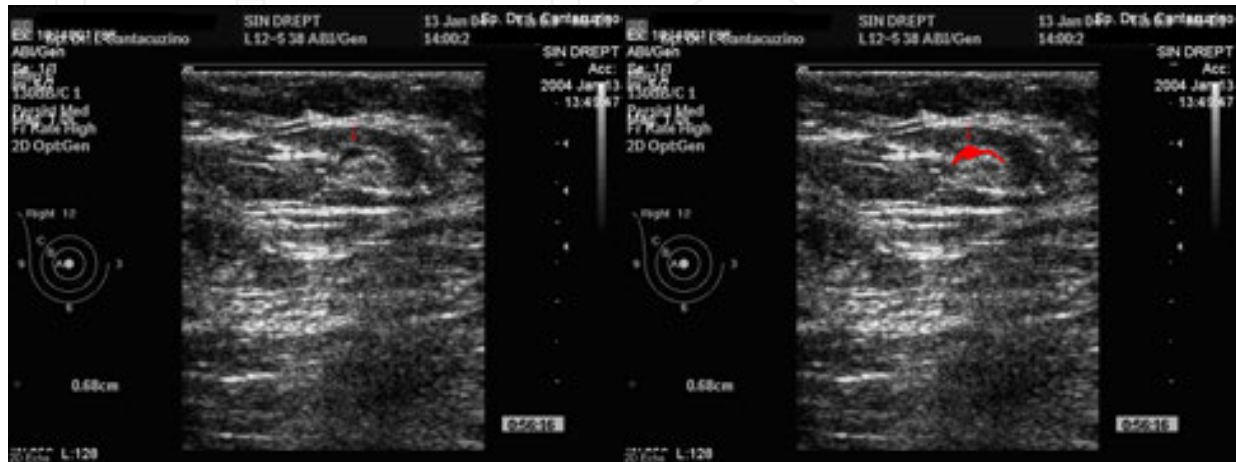

Figure 9. Postoperative assessment of ultrasound. The first lymph node during scanning towards axilla: metastatic sentinel lymph node with normal size and shape, but with small focal cortical thickness. After complete axillary dissection, the sentinel lymph node was the only metastatic lymph node.

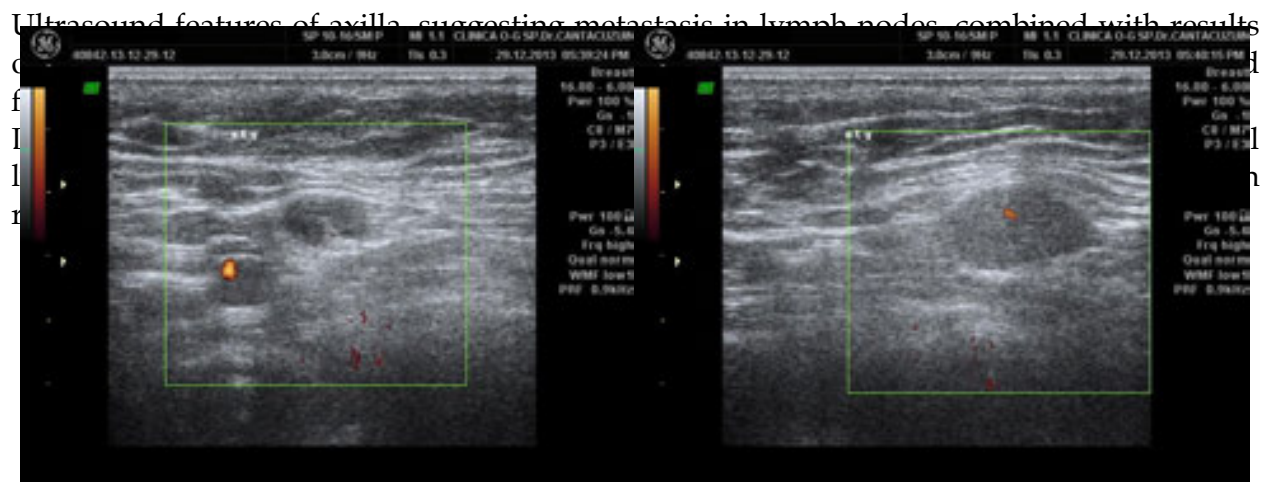


Figure 10. Left and right same case: advanced ductal carcinoma (T2 N2 M0). These lymph nodes displaying the features of metastatic disease. Axillary metastases were confirmed by core biopsy, and the patient was referred to preoperative chemotherapy.

Preoperative ultrasound procedures with ultrasound-guided biopsy can be used for preoperative axillary staging in patients who will be referred to preoperative systemic therapy. Study of Jorgensen et al, in reference [14], showed that planning and initiation of preoperative axillary dissection can reliably be done using ultrasound axillary evaluation and biopsy.

4.6 Percutaneous biopsy procedures

Unfortunately, no imaging technique has enough reliability to attribute patients directly to complete axillary dissection, without first performing SLNB. The study of Valente SA, Sener SF et al, in [15], evaluated retrospectively 244 consecutive patients diagnosed with invasive breast carcinoma, by physical examination of the axilla, digital mammography, axillary

SF et al, in [15], evaluated retrospectively 244 consecutive patients diagnosed with invasive breast carcinoma, by physical examination of the axilla, digital mammography, axillary ultrasonography, and contrast enhanced breast magnetic resonance imaging. The authors found that from the patients who had all four modalities negative, 14% were ultimately found to have histologically positive nodes at the time of surgery.

The role of ultrasound in staging breast cancer differs with stage of disease, helping treatment decisions for surgery, chemotherapy, and radiation therapy.

4.6.1. Percutaneous biopsy procedures in operable breast cancer

In operable breast cancer, ultrasound helps identification of sentinel lymph node and of suspicious nodes, that warrant biopsy. Ultrasound alone has modest accuracy in detecting axillary metastasis, not being reliable, on its own, to make a decision in surgical treatment of the axilla. Ultrasound does not provide enough information to refer patients to complete axillary dissection.

The reported a median ultrasound sensitivity, in a meta-analysis of 21 studies, including 4313 patients, made by Houssami et al, was 61.4% [51.2%-79.4%], and the median ultrasound specificity was 82.0% (76.9%-89.0%), in reference [16]. Adding a axillary biopsy procedure to ultrasound, to assess patients with abnormal or suspicious axillary nodes, leads to a good sensitivity and excellent specificity (nearly 100%). The same meta-analysis, made by Houssami et al, in [16], evaluated 1733 patients, in whom needle biopsy was added and guided by ultrasound, because of abnormal findings. In these patients, the ultrasound-guided biopsy had median sensitivity of 79.4% (68.3%-89.9%) and a median specificity of 100% (100%-100%).

The study of Holwit DM, Margenthaler JA, in [17], retrospectively performed on 256 patients with clinically node-negative breast cancer, who underwent axillary ultrasound (AUS) evaluation and ultrasound-guided FNAB/needle core biopsy only in suspicious-appearing lymph nodes, found that the sensitivity and specificity of axillary ultrasound alone were 79% and 81%, respectively. The overall combined sensitivity and specificity for AUS-guided FNAB/needle core biopsy were 71% and 99%, respectively, with a negative predictive value of 84% and a positive predictive value of 97%.

Axillary UNB has a good clinical utility, based on a meta-analysis of Houssami N, Diepstraten SCE et al, in [18], on 7097 patients, with a percent of 18.4% of patients effectively referred to axillary treatment thus avoiding SNB.

4.6.2. Percutaneous biopsy procedures in locally advanced breast cancer

Locally advanced stages of the disease are usually associated with obvious ultrasound features of axillary node involvement, and ultrasound helps the biopsy of these nodes, in most cases referring the patient to systemic preoperative treatment.

Ultrasound examination and US-guided biopsy may be the only possibility to diagnose the breast cancer that presents with no identifiable breast tumor and clinically positive axillary metastasis only. When mammography is negative, biopsy of the clinically positive lymph node is the only

way to obtain a specimen for pathology and ultrasound could help localization and guiding the procedure.

The advantages of preoperative systemic therapy include the potential downsizing of large tumors for either conversion of inoperable disease to resectable lesions or conversion of patients to breast conservation therapy, and in vivo assessment of the response of the tumor to chemotherapy, in reference [19]. Algorithms were issued for attributing patients to preoperative systemic therapy.

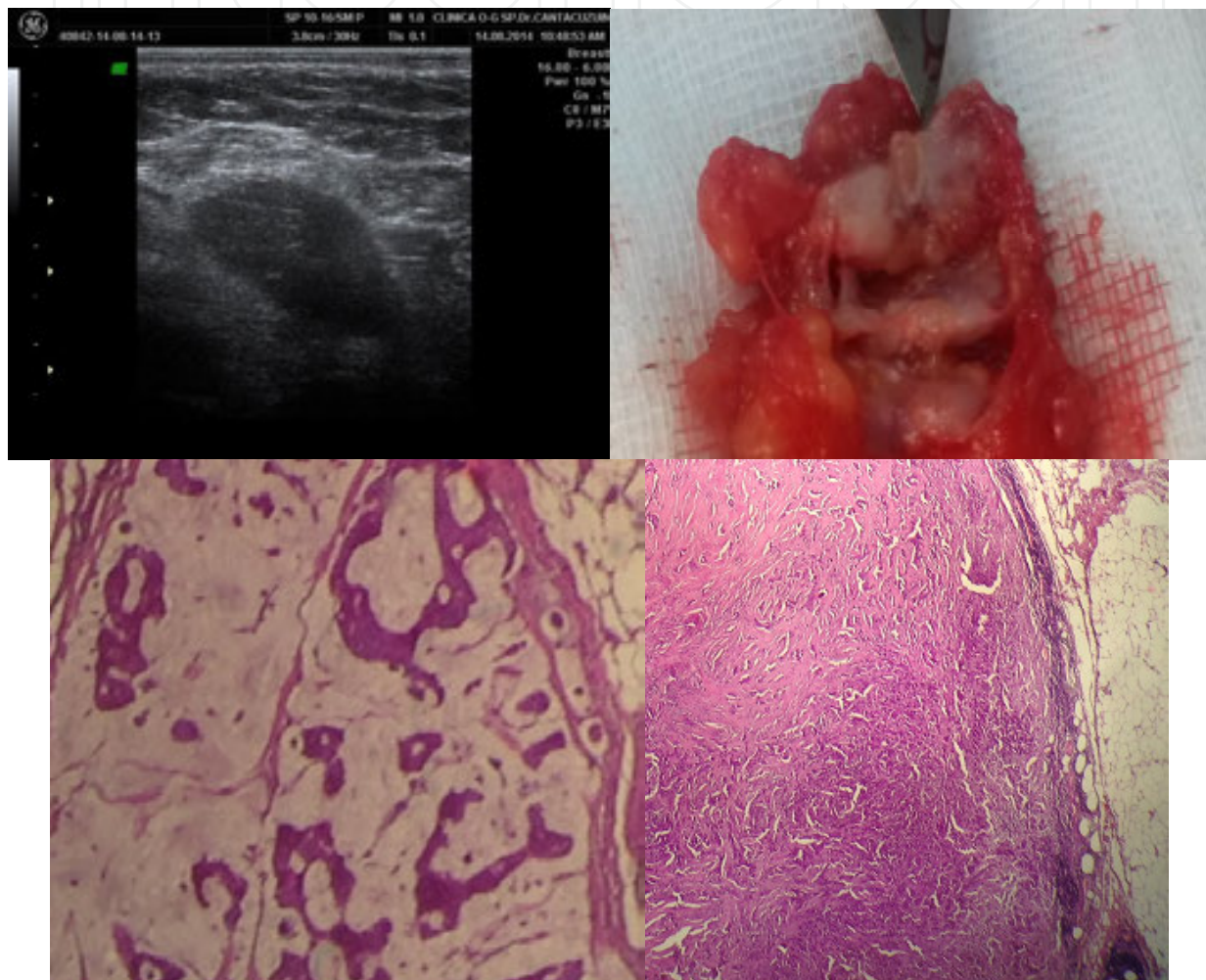


Figure 11. Patient presenting with palpable axillary lymph node. No breast tumor could be identified (mammography negative). Multiple passes were performed on the breast for core-biopsy, and the palpable node was removed by open surgery. Pathology showed axillary metastasis of invasive ductal carcinoma, with areas of mucinous carcinoma and failed to confirm the presence of the disease at the breast level.

The advantages of preoperative systemic therapy include the potential downsizing of large tumors for either conversion of inoperable disease to resectable lesions or conversion of patients to breast conservation therapy, and in vivo assessment of the response of the tumor to chemotherapy, in reference [19]. Algorithms were issued for attributing patients to preoperative systemic therapy.

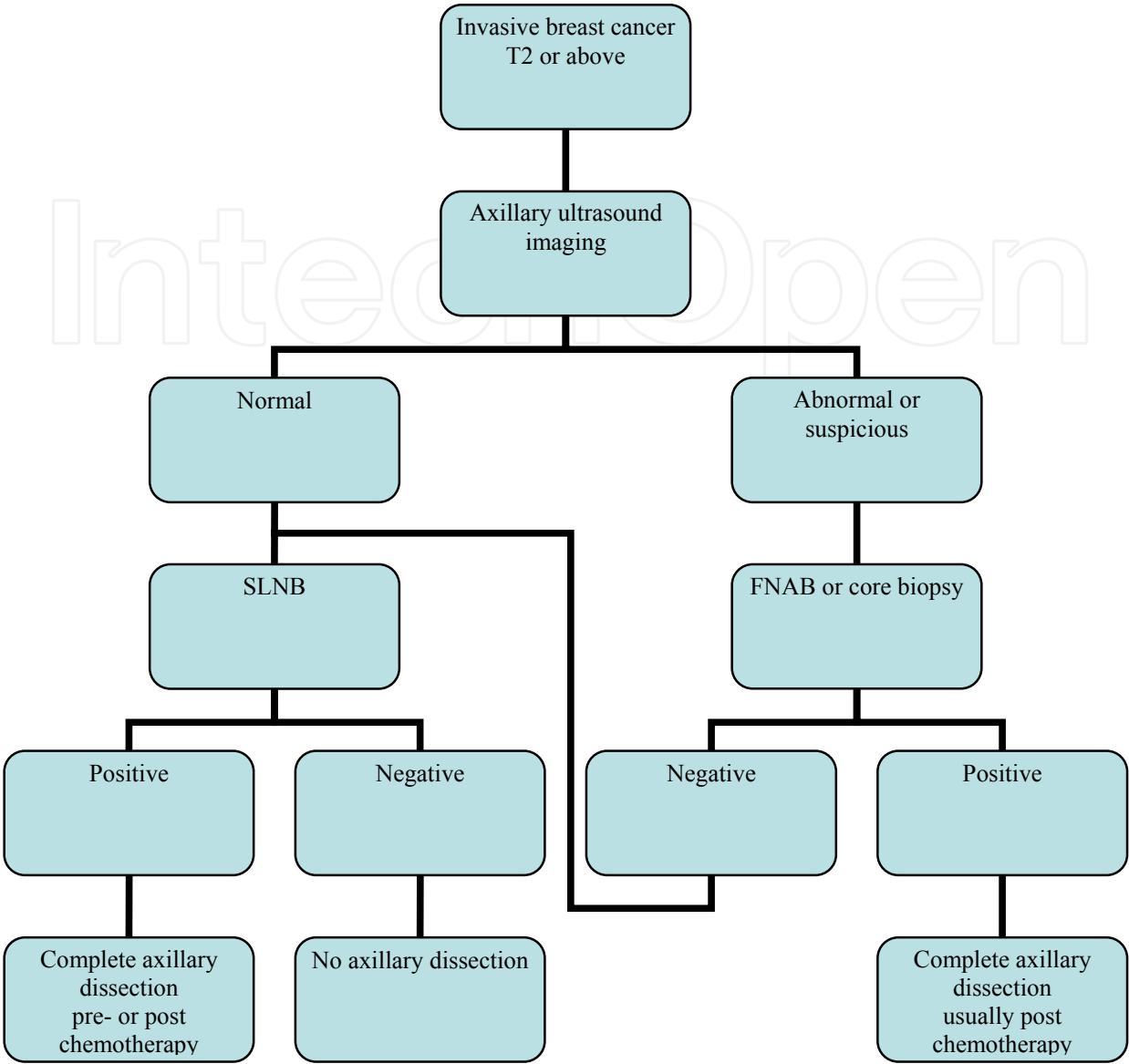


Figure 12. Algorithm for axillary assessment in patients with locally advanced invasive breast cancer (adapted from Lee MC et al, in [20]).

Lee et al, in [20], consider sonographically detected axillary metastases as a clinically positive axilla, so complete ALND is recommended for patients with positive axillary metastases. For a clinically negative axilla, after neoadjuvant chemotherapy.

5. Conclusion

Staging for breast cancer evolved from axillary lymph node dissection towards the lesser invasive sentinel lymph node biopsy. Nowadays, although SLNB remains the standard procedure for diagnosing axillary involvement, axillary ultrasonography is performed as the initial staging examination for breast cancer patients. In operable breast cancer, ultrasound helps identification and guide biopsy of sentinel lymph node, and/or other imaging suspicious-appearing lymph nodes. As axillary ultrasonography

with either FNAB or core-biopsy is a far less invasive approach to diagnose lymph node metastasis, approximately 15 % of breast cancer patients will avoid an unnecessary SLNB and proceed directly to complete axillary dissection.

For patients with locally advanced invasive breast cancer, the recent years brought a growing practice of the routine axillary ultrasound imaging, with early referral of patients to preoperative systemic chemotherapy.

Author details

Nastasia Serban*

Address all correspondence to: serban_nastasia@yahoo.com

“Carol Davila” University of Medicine and Pharmacy, “Dr. Ion Cantacuzino” Department of Obstetrics and Gynecology, Bucharest, Romania

References

- [1] Carter CL, Allen C, Henson DE. Relation of tumor size, lymph node status, and survival in 24,740 breast cancer cases. *Cancer* 1989;63 181-7.
- [2] Whitman GJ, Lua TJ, Adejolu M, Krishnamurthy S, Sheppard D. Lymph node sonography. *Ultrasound Clinics* 2011;6(3) 369–380.
- [3] Vassallo P, Wernecke K, Roos N, et al. Differentiation of benign from malignant superficial lymphadenopathy: the role of high-resolution US. *Radiology* 1992;183 215–20.
- [4] Fajardo LF. Lymph nodes and cancer: a review. *Frontiers of Radiation Therapy and Oncology* 1994;28 1–10.
- [5] Yeoh EK, Denham JW, Davies SA, Spittle MF. Primary breast cancer. Complications of axillary management. *Acta Radiol Oncol* 1986;25(2) 105-8.
- [6] Cho N, Moon WK, Han W, Park IA, Cho J, Noh DY. Preoperative sonographic classification of axillary lymph nodes in patients with breast cancer: node-to-node correlation with surgical histology and sentinel node biopsy results. *AJR American Journal of Roentgenology* 2009;193 1731-7.
- [7] Song SE, Seo BK, Lee SH, Yie A, Lee KY, Cho KR, Woo OH, Cha SH, Kim BH. Classification of metastatic versus non-metastatic axillary nodes in breast cancer patients: value of cortex-hilum area ratio with ultrasound. *Journal of Breast Cancer* 2012; 15(1) 65-70.

- [8] Nastasia S, Bordea C, Russu MC, Blidaru AI, Hudita D. Axillary ultrasound and the concept of sentinel lymph node in breast cancer. *Revista Societății Române de Obstetrică-Ginecologie* 2008;2(LVI) 117-123.
- [9] Choi JJ, Kang BJ, Kim SH, Lee JH, Jeong SH, Yim HW, Song BJ, Jung SS. Role of sonographic elastography in the differential diagnosis of axillary lymph nodes in breast cancer. *Journal of Ultrasound in Medicine* 2011;30(4) 429-36.
- [10] Taylor K, O'Keeffe S, Britton PD, Wallis MG, Treece GM, Housden J, Parashar D, Bond S, Sinnatamby R. Ultrasound elastography as an adjuvant to conventional ultrasound in the preoperative assessment of axillary lymph nodes in suspected breast cancer: a pilot study. *Clinical Radiology* 2011;66(11) 1064-71.
- [11] Wojcinski S, Dupont J, Schmidt W, Cassel M, Hillemanns P. Real-time ultrasound elastography in 180 axillary lymph nodes: elasticity distribution in healthy lymph nodes and prediction of breast cancer metastases. *BMC Medical Imaging* 2012;19 12-35. Open Access. <http://www.biomedcentral.com/1471-2342/12/35>. DOI: 10.1186/1471-2342-12-35.
- [12] Esen G, Gurses B, Yilmaz MH, Ilvan S, Ulus S, Celik V, Farahmand M, Calay OO. Gray scale and power Doppler US in the preoperative evaluation of axillary metastases in breast cancer patients with no palpable lymph nodes. *European Radiology* 2005;15(6) 1215-23.
- [13] Moore A, Hester M, Nam MW, Brill Y M, McGrath P, Wright H, Weisinger K, Romond E, Samayoa L M. Distinct lymph nodal sonographic characteristics in breast cancer patients at high risk for axillary metastases correlate with the final axillary stage. *The British Journal of Radiology* 2008;81(968) 630-636.
- [14] Joh JE, Han G, Kiluk JV, Laronga C, Khakpour N, Lee MC. Indications for axillary ultrasound use in breast cancer patients. *Clinical Breast Cancer* 2012;12 433-437.
- [15] Valente SA, Levine GM, Silverstein MJ, Rayhanabad JA, Weng-Grumley JG, Ji L, Holmes DR, Sposto R, Sener SF. Accuracy of predicting axillary lymph node positivity by physical examination, mammography, ultrasonography, and magnetic resonance imaging. *Annals of Surgical Oncology* 2012;19(6):1825-30. DOI: 10.1245/s10434-011-2200-7.
- [16] Houssami N, Ciatto S, Turner RM, Cody HS III, Macaskill P. Preoperative ultrasound-guided needle biopsy of axillary nodes in invasive breast cancer: meta-analysis of its accuracy and utility in staging the axilla. *Annals of Surgery* 2011;254 243-251.
- [17] Holwitt DM, Swatske ME, Gillanders WE, Monsees BS, Gao F, Aft RL, Eberlein TJ, Margenthaler JA. The combination of axillary ultrasound and ultrasound-guided biopsy is an accurate predictor of axillary stage in clinically node-negative breast cancer patients. *The American Journal of Surgery* 2008;196 477-482.

- [18] Houssami N, Diepstraten SCE, Cody H, Turner RM, Sever AM. Clinical utility of ultrasound-needle biopsy for preoperative staging of the axilla in invasive breast cancer. *Anticancer Research* 2014;34 1087-1098.
- [19] Fisher B, Bryant J, Wolmark N, Mamounas E, Brown A, Fisher ER, Wickerham DL, Begovic M, DeCillis A, Robidoux A, Margolese RG, Cruz AB Jr, Hoehn JL, Lees AW, Dimitrov NV, Bear HD. Effect of preoperative chemotherapy on the outcome of women with operable breast cancer. *Journal of Clinical Oncology* 1998;16(8) 2672-2685.
- [20] Lee MC, Joh JE, Chau A. Axillary staging prior to neoadjuvant chemotherapy: the roles of sentinel lymph node biopsy and axillary ultrasonography. *Cancer Control* 2012;4(19) 277-85.

