

We are IntechOpen, the world's leading publisher of Open Access books Built by scientists, for scientists

6,900

Open access books available

186,000

International authors and editors

200M

Downloads

Our authors are among the

154

Countries delivered to

TOP 1%

most cited scientists

12.2%

Contributors from top 500 universities



WEB OF SCIENCE™

Selection of our books indexed in the Book Citation Index
in Web of Science™ Core Collection (BKCI)

Interested in publishing with us?
Contact book.department@intechopen.com

Numbers displayed above are based on latest data collected.
For more information visit www.intechopen.com



Panoramic Radiography — Diagnosis of Relevant Structures That Might Compromise Oral and General Health of the Patient

Ticiana Sidorenko de Oliveira Capote,
Marcela de Almeida Gonçalves,
Andrea Gonçalves and Marcelo Gonçalves

Additional information is available at the end of the chapter

<http://dx.doi.org/10.5772/59260>

1. Introduction

The chapter provides information about panoramic radiography, showing the principal indications, advantages and disadvantages of this examination. Moreover, focus is given to some anatomical variations that can be detected on panoramic radiographs such as bifid mandibular canal, retromolar canal, and alterations such as calcified stylohyoid complex, arterial calcifications, phleboliths, sialolithiasis and tonsilloliths. Such structures/alterations are not reasons for indication of panoramic radiography, but they are radiographic findings, being important their identification, indication of more accurate examinations, and even referring to other professionals. Therefore, a literature review was conducted, citing relevant anatomy textbooks and scientific papers, and it was illustrated with panoramic radiographs showing these described structures/alterations.

2. Indications and contraindications of panoramic radiographs

Panoramic radiography is a radiologic technique that provides an overview of the jaws and surrounding structures. It is frequently indicated when professionals want to evaluate some structures such as unerupted third molars, orthodontic treatment, tooth development, developmental abnormalities, trauma, large lesions, and others [1, 2]. The panoramic radio-

graph allows the dental professional to view a large area of the maxilla and mandible on a single film [2].

The panoramic radiography is frequently used as initial diagnostic image of some alterations and based on it, the professional will verify the need of other more detailed and more accurate examinations [1].

If you have a full-mouth series, the panoramic radiography shows no more or little useful information for a patient receiving general dental care [1].

Some contraindications of panoramic radiographs are clinical situations that require detail and definition, such as carious lesions, visualization of alveolar crests, level of root canal filling [3], periodontal disease or periapical lesions [2].

In dental clinical practice, panoramic radiography is one of the most indicated radiographic examinations by dentists because it provides a general overview of dentomaxilomandibular structures and it is not so costly for patients.

3. Advantages and disadvantages of panoramic radiography

Panoramic radiography has many advantages including short time for the procedure, greater patient acceptance and cooperation, overall coverage of the dental arches and associated structures (more anatomic structures can be viewed on a panoramic film than on a complete intraoral radiograph series), simplicity, low patient radiation dose [2, 4]. The dose to the patient is approximately ten times less than full-mouth survey using the long cone and E+ film and it is four times less than four bitewings using the long round cone and E+ film [4].

The panoramic radiograph is less confusing to the patient than a series of small separate intraoral radiographs, making it easier for the dentist to explain the diagnosis and treatment plan to the patient [5].

The panoramic radiograph is an excellent imaging modality in patients with trismus or trauma, because such patients cannot open their mouths and this is not needed to take a panoramic film [4]. It is an excellent projection of diverse structures on a single film, which no other imaging system can achieve. Individual structures may be imaged by other methods, once pathologic conditions have been detected using the panoramic radiography [3, 4].

Nevertheless, this radiographic examination presents a lack of details and resolution of some structures due to overlapping of anatomical structures in the image, mild distortion and magnification [1, 3]. Objects of interest that are located outside the focal trough (it is the area of the dental anatomy that is reproduced distinctly on the panoramic radiograph) [5] are not seen [2], and artifacts are common and may easily be misinterpreted [5].

These features limit the indications of panoramic radiographs in cases where details and accurate measurements are needed [1, 3].

4. Anatomical variations observed on panoramic radiographs

The term "normal" in Anatomy refers to the shape and position most frequently found in individuals, that is, the typical shape. Anatomical variation is the deviation from the normal that does not bring any noticeable functional disorder [6].

Not very unusual, the bifid mandibular canals are observed on panoramic radiographs (Figure 1).

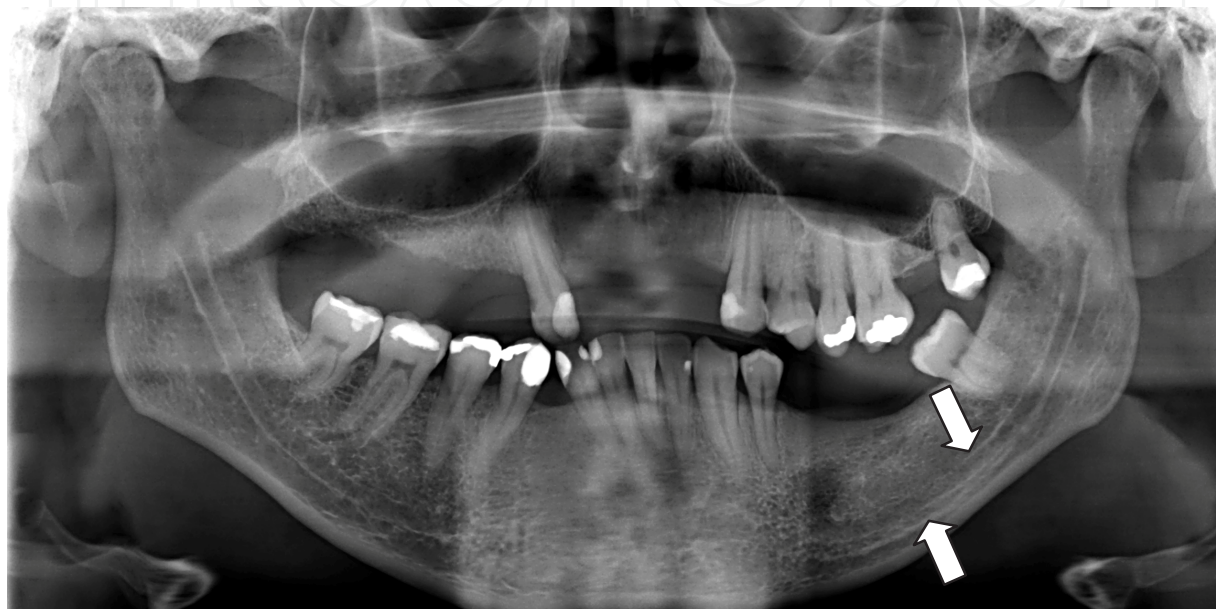

Figure 1. Digital panoramic radiography with a bifid mandibular canal image on the left side.

There are different frequencies and shapes in the literature.

Only 4 panoramic radiographs (0.08%) from 5,000 were highly suggestive of bifurcation [7]. Seven cases (0.35%) from 2,012 radiographs presented a suggestive image of a double mandibular canal [8]. From 700 panoramic radiographs evaluation, 3 cases (0.43%) showed bifid mandibular canal [9]. Duplication or division of the mandibular canal was found in 33 individuals (0.9%) from the 3,612 evaluated panoramic radiographs [10]. It is important to observe the presence of bifid mandibular canals to prevent potential complications during surgical dental procedures. A total of 6,000 panoramic radiographs were studied, and there were 57 bifid mandibular canals (0.95%) [11].

Three main patterns of duplication were found radiographically [10]. The first variety (Type 1) consisted of two canals originating from one foramen. The second variety of duplication or division (Type 2) was produced by a short upper canal extending to the second molar or third molar teeth. Type 3 was seen as two mandibular canals of equal dimensions apparently arising from separate foramina in the mandibular ramus and joining together to form one canal in the molar region of the body of the mandible. Other variations (Type 4) included duplication or division of the canal, apparent partial or complete absence of the canal or lack of symmetry.

The most common supplemental mandibular canals are duplicate canals commencing from a single mandibular foramen and the least common arising from two distinctly separate foramina [10]. A different classification was used by reference [9], which verified that type III (the canal is located close to the lower border of the mandible) is the most common, followed by the type II (the canal is noted between the apices of the first and second molars and the lower border of the mandible) and the type I (the canal is in close contact with the apices of the first and the second molars).

No great difference in frequency between males and females was found by reference [10] and there was no statistical significance between sex and types of the mandibular canal in the study of reference [9]. Women presented more bifid mandibular canals than men (63.5% vs. 36.5%) [8].

When bifid mandibular canals were evaluated by cone beam computed tomography (CBCT), a higher frequency was found. An incidence of 15.6% from 301 mandible sides was observed by [12] and, in a recent study an incidence of 10.2% was found in CBCT of 1933 patients [13]. However, different results were found by reference [8]. In their study, computed axial tomography was used in 3 of the 7 cases with apparent double inferior alveolar nerve images on panoramic radiographs. The existence of a bifid canal could only be confirmed in 2 of these patients. The authors suggested that the true incidence of bifid mandibular canals might be lower than reported by other studies. The possible causes underlying a false double-canal radiograph may include the imprint of the mylohyoid nerve on the internal mandibular surface where it separates from the inferior alveolar nerve and travels to the floor of the mouth [8, 14, 15]. Another explanation could be the radiologic osteocondensation image produced by the insertion of the mylohyoid muscle into the internal mandibular surface, with a distribution parallel to the dental canal [8, 16].

Bifurcation of the mandibular nerve may be a cause of inadequate anesthesia in a small percentage of cases [7, 8]. One of the seven patients who presented bifid mandibular canals on panoramic radiographs commented that her dentist had experienced problems in performing inferior alveolar nerve block in the past. Another patient had no such problems, and the remaining five patients had either never undergone anesthesia or remembered no associated problems [8]. This problem is usually resolved by performing inferior alveolar nerve anesthesia at a somewhat higher level (the so-called "Gow-Gates" technique) [8, 17]. Other possible complications can occur during surgery of the lower third molar, in orthognathic or reconstructive mandibular surgery, and in the placement of dental implants [8, 18], because of possible damage to an unidentified second mandibular canal [8].

Another anatomical variation that can be observed on panoramic radiographs is the retromolar canal, and it can be considered a type of mandibular canal division.

Retromolar canal has been observed in dry mandibles, cadaveric dissections, panoramic radiographs and cone beam computed tomography. Variability in the prevalence of the retromolar canal is also verified in different studies, 1.7% [19], 12.19% [20], 12.9% [21], 14.08% [22], 17% [23], 18% [24], 21.9% [25], 25% [26], 26.58% [27] (studies with dry mandibles); 5.8% [28], 16.8% [29] (studies with panoramic radiography); 16% [30], 75.4% in individuals assessed

by tomography exams, 72% in cadavers [31], 52.5% [13], 75.4% [32] (studies with computed tomography).

In the retromolar canals there were found striated muscle fibers, myelinated nerve fibers and blood vessels [26]. In the retromolar canal an artery was found, being the branch of the inferior alveolar artery, and the existing nerve derived from the inferior alveolar nerve and went to the third-molar region, the retromolar triangle mucosa, the buccal mucosa, the vestibular gingiva of the premolar region and inferior molars [33]. Accessory canals in the retromolar region are functionally important in providing the neural and/or vascular components of the mandible [34]. Figure 2 shows one retromolar canal bilaterally.

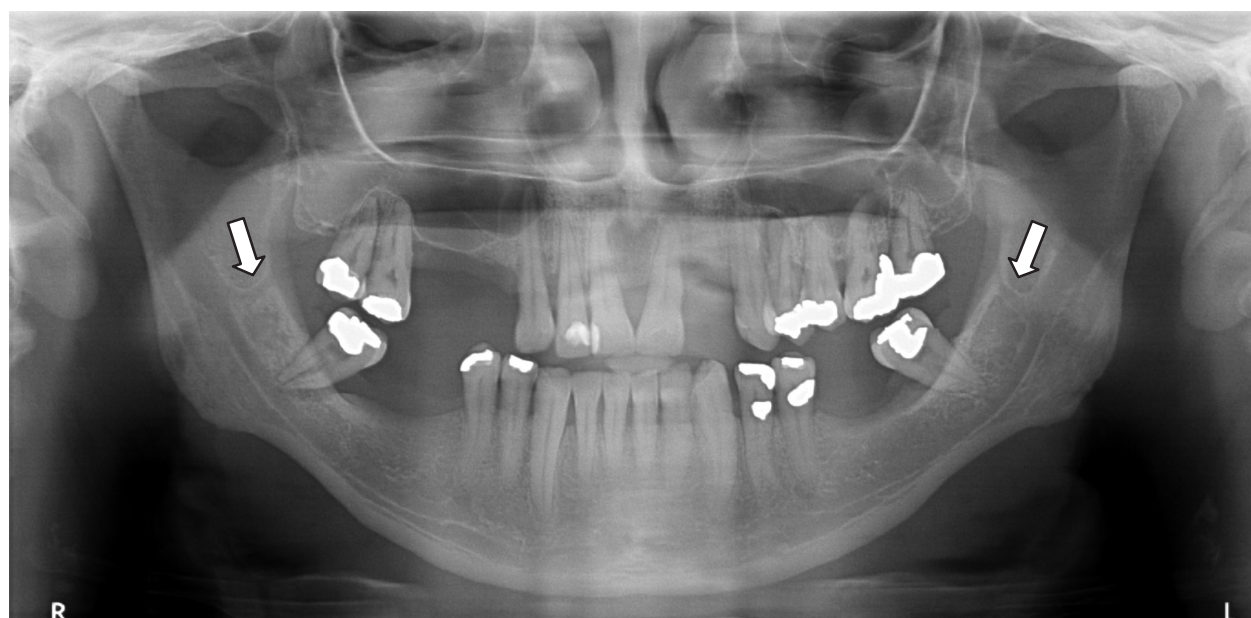

Figure 2. Digital panoramic radiography presenting a retromolar canal image on both sides.

Therefore, the content of the mandibular retromolar canal, usually of nerve fibers and/or blood vessels, is very important for surgical and anesthetic procedures involving the retromolar area. The confirmation of retromolar foramen and canal locations prior to surgical procedures, such as extraction of an impacted molar and bone harvesting as a donor site for bone graft surgery [35]. Complications such as traumatic neuroma, paraesthesia, and bleeding could arise because of failure to recognize the presence of mandibular canal variation [36, 37].

Studies have demonstrated the advantage of computed tomography over panoramic radiography in identification of anatomical variations [30, 36, 38].

It is clinically significant to accurately localize a bifid mandibular canal before dentoalveolar surgery especially when their presence is suspected by panoramic radiography [39]. Therefore, when professionals have suspicious of accessory mandibular canals on panoramic radiography, computed tomography should be done to confirm them and avoid complications.

5. Alterations observed on panoramic radiographs that might compromise oral and general health

Due to the broad coverage of panoramic radiographs, sometimes we can visualize some structures that affect more than the patient's oral health, but also general health. Many changes are asymptomatic and can be identified casually, as when the panoramic radiography is required for dental evaluation.

Among them, there are the calcified stylohyoid complex, arterial calcifications and other soft tissue calcifications.

5.1. Calcified stylohyoid complex

The styloid process is a cylindrical bone originated on the temporal bone [40-44] in front of the stylomastoid foramen [41-43], being located between the internal and external carotid arteries and laterally to the tonsillar fossa [43, 45, 46].

According to reference [47], elongated styloid process defines a styloid process that is longer than normal and thus associated with calcification of the process and its ligament, but some authors preferred the term calcified stylohyoid complex to describe the elongated process with advanced calcification [47].

The stylohyoid ligament is attached to the lesser horn of the hyoid bone [43, 48] and the calcification of the stylohyoid complex includes the stylohyoid ligament which connects the styloid process to the lesser horn of the hyoid bone [43].

The etiology of elongated styloid process is unknown [40, 43-45, 49, 50]. It was suggested that calcified stylohyoid complex could be resulted from local chronic irritations, history of trauma, endocrine disorders in female at menopause, persistence of mesenchymal elements, bone tissue growth and mechanical stress or trauma during stylohyoid ligament development [40, 43, 45, 46, 49], although no significant difference between females at menopause or not were showed [43]. A case report of twins suggested a possibility that calcified stylohyoid complex might be originated from genetic factors [44].

Only one report commented about the positive correlation that was found between the length of the styloid process and serum calcium concentration, heel bone density and body height and weight [47]. Previous studies reported difference in age for calcified stylohyoid ligament [51], i.e., the length increased with the age [41-43, 52], and its occurrence is rare in children [46]. Thus, dentists should pay attention not only for pathosis of the teeth and jaws, but also for information on general health conditions [47].

The measurements of the calcified stylohyoid complex on the panoramic radiography consist on the distance from the point where the styloid process left the tympanic plate to the tip of the process, involving mineralized parts of the ligament [42, 47, 50].

The literature reports that calcified styloid process is considered normal when it does not extend below the mandibular foramen. It is considered elongated when it extends below the

mandibular foramen [51]. Finally, calcification of the stylohyoid ligament occurs when the calcification extends below the mandibular foramen and does not appear to be continuous with the base of the skull [51]. Figure 3 presents a panoramic radiography showing a calcified stylohyoid complex on both sides.

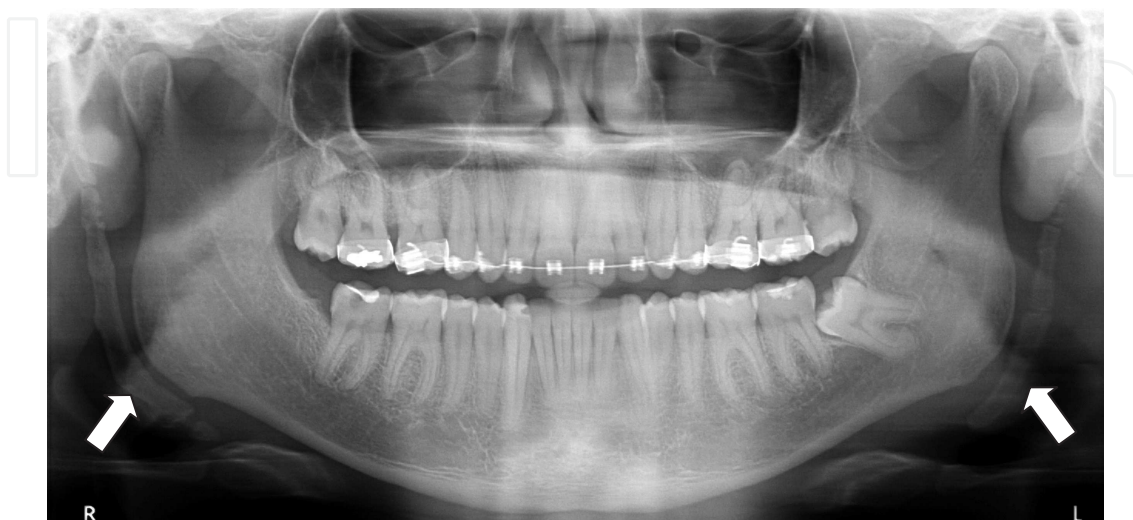

Figure 3. Digital panoramic radiography with a calcified stylohyoid complex on both sides. On the right side we can observe the stylohyoid ligament calcification near the hyoid bone. On the left side a fragmented stylohyoid ligament calcification can be seen.

Cervicalpharyngeal pain is classified into 3 entities: Eagle syndrome, stylohyoid syndrome and pseudostylohyoid syndrome [46]. Eagle's syndrome comprises elongated styloid process when it causes clinical symptoms, including dysphagia, foreign body sensation [45, 46, 48, 50, 53, 54], odynophagia, hypersalivation, and more rarely, temporary voice changes [53]. Eagle syndrome needs a history of trauma or neck surgery and painful symptoms on clinical palpation of the elongation or ossification of the stylohyoid process complex [46]. It may also cause stroke when compresses carotid arteries [40].

Stylohyoid syndrome does not comprise a history of trauma or surgery [46], and it occurs due to the compression of the internal and external carotid arteries and vascular structures [43, 53], resulting in a persistent pain to the carotid region, as headache, chronic neck pain, pain upon head movement and pain radiating to the eye [53]. It also shows radiographic elongation or ossification of the stylohyoid process complex [46] and it affects patients older than 40 years [46, 48]. This condition is more prevalent than Eagle syndrome [48].

In pseudostylohyoid syndrome there is no evidence of any elongation or ossification, but the patient describes the symptoms [46].

In Eagle syndrome, the styloid process is longer than 25mm [46]; from 25mm to 30mm it is considered elongated [42], although it varies in length in different people and even on the two sides of the same person [41, 42]. There is a significant prevalence for men concerning the styloid process length [42, 47]. However, there was no difference between sexes on the pattern

distribution of calcified stylohyoid complex [43, 47, 51, 52]. The calcified stylohyoid complex bilaterally is prevalent [1, 41-43, 49, 52].

Radiographic imaging may include panoramic radiography, lateral cephalometry, Towne projection film, or computed tomography (CT) scan [42, 43, 45, 46, 48, 53].

Calcified stylohyoid complex is usually visualized on panoramic radiography [1, 40, 51] as an incidental finding [49], as a long, thin, radiopaque process that is thicker at its base, posteriorly to the external acoustic meatus, with a trajectory downward and forward [1, 46]. A thicker calcified stylohyoid complex is uncommon. Figure 4 presents a very thick calcified stylohyoid complex.

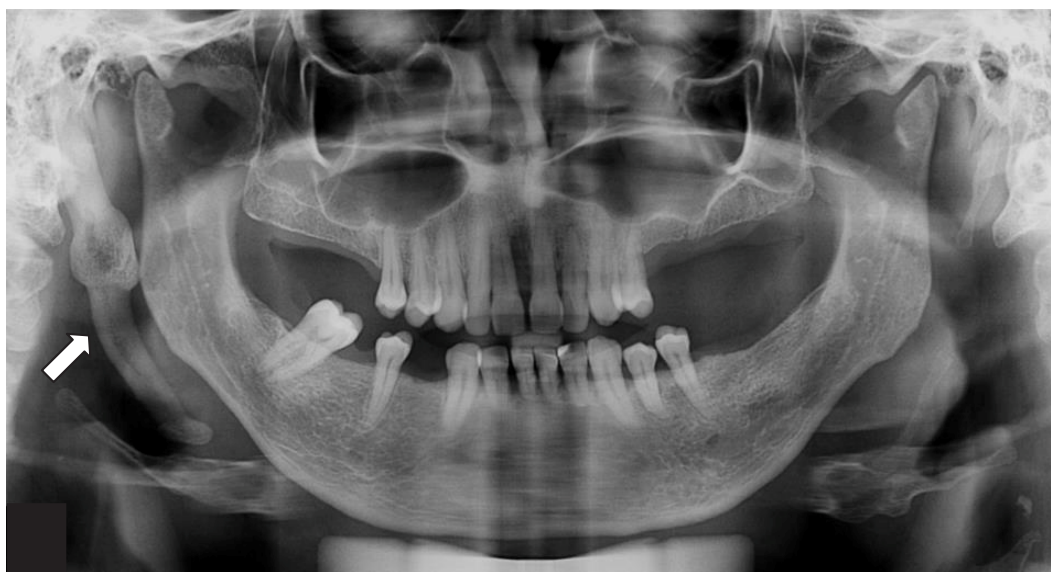

Figure 4. Digital panoramic radiography shows a thick calcified stylohyoid complex on the right side.

Panoramic radiography is the best imaging modality to visualize the styloid process bilaterally [42, 45] in patients with or without symptoms, and helps avoid misinterpretation of symptoms as tonsillar pain or dental pain, pharyngeal or muscular origin [42]. Panoramic radiography may be the first choice as imaging modality, because of its availability, low cost, diagnostic performance, and less patient dose compared to other imaging methods [43]. Nevertheless, panoramic radiography is not appropriate for measuring the length, and to show direction and anatomical variation of calcified stylohyoid complex compared to the multislice computed tomography [40, 46, 48, 54] and cone beam computed tomography do [43].

Data from clinical history, physical and radiographic examination must be considered when diagnosing Eagle's syndrome [46, 47, 54]. In the physical examination the calcified stylohyoid complex can be palpated on the tonsillar fossa as a hard and pointed structure [45, 49, 54].

The differentiation diagnosis of styloid ligament calcification may include calcified carotid artery atheromas, pheboliths and lymph node calcification [47] and for symptomatic elongated styloid process may comprise temporomandibular joint disorder, glossopharyngeal and

trigeminal neuralgias, temporal arteritis, migraine, myofacial pain, atypical odontalgia, sialadenitis, sialolithiasis, cervical arthritis and tumors [46, 49], pain secondary to unerupted or impacted third molars, histaminic headache [46].

Most patients with calcified stylohyoid complex are asymptomatic [1, 44, 52] and no treatment is required [1]. The first choice of treatment is the use of analgesics and anti-inflammatory medications [46, 49]. However, for severe symptomatic patients with Eagle's syndrome the surgical excision of the stylohyoid complex is recommended [1, 44, 46, 54]. Regardless the cervicalpharyngeal pain it is important for the dentist who is involved in the diagnosis and treatment of these syndromes to identify on the panoramic radiography the calcified stylohyoid complex and to refer the patient to a specialized team.

5.2. Arterial calcifications

The common carotid artery originates from the aorta artery and in the height of the upper edge of the thyroid cartilage branches into two terminal branches: internal and external carotid artery. The identification of the point of bifurcation is often located 3 cm below the lower edge of the mandible [55].

It is considered a dystrophic calcification where there are deposited calcium salts in chronically inflamed or necrotic tissues. The presence of an atheromatous plaque in the extracranial carotid vascular path is the main cause for vasculocerebral embolism and obstructive diseases [1].

Carotid artery atherosclerotic plaques develop when fatty substances, cholesterol, platelets, cellular waste products, and calcium are deposited in the lining of the artery [56]. Some risk factors for atherosclerosis are: diabetes mellitus, obesity, hypertension, smoking, inadequate diet, chronic kidney disease and menopause among others [57].

Panoramic radiographs, obtained during professional dental examinations, are a potential method for early detection of Calcified Carotid Artery Atheroma (CCAA) [58]. Patients found to have carotid calcification on panoramic radiographs should be referred for cerebrovascular and cardiovascular evaluation and aggressive management of vascular risk factors [59]. Patients who have risk factors and CCAA on panoramic radiographs have a higher chance of suffering a vascular event compared with patients without image CCAA on panoramic radiographs, indicating that the incidental finding of calcifications on a panoramic dental radiograph is a powerful marker for future adverse, nonfatal, vascular events, with cardiovascular events being more common than cerebrovascular events [56].

The prevalence of CCAA in HIV+patients was assessed by reference [60] through review of medical records and on panoramic radiography and the authors concluded that infection and the treatment used to treat HIV infection can influence the identification of CCAA. Thus, a careful examination of panoramic radiographs in these patients is recommended and the need for further studies related to the subject is reinforced.

Authors [61] observed hypertension as the major risk factor associated with carotid artery calcification followed by diabetes mellitus and hyperlipidemia in the Thai population. A standard panoramic dental radiography detected the presence of calcified cervical carotid

artery disease in approximately 31% of postmenopausal women with no history of transient ischemic attack or stroke. It was demonstrated that hypertension was a significant risk factor for the development of atheromas [62]. Other authors [63] observed that patients who had evidence of calcified carotid plaque on panoramic radiographs had lower incidence of diabetes mellitus and hyperlipidemia but were more likely to have stroke, compared with patients with negative panoramic radiography for calcification.

The utility of observing calcification will obviously depend on the prevalence and amount of calcium within these lesions, which varies according to each patient [64].

A high interobserver agreement (92.4%) on the detection of carotid artery calcification (CAC) on panoramic radiographs of male patients above 50 years old was observed by reference [65]. No significant difference in the prevalence CCA in HIV+patients using conventional and digital panoramic radiograph was found [60]. Authors [66] emphasized that digital panoramic radiograph allow low intensity calcifications to be visualized due to the possibility of changing the contrast, density and expansion.

Radiographically, calcified carotid atheroma is initially developed at the bifurcation of arteries, soft tissues of the neck, and adjacent to the greater horn of the hyoid bone and the cervical vertebrae C3 and C4 or the intervertebral space between them. They are radiopaque, usually multiple and irregularly shaped, with a vertical distribution and they have an internally heterogeneous radiopacity [1]. The shape varies from circular to mostly linear with irregular margins and appears punctate containing areas of radiolucencies [67]. Figures 5 and 6 present panoramic radiographs with images suggesting the presence of atheromas.

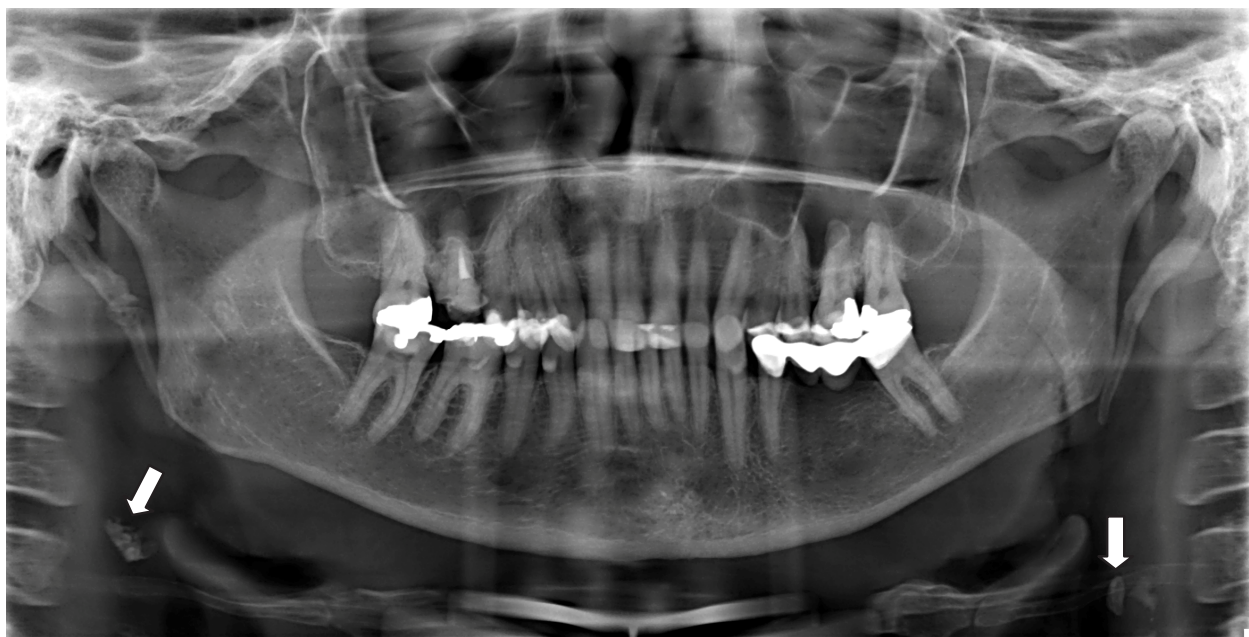


Figure 5. Digital panoramic radiography with images suggesting the presence of atheroma on both sides.

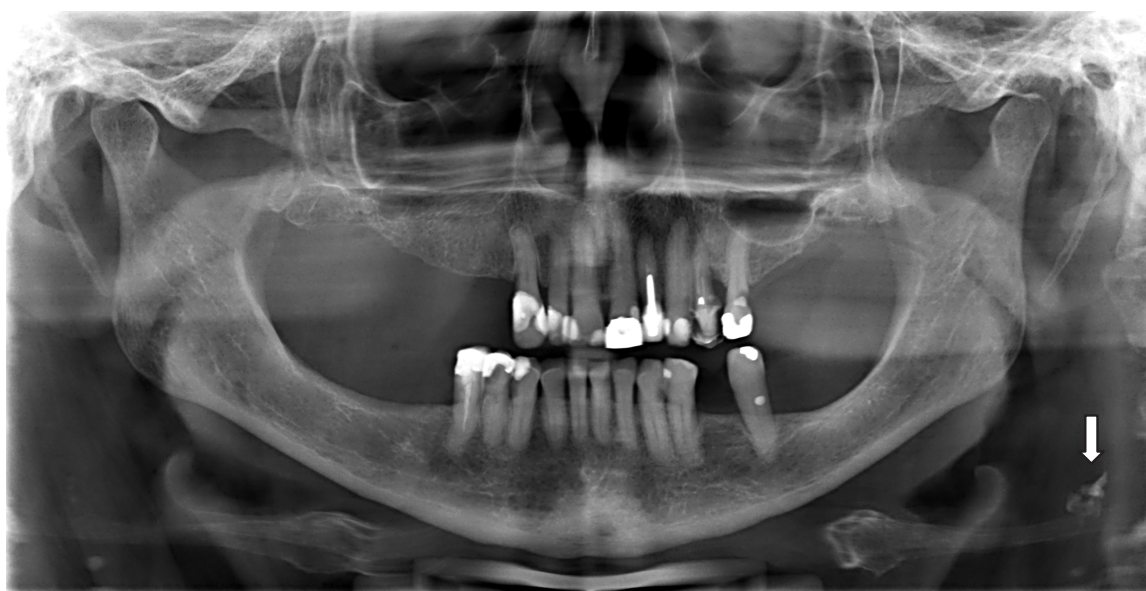

Figure 6. Digital panoramic radiography with image suggesting the presence of atheroma on left side.

Panoramic radiographs of a 67-year-old white woman were evaluated, and observed the presence of multiple, irregular, nonhomogenous radiopacities lying over both the right and the left carotid bifurcations [64]. The calcifications were located inferior to the angle of the mandible and the tip of the hyoid bone, and to the top tip of the thyroid cartilage and the C3, C4 and C5 vertebrae [64]. Other authors [61] evaluated panoramic radiographs in 1370 patients and reported the presence of calcified carotid artery as irregular, heterogenous, verticolinear or circular radiopaque lower to the neck at the level of the C3 and C4 intervertebral junction in the Thai population. The carotid artery calcifications were located within the soft tissues of the neck, approximately 2 centimeters inferior and posterior to the angle of the mandible, at about the level of the lower margin of the third cervical vertebra [62].

The differential diagnosis of CCAA image can be performed with several nearby anatomical structures such as the hyoid bone, styloid process, especially the thyroid cartilage and triticeous cartilage.

The triticeous cartilage often occurs in each lateral thyrohyoid ligament forming the edges of the thyrohyoid membrane [68].

The calcified triticeous cartilage can be confused with an atheromatous plaque but the shape, outline and location help in discriminating the triticeous cartilage from calcification in the carotid arteries [1, 67].

Triticeous cartilages and calcified carotid atheromas are located in a similar region on panoramic radiographs; the shape and outline help in differentiating these 2 calcifications in the neck. Triticeous cartilage is specifically located between the greater horn of the hyoid and superior horn of the thyroid cartilage, and the shape is mostly well-defined oval, with a smooth, well-defined corticated border [67]. Figure 7 shows a panoramic radiography with triticeous cartilages on both sides.

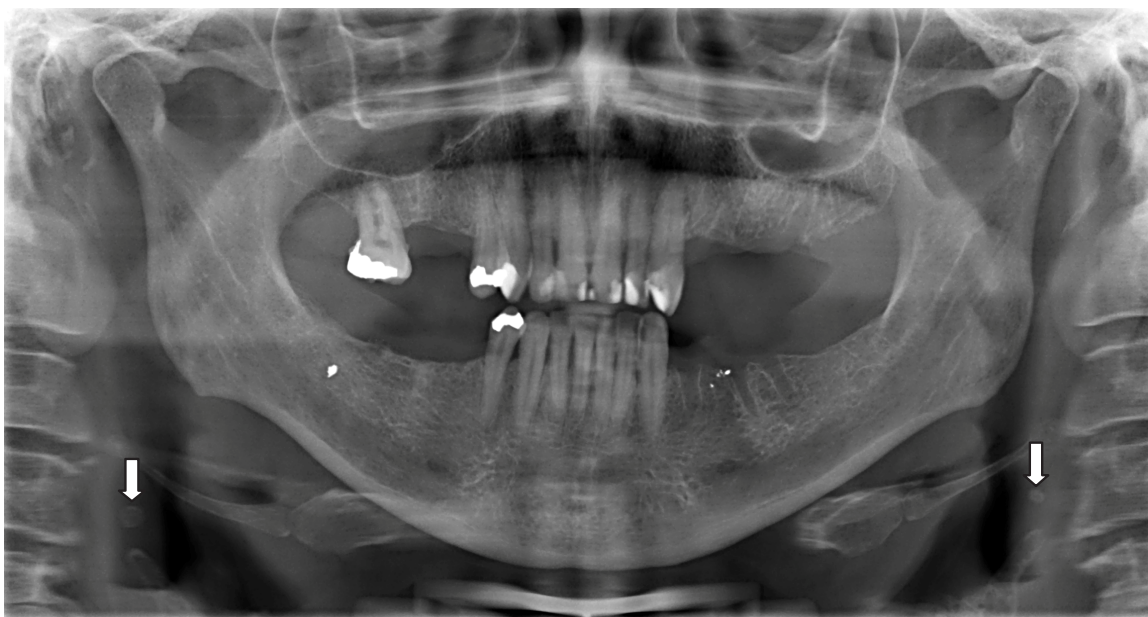


Figure 7. Digital panoramic radiography with image suggesting triticeous cartilage on both sides (between the greater horn of the hyoid and superior horn of the thyroid cartilage).

Authors [57] emphasized that although the panoramic radiography is not the test of choice, it is possible to identify atheroma in the carotid artery and therefore the dentist may instruct the patient to seek medical advice as soon as possible.

In order to confirm the presence of CACs, advanced imaging techniques such as duplex ultrasound, magnetic resonance imaging, and angiography should be performed [61].

The reliability of digital panoramic radiographs in detecting atheroma in the carotid artery was assessed [69] and the authors compared with ultrasound examinations. The results showed that digital panoramic radiography has a high level of agreement with ultrasonography with 76% of sensitivity and 98.66% of specificity. The authors concluded that the panoramic radiograph should not be routinely used in the detection of calcified carotid atheromatous plaques although when detected on a routine dental examination it is very useful.

The image of CCAA on panoramic radiograph was confirmed utilizing duplex ultra-sonography, which revealed carotid artery stenosis (CAS) [64]. The authors suggested that calcifications seen lying over the carotid bifurcation on panoramic radiographs should prompt further evaluation for CAS.

The dystrophic calcification of the tunica intima resulting in CCAA can be distinguished radiographically from another calcified form of arteriosclerosis, medial artery arteriosclerosis (MAA) or Mönckeberg's medial calcific sclerosis. The calcification in MAA is generalized because it affects the tunica media of medium and smaller muscular arteries. Calcifications are typically diffuse, multiple, and circumferential along the wall of the arterial vessel. MAA may be an indicator of peripheral artery disease, including diabetes mellitus or chronic kidney disease. MAA is generally observed in the limbs and rarely reported in the head and neck [70]. MAA can be identified on the panoramic radiography when the facial artery is affected.

According to reference [71], the panoramic radiography can be the first auxiliary in diagnosis for detecting facial artery calcification in patients in hemodialysis. The authors suggested that more studies should be performed, in order to determine the incidence of that alteration in those patients.

Radiographically, the calcium deposited in the arterial wall outlines the artery contour, being identified as a pair of parallel, thin radiopaque lines, or with circular aspect, depending on the evaluated view [1].

5.3. Sialolithiasis

Sialolithiasis is the most common disease of the salivary glands [72-74] characterized by obstruction of salivary secretion by a calculus, associated with swelling, pain [72, 75, 76] and infection of the affected gland [75]. More than 80% of the salivary gland calculi occurs in the submandibular gland [1, 72, 74-78] and 5%-20% in the parotid gland [72, 75-78] and rarely in the sublingual gland and the minor salivary glands (1% to 2%) [72, 75-77]. It is common in adults (1.2% of the population), with a male predominance [1, 72, 74, 76, 77], although previous investigators cited that sialolithiasis occurs more frequently in white woman [73]. Children are rarely involved and sialolithiasis is more frequently in the third to the sixth decades of life [72, 74-77].

Patients with sialolithiasis may complain of moderate to intense pain when it involves the duct of a major salivary gland, particularly at mealtimes, when salivary flow is stimulated [1, 73], associated with enlargement of the gland [73].

Sialoliths are stones found within the ducts of salivary glands [1] and may be single or multiple [72, 76]. Single sialolith is more common seen [1, 79]. Figure 8 shows a panoramic radiography with a single sialolith on the right side in the submandibular gland. They measure from 1 mm to less than 1 cm [72, 74, 75]. Giant sialoliths are rare, bigger than 3.5 cm and also occur in male patients and are commonly located in the submandibular gland [74].

According to reference [74], several factors seem to be involved in the development of salivary calculi in the submandibular gland tissues such as: the submandibular excretory duct is wider in diameter and longer than the Stensen's duct; the secretion against gravity [74, 77]; the secretion is more alkaline compared with pH of the parotid saliva; the submandibular saliva contains a higher quantity of mucin proteins, while parotid saliva is entirely serous; then its saliva presents high calcium and phosphate content [73, 74, 77].

Initial events that contribute for the formation of a nidus that later will be the site for the precipitation of mineral salts contained in the salivary secretion include infection, inflammation, physical trauma, salivary stagnation, introduction of foreign bodies and the presence of desquamated epithelial cells [73, 74].

The likely mechanism of sialolith formation in the sublingual gland is mechanical trauma with mucus extravasation, which serves as a nidus for stone formation [77]. In summary, the formation of a sialolith requires salivary stagnation, a nidus and a precipitation of salivary salts [75].

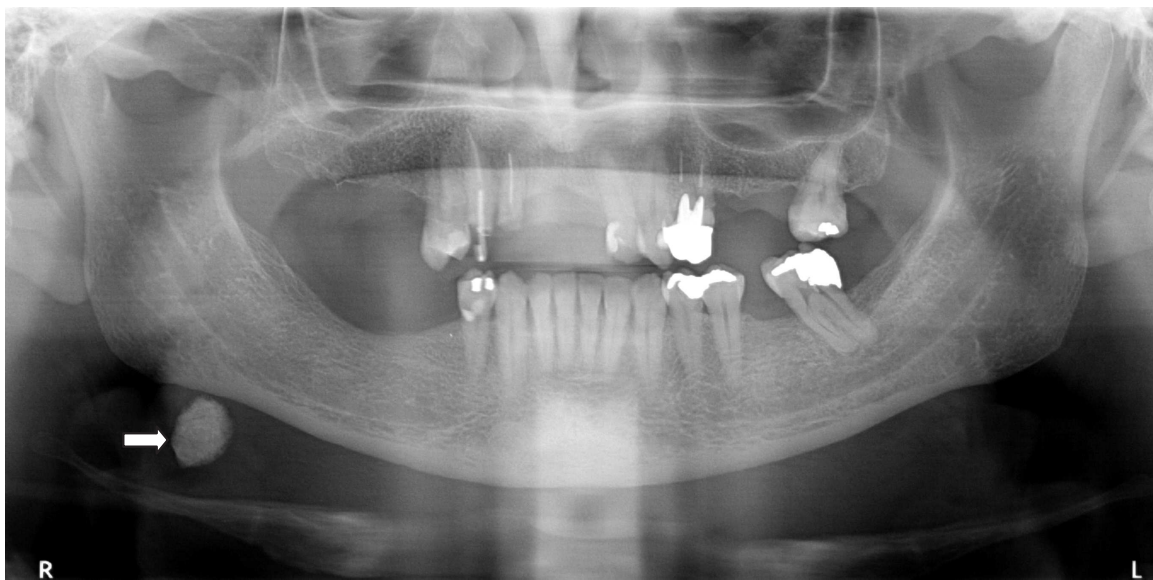


Figure 8. Digital panoramic radiography with image suggesting a single sialolith in the right submandibular gland.

Depending on the sialolith size and calcification degree, it can be visible in conventional radiographs. In panoramic radiography, the calcification image may appear superimposed on the mandible; therefore, it may be mistaken by an intrabone lesion [73]. Plain film radiography demonstrates dystrophic calcifications and the possible involvement of adjacent osseous structures [1].

Panoramic radiography usually shows sialoliths in the submandibular gland if they are located in the posterior duct [1]. If calculi can not be visualized in conventional radiographs, other imaging examinations may be necessary [73]. Sialography is used to evaluate obstructive and inflammatory conditions of the ductal system. If the patient is allergic to the iodine contrast agent used in sialography, the alternative imaging examination is ultrasonography or scintigraphy [1].

Computed tomography or magnetic resonance imaging are appropriate if the sialography suggests the presence of a space-occupying mass [1]. According to previous investigation, panoramic radiography and CT scan estimation appeared to be somewhat closer to the surgical specimen size [75].

Sialoliths in the sublingual gland are usually round or oval shaped. However, stones in Wharton's duct may be elongated. Parotid stones are usually smaller and more often multiple [77]. A single mass of calcification of the parotid gland with a calcification of part of its duct can be seen in the Figure 9.

Giant sublingual sialolith was previously described as a large single calcified mass in sublingual area on panoramic radiography. Giant sublingual sialolith has already been associated with dysphagia as well as eating and speaking difficulty [76]

Sialolith is usually homogeneously radiopaque, although it can show evidence of multiple layers of calcification if large [1, 79]. Salivary stones are usually shaped by the duct and then

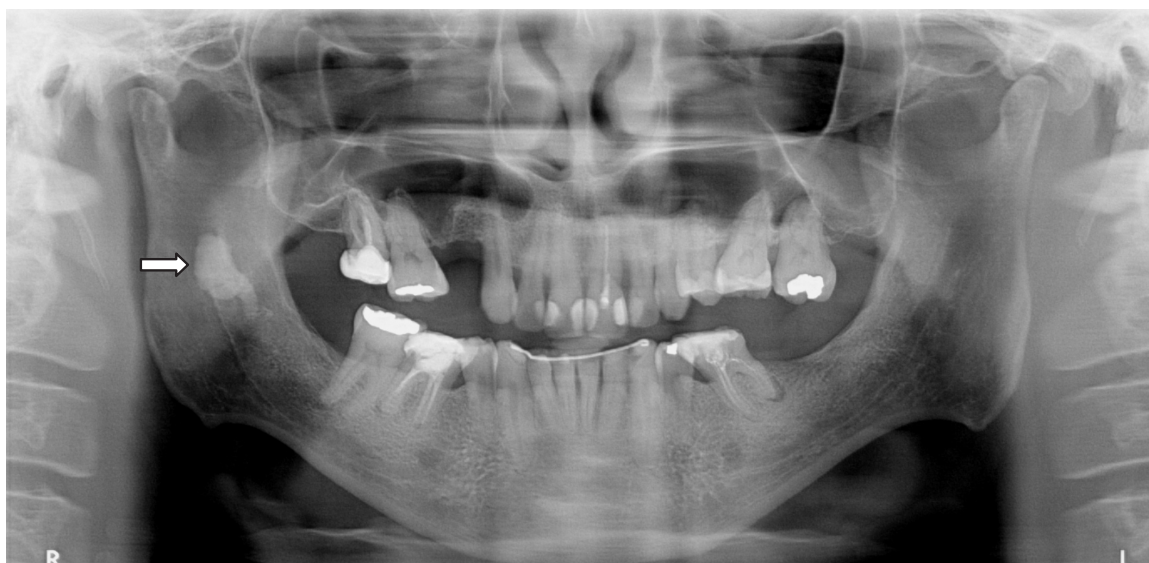

Figure 9. Digital panoramic radiography showing a image suggesting a calcification in the right parotid gland and in its duct.

they are elongated [77, 79]. Sialoliths are more likely localized in the Wharton's duct (submandibular gland) than in the Stensen's duct (parotid gland) [79]. Figure 10 shows calcifications in the submandibular and parotid glands.

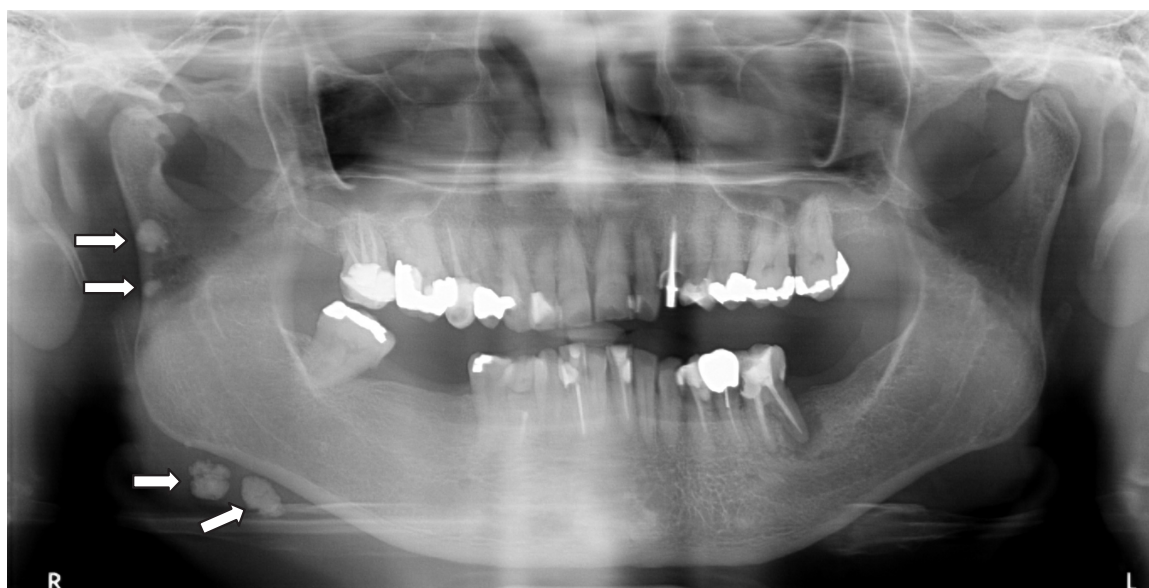

Figure 10. Digital panoramic radiography with image suggesting calcifications in the right submandibular and parotid glands.

A previous report described 3 cases with multiple microliths in their parotid parenchyma in Sjögren's syndrome showing panoramic radiography with many spots-like calcifications observed around the gonial angle and in the posterior part of the ramus [78]. According to

previous publication, parotid calculi are frequently seen about halfway up on the ramus and may be multiple [80] as cited above. We can observe a panoramic radiography with multiple microliths in the parotid gland on both sides in the Figure 11.

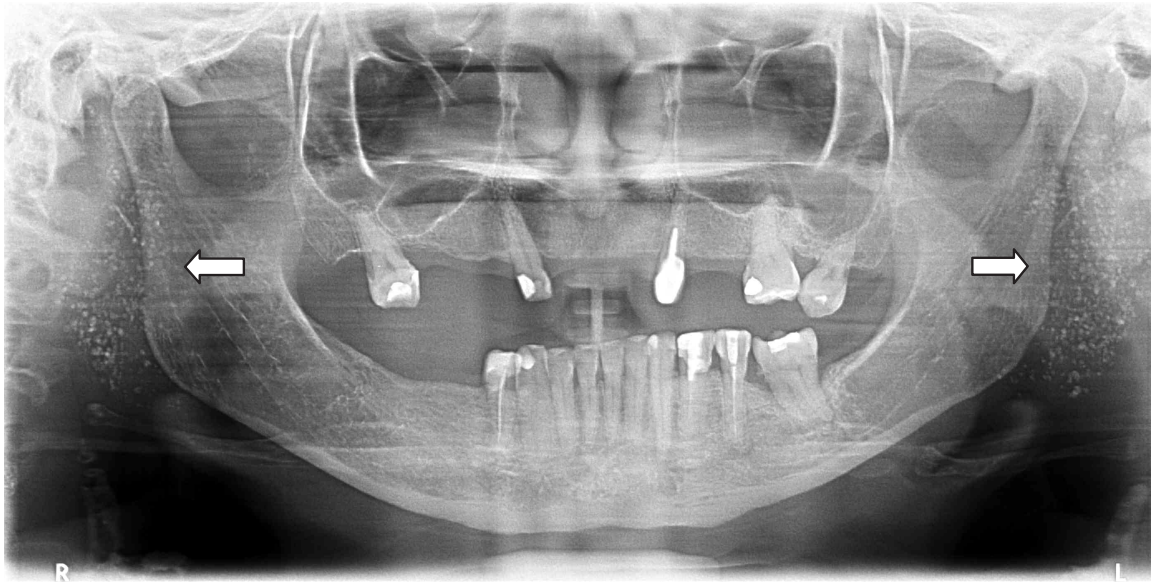


Figure 11. Digital panoramic radiography with image suggesting multiple microliths in the parotid gland on both sides.

Although this report is about panoramic radiography, previous investigations comment about cone beam computed tomography (CBCT) and reported that for visualization of the delicate structures of the parotid and submandibular salivary glands and for identification of sialoliths and single ductal strictures, CBCT sialography may be better than plain film sialography [81]. CBCT is the preferable imaging modality for salivary calculus diagnosis considering its high diagnostic-information-to-radiation-dose ratio [82] and to show the shapes of stones more clearly [75].

Vascular malformation with phleboliths must be included in the differential diagnosis of salivary gland obstruction and magnetic resonance imaging may be able to distinguish between them, but sialography is the most effective diagnostic modality to this differentiation [79].

According to [72], sialolithiasis treatment depends on the localization of the salivary calculus [72, 73]. The sialolith should be removed via a transoral sialolithotomy avoiding sialadenectomy. Intraglandular sialoliths necessitate sialadenectomy [73, 75]. Solitary sialoliths usually do not recur [72].

5.4. Phleboliths

Phleboliths are idiopathic calcification (or calcinosis) that results from deposition of calcium in the normal tissue. This calcification results from deposition of calcium in the normal tissue, despite normal serum levels of calcium and phosphate [1]. Phleboliths are calcified thrombi

found within vascular channels, often in the presence of hemangiomas or vascular malformations. They may originate from injury to a vessel wall or result from stagnation of the flow of blood [83, 84]. A case of intramuscular hemangioma was related by reference [85], where it was observed the large number of phleboliths of the tongue due to the long-term presence of hemangioma and stagnant blood flow. The authors [86], when reporting an intramuscular hemangioma also suggested that the cause of the large number of phleboliths is the long-term presence of hemangioma and stagnant blood.

The presence of vascular anomalies in the head and neck has a great importance for the professionals working in this area, since any procedure performed in this region without the due caution may trigger the onset of an emergency, as bleeding, which can lead to the patient's death. Therefore, there is a need to conduct a thorough diagnosis in order to help in the discovery of the existence of these defects, so that such situations are avoided [87]. Those authors reviewed the charts of 108 patients with vascular anomalies and observed in 31% of the cases that the changes were in the region of the mouth and tongue, being the period of childhood and adolescence the most affected (64%).

Clinically, the vascular changes may have a swollen soft tissue, which is throbbing and with its modified coloration and some noises when auscultating [1].

A case of a patient with multiple swellings on the surface and in the mouth with a purplish coloration in intraoral examination was reported by reference [88]. Radiographic examination showed small phleboliths in the left submandibular region, and ultrasound also showed calcifications. Histological examination showed that the characteristics are originated from venous malformation. Three cases of hemangioma of the head and neck varying like the clinical characteristics presented were presented by reference [89], however some commonalities between them could be noticed as swelling, absence of pulse or noise, and two cases showed discoloration.

Phleboliths calcification starts in the center of the thrombus and consists of apatite crystals of calcium phosphate and carbonate [1]. Initially, calcification of the thrombus occurs, forming the core of the phlebolith. The fibrinous component then undergoes secondary calcification and becomes attached. Repetition of this process causes enlargement of the phlebolith [86].

Radiographically, the phlebolith features radiopaque, rounded or oval image measuring more than 6mm in diameter and uniform periphery. Internally, it can present a homogeneous radiopacity, but it commonly presents a laminated appearance with a target aspect [1]. A patient with an oral mixed mucosal and submucosal venous malformation with multiple phleboliths, which the panoramic radiograph revealed multiple round-to-oval radiopaque bodies located in the soft tissues of the left retromolar trigone. Those structures had a laminated pattern and were interpreted as phleboliths [90].

A patient presented a small mass that contained calcification in the anterior part of the masseter muscle and the plain radiograph showed a round, uniformly radiopaque lesion [91]. The same was observed by other authors [92], who reported about a patient with a masseteric intramuscular hemangioma, which other than a mild facial asymmetry, was subjectively asymptomatic. This diagnosis could not be reached without computed tomography (CT) scan that identified

the presence of the calcified body confirmed by the panoramic radiograph. The patient did not exhibit the lamellated feature of a phlebolith. MRI with contrast was ordered for further evaluation and diagnosis that clearly visualized an enhanced vascular lesion within the left masseter muscle, and confirmed the presence and location of the phlebolith. However, phleboliths are not easily recognized in magnetic resonance image (MRI) film because of their very low signal intensity. They are best identified on plain radiograph and CT scan. Authors [93] observed in occlusal radiograph of a patient with vascular malformation, two oval radiopaque images, diagnosed after microscopic examination as being phlebolith.

Studies about hemangiomas and venous malformations associating imaging methods have been reported in literature aiming to improve the diagnosis of these changes and the presence of phleboliths. CT was used in 3 cases that revealed phleboliths so no other imaging was considered to be necessary [89]. Phlebolith was observed on radiography and ultrasonography of paranasal sinus [88]. Plain x-rays may also help with the diagnosis because of the typical appearance of the calcified bodies and computed tomography, magnetic resonance, and ultrasonography are more useful for making an accurate diagnosis [91]. A case of intramuscular hemangioma and another one of vascular malformation presenting phleboliths by the use of sialography and occlusal radiographs was presented by reference [84]. Occlusal radiography and Doppler ultrasonography also were used in a case of vascular malformation [93].

The radiographic image of phlebolith can be similar to a sialolith [1]. Phleboliths are usually multiple, with oval shape, randomly located and lamellated [92]. Figure 12 shows a panoramic radiography with multiple phleboliths on the right side.

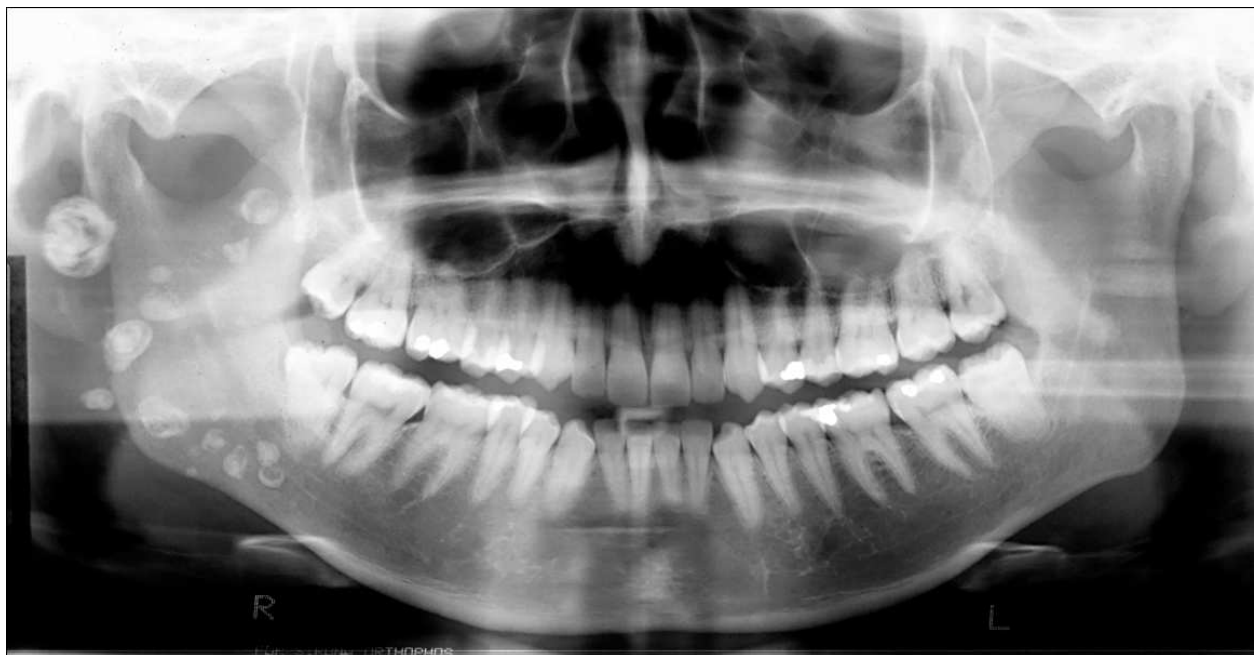


Figure 12. Panoramic radiography with image suggesting multiple phleboliths on the right side.

The sialoliths are frequently elliptically or elongated shaped due to the anatomic contour of the salivary duct [90, 92]. According to reference [90], sialography usually reveals a filling defect at the site of the salivary calculus, whereas phleboliths appear to be external to the duct system [90]. A case of recurrent episodes of pain and swelling in the right submandibular region was reported by reference [79]. Radiopaque images were identified in occlusal and panoramic radiographs, being diagnosed as sialoliths. The sialendoscopy was indicated and no intraductal stones were detected. A vascular network of capillaries was detected in all the ductal lumen altering the sialolithiasis diagnostic to a vascular malformation with phleboliths. The authors concluded that the vascular malformation obstructing the duct of the salivary gland is overlooked by physicians, and that phleboliths may be confounded with sialoliths.

5.5. Tonsilloliths

Tonsilloliths are calcifications within a tonsillar crypt, which involve primarily the palatine tonsil caused by dystrophic calcification as a result of chronic inflammation [94]. Small concretions are not uncommon findings especially in the aged population [95], however large tonsillar concretions occur with a much lower incidence [95-98].

The prevalence of tonsilloliths (measuring above 2 mm) in 1524 patients attending the oral and maxillofacial radiology clinic of The University of Iowa was observed to be 8.14% by reference [99]. The age range of subjects was 9.2–87 years (mean 52.6 years), the average size of tonsillolith was 4mm (range: 3–11 mm), with no sex predilection.

The large tonsilloliths occur in males and females equally [98, 100], and on the fifth decade of life [100]. Tonsilloliths in children are rare and they are more common in young adults with long stories of recurrent tonsillar inflammation [98, 100].

The exact etiology and pathogenesis is unknown. Repeated episodes of inflammation may produce fibrosis at the openings of the tonsillar crypts. Bacterial and epithelial debris then accumulates within these crypts and contributes to the formation of retention cysts. Calcification occurs subsequent to the deposition of inorganic salts and the enlargement of the formed concretion takes place gradually. The tonsilloliths derive their phosphate and carbonate of lime and magnesia from saliva secreted by salivary glands [94-98, 101]. The mineral content of tonsilloliths can be composed by phosphorus, calcium, carbonate or magnesium [95].

On the panoramic radiography, tonsilloliths commonly appear as multiple, small, and ill-defined radiopacities [99]. On the other hand, other authors [94] described tonsilloliths as usually being single and unilateral, but occasionally they may be multiple or bilateral. Tonsilloliths should be the first differential diagnosis when multiple opaque lesions with ill-defined borders, which are superimposed on the palatal uvula and the ramus are detected on the panoramic radiography [94]. The radiographic appearance of tonsilloliths was predominantly multiple and well defined (62.90%) and the single, well-defined tonsillolith in a similar location constituted 28.23% in the study of reference [99]. The authors verified that the majority of the cases were located in the lower one third of the mandibular ramus (93.55%). Figures 13 and 14 shows panoramic radiographs with multiple tonsilloliths in the lower one third of the mandibular ramus on both sides.

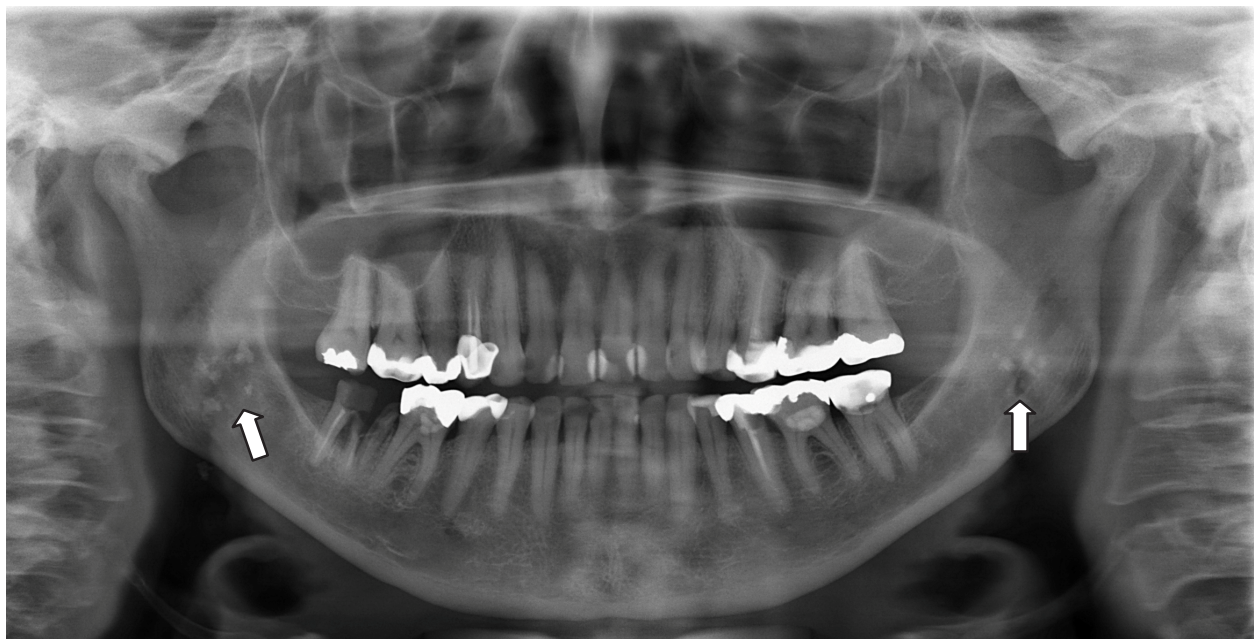

Figure 13. Digital panoramic radiography with image suggesting multiple tonsilloliths in the lower one third of the mandibular ramus on both sides.

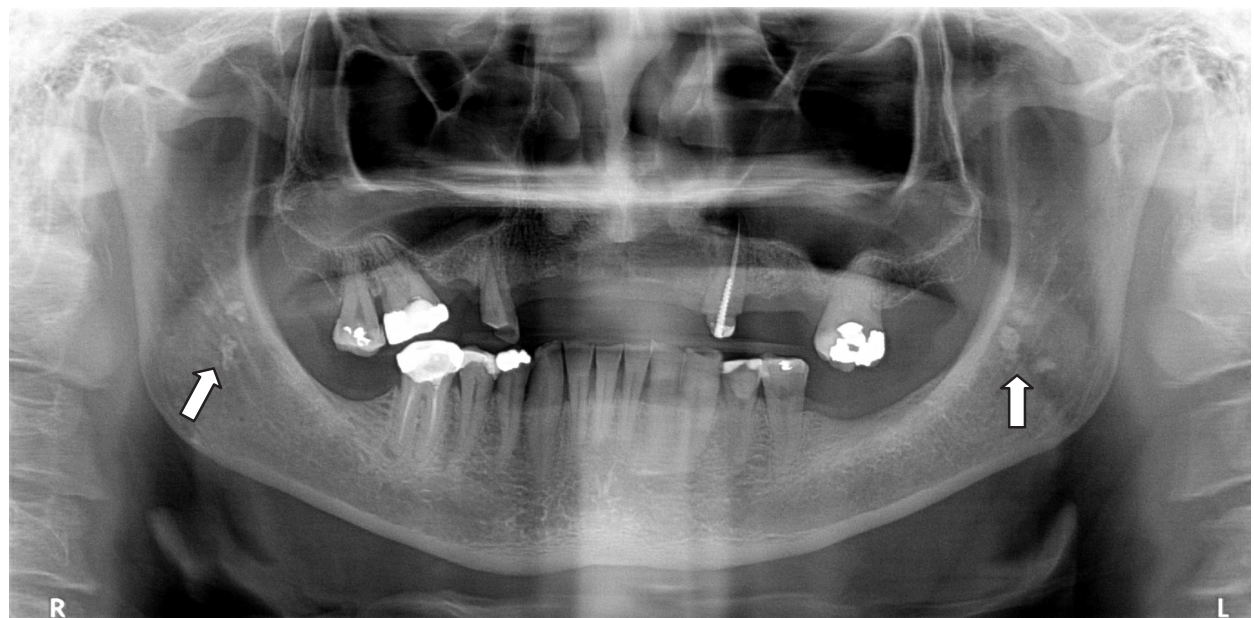


Figure 14. Digital panoramic radiography with image suggesting multiple tonsilloliths in the lower one third of the mandibular ramus on both sides.

Calcifications in the carotid arterial, lymph nodes, salivary gland and stylohyoid ligament are some of the differential diagnosis that might be considered [101].

On the clinical examination, it should be considered malignancy or calcified granulomatous disease such as tertiary syphilis, tuberculosis and deep fungal infection as differential diagnosis [98].

When no predisposing causes can be discovered (like chronic obstructive sialolithiasis of the salivary glands, past medical history of kidney stone), the medical history represents the most important element to recognise the tendency of some patients to develop calcifications, as in the case reported [96]. The observations in the study of [99] do not support any correlations between tonsilloliths and calcifications in other body organs, tissues, or ducts.

Patients with tonsilloliths may be asymptomatic probably when the calcifications have small size [101], and their lesions discovered incidentally on panoramic radiographs or they can present pain or soreness, dysphagia, halitosis, otalgia, infection, a foreign body-like sensation, irritable cough, difficulty in swallowing, bad/altered taste [94-96, 98-100].

Incidental findings of large tonsilloliths are reported using panoramic radiography [96, 98, 100]. The panoramic radiography helps to observe the location of opacities, but considering its two-dimensional limitations, a computed tomography or cone beam computed tomography scan is necessary to accurately position the calcifications [96, 100].

Treatment is usually removal of concretions by curettage and larger lesions may require local excision [96, 98, 99]. If there is evidence of chronic tonsillitis, tonsillectomy offers definitive therapy; however it is advisable to postpone tonsillectomy until all acute symptoms have subsided [98].

The diagnosis of tonsillar calculi, exploring their etiology, evaluating them for removal, and not dismissing them as clinically insignificant it is important because of the significant morbidity via chronic infection, pain, and/or swallowing abnormalities, with the potential of further pulmonary complications [95].

6. Conclusion

Panoramic radiograph is a radiological technique that provides an overview of the jaws and adjacent structures. Asymptomatic patients may show anatomical variations or alterations that may be randomly displayed on panoramic radiographs. These alterations may contribute to clinical complications and damage the patient's oral and general health. Therefore, it is of utmost importance that dentists be able to recognize the evidence of these variations and alterations on panoramic radiographs and request additional examinations that provide a more accurate diagnosis. Thus, we conclude that the panoramic radiograph, within its limitations, contributes effectively to the initial diagnosis of anatomic variations and alterations, and the dental professional can identify the risks and refer their patients to a specialist.

Author details

Ticiana Sidorenko de Oliveira Capote^{1*}, Marcela de Almeida Gonçalves¹,
Andrea Gonçalves² and Marcelo Gonçalves²

*Address all correspondence to: ticiana@foar.unesp.br

1 Dental School at Araraquara, Univ. Estadual Paulista, UNESP, Department of Morphology, Araraquara, São Paulo, Brazil

2 Dental School at Araraquara, Univ. Estadual Paulista, UNESP, Department of Diagnostic and Surgery, Araraquara, São Paulo, Brazil

References

- [1] White SC, Pharoa MJ. Oral Radiology: Principles and Interpretation. 5th ed. Saint Louis: Mosby; 2007.
- [2] Haring JJ, Jansen L. Dental radiography: principles and techniques. 2nd ed. Philadelphia: Saunders; 2000. 569 p.
- [3] Alvares LC, Tavano O. Curso de radiologia em odontologia. 4th ed. São Paulo, Brazil: Livraria Santos Editora Ltda; 2002. 248 p.
- [4] Langland OE, Langlais RP, Preece JW. Principles of dental imaging. 2nd ed. Lippincott Williams & Wilkins; 2002. 459 p.
- [5] De Lyre WR, Johnson ON. Essentials of dental radiography for dental assistants and hygienists. 4th ed. Norwalk, Conn.: Appleton & Lange; 1990. xvii, 446 p.
- [6] Aumuller G. Anatomia. Rio de Janeiro: Guanabara Koogan; 2009.
- [7] Grover PS, Lorton L. Bifid mandibular nerve as a possible cause of inadequate anesthesia in the mandible. Journal of oral and maxillofacial surgery : official journal of the American Association of Oral and Maxillofacial Surgeons 1983;41(3):177-179.
- [8] Sanchis JM, Penarrocha M, Soler F. Bifid mandibular canal. Journal of oral and maxillofacial surgery : official journal of the American Association of Oral and Maxillofacial Surgeons 2003;61(4):422-424.
- [9] Zografos J, Kolokoudias M, Papadakis E. [The types of the mandibular canal]. To Helleniko periodiko gia stomatike & gnathoprosopike cheirourgike / episemo organotes Hetaireias Stomatognathoprosopikes Cheirourgikes. The Greek Journal of Oral & Maxillofacial Surgery 1990;5(1):17-20.

- [10] Nortje CJ, Farman AG, Grotepass FW. Variations in the normal anatomy of the inferior dental (mandibular) canal: a retrospective study of panoramic radiographs from 3612 routine dental patients. *The British Journal of Oral Surgery* 1977;15(1):55-63.
- [11] Langlais RP, Broadus R, Glass BJ. Bifid mandibular canals in panoramic radiographs. *Journal of the American Dental Association* 1985;110(6):923-926.
- [12] Kuribayashi A, Watanabe H, Imaizumi A, Tantanapornkul W, Katakami K, Kurabayashi T. Bifid mandibular canals: cone beam computed tomography evaluation. *Dentomaxillofacial Radiology* 2010;39(4):235-239.
- [13] Kang JH, Lee KS, Oh MG, Choi HY, Lee SR, Oh SH, et al. The incidence and configuration of the bifid mandibular canal in Koreans by using cone-beam computed tomography. *Imaging Science in Dentistry* 2014;44(1):53-60.
- [14] Wilson S, Johns P, Fuller PM. The inferior alveolar and mylohyoid nerves: an anatomic study and relationship to local anesthesia of the anterior mandibular teeth. *Journal of the American Dental Association* 1984;108(3):350-352.
- [15] Sillanpaa M, Vuori V, Lehtinen R. The mylohyoid nerve and mandibular anesthesia. *International Journal of Oral and Maxillofacial Surgery* 1988;17(3):206-207.
- [16] Kiersch TA, Jordan JE. Duplication of the mandibular canal. *Oral Surgery, Oral Medicine, and Oral Pathology* 1973;35(1):133-134.
- [17] Meechan JG. How to overcome failed local anaesthesia. *British Dental Journal* 1999;186(1):15-20.
- [18] Quattrone G, Furlini E, Bianciotto M. [Bilateral bifid mandibular canal. Presentation of a case]. *Minerva Stomatologica* 1989;38(11):1183-1185.
- [19] Ossenberg NS. Temporal crest canal: case report and statistics on a rare mandibular variant. *Oral Surgery, Oral Medicine, and Oral Pathology* 1986;62(1):10-12.
- [20] Bilodi AKS, Singh S, Ebenezer DA, Suman P, Kumar K. A study on retromolar foramen and other accessory foramina in human mandibles of Tamil Nadu region. *International Journal of Health Sciences and Research* 2013;3(10):61-65.
- [21] Galdámes IS, Matamala DZ, López MC. Retromolar Canal and Forame prevalence in dried mandibles and clinical implications. *International Journal of Odontostomatology* 2008;2(2):183-187.
- [22] Athavale SA, Vijaywargia M, Deopujari R, Kobayashi K. Bony and cadaveric study of retromolar region. *People's Journal of Scientific Research* 2013;6(2):14-18.
- [23] Motta-Junior J, Ferreira ML, Matheus RA, Stabile GAV. Forame retromolar: sua repercussão clínica e avaliação de 35 mandíbulas secas. *Revista de Odontologia da UNESP* 2012;41(3):164-168.

- [24] Gupta S, Soni A, Singh P. Morphological study of accessory foramina in mandible and its clinical implication. *Indian Journal of Oral Sciences* 2013;4(1):12-16.
- [25] Narayana K, Nayak UA, Ahmed WN, Bhat JB, Devaiah BA. The retromolar foramen and canal in south Indian dry mandibles. *European Journal of Anatomy* 2002;6(3):141-146.
- [26] Bilecenoglu B, Tuncer N. Clinical and anatomical study of retromolar foramen and canal. *Journal of oral and maxillofacial surgery : official journal of the American Association of Oral and Maxillofacial Surgeons* 2006;64(10):1493-1497.
- [27] Rossi AC, Freire AR, Prado BG, Prado FB, Botacin PR, Caria PHF. Incidence of retromolar foramen in human mandibles: ethnic and clinical aspects. *International Journal of Morphology* 2012;30(3):1074-1078.
- [28] von Arx T, Hanni A, Sendi P, Buser D, Bornstein MM. Radiographic study of the mandibular retromolar canal: an anatomic structure with clinical importance. *Journal of Endodontics* 2011;37(12):1630-1635.
- [29] Muinelo-Lorenzo J, Suarez-Quintanilla JA, Fernandez-Alonso A, Marsillas-Rascado S, Suarez-Cunqueiro MM. Descriptive study of the bifid mandibular canals and retromolar foramina: cone beam CT vs panoramic radiography. *Dentomaxillofacial Radiology* 2014;43(5):20140090.
- [30] Lizio G, Pelliccioni GA, Ghigi G, Fanelli A, Marchetti C. Radiographic assessment of the mandibular retromolar canal using cone-beam computed tomography. *Acta Odontologica Scandinavica* 2013;71(3-4):650-655.
- [31] Schejtman R, Devoto FC, Arias NH. The origin and distribution of the elements of the human mandibular retromolar canal. *Archives of Oral Biology* 1967;12(11):1261-1268.
- [32] Patil S, Matsuda Y, Nakajima K, Araki K, Okano T. Retromolar canals as observed on cone-beam computed tomography: their incidence, course, and characteristics. *Oral Surgery, Oral Medicine, Oral Pathology, and Oral Radiology* 2013;115(5):692-699.
- [33] Koder H, Hashimoto I. [A case of mandibular retromolar canal: elements of nerves and arteries in this canal]. *Kaibogaku Zasshi Journal of Anatomy* 1995;70(1):23-30.
- [34] Haveman CW, Tebo HG. Posterior accessory foramina of the human mandible. *The Journal of Prosthetic Dentistry* 1976;35(4):UNKNOWN.
- [35] Kawai T, Asaumi R, Sato I, Kumazawa Y, Yosue T. Observation of the retromolar foramen and canal of the mandible: a CBCT and macroscopic study. *Oral Radiology* 2012;28(1):10-14.
- [36] Kaufman E, Serman NJ, Wang PD. Bilateral mandibular accessory foramina and canals: a case report and review of the literature. *Dentomaxillofacial Radiology* 2000;29(3):170-175.

- [37] Anderson LC, Kosinski TF, Mentag PJ. A review of the intraosseous course of the nerves of the mandible. *The Journal of Oral Implantology* 1991;17(4):394-403.
- [38] Lee J, Yoon S, Kang B. Mandibular canal branches supplying the mandibular third molar observed on cone beam computed tomographic images: reports of four cases. *Korean Journal of Oral and Maxillofacial Radiology* 2009;39:209-212.
- [39] Fukami K, Shiozaki K, Mishima A, Kuribayashi A, Hamada Y, Kobayashi K. Bifid mandibular canal: confirmation of limited cone beam CT findings by gross anatomical and histological investigations. *Dentomaxillofacial Radiology* 2012;41(6):460-465.
- [40] Gokce C, Sisman Y, Sipahioglu M. Styloid Process Elongation or Eagle's Syndrome: Is There Any Role for Ectopic Calcification? *European Journal of Dentistry* 2008;2(3):224-228.
- [41] MK OC. Calcification in the stylohyoid ligament. *Oral Surgery, Oral Medicine, and Oral Pathology* 1984;58(5):617-621.
- [42] More CB, Asrani MK. Evaluation of the styloid process on digital panoramic radiographs. *The Indian Journal of Radiology & Imaging* 2010;20(4):261-265.
- [43] Alpoz E, Akar GC, Celik S, Govsa F, Lomcali G. Prevalence and pattern of stylohyoid chain complex patterns detected by panoramic radiographs among Turkish population. *Surgical and Radiologic Anatomy : SRA* 2014;36(1):39-46.
- [44] Kim JE, Min JH, Park HR, Choi BR, Choi JW, Huh KH. Severe calcified stylohyoid complex in twins: a case report. *Imaging Science in Dentistry* 2012;42(2):95-97.
- [45] Rizzatti-Barbosa CM, Ribeiro MC, Silva-Concilio LR, Di Hipolito O, Ambrosano GM. Is an elongated stylohyoid process prevalent in the elderly? A radiographic study in a Brazilian population. *Gerodontology* 2005;22(2):112-115.
- [46] Valerio CS, Peyneau PD, de Sousa AC, Cardoso FO, de Oliveira DR, Taitson PF, et al. Stylohyoid syndrome: surgical approach. *The Journal of Craniofacial Surgery* 2012;23(2):e138-140.
- [47] Okabe S, Morimoto Y, Ansai T, Yamada K, Tanaka T, Awano S, et al. Clinical significance and variation of the advanced calcified stylohyoid complex detected by panoramic radiographs among 80-year-old subjects. *Dentomaxillofacial Radiology* 2006;35(3):191-199.
- [48] Kaushik A, Kaushik M, Panwar R, Tanwar R, Garg P, Garg S. Calcified stylohyoid ligaments: A diagnostic dilemma. *SRM Journal of Research in Dental Sciences* 2012;3(4):275.
- [49] Koivumaki A, Marinescu-Gava M, Jarnstedt J, Sandor GK, Wolff J. Trauma induced eagle syndrome. *International Journal of Oral and Maxillofacial Surgery* 2012;41(3):350-353.

- [50] Sudhakara Reddy R, Sai Kiran C, Sai Madhavi N, Raghavendra MN, Satish A. Prevalence of elongation and calcification patterns of elongated styloid process in south India. *Journal of Clinical and Experimental Dentistry* 2013;5(1):e30-35.
- [51] MacDonald-Jankowski DS. Calcification of the stylohyoid complex in Londoners and Hong Kong Chinese. *Dentomaxillofacial Radiology* 2001;30(1):35-39.
- [52] Ferrario VF, Sigurta D, Daddona A, Dalloca L, Miani A, Tafuro F, et al. Calcification of the stylohyoid ligament: incidence and morphoquantitative evaluations. *Oral Surgery, Oral Medicine, and Oral Pathology* 1990;69(4):524-529.
- [53] Jain S, Bansal A, Paul S, Prashar DV. Styloid-stylohyoid syndrome. *Annals of Maxillofacial Surgery* 2012;2(1):66-69.
- [54] Moon CS, Lee BS, Kwon YD, Choi BJ, Lee JW, Lee HW, et al. Eagle's syndrome: a case report. *Journal of the Korean Association of Oral and Maxillofacial Surgeons* 2014;40(1):43-47.
- [55] Figún ME, Garino RR. *Anatomia odontológica funcional e aplicada*. São Paulo: Panamericana; 1989. 658 p.
- [56] Friedlander AH, Cohen SN. Panoramic radiographic atheromas portend adverse vascular events. *Oral Surgery, Oral Medicine, Oral Pathology, Oral Radiology, and Endodontics* 2007;103(6):830-835.
- [57] Guimaraes Henriques JC, Kreich EM, Helena Baldani M, Luciano M, Cezar de Melo Castilho J, Cesar de Moraes L. Panoramic radiography in the diagnosis of carotid artery atheromas and the associated risk factors. *The Open Dentistry Journal* 2011;5:79-83.
- [58] Bayram B, Uckan S, Acikgoz A, Muderrisoglu H, Aydinalp A. Digital panoramic radiography: a reliable method to diagnose carotid artery atheromas? *Dentomaxillofacial Radiology* 2006;35(4):266-270.
- [59] Cohen SN, Friedlander AH, Jolly DA, Date L. Carotid calcification on panoramic radiographs: an important marker for vascular risk. *Oral Surgery, Oral Medicine, Oral Pathology, Oral Radiology, and Endodontics* 2002;94(4):510-514.
- [60] da Silva NG, Pedreira EN, Tuji FM, Warmling LV, Ortega KL. Prevalence of calcified carotid artery atheromas in panoramic radiographs of HIV-positive patients undergoing antiretroviral treatment: a retrospective study. *Oral Surgery, Oral Medicine, and Oral Pathology* 2014;117(1):67-74.
- [61] Pornprasertsuk-Damrongsri S, Thanakun S. Carotid artery calcification detected on panoramic radiographs in a group of Thai population. *Oral Surgery, Oral Medicine, Oral Pathology, Oral Radiology, and Endodontics* 2006;101(1):110-115.

- [62] Friedlander AH, Altman L. Carotid artery atheromas in postmenopausal women. Their prevalence on panoramic radiographs and their relationship to atherogenic risk factors. *Journal of the American Dental Association* 2001;132(8):1130-1136.
- [63] Griniatsos J, Damaskos S, Tsekouras N, Klonaris C, Georgopoulos S. Correlation of calcified carotid plaques detected by panoramic radiograph with risk factors for stroke development. *Oral Surgery, Oral Medicine, Oral Pathology, Oral Radiology, and Endodontics* 2009;108(4):600-603.
- [64] Almog DM, Illig KA, Khin M, Green RM. Unrecognized carotid artery stenosis discovered by calcifications on a panoramic radiograph. *Journal of the American Dental Association* 2000;131(11):1593-1597.
- [65] Yoon SJ, Shim SK, Lee JS, Kang BC, Lim HJ, Kim MS, et al. Interobserver agreement on the diagnosis of carotid artery calcifications on panoramic radiographs. *Imaging Science in Dentistry* 2014;44(2):137-141.
- [66] Garay I, Netto HD, Olate S. Soft tissue calcified in mandibular angle area observed by means of panoramic radiography. *International Journal of Clinical and Experimental Medicine* 2014;7(1):51-56.
- [67] Ahmad M, Madden R, Perez L. Triticeous cartilage: prevalence on panoramic radiographs and diagnostic criteria. *Oral Surgery, Oral Medicine, Oral Pathology, Oral Radiology, and Endodontics* 2005;99(2):225-230.
- [68] William PL, Warwick R, Dyson M, Bannister LH. *Gray Anatomia*. 37 ed. Rio de Janeiro: Guanabara Koogan; 1995.
- [69] Khambete N, Kumar R, Risbud M, Joshi A. Evaluation of carotid artery atheromatous plaques using digital panoramic radiographs with Doppler sonography as the ground truth. *Journal of Oral Biology and Craniofacial Research* 2012;2(3):149-153.
- [70] MacDonald D, Chan A, Harris A, Vertinsky T, Farman AG, Scarfe WC. Diagnosis and management of calcified carotid artery atheroma: dental perspectives. *Oral Surgery, Oral Medicine, Oral Pathology, and Oral Radiology* 2012;114(4):533-547.
- [71] Miles DA, Craig RM. The calcified facial artery. A report of the panoramic radiographic incidence and appearance. *Oral Surgery, Oral Medicine, and Oral Pathology* 1983;55(2):214-219.
- [72] Eyigor H, Osma U, Yilmaz MD, Selcuk OT. Multiple sialolithiasis in sublingual gland causing dysphagia. *The American Journal of Case Reports* 2012;13:44-46.
- [73] Jardim EC, Ponzoni D, de Carvalho PS, Demetrio MR, Aranega AM. Sialolithiasis of the submandibular gland. *The Journal of Craniofacial Surgery* 2011;22(3):1128-1131.
- [74] Ledesma-Montes C, Garces-Ortiz M, Salcido-Garcia JF, Hernandez-Flores F, Hernandez-Guerrero JC. Giant sialolith: case report and review of the literature. *Journal of Oral and Maxillofacial Surgery* 2007;65(1):128-130.

- [75] Bodner L. Giant salivary gland calculi: diagnostic imaging and surgical management. *Oral Surgery, Oral Medicine, Oral Pathology, Oral Radiology, and Endodontics* 2002;94(3):320-323.
- [76] Gungormus M, Yavuz MS, Yolcu U. Giant sublingual sialolith leading to dysphagia. *The Journal of Emergency Medicine* 2010;39(3):e129-130.
- [77] Hong KH, Yang YS. Sialolithiasis in the sublingual gland. *The Journal of Laryngology and Otology* 2003;117(11):905-907.
- [78] Shimizu M, Yoshiura K, Nakayama E, Kanda S, Nakamura S, Ohyama Y, et al. Multiple sialolithiasis in the parotid gland with Sjogren's syndrome and its sonographic findings--report of 3 cases. *Oral Surgery, Oral Medicine, Oral Pathology, Oral Radiology, and Endodontics* 2005;99(1):85-92.
- [79] Su YX, Liao GQ, Wang L, Liang YJ, Chu M, Zheng GS. Sialoliths or phleboliths? *The Laryngoscope* 2009;119(7):1344-1347.
- [80] Langland OE, Langlais RP, Morris CR. Principles and practice of panoramic radiology : including intraoral radiographic interpretation. Philadelphia: Saunders; 1982. xiv, 458 p.
- [81] Jadu FM, Lam EW. A comparative study of the diagnostic capabilities of 2D plain radiograph and 3D cone beam CT sialography. *Dentomaxillofacial Radiology* 2013;42(1):20110319.
- [82] Dreiseidler T, Ritter L, Rothamel D, Neugebauer J, Scheer M, Mischkowski RA. Salivary calculus diagnosis with 3-dimensional cone-beam computed tomography. *Oral Surgery, Oral Medicine, Oral Pathology, Oral Radiology, and Endodontics* 2010;110(1):94-100.
- [83] Shemilt P. The origin of phleboliths. *The British Journal of Surgery* 1972;59(9):695-700.
- [84] Mandel L, Perrino MA. Phleboliths and the vascular maxillofacial lesion. *Journal of Oral and Maxillofacial Surgery* 2010;68(8):1973-1976.
- [85] Kamatani T, Saito T, Hamada Y, Kondo S, Shiota T, Shintani S. Intramuscular hemangioma with phleboliths of the tongue: A case report. *Indian Journal of Dentistry* 2014.
- [86] Kanaya H, Saito Y, Gama N, Konno W, Hirabayashi H, Haruna S. Intramuscular hemangioma of masseter muscle with prominent formation of phleboliths: a case report. *Auris, nasus, larynx* 2008;35(4):587-591.
- [87] Silva MI, Sassi LM, Rapoport A, Benedito VO, Machado R, Quebur MI. Aspectos clínicos e histológicos das anomalias vasculares da boca. *Revista Brasileira de Cirurgia de Cabeça e Pescoço* 2004;33(2):63-69.

- [88] Chava VR, Shankar AN, Vemanna NS, Cholleti SK. Multiple venous malformations with phleboliths: radiological-pathological correlation. *Journal of Clinical Imaging Science* 2013;3(Suppl 1):13.
- [89] Altug HA, Buyuksoy V, Okcu KM, Dogan N. Hemangiomas of the head and neck with phleboliths: clinical features, diagnostic imaging, and treatment of 3 cases. *Oral Surgery, Oral Medicine, Oral Pathology, Oral Radiology, and Endodontics* 2007;103(3):e60-64.
- [90] Scolozzi P, Laurent F, Lombardi T, Richter M. Intraoral venous malformation presenting with multiple phleboliths. *Oral Surgery, Oral Medicine, Oral Pathology, Oral Radiology, and Endodontics* 2003;96(2):197-200.
- [91] Kato H, Ota Y, Sasaki M, Arai T, Sekido Y, Tsukinoki K. A phlebolith in the anterior portion of the masseter muscle. *The Tokai Journal of Experimental and Clinical Medicine* 2012;37(1):25-29.
- [92] Gordon JS, Mandel L. Masseteric Intramuscular Hemangioma: Case Report. *Journal of Oral and Maxillofacial Surgery* 2014.
- [93] Mohan RP, Dhillon M, Gill N. Intraoral venous malformation with phleboliths. *The Saudi Dental Journal* 2011;23(3):161-163.
- [94] Babu BB, Tejasvi MLA, Avinash CK, B C. Tonsillolith: a panoramic radiograph presentation. *Journal of Clinical and Diagnostic Research* 2013;7(10):2378-2379.
- [95] Cooper MM, Steinberg JJ, Lastra M, Antopol S. Tonsillar calculi. Report of a case and review of the literature. *Oral Surgery, Oral Medicine, and Oral Pathology* 1983;55(3):239-243.
- [96] Giudice M, Cristofaro MG, Fava MG, Giudice A. An unusual tonsillolithiasis in a patient with chronic obstructive sialoadenitis. *Dentomaxillofacial Radiology* 2005;34(4):247-250.
- [97] Mesolella M, Cimmino M, Di Martino M, Criscuoli G, Albanese L, Galli V. Tonsillolith. Case report and review of the literature. *Acta Otorhinolaryngologica Italica* 2004;24(5):302-307.
- [98] Sezer B, Tugsel Z, Bilgen C. An unusual tonsillolith. *Oral Surgery, Oral Medicine, Oral Pathology, Oral Radiology, and Endodontics* 2003;95(4):471-473.
- [99] Bamgbose BO, Ruprecht A, Hellstein J, Timmons S, Qian F. The prevalence of tonsilloliths and other soft tissue calcifications in patients attending oral and maxillofacial radiology clinic of the University of Iowa. *International Scholarly Research Notices Dentistry* 2014;2014:839635.
- [100] Guevara C, Mandel L. Panoramic radiographic demonstration of bilateral tonsilloliths. *The New York State Dental Journal* 2011;77(3):28-30.

- [101] de Moura MD, Madureira DF, Noman-Ferreira LC, Abdo EN, de Aguiar EG, Freire AR. Tonsillolith: a report of three clinical cases. *Medicina Oral, Patologia Oral y Cirugia Bucal* 2007;12(2):E130-133.

IntechOpen

IntechOpen